

# We are IntechOpen, the world's leading publisher of Open Access books Built by scientists, for scientists

6,900

Open access books available

185,000

International authors and editors

200M

Downloads

Our authors are among the

154

Countries delivered to

TOP 1%

most cited scientists

12.2%

Contributors from top 500 universities



WEB OF SCIENCE™

Selection of our books indexed in the Book Citation Index  
in Web of Science™ Core Collection (BKCI)

Interested in publishing with us?  
Contact [book.department@intechopen.com](mailto:book.department@intechopen.com)

Numbers displayed above are based on latest data collected.  
For more information visit [www.intechopen.com](http://www.intechopen.com)



# Tissue Engineering in Maxillar Sinus Lifting: A Comparison of Differents Grafts and Confocal Laser Scanning Microscopic Evaluation

Andrea Ballini, Michele Scivetti, Stefania Cantore,  
Biagio Rapone, Gianfranco Favia and Felice Roberto Grassi  
*Department of Dental Sciences and Surgery-University of Bari "Aldo Moro"*  
*Italy*

## 1. Introduction

### 1.1 Tissue engineering

The term tissue engineering was originally coined to denote the construction in the laboratory of a device containing viable cells and biologic mediators (e.g., growth factors and adhesins) in a synthetic or biologic matrix, which could be implanted in patients to facilitate regeneration of particular tissues. The role of tissue oxygenation in wound healing became the focal point in the 1980s. Tissue oxygenation enhances phagocytic and bactericidal ability of host immune cells and supports collagen as well as other protein synthetic events. The importance of growth factors in enhancing wound healing has become the focus of research in the present day. In addition, a link has been established between tissue oxygenation and growth factors. Macrophage stimulation causes the release of angiogenic and other growth factors that support wound healing and resist infection [1]. In general, tissue engineering combines three key elements, namely scaffolds (collagen, bone mineral), signaling molecules (growth factors), and cells (osteoblasts, fibroblasts). Tissue engineering has been redefined presently as the relatively new, highly promising field of reconstructive biology, which draws on the recent advances in medicine and surgery, molecular and cellular biology, polymer chemistry, and physiology. These principles of tissue engineering have found widespread application in several branches of dentistry, such as periodontics, oral and maxillofacial surgery, and oral implantology. In the field of implant dentistry, the most frequently encountered problems at the implantation site are lack of adequate bone and proximity to anatomic structures, such as the maxillary sinus and the inferior alveolar nerve canal. Advanced surgical procedures that act as an adjunct in dental implants consist of sinus grafting and guided bone regeneration. These procedures are quite predictable when proper surgical protocols are established and followed. In this preliminary study we performed histological analisys using confocal laser scanning microscopy (CLSM), with the aim of evaluating the differences between graft and newly formed bone.

## 2. Confocal laser scanning microscopy

CLSM is a recent technique that has proved to be a valuable tool in the study of tissue and cell biology, as well as in the *in vivo* and *in vitro* detection of fluorescent markers. CLSM analysis shows a different fluorescence of different tissues. Specifically, the technique consists of illuminating the sample with a mono- and/or bi-chromatic punctiform laser source. The resulting emission energy is detected by a spatially filtered optical system, the pinhole, which eliminates light signals arising from out-of-focus planes. The possibility of visualizing each sample at different focal planes (optical sectioning) allows the acquisition of a series of images which can be then assembled for three-dimensional reconstruction and analysis [2]. In this study CLSM has been used because is a simple technique and also an easy way to underline differences between graft and human bone (either pre-existing and new-formed). The following picture shows how CLSM enhances graft matherial (bovine hydroxyapatite) compared with native bone. (Fig CLSM\_1 and \_2)

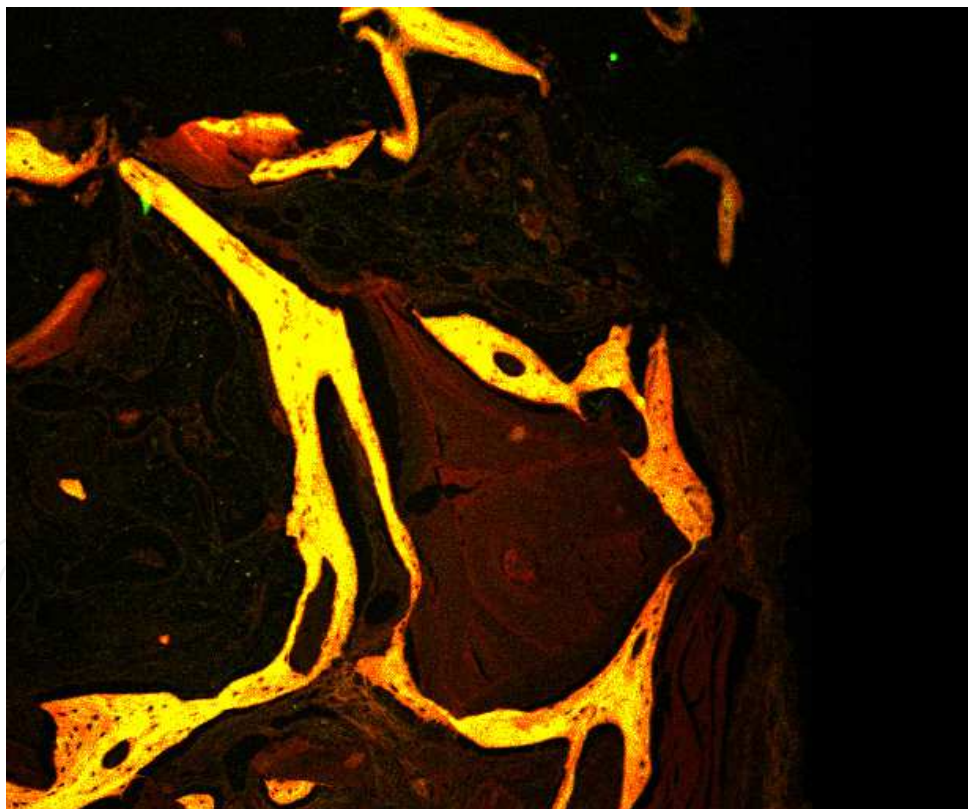


Fig. CLSM\_1. Well-defined difference between graft matherial (dark brown) and newly-formed bone (yellow) in a case of sinus-lift bone regeneration (CLSM, original magnification 100X).

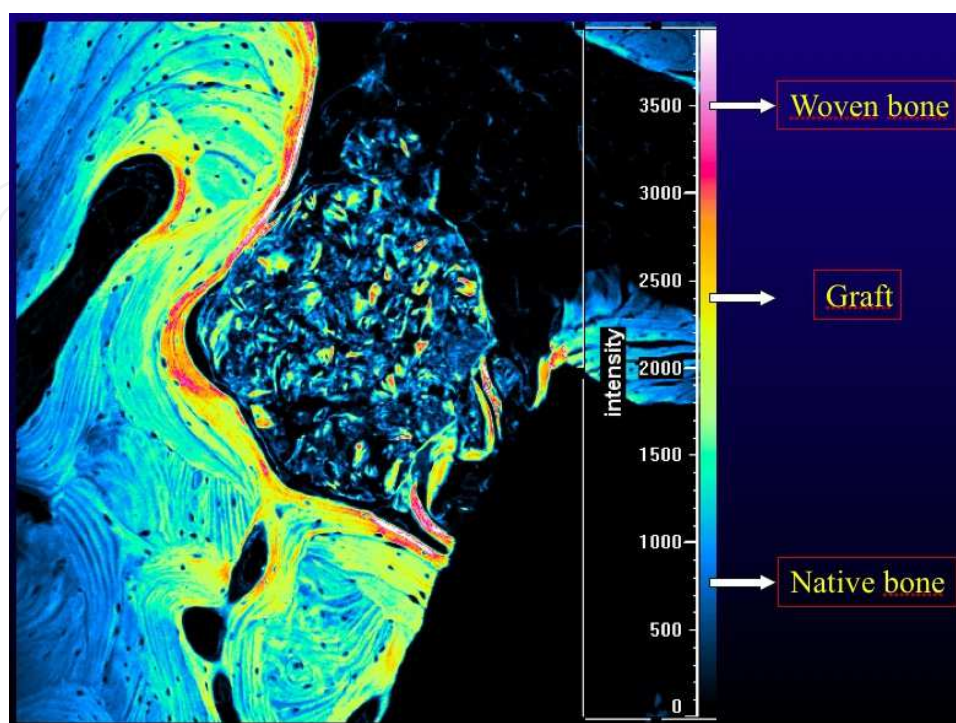


Fig. CLSM\_2. Specimen of regenerated bone observed by CLSM: the color scale allows to define several tissues, on the base of different emitting autofluorescence (CLSM; original magnification 200X).

### 3. Demineralized Freeze-Dried Bone Allograft (DFDBA) and Freeze-Dried Bone Allograft (FDBA)

Bone graft materials commonly used for these procedures are demineralized freeze-dried bone allograft (DFDBA) and freeze-dried bone allograft (FDBA). The osteoinductive properties of DFDBA have made it the grafting material of choice as compared to FDBA, xenografts, and alloplasts. However, the osteoinductive potential of DFDBA procured from different bone banks or from different batches of the same bank may vary highly. The bioactivity of DFDBA seems to be dependent on the age of the donor; the younger the donor the more osteoinductive the graft material [3]. This controversy as well as concerns about disease transmission has pushed clinicians toward using xenografts and alloplastic materials. Although these materials are biocompatible and are osteoconductive in nature, clinical outcomes are unpredictable. The problem that arises next is how to improve clinical outcomes by improving the properties of these grafts.

### 4. Platelet concentrates

In general, platelet concentrates are blood-derived products used for the prevention and treatment of hemorrhages due to serious thrombopenia of the central origin. The

development of platelet concentrates as bioactive surgical additives that are applied locally to promote wound healing stems from the use of fibrin adhesives. Since 1990, medical science has recognized several components in blood, which are a part of the natural healing process; when added to wounded tissues or surgical sites, they have the potential to accelerate healing. Fibrin glue was originally described in 1970 and is formed by polymerizing fibrinogen with thrombin and calcium. It was originally prepared using donor plasma; however, because of the low concentration of fibrinogen in plasma, the stability and quality of fibrin glue were low. These adhesives can be obtained autologously from the patient or can be obtained commercially (Tisseel, Baxter Healthcare). These products are heat-treated, thus immensely reducing, but not entirely eliminating, the risk of disease transmission. Therefore, the commercially available adhesives constitute an infinitely small risk of disease transmission. PRP is an autologous modification of fibrin glue, which has been described and used in various applications with apparent clinical success. PRP obtained from autologous blood is used to deliver growth factors in high concentrations to the site of bone defect or a region requiring augmentation. [4]

Platelet-rich plasma (PRP) is a platelet concentrate that has been used widely to accelerate soft-tissue and hard-tissue healing. The preparation of PRP has been described by several authors. Platelet-rich fibrin (PRF) was first described by Choukroun *et al.* in France. It has been referred to as a second-generation platelet concentrate, which has been shown to have several advantages over traditionally prepared PRP. Its chief advantages include ease of preparation and lack of biochemical handling of blood, which makes this preparation strictly autologous.

Platelets isolated from peripheral blood are an autologous source of growth factors. When platelets in a concentrated form are added to graft materials, a more predictable outcome is derived. Platelet-rich plasma (PRP) is an easily accessible source of growth factors to support bone- and soft-tissue healing. It is derived by methods that concentrate autologous platelets and is added to surgical wounds or grafts and to other injuries in need of supported or accelerated healing. A blood clot is the center focus of initiating any soft-tissue healing and bone regeneration. In all natural wounds, a blood clot forms and starts the healing process. PRP is a simple strategy to concentrate platelets or enrich natural blood clot, which forms in normal surgical wounds, to initiate a more rapid and complete healing process. A natural blood clot contains 95% red blood cells, 5% platelets, less than 1% white blood cells, and numerous amounts of fibrin strands.

A PRP blood clot contains 4% red blood cells, 95% platelets, and 1% white blood cells. PRF is in the form of a platelet gel and can be used in conjunction with bone grafts, which offers several advantages including promoting wound healing, bone growth and maturation, graft stabilization, wound sealing and hemostasis, and improving the handling properties of graft materials[5]. PRF can also be used as a membrane.

Clinical trials suggest that the combination of bone grafts and growth factors contained in PRP and PRF may be suitable to enhance bone density. In an experimental trial, the growth factor content in PRP and PRF aliquots was measured using Elisa kits. The results suggest that the growth factor content (PDGF and TGF- $\beta$ ) was comparable in both. Another

experimental study used osteoblast cell cultures to investigate the influence of PRP and PRF on proliferation and differentiation of osteoblasts. In this study, the affinity of osteoblasts to the PRF membrane appeared to be superior. [6] PRF has many advantages over PRP. It eliminates the redundant process of adding anticoagulant as well as the need to neutralize it. The addition of bovine-derived thrombin to promote conversion of fibrinogen to fibrin in PRP is also eliminated. The elimination of these steps considerably reduces biochemical handling of blood as well as risks associated with the use of bovine-derived thrombin. The conversion of fibrinogen into fibrin takes place slowly with small quantities of physiologically available thrombin present in the blood sample itself. Thus, a physiologic architecture that is very favorable to the healing process is obtained due to this slow polymerization process. Literature pertaining to PRF is found in French, and the material is being used widely in France. The popularity of this material should increase considering its many advantages. The findings of Wiltfang *et al.* [5] from a series of clinical trials are encouraging, in that they show improved properties of PRF as compared with PRP. In future, more histologic evaluations from other parts of the world are required to understand the benefits of this second-generation platelet concentrate.

## 5. The Antral Membrane Balloon Elevation (AMBE) technique

Many edentulous posterior maxilla are found to be encumbered by alveolar resorption and increased pneumatization of the sinus. These factors limit the quantity and quality of bone necessary for successful implant placement in these areas. One solution is to use shorter implants, but this often results in an unfavorable crown-root ratio. To create an improved environment in such regions, the classic sinus floor elevation with bone augmentation is a well-accepted technique. However, when the edentulous area is limited to a zone between 1 and 2 teeth, lifting the membrane becomes difficult and may subject it to iatrogenic injury. The antral membrane balloon elevation technique, which is introduced in this preliminary report, is a modification of the currently used sinus lift. It elevates the membrane easily and makes the antral floor accessible for augmentation with grafting materials. The edentulous posterior maxilla presents special challenges to the implant surgeon that are unique compared with other areas in the mouth. After tooth extraction, the initial decrease in bone width is secondary to resorption of the buccal bone plate. As the edentulous area continues to atrophy, there is a continuing loss of bone height and density and an increase in antral pneumatization [6,7]. The maxilla is primarily trabecular or spongy bone enclosed within thin cortical layers. In addition, the posterior maxilla contains the least dense bone in the oral environment. In some cases, the alveolus may be 2 mm high or shorter and of poor quality. Even if an individual were to have a modicum of bone, the resulting short endosseous implants would lead to insufficient anchorage, questionable integration, and unfavourable crown-root ratios. It has been written that as much as a minimum of 10 mm of bone height is necessary for successful implant stabilization and integration. The antral membrane balloon elevation (AMBE) technique lifts the sinus membrane with minimal trauma and is particularly useful in areas that are difficult to reach. It is beneficial when teeth are adjacent to the edentulous area that requires augmentation. The AMBE technique is accomplished with a limited incision, minimal mucoperiosteal flap reflection, and a small window. The membrane is elevated to the medial wall of the sinus cavity avoiding sharp

dissection around the roots of adjacent teeth. Thus, morbidity, blood loss, operative time, and postoperative pain and complications are reduced when compared with the conventional procedure. Sinus lift surgery is predictable and is usually not technically demanding. However, it is a more difficult surgical technique when teeth are adjacent to the edentulous area. It presents a far lesser challenge in the totally edentulous posterior maxilla [8]. The AMBE is a modification and combination of surgical techniques that adds sufficient bone height to allow placement of longer implants of up to 16 mm. The balloon operation and graft procedure described herein can be used to augment a severely atrophic ridge and does not depend on the accessible ridge height, as does the crestal approach, which uses trephines and osteotomes. Numerous approaches to the management of the deficient posterior maxilla have been described. Among them is the 2-stage classic approach with a 4- to 6-month interregnum required before the placement of implants. Fifteen millimeters or more of bone height can be achieved by this operation. A single-stage procedure following the same protocol as the 2-stage approach also is frequently used. The requirement here is for a beginning bone height of at least 4 to 6 mm. No lateral osteotomy into the antral cavity is required when using the Summers technique. It uses a number of concave-tipped, tapered osteotomes that are used to both enlarge and deepen the osteotomies while pushing the garnered bone apically beneath the tented membrane [9,10]. This is not unlike the green stick fracture method, which adds 2 to 3 mm of bone height beneath the elevated but unsullied sinus membrane. A recently published trephine bonecore sinus elevation graft is a new technique that permits autogenous bone grafting from 5 to 10 mm [11].

### **5.1 Advantages of the AMBE technique**

The use of the AMBE allows the surgeon to elevate the sinus membrane with minimal risk of tearing and with a conservative, tissue-sparing surgical approach. This reduces postoperative pain, bleeding, possibilities of infection, and the other morbid symptoms often associated with sinus lift procedures. The technique introduced in this article is often completed within 30 minutes. It is especially beneficial when access is difficult and when adjacent teeth are present next to the edentulous area.

### **5.2 Disadvantages of the AMBE technique**

Unlike some of the currently used techniques, which are performed from a crestal approach, AMBE requires a buccal fenestration and a larger incision than do other alternative operations.

The AMBE technique with augmentation has been a highly successful and predictable procedure. It facilitates lifting the sinus membrane gently and displacing it upward. The graft material is deposited into the space thus created. Implants may be placed simultaneously with the graft.

### **5.3 Aim**

The aim of our preliminary work is to evaluate the role of PRF in enhancing bone regeneration in maxillary sinus grafting, performed for implant placement and prosthetic rehabilitation.

## 6. Preliminary study

### 6.1 Patients and methods

This study included 10 (ten) patients that underwent to bilateral sinus lifting surgical procedure for implant placement and prosthetic rehabilitation. Sinus grafting has been performed in both sides in the same surgical procedure, using AMBE technique, following this protocol: right sinus received only bovine hydroxyapatite (Bio-Oss®) as grafting material, while left sinus received Bio-Oss® and PRF previously obtained by using Choukroun technique [12]. During the stage-two surgery, performer after four months, ten trephine cores were taken, using a trephine bur instead pilot(s) drill, one for each one for each graft site, and sent for histologic examination. Each specimen was first fixed in a buffered solution of 10% formalin and then immersed in an appropriate fixing and decalcifying solution (Mielodec, Bio Optica, Milan, Italy) for 90 min, rinsed in 70% ethyl alcohol for 30 min, and then conventionally processed for histopathologic paraffin embedding, thin sectioning at 5 mm perpendicular to the long axis, and staining with hematoxylin–eosin. Histological examination was carried out using a Nikon Eclipse E600 microscope (Nikon Corporation, Tokyo, Japan), equipped with argon-ion and helium-neon lasers, emitting at 488- and 543-nm wavelengths respectively, which allows both optical and confocal laser scanning microscopic analyses. The Nikon EZ C1 software (Nikon Corporation, version 2.10, Coord Automatisering) was used for image processing.

Statistical analyses were performed using the SPSS statistical software package for Microsoft Windows (version 14.0, SPSS Inc, Chicago, IL, USA).

### 6.2 Results

When analyzed by CLSM, the samples showed a strong natural autofluorescence pattern that was not homogenous, either quantitatively or qualitatively. We have inferred that such an intense fluorescence is due to the collagen component of the organic matrix, different between equine and human, in agreement with a number of studies reporting high autofluorescence intensity of collagen [13].

In fact, Figure 1 exhibited variable degrees of autofluorescence intensity, where higher scale values are related to higher fluorescence intensity. Different layers of bone showed different fluorescence extent and the autofluorescence variability was also qualitative, according to different stages of bone growth. Autofluorescence appears homogeneous in graft, where collagen fibrils are linear; otherwise, newly formed bone shows different autofluorescence degrees patterns as can be seen from Figure 2 due to the different hardness between woven and mature bone.

After statistical and histomorphometrical analysis, even if on a little cohort with few specimens, preliminary interesting results should be underlined. PRF seems to significantly enhance bone regeneration: in fact, in all specimens obtained from left graft side (Bio-Oss® with PRF) we observed large amounts of mature bone than contralateral side. At 4 months, histology showed a rich connective and vascular tissues surrounding graft particles with a low quantity of newly-formed woven bone (Figures 3(a), 3(b)) in right samples (only Bio-Oss®) while large amounts dense mature bone with marrow and blood vessels are observed in left samples

(Fig. 1). At higher magnification, it was observed that the graft remained engaged with the bone with a few number of resorption lacunae and no inflammatory infiltrate (Fig. 5). New bone was also functionally organized with osteons and Havers channels.

IntechOpen




Fig. 1. Histology of one of the biopsy cores at 4 months. A large amount of new and well-characterized bone is present. (CLSM, original magnification 100X).

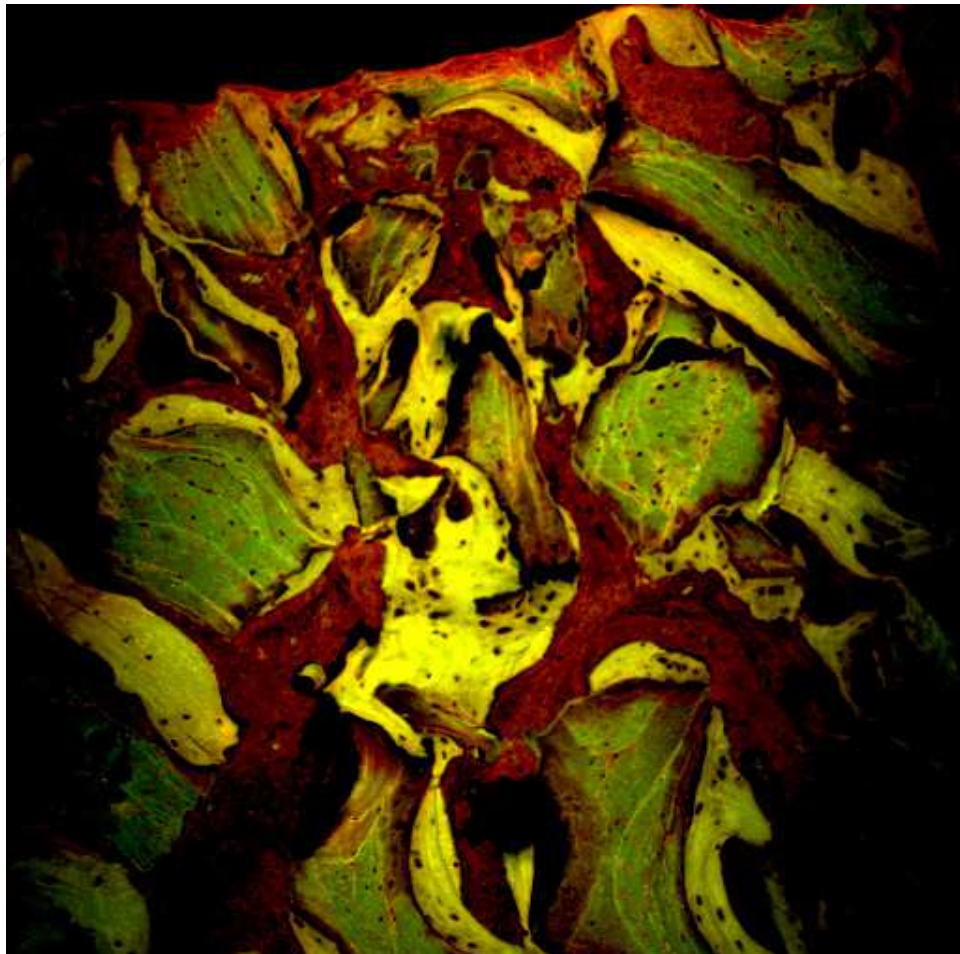
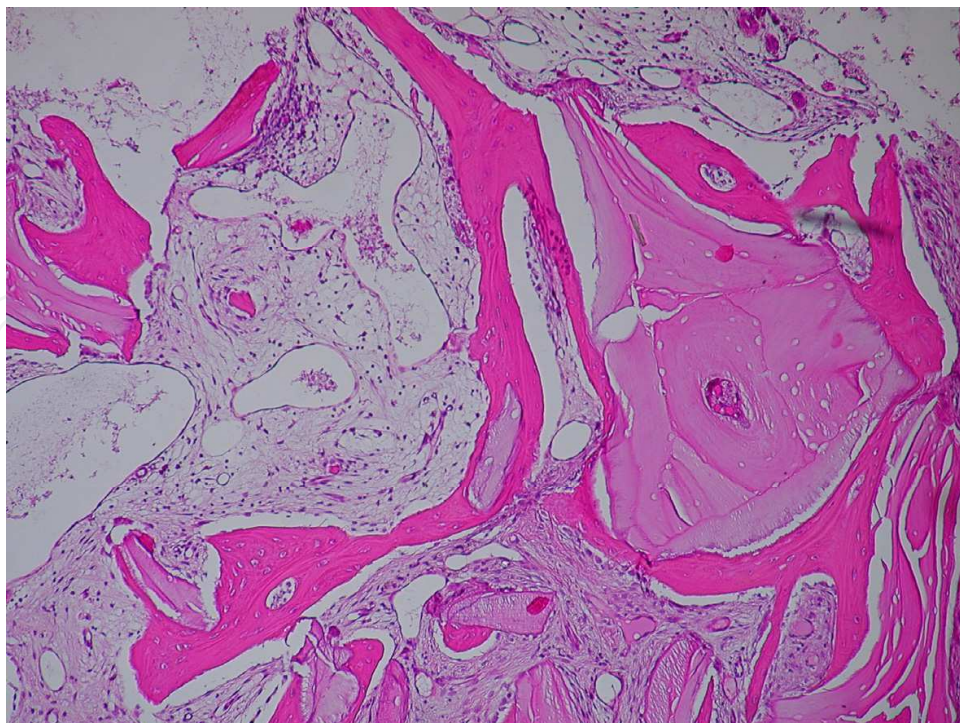


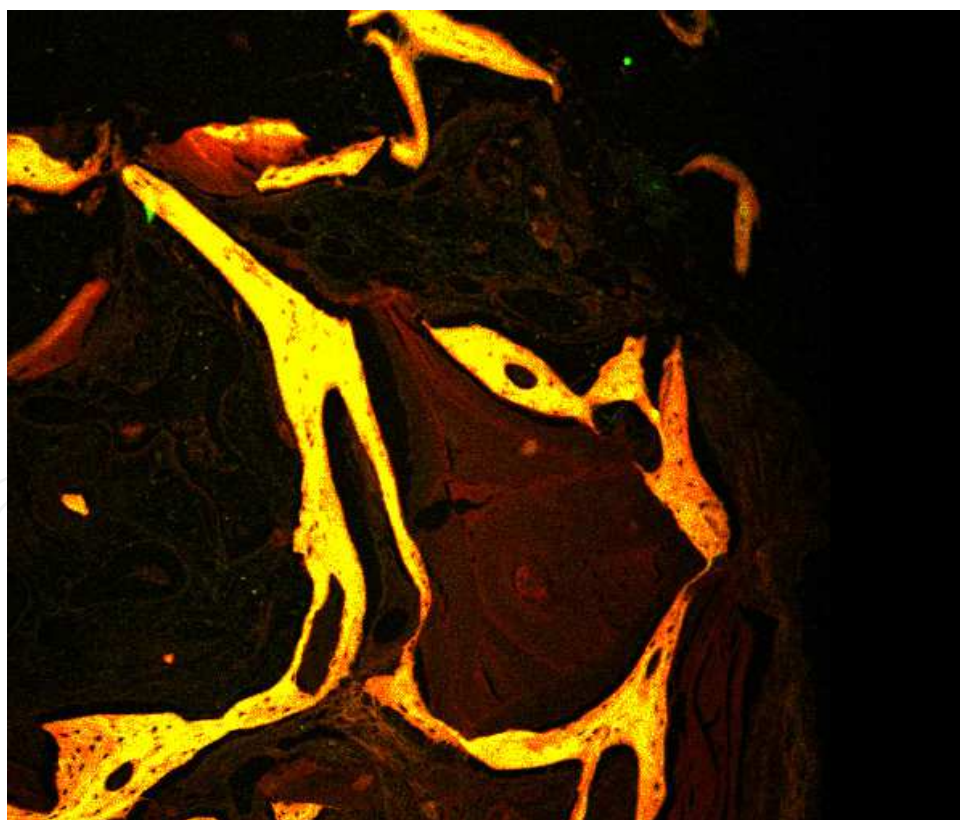
Fig. 2. Particular of Fig. 1, newly formed bone shows different autofluorescence degrees patterns. (CLSM, original magnification 200X).

The principles of tissue engineering have been applied to dental surgery. PRF is a natural medical device that seems to enhance wound healing and bone-soft tissue regeneration. The purpose of this preliminary study is to demonstrate the possibility of obtaining mature bone regeneration in humans with the combination of a biomaterial graft and PRF in a short period of time. Similar results are also been obtained with other proteins, such as rh-PDGF [14] and in our opinion all these results should be compared.

The limited conclusions of this study are that this technique provides a very important new amount of bone in a short period of time, and this bone already has all the characteristics of mature bone around the scaffold. Since there is a lack of available literature on this topic, this case study should encourage clinicians to use this technique, although further studies are needed to provide evidence-based conclusions.



(a)



(a)

Fig. 3. Right sample (only Bio-Oss®) showing connective and vascular tissues surrounding graft particles with a low quantity of newly-formed woven bone (Optical and CLSM, original magnification 200X)

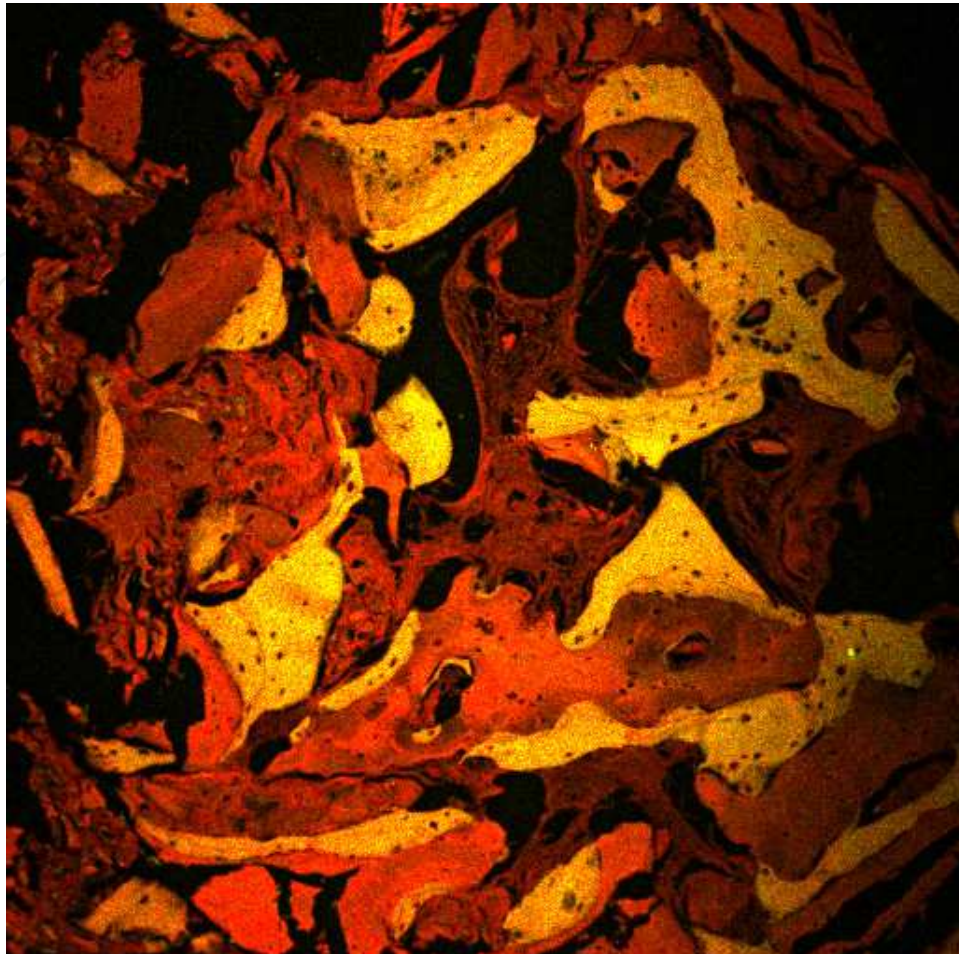


Fig. 4. Graft particles strictly closed with the bone, resorption lacunae and no inflammatory infiltrate. (CLSM, original magnification 100X).

## 7. Tissue engineering in the future

Bone tissue engineering is the general term for a number of ways by which bony tissue lost as a result of trauma and disease might be restored. It is possible to use cells alone (as in the case of bone marrow transplantation), however for most applications in regenerative medicine, cells in combination with appropriate scaffolds and carriers are more commonly used [15].

The design of scaffolds for bone tissue engineering includes a large number of factors related to structural integrity, superficial properties, incubating and cell growth conditions, and cell/biomaterial interactions [15]. One of the main factors that have an influence on the cellular and molecular mechanisms is the biophysical stimulus transmitted to the mesenchymal tissue [15]. This stimulus is linked to the architecture and the material properties of the scaffold that will serve as a host to receive external stimuli for matrix production. The ideal scaffold is capable of transferring the most favourable stimulus on the re-generating tissue hence allowing the times for the regeneration to be reduced and the optimal me-chanical properties of the regenerate to be obtained.

Mechano-regulation models can be utilized in bone tissue engineering to optimize the morphology, the porosity, the mechanical properties etc of scaffolds as well as the environment conditions. Such an issue has been recently investigated in different studies [15].

Stem cells are object of a growing interest from the international scientific community for their potentialities in regenerative medicine for their interactions with scaffolds.

At the moment, many laboratories working in this field are designing and setting up biocompatible and biodegradable scaffolds that might facilitate cell differentiation and *in vitro* reconstruction tissues of interest, before grafting them to patients.

Stem cells are defined as clonogenic cells capable of both self-renewal and multi-lineage differentiation. A population of these cells have been identified in human dental pulp.

Dental Pulp Stem Cells (DPSCs) were found in adults teeth and have been shown to differentiate, under particular conditions, into various cell types including osteoblast-like cells.

The stem cells in these locations lie dormant in a non-proliferating state until they are required to participate in local repair and regeneration. The stem cells in these locations lie dormant in a non-proliferating state until they are required to participate in local repair and regeneration.

In a few of our previous experiences we studied the osteoblastic phenotype developed by DPSCs cultured in osteogenic medium.

In particular, the typical osteoblast markers such as alkaline phosphatase (ALP), collagen type-I (COLL-1) and mineralized matrix production were analyzed. [16-18].

Results are promising and with DPSCs researchers can offer the possibility of realizing scaffolds for bone tissue engineering with a customized external shape as well as with structures to increase the mass transport of oxygen and nutrients.

## 8. Conclusions

A more robust integration is required, in future, between biology, mechanics and materials science. This should lead to the development of mechano-regulation models that more accurately describe physiological processes such as the fracture healing, the tissue genesis etc. Future perspectives of numerical simulations of biomaterial scaffolds for bone tissue engineering rely also on the development of new methods to account for the multi-scale dimension of the problems.

As a conclusion, bone tissue engineering is an emerging multidisciplinary field that can revolutionize the ways we improve the health and quality of life for millions of people worldwide. The future of computational models integrating the finite element method and mechano-regulation algorithms appears promising. More realistic models of biological/physiological processes need to be simulated; however, in order to make the implementation of these algorithms, affordable for a clinical use, more efforts need to be put into the development of powerful computational tools.

## 9. Acknowledgments

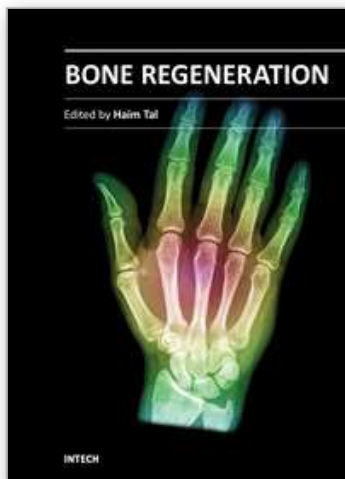
Funding for Stem Cell work was awarded from Ministero dell'Istruzione, dell'Università e della Ricerca -PRIN 2009 (Progetto di Ricerca d'Interesse Nazionale- Grant 2009)

## 10. References

- [1] Marx ER. Platelet-rich plasma: A source of multiple autologous growth factors for bone grafts. In : Lynch SE, Genco RJ, Marx RE, editors. Tissue engineering, applications in maxillofacial surgery and periodontics, Quintessence Publishing Co, Inc: Illinois; 1999. p. 71-82.
- [2] Scivetti M, Pilolli GP, Corsalini M, Lucchese A, Favia G. Confocal laser scanning microscopy of human cementocytes: analysis of three-dimensional image reconstruction. *Ann Anat.* 2007;189(2):169-74
- [3] Schwartz Z, Somers A, Mellonig TJ, Carnes DL Jr, Dean DD, Cochran DL, et al. Ability of commercial demineralized freeze-dried bone allograft to induce new bone formation is dependent on donor age but not gender. *J Periodontol* 1998;69:470-8.
- [4] Carlson ER. Bone grafting the jaws in the 21 st century: The use of platelet-rich plasma and bone morphogenetic protein. *Alpha Omegan* 2000;93:26-30.
- [5] Par Wiltfang J, Terheyden H, Gassling V, Acyl A. Platelet rich plasma (PRP) vs. platelet rich fibrin (PRF): Comparison of growth factor content and osteoblast proliferation and differentiation in the cell culture. *In: Report of the 2nd International Symposium on growth Factors (SyFac 2005).*
- [6] Sanchez AR, Sheridan PJ, Kupp LI. Is platelet-rich plasma the perfect enhancement factor? A current review. *Int J Oral Maxillofac Implants* 2003;18:93-103.
- [7] Thomas GJ. Sinus lifts: a possible solution to the atrophic maxilla. *J Macomb Dent Soc.* 1990;29:9-11.
- [8] Garg A. Augmentation grafting of the maxillary sinus for the placement of dental implants: anatomy, physiology, and procedure. *Implant Dent.* 1994;8:36-45
- [9] Woo I, Le BT. Maxillary sinus floor elevation: a review of anatomy and two techniques. *Implant Dent.* 2004;13:28-30.
- [10] Rosen P, Summers RB, Mellado JR, Salkin LM, Shanaman RH, Manuel HM. The bone-added osteotome sinus floor elevation technique: multicenter retrospective report of consecutively treated patients. *Int J Oral Maxillofac Implants.* 1999;14:853-858.
- [11] Soltan M, Smiler DG. Trephine bone core sinus elevation graft. *Implant Dent.* 2004;13:148-152.
- [12] Dohan DM, Choukroun J, Diss A, Dohan SL, Dohan AJ, Mouhyi J, Gogly B. Platelet-rich fibrin (PRF): a second-generation platelet concentrate. Part I: technological concepts and evolution. *Oral Surg Oral Med Oral Pathol Oral Radiol Endod.* 2006 Mar;101(3):e37-44. Epub 2006 Jan 19.
- [13] Prentice AID. Autofluorescence of bone tissues. *J Clin Pathol.* 1967;20:717-719.
- [14] De Angelis N, Scivetti M., Lateral Ridge Augmentation Using an Equine Flex Bone Block Infused with Recombinant Human Platelet-Derived Growth Factor BB: A Clinical and Histologic Study. *Int J Periodontics Restorative Dent.* 2011 Jul-Aug;31(4):383-8.

- [15] Ballini A, De Frenza G, Cantore S, et al. In vitro stem cell cultures from human dental pulp and periodontal ligament: new prospects in dentistry. *Int J Immunopathol Pharmacol*. 2007; 20: 9-16.
- [16] Ballini A, Capodiferro S, Cantore S, Crincoli V, Grassi FR. Dental pulp stem cells curriculum vitae. *Journal of osteology and biomaterials*. 2010; 1: 23-27.
- [17] Mori G, Centonze M, Brunetti G, Ballini A, Colucci S, Grano M, Grassi FR. Osteogenic properties of human dental pulp stem cells. *J Biol Regul Homeost Agents*. 2010; 24: 167-75.
- [18] Boccaccio A, Ballini A, Pappalettere C, Tullo D, Cantore S, Desiate A Finite Element Method (FEM), Mechanobiology and Biomimetic Scaffolds in Bone Tissue Engineering. *Int J Biol Sci*. 2011; 7(1):112-132

IntechOpen



## **Bone Regeneration**

Edited by Prof. Haim Tal

ISBN 978-953-51-0487-2

Hard cover, 340 pages

**Publisher** InTech

**Published online** 04, April, 2012

**Published in print edition** April, 2012

Bone is a specialized connective tissue, most prominently characterized by its mineralized organic matrix that imparts the physical properties that allow bone tissue to resist load, to support functional organs, and to protect highly sensitive body parts. Bone loss and bone damage may occur as a result of genetic conditions, infectious diseases, tumours, and trauma. Bone healing and repair, involves integrative activity of native tissues and living cells, and lends itself to the incorporation of naturally derived or biocompatible synthetic scaffolds, aimed at replacing missing or damaged osseous tissues. There are several modalities of bone regeneration including tissue engineering, guided bone regeneration, distraction osteogenesis, and bone grafting. This book concentrates on such procedures that may well be counted among the recent outstanding breakthroughs in bone regenerative therapy.

### **How to reference**

In order to correctly reference this scholarly work, feel free to copy and paste the following:

Andrea Ballini, Michele Scivetti, Stefania Cantore, Biagio Rapone, Gianfranco Favia and Felice Roberto Grassi (2012). Tissue Engineering in Maxillar Sinus Lifting: A Comparison of Differents Grafts and Confocal Laser Scanning Microscopic Evaluation, Bone Regeneration, Prof. Haim Tal (Ed.), ISBN: 978-953-51-0487-2, InTech, Available from: <http://www.intechopen.com/books/bone-regeneration/tissue-engineering-in-maxillar-sinus-lifting-a-comparison-of-differents-grafts-and-confocal-laser->

**INTECH**  
open science | open minds

### **InTech Europe**

University Campus STeP Ri  
Slavka Krautzeka 83/A  
51000 Rijeka, Croatia  
Phone: +385 (51) 770 447  
Fax: +385 (51) 686 166  
[www.intechopen.com](http://www.intechopen.com)

### **InTech China**

Unit 405, Office Block, Hotel Equatorial Shanghai  
No.65, Yan An Road (West), Shanghai, 200040, China  
中国上海市延安西路65号上海国际贵都大饭店办公楼405单元  
Phone: +86-21-62489820  
Fax: +86-21-62489821

© 2012 The Author(s). Licensee IntechOpen. This is an open access article distributed under the terms of the [Creative Commons Attribution 3.0 License](https://creativecommons.org/licenses/by/3.0/), which permits unrestricted use, distribution, and reproduction in any medium, provided the original work is properly cited.

IntechOpen

IntechOpen