

We are IntechOpen, the world's leading publisher of Open Access books Built by scientists, for scientists

6,900

Open access books available

186,000

International authors and editors

200M

Downloads

Our authors are among the

154

Countries delivered to

TOP 1%

most cited scientists

12.2%

Contributors from top 500 universities



WEB OF SCIENCE™

Selection of our books indexed in the Book Citation Index
in Web of Science™ Core Collection (BKCI)

Interested in publishing with us?
Contact book.department@intechopen.com

Numbers displayed above are based on latest data collected.
For more information visit www.intechopen.com



Surgical Complications with Synthetic Materials

Verónica Ma. De J. Ortega-Castillo¹ and Eduardo S. Neri-Ruz²

¹*Instituto Nacional de Perinatología, SSA*

²*Clínica de Especialidades de la Mujer, SEDENA
México D.F.
México*

1. Introduction

Many factors are involved in the pathogenesis of stress urinary incontinence (SUI) and for several decades attempts have been made to design the best device for its treatment. Experience and research have led to important breakthroughs, but there is currently no 100% effective treatment devoid of complications. As treatments have changed, the materials and access routes have given way to complications not previously reported that have sometimes been fatal. ObGyns, urologists and urogynecologists that perform surgical procedures for urinary incontinence would like to have the best kit and none of the reported complications, but in actuality, everyone has such complications. Every surgeon wonders: What was the cause of this complication? How will it be resolved? How is it classified? For future patients, how can such a complication be prevented? There have been reports of erosion and/or extrusion of material in new kits or devices for urinary incontinence in the urethra, bladder, vagina and ureter; as well as bleedings during the surgical procedure with injury to the pelvic or vaginal vessels, suburethral hematomas, intestinal perforation, voiding dysfunction, nerve lesions, bladder perforation, infections and abscesses, de novo overactive bladder, pelvic pain, necrotizing fasciitis and even death.

For decades, different types of materials have been used, such as monofilament or multifilament mesh, micropore, macropore, silicone, polyester, polypropylene and gore-tex, and none of them is free of complications.

This chapter is an overview of the complications reported according to the device or kit used, the type of mesh, with reference to the classification of complications of the International Continence Society (ICS) and the International Urogynecological Association (IUGA) and the treatments used to resolve these complications. It is necessary to adequately follow the technical procedure, check the correct position of the patient's legs, know the anatomy and receive periodical training.

2. History

The first to use synthetic material for a female urethral sling were Williams and Te Linde in 1962, followed by Ridley in 1966 and Morgan in 1970, using a polypropylene Marlex mesh for recurrent stress urinary incontinence. Subsequently, Morgan and colleagues (1985) reported at least a 5 year follow-up of patients with a 77.4% success rate. The complications

of this procedure include bladder neck obstruction and chronic cystitis. Subsequently, his patients had problems of erosion, infection and fistula formation

Vervigni and Natale (2001) described the three most important components for the use of a mesh in urological reconstructive surgery: the pore size, the type of fiber and its inflexibility. The pore size and the type of fiber may be used to classify mesh in 4 types: Mesh type 1, such as prolene, which is very soft (Ethicon, Endosurgery Inc, Summerville) and Marlex, having a long pore (>75µg) and usually made of polypropylene. This pore size allows macrophages to cross over and there is growth of fibroblasts (fibroplasias), as well as blood vessels (angiogenesis), and collagen deposits; White (1988) reported that because of these features, the mesh leads to changes to prevent infections and fibrous connective tissue grows around the tissue. Type II mesh such as Gore-tex (WL Gore & Associates Inc; Flagstaff, AZ) has a pore size under 10 µg in each one of its three dimensions (micropore). Mesh type III, such as Mersilene, is a macropore shaped naturally, but with micropore components that often include braided material and one/or multiple filaments. Mesh type IV has material with a pore size under a micron, and it is not used as a sling for urinary incontinence surgical procedures. (Table 1). Another important property is fiber composition: polypropylene mesh is made of monofilament and there are others made of multiple filaments which are commonly used. Multiple filament mesh often has a hole less than 10 µg wide, allowing small bacteria to infiltrate and proliferate. In theory, this small hole does not allow macrophages (16 to 20 µg) or white cells (9 a 15 µg) to pass through to kill bacteria, resulting in potential risk of infections. Flexibility or inflexibility of the mesh is another important feature. Prolene has a pore size twice as big as Marlex (1500 µg vs. 600 µg) and is much more flexible. Considering all of these properties, theoretically, prolene may have the lowest rate of erosion on the vagina and adjacent organs.

Type	Fiber	Pore Size
I	Monofilament	Macro(>75µm)
II	Multifilament	Micro(<75µm)
III	Multifilament	Variable
IV	Monofilament	Submicro

Table 1. Classification of Mesh Types

Ulmsten et al (1996) were the first to use a tension-free polypropylene mesh (TVT) to repair female stress urinary incontinence. They used a prolene mesh to support the mid urethra. The procedure needs to be performed with cystoscopy. This procedure was designed to avoid excessive tension and the kit is adjusted according to a cough test. The authors do not report any complication during surgery and they conclude that the procedure has a good success rate. This surgical procedure was known worldwide and surgeons started to use it, however some time later, complications were reported in publications. Primicero et al (1999) used the device in 24 patients, reporting a case of a patient with perforation of the external iliac vein and needing surgical repair. Brink (2000) reported a case of intestinal injury. Already in the year 2005 Atherton and Stanton reported that the bladder perforation rate with this kit has a 4.4% incidence in up to 71% of cases, but these were not the only complications. Delorme et al (2204) was the first to use the approach through the obturator hole. In this procedure it is not necessary to use cytoscopy. But some time later, urinary tract injuries were also documented.

Lapitan et al (2009), in their systematic Cochrane review, evaluated the different treatments for urinary incontinence: open retropubic vaginal suspension, among others, and the tension-free vaginal tape. This review included 46 articles for a total of 4738 women. The total cure rate for open retropubic vaginal suspension was 68.9% to 88%. When open retropubic vaginal suspension is compared to the tension-free tape in 12 studies, there is no difference in the success rate throughout the follow-up time. The available evidence according to Lapitan’s report is that there is no high morbidity or complication rate difference between these two surgical procedures.

Several commercial houses have started to change the mesh placement, with different access routes, either inside-out or outside-in; with suprapubic or transobturator approach.

3. Classification

Haylen et al (2011) in The Standardization and Terminology Committees of the International Urogynecological Association (IUGA) and the International Continence Society (ICS) and the joint IUGA/ICS working group on Complications Terminology seek to provide a terminology and a standardized classification for those complications arising directly from the insertion of prostheses and graft in female pelvic floor surgery. A significant increase in the use of an ever widening array of prostheses and graft has occurred in female pelvic floor surgery over the last 30 years. Terminology involved in the classification (Table 2), Classification of complications related directly to the insertion of prosthesis (Table 3) and Grades of pain (Table 4)

TERMS USED	DEFINITION
PROSTHESIS	A Fabricated substitute to assist a damaged body part or to augment or stabilize a hypoplastic structure
a. Mesh	A (prosthetic) network fabric or structure
b. Implant	A surgically inserted or embedded prosthesis
c. Tape(sling)	A flat strip of synthetic material
GRAFT	Any tissue or organ for transplantation. This term will refer to biological materials inserted.
a. Autologous Grafts	From the woman’s own tissues e.g. dura mater, rectus sheath or fascia lata
b. Allografts	From post-mortem tissue banks
c. Xenografts	From other species e.g. modifies porcine dermis, porcine small intestine, bovine pericardium
COMPLICATION	A morbid process or event that occurs during the course of a surgery that is not an essential part of that surgery
CONTRACTION	Shrinkage or reduction in size
PROMINENCE	Parts that protrude beyond the surface (e.g. due to wrinkling or folding with no epithelial separation)
SEPARATION	Physically disconnected (e.g. vaginal epithelium)
EXPOSURE	A condition of displaying, revealing, exhibiting or making accessible e.g. vaginal mesh visualized through separated vaginal epithelium
EXTRUSION	Passage gradually out of a body structure or tissue
COMPROMISE	Bring into danger
PERFORATION	Abnormal opening into a hollow organ or viscus
DEHISCENCE	A bursting opening or gaping along natural or sutured line

Table 2. Terminology involved in the Classification.

	CATEGORY			
GENERAL DESCRIPTION	A ASYMPTOMATIC	B SYMPTOMATIC	C INFECTION	D ABSCESS (+)
1 VAGINAL: no epithelial separation. Includes prominence (e.g. due to wrinkling or folding), mesh fiber palpation or contraction (shrinkage	1 A : Abnormal prosthesis or graft finding on clinical examination	1 B: Symptomatic e.g. unusual discomfort/ pain; dyspareunia (either partner); bleeding	1C: Infection (suspected or actual)	1D: (+)
2 VAGINAL: Smaller ≤ 1cm exposure	2A : Asymptomatic	2B: Symptomatic	2C: Infection	2D: (+)
3 VAGINAL: larger >1 cm exposure, or any extrusion	3A: Asymptomatic 1-3Aa if no prosthesis or graft related pain	3B: Symptomatic 1-3B(b-e) if prosthesis or graft related pain	3C: Infection 1-3C/1-3D (b-e) if prosthesis or graft related pain	3D: (+)
4 URINARY TRACT: Compromise or perforation including prosthesis(graft) perforation, fistula and calculus	4A: Small intra-operative defect e.g. bladder perforation	4B: Other lower urinary tract complication or urinary retention	4C: Ureteric or upper urinary tract complication	
5 RECTAL OR BOWEL: Compromise or perforation including prosthesis(graft) perforation and fistula	5A: Small intra-operative defect (rectal or bowel)	5B: Rectal injury or compromise	5C: Small or large bowel injury or compromise	5D (+)
6 SKIN AND/OR MUSCULOSKELETAL Complications including discharge pain lump or sinus tract formation	6A: Asymptomatic, abnormal finding or clinical examination	6B: Symptomatic e.g. discharge, pain or lump	6C: Infection e.g. sinus tract formation	6D (+)
7 PATIENT: Compromise including hematoma or systemic compromise	7A: Bleeding complication including hematoma	7B: Major degree of resuscitation or intensive care	7C: Mortality* *additional complication *no site applicable-S0)	
TIME (CLINICALLY DIAGNOSED)				
T1: Intraoperative to 48 hours	T2: 48 hours to 2 months	T3: 2 months to 12 months	T4: Over 12 months	
SITE				
S1: Vaginal area of suture line	S2: Vaginal: away from area of suture line.	S3: Trocar passage Exception: Intra-abdominal(S5)	S4: Other skin or musculoskeletal site	

Table 3. A Classification of complications related directly to the insertion of prosthesis (meshes, implants, tapes) or graft in female pelvic floor surgery.

To specify the presence of pain (by the patient only, not the partner) as part or all of the abnormal findings and the grade in terms of presence and severity of symptoms	
a	Asymptomatic or no pain
b	Provoked pain only (during vaginal examination)
c	Pain during sexual intercourse
d	Pain during physical activities
e	Spontaneous pain.

Table 4. Grades of pain: Sub classification of complication category

4. Pathophysiology

Jeffry et al (2001) reported that the bladder lesion rate due to perforation, increased in patients who had a prior anti-incontinence surgical procedure, this is due to the retropubic scarring process, and they also observed that the bladder perforation site is greater on the opposite side of the surgeon’s dominating hand.

Is a bladder lesion never observed during cystoscopy? Not really. Buchsbaum et al in (2004) reported that when they discarded the presence of bladder lesion after a cystoscopy, they found fluid leak through the incision or through the trocar path. Therefore, it is important to perform an appropriate bladder distension in order to separate the bladder folds and discard or confirm this complication appropriately. If necessary, methylene blue or indigo carmine can be used.

What is the anatomical relationship between vascular anatomy and placement of trocars in the insertion of a TVT? Muir et al (2003) did an anatomical dissection in cadavers and found that the TVT trocar goes through at an average distance of 4.9 cm from the external iliac artery and 3.2 cm from the obturator vessels, therefore, when the trocar goes in deviated laterally, it can cause an injury to the external iliac artery or vein. An inadequate technique when the trocar is inserted can cause severe complications.

Is the patient’s position as well as position of the legs important to avoid complications? Yes. Whiteside et al (2004) reported the anatomy of the neurovascular bundle in relation to the obturator fossa when the TOT is placed; the trocar goes through at a 1.1 ± 0.4 cm average distance from the medial branch of the obturator vessels and the average distance to the obturator nerve is 2.5 ± 0.7 cm. Hubka et al (2010) reported in a study of 14 embalmed bodies with poor position of the legs (group 1), 5 fresh frozen bodies with poor leg position (group 2) and 5 fresh frozen bodies with the proper leg position (group 3). After dissection, they measured the rami of the obturator nerve; in group 1, the average distance of the anterior ramus of the obturator nerve was at 8.4 mm (left) and at 8.9 mm (right). In group 2 the average was 5 mm (left) and at 8 mm (right) and the posterior ramus of the obturator nerve was at 5 mm (left) and 8 mm (right) respectively. In group 3, the average distance of the anterior ramus of the obturator nerve was 24mm (left) and 23 mm (right). Therefore, the correct position of the patient and of the legs ensures proper placement of the TVT-O.

Several factors have been proposed for complications with these kits: broad dissection with devascularization of the vaginal tissue, estrogen deficiency, excess tension, and presence of subclinical or overt infection before surgery, poor placement of the patient’s legs during surgery, poor knowledge of the surgical technique to place the kits and smoking.

Atis et al (2009) did an assessment in rats to see the reaction produced by the materials of the different slings in the bladder through histopathology (TVT, Vypro mesh, intravaginal plastic sling: IVS); they studied 30 rats with a similar control group, through laparotomy they placed a 0.5 to 1 cm mesh on the anterior bladder wall; after 12 weeks they did a histopathological test of the bladder. They found signs of inflammation, reaction to a foreign body, subserous fibrosis, necrosis and different degrees of collagen deposits. The Kruskal-Wallis and Posthoc Dunn tests were performed, observing that the inflammatory process was greater in the IVS ($p=0.001$) group than in the TVT ($p=0.006$) group, and Vypro ($p=0.031$); this IVS group also showed greater subserous fibrosis ($p=0.0001$); reaction to a foreign body ($p=0.0001$) and more collagen deposit ($p=0.0001$). The bladder showed a greater inflammatory response in the IVS group than in the TVT and Vypro ($p=0.041$, $p=0.028$) groups. This can play an important role in the results or complications of the slings.

But et al (2005) reported the probability of the mesh migrating and thus presenting some of the complications mentioned above. We should recall that meshes are a foreign object in the body and there may be a response to these.

Other causes may be that the kit is placed with greater tension than necessary, the quality of the tissue may be poor for several reasons such as: estrogen deficiency or due to poor dissection that leaves tissue with significant devascularization and thus with less blood irrigation which causes a deficiency in the fibroblast migration, in angiogenesis and therefore complications may arise. Surgeons who are going to place any of these devices should be well aware of the neurovascular anatomy of the pelvis as well as of the recommendations to place the chosen device.

Letouzey et al (2011) in an experimental study in rats, used macropore and multifilament polypropylene mesh contaminated with *Escherichia Coli*, removing it after 30 days. They concluded that the mesh infection forms a bacterial film that acts as a lining and this may be associated to prosthetic erosion without observing changes in the polymer of the mesh. Same results have Mammy et al (2011) highlights a link between infection and shrinkage in the model used (rats).

Withagen et al (2011) reported the risk factors associated to mesh exposure after insertion of the TVT in patients with pelvic organ prolapse; 12 months later only 294 (79%) patients were studied. The risk factors identified were smoking with a RR of 3.08 (IC 95% 1.09-8.72); the surgeons lack of experience (< than 10 years) RR 0.49 (IC 95% 0.29-0.83) and placement of a total Prolift RR 2.95 (IC 95% 1.24-7.01) although this is prolapse information, the TVT mesh was used.

5. Complications

We will divide complications into: intra-operative and post-operative (immediate and late).

5.1 Intra-operative complications

5.1.1 Bladder and urethral lesions

Abouassaly et al (2004) analyzed surgical complications of the tension free tape (TVT) in six institutions; the procedures were carried out by 6 different urologists. They checked the

management of each complication and the patient outcomes. Of the 241 patients, complications during surgery were bladder perforation in 48 patients (5.8%). Andonian et al (2005) compared SPARC with TVT reporting a similar percentage in both groups 24% and 23% respectively. Kristensen et al (2010) reported that out of 778 patients there was bladder perforation in 51 (6.6%). Lee et al (2010) reported 141 patients, with 9 patients (6.4%) having bladder perforation. When Novara et al (2010) in a systematic review of pubovaginal sling, retropubic tape (RT) and transobturator tape (TOT), made a comparison between procedures they reported that the TOT has less risk of bladder or vaginal perforation (OR: 2.5 IC: 1.75-3.57; $p < 0.00001$); but Revicky et al (2011) reported in 342 women with TVT, that the incidence of bladder lesion was 4.7% (16/342). Pushkay et al (2011) reported in 577 patients a high incidence of bladder perforation in the TVT group vs. the TVO-O group (5.4% vs. 0.6%; $p = 0.001$) George et al (2010) reported bladder perforation in 1.3% of the TVT group and none in the TOT group. Barry et al (2011) in a multicentric, randomized trial comparing TVT- Monarc at 3 months follow up, report a bladder lesion in 7/140 patients with TVT and 0/140 patients with Monarc. Rajendra et al (2011) reported 419 patients with stress urinary incontinence at 3 years follow up, 2 patients (0.5%) with bladder perforation. Latthe et al (2010) in his systematic review of 4 articles, report that bladder lesions with the TOT procedure have an OR 0.11 (IC 95% 0.05-0.25) and TVTO has an OR of 0.15 (IC 95% 0.06-0.35).

Bladder perforation during surgery due to the trocars is reported at 1.3% by George et al (2010) and up to 22% during the learning curve phase as described by Lebret et al (2001).

Up to date there have been no reports of urethral lesion during surgery.

Alvárez-Bandrés et al (2010) reported complications with the mini-sling system (50 patients with TVT-secur and 105 with Miniarc), there were bladder perforations in 0.64% total in both groups which were resolved with conservative bladder drainage management.

6. Bleeding

Primicero et al (1999) reported one lesion of the external iliac vein in a patient with TVT which had to be repaired through laparotomy; Zilbert and Farrel (2001) reported one patient with laceration of the external iliac artery and a neurovascular bundle lesion of the obturator ramus when the TVT was applied. Kuuva and Nilssons (2002) reported in 1455 patients a lesion incidence of large vessels and nerves in 2 patients (0.1%). Flock et al (2004) reported in 7 patients with TVT, blood loss quantified at 250 to 400 ml (2.1%); Abouassaly et al (2004) reported major bleeding of 500 ml in 16 women (2.5%) (16/421) with TVT. Kristensen et al (2010) in 778 patients with TVT reported hemorrhage that needed transfusion in 5 patients (0.6%), Barry et al (2011) observed that bleeding is minor in the group of patients with Monarc, 49 ml; in the TVT group it was 64 ml ($p < 0.05$), likewise surgical time was 14.6 min with Monarc and 18.5 min with TVT ($p < 0.001$). Rajendra et al (2011) reported that of 419 patients with TVT-O, 3 patients (0.8%) had a blood loss over 200 ml. Dunn et al (2004) reported 30 cases with vascular injury including 2 fatalities.

Brink (2000) reported one case of intestinal lesion that was repaired with a good outcome for the patient. Although we have minimally invasive procedures, these also pose arterial complications as Jung et al (2010) reported in a patient with TVT-secur who presented a

lesion of the internal pudendal artery. The complication was resolved with embolization of the artery guided with angiography, the treatment was successful. Jabureck et al (2011) documented that retropubic access surgery has a high lesion incidence of paraurethral, bladder and paravesical plexus vessels and even external iliac vessels.

7. Nerve lesion

Kuuva and Nilsson (2002) reported a nerve lesion 0.7/1000 with the placement of TVT.

7.1 Immediate post-surgical complications

7.1.1 Hematomas

Abouassaly et al (2004) reported a pelvic hematoma in 4 (1.9%) patients with TVT (4/421), Andonian et al (2005) reported a single case of an infected pelvic hematoma in the SPARC group and none in the TVT group. Pushky et al (2011) found that the formation of a hematoma is more frequent with TVT than with TVT-O (9.1% vs. 1.5%; $p=0.001$). Flock et al (2011) reported successful treatment of hematomas with retziusscopy in patients with TVT, of 685 patients, only 28 (4.1%) had a symptomatic hematoma in the Retzius space and in only 10 cases (1.5%) the volume exceeded 250 ml (range of 250-1000ml), the first case was resolved through laparotomy but the other cases were resolved successfully with a drainage through a retziuscopy; this is a minimally invasive procedure. Latthe et al (2010) in a systematic review of 12 papers observed that the formation of hematomas is lower with the TOT procedure compared with the TVT with an OR of 0.06 (IC 95% 0.01-0.30). When Álvarez-Bandrés et al (2010) compared TVT -secur and Miniarc; they reported one case of hematoma of the obturator fossa (0.64%) in the Miniarc group, which resolved spontaneously.

8. Voiding disorders

Abouassaly et al (2004) reported urinary retention (>24 hours later) in 47 patients (19.7%). Of the 47 patients, retention was present in only 32 less than 48 hours later, which were managed with clean intermittent catheterization, the remaining 15 patients also had clean intermittent catheterization for several days and only one patient had catheterization for 22 days. In order to resolve retention in 7 patients, the mesh had to be released and in 3 patients the mesh had to be cut. Kristensen et al (2010) reported difficulty in voiding in 56% and 16.6% had urinary retention, 34.3% of the patients had catheterization and 8% needed continuous catheterization. They conclude that patients who had voiding dysfunction prior to surgery have an OR of 1.80 to present urinary retention post surgically. Lee et al (2010) reported that 10 patients with TVT surgery, (7.1%) had urinary retention after surgery; patients were treated with clean intermittent catheterization less than 1 week, 10 patients (7.1%) needed continuous catheterization and in 2 patients the TVT mesh had to be cut. George et al (2010) reported voiding difficulty with a follow up of 2 years; in the TVT group 9.3% it lasted less than one week and in 2.6% it lasted more than one week. In the TOT group, the voiding dysfunction was 4.1% less than 1 week and 1.4% more than 1 week. Bladder perforation has a higher incidence in the TVT group. Revicky et al (2011) reported urinary retention in 9% (31/342). Sun and Tsai (2011) reported a voiding dysfunction

frequency of 6.8% with MONARC (5/73). Latthe et al (2010) in a systematic review of voiding disorder it is slightly lower in the TOT group than in the TVT-O group, but it wasn't statistically significant; for TOT the OR was 0.61 (IC 95% 0.35-1.07) and for TVT-O the OR was 0.81 (IC 95% 0.48-1.31)

9. Infection

Abouassaly et al (2004) reported infection of the supra pubic wound in one patient (0.4%). Kristensen et al (2010) reported infection of the urinary tract in 3.1%.

Flam et al (2009) had a patient with necrotizing fasciitis after placement of the TVT-O; they performed extensive debridement of the affected site, a colostomy, antibiotic therapy and 8 sessions of hyperbaric oxygen. Fig. 1

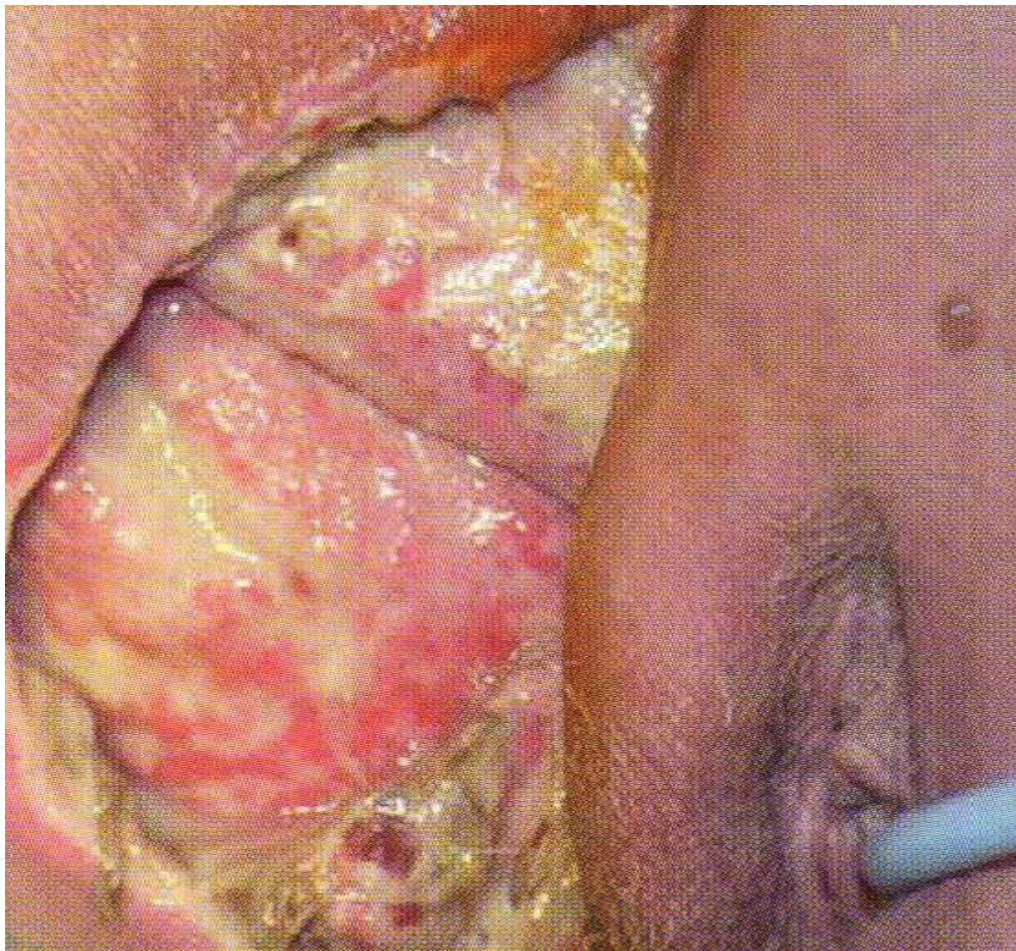


Fig. 1. 65-year-old with urinary incontinence, underwent a multifilament transobturator sling. At 14 months follow up, she experienced severe pelvic pain and vaginal discharge. Clinical examination revealed hyperthermia to 40°C, sling exposure at right vaginal sulcus and severe cellulitis in the genital-crural fold: Classification: 3C T4 S 2 and 6C T4 S3

Lee et al(2011) in four of the five patients presented with symptom of chronic vaginal discharge and these patients have a chronic infection forming a sinus tract into the vagina or other viscus, causing symptoms years after its mesh placement.

10. Late complications

10.1 De novo urgency

Abouassaly et al (2004) reported de novo urgency in 36 patients (15%), Lleberia-Juanós et al (2011) determined the incidence of de novo urgency with VT (in 243 patients) and with TVT-O (123 patients) evaluating them at 1, 6, 12 and 36 months after surgery. De novo urgency occurs in 13.4% of patients at 6 months, in 19.3 at 12 months and in 22.1% at 36 months. De novo urgency was more frequent in the TVT group than in the TVT-O group at 12 months (22.2% vs. 11.2%, $P=0.025$) and at 24 months (24.8% vs. 12.3%, $P=0.033$). Lee et al (2010) after 6 years of observation reported that de novo urgency was present in 28% (30/107) and de novo overactive bladder with incontinence was present in 27.1% (29/107) of patients. Sun and Tsai (2011) reported a frequency of de novo urgency of 2.7% with MONARC (2/73). Sabadell et al (2011) reported that 23 patients failed to TOT and a TVT was placed in a second surgery; de novo urgency occurs in 5 cases (21.7%) and it is treated with oral anticholinergics with a good clinical response.

11. Voiding disorders

Rajendra et al (2011) reported after a 3 year follow up, that 11 patients with TVT-O (2.6%) (11/419) were readmitted since 10 patients had voiding dysfunction, in 6 patients it was necessary to remove or cut the tape. Reich et al (2011) reported it in 108 patients in a follow up period of 102 months (range of 85-124). They did not find adverse effects of the mesh; 90% of these patients presented urgency incontinence and were dissatisfied with the surgical procedure. The same group studied 478 with TVT and voiding dysfunction, documenting it by measuring residual volume pre and post surgery; they reported micturition dysfunction in the first 2 weeks in 4 patients (0.8%), 7.1% had a residual volume of 50-100 ml at 3 months of surgery and 2.6% had a residual urine volume of over 100 ml. Therefore, a total of 93% of patients did not show bladder voiding disorders after a follow up of 12 to 74 months, which was documented through translabial ultrasound. Álvarez-Bandrés et al (2010) reported that the Miniarc group had urethral obstruction and thus the mesh had to be cut.

12. Pain and suprapubic discomfort

Abouassaly et al (2004) reported persisting suprapubic discomfort in 18 (7.5%) (18/241 patients). Rajendra et al (2011) after following up 419 patients for 3 years reported persistent pain in 15 patients (3.6%). Ross et al (2009) reported 199 patients, 105 of these had a TVT inserted and 94 patients had a TVT-O; they documented in the vaginal examination that the mesh was palpable in 68 (80%) in the TVT-O group and in 24 (27%) of the TVT group (RR 0.22, CI 95% 0.13-0.37, $P<0.001$); many women are also experiencing groin pain during vaginal palpation, 13 patients (15%) in the TVT-O group and 5 patients (6%) in the TVT group.

Latthe et al (2010) did a systematic review reporting that groin and/or thigh pain with the TVT-O procedure has an OR of 8.05 (IC 95% 3.78-17.16).

When Álvarez-Bandrés et al (2010) compared TVT-secur and Miniarc; the Miniarc group reported 4 (2.5%) patients with groin pain who were treated successfully with NSAID's.

12.1 Mesh extrusion

Abouassaly et al (2004) reported one patient with mesh erosion intravaginally (0.4%) (1/241); Andonian et al (2005) reported a single case of erosion in the SPARC group (1/41) and none in the TVT group (0/43). During the first year of follow up Rajendra et al (2011) reported vaginal erosion in 2.4 % (10/419); Ortega et al (2009) reported 1 case of erosion/extrusion of the mesh toward the urethra, the mesh was resected transvaginally with a good outcome. Wijffels et al (2009) reported 3 patients with urethral erosion/extrusion, treated by resection of the mesh endoscopically; Matsumura et al (2010) reported that after 2 years of surgery a 72 year old patient had an erosion/extrusion of the mesh in the urethra and a stone in the same site; management was done endoscopically with resection of the mesh and the stone was treated with lithotripsy with a good response.

Latthe et al (2010) in a systematic review reported that the mesh erosion of TVT-O has an OR 0.77 (IC 95% 0.22-2.72), while TOT and TVT have an almost similar OR 1.11 (IC 95% 0.54-2.28) Fig. 2

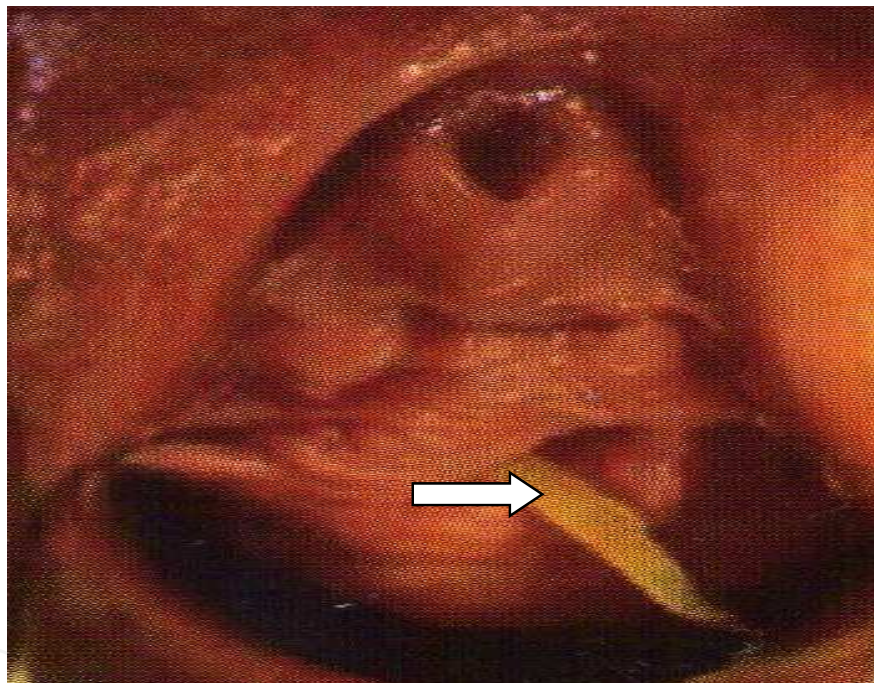


Fig. 2. A 47-years-old woman underwent a transobturator tape for USI. At 5 months follow-up, she reported vaginal discharge. Clinically she was febrile at 38°C with a large sling extrusion as depicted. Classification: 3C T3 S1

When Álvarez-Bandrés et al (2010) compared TVT-secur and Miniarc they reported vaginal erosion in 8 patients (5%); 4 patients required removal and closure of the vaginal wall, 2 were treated with local estrogen therapy in the vagina and 2 were asymptomatic and did not require any treatment.

Lo and Nusse (2010) reported a rare case of erosion over the bladder dome with formation of a stone 11 years after insertion of the TVT. Diagnosis was made with cystoscopy after the patient referred symptoms of the lower urinary tract for 5 months. A cysto-lithotripsy was performed observing a small filament of the mesh that was removed. A control cystoscopy was made

after one year showing recurrence of a stone in the same site of the previous surgery; surgery was performed in the office since the patient refused major surgery. Siegel (2006) reported one case of urethral necrosis and a urethra-vaginal fistula in a 64 year old woman, who needed 3 surgeries; initially TVT mesh fragments were removed and adjacent tissue needed debridement. A urethroplasty was performed as a second surgical procedure and in the third surgery a coaptation with an occlusive sling was made to repair the continence.

E Kobashi’s (2009) reviewed the different materials and reported the rate of extrusion of these. Table 5.

Material	Fiber type	Pore Size	Extrusion Rate (%)
Silicone	Monofilament	Macro	40-71
TVT	Monofilament	Macro	2-3
Prolapse repair	Monofilament	Macro	Up to 26
Obtape	Monofilament	Micro	5.4-16.6
Sparc/Monarc	Monofilament	Macro	1.7-2.4

Table 5. Synthetic mesh types, Characteristics and Associated Vaginal Extrusion rates.

Miraliakbari and Tse (2011) reported the first case of ureteral erosion in a 78 year old woman, the erosion was located in the distal third of the ureter, and the patient was treated successfully.

Rouprêt et al (2010) reported resection of the mesh via laparoscopy in 38 women with bladder erosion, vaginal extrusion, bladder obstruction and groin pain. The resection was complete with an operating time of 110 minutes (50 to 240 minute range) all patients reported a decrease in symptoms in a follow up period of 37.9 months (2-80 months range). However, the incontinence recurrence rate is 65.7% (25 patients). Laparoscopic resection of the TVT is safe and technically possible and solves patient’s symptoms.

Novara et al (2010) did a systematic review of pubovaginal sling; retropubic tape (RT) and transobturator tape (TOT) the subjective cure rate is similar among those procedures. Patients who have a TOT inserted have less risk of bladder or vaginal perforation (OR: 2.5 IC: 1.75-3.57; p<0.00001); less risk of hematoma (OR: 2.62; CI: 1.35-5.08; p=0.005) and less risk of urinary tract injury (OR: 1.35; CI: 1.05-1.72; p=0.02). This meta-analysis showed similar results between TVT-O and Monarc. The use of a retropubic tape had a higher objective rate than TOT, but the subjective cure is similar for both.

Mendoca et al (2011) report two cases with late urethral erosion with transobturator suburethral mesh (Obtape) the first one diagnosed 1 year after the surgery and the second one, a very late complication, occurring 4 years after the placement of the sling.

13. Intestinal lesion

With an intestinal lesion, patients refer abdominal pain, peritoneal irritation and sometimes fecal matter leak through the incisions of the kit used (TVT) as was reported by Meschia et al

(2002); Leboeuf et al (2003) and Castillo et al (2004). Leboeuf et al (2004) did a vaginal hysterectomy in a 73 year old patient due to genital prolapse followed by insertion of a TVT, during the post-op period she presented abdominal distension, and in an axial CAT scan they observed bowel distention and the bowel lesion site; they did an exploratory laparotomy where they found perforation of the mesentery without no other lesion, the perforation was repaired without complications.

Phillips et al (2009) reported a small size, thin patient with clinical signs of intestinal obstruction 3 years after the insertion of a TVT; she underwent an exploratory laparotomy where they found that the TVT mesh went through the peritoneum and was attached to the distal ileus; they did a resection and a primary anastomosis.

14. Nerve lesion

Geis and Dietl (2002) reported an ilioinguinal nerve lesion after insertion of a TVT, this due to the closeness of the nerve to the sites where the suprapubic incision was made. Rigaud et al (2010) said that pelvic or perineal pain may be a consequence of the obturator nerve or pudendal nerve lesion, a clinical sign that is underestimated.

15. Sexual function

Lau et al (2010) evaluated the impact of TVT-O insertion on sexual function in 56 women; they were evaluated through short questionnaires PISQ-12, UDI-16 and the IIQ7 before and 6 months after surgery. Their conclusion was that women perceived the surgery was successful but there was no improvement in sexual function.

16. Success and failure

Jain et al (2011) did a systematic review of TVT and TOT in the treatment of Mixed Urinary Incontinence (MUI). The subjective cure rate in 7 prospective trials was 56.4% (IC 95% 45.7-69.6%) in a follow up period of 34.9 ± 22.9 months. The cure rate for stress urinary incontinence varied from 85% to 97% in a follow up period of 6 to 31 months. TVT and TOT have a similar cure in mixed urinary incontinence. Madhuvrata et al (2011) in a systematic review and meta-analysis of the mini-sling (SIMS) compared the retropubic procedure: TVT (9 studies were included) and TVT-O (7 studies were included). The objective short term cure rate (6-12 months) was greater in urethral sling procedures than in mini-slings (SIMS) with a RR 1.20 (IC 95% 1.01-1.43) and RR 1.18 (IC 95% 1.04-1.34); a second surgery was necessary in the SIMS group with a RR 0.15 (IC 95% 0.05-0.42). Novara et al (2010) in a systematic review and meta-analysis of 39 papers reported that patients who had a sub-urethral mesh inserted the objective cure rate had an OR: 0.38 (IC95% 0.25-0.57; $p < 0.0001$) compared to the patients who had a Burch colpo-suspension procedure, although they had a high bladder perforation risk with an OR of 4.94 (IC 95% 2.09-11.68; $p = 0.00003$). Patil (2011) in a total of 12977 surgeries performed in 68 centers in the United Kingdom, 313 patients (2.4%) failed to sub-urethral slings. Chen et al (2011) in 30 patients followed up 1 year, who had a TVT-secur inserted, the success rate decreased significantly from 83.3% one month after surgery to 60.0% one year after the procedure.

17. Risk factors for surgical failure

Abdel-Fattah et al (2010) did a randomized report of 341 patients who had an outside-in transobturator (TOT-ARIS) and an inside-out (TVT-O). The risk factors for failure in the insertion of these meshes are: prior incontinence surgery (OR 1.41; 95% CI 1.18, 1.91; $P = 0.029$), preoperative urgency urinary incontinence (OR 1.78; 95% CI 1.21, 3.91, $P = 0.048$) during the first year of follow up of these surgeries.

Revicky et al (2011) evaluated the following risk factors to predict failure of the procedure: body mass index (BMI), age, type of analgesia, concomitant prolapse repair or prior surgery and obesity. These factors were not related to bladder injury or to urinary retention. Liu et al (2011) reported that obesity was not a risk factor for surgical failure just like Revicky reported in his review.

When Pushkar et al (2011) evaluated risk factors like age, body mass index and parity; there was no correlation with the complications of TVT and TVT-O.

18. Diagnosis

All patients who have had any of the anti-incontinence kits available in the market placed through the following procedures: retropubic, transobturator, outside-in or inside-out, or any minimally invasive kit, should be followed up long term since complications have been observed up to 11 years after insertion.

For intra-operative complications it is necessary to observe the patient's vitals: heart rate, blood pressure, oxygen saturation, state of awareness, so that if a disturbance is observed in any of these parameters, any necessary additional tests can be performed; like clinical labs to diagnose a vascular complication. A cystoscopy should be performed to assess the entire bladder with proper distention (250 cc minimum of physiologic solution) and with the proper instrument like a 70° lens cystoscope in order to check the bladder dome and lateral bladder walls; and for the urethra a 0° or 30° lens. In the event of doubt we can use methylene blue or indigo carmine to identify any damage that may be overlooked. Hematomas are identified according to the amount or size of the hematoma, it can go from mild pain, ecchymosis or hemorrhage through the puncture sites; this can be confirmed with imaging tests (ultrasound, axial CAT scan, MRI) depending on the patient's clinical status.

For post-operative complications: signs and symptoms of a patient who refers voiding disorders, residual urine should be measured using a clean bladder catheter or with translabial or suprapubic ultrasound in order to measure urine. De novo urgency can be documented by asking the patient directly and with a multichannel Urodynamic or Video-Urodynamic test, depending on the discomfort reported by the patient. During the patient's visit to the office, the vagina and urethra must be checked to discard any extrusion complications. A cystoscopy, a urethroscopy or an additional test must be performed depending on the symptoms reported by the patient. If the patient shows any irritation symptoms in the lower urinary tract or in the bowel, hematuria, dyspareunia, discomfort reported by the spouse, voiding disorders, pain, recurring infections, palpation of the mesh or recurring urinary incontinence, the integrity of the urinary tract and adjacent organs must be documented. If a patient has an intestinal injury, they will refer abdominal pain, signs of peritoneal irritation and sometimes leak of fecal matter through the incision of the kit used.

Rigaud et al (2010) said that when the patient refers perineal pain or chronic pelvic pain, immediately or shortly after insertion of a TVT or TOT Kit, this is probably associated directly or indirectly to a nerve injury (obturator nerve or pudendal nerve); diagnosis is made with the history that pain started after insertion of the kit and it can be confirmed with infiltration of local anesthesia through the mesh. This complication may be underestimated.

18.1 Treatment

Treatment of complications with these kits is still not standardized and it is something we will have to work on. When complications are severe, a multidisciplinary team is necessary to provide the best treatment and obtain favorable results for the patient.

18.2 Treatment of intra-operative complications

Complications due to punctures are caused by the passage of the kit's trocar, it can injure the urethra or the bladder, therefore, during the retropubic inside-out or outside-in procedure, a cystoscopy using a 70° lens should be performed in order to see the dome of the bladder and lateral walls; and a 0° to 30° lens to properly evaluate the urethra; so that under this direct view we can see whether the trocar is inside the bladder or urethra before placing the mesh. In the event the trocar punctures the bladder or urethra, it can be removed and inserted again. If there is no evidence of puncture to the urethra and/or bladder, it is now possible to place the mesh and a cystoscopy should be repeated. In the event of bladder injury, the size of the puncture should be measured and if small, a continuous drainage should be left with a Foley catheter for 48 to 72 hours. When the bladder damage is larger, a primary repair is necessary with 2 layers of absorbing suture (vicryl) and a continuous drainage using a Foley Catheter for 5 to 7 days should also be placed.

Flock et al (2011) reported 7 patients with TVT who had hemorrhage of 250ml to 400 ml that was managed with cauterization, compression or tamponade. Zorn et al (2005) recommend an exploratory laparotomy to repair the vascular damage and for proper hemostasis, or an embolization in patients who present massive bleeding after placement of the TVT; if we have this technique it provides good results.

Hubka et al (2010) recommend the patient be placed in a proper position in order to stay away from the obturator neurovascular bundle, this way, the success rate increases and the number of neurovascular damage decrease.

18.3 Treatment of post-operative complications

Abouassaly et al (2004) recommend in patients with voiding dysfunctions, the use of clean intermittent catheterization and if it has to be for a longer period of time, the mesh must be released, and in patients who continue with voiding disorders the mesh must be cut.

Abouassaly et al (2004) reported that when an infectious process arises, a culture must be performed and antibiotics should be prescribed depending on the sensitivity obtained; and as reported by Flam et al (2009) hyperbaric oxygen can be used to improve oxygenation of the tissue involved with excellent results. Abouassaly et al (2004) recommend for intravaginal mesh erosion, partial resection of the meshes and repair of the vaginal epithelium if the patient refers symptoms if not, she can just be observed as reported by

Alv rez-Bandr s et al (2010). Giri et al (2007) recommend a primary closure of the vaginal mucosa with a single line of a polyglactine 910, 2/0 suture avoiding inversion of the mucosa, when there is extrusion of the TVT mesh toward the vagina.

Roupr t et al (2010) reported surgical resection of the mesh through laparoscopy, in 38 women with complications like: bladder erosion, vaginal extrusion, bladder obstruction and groin pain. Resection was complete in all patients through laparoscopy; with an operating time of 110 minutes (range of 50 to 240 minutes) all patients reported a decrease in symptoms in a follow up period of 37.9 months (range 2-80 months). However, the recurrence rate of incontinence was 65.7% (25 patients). Laparoscopic resection of the TVT is safe and technically possible and solves patient's symptoms if we have the necessary instruments as well as trained personnel since it is a minimally invasive treatment alternative. In patients with de novo urgency, the use of anticholinergics is necessary to improve the patient's quality of life and in patients who report pelvic or perineal pain we can prescribe NSAID's.

When there is mesh extrusion and there is no satisfactory response to primary management such as the use of antibiotics or application of local estrogen in the organ extruded; the appropriate management is to remove the mesh. Fig 3. Removal of the mesh has been performed vaginally, via the urethra or the ureter through cystoscopy or laparoscopy with a good success rate and it is a minimally invasive procedure.

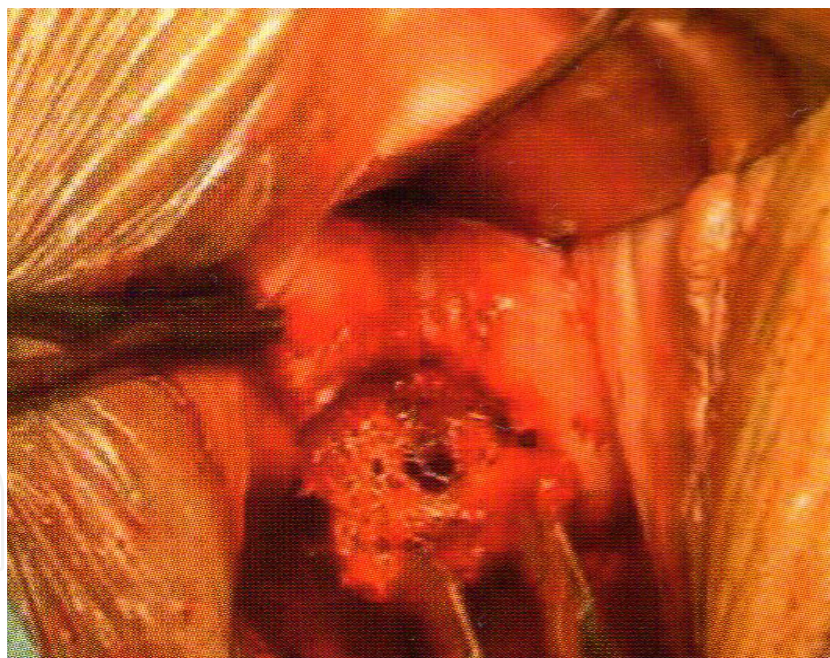


Fig. 3. The appropriated management is to remove the mesh when there is no satisfactory response to primary management.

Lo and Nusse (2010) recommend that in patients who have had a TVT or any other kit inserted to treat urinary incontinence and who show irritation symptoms of the lower urinary tract, a cystoscopy must be done to discard the presence of the mesh in the vagina, the urethra or in any other organ. If an intestinal injury is suspected, additional imaging test should be performed to document the injury and an exploratory laparotomy will be

necessary to repair the injury, with an intestinal resection and/or colostomy depending on the lesion found.

Rigaud et al (2010) said that for the treatment of pelvic or perineal pain we can infiltrate local anesthesia throughout the mesh or in the nerves involved, thus achieving temporary clinical improvement. However, although there was improvement in 2 of their 3 patients, the mesh had to be removed.

Mendoca et al(2011) describe a minimally invasive trans-urethral approach for the urethral erosion under local anaesthesia. They present some "tricks of the trade" on retrieving the tape trans-urethrally while maximizing the length of tape removed.

Khong and Lam (2011) in nine patients with synthetic mesh erosion when failed to respond to conservative measures were managed surgically with Surgisis. The size erosion ranged from 1 to 4 cm in diameter. The Surgisis may prove to be a useful option in the treatment of large vaginal mesh defects.

19. Conclusion

Whenever a surgical procedure involving the use of a mesh for urinary incontinence (any sort of mesh found in the market), the patient and her family must be informed about risks and complications. It is also important to have an informed consent for the patient stating the incidence of each of the complications pertaining to the specific kit used. Surgeons should follow patients at long term, since many complications occur after a long time, and they should be prepared to act quickly and effectively to solve the complication that has arisen. The use of new technology has improved the success rate of the surgical procedures for urinary incontinence, but clinically and legally, surgeons are the ones that should determine the use of these new devices and not the representatives of the commercial houses. We suggest that all suburethral slings are not created equal and that clinical adoption of new technology should follow clinical trials demonstrating efficacy, safety and long-term outcomes.

20. References

- Abdel-Fattah M, Ramsay I, Pringle S, Hardwick C, Ali H, et al(2010). Randomised prospective single-blinded study comparing 'inside-out' versus 'outside-in' transobturator tapes in the management of urodynamic stress incontinence: 1-year outcomes from the E-TOT study. *BJOG*.;117(7):870-8.
- Abouassaly R, Steinberg JR, Lemieux M, Marois C, Gilchrist LI, et al. (2004) Complications of tension-free vaginal tape surgery: a multi-institutional review. *BJU Int*. 94(1):110-3.
- Alvarez-Bandrés S, Hualde-Alfaro A, Jiménez-Calvo J, Cebrián-Lostal JL, Jiménez-Parra JD, et al. (2010).Complications of female urinary incontinence surgery with mini-sling system. *Actas Urol Esp*. 34(10):893-7.
- Andonian S, Chen T, St Denis B and Corcos J. (2005). Randomized clinical trial comparing suprapubic arc (SPARC) and tension-free vaginal tape (TVT): one year results. *Eur Urol* 47(4):537-41.

- Atherton MJ, Stanton SL. (2005) The tension-free vaginal tape reviewed: an evidence-based review from inception to current status. *BJOG*. 112 (5):534-46.
- Atis G, Arisan S, Ozagari A, Caskurlu T, Dalkilinc A, et al (2009). Tissue reaction of the rat urinary bladder to synthetic mesh materials. *ScientificWorldJournal*. 2;9:1046-51.
- Barry C, Lim YN, Muller R, Hitchins S, Corstiaans A, Foote A, Greenland H, Frazer M, Rane A (2008) . A multi-centre, randomized clinical control trial comparing the retropubic (RP) approach versus the transobturator approach (TO) for tension-free, suburethral sling treatment of urodynamic stress incontinence: The TORP study. *Int Urogynecol J Pelvic Floor Dysfunct* 19(2):171-8.
- Brink DM. (2000) Bowel injury following insertion of tension-free vaginal tape. *S Afr Med J*. May; 90(5):450-52.
- Buchsbaum GM, Moll C, Duecy EE. (2004) True occult bladder perforation during placement of tension-free vaginal tape. *Int Urogynecol J Pelvic Floor Dysfunct* 15:432.
- But I, Bratus D, Faganelj M. (2005) Prolene tape in the bladder wall after TVT procedure-intramural tape placement or secondary tape migration? *Int Urogynecol J Pelvic Floor Dysfunct* 16(1): 75-76.
- Castillo OA, Bodden E, Olivares RA, et al . (2004) Intestinal perforation: An infrequent complication during insertion of tension-free vaginal tape. *J Urol* 172:1364.
- Chen YH, Wang YJ, Li FP, Wang Q. (2011) Efficacy and postoperative complication of tension-free vaginal tape-Secur for female stress urinary incontinence. *Chin Med J* 124(9):1296-9.
- Delorme E, Droupy S, de Tayrac R, Delmas V. (2004) Transobturator tape (Uratape): A new minimally invasive procedure to treat female urinary incontinence. *Eur Urol* 45:203-7.
- Dunn JS Jr, Bent AE, Ellerkmann RM, Nihira MA, Melick CF. (2004) Voiding dysfunction after surgery for stress incontinence: literature review and survey results. *Int Urogynecol J Pelvic Floor Dysfunct* 15(1):25-31.
- Flam F, Boijesen M, Lind F. (2009) Necrotizing fasciitis following transobturator tape treated by extensive surgery and hyperbaric oxygen. *Int Urogynecol J Pelvic Floor Dys* 20(1):113-5.
- Flock F, Reich A, Muche R, et al (2004) Hemorrhagic complications associated with tension-free vaginal tape procedure. *Obstet Gynecol* 104: 989-94.
- Flock F, Kohorst F, Kreienberg R, Reich A. (2011) Retziuscopy: a minimal invasive technique for the treatment of retropubic hematomas after TVT procedure. *Eur J Obstet Gynecol Reprod Biol. Sep*;158(1):101-3.
- Geis K, Dietl J. (2002) Ilioinguinal nerve entrapment after tension-free vaginal tape (TVT) procedure. *Int Urogynecol J Pelvic Floor Dysfunction* 13:136.
- George S, Begum R, Thomas-Philip A, Thirumalakumar L, Sorinola O. (2010) Two-year comparison of tension-free vaginal tape and transobturator tape for female urinary stress incontinence. *J Obstet Gynaecol* 30(3):281-4.
- Giri SK, N Arsimhulu G, Flood HD, Skehan M and Drumm J (2007) Management of vaginal extrusion after tension-free vaginal tape procedure for urodynamic stress incontinence. *Urology* 69(6):1077-1080.
- Haylen BT, Freeman RM, Swift SE, Cosson M, Davila GW, et al. (2011) An International Urogynecological Association (IUGA)/ International Continence Society (ICS) joint

- terminology and classification of the complications related directly to the insertion of prostheses(meshes, implants, tapes) & grafts in female pelvic floor surgery. *Int Urogynecol J* 22:3-15.
- Hubka P, Nanka O, Martan A, Svabik K, Zvarova J, Masata J.(2010) Anatomical study of position of the TVT-O to the obturator nerve influenced by the position of the legs during the procedure: based upon findings at formalin-embalmed and fresh-frozen bodies. *Arch Gynecol Obstet* 284(4):901-5.
- Jaburek L, Jaburkova J, Lubusky M, Prochazka M.(2011) Risk of haemorrhagic complications of retropubic surgery in females: anatomic remarks. *Biomed Pap Med Fac Univ Palacky Olomouc Czech Repub.*Mar;155(1):75-7.
- Jain P , Jirschele K, Botros SM, Latthe P. (2011) Effectiveness of mid-urethral sling in mixed urinary incontinence: A systematic review and Meta-analysis. *Int Urogynecol J* 22 (8):923-32.
- Jeffry L, Deval B, Birsan A, et al (2001). Objective and subjective cure rates after tension-free vaginal tape for treatment of urinary incontinence. *Urology* 58:702-6.
- Jung YS, Lee JH, Shin TS, Han CH, Kang SH, et al.(2010) Arterial Injury Associated with Tension-Free Vaginal Tapes-SECUR Procedure Successfully Treated by Radiological Embolization. *Int Neurourol J.* 14(4):275-7.
- Khong SY and Lam A. (2011) Use of Surgisis mesh in the management of polypropylene mesh erosion into the vagina. *Int Urogynecol J.* 22:41-46.
- Kristensen I, Eldoma M, Williamson T, Wood S, Mainprize T, (2010). Complications of the tension-free vaginal tape procedure for stress urinary incontinence. *Int Urogynecol J.* 21(11):1353-7.
- Kuuva N, Nilsson CG: (2002) A nationwide analysis of complications associated with tension-free vaginal tape (TVT) procedure. *Acta Obstet Gynecol Scand* 81(1):72-7.
- Lapitan MC, Cody JD, Grant A. (2009) Open retropubic colposuspension for urinary incontinence in women. *Cochrane Database Syst Rev.* 15;(2):CD002912.
- Lau HH, Su TH, Su CH, Lee MY, Sun FJ.(2010) Short-term impact of tension-free vaginal tape obturator procedure on sexual function in women with stress urinary incontinence. *J Sex Med.* 7(4 Pt 1):1578-84.
- Latthe PM, Singh P, Foon R, Tooze-Hobson P.(2010) two routes of transobturator tape procedures in stress urinary incontinence: a meta-analysis with direct and indirect comparison of randomized trials. *BJU Int.* 106(1):68-76.
- Lebret T, Lugagne PM, Hervé JM, Barré P, Orsoni JL, et al.(2001) Evaluation of tension-free vaginal tape procedure. Its safety and efficacy in the treatment of female stress urinary incontinence during the learning phase. *Eur Urol.* 40(5):543-7.
- Leboeuf L, Mendez LE, Gousse AE. (2004) Small bowel obstruction associated with tension-free vaginal tape. *Urology* 63(6):1182-4.
- Leboeuf L, Tellez CA, Ead D, et al. (2004) Complication of bowel perforation during insertion of tension-free vaginal tape. *J Urol* 170:1310; discussion 1310, 2003.
- Lee JH, Cho MC, Oh SJ, Kim SW, Paick JS.(2010) Long-term outcome of the tension-free vaginal tape procedure in female urinary incontinence: a 6-year follow-up. *Korean J Urol.* 51(6):409-15.
- Lee JKS, Agnew G, Dwyer. (2011) Mesh-related chronic infections in silicone-coated polyester suburethral sling. *Int Urogynecol J* 22:29-35.


- Letouzey V, Cornille A, Mourtialon P, Garric X, Lavigne J. et al.(2011) What have we learned from basic science for mesh complication in pelvic floor reconstructive surgery? From infection to polypropylene degradation?. *Int Urogynecol J* 22 (Suppl 1): S-185-186.
- Liu PE, Su CH, Lau HH, Chang RJ, Huang WC,et al(2011). Outcome of tension-free obturator tape procedures in obese and overweight women. *Int Urogynecol J*. 22(3):259-63.
- Lleberia-Juanós J, Bataller-Sánchez E, Pubill-Soler J, Mestre-Costa M, Ribot-Luna L, et al. (2011) De novo urgency after tension-free vaginal tape versus transobturator tape procedure for stress urinary incontinence. *Eur J Obstet Gynecol Reprod Biol*. 155(2):229-32.
- Lo TS, Nusee Z.(2010) Repeated endoscopic excision of an eroding calcified mesh sling-continued follow-up is required. *J Minim Invasive Gynecol*.17(3):383-5.
- Madhuvrata P, Ford J, Lim CP, Fattah MA. (2011) A systematic review and meta-analysis of single-incision slings in surgical management of female stress urinary incontinence. *Int Urogynecol J*, 22(Suppl 1) S-01.
- Matsumura E, Tasaki S, Ashikari A, Toyosato T, Ashimine S, et al. (2010) A case report of transurethral resection of eroding urethral mesh after a tension-free vaginal tape procedure. *Hinyokika Kyo*. 56(11):655-7.
- Mamy L, Letouszey V, Lavigne JP, Garric X, Gondry J, et al. Correlation between shrinkage and infection of implanted synthetic meshes using an animal model of mesh infection. *Int Urogynecol J*. 22:47-52.
- Mendoca TM, Martinho D, Dos Reis JP.(2011) Late urethral erosion of transobturator suburethral mesh (Obtape): a minimally invasive management under local anaesthesia. *Int Urogynecol J* 22:37-39.
- Meschia M, Busacca M, Pifarotti P, et al (2002) Bowel perforation during insertion of tension-free vaginal tape (TVT). *Int Urogynecol J Pelvic Floor Dysfunct* 13:263-5.
- Miraliakbari H and Tse E.(2011) Ureteral erosion of a transvaginal tape. *Can Urol Assoc J*. 5(3): E44-E46.
- Morgan JE. (1970) A sling operation using Marlex polypropylene mesh for treatment of recurrent stress incontinence. *Am J Obstet Gynecol* 106:369-377.
- Morgan JE, Farrow GA, Stewart FE. (1985)The Marlex sling operation for the treatment of recurrent stress urinary incontinence: a 16-year review. *Am J Obstet Gynecol*. Jan 15;151(2):224-6.
- Muir TW, Tulikangas PK, Fidela Paraiso M, Walters MD.(2003) The relationship of tension-free vaginal tape insertion and the vascular anatomy. *Obstet Gynecol*. 101(5 Pt 1):933-6.
- Novara G, Artibani W, Barber MD, Chapple CR, Costantini E, et al(2010). Updated systematic review and meta-analysis of the comparative data on colposuspensions, pubovaginal slings, and midurethral tapes in the surgical treatment of female stress urinary incontinence. *Eur Urol*. 58(2):218-38.
- Ortega C, Velázquez S, Kunhardt R.(2009) Urethral erosion secondary to the placing of tension-free vaginal tape. A case report. *Ginecol Obstet Mex*; 77(8):393-5.
- Patil A. (2011) How do Urogynaecologists treat failed suburethral slings? Experience from the British Society of Urogynaecology database and literature review. *Int Urogynecol J*; 22 (Suppl 1) S:21

- Phillips L, Flood CG, Schulz JA.(2009) Case report of tension-free vaginal tape-associated bowel obstruction and relationship to body habitus. *Int Urogynecol J Pelvic Floor Dysfunct* 20(3):367-8
- Primicerio M, De Matteis G, Montanino OM, Marceca M, Alessandrini A, et al (1999) Use of the TUT (Tension-free Vaginal Tape) in the treatment of female urinary stress incontinence. Preliminary results. *Minerva Ginecol* 51(9):355-8.
- Pushkar DY, Godunov BN, Gvozdev M, Kasyan GR.(2011) Complications of mid-urethral slings for treatment of stress urinary incontinence. *Int J Gynaecol Obstet.* Apr;113(1):54-7.
- Rajendra M, Han HC, Lee LC, Tseng LA, Wong HF.(2011) Retrospective study on tension-free vaginal tape obturator (TVT-O). *Int Urogynecol J.* Sep 3. [Epub ahead of print]
- Reich A, Kohorst F, Kreienberg R, Flock F. (2011) Long-term Results of the Tension-free Vaginal Tape Procedure in an Unselected Group: A 7-Year Follow-up Study. *Urology* 78(4): 774-7.
- Revicky V, Mukhopadhyay S, De Boer F, Morris EP.(2011) Obesity and the incidence of bladder injury and urinary retention following tension-free vaginal tape procedure: retrospective cohort study. *Obstet Gynecol Int.* ;2011:746393.
- Ridley JH (1966). Appraisal of the Goebell-Frangenheim-Stoeckel sling procedure. *Am J Obstet Gynecol* 95:714-721.
- Rigaud J, Delavierre D, Sibert L, Labat JJ.(2010) Management of chronic pelvic and perineal pain after suburethral tape placement for urinary incontinence. *Prog Urol* 20(12):1166-74.
- Ross S, Robert M, Swaby C, Dederer L, Lier D, et al (2009). Transobturator tape compared with tension-free vaginal tape for stress incontinence: a randomized controlled trial. *Obstet Gynecol.* 114(6):1287-94.
- Rouprêt M, Misraï V, Vaessen C, Cour F, Haertig A, (2010). Laparoscopic surgical complete sling resection for tension-free vaginal tape-related complications refractory to first-line conservative management: a single-centre experience. *Eur Urol* 58(2):270-4.
- Siegel AL. (2006) Urethral necrosis and proximal urethro-vaginal fistula resulting from tension-free vaginal tape. *Int Urogynecol J Pelvic Floor Dysfunct* 17(6):661-4.
- Sun MJ and Tsai HD (2011) Is transobturator suburethral sling effective for treating female urodynamic stress incontinence with low maximal urethral closure pressure? *Taiwan J Obstet Gynecol* 50(1):20-4.
- Ulmsten U, Henriksson L, Johnson P, Varhos G (1996). An ambulatory surgical procedure under local anesthesia for treatment of female urinary incontinence. *Int Urogynecol* 7:81-86
- Vervigni M, Natale F (2001) The use of synthetics in the treatment of pelvic organ prolapse. *Curr Opin Urol*; 11: 429-35.
- Wijffels SA, Elzevier HW, Lycklama a Nijeholt AA. (2009) Transurethral mesh resection after urethral erosion of tension-free vaginal tape: report of three cases and review of literature. *Int Urogynecol J Pelvic Floor Dysfunct*; 20(2):261-3.
- Withagen MI, Vierhout ME, Kluivers KB, Milani AL.(2011) Risk factors for exposure after tension-free vaginal mesh procedure. *Int Urogynecol J* 22(Suppl 1): S83-84.
- Williams TJ, Telinde RW.(1962) The sling operation for urinary incontinence using mersilene ribbon. *Obstet Gynecol* 19: 241-5

- Whiteside JL, Weber AM, Meyn LA, Walters MD. (2004) Risk factors for prolapse recurrence after vaginal repair. *Am J Obstet Gynecol* 191(5):1533-8.
- Zorn KC, Daigle S, Belzile F, Tu le M, (2005) Embolization of a massive retropubic hemorrhage following a tension-free vaginal tape (TVT) procedure: case report and literature review. *Can J Urol* 12(1):2560-3.

IntechOpen

IntechOpen



Urinary Incontinence

Edited by Mr. Ammar Alhasso

ISBN 978-953-51-0484-1

Hard cover, 324 pages

Publisher InTech

Published online 04, April, 2012

Published in print edition April, 2012

Management strategies are framed within a multidisciplinary team structure and as such a range of specialists ranging from psychologists, specialist nurses, gynaecologists and urologists author the chapters. There are some novel methods outlined by the authors with their clinical application and utility described in detail, along with exhaustive research on epidemiology, which is particularly relevant in planning for the future.

How to reference

In order to correctly reference this scholarly work, feel free to copy and paste the following:

Verónica Ma. De J. Ortega-Castillo and Eduardo S. Neri-Ruz (2012). Surgical Complications with Synthetic Materials, Urinary Incontinence, Mr. Ammar Alhasso (Ed.), ISBN: 978-953-51-0484-1, InTech, Available from: <http://www.intechopen.com/books/urinary-incontinence/complications-of-genital-prolapse-and-urinary-incontinence-surgery>

INTech
open science | open minds

InTech Europe

University Campus STeP Ri
Slavka Krautzeka 83/A
51000 Rijeka, Croatia
Phone: +385 (51) 770 447
Fax: +385 (51) 686 166
www.intechopen.com

InTech China

Unit 405, Office Block, Hotel Equatorial Shanghai
No.65, Yan An Road (West), Shanghai, 200040, China
中国上海市延安西路65号上海国际贵都大饭店办公楼405单元
Phone: +86-21-62489820
Fax: +86-21-62489821

© 2012 The Author(s). Licensee IntechOpen. This is an open access article distributed under the terms of the [Creative Commons Attribution 3.0 License](https://creativecommons.org/licenses/by/3.0/), which permits unrestricted use, distribution, and reproduction in any medium, provided the original work is properly cited.

IntechOpen

IntechOpen