

# We are IntechOpen, the world's leading publisher of Open Access books Built by scientists, for scientists

6,900

Open access books available

185,000

International authors and editors

200M

Downloads

Our authors are among the

154

Countries delivered to

TOP 1%

most cited scientists

12.2%

Contributors from top 500 universities



WEB OF SCIENCE™

Selection of our books indexed in the Book Citation Index  
in Web of Science™ Core Collection (BKCI)

Interested in publishing with us?  
Contact [book.department@intechopen.com](mailto:book.department@intechopen.com)

Numbers displayed above are based on latest data collected.  
For more information visit [www.intechopen.com](http://www.intechopen.com)



# Aseptic Meningitis Caused by Enteroviruses

Takeshi Hayashi, Takamasa Shirayoshi and Masahiro Ebitani

*Department of Neurology,  
Fuji Heavy Industries Health Insurance Corporation,  
Ota General Hospital,  
Japan*

## 1. Introduction

A broad range of microorganisms cause meningitis; viruses, bacteria, mycobacteria, mycoplasma, spirochetes, fungi, and protozoa have all been identified as causative agents. Some pathogens almost exclusively affect immunocompromised hosts, and some are confined only to endemic areas, but viruses are the most common pathogen worldwide. It is estimated that about 75,000 people in the United States suffer from viral meningitis annually. The annual incidence of bacterial meningitis in the United States is approximately 3 per 100,000 (Tunkel & Sheld, 1993), therefore, viral meningitis is far more common. Although the exact number of cases varies among countries, viral meningitis is the most common meningitis in almost all countries throughout the world.

Although many patients with viral meningitis are not admitted to a hospital because of an uneventful clinical course, 25,000-50,000 are hospitalized every year in the United States (Khetsuriani et al., 2003; Wang et al., 2002). The estimated mean charge for viral meningitis-associated hospitalization from 1993-1997 was between USD 6,562 and 8,313, resulting in annual estimated hospitalization costs between USD 234 and 310 million (Khetsuriani et al., 2003; Parasuraman et al., 2001). Viral meningitis is, in most cases, a benign disease with a self-limiting clinical course, but the economic impact it imposes is large. Furthermore, the disease may appear as a small to large outbreak. If large outbreak occurs, they are likely to be enormous economic losses. To better characterize the features of viral meningitis and the causative agents are therefore of importance.

Many viruses can cause meningitis, and the frequency at which each virus is identified differs geographically and yearly. In addition, a causative virus is not identified in many cases of aseptic meningitis. In spite of extensive investigation, no causative agents are identified in about one-third of the cases of aseptic meningitis. When identified, however, enteroviruses are the most frequent agent in every investigated series (CDC, 2003; Kao et al., 2003; Meyer et al., 1960; Tyler & Martin, 1993; Wang et al., 2002), being detected in from 30 to 83% of the cases. Some studies have revealed that enteroviruses are also the most common cause of meningitis in infants; more than 90% of patients younger than 1 year old who develop aseptic meningitis are identified to have an enterovirus infection, although this

virus is responsible for only about 50% of adult cases of aseptic meningitis (Berlin et al., 1993; Marier et al., 1975). In this chapter, we review the features of enteroviruses and meningitis caused by this pathogen, with reference to an outbreak we recently experienced (Hayashi et al., 2009).

2. Virology

Enteroviruses are single-stranded RNA viruses, and belong to the Picornaviridae family. Other viruses which belong to this family include rhinovirus, which is the major cause of the common cold. Enteroviruses are divided into 5 subgenera, which are polioviruses, coxsackieviruses (group A and B), and echoviruses. Each subgenus comprises many serotypes, making the total number of serotypes more than 60. Some serotypes have a strong association with meningitis, while others seldom cause it. A list of serotypes associated with aseptic meningitis is summarized in Table 1. Enteroviruses also cause other neurological disorders and the association of serotypes with specific neurological disorders is described in Table 2. Although rare, opsoclonus-myoclonus syndrome and infantile hemiplegia have been attributed to enteroviruses in some cases (Kuban et al., 1983; Rodden et al., 1975).

	Frequently associated	Occasionally associated
Polivirus		1-3
Group A coxsackievirus	2, 4, 5, 7, 9, 10, 16	1, 3, 6, 8, 11, 14, 17, 18, 22, 24
Group B coxsackievirus	1-5	6
Echovirus	4, 6, 9, 11, 16, 30, 33	1-3, 5, 7, 8, 12-15, 17-25, 31, 32
Enterovirus	70, 71	

Table 1. The association of enterovirus serotypes with viral meningitis

Enteroviruses lack the envelope, and are stable even in an acidic environment, which allows this virus to transit through the stomach (Rosenthal, 1994). The capsid protein is made of four virion polypeptides (VP1-4), among which VP1 serves as a structure to bind its receptor. The virus is internalized by receptor-mediated endocytosis, and then the genome is released into the cytoplasm. Cytolysis ensues in many cases, depending on the virus and the types of infected cells.

Because the gene encoding this protein undergoes a high rate of mutation during replication, this virus is able to avoid immune detection, and sometimes causes large outbreaks. In the coxsackievirus B3-associated meningitis outbreak in Hong Kong in 2008, for example, an amino acid change of this virus was documented (Wong et al., 2011). There was also a large outbreak of aseptic meningitis caused by echovirus 30 in Korea in 2008. A gene analysis of the sequence of VP1 revealed that the causative strain was of a distinct lineage (Choi et al., 2010). There have also been other reports which demonstrated that changes in the immunogenic portion of the viral protein was related to a large outbreak of meningitis (Cui et al., 2010; Mao et al., 2010).

Encephalitis	Poliovirus	1-3
	Group A coxsackievirus	2, 4, 5-9, 10, 16
	Group B coxsackievirus	1-6
	Echovirus	2-4, 6, 7, 9, 11, 14, 17-19, 22, 25, 30, 33
	Enterovirus	70, 71
Paralysis	Poliovirus	1-3
	Group A coxsackievirus	2-11, 14, 16, 21, 24
	Group B coxsackievirus	1-6
	Echovirus	1, 2, 4, 6, 7, 9, 11, 14, 16-19, 30
	Enterovirus	70, 71
Cerebellar ataxia	Poliovirus	1, 3
	Group A coxsackievirus	2, 4, 7, 9
	Group B coxsackievirus	1-6
	Echovirus	6, 9
	Enterovirus	71
Polyneuropathy	Group A coxsackievirus	2, 5, 9
	Group B coxsackievirus	14
	Echovirus	5, 6, 22

Table 2. The association of enterovirus serotypes with neurological disorders

After initial replication in the oropharynx, the enterovirus transits the stomach and reaches the intestinal loop. In the submucosal lymphatic tissue, the viruses actively replicate and cause viremia, which then targets many organs. The best temperature for enterovirus to replicate is 37°C, and conditions with lower temperatures are unsuitable for the development of this viremia. This is one of the reasons why enterovirus meningitis is most prevalent in hot seasons. A large study showed that enterovirus meningitis is more than 5 times more common in summer than in winter, although mumps or arenavirus meningitis is more common in the winter and spring (Meyer et al., 1960). Exercise, which raises the body temperature, may also promote viral replication. In a mouse model of poliomyelitis, the degree of exercise correlated with the severity of paresis (Rosenbaum & Harford, 1953). Clinical data also shows that hard physical exercise has often preceded the establishment of paresis in this disease (Horstmann, 1950). Cardiac muscle damage caused by the coxsackievirus is also augmented by exercise (Gatmaitan et al., 1970). It is thus believed that severe exercise makes the disease more severe in cases of enteroviruses infection (Modlin, 2008).

We recently experienced an outbreak of aseptic meningitis caused by echovirus 30 in a high school baseball club (Hayashi et al., 2009). Among the 43 members of the baseball club

related to our case, 12 were admitted to our hospital, 5 to other hospitals, and all of the other members developed a fever and headache even though they were not admitted to hospitals. This attack rate was extraordinarily high; that in previous reports ranged from 3 to 13% (Akiyoshi et al., 2007; Dumaidi et al., 2006; Mohle-Boetani et al., 1999; Vieth et al., 1999). This extraordinarily high attack rate could be explained by the physically severe training the club members undertook before or just after virus infection.

The route of central nervous system invasion of this virus has not been fully elucidated, but blood-mediated spread is most plausible. The simultaneous occurrence of neurological and other symptoms supports this route. Experimental data show that viremia precedes central nervous system invasion (Nathanson & Bodian, 1962), which also supports this route. Alternatively, the direct spread from intestinal peripheral nerves is also suspected (Sabin, 1956). In the case of poliomyelitis, virus may spread through the muscle and access the innervating nerves, and then travel to the brain (Rosenthal, 1994).

### 3. Clinical features

More than 90% of enterovirus-infected people remain asymptomatic (Kogon et al., 1969). Even if the infection becomes symptomatic, most of the patients develop only mild febrile illness; less than 5% of febrile patients develop meningitis (Rotbart, 1995, 2000). It is estimated that about 1 in 3,000 cases of enterovirus infection causes meningitis. Females are more prone to evolve meningitis (the male:female ratio is 1.3-1.5:1), although the exact reason for this is unknown. There are no specific findings for the febrile illness caused by enterovirus. It is known that the fever may last for one week or longer (Kogon et al., 1969; Rotbart et al., 1998). Headache, throat pain, emesis, and diarrhea are also common findings in cases of enterovirus infection, all of which are also common in mild febrile illnesses caused by other pathogens.

Organs other than the nervous system are also the targets of this virus, and therefore, various disorders are caused by this infection. Acute hemorrhagic conjunctivitis, exanthems, hand-foot-and-mouth disease, herpangina, myositis, and pericarditis are well-known disorders caused by this virus. As seen for the neurological symptoms (Table 1 and 2), these disorders are also associated with specific enterovirus serotypes. Acute hemorrhagic conjunctivitis, for example, has a strong association with enterovirus 70 and coxsackievirus A24. Herpangina is mainly caused by coxsackievirus A or E71.

As described above, most cases of aseptic meningitis follow an uneventful course. However, a few people show complications such as seizure, coma, and movement disorders. There were no such cases in the outbreak we experienced (Hayashi et al., 2009), but 5 to 10% of infant cases show severe complications (Rorabaugh et al., 1993). Infant cases may suffer from neurological sequela such as altered language development, which suggests a higher vulnerability of infants to this virus. On the other hand, other studies have suggested that older people are more vulnerable to poliovirus infections (Nathanson & Martin, 1979; Weinstein 1957). There is also data suggesting that adults show a more prolonged course of enterovirus infection (Rotbart et al., 1998). The reason why younger people suffer from enterovirus infections more frequently may be related to the absence of specific immunity. The reason older people tend to have a prolonged clinical course, on the other hand, remains unknown.

Although most cases of enterovirus meningitis take a quite benign course, electroencepharograms may show slowing of the waves (Lepow et al., 1962). We investigated the electroencepharograms in several cases of enterovirus meningitis (Hayashi et al., 2009), but no cases revealed abnormal findings. The results of electroencephalograms may be different based on the causative serotype, but this issue has not been fully elucidated. Eleven to twenty-two percent of the cases of viral encephalitis are caused by enteroviruses (Modlin, 2008), which indicates that some serotypes are highly neurotropic and take an aggressive form. Echoviruses 9 and 71 are notorious for their frank brain damage (Fowlkes et al., 2008). However, even in the same serotype-caused outbreak, the clinical picture may be different for those affected by the viruses (Akiyoshi et al., 2007; Faustini et al., 2006; Hayashi et al., 2009; Helfand et al., 1994; Mohle-Boetani et al., 1999; Vieth et al., 1999). Mutations in VP1 change the virulence, as may other mutations.

The classic clinical presentation of bacterial meningitis is the triad of fever, neck stiffness and an altered mental state. Viral meningitis, on the other hand, usually lacks mental state alteration. In our experience, all patients with enterovirus meningitis suffered from headache and fever, but the mental state was unaltered in all of the cases (Hayashi et al., 2009). However, there were other symptoms in these patients (summarized in Table 3). Most previous reports show similar results: headache and fever in all patients, vomiting in 60 to 90%, diarrhea in 11%, and rash in 3 to 9% (Bernit et al., 2004; Gosbell et al., 2000; Ihekweba et al., 2008; Kao et al., 2003). Why a rash was not observed in our case series remains uncertain. Some serotypes, such as enterovirus 71, tend to be more aggressive, but to speculate the causative serotype based on the clinical presentation alone is impossible. In cases of aseptic meningitis caused by other viruses, some symptoms are informative about the causative agent; concomitant parotitis or genital lesions, for example, indicates a mumps infection or herpes simplex 2 infection, respectively. However, even in mumps-related meningitis, only half of all patients show parotitis. In addition, only 3 of 23 herpes simplex virus 2-related aseptic meningitis cases had shown prior genital lesions (Landry et al., 2009). Whether the meningitis is caused by an enterovirus or another viruses cannot be inferred clinically.

Meningeal irritation signs are important for diagnosing meningitis. Unless meningeal irritation signs are confirmed, the clinician does not generally investigate the cerebrospinal fluid (Attia et al., 2009). In our case series, however, neck stiffness was confirmed in only 60% of cases (Hayashi et al., 2009). Previous reports also showed that this sign was confirmed in only 70% of cases. The absence of this sign does not exclude meningitis. Kernig signs, a common symptom of meningeal irritation, is less sensitive than neck stiffness; as shown in Table 3, only 23.5% of cases showed this sign. Among the three meningeal irritation signs we investigated, the Jolt accentuation signs showed the highest sensitivity (Table 3), which was compatible to that shown in previous report (Uchihara et al., 1991). The Brudzinski sign has high sensitivity in cases of bacterial and tuberculous meningitis (Brody & Wilkins, 1969), but how often this sign is observed in enterovirus-associated meningitis remains uncertain. Although we did not carry out an exact analysis, this sign was only rarely observed in our case series of echovirus 30-associated meningitis. When a patient with a possible diagnosis of meningitis is encountered, then the Jolt accentuation test is considered to be of great importance.



As the disease usually takes benign clinical course, no specific treatment is required in most cases. Analgesics or anti-emetics are used for relief of symptoms. Pleconaril may reduce the duration of headache or fever, but is not approved for use in the United States.

When immunocompromised patients develop enterovirus meningitis, the outcome is often poor. It tends to become a chronic infection. Even with intravenous administration of immunoglobulin, the disease often has a fatal outcome (Modlin, 2008).

Symptoms	Headache	100%
	Fever	100%
	Emesis	90.5%
	Throat pain	23.8%
	Diarrhea	9.5%
	Rash	0%
Signs	Jolt accentuation	87.5%
	Neck stiffness	60.0%
	Kerni sign	23.5%

Table 3. The signs and symptoms of patients hospitalized with enterovirus meningitis

4. Laboratory data

Pleocytosis in the cerebrospinal fluid, with predominance of mononuclear cells, is one of the most important findings for diagnosing viral meningitis. However, many previous studies of enterovirus meningitis have reported results that contradict this rule (Bernit et al., 2004; Carrol et al., 2006; Kao et al., 2003; Lee & Davies, 2007). Our case series also revealed that 59.7±28.9% of the cells in the cerebrospinal fluid were of polymorphonuclear origin (Table 4). Therefore, polymorphonuclear cell predominance in the cerebrospinal fluid is not unusual in enterovirus meningitis. In herpesvirus infection of the central nervous system, polymorphonuclear cell predominance is also common. Although it is sometimes insisted that an inflammatory response in the cerebrospinal fluid tends to be more prominent in herpesvirus infection than in enterovirus infection, to differentiate them by the cerebrospinal fluid findings is impossible. Our case series showed that the cells in the cerebrospinal fluid ranged from 0 to 370/μl, and a study of herpesvirus infection showed 4 to 755/μl (Olson et al., 1967). The results are therefore highly variable among cases, and are not sufficiently informative to speculate on the causative agent.

In cases of bacterial meningitis, some parameters such as a low glucose level in the cerebrospinal fluid, predict a poor outcome of disease. In cases of aseptic meningitis caused by enteroviruses, however, the cerebrospinal fluid profile does not predict the clinical course. Furthermore, the pleocytosis or an increased protein level in the cerebrospinal fluid was not related to the severity of headache or emesis. This may be, at least in part, because the time when the cerebrospinal fluid was obtained varied among the cases; the

inflammatory response in the cerebrospinal fluid may be mild when a lumbar puncture is performed early in the course of infection (Jiménez Caballero et al., 2011).

As shown in Table 4, white blood cells and/or C-reactive protein elevation in the blood are generally mild in cases of aseptic meningitis. This profile is similar to that of other viral infections. These findings are useful when viral meningitis needs to be differentiated from bacterial meningitis.

Isolation of the virus in cell culture was the traditional method used to identify the causative agent of viral meningitis, but it usually has low sensitivity, ranging from 60 to 75% (Trabelsi et al., 1995). Serological examinations and RT-PCR have, therefore, now become commonplace, and RT-PCR has recently become preferred because of its high sensitivity and shorter time required for the test. The sensitivity and specificity of RT-PCR are 100 and 97%, respectively (Halonen et al., 1995; Rotbart et al., 1994). We have examined the cerebrospinal fluid and pharyngeal swabs to identify causative agents, and found that both serological and RT-PCR studies have high sensitivity (Hayashi et al., 2009). The amount of sample and the time it was obtained may influence the results.

Cerebrospinal fluid	Initial pressure	216.4±43.6 mmH2O
	Cells	108.9±114.0 /µl
	Polymorphonuclear cells	59.7±28.9 %
	Protein	33.8±16.2 mg/dl
	Glucose (% of blood glucose)	55.5±7.8 %
Blood	White blood cells	10205±2157 /µl
	C-reactive protein	1.65±1.72 mg/dl

Table 4. The laboratory findings of patients hospitalized with enterovirus meningitis

5. Mode of transmission and outbreak prevention

Enteroviruses begin to be excreted when the infection is still asymptomatic. It is thus possible for a person to transmit the virus even when he/she is not aware of being infected. The time from enterovirus exposure to symptom onset differs between disorders; it is 12 to 24 hours for conjunctivitis, 2 to 3 days for gastroenteritis, and 3 to 10 days for aseptic meningitis (Modlin, 2008; Tyler & Martin, 1993). Even during this period, the virus may be propagated.

Viral particles are shed in the upper respiratory tract secretions and feces, the former for about 1 to 3 weeks and the latter for 5 to 6 weeks. There are some exceptions, such as enterovirus 70 in tears, which cause acute hemorrhagic conjunctivitis (Onorato et al., 1985). For the transmission and outbreak of enterovirus meningitis, the fecal-oral route plays the pivotal role. Respiratory secretions could theoretically be involved, but whether this route actually plays a role in meningitis transmission is uncertain. When one became infected by an enterovirus, a member in the same family becomes infected in 43 to 76% of cases (Kogon



et al., 1969). Living in crowded conditions increases the probability of transmission. Poor hygiene also facilitates the spread of infection. Consequently, enterovirus infection is more prevalent in people of lower socioeconomic status.

In order to prevent transmission and outbreaks, hand washing is important. Sharing cups or bottles should be forbidden. The outbreak we recently experienced was, at least in part, caused by sharing drink bottles (Hayashi 2009). When the patient is an infant who still needs diapers, caregivers should take special precautions to decrease the spread of infection. Indeed, child-care centers sometimes become the center of outbreaks (Akiyoshi et al., 2007; Dumaidi et al., 2006; Mohle-Boetani et al., 1999; Vieth et al., 1999). To use gloves is warranted.

Not only the above-mentioned limited-community outbreaks, but also larger outbreaks, which involve a city to a country, sometimes occur (Choi et al., 2010; Cui et al., 2010; Gobbi et al., 2010; Kao et al., 2003; Mao et al., 2010; Perevoscikovs et al., 2010). In most of such cases, a mutation of the immunogenic viral protein is involved. In such outbreaks, the attack rate for each person is quite low. Careful hand washing and maintaining quality standards are important. Virus-containing water occasionally pours into a pond, lake, or sea. Relatively small open-community outbreaks can take place under such circumstances (Begier et al., 2008; Hauri et al., 2005). Although exposure to the virus is inevitable when one swims in such pond, the rate of symptomatic infection is variable. What determines whether the infection is symptomatic or asymptomatic is not clear, but the time spent swimming correlated with the occurrence of clinically apparent meningitis (Begier et al., 2008; Hauri et al., 2005). Therefore, it is best to limit the time spent swimming in a pond for a long time, when meningitis is prevalent.

Serum IgG against enteroviruses persists for life, and IgA (secretory immunoglobulin) continues to circulate for approximately 15 years. Infants and young people are less likely to possess serotype-specific antibodies against enteroviruses. Special attention should be paid in order not to expose young people to prevailing virus. In the outbreak we experienced, we notified all schools, kindergartens, and nurseries that an enterovirus infection had been detected. We asked public health centers to teach the school staff in the city how to prevent transmission. Owing to these activities, we successfully contained the echovirus 30-associated meningitis outbreak within a limited-community.

## 6. References

- Akiyoshi, K.; Nakagawa, N. & Suga, T. (2007). An outbreak of aseptic meningitis in a nursery school caused by echovirus type 30 in Kobe, Japan. *Jpn J Infect Dis*. Vol.60, pp. 66-68.
- Attia, J.; Hatala, R.; Cook, D.J. & Wong, J.G. (2009). Does this patient have acute meningitis?. In: *The rational clinical examination*. Simel, D.L. & Rennie, D. (Ed.). 395-406, Mc Graw Hill Medical, New York.
- Begier, E.M.; Oberste, M.S.; Landry, M.L.; Brennan, T.; Mlynarski, D.; Mshar, P.A.; Frenette, K.; Rabatsky-Her, T.; Purviance, K.; Nepaul, A.; Nix, W.A.; Pallansch, M.A.; Ferguson, D.; Cartter, M.L. & Hadler, J.L. (2008). An outbreak of concurrent echovirus 30 and coxsackievirus A1 infections associated with sea swimming among a group of travelers to Mexico. *Clin Infect Dis*. Vol.47, pp. 616-623.

- Berlin, L.E.; Rorabauch, M.L.; Heldrich, L.; Roberts, K.; Doran, T. & Modlin, J.F. (1993). Aseptic meningitis in infants <2 years of age: diagnosis and etiology. *J Infect Dis.* Vol.168, pp. 888-892.
- Bernit, E.; de Lamballerie, X.; Zandotti, C.; Berger, P.; Veit, V.; Schleinitz, N.; de Micco, P.; Harlé, J.R. & Charrel, R.N. (2004). Prospective investigation of a large outbreak of meningitis due to echovirus 30 during summer 2000 in marseilles, france. *Medicine (Baltimore)*. Vol.83, pp. 245-253.
- Brody, I.A. & Wilkins, R.H. (1969). The signs of Kernig and Brudzinski. *Arch Neurol.* Vol.21, pp. 215-218.
- Carrol, E.D.; Beadsworth, M.B.; Jenkins, N.; Ratcliffe, L.; Ashton, I.; Crowley, B.; Nye, F.J. & Beeching, N.J. (2006). Clinical and diagnostic findings of an echovirus meningitis outbreak in the north west of England. *Postgrad Med J.* Vol.82, pp. 60-64.
- CDC. (2003). Outbreaks of aseptic meningitis associated with enteroviruses 9 and 30 and preliminary surveillance reports on enterovirus activity - United States, 2003. *MMWR* Vol.52, pp. 761-764.
- Choi, Y.J.; Park, K.S.; Baek, K.A.; Jung, E.H.; Nam, H.S.; Kim, Y.B. & Park, J.S. (2010). Molecular characterization of echovirus 30-associated outbreak of aseptic meningitis in Korea in 2008. *J Microbiol Biotechnol.* Vol.20, pp. 643-649.
- Cui, A.; Yu, D.; Zhu, Z.; Meng, L.; Li, H.; Liu, J.; Liu, G.; Mao, N. & Xu, W. (2010). An outbreak of aseptic meningitis caused by coxsackievirus A9 in Gansu, the People's Republic of China. *Virol J.* Vol. 7, pp. 72.
- Dumaidi, K.; Frantzidou, F.; Papa, A.; Diza, E. & Antoniadis, A. (2006). Enterovirus meningitis in Greece from 2003-2005: diagnosis, CSF laboratory findings, and clinical manifestations. *J Clin Lab Anal.* Vol.20, pp. 177-183.
- Faustini, A.; Fano, V.; Muscillo, M.; Zaniratti, S.; La Rosa, G.; Tribuzi, L. & Perucci, C.A. (2006). An outbreak of aseptic meningitis due to echovirus 30 associated with attending school and swimming in pools. *Int J Infect Dis.* Vol.10, pp. 291-297.
- Fowlkes, A.L.; Honarmand, S.; Glaser, C.; Yagi, S.; Schnurr, D.; Oberste, M.S.; Anderson, L.; Pallansch, M.A. & Khetsuriani, N. (2008). Enterovirus-associated encephalitis in the California encephalitis project, 1998-2005. *J Infect Dis.* Vol.198, pp. 1685-1691.
- Gatmaitan, B.G.; Chason, J.L. & Lerner, A.M. (1970). Augmentation of the virulence of murine coxsackie-virus B-3 myocardiopathy by exercise. *J Exp Med.* Vol.131, pp. 1121-1136.
- Gobbi, F.; Calleri, G.; Spezia, C.; Lipani, F.; Balbiano, R.; De Agostini, M.; Milia, M.G. & Caramello P. (2010). Echovirus-4 meningitis outbreak imported from India. *J Travel Med.* Vol.17, pp. 66-68.
- Gosbell, I.; Robinson, D.; Chant, K. & Crone, S. (2000). Outbreak of echovirus 30 meningitis in Wingecarribee Shire, New South Wales. *Commun Dis Intell.* Vol.24, pp. 121-124.
- Halonen, P.; Rocha, E.; Hierholzer, J.; Holloway, B.; Hyypiä, T.; Hurskainen, P. & Pallansch, M. (1995). Detection of enteroviruses and rhinoviruses in clinical specimens by PCR and liquid-phase hybridization. *J Clin Microbiol.* Vol.33, pp. 648-653.
- Hauri, A.M.; Schimmelpfennig, M.; Walter-Domes, M.; Letz, A.; Diedrich, S.; Lopez-Pila, J. & Schreier, E. (2005). An outbreak of viral meningitis associated with a public swimming pond. *Epidemiol Infect.* Vol.133, pp. 291-298.
- Hayashi, T.; Shirayoshi, T.; Nagano, T.; Yaoita, H.; Kogure, S.; Nariai, H.; Natsumeda, T.; Taniuchi, M.; Sandoh, M. & Sato, Y. (2009). An outbreak of aseptic meningitis due

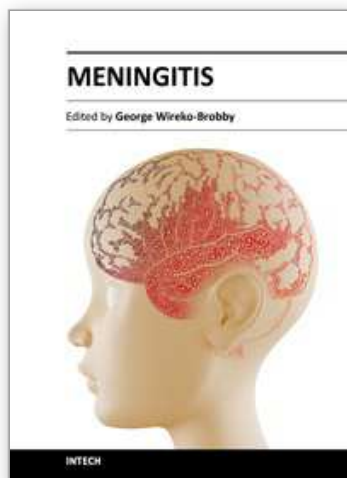
- to echovirus 30 in a high school baseball club – possible role of severe exercise for a high attack rate. *Inter Med.* Vol.48, pp. 1767-1771.
- Helfand, R.F.; Khan, A.S.; Pallansch, M.A.; Alexander, J.P.; Meyers, H.B.; DeSantis, R.A.; Schonberger, L.B. & Anderson, L.J. (1994). Echovirus 30 infection and aseptic meningitis in parents of children attending a child care center. *J Infect Dis.* Vol.169, pp. 1133-1137.
- Horstmann, D.M. (1950). Acute poliomyelitis relation of physical activity at the time of onset to the course of the disease. *J Am Med Ass.* Vol.142, pp. 236-241.
- Ihekweba, U.K.; Kudesia, G. & McKendrick, M.W. (2008). Clinical features of viral meningitis in adults: significant differences in cerebrospinal fluid findings among herpes simplex virus, varicella zoster virus, and enterovirus infections. *Clin Infect Dis.* Vol.47, pp. 783-789.
- Jiménez Caballero, P.E.; Muñoz Escudero, F.; Murcia Carretero, S. & Verdú Pérez, A. (2011). Descriptive analysis of viral meningitis in a general hospital: differences in the characteristics between children and adults. *Neurologia*. Epub ahead of print..
- Kao, C.H.; Lee, S.S.; Liu, Y.C.; Yen, M.Y.; Chen, Y.S.; Wan, S.R.; Lin, H.H.; Lin, W.R.; Huang, C.K. & Chin, C. (2003). Outbreak of aseptic meningitis among adults in southern Taiwan. *J Microbiol Immunol Infect.* Vol.36, pp. 192-196.
- Khetsuriani, N.; Quiroz, E.S.; Holman, R.C. & Anderson, L.J. (2003). Viral meningitis-associated hospitalizations in the United States, 1988-1999. *Neuroepidemiology.* Vol.22, pp. 345-52.
- Kogon, A.; Spigland, I.; Frothingham, T.E.; Elveback, L.; Williams, C.; Hall, C.E. & Fox, J.P. (1969). The virus watch program: a continuing surveillance of viral infections in metropolitan New York families. VII. Observations on viral excretion, seroimmunity, intrafamilial spread and illness association in coxsackie and echovirus infections. *Am J Epidemiol.* Vol.89, pp. 51-61.
- Kuban, K.C.; Ephros, M.A.; Freeman, R.L.; Laffel, L.B. & Bresnan, M.J. (1983). Syndrome of opsoclonus-myoclonus caused by coxsackie B3 infection. *Ann Neurol.* Vol.13, pp. 69-71.
- Landry, M.L.; Greenwold, J. & Vikram, H.R. (2009). Herpes simplex type-2 meningitis: presentation and lack of standardized therapy. *Am J Med.* Vol.122, pp. 688-691.
- Lee, B.E. & Davies, H.E. (2007). Aseptic meningitis. *Curr Opin Infect Dis.* Vol.20, pp. 272-277.
- Lepow, M.L.; Coyne, N.; Thompson, L.B.; Carver, D.H. & Robbins, F.C. (1962). A clinical, epidemiological, and laboratory investigation of aseptic meningitis during the four-year period 1955-1958. II. The clinical disease and its sequelae. *N Engl J Med.* Vol. 266, pp. 1188-1193.
- Mao, N.; Zhao, L.; Zhu, Z.; Chen, X.; Zhou, S.; Zhang, Y.; Cui, A.; Ji, Y.; Xu, S. & Xu, W. (2010). An aseptic meningitis outbreak caused by echovirus 6 in Anhui province, China. *J Med Virol.* Vol.82, pp. 441-445.
- Marier, R.; Rodriguez, W.; Chloupek, R.J.; Brandt, C.D.; Kim, H.W.; Baltimore, R.S.; Parker, C.L. & Artenstein, M.S. (1975). Coxsackievirus B5 infection and aseptic meningitis in neonates and children. *Am J Dis Child.* Vol.129, pp. 321-325.
- Meyer, H.M.; Johnson, R.T.; Crawford, I.P., Dascomb, H.E. & Rogers, N.G. (1960). Central nervous system syndromes of viral etiology. A study of 713 cases. *Am J Med.* Vol.29, pp. 334-347.

- Modlin, J.F. (2008). Enterovirus infections. In: *Cecil Medicine*. 23rd ed. Goldman, L. & Ausiello, D. (Ed.). 2514-2519, Elsevier, Philadelphia.
- Mohle-Boetani, J.C.; Matkin, C.; Pallansch, M.; Helfand, R.; Fenstersheib, M.; Blanding, J.A. & Solomon, S.L. (1999). Viral meningitis in child care center staff and parents: an outbreak of echovirus 30 infections. *Public Health Rep.* Vol.114, pp. 249-256.
- Nathanson, N. & Bodian, D. (1962). Experimental poliomyelitis following intramuscular virus injection. III. The effect of passive antibody. *Bull Johns Hopkins Hosp.* Vol.111. pp. 198-220.
- Nathanson, N. & Martin, J.R. (1979). The epidemiology of poliomyelitis: enigmas surrounding its appearance, epidemicity, and disappearance. *Am J Epidemiol.* Vol.110, pp. 672-692.
- Olson, L.C.; Buescher, E.L.; Artenstein, M.S. & Parkman, P.D. (1967). Herpesvirus infections of the human central nervous system. *N Engl J Med.* Vol.277, pp. 1271-1277.
- Onorato, I.M.; Morens, D.M.; Schonberger, L.B.; Hatch, M.H.; Kaminski, R.M. & Turner, J.P. (1985). Acute hemorrhagic conjunctivitis caused by enterovirus type 70: an epidemic in American Samoa. *Am J Trop Med Hyg.* Vol.34, pp. 984-991.
- Parasuraman, T.V.; Frenia, K. & Romero, J. (2001). Enteroviral meningitis. Cost of illness and considerations for the economic evaluation of potential therapies. *Pharmacoeconomics.* Vol.19, pp.3-12.
- Perevoscikovs, J.; Brila, A.; Firstova, L.; Komarova, T.; Lucenko, I.; Osmjana, J.; Savrasova, L.; Singarjova, I.; Storozenko, J.; Voloscuka, N. & Zamjatina, N. (2010). Ongoing outbreak of aseptic meningitis in South-Eastern Latvia, June - August 2010. *Euro Surveill.* Vol. 15, pii. 19639.
- Rodden, V.J.; Cantor, H.E.; O'Coner, D.M.; Schmidt, R.R. & Cherry, J.D. (1975). Acute hemiplegia of childhood associated with coxsackie A9 viral infection. *J Pediatr.* Vol.86, pp. 56-58.
- Rorabaugh, M.L.; Berlin, L.E.; Heldrich, F.; Roberts, K.; Rosenberg, L.A.; Doran, T. & Modlin, J.F. (1993). Aseptic meningitis in infants younger than 2 years of age: acute illness and neurologic complications. *Pediatrics.* Vol.92, pp. 206-211.
- Rosenbaum, H.E. & Harford, C.G. (1953). Effect of fatigue on susceptibility of mice to poliomyelitis. *Proc Soc Exp Biol Med.* Vol.83, pp. 678-681.
- Rosenthal, K.S. (1994). Picornaviruses, In: *Medical Microbiology*. Murray, P.R.; Kobayashi, G.S.; Pfaller, M.A. & Rosenthal, K.S. (Ed.), 607-619, Mosby, St. Louis.
- Rotbart, H.A.; Sawyer, M.H.; Fast, S.; Lewinski, C.; Murphy, N.; Keyser, E.F.; Spadoro, J.; Kao, S.Y. & Loeffelholz, M. (1994). Diagnosis of enteroviral meningitis by using PCR with a colorimetric microwell detection assay. *J Clin Microbiol.* Vol.32, pp. 2590-2592.
- Rotbart, H.A. (1995). Enteroviral infections of the central nervous system. *Clin Infect Dis.* Vol.20, pp. 971-981.
- Rotbart, H.A.; Brennan, P.J.; Fife, K.H.; Romero, J.R.; Griffin, J.A.; McKinlay, M.A. & Hayden, F.G. (1998). Enterovirus meningitis in adults. *Clin Infect Dis.* Vol.27, pp. 896-898.
- Rotbart, H.A. (2000). Viral meningitis. *Semin Neurol.* Vol.20, pp. 277-292.
- Sabin, A.B. (1956). Pathogenesis of poliomyelitis. Reappraisal in the light of new data. *Science.* Vol.123, pp. 1151-1157.

- Trabelsi, A.; Grattard, F.; Nejmeddine, M.; Aouni, M.; Bourlet, T. & Pozzetto, B. (1995). Evaluation of an enterovirus group-specific anti-VP1 monoclonal antibody, 5-D8/1, in comparison with neutralization and PCR for rapid identification of enteroviruses in cell culture. *J Clin Microbiol.* Vol.33, pp. 2454-2457.
- Tunkel, A.R. & Scheld, W.M. (1993). Pathogenesis and pathophysiology of bacterial meningitis. *Clin Microbiol Rev.* Vol.6, pp. 18-136.
- Tyler, K.L. & Martin, J.B. (1993). *Infectious Diseases of the Central Nervous System.* F.A. Davis Company, Philadelphia.
- Uchihara, T. & Tsukagoshi, H. (1991). Jolt accentuation of headache: the most sensitive sign of CSF pleocytosis. *Headache.* Vol.31, pp. 167-171.
- Vieth, U.C.; Kunzelmann, M.; Diedrich, S.; Timm, H.; Ammon, A.; Lyytikäinen, O. & Petersen LR. (1999). An echovirus 30 outbreak with a high meningitis attack rate among children and household members at four day-care centers. *Eur J Epidemiol.* Vol.15, pp. 655-658.
- Wang, J.R.; Tsai, H.P.; Huang, S.W.; Kuo, P.H.; Kiang, D.; & Liu, C.C. (2002) Laboratory diagnosis and genetic analysis of an echovirus 30-associated outbreak of aseptic meningitis in Taiwan in 2001. *J Clin Microbiol.* Vol.40, pp. 4439-4444.
- Weinstein, L. (1957). Influence of age and sex on susceptibility and clinical manifestations in poliomyelitis. *N Engl J Med.* Vol.257, pp. 47-52.
- Wong, A.H.; Lau, C.S.; Cheng, P.K.; Ng, A.Y. & Lim, W.W. (2011). Coxsackivirus B3-associated aseptic meningitis: an emerging infection in Hong Kong. *J Med Virol.* Vol.83, pp. 483-489.

IntechOpen





## **Meningitis**

Edited by Prof. George Wireko-Brobby

ISBN 978-953-51-0383-7

Hard cover, 232 pages

**Publisher** InTech

**Published online** 30, March, 2012

**Published in print edition** March, 2012

Meningitis is a medical emergency requiring a rapid diagnosis and an immediate transfer to an institution supplied with appropriate antibiotic and supportive measures. This book aims to provide general practitioners, paediatricians, and specialist physicians with an essential text written in an accessible language, and also to highlight the differences in pathogenesis and causative agents of meningitis in the developed and the developing world.

### **How to reference**

In order to correctly reference this scholarly work, feel free to copy and paste the following:

Takeshi Hayashi, Takamasa Shirayoshi and Masahiro Ebitani (2012). Aseptic Meningitis Caused by Enteroviruses, Meningitis, Prof. George Wireko-Brobby (Ed.), ISBN: 978-953-51-0383-7, InTech, Available from: <http://www.intechopen.com/books/meningitis/aseptic-meningitis-caused-by-enteroviruses>

**INTeCH**  
open science | open minds

### **InTech Europe**

University Campus STeP Ri  
Slavka Krautzeka 83/A  
51000 Rijeka, Croatia  
Phone: +385 (51) 770 447  
Fax: +385 (51) 686 166  
[www.intechopen.com](http://www.intechopen.com)

### **InTech China**

Unit 405, Office Block, Hotel Equatorial Shanghai  
No.65, Yan An Road (West), Shanghai, 200040, China  
中国上海市延安西路65号上海国际贵都大饭店办公楼405单元  
Phone: +86-21-62489820  
Fax: +86-21-62489821



© 2012 The Author(s). Licensee IntechOpen. This is an open access article distributed under the terms of the [Creative Commons Attribution 3.0 License](https://creativecommons.org/licenses/by/3.0/), which permits unrestricted use, distribution, and reproduction in any medium, provided the original work is properly cited.

IntechOpen

IntechOpen