

# We are IntechOpen, the world's leading publisher of Open Access books Built by scientists, for scientists

6,900

Open access books available

185,000

International authors and editors

200M

Downloads

Our authors are among the

154

Countries delivered to

TOP 1%

most cited scientists

12.2%

Contributors from top 500 universities



WEB OF SCIENCE™

Selection of our books indexed in the Book Citation Index  
in Web of Science™ Core Collection (BKCI)

Interested in publishing with us?  
Contact [book.department@intechopen.com](mailto:book.department@intechopen.com)

Numbers displayed above are based on latest data collected.  
For more information visit [www.intechopen.com](http://www.intechopen.com)



# Neurologic Complications of Bacterial Meningitis

Emad uddin Siddiqui  
Aga Khan University Hospital  
Pakistan

## 1. Introduction

Bacterial meningitis is a serious and potentially life threatening CNS infection. It often results in disabling or deaths in 170,000 patients each year worldwide. Younger children are predominantly at risk of bacterial meningitis, mainly because of their immature immune systems and malnutrition while lack of immunization practices also makes them more susceptible to significantly high morbidity & mortality. (Anderson, V. et al., 2004). Even with the provision of highly effective antibiotic therapy, death and long-term disabilities are the common but still serious consequences of acute bacterial meningitis in developing countries. Common neurological complications in adult are hearing loss, motor deficit, cognition defect and speech problem, whereas sensorineural deafness, followed by seizure disorder and motor deficit are more common in children. Sixteen percent of pediatric patients from developed countries have neurological complications, while this figure rose 26 percent from developing countries. (Braff, LJ. et al., 1993). Two third of all pediatric deaths due to meningitis occur in low income countries and as many as 50% survivors of childhood meningitis experience some neurological sequel. (Mace, SE 2008)

Neurological complications of meningitis can occur at any time during the course of disease and even after the completion of therapy. Neurological complications may either be focal or generalized or it may be of sudden or gradual in onset. Patients either remain conscious or may present with altered consciousness or even coma. Usually the complications develop during the course of acute bacterial meningitis but some of them manifest or persist as the long-term sequel such as; hearing loss, epilepsy, hemiplegia, neuropsychological impairment, developmental and learning disabilities. Shock or disseminated intravascular coagulation, frequently is associated with meningococcal meningitis. Pneumococcal meningitis is associated with the highest case fatality rate. Apnea and respiratory failure may occur with any bacterial meningitis, especially in infants. Post meningitis complications may occur in almost half of all cases, 81% of them may present with neurological sequel. A part of this may present with systemic sequel, while a quarter of them have both neurological and systemic complications. (Pfister, HW. et al., 1993)

2. Risk factors for neurological complications

There are multiple risk factors either directly or indirectly related to any one or more of the neurological complications as listed in Table 1. Extremes of age is directly associated with the consequences and prognosis. Organism type, virulence and number of bacteria entered, portal of entry along with the susceptibility of host all count in the development of neurological complications. Duration and progression of illness before initiation of effective antibiotic therapy is also associated with neurological complication. On the other hand mode of presentation, and compliance to the appropriate treatment or any associated co-morbid may also have detrimental effect on patient neurological outcome and morbidity. Patients on immunosuppressive drug, chronic liver disorders, alcoholics, diabetics and patients with congenital or acquired immune deficiency disease, malignancy and HIV, are at increased risk of meningitis and its sequel as compare to general population. Streptococcus pneumoniae is associated with most of the sequel as compared to the other organisms.

Neurological	Systemic (Non Neurological)
<b>Acute onset</b> Altered mental status/ coma Cerebral edema and raised intracranial pressure Acute onset Seizures Subdural effusion or empyema Cranial nerve palsies Hydrocephalus Sensorineural deficit Hemiparesis or quadriparesis Blindness <b>Late onset</b> Late onset seizure (epilepsy) disorder Ataxia Cerebrovascular abnormalities Neuropsychological impairment Developmental disability Intellectual deficit	Prolong fever Septic shock and DIC Vasomotor collapse Loss of airway reflexes Respiratory arrest Pericardial effusion Hypothalamic and other endocrine dysfunction Hyponatremia Bilateral adrenal hemorrhage Death

Table 1. Complications of meningitis and its types

Several studies have been conducted to identify the clinical factors that are associated with adverse outcomes in children with bacterial meningitis. Unconsciousness early in the disease, multiple or prolong seizures (>72 hours), use of inotrops, and leucopenia are important predictors of adverse neurological outcome. It has been observed that patients with neurological symptoms lasted for >24hrs, focal neurological signs, ataxia, or deteriorating conscious level despite the commencement of adequate and appropriate therapy and serum sodium concentration <130 mmol/L are associated with adverse outcomes. Other clinical presentations of meningitis that are associated with increased risk of neurologic complications are low CSF glucose concentration, and CSF bacterial count of ≥10 cfu/ml. (Feldman, WE. 1997). Patients on ventilatory support and PRISM score of ≥20 in

first 24 hours of admission are few other common clinical predictors associated with increased incidence of neurological complications. (Madagame, ET. et al., 1995)

### 3. Altered mental status

Inflammation of CNS is responsible for the hallmark presentation of CNS infection which including fever, meningismus, and altered mental status. Altered mental status is described as irritability or lethargy. However in pediatric patients altered mental status is highly variable. Increased intracranial pressure (ICP) is one of the major causes of altered mental status. In adults, the incidence of altered mental status ranged from 78 to 83 percent at presentation, (de Gans, J et al., 2002), most patients are either confused or lethargic, while a quarter may be responsive only to pain only, and 6 percent unresponsive to all stimuli. (Durand, ML. et al., 1993). In adult patients with pneumococcal meningitis, 29% were found semi comatose or comatose at the time of admission. Coma with GCS <8 at initial presentation may present in 14 percent. (Durand, 1993 & Aronin 1998). From a pediatric study (Roine, I. et al., 2008) with bacterial meningitis, approximately 78% were irritable or lethargic, 7% were somnolent, and 15% semi comatose or comatose at the time of admission. The level of consciousness at the time of admission has prognostic significance; patients who are obtunded, semi conscious, or comatose at the time of admission are significantly more likely to have an adverse outcome than those who are lethargic or somnolent.

### 4. Cerebral edema & raised intracranial pressure

Cerebral blood flow (CBF) normally is maintained at a relatively constant rate by an auto regulatory mechanism. This auto regulation adjusts the CBF according to the metabolic need and regulates the changes in cerebral vascular resistant (CVR). During fever or seizures activity there is increase in the metabolic activity in brain, this result in increased CBF.

$$CBF = (CAP - JVP) \div CVR \quad (1)$$

(CAP is carotid arterial pressure, JVP is jugular venous pressure, and CVR is cerebrovascular resistance).

Arterial PaO<sub>2</sub> and PaCO<sub>2</sub> also have well-defined effects on CBF. Arterial PaO<sub>2</sub> ≤ 50 mmHg has its most significant effect on CBF, and it cause vasodilatation in order to maintain the necessary oxygen and nutrient supply to the brain. High arterial PaCO<sub>2</sub> also causes cerebral vasodilatation and increased CBF, whereas hypocapnia reduces CBF. Regulating PaCO<sub>2</sub> by hyperventilation is a useful tool in the acute management of increased ICP.

Increased ICP in patients with bacterial meningitis seems to be multi factorial in origin. Released cytotoxic mediators and interstitial edema with increased permeability of the blood-brain barrier are some of the main factors leading to increased ICP, although increased intracranial blood volume and disturbances in CSF flow are also important. Inflammation on the other hand itself increases the permeability of the blood-brain barrier, via vasogenic mechanism and edema formation. (Tunkel, AR. 1993).

Cerebral edema in the nonexpendable cranial vault increases intracranial pressure (>300cm of H<sub>2</sub>O) and results in secondary injury from diminished (<50cm of H<sub>2</sub>O) cerebral perfusion (MAP-ICP) and ischemia. Mild to moderate increase in ICP causes headache, confusion,

irritability, nausea, and vomiting. More severe increases can produce coma, Cushing reflex (bradycardia with hypertension), papilledema, cranial nerve palsy, mostly the abducent (VI) nerve, and herniation of the cerebellar tonsils, which may lead to death. (Durand, 1993 & de Gans 2002). Hydrocephalus is hardly ever reported to be the cause of raised ICP at presentation. Raised intracranial pressure is reported to be an indicator of a more severe disease related with a much higher mortality than in simple uncomplicated cases of bacterial meningitis. Judicious fluid management, dexamethasone, mannitol, hypertonic saline and hyperventilation to keep PaCO<sub>2</sub> to 25- 35mmHg and 30° head elevation, are helpful in reducing the raised ICP and cerebral edema. (Lindval, P. et al., 2004).

## 5. Seizures

Little is known about the pathogenesis of seizures in bacterial meningitis. Other than fever in younger children, inflammatory exudates, bacterial toxins, chemical mediators and neurochemical changes within brain parenchyma are supposed to cause seizures in 15 - 30 percent of adults (Zoons, E. et al., 2008) and 20-30 percent of children (Feigin, RD. et al., 2009). Seizures in bacterial meningitis may develop at any time during the course of disease or later on. Seizures are either generalized or partial; those occurring early in the course are rather easily controllable by anticonvulsant drugs, and are rarely associated with permanent neurologic deficit. In contrast, prolonged and difficult to control seizures, or seizures that begin after 72 hours of hospitalization are more likely to be associated with permanent neurologic sequel. (Arditi, M. 1998). Prolonged & intractable seizures may also suggest that a cerebrovascular complication might have occurred. Pneumococcal meningitis has 5-fold increase risk of seizures activity. (Zoons, E. et al., 2008). Patients with other inter current illnesses and infections, low GCS, focal neurological deficit, low CSF leucocytes and high protein are associated with increased risk of seizure activity. Seizures during acute phase of illness are associated with increased risk of neurological complication and deaths. (Aronin, 1998 & Annegers, 1988).

## 6. Subdural effusions

Subdural effusion is the collection of fluids in subdural spaces. This is another common complication of meningitis and occurs in 50 percent of adult meningitis and 10-30 percent of children. (Agarwal, A. et al., 2007). It is usually asymptomatic in most of the cases and is benign or self limiting. Mild effusions mostly resolve spontaneously and do not require any intervention. Subdural tap is indicated if there is persistent or recurrent fever, signs of raised ICP, focal neurological sign and presence of subdural empyema. Subdural empyema is usually unilateral but has the potential to spread rapidly through the falx cerebri in to tentorium cerebella and can spread to the base of brain and in to the spinal column. H. Influenzae meningitis is commonly associated with effusion. Clinical manifestations of effusion are often subtle or absent. Bulging fontanelle and irritability may be the only sign in infants. Diastasis of sutures, enlarging head circumference in infant, recurrence or new onset seizures, emesis and fever, and abnormal cranial transillumination are other common clinical findings. In older children it can produce increased ICP, a focal neurological sign and a mid line shift of intracranial structures. CT or MRI confirms the presence of effusion. In pediatric patients, subdural effusions produce few symptoms and so require no

treatment. However, development of subdural empyema or symptomatic effusion requires drainage. (Snedeker, JD. Et al., 1990)

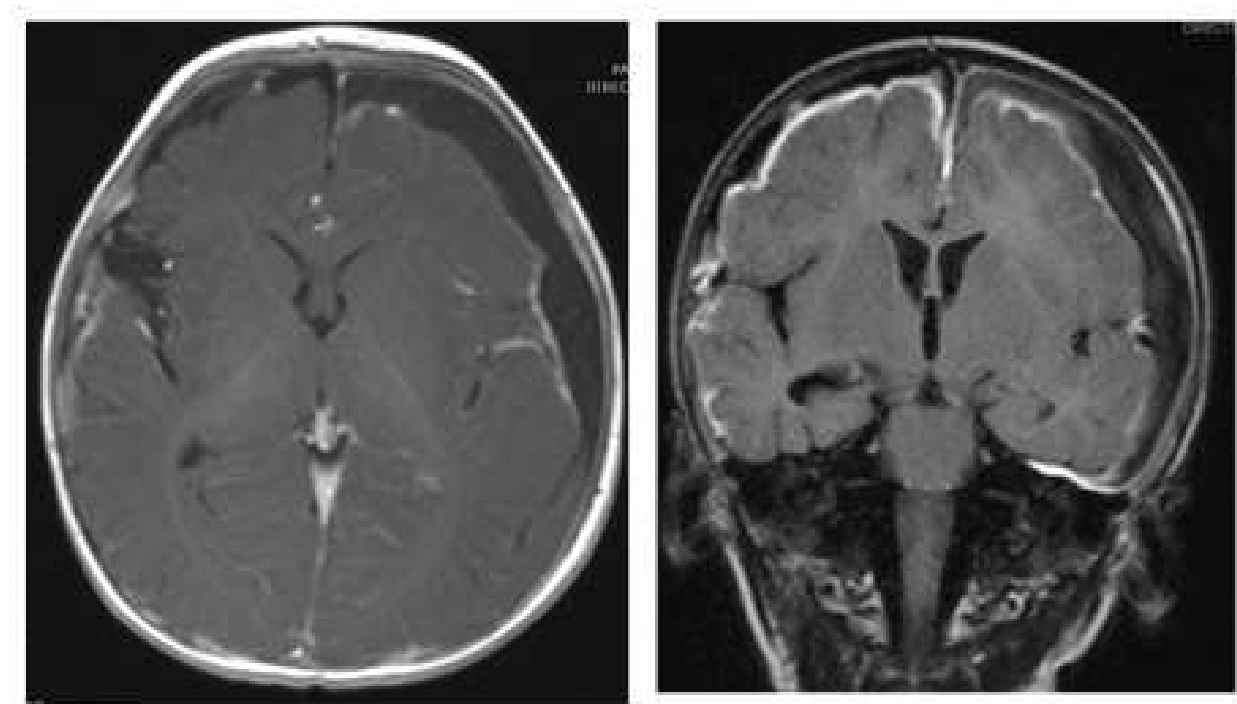


Fig. 1. MRI brain showing subdural fluid collection along the left cerebral convexity with ring enhancement in the contrast images

## 7. Cranial nerve palsies

Meningitis with basal exudate collection is often related with cranial nerves (CN) involvement. CN palsies likely to occur when the cranial nerve are sheathed by exudates (perineuritis) within the arachnoidal sheath. CN may also be affected by compressible pressure of brain in general. Abducent (VI) nerves with its longest intra cranial route adjacent to brain stem are more prone to raised ICP and exudates (perineuritis) related compression. Other CNs like III, IV, and VII may also be affected. CN involvement is more common in pediatric patients and is described in 5-11 percent of cases. Focal neurological sign may or may not be present. CN deficits related to meningitis are usually transient. Strabismus may be the presenting feature early in the course with only gaze towards the paralyzed side. Optic nerve involvement can lead to transient or permanent visual loss while optic nerve atrophy may result in irreversible total blindness, a rare complication of severe meningitis. Cranial nerve palsies may be the warning sign of raised intracranial pressure.

## 8. Hydrocephalus

Hydrocephalus is the complication of acute meningitis which usually manifest later as post meningitis sequel. It is commonly associated with untreated or partially treated pyogenic meningitis and tuberculous meningitis. Hydrocephalus more commonly occurs in infants and neonates especially with group B streptococcus type III. (de Louvois, J. 1994). Mild to moderate



type can be treated pharmacologically while severe hydrocephalus compressing the brain parenchyma should be managed surgically with various types of shunt.

## 9. Focal neurological deficits

Focal neurological deficits account for most of the common complication of meningitis and it may account up to 50 percent of all neurological complication. (van de Beek, D. et al., 2004). This depends on the multiple factors like extremes of ages, duration of pretreatment illness, causative organism and efficacy of treatment. Pneumococcal and meningococcal in adults with the addition of H. Influenzae in children are associated with most of these complications. Majority of focal neurological complications tend to resolve with appropriate treatment but long term disability may persist.

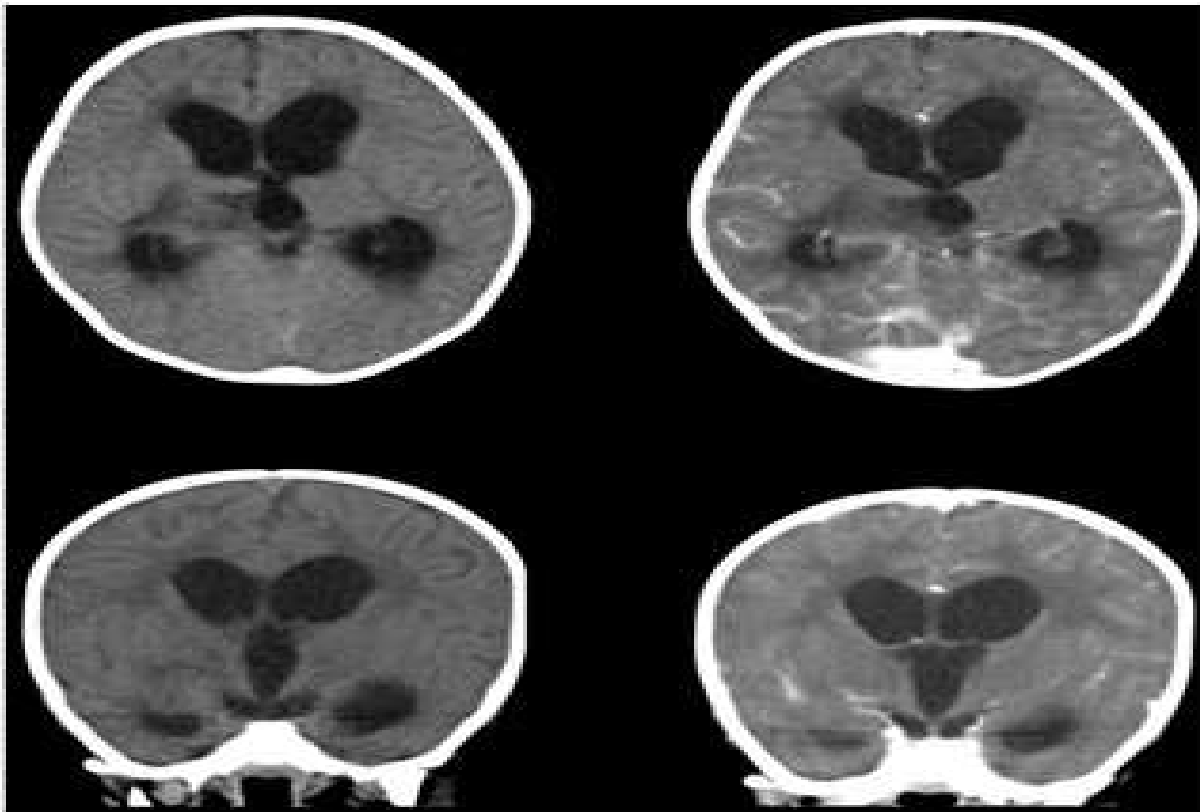


Fig. 2. CT scan brain with low attenuated areas and increase enhancements in right thalamus, posterior limb of internal capsule and right superior cerebellar peduncle with hydrocephalus.

### 9.1 Hemiparesis or quadriparesis

General weakness of the body following meningitis is usually generalized (quadriparesis) or on one side (Hemiparesis), rarely isolated monoparesis are also observed. This usually results from vasculitis, cortical vein or sagittal vein thrombosis, cerebral artery spasm, subdural effusion or empyema, hydrocephalus, cerebral infarct or abscess, or cerebral edema. Paresis generally improves with time.

## 9.2 Hearing loss

Hearing impairment after meningitis may have several reasons. Pneumococcus organism invading the cochlea through the internal auditory canal with exudative and inflammatory damage to the vestibulocochlear nerve, cochlea, and labyrinth, leads to sensorineural hearing loss. Animal studies and catastrophic studies have shown that purulent material entering from the subarachnoid space to the perilymphatic space of the inner ear through the internal ear canal or aqueductus cochlearis of the temporal bone causes destruction of hair cells in the labyrinth following inflammation. The possibility of sterile labyrinthitis caused by toxic components (lipopolysaccharides) of the bacterial cell wall or perineuritis and damage of the eighth cranial nerve can also be there. (Bhatt, 1993 & Merchant, 1996). Thrombophlebitis and vascular occlusions with lesions and focal necrosis in peripheral and central auditory pathways may be the other possible mechanism. This may be transient or permanent. All of the children with hearing loss had either one or more of the risk factors which includes disease symptoms for  $\geq 2$  days before admission, CSF glucose concentration  $\leq 10.8$  mg/dL, streptococcus pneumoniae infection, and ataxia. Audiometry must be done in all patients with acute pyogenic meningitis before discharge. Delay response of brain stem evoked potential occurs within days and generally recovers in the initial two weeks of treatment. However major deficit may persist in 11 percent of children and 12-14 percent in adults with pyogenic meningitis.

Anti inflammatory agents like dexamethasone can reduce the neurologic complications of bacterial meningitis like sensorineural hearing loss by decreasing the intracranial pressure and modulating the production of cytokines particularly in H. Influenzae type b (grade 1A). However it does not reduce these post meningitis complications induced by other organisms. Similarly demographic studies support the use of dexamethasone in high income countries, while results are not promising from low income countries. (van de Beek, D. et al., 2004)

## 10. Cerebrovascular abnormalities

Brain tissues are extremely vulnerable to ischemic injury because of its relatively high oxygen consumption and near-total dependence on aerobic glucose metabolism. Interruption of cerebral perfusion, metabolic substrate (glucose) or severe hypoxemia rapidly results in functional impairment; reduced perfusion also impairs the clearance of potentially toxic substrates from brain. If oxygen tension, blood flow, and glucose supply are not reestablished to its normal range within 3–8 min, ATP stores start depleting and irreversible neuronal injury begins in most of cases. During ischemia, intracellular  $K^+$  decreases and intracellular  $Na^+$  increases. More important, intracellular  $Ca^{2+}$  increases because of failure of ATP-dependent pumps to either extrude the ion extracellularly or into intracellular cisterns, increased intracellular  $Na^+$  concentration, and release of the excitatory neurotransmitter glutamate causes damage to neurons. Other than intracellular  $Ca^{2+}$ , chemical mediators like prostaglandins and leukotrienes are potent cellular killers. Lastly, reperfusion of ischemic tissues can cause additional tissue damage due to the formation of oxygen-derived free radicals.

Other than ischemia thromboembolism, hemorrhage or infarction, and cerebral vessel anomalies like aneurysm and vasculitis may also lead to cerebrovascular complications of bacterial meningitis. Thrombosis of superior sagittal sinus is also evident in literature. Cerebral infarction in survivors of childhood bacterial meningitis emerges as a grave and



moderately frequent complication. Factors associated with the development of cerebral infarction in childhood bacterial meningitis include age less than one year, infection with *S. pneumoniae*, severe hypoglycorrhachia, early inappropriate antibiotic therapy and male sex.

## 11. Brain abscess

Patient with meningitis induce intracranial abscess usually differs clinically from patients with meningitis or encephalitis. They are generally nontoxic with sub acute onset, but clinical condition rapidly deteriorates if brain abscess ruptures. Focal deficit and papilledema are usually present in most of these patients, while fever and neck stiffness are infrequent findings. Brain abscess is associated with high morbidity, seizures (80% of cases), persistent altered mental status, and focal motor deficits. Brain abscesses are common with rare pathogens like *Enterobacter* but are relatively rare in patients with *S. pneumoniae*, *H. influenzae*, and *N. meningitidis*.

Mortality from a brain abscess has decreased to 20 percent, as a result of earlier diagnosis and appropriate treatment. CT scan with contrast is essential to make the diagnosis of brain abscess. The typical finding on CT scan is a hypodense area with a contrast ring enhancement. Lumbar puncture is not recommended when cerebral abscess is suspected because of raised ICP and risk of herniation.

The management of brain abscess requires appropriate antibiotics and neurosurgical consultation. Broad spectrum antibiotics along with anaerobic coverage include third-generation cephalosporin and metronidazole. For penetrating trauma, surgical procedure or suspected staphylococcal add vancomycin.

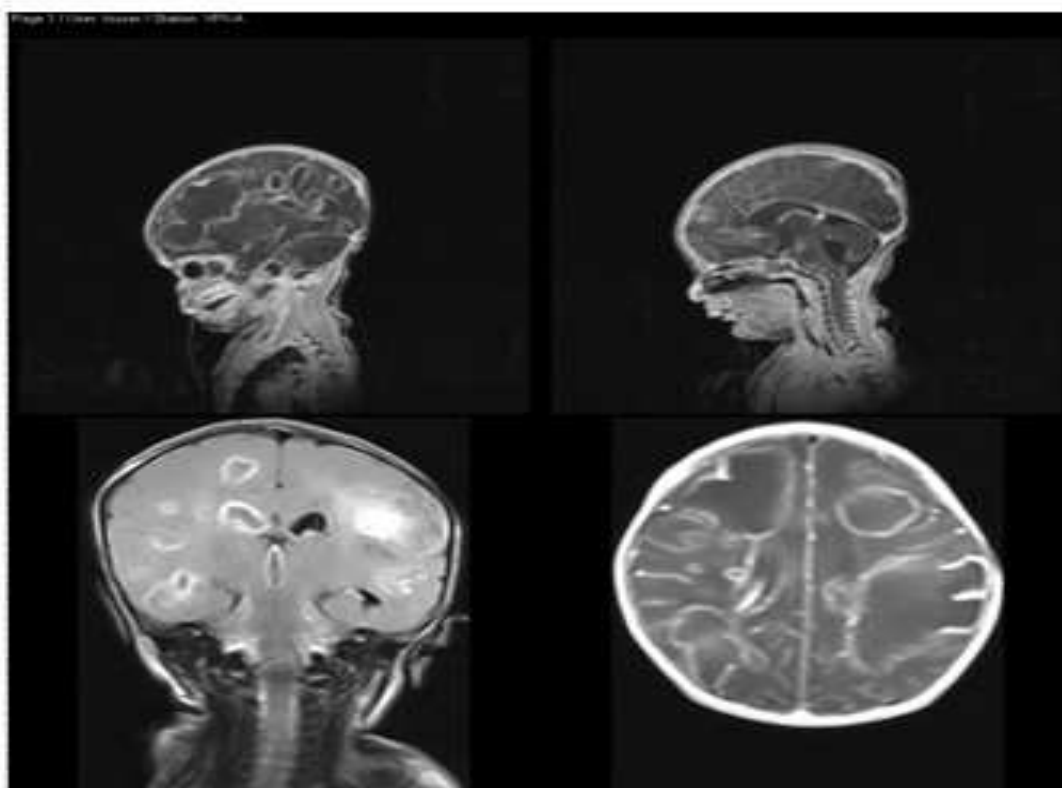


Fig. 3. MRI Brain showing multiple abscesses

## 12. Neuropsychological impairment

Neuropsychological impairment and cognitive dysfunction range from mild to severe disability and are well-recognized complication of bacterial meningitis. Neurobehavioral (50%) and neuro developmental (10-20%) sequel is more often found as residual long term defect in pediatric patients. A larger proportion of children with meningitis has IQ <70 and categorize as intellectual disability. (Braff, LJ et al., 1993). Meningitis in children under 12 months of age with high cellular count in CSF is significantly associated with impairment of language, learning, behavioral and cognitive skills. Cognitive impairment in adults is the commonest intellectual impairment in post meningitis patients. (Hogman, M. et al., 2007).

Other cognitive and somatic complaints, mood problems, social issues, thought and attention deficits, and delinquent behavior are amongst few rare complications, which need further research. (Halket, S. et al., 2003). Early identification and intervention may help to minimize the long-term impact of these problems, speech therapy.

## 13. Unusual complications

Severe permanent hydrocephalus, transverse myelitis, cortical visual impairment, aneurysm formation of focal intracranial vessels, aphasia and ataxia (Koomen, L et al., 2003) are rare neurological complications of meningitis. Reading and understanding the words and language deficit are other long term problems which should be anticipated and manage through special teaching modalities.

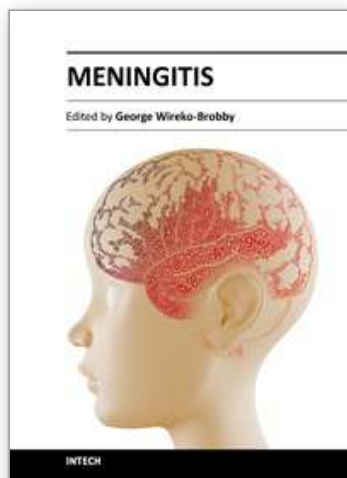
## 14. Acknowledgment

I would like to thanks Dr Yousuf Husen for his support in providing me the expert radiological assistant. I would also like to thank Ms Uzma Siddiqui who gave her enormous support and assistant in writing this book chapter.

## 15. References

- Agrawal A, Timothy J, Pandit L, Shetty L, and J.P. Shetty, A Review of Subdural Empyema and Its Management. *Infect Dis Clin Pract* 2007;15:149-153
- Anderson, V, Anderson, P, Grimwood, K, Nolan, T. Cognitive and executive function 12 years after childhood bacterial meningitis: effect of acute neurologic complications and age of onset. *J Pediatr Psychol* 2004; 29(2):67-81.
- Annegers, JF, Hauser, WA, Beghi, E, Nicolosi, A. Kurland, LT. The risk of unprovoked seizures after encephalitis and meningitis. *Neurology* 1988; 38(9):1407-10.
- Arditi, M, Mason EO Jr., Bradley, JS, Tan, TQ, Barson, WJ. Schutze, GE. Wald, ER. Givner, LB. Kim, KS. Yoqev, R. Kaplan, SL. Three-year multicenter surveillance of pneumococcal meningitis in children: clinical characteristics, and outcome related to penicillin susceptibility and dexamethasone use. *Pediatrics* 1998; 102(5):1087-97.
- Baraff, LJ, Lee, SI, Schriger, DL. Outcomes of bacterial meningitis in children: a meta-analysis. *Pediatr Infect Dis J* 1993; 12(5):389-94.
- Bhatt, SM. Lauretano, A. Cabellos, C. Halpin, C. Levine, RA. Xu, WZ. Nadol, JB Jr. Tuomanen, E. Progression of hearing loss in experimental pneumococcal meningitis: correlation with cerebrospinal fluid cytochemistry. *J Infect Dis* 1993; 167(3):675-83.

- De Gans, J. van de Beek, D. European Dexamethasone in Adulthood Bacterial Meningitis Study Investigators. Dexamethasone in adults with bacterial meningitis. *N Engl J Med* 2002; 347(20):1549-56.
- de Louvois, J. Acute bacterial meningitis in the newborn. *J Antimicrob Chemother* 1994; 34 Suppl A:61-73.
- Durand, ML. Calderwood, SB. Weber, DJ. Miller, SI. Southwick, FS. Caviness, VS Jr. Swartz, MN. Acute bacterial meningitis in adults. A review of 493 episodes. *N Engl J Med* 1993; 328(1):21-8.
- Feigin, RD. Cutrer, WB. Demmler-Harrison, GJ. Kaplan, SL. (2009). *Textbook of Pediatric Infectious Diseases, 6th ed*, chapter: Bacterial meningitis beyond the neonatal period. Saunders, Philadelphia, 2009. p.439.
- Feldman, WE. Relation of concentrations of bacteria and bacterial antigen in cerebrospinal fluid to prognosis in patients with bacterial meningitis. *N Engl J Med* 1977; 296(8):433-35.
- Halket, S. de Louvois, J. Holt, DE. Harvey, D. Long term follow up after meningitis in infancy: behaviour of teenagers. *Arch Dis Child* 2003; 88(5):395-98.
- Hoogman, M. van de Beek, D. Weisfelt, M. de Gans, J. Schmand, B. Cognitive outcome in adults after bacterial meningitis. *J Neurol Neurosurg Psychiatry* 2007; 78(10):1092-96.
- Koomen, I. Grobbee, DE. Roord, JJ. Donders, R. Fennekens-Schinkel, A. van Furth, AM. Hearing loss at school age in survivors of bacterial meningitis: assessment, incidence, and prediction. *Pediatrics* 2003; 112(5):1049-53.
- Lindval, P. Ahlm, C. Ericsson, M. Gothefors, L. Naredi, S. Koskinen, LD. Reducing Intracranial Pressure May Increase Survival among Patients with Bacterial Meningitis. *Clinical Infectious Diseases* 2004; 38(3):384-90
- Madagame, ET. Havens, PL. Bresnahan, JM. Babel, KL. Splaingard, ML. Survival and functional outcome of children requiring mechanical ventilation during therapy for acute bacterial meningitis. *Crit Care Med* 1995; 23(7):1279-83.
- Merchant, SN. Gopen, Q. A human temporal bone study of acute bacterial meningogenic labyrinthitis. *Am J Otol* 1996; 17(3):375-85
- Pfister, HW. Feiden, W. Einhaupl, KM. Spectrum of complications during bacterial meningitis in adults. Results of a prospective clinical study. *Arch Neurol*. 1993;50(6):575-581.
- Roine, I. Peltola, H. Fernández, J. Zavala, I. González Mata, A. González Ayala, S. Arbo, A. Bologna, R. Miño, G. Goyo, J. López, E. Dourado de Andrade, S. Sarna, S. Influence of admission findings on death and neurological outcome from childhood bacterial meningitis. *Clin Infect Dis* 2008; 46(8):1248-52.
- Mace, SE. Acute Bacterial Meningitis. *Emerg Med Clin N Am* 2008; 26(2):281-317
- Snedeker, JD. Kaplan, SL. Dodge, PR. Holmens, SJ. Feigin, RD. Subdural effusion and its relationship with neurologic sequelae of bacterial meningitis in infancy: a prospective study. *Pediatrics* 1990; 86(2):163.
- van de Beek, D. de Gans, J. Spanjaard, L. Weisfelt, M. Reitsma, JB. Vermeulen, M. Clinical features and prognostic factors in adults with bacterial meningitis. *N Engl J Med* 2004; 351(18):1849-59.
- Zoons, E. Weisfelt, M. de Gans, J. Spanjaard, L. Koelman, JH. Reitsma, JB. Van de Beek, D. Seizures in adults with bacterial meningitis. *Neurology* 2008; 70:2109-15.



## **Meningitis**

Edited by Prof. George Wireko-Brobby

ISBN 978-953-51-0383-7

Hard cover, 232 pages

**Publisher** InTech

**Published online** 30, March, 2012

**Published in print edition** March, 2012

Meningitis is a medical emergency requiring a rapid diagnosis and an immediate transfer to an institution supplied with appropriate antibiotic and supportive measures. This book aims to provide general practitioners, paediatricians, and specialist physicians with an essential text written in an accessible language, and also to highlight the differences in pathogenesis and causative agents of meningitis in the developed and the developing world.

### **How to reference**

In order to correctly reference this scholarly work, feel free to copy and paste the following:

Emad uddin Siddiqui (2012). Neurologic Complications of Bacterial Meningitis, Meningitis, Prof. George Wireko-Brobby (Ed.), ISBN: 978-953-51-0383-7, InTech, Available from:  
<http://www.intechopen.com/books/meningitis/neurologic-complications-of-bacterial-meningitis>

**INTech**  
open science | open minds

### **InTech Europe**

University Campus STeP Ri  
Slavka Krautzeka 83/A  
51000 Rijeka, Croatia  
Phone: +385 (51) 770 447  
Fax: +385 (51) 686 166  
[www.intechopen.com](http://www.intechopen.com)

### **InTech China**

Unit 405, Office Block, Hotel Equatorial Shanghai  
No.65, Yan An Road (West), Shanghai, 200040, China  
中国上海市延安西路65号上海国际贵都大饭店办公楼405单元  
Phone: +86-21-62489820  
Fax: +86-21-62489821

© 2012 The Author(s). Licensee IntechOpen. This is an open access article distributed under the terms of the [Creative Commons Attribution 3.0 License](https://creativecommons.org/licenses/by/3.0/), which permits unrestricted use, distribution, and reproduction in any medium, provided the original work is properly cited.

IntechOpen

IntechOpen