

# We are IntechOpen, the world's leading publisher of Open Access books Built by scientists, for scientists

6,900

Open access books available

185,000

International authors and editors

200M

Downloads

Our authors are among the

154

Countries delivered to

TOP 1%

most cited scientists

12.2%

Contributors from top 500 universities



WEB OF SCIENCE™

Selection of our books indexed in the Book Citation Index  
in Web of Science™ Core Collection (BKCI)

Interested in publishing with us?  
Contact [book.department@intechopen.com](mailto:book.department@intechopen.com)

Numbers displayed above are based on latest data collected.  
For more information visit [www.intechopen.com](http://www.intechopen.com)



# Emerging Pathogens in Neonatal Bacterial Meningitis

Marisa Rosso, Pilar Rojas, Gemma Calderón and Antonio Pavón  
UGC of Neonatology Hospital Virgen del Rocio,  
Spain

## 1. Introduction

Neonatal meningitis (NM) is a serious disease with substantial mortality and morbidity even among treated neonates (Overall, 1970; Harvey et al., 1999). Costs associated with treating false positive patients include prolonged hospital stay, exposure of the neonate to broad spectrum antibiotics, and insertion of central venous catheters for prolonged antibiotic administration.

The incidence of neonatal meningitis is difficult to accurately determine because of testing limitations. The incidence of bacterial meningitis is approximately 0.3 per 1000 live births in industrialized countries (Davies & Rudd, 1994). A recent study of neonatal infections in Asia (collecting data from China, Hong Kong, India, Iran, Kuwait, and Thailand), reported estimated incidence of neonatal meningitis from 0.48 per 1000 live births in Hong Kong to 2.4 per 1000 live births in Kuwait (Tiskumara et al., 2009). Another recent publication that looked at neonatal infections in Africa and South Asia found an incidence of neonatal meningitis ranging from 0.8 to 6.1 per 1000 live births (Thaver et al., 2009).

The rate of mortality from bacterial meningitis in developed countries among neonates has declined from almost 50% in the 1970s to less than 10% in the late 1990s due to advances in perinatal care over the last decades. However, a corresponding decrease in the morbidity rate has not occurred (Puopolo et al., 2005). Neonatal bacterial meningitis continues to be a serious disease with an unchanging rate of adverse outcome of 20-60%, despite a worldwide decline in mortality (Berardi et al., 2010). Morbidities related to neonatal bacterial meningitis continue to be a significant source of disability. In a prospective sample of more than 1500 neonates surviving until age 5 years, the prevalence of neuromotor disabilities including cerebral palsy was 8.1%, learning disability 7.5%, seizures 7.3%, and hearing problems 25.8%. No problems were reported in 65% of babies who survived group B streptococcal (GBS) meningitis and in 41.5% of those who survived *Escherichia coli* (*E.Coli*) meningitis (Bedford et al., 2001).

The three major pathogens in developed countries are: *Group B streptococcus*, gram negative rods and *Listeria monocytogenes*. Group B streptococci are the most commonly identified organisms, implicated in roughly 50% of all cases of bacterial meningitis, and *E coli* accounts for another 20%; identification and treatment of maternal genitourinary infections is thus an important prevention strategy (Klinger et al., 2000). *Listeria monocytogenes* is the third most

common pathogen, with 5-10% of cases; it is unique because it exhibits transplacental transmission (Heath et al., 2003). Historically regardless of the specific pathogen involved, neonatal meningitis is most often caused by vertical transmission during labor, but the increasing numbers of infants surviving premature delivery and advances in unit intensive care it is increasingly recognized as an emerging cause of hospital-acquired infection, particularly among severely debilitated or immunosuppressed patients. The accumulative incidence of meningitis is highest in the first month of life and is higher in preterm neonates than term neonates (Overall, 1970). For premature infants who develop meningitis, the neurodevelopmental consequences are often profound (Stoll et al., 2004). It occurs most frequently in the days following birth and is more common in premature infants than term infants (Davies & Rudd, 1994). Neonatal meningitis occurs in roughly 0.3 per 1000 live births; it is closely associated with sepsis, which is 5 times as common.

Risk factors for the development of meningitis include low birth weight (< 2500 g), preterm birth (< 37 weeks' gestation), premature rupture of membranes, traumatic delivery, fetal hypoxia, and maternal peripartum infection (including chorioamnionitis). Moreover neonates are at greater risk of sepsis and meningitis than other age groups because of deficiencies in humoral and cellular immunity and in phagocytic function. Infants younger than 32 weeks' gestation receive little of the maternal immunoglobulin received by full-term infants. (Volpe, 2008a, 2008b). Inefficiency in the neonates alternative complement pathway compromises their defense against encapsulated bacteria (Krebs et al., 2007). T-cell defense and mediation of B-cell activity also are compromised. Finally, deficient migration and phagocytosis by neutrophils contribute to neonatal vulnerability to pathogens of even low virulence.

No one clinical sign is pathognomonic of meningitis. Because the signs of meningitis are subtle and nonspecific there may be delays in diagnosis and treatment (Feigin et al., 1992).

- Bacterial meningitis, early onset
  - Symptoms appearing within the first 72 hours of life are referable primarily to systemic illness rather than meningitis. These include temperature instability, episodes of apnea or bradycardia, hypotension, feeding difficulty, hepatic dysfunction, and irritability alternating with lethargy. (Volpe, 2008 a, 2008b)
  - Respiratory symptoms can become prominent within hours of birth in GBS infection; however, the symptom complex also is seen with infection by *Escherichia coli* or *Listeria* species.
- Bacterial meningitis, late onset
  - Late-onset bacterial meningitis (symptom onset beyond 72 hours of life) is more likely to be associated with neurologic symptoms. Most commonly seen are stupor and irritability, which Volpe describes in more than 75% of affected neonates.

Between 25% and 50% of neonates will exhibit the following neurological signs: seizures; bulging anterior fontanel; extensor posturing/ opisthotonus; focal cerebral signs including gaze deviation and hemiparesis; cranial nerve palsies. Nuchal rigidity per se is the least common neurologic sign in neonatal bacterial meningitis, occurring in fewer than 25% of affected neonates.

Interpretation of cerebrospinal fluid (CSF) findings is more difficult in neonates than in older children, especially in premature infants whose more permeable blood-brain barrier causes higher levels of glucose and protein (Smith et al., 2008). So when faced with the need to make therapeutic decisions on the interpretation of CSF parameters, pediatricians, family practice physicians, and neonatologists often use The Harriet Lane Handbook as their guide (Robertson & Shilkofski, 2005). The classic finding of decreased CSF glucose, elevated CSF protein, and pleocytosis is seen more with gram-negative meningitis and with late gram-positive meningitis; this combination also is suggestive of viral meningitis, especially HSV (Garges et al., 2006). The number of white blood cells found in the CSF in healthy neonates varies based on gestational age. Many authors use a cutoff of 20-30 WBC/ $\mu$ L. Only if all 3 parameters are normal does the lumbar puncture provide evidence against infection; no single CSF parameter exists that can reliably exclude the presence of meningitis in a neonate (Garges et al., 2006). Bacterial meningitis commonly causes CSF pleocytosis greater than 100 WBC/ $\mu$ L, with predominantly polymorphonuclear leukocytes gradually evolving to lymphocytes (Garges et al., 2006).

Emerging pathogens are those that have appeared in a human population for the first time, or have occurred previously but are increasing in incidence or expanding into areas where they have not previously been reported, usually over the last 20 years (World Health Organization (WHO), 1997). In our patients, the reported risk factors associated with emerging pathogens infection are prematurity, neurosurgical procedures (especially shunts and drainages), intracranial haemorrhages. Our current patients have been undergone several neurosurgical procedures and also, importantly, have been treated with a previous broad-spectrum antibiotic, which is also a suggested risk factor for infection with these emerging pathogens (*Stenotrophomonas Maltoophilia* (Rojas et al., 2009), *Kluyvera ascorbata* (Rosso et al., 2007), *Enterobacter sakazakii* (Hunter et al., 2008) and *Rhodococcus equi* (Strunk et al., 2007). Although these pathogens are considered an infrequent cause of meningitis, it has become a focus of interest not only due to increasing recognition of its pathogenic potential but also because of its marked antibiotic resistance.

## 2. Emerging pathogens and clinical case reports

In this chapter we report several cases of these emerging pathogens meningitis in newborns successfully treated. Two of them have been reported previously for us.

### 2.1 *Rhodococcus equi* (R. equi)

*Rhodococcus equi* is a Gram-positive, aerobic, pleomorphic, nonmotile, branching filamentous coccobacillus and was first isolated from the lungs of foals in Sweden in 1923 by Magnusson. Called *Rhodococcus* because of its ability to form a red (or salmon-colored) pigment, *R. equi* can be weakly acid-fast and bears a similarity to diphtheroids. *R. equi* primarily causes zoonotic infections that affect grazing animals. The first report of human infection occurred in the 1960s. The natural reservoir for this organism appears to be soil. The two main methods of acquiring this organism are inhalation and direct inoculation through trauma. Infections with *R. equi* have a significant potential for hematogenous dissemination, with bacteremia occurring in up to 80% of immunocompromised patients (Emmons et al., 1991).

### 2.1.1 Case report

Patient was born as the first of twin brothers at 27 +2 weeks. The pregnancy was complicated by twintwin-transfusion syndrome, with twin 1 being the recipient. Delivery was by cesarean section for fetal distress. The APGAR scores at 1 and 5 minutes were 8 and 9, respectively. Shortly after delivery, the baby developed respiratory distress syndrome requiring intubation and ventilation for 2 days. After that, respiratory support was by continuous positive airway pressure. On day 10, sepsis with coagulase-negative staphylococci was treated with intravenous vancomycin (10 days) and gentamicin (3 days). Head ultrasound examination on day 1 was normal, but a repeated scan on day 7 revealed a right-sided grade III intraventricular hemorrhage. Subsequent examinations demonstrated a slow increase of the size of the lateral ventricles and elevated resistive indices indicative of posthemorrhagic hydrocephalus. Therapeutic lumbar punctures performed 2–3 times per week yielded sterile cerebrospinal fluid (CSF). Cerebral magnetic resonance imaging on day 57 demonstrated post hemorrhagic aqueduct stenosis with dilated lateral and third ventricles. A ventriculoperitoneal-shunt was inserted on day 59 under perioperative antibiotic prophylaxis with intravenous vancomycin (1 dose) and cefotaxime (3 doses). On day 61, the baby developed apnea episodes and seizures requiring intubation and mechanical ventilation. A lumbar puncture was performed and CSF showed 24 106/L white cells (56% neutrophils) and 56 106/L erythrocytes. Gram-positive bacilli were seen in the CSF. Empiric antibiotic treatment with intravenous vancomycin (15 mg/kg/dose twice daily), meropenem (40 mg/kg/dose thrice daily), and ciprofloxacin (10 mg/kg/dose twice daily) was started. The VP-shunt was externalized on day 63 and removed on day 67. Cultures of the removed shunt and follow-up lumbar puncture CSF did not grow bacteria. The initial CSF culture had bacterial growth on day 68. CSF plated onto Blood Agar (Columbia agar base, Oxoid, Melbourne, Australia) and Chocolate Agar (GC agar base, Oxoid) and incubated at 35°C in a 5% CO<sub>2</sub> atmosphere for 48 hours grew colonies 3–4 mm in diameter, irregularly round, smooth, and semitransparent. Production of salmon-colored pigmentation occurred after 4 days incubation. Gram stain revealed the presence of irregular shaped Gram-positive bacilli. Colonies were catalase- positive, oxidase negative, nitrate reduction positive, alkaline phosphatase positive, and urease negative. By the API Coryne system (Biomérieux, Marcy l'Etoile, France), the profile number was 1100004. The organism produced equi factors that interacted with the beta-toxin of *Staphylococcus aureus* to give an area of complete hemolysis on Sheep Blood Agar (Trypticase Soy agar base, Oxoid). Identification of *Rhodococcus equi* was confirmed by cellular fatty acid analysis and DNA sequencing. The antibiotic regimen was changed to intravenous vancomycin (15 mg/kg/dose twice daily) and rifampin (20 mg/kg once daily) and continued until day 90. This was followed by oral treatment with rifampin (10 mg/kg once daily) and azithromycin (10 mg/kg once daily) for a further 3 months. The baby's condition improved, and the CSF white cell count normalized. At the chronologic age of 6.5 months, a VP-shunt was reinserted without complications because of increasing hydrocephalus. When last seen at corrected age of 1 year, the boy had made good developmental progress with only slightly delayed motor skills.

### 2.2 *Kluyvera ascorbata* (K. ascorbata)

A new genus in the family *Enterobacteriaceae* in 1981 using molecular characterization and deoxyribonucleic acid (DNA)-DNA hybridation techniques. Strains of *Kluyvera* were



divided into two named species, *Kluyvera ascorbata* and *Kluyvera cryocrescens*, and a third unnamed group, *Kluyvera* species group 3 (Farmer et al., 1981). The genus currently consists of 4 species, *K. ascorbata*, *K. cryocrescens*, *K. georgina* (formerly species group 3) and *K. cochleae* (Carter et al., 2005). It is a small, motile Gram-negative bacillus with peritrichous flagella that is oxidase- negative and catalase- positive, and it ferments glucose (Farmer et al., 1981; Brooks et al., 2003; Narchi et al., 2005; Paredes-Rodriguez et al., 2002). Confirmatory species identification of *Kluyvera* requires the demonstration of ascorbate utilization and glucose fermentation at 5°C. *Kluyvera* is present in the environment in water, soil, sewage, hospital sinks, and food products of animal origin (Brooks et al., 2003). It also has been isolated from a variety of human specimens (most commonly sputum, urine, stool, throat, and blood). It was initially considered to be a benign saprophyte predominantly colonizing the respiratory, gastrointestinal or urinary tract (Carter et al., 2005; Narchi et al., 2005; Sarria et al., 2001).

### 2.2.1 Case report

A male infant was born full term with a prenatally diagnosed lumbosacral myelomeningocele and dilated cerebral ventricles. The herniation was reduced and the defect repaired and a ventriculoperitoneal shunt was inserted. Five days following surgery he developed fever, irritable crying and poor appetite. The physical examination was otherwise normal. Blood tests showed a peripheral white blood cell count of  $4 \times 10^9$  /L, normal hemoglobin and platelet count and a C-reactive protein of 148 mg/L. Urine analysis by the dipstick method was normal. Cerebrospinal fluid obtained by ventriculoperitoneal shunt puncture was yellow and turbid. Analysis of CSF revealed pleocytosis with a white blood cell count of 11664 cells/mm<sup>3</sup> (98% neutrophils), protein 3.4 g/l, glucose 0.01 g/l. The concomitant plasma glucose was normal. Blood, urine and CSF cultures were obtained. The Gram stain of CSF was negative. Empirical antibiotic therapy with meropenem was started. Blood and urine cultures were normal. *Kluyvera ascorbata* was isolated from CSF sample. It was susceptible in vitro to third generation cephalosporins, trimethoprim, aminoglycosides, aztreonam, fluorquinolones, imipenem and amoxicillin-clavulanate; it was resistant to first generation cephalosporins and with intermediate susceptibility to second generation cephalosporins. Despite treatment with antibiotics, the patient remained febrile and with poor appetite. A computed tomography brain scan showed a left dilated ventricle. The shunt was removed and a temporary external CSF drainage was inserted. Two days after external CSF drainage was inserted, he became afebrile and appeared better. CSF analyses performed after 21 days of treatment revealed clear CSF. There were no white blood cells and the protein and glucose values were 2.7 g/l and 0.34 g/l, respectively. Gram stain of that CSF specimen failed to reveal bacteria and the culture was sterile. He received antibiotic therapy for 28 days, a ventriculoperitoneal shunt was replaced after infection was eradicated.

### 2.3 *Stenotrophomonas maltophilia* (S. maltophilia)

Is a nonfermentative Gram-negative bacillus, previously known as *Pseudomonas maltophilia* and later *Xanthomonas maltophilia*. This bacterium is found in several environments such as water, soil, plants, food and hospital settings (Nicodemo & Garcia -Paez 2007; Yemisen et al., 2008). It is increasingly recognised as a significant cause of hospital acquired infection

particularly among severely debilitated and immunosuppressed patients, those receiving longterm antimicrobial therapy and those with indwelling central venous catheters. The resultant infections are extensive, with the respiratory tract, soft tissues and the skin most frequently involved (Nicodemo & Garcia -Paez 2007; Denis et al., 1977).

### 2.3.1 Case report

A baby boy was delivered at 26 weeks of gestation after a spontaneous rupture of membranes. The patient was admitted to our neonatal intensive care unit with Apgar scores of two and eight at 1 and 5 minutes, respectively. On the 12th day of his life clinical and radiological signs of perforated necrotizing enterocolitis (NEC) occurred and required surgical intestinal resection. Cerebral ultrasound at day 15 of his life was performed and showed intraventricular haemorrhage and dilated cerebral ventricles. Because of NEC, temporary external CSF drainage was inserted. Two weeks after external CSF drainage was performed, he developed *Klebsiella Extended-spectrum beta-lactamase (ESBL)* meningitis. Antibiotic therapy with meropenem was started and the external CSF drainage was replaced. After 19 days of treatment with meropenem a new CSF sample from drainage revealed 1200 cells/mm<sup>3</sup> (95% neutrophils), protein 3.4 g/L and glucose 0.03 g/L. Gramnegative bacillus were seen on gram stain in the CSF culture and it was positive for *S. maltophilia*. The strain was only susceptible in vitro to trimethoprim-sulfamethoxazole (TMP-SMX), with a mean inhibitory concentration (MIC) of  $\leq 2/38$ , minocycline and ciprofloxacin. TMP-SMX intravenous therapy (50 mg/kg per day in two divided doses) was commenced. The external ventricular drainage was not removed at this stage because the patient's state was critical. The next sample analysis of CSF from the drainage 14 days after starting TMP-SMX revealed the following profile: white blood cell count of 1300 cells/mm<sup>3</sup> (90% neutrophils), protein 1.39 g/L and glucose 0.04 g/L. The CSF culture was still positive for *S. maltophilia* and consequently ciprofloxacin (15 mg/kg per day in two divided doses) was added to TMP-SMX. Furthermore, the external ventricular drainage was removed and after 7 days of therapy with ciprofloxacin in combination with TMP-SMX, the analysis of the CSF was normal and the culture was sterile. Finally, 21 more days of therapy were completed with both antibiotics. No adverse effects were found during ciprofloxacin treatment. There was no displacement of bilirubin with the use of sulfamethoxazole in our patient and the values were normal (maximum total bilirubin 127 mg/dL). A ventricular-peritoneal shunt was inserted after the infection was eradicated due to severe ventricular dilatation.

### 2.4 *Enterobacter sakazakii* (E. sakazakii)

Is a motile, non-sporeforming, Gramnegative facultative anaerobe. It was known as 'yellow pigmented *Enterobacter cloacae*' until 1980 when it was designated as a new species by Farmer, Asbury, Hickman and Brenner in honour of the Japanese bacteriologist Riichi Sakazaki. They reported that DNA-DNA hybridization studies found no clear generic assignment for *E. sakazakii* as it was 53–54% related to *Enterobacter* and *Citrobacter* species. A comparison of the type strains of these two genera showed that *E. sakazakii* was 41% related to *C. freundii* and 51% related to *E. cloacae*. Subsequently, since it was also phenotypically closer to *E. cloacae*, Farmer, Asbury, Hickman and Brenner (1980) assigned the organism to the *Enterobacter* genus. The natural habitat of *E. sakazakii* is unknown, but it has been isolated from a number of hospital sources (Farmer et al., 1980). Most of these reports describe single

cases. Because pigment production, a distinguishing characteristic of *E. sakazakii*, is greatly diminished at the usual incubation temperature of 36°C, it seemed likely that a number of *E. sakazakii* isolates were not recognized as atypical *E. cloacae* in the past

### 2.4.1 Cases report

Infection of the newborn is probably through ingestion of contaminated infant milk formula and not through vertical transmission from the mother during birth (Mutyjens & Kollee, 1990). The first reported association of *E. sakazakii* with contaminated Infant milk formula (IMF) powder was by (Muytjens et al., 1983) in the Netherlands studying eight cases of neonatal meningitis and sepsis. *E. sakazakii* was isolated from prepared milk formula, a dish brush and a stirring spoon. These isolates were studied in more detail later by (Smeets et al., 1998). In Iceland three cases were reported linked to milk formula contaminated with *E. sakazakii* (Biering et al., 1989). US Centers for Disease Control and Prevention (Himelright et al., 2002) reported an investigation into the 2001 Tennessee outbreak of *E. sakazakii* in a neonatal intensive care unit in which 10 cases were identified. The index case was a male infant (born at 33.5 weeks) who had been admitted to the neonatal intensive care unit because of premature birth weight and respiratory distress. After 11 days the baby developed symptoms of meningitis (fever, tachycardia, decreased vascular perfusions and suspected seizure activity) and despite being given intravenous antibiotics the infant died after a further 9 days. *E. sakazakii* was cultured from the cerebrospinal fluid. Following increased surveillance a further 10 cases of *E. sakazakii* colonisation were found on the neonatal unit; 2 from 'non-sterile' site with clinical deterioration. The use of infant formula milk was the only factor associating the cases. More recently (Simon et al., 2010) described a case of meningitis in a neonatal intensive care unit occurred as a result of the use of a powered infant formula contaminated with *E. sakazakii* at manufacturing level, and an inadequate preparation and storing of the reconstituted product were identified as risk factors.

## 3. Discussion

The potential virulence of these pathogens above mentioned have been uncertain in the past, owing in part to its relatively recent characterization and the small number of reported clinical infections.

The reported risk factors associated with these pathogens infection are prematurity, neurosurgical procedures (especially shunts and drainages), intracranial haemorrhages and malignancies (Caylan et al., 2002). Our patients had undergone several neurosurgical procedures and also importantly, had been treated with a previous broad-spectrum antibiotic such as ampicillin, 3rd generation cephalosporins and carbapenem, which is also a suggested risk factor for infection. Aggressive antimicrobial intervention is lifesaving in neonates with suspected meningitis.

These emergent pathogens are increasingly recognised as a cause of nosocomial infections of special interest because of its intrinsic resistance to multiple antimicrobial agents used to treat Gram-negative infections. So (Rojas et al., 2009) found *S. maltophilia* isolates were resistant to ampicillin, cefazolin and extended spectrum penicillins, but were susceptible to the aminoglycosides and trimethoprim-sulfamethoxazole. It is resistant to a variety of antibiotics, for example aminoglycosides,  $\beta$ -lactam agents and it is intrinsically resistant to



carbapenems. Based on susceptibility studies, TMP-SMX is the drug of choice for treatment of *S. maltophilia* infections. However, recent data indicate that the percentage of strains resistant to TMP/SMX may be increasing (Nicodemo & Garcia -Paez 2007; Wen-Tsung et al., 2002; Krcmery V et al., 1999; Van den Oever et al., 1998). In this patient the pathogen was susceptible to this antimicrobial therapy but CSF cultures only became sterile after removal of the external ventricular drainage and the addition of ciprofloxacin to TMP-SMX. We decided to add ciprofloxacin because TMP-SMX is bacteriostatic and the infant was seriously ill (Table1). The administration of sulfamethoxazole, which binds to albumin and competes with bilirubin, can increase the possibility of hyperbilirubinaemia and serious neurological complications such as kernicterus in neonates. This was not observed in our patient.

Little information is available regarding the in vitro antibiotic susceptibilities and clinical effectiveness of antibiotics in *Kluyvera* infections. The agents most consistently active in vitro against *Kluyvera* are third-generation cephalosporins, fluorquinolones, aminoglycosides, imipenem, chloramphenicol, and nitrofurantoin. Most strains are resistant to ampicillin, first and second-generation cephalosporins and ticarcillin. Agents with variable activity include ampicillin-sulbactam, aztreonam, piperacillin, tetracycline and trimethoprim-sulfamethoxazole. (Narchi et al., 2003; Sarria et al.,2001). In our case, above mentioned the *Kluyvera* species was also sensitive to third-generation cephalosporins, quinolones, aminoglycosides and carbapenems. We used meropenem with a good clinical response. We used this antibiotic because of predisposing factors for resistant hospital acquired microorganisms such as colonization with nosocomial pathogens, broad spectrum antibiotic usage, underlying disease and intensive care unit admission.

Case No	Reference/ Year	Age/sex	Neurosurgical procedure	Therapy	Outcome
1	1977	8 months/male	None	Ampicilin, colistin	Died
2	1977	13 months/female	None	Chloramphenicol, sulphadoxine	Recovered
3	1984	7 days/male	None	None	Died
4	2002	4 days/female	None	Ciprofloxacin	Recovered
5	2009	69 days/male	External (CSF) drainage	TMP-SMX, ciprofloxacin	Recovered

Table 1. Details of children with meningitis caused by *S. maltophilia*

(Lai, 2001) found all *E. sakazakii* isolates were resistant to ampicillin, cefazolin and extended spectrum penicillins, but were susceptible to the aminoglycosides and trimethoprim-sulfamethoxazole. Whereas sensitivity to 3rd generation cephalosporins and the quinolones was variable. Subsequently (Lai, 2001) proposed the use of carbapenems or 3rd generation cephalosporins with an aminoglycoside or trimethoprim with sulfamethoxazole. This treatment regime has improved the outcome of *E. sakazakii* meningitis though the resistance of *Enterobacter spp.* to these antibiotics is increasing (Lai, 2001; Dennison & Morris, 2002) have reported an *E. sakazakii* infection that was resistant to multiple antibiotics, including ampicillin, gentamicin and cefotaxamine.

Other hand selection of antibiotics should be determined based on likely pathogen, local patterns of antibacterial drug sensitivities, and hospital policies. When NM is suspected, treatment must be aggressive, as the goal is to achieve bactericidal concentration of antibiotics and to sterilize CSF as soon as possible with empiric antibiotic treatment should include agents active against all main pathogens; but we must be alert because these novel pathogens are resistant to a variety of antibiotics, for example aminoglycosides,  $\beta$ -lactam agents and including to carbapenems. Here, we have reported our experience with these emerging pathogens in neonatal meningitis.

#### 4. Conclusion

In summary we are witnessing new emerging pathogens causing potentially fatal bacterial neonatal meningitis. Here, we report our experience with these emerging pathogens. Given the expected increase in the future regarding the frequency of these emerging pathogens causing nosocomial infections including meningitis due to these organisms in neurosurgical patients and its marked resistance to antibiotics, they should be considered as a potential cause of meningitis in neonates with external ventricular drainage who are receiving long term broad spectrum antimicrobial therapy.

#### 5. Acknowledgements

We would like to express our gratitude to Dr. Olaf Neth for technical support.

#### 6. References

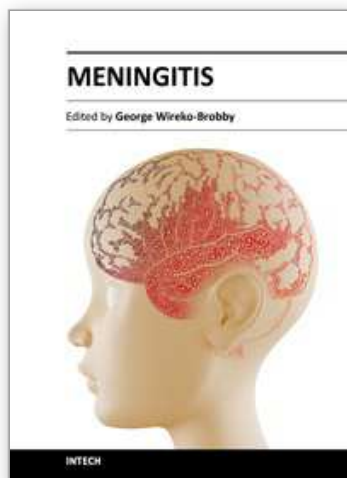
- Bedford, H.; de Louvois, J; Halket, S.; Peckham, C.; Hurley, R. & Harvey, D.(2001). Meningitis in infancy in England and Wales: follow up at age 5 years. *BMJ*. Sep 8 323(7312), pp.533-6.
- Berardi, A.; Lugli, L.; Rossi, C.; China, MC.; Vellani, G.; Contiero, R.; Calanca, F.; Carmelo, F.; Causula, F.; DiCarlo, C.; Rossi, Mr.; Chiarabini, R.; Ferrari, M.; Mininti, S.; Venturelli, C.; Silvestrini, D., Dodi, I., Zucchini, A. & Ferrari, F.(2010). Infezioni da Streptococco B Della Regione Emilia Romagna. Neonatal bacterial meningitis. *Minerva Pediatri*, Jun; Vol.62, (3 Suppl 1)pp.51-4
- Biering, G.; Karlsson, S.; Clark, NC.; Jonsdottir, KE.; Ludvigson, P. & Streingrimsson, O.(1989). Three cases of neonatal meningitis caused by *Enterobacter sakazakii* in powdered milk. *J Clin Microbiol*, Vol, 27, pp. 2054–56
- Brooks, T. & Feldman, S.(2003).Central venous catheter infection in a child: case report and review of *Kluyvera* infection in children. *South Med J*, Vol.96, pp.214-17.
- Carter, JE. & Evans, TN.(2005). Clinically significant *Kluyvera* infections: a report of seven cases. *Am J Clin Pathol*, Vol.123, pp.34-338
- Caylan, R.; Aydin, K. & Koksall, I.(2002). Meningitis cause by *Stenotrophomonas maltophilia*: case report and review of the literature. *Ann Saudi Med.*, Vol. 22, pp.216-8.
- Davies, PA. & Rudd, PT.(1994). Incidence; The Developing Brain. In: *Neonatal Meningitis*. Cambridge, England: Cambridge University Press;
- Dennison, S K. & Morris, J.(2002). Multiresistant *Enterobacter sakazakii* wound infection in an adult. *Infections in Medicine*, Vol.19, pp.533–35.

- Denis, F.; Sow, A. & David M. (1977). Etude de deux cas de meningitis a *Pseudomonas maltophilia* observes au Senegal. *Bull Soc Med Afr Noire Lang Fr*, Vol. 22, pp.135-9.
- Emmons, W.; Reichwein, B. & Winslow, DL (1991). *Rhodococcus equi* infection in the patient with AIDS: literature review and report of an unusual case. *Rev Infect Dis*, Vol.13, pp.91-6.
- Farmer, JJ III.; Asbury, MA.; Hickmann, FW. & Brenner, DJ. (1980). *Enterobacter sakazakii*: a new species of "Enterobacteriaceae" isolated from clinical specimens. *Int. J. Syst. Bacteriol*, Vol.30, pp.569-84.
- Farmer, JJ III.; Fanning, GR.; Huntley-Carter, GP.; Holmes, B., Hickman, FW.; Richard, C. & Brenner, DJ. (1981) *Kluyvera*, a new (redefined) genus in the family Enterobacteriaceae: identification of *Kluyvera ascorbata* sp. nov. and *Kluyvera cryocrescens* sp. nov. in clinical specimens. *J Clin Microbiol*, Vol. 13, pp.919-933
- Feigin, RD.; McCracken, GH Jr. & Klein, JO.(1992). Diagnosis and management of meningitis. *Pediatr Infect Dis J*, Vol.11, pp.785-814
- Garges, HP.; Moody, MA.; Cotten, CM.; Smith, PB.; Tiffany, KF.; Lenfestey, R.; Li, JS.; Fowler, VG. & Benjamin, DK Jr.(2006). Neonatal meningitis: what is the correlation among cerebrospinal fluid cultures, blood cultures, and cerebrospinal fluid parameters?. *Pediatrics*, Apr; Vol. 117(4), pp. 1094-100
- Heath, PT.; Nik Yusoff, NK. & Baker, CJ.(2003). Neonatal meningitis. *Arch Dis Child Fetal Neonatal Ed*. May, Vol.88(3), pp.F173-8.
- Himelright, I.; Harris, E.; Lorch, V.; Anderson, M.; Jones, T.; Craig, A.; Kuehnert, M.; Forster, T.; Arduino, M.; Jensen, B. & Jernigan, D.(2002). Enterobacter sakazakii infections associated with the use of powdered infant formula – Tennessee, 2001. *Morbidity Mortality Weekly Report*, Vol.51, pp. 298-300.
- Iversen, C. S & Forsythe, J. (2003). Risk profile of *Enterobacter sakazakii*, an emergent pathogen associated with infant milk formula. *Trends Food Sci. Technol*, Vol.11, pp. 443-54
- Klinger, G.; Chin, CN.; Beyene, J. & Perlman, N.(2000). Predicting the outcome of neonatal bacterial meningitis. *Pediatrics*, Sep Vol.106(3), pp.477-82
- Krcmery, V Jr.; Filka, J.; Uher, J.; Kurak, H.; Sagat, T.; Tuharsky, J.; Novak, I.; Urbanova, T.; Kralinsky, K.; Mateicka, F.; Krcmeryová, T.; Jurga, L.; Sulcová, M.; Stencl, J. & Krúpová, I.(1999) Ciprofloxacin in treatment of nosocomial meningitis in neonates and in infants: report of 12 cases and review. *Diagn Microbiol Infect disease*, Vol.35, pp.75-80.
- Krebs, VLJ. & Costa GAM. (2007). Clinical outcome of neonatal bacterial meningitis according to birth weight. *Arq*, December; Vol.65, pp.1149-1153.
- Lai KK.(2001). Enterobacter sakazakii infections among neonates, infants, children, and adults: Case reports and a review of the literature. *Medicine*, Vol.80, pp.113-122
- Magnusson, H(1923). Spezifische infektiöse Pneumonie beim Fohlen: ein neuer Eitererreger beim Pferd. *Arch Wiss Prakt Tierheilkd*, Vol.50, pp.22-38
- Muytjens, HL.; Zanen, HC.; Sonderkamp, HJ.; Kollee, LA.; Wachsmuth, IK. & Farmer, JJ.III.(1983) Analysis of eight cases of neonatal meningitis and sepsis due to Enterobacter sakazakii. *J Clin Microbiol*, Vol.18, pp.115-120
- Muytjens, HL. & Kallee, LA. (1990). Enterobacter sakazakii meningitis in neonates: causative role of formula?. *Pediatric Infectious Disease*, Vol.9, pp. 372-73.

- Narchi, H.(2005). *Kluyvera* urinary tract infection: case report and review of the literature. *Pediatr Infect Dis J*, Vol. 24, pp.570-572.
- Nicodemo, AC. & García Paez JI.(2007). Antimicrobial therapy for *Stenotrophomonas maltophilia* infections. *Eur J Clin Microbiol Infect Dis*, Vol. 26, pp.229-37.
- Overall, JC.Jr.(1970) Neonatal bacterial meningitis. Analysis of predisposing factors and outcome compared with matched control subjects. *J Pediatr*, Vol.76, pp.499-511.
- Paredes-Rodriguez, D.; Villalobos-Vinda, J.; Avilés-Montoya, A. & Alvarado-Cerdas, E.(2002) Meningitis por *Kluyvera* sp. en una paciente con una derivación lumbo-peritoneal: reporte de un caso. *Acta Med Costarric*, pp.44.
- Puopolo, KM.; Madoff, LC. & Eichenwald, EC. (2005) Early-onset group B streptococcal disease in the era of maternal screening. *Pediatrics*. May Vol.115(5), pp. 1240-6.
- Robertson, J. & Shilkofski, N.( 2005) *The Harriet Lane Handbook*. 17th (Ed). Mosby; Philadelphia, pp. 557.
- Rojas, P.; Garcia, E.; Calderón, GM.; Ferreira, F. & Rosso, M.(2009). Successful treatment of *Stenotrophomonas maltophilia* meningitis in a preterm baby boy: a case report. *Journal of Medical Case Reports*, Vol 3, pp.7389.
- Rosso, M.; Rojas, P.; Garcia, E.; Marquez, J.; Losada, A. & Muñoz, M.(2007). *Kluyvera* meningitis in a newborn. *Pediatr Infect Dis J*, Vol 26, pp. 1070-1071.
- Sarria, JC.; Vidal, AM. & Kimbrough, RC.(2001) Infections caused by *Kluyvera* species in humans. *Clin Infect Dis*. Vol. 33, pp E69-E74.
- Simón, M.; Sabaté, S.; Osanz, AC.; Bartolomé, R. & Ferrer, MD. (2010).Investigation of a neonatal case of *Enterobacter sakazakii* infection associated with the use of powdered infant formula. *Enferm Infecc Microbiol Clin*, Vol. 28, 10, pp. 713-15
- Smeets, LC.; Voss, A.; Muytjens, H L.; Meis, J F G M. & Melchers, W J G. (1998). Genetische karakterisatie van *Enterobacter sakazakii*-isolaten van Nederlandse patiënten met neonatale meningitis. *Nederlands Tijdschrift voor Medische Microbiologie*, Vol.6, pp. 113-15.
- Smith, PB.; Carges, HP.; Cotton, CM.; Walsh, TJ.; Clark, RH. & Benjamin, DK.Jr.(2008). Meningitis in preterm neonates: importance of cerebrospinal fluid parameters. *Am J Perinatol*, Aug; Vol.25(7):421-6. Epub 2008 Aug 22
- Stoll, BJ.; Hansen, NI., Adams-Chapman, I.; Fanaroff, AA.; Hintz, SR.; Vohr, B. & Higgins, RD.(2004). Neurodevelopmental and growth impairment among extremely low-birth-weight infants with neonatal infection. *JAMA*, Vol.292, pp.2357-65
- Strunk, T.; Gardiner, K.; Simmer, K.; Altas, D. & Keli AD.(2007) *Rhodococcus equi* meningitis after ventriculoperitoneal shunt insertion in a preterm infant. *Pediatr Infect Dis J*. nov; Vol.26(11), pp.1076-7.
- Tiskumara, R.; Fakharee, SH.; Liu, C-Q.; Nuntnarumit, P.; Lui, K-M.; Hammoud, M.; Lee, JKF.; Chow, CB.; Shenoi, A.; Halliday, R. & Isaacs, D.( 2009). Neonatal infections in Asia. *Arch Dis Child Fetal Neonatal Ed*. Vol. 94, pp.144-8.
- Thaver, D. & Zaidi, AK.( 2009). Burden of neonatal infections in developing countries: a review of evidence from community-based studies. *Pediatr Infect Dis J*. Jan; 28(1 Suppl), pp. S3-9.
- Van den Oever, HL.; Versteegh, FG.; Thewessen, EA.; van den Anker, JN.; Mouton, JW. & Neijens HJ.(1998) Ciprofloxacin in preterm neonates: case report and review of the literature. *Eur J Pediatr*, Vol.157, pp.843-5.

- Volpe JJ(2008b). Bacterial and fungal intracranial infections. In: *Neurology of the Newborn*. 5th. Philadelphia, Pa: Saunders Elsevier, pp.916-56.
- Volpe JJ. (2008a). Viral, protozoal, and related intracranial infections. In: *Neurology of the Newborn*. 5th. Philadelphia, Pa: Saunders Elsevier, pp.851-915.
- Wen-Tsung, L.; Chin-Chien, W.; Chuen-Ming, L. & Mong-Ling, C.(2002) Successful treatment of multi-resistant *Stenotrophomonas maltophilia* meningitis with ciprofloxacin in a pre-term infant. *Eur J Pediatr*, Vol.161, pp.680-2.
- Yemisen, M.; Mete, B.; Tunali, Y.; Yentur, E. & Ozturk, R.(2008). A meningitis case due to *Stenotrophomonas maltophilia* and review of the literature. *Int J Infect Dis*, Vol. 23, pp.1-3.





## **Meningitis**

Edited by Prof. George Wireko-Brobby

ISBN 978-953-51-0383-7

Hard cover, 232 pages

**Publisher** InTech

**Published online** 30, March, 2012

**Published in print edition** March, 2012

Meningitis is a medical emergency requiring a rapid diagnosis and an immediate transfer to an institution supplied with appropriate antibiotic and supportive measures. This book aims to provide general practitioners, paediatricians, and specialist physicians with an essential text written in an accessible language, and also to highlight the differences in pathogenesis and causative agents of meningitis in the developed and the developing world.

### **How to reference**

In order to correctly reference this scholarly work, feel free to copy and paste the following:

Marisa Rosso, Pilar Rojas, Gemma Calderón and Antonio Pavón (2012). Emerging Pathogens in Neonatal Bacterial Meningitis, Meningitis, Prof. George Wireko-Brobby (Ed.), ISBN: 978-953-51-0383-7, InTech, Available from: <http://www.intechopen.com/books/meningitis/emerging-pathogens-in-neonatal-bacterial-meningitis>

**INTech**  
open science | open minds

### **InTech Europe**

University Campus STeP Ri  
Slavka Krautzeka 83/A  
51000 Rijeka, Croatia  
Phone: +385 (51) 770 447  
Fax: +385 (51) 686 166  
[www.intechopen.com](http://www.intechopen.com)

### **InTech China**

Unit 405, Office Block, Hotel Equatorial Shanghai  
No.65, Yan An Road (West), Shanghai, 200040, China  
中国上海市延安西路65号上海国际贵都大饭店办公楼405单元  
Phone: +86-21-62489820  
Fax: +86-21-62489821

© 2012 The Author(s). Licensee IntechOpen. This is an open access article distributed under the terms of the [Creative Commons Attribution 3.0 License](https://creativecommons.org/licenses/by/3.0/), which permits unrestricted use, distribution, and reproduction in any medium, provided the original work is properly cited.

IntechOpen

IntechOpen