

We are IntechOpen, the world's leading publisher of Open Access books Built by scientists, for scientists

6,900

Open access books available

186,000

International authors and editors

200M

Downloads

Our authors are among the

154

Countries delivered to

TOP 1%

most cited scientists

12.2%

Contributors from top 500 universities



WEB OF SCIENCE™

Selection of our books indexed in the Book Citation Index
in Web of Science™ Core Collection (BKCI)

Interested in publishing with us?
Contact book.department@intechopen.com

Numbers displayed above are based on latest data collected.
For more information visit www.intechopen.com



Peripheral Nerve Reconstruction with Autologous Grafts

Fabrizio Schonauer, Sergio Marlino,
Stefano Avvedimento and Guido Molea

*Chair of Plastic Surgery, University "Federico II", Naples
Italy*

1. Introduction

A nerve gap is defined as the distance between two ends of a divided nerve. It is caused not just by the nerve tissue lost due to the trauma, or to the following debridement, but also by the actual retraction of the nerve stumps. The retraction is due to the elastic properties of the nerve fibers. Only small nerve gaps, in which minimal tension is required to contrast the elastic properties of the nerve, can be directly repaired (Fig. 1). Any significant tension at the repair site must be managed using other techniques. Peripheral nerve injuries causing gaps larger than 1-2 cm require bridging strategies for repair. Various methods exist to reconstruct nerve lesions with a significant gap: nerve grafts as autologous non-vascularised nerves, vascularised nerve grafts, interposition of venous or arterial segments or interposition of synthetic conduits. Despite the easier availability and execution of these last options, the gold standard, in nerve repair, remains the use of nerve grafts.

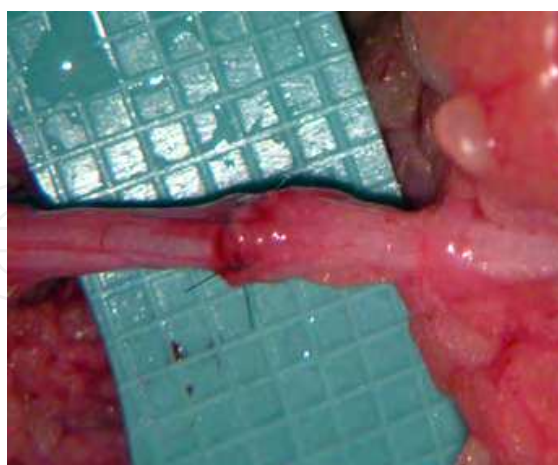


Fig. 1. Magnified view of a directly repaired digital nerve injury.

2. Nerve grafts

Nerve grafts used to be considered less effective than primary repair since the regenerating axons had to cross the gap and two neurorrhaphies. These impressions were

supported by the poor results which normally followed reconstructions using this technique; various factors influenced the results in the early attempts.¹ For a start, it was thought that the longer the nerve graft, the worse the final result would be. This led surgeons to perform all sorts of manoeuvres in order to reduce the distance between the two nerve stumps, including flexing the joints, extensive nerve mobilisations and even bone shortening. The results were disastrous because the disadvantage of the grafts (two anastomosis to cross) was combined with the disadvantage of sutures under tension. We now know that axonal regeneration takes place more easily when crossing two anastomosis sites which are free of tension than across a neurorrhaphy carried out under unfavourable conditions.

Another point of discussion was the source of the nerve grafts: the harvesting of rather thick segments from nerve trunks of considerable size was thought necessary. However, a nerve graft must first be re-vascularised before being repopulated by fibers. If the nerve graft is too thick, its central part cannot be well re-vascularised and the results of the operation will be poor. The introduction of thin nerve grafts has contributed greatly to the success of this technique.²

The principles and techniques for the use of nerve grafts are very similar to those used in primary repair. The proximal and distal ends must be carefully prepared by transverse section. The debate is whether it is better to postpone the graft reconstruction for a few weeks or not. In fact, it may be risky to re-explore the region in complex traumas in which multiple structures such as bone or blood vessels are involved. Under such circumstances, intervention using a primary nerve graft may be justified. Should this be the choice, thorough debridement must be carried out to ensure that the resection is well away from the trauma zone. The dimensions of the defect are then measured with the joints extended to ensure that repair occurs without tension, using a nerve graft of adequate length (Fig. 2 a, b).

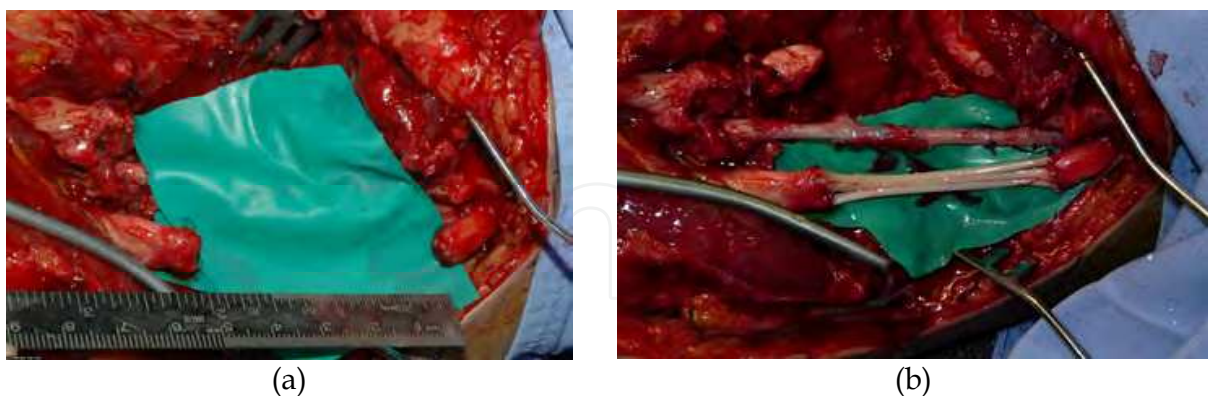


Fig. 2. (a) Median nerve defect, at the elbow level, with 5 cm nervous gap (b) Use of sural nerve cable grafts to bridge the defect. At the same time brachial artery has been repaired with a vein graft

2.1 Sources of nerve grafts

The selection of the donor nerve depends on the ease of harvesting and on post surgical morbidity. The ideal donor nerve should have the following characteristics: the sensory

deficit caused by harvesting should occur in a non-critical cutaneous region; the donor nerve should have sufficiently long segments with no lateral branches; it should be easy to locate and surgically accessible; it should have a small overall diameter and well-developed fascicles.³

Donor nerves for peripheral nerve reconstruction include: the medial antebrachial cutaneous nerve (MABCN), the lateral antebrachial cutaneous nerve (LABCN), the terminal sensitive branches of the posterior interosseous nerve and, traditionally, the sural nerve.

The MABCN can provide up to a 10 cm graft. The resultant sensory deficit lies along the medial aspect of the mid-forearm. The MABCN has also been reported as a donor graft for repair of facial nerve defects. Higgins provided criteria for the selection of donor sites for nerve harvest in digital nerve reconstruction.⁴ He investigated the cross-sectional area and number of fascicles of both donor nerves and specific digital nerve segments.

The LABCN is the terminal branch of the musculo-cutaneous nerve and provides sensory innervation to the volar forearm. It is easily harvested medial to the cephalic vein, below the elbow (Fig. 3 a, b). Both anterior and posterior divisions can be harvested, obtaining approximately 12 cm of nerve graft.

The LABCN proved to be the most suitable graft for defects at the common digital nerve bifurcation level. In terms of morbidity, the sensory deficit after LABCN harvesting, at the radial aspect of the volar forearm, can be considered negligible due to the overlap in distribution by the radial sensory branch.

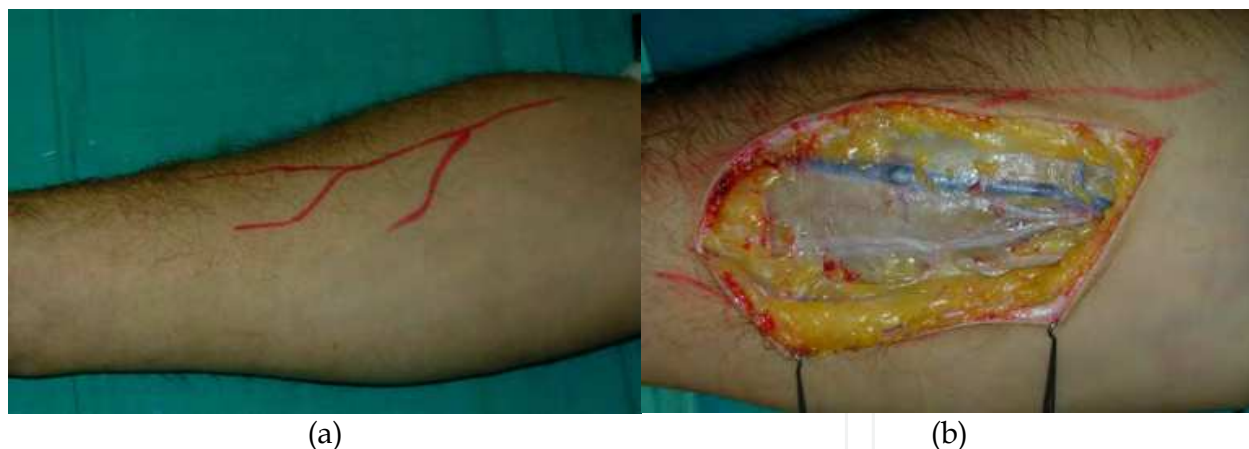

Fig. 3. (a) Lateral antebrachial cutaneous nerve (LABCN) at the right forearm (b) Harvesting of LABCN at the right forearm

Difficulties can arise when attempting to join the proximal stump of the common digital nerve with two distal stumps of proper digital nerves as in lesions occurring at the web space level. For this clinical condition, we have described the use of the lateral antebrachial cutaneous nerve (LABCN) as donor nerve, by exploiting its natural branching (Fig. 4 a, b, c). When harvested with its branches at the proximal forearm, LABCN can be a valuable alternative to provide Y-shaped nerve grafts.⁵

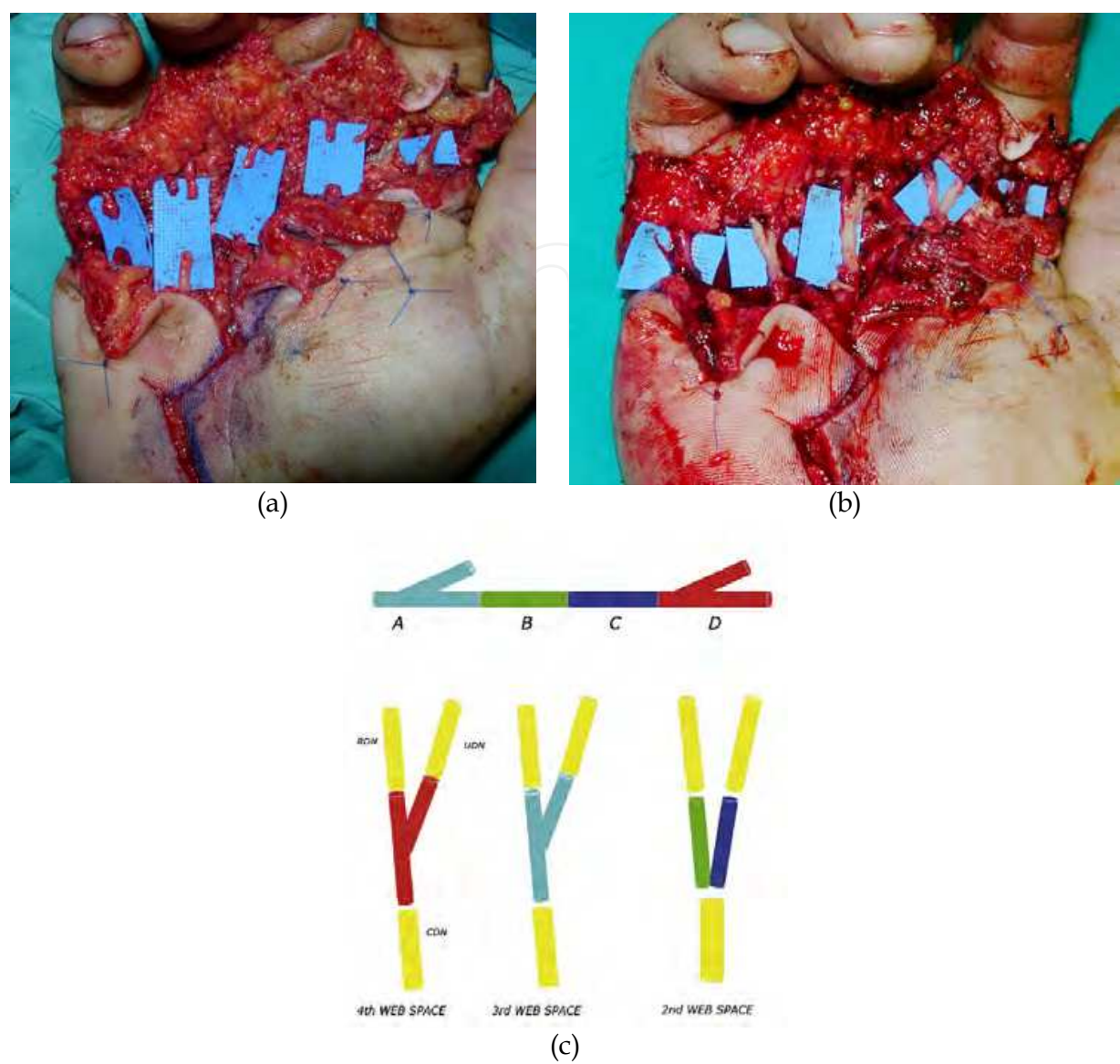


Fig. 4. (a) Right hand circular saw injury with disruption of all digital nerves in the palm with exception of the digital nerves to the thumb. (b) Use of standard and Y-shaped nerve grafts harvested from the right forearm (c) Use of LABCN and its branchings to mimic common digital nerve bifurcations.

The terminal branch of the posterior interosseus nerve has been used for distal digital nerve graft or as a single fascicular strand that can be used to replace one fascicle of the digital nerve. Today, the posterior interosseus nerve is considered a good choice for digital nerve grafting. The use of this nerve is limited, but there is no functional deficit from harvesting the nerve, as it is an articular branch. The posterior interosseus nerve is found at the wrist level, lying on the interosseous membrane deep to the extensor tendons. As it branches distally, it usually lies just ulnar and deep to the pollicis longus tendon and muscle. This nerve is obtained by a longitudinal dorsal wrist incision. After opening the deep fascia, retraction of the extensor tendons reveals the nerve lying on the interosseous membrane. Care should be taken to preserve the extensor retinaculum.⁶

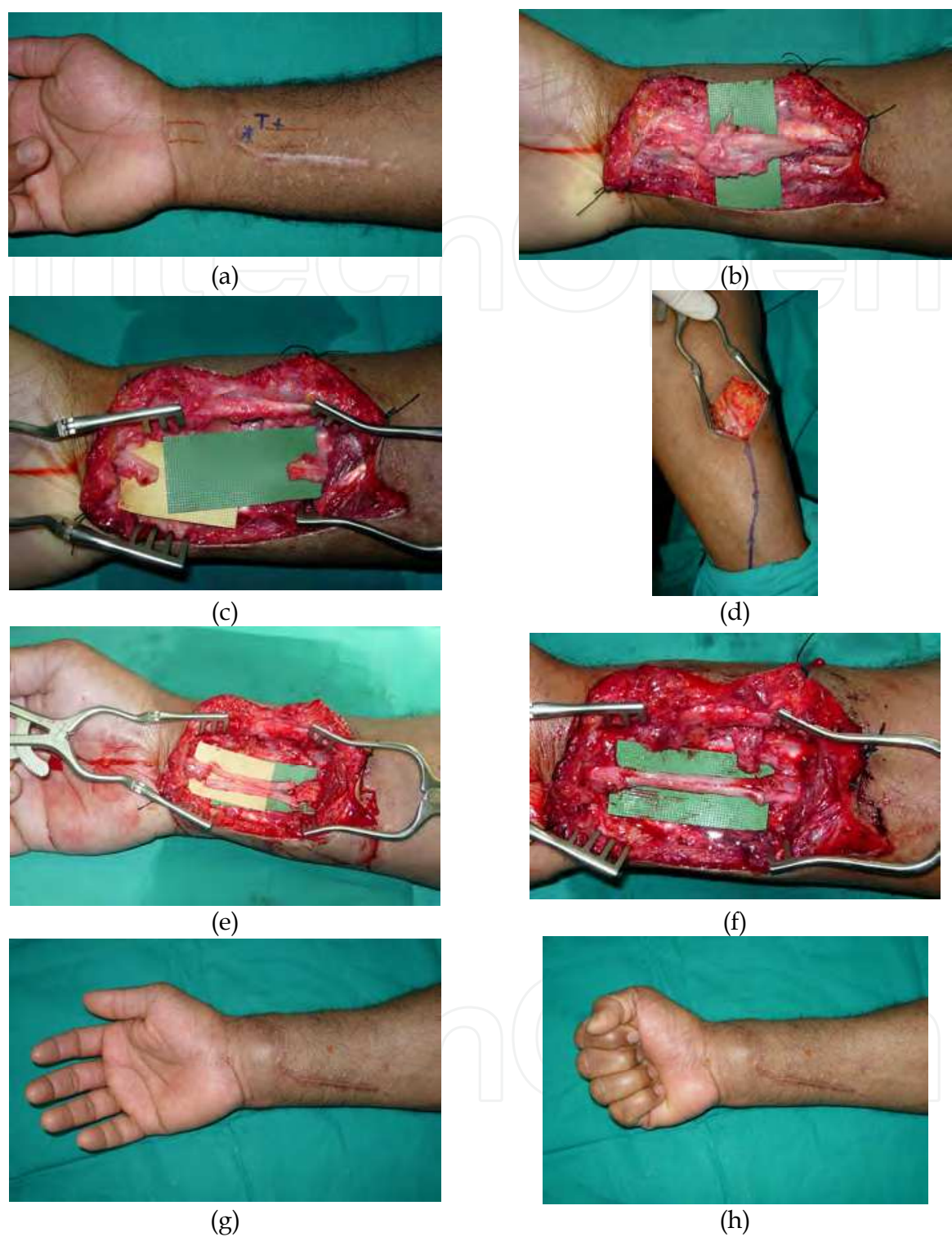


Fig. 5. (a) Right median nerve injury in a 28 years-old 2004 Indian Ocean Tsunami victim. (b) At surgical exploration presence of a large neuroma of the median nerve. (c) After neuroma excision the gap measured 6 cm. (d) Conservative approach for left sural nerve harvesting (e) Reconstruction of median nerve defect with cable grafts. (f) Tailored sural nerve grafts (g) Same patient during the rehabilitation. (h) Same patient showing clinical signs of distal re-innervation (Tinel +).

The sural nerve complex usually consists of three components: the medial sural cutaneous nerve, the peroneal communicating branch and the “proper” sural nerve. In 80% of dissections the sural nerve is formed by the union of the medial cutaneous nerve and the peroneal communicating branch. In 20% of cases the peroneal communicating branch is absent.⁷ The nerve is found adjacent to the lesser saphenous vein at the lateral malleolus. When the length of nerve graft need is limited, the peroneal communicating branch can be harvested alone and the medial sural cutaneous nerve can be saved.

Harvest of the sural nerve is usually performed with the patient in a supine position, with the lower extremity flexed and internally rotated at the hip, flexed about 40 degrees at the knee and the ankle dorsiflexed. The sural nerve in the adult can provide 30 to 40 cm of nerve graft. (Fig. 5 a, b, c, d, e, f, g, h)

Sural nerve harvest has traditionally been performed through a “stocking-seam” posterior lower leg incision. This longitudinal approach, that can theoretically extend from the lateral aspect of the ankle to the popliteal fossa, has the advantage of providing excellent visualization of the entire sural nerve anatomy.⁸

The resulting donor-site scar has a tendency to thicken and widen and can be aesthetically unsatisfactory.⁹ Alternatively multiple step incisions can be used to harvest the sural nerve.¹⁰ This method yields better donor-site scars, but the limited visualization makes the nerve vulnerable to injury.¹¹ The use of a tendon stripper with a limited incision at the ankle has also been described.¹²⁻¹³

To minimize donor-site scars and maximize visualization, endoscopic harvest of the sural nerve has been proposed by several authors (Kobayashi et al.¹⁴, Capek et al.⁹ and Eich and Fix¹⁵). Endoscopic harvest of the sural nerve offers better results in terms of scars but requires more operating time, familiarity with endoscopic techniques and proper instruments, including long scissors, a nerve retractor and a tendon or nerve stripper device. However, the increase in time as compared with conventional open methods could be counterbalanced by shorted time in suturing the wounds.¹⁶

3. Vascularized nerve grafts

The theoretical advantage of a vascularized nerve graft (VNG) lies in being able to immediately supply intra-neural perfusion in a poorly vascularized bed in the presence of very wide gaps. Their clinical role has not been well defined despite the fact that they were introduced over two decades ago. Taylor and Ham introduced free vascularized nerve grafts in an attempt to prevent ischemic graft failure.¹⁷ Initial experience with this technique in scarred beds was promising, however results and indications still remain controversial. In general, it may be said that vascularized nerve grafts are indicated when a long graft is required in a poorly vascularized bed, or when a graft with a large diameter is desired, in order to provide it with independent vascularization. Bonney et al.¹⁸ reviewed 12 cases of brachial plexus reconstruction with microsurgically revascularization nerve grafts and could only report an “impression” of improved recovery; Gilbert found no superiority of free vascularized grafting over routine sural grafts¹⁹

More recently VNG have gained a new popularity; clinical studies with VNG of sural nerve have been conducted revealing their usefulness especially in lower limb nerve reconstruction.²⁰

4. Nerve conduits

Nerve gaps which are too large to be repaired using tension-free sutures are usually reconstructed using nerve grafts (interpositional nerve grafts). Research on the alternative use of conduits is in continual expansion²¹. The advantage lies in avoiding the donor nerve sacrifice. The first works date back to 1880; since then, nerve conduits have been constructed using biological materials: bone, vein, muscle, artery and synthetic materials (silicon, polyglycolic acid and polyglactin).

For structural reasons, blood vessels were used as an obvious choice, due to the natural presence of a lumen. They were used both to protect the site of nerve anastomoses and as nerve conduits, in a number of modifications. In the past, the use of nerve conduits in nerve reconstruction has provided results inferior to those obtained using nerve grafts; today we see a renewed interest both in venous grafts²²⁻²⁵ and arterial grafts²⁶, especially for short gap reconstruction (<3 cm).

4.1 Vein grafts

As we already stated the superior regenerative performance of autologous peripheral nerve grafts has resulted in a wide acceptance as the “gold standard” for peripheral nerve repair. Nevertheless, a number of issues pushed the research towards alternative bridging materials for the repair of peripheral nerve injuries. Such issues included the comorbidity at the site of donor nerve harvesting, the obvious limitations to the amount of donor nerve that can be used and the unsatisfactory functional outcomes in some of the patients receiving nerve autografts.

Vein conduit grafting has not been accepted as an alternative to nerve grafting until 1982, when Chiu et al. proved that it produced regeneration of nerve fascicles and recovery of distal sensation.²⁷ The vein conduit graft acts as a guide for axonal sprouting and as a barrier against scar tissue ingrowth, maintaining an internal milieu for nerve regeneration.

Vein conduit grafts have two advantages compared to nerve grafts: they are readily accessible and they cause minimal donor-site morbidity.

Walton et al. reported the recovery of two-point discrimination in 12 of 18 digital nerves reconstructed with vein conduit grafts.²⁸

Chiu and Strauch found that nerve gaps of 3 cm or less could be repaired successfully with vein conduit grafting and demonstrated their efficacy in both acute and delayed digital nerve repair.²²

Tang et al. repaired nerve defects less than 3 cm long with vein conduit graft and the results were good to excellent in 61.1% of the injured digital nerves.²⁹

A potential drawback with vein grafting is that the vein wall may collapse. However, Tseng et al. have demonstrated, in the rat, that hematoma and thrombin within the vein keep the conduit patent.³⁰

A limitation of autogenous venous nerve conduit is that its success has only been demonstrated in peripheral sensory nerves with small defects (<3 cm). When nerve defects exceed 3 cm, a vein conduit graft is less effective in maintaining the growth of nerve axons.³¹

In a rabbit model it has been shown that nerve regeneration is enhanced by the distal stump of the transected nerve. This happens mainly because the distal stump of the nerve produces some key factors that promote nerve regeneration as nerve growth factor (NGF). In a rat model, the outcome of an NGF-treated vein graft was better than that of a saline-treated vein graft.³² Human study also showed good functional recovery in digital, median, ulnar, and superficial radial nerve defects longer than 3 cm with nerve tissue interposed into the vein conduit grafts.³³ Although NGF is present in the intima and adventitia of the femoral veins of rats, the amount of it in a vein graft may be insufficient to promote nerve healing.³⁴ The 3 cm limit of the vein conduit graft might be overcome by adding NGF to the wound to create a more suitable milieu for nerve regeneration

The technique of repair is based on the classic separate micro sutures (Fig. 6 a, b, c, d) or, alternatively, by a telescoping veno-neuorrhaphy in which the nerve stumps are telescoped into the lumen of the vein conduit and anchored by 9-0 or 10-0 nylon sutures.³⁵

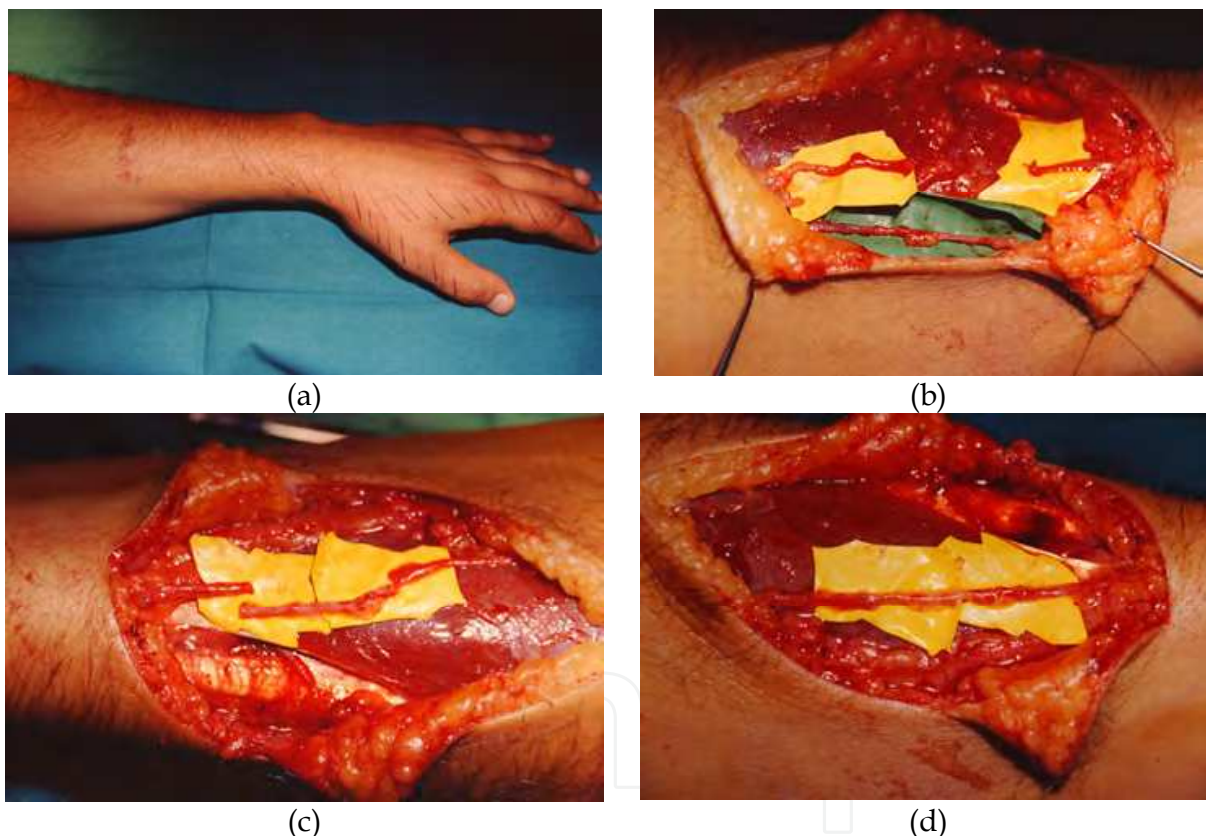


Fig. 6. (a) Division of the dorsal sensitive branch of the radial nerve at the left forearm. Loss of sensation in the skin area distal to the injury. (b) At surgical exploration the divided dorsal branch of the radial nerve and a donor vein. (c) The nervous gap measured 2,8 cm. The vein was harvested and reversed 180°. (d) Microsurgical reconstruction with the vein graft.

4.2 Arterial grafts

The possibility of using an arterial graft for nerve repair was investigated in rats in the nineties.

Itoh et al. failed to find consistent nerve fiber regeneration with artery graft. They supposed that their failure was caused by a laminin deficiency in the endothelial layer of artery wall.³⁶ They concluded that arteries should not be used for tubulization.

Many authors reported the beneficial effects of laminin and collagen in the enhancement of peripheral nerve regeneration. The artery wall has three layers: the endothelial layer contains a laminin-rich basal lamina, the media is a muscle layer that is also rich in laminin and the adventitia is rich in collagen. De Castro et al. turned the artery graft inside-out, having these anatomical layers reversed. The resulting conduit exposed regenerating axons directly to the adventitia. De Castro concluded that both the inside-out artery graft and standard artery graft were valuable techniques for the repair of sensory peripheral nerves in rats.³⁷

Our group suggested the clinical use of an arterial graft for digital nerve reconstruction: in the presence of an injured digital neurovascular bundle, after the contralateral artery flow has been checked, the use of a digital artery pro nerve graft can be an easy and quick alternative to a standard nerve graft reconstruction (Fig. 7 a, b).²⁶

These findings were confirmed by Kosutic et al. in the repair of up to 3 cm digital nerve defects with a segment of digital artery.³⁸

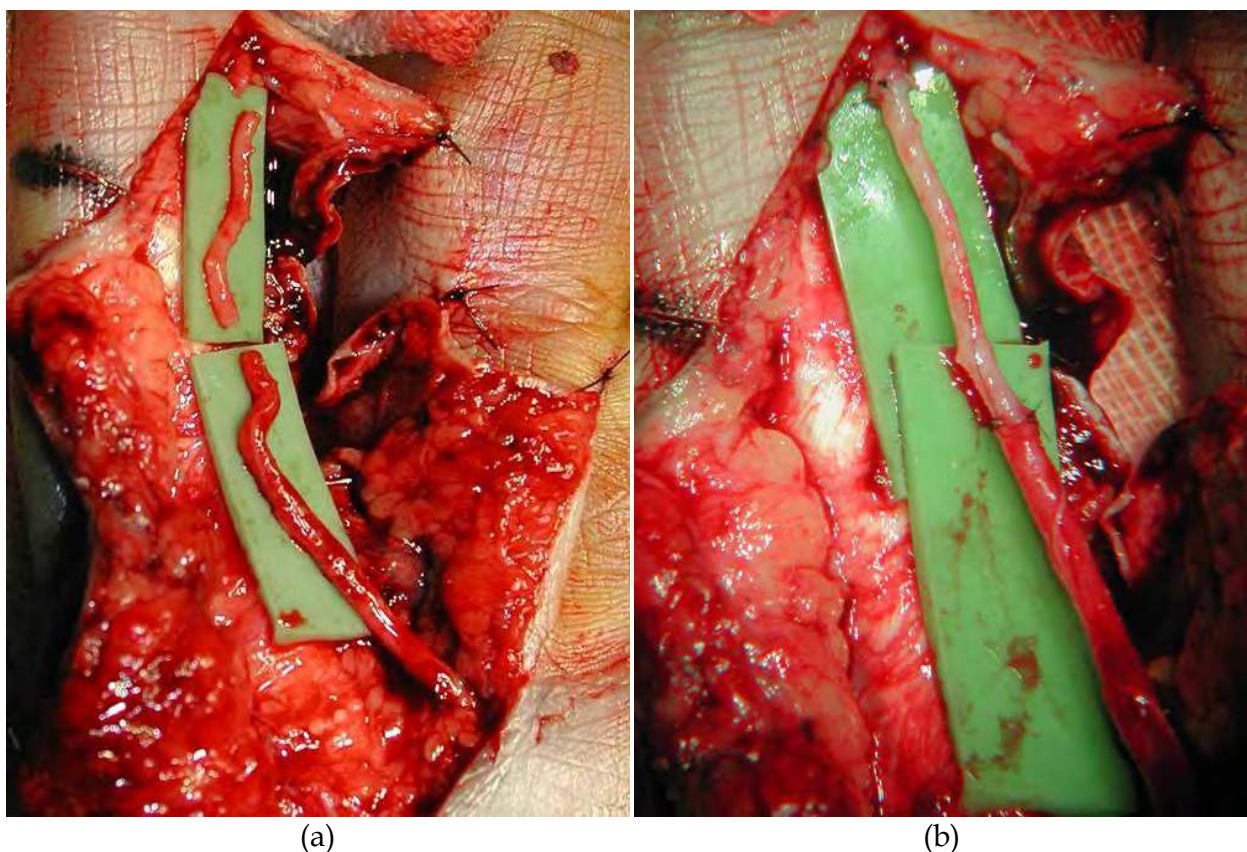


Fig. 7. (a) Right middle finger circular saw injury with division of the radial neurovascular bundle. The digital artery was used to bridge the nervous gap. (b) Microsurgical sutures at the proximal and distal stumps.

4.3 Muscle grafts

In theory, any biological tissue containing basal lamina may be a candidate to be used as a bridge for nerve regeneration.³⁵

The use of muscle conduits has been recorded by multiple authors. The rationale is that the longitudinally oriented basal lamina in skeletal muscle and the extracellular matrix components are sufficient to direct and enhance nerve regeneration. This is based on similarities between the basal lamina of muscle and the endoneural tubes of degenerating nerves.³⁹⁻⁴⁰

Studies in animals and humans have demonstrated that both fresh and denatured muscle conduits can provide successful regeneration and even lead to superior results when compared with end-to-end sutures.

Skeletal muscle may be pretreated to produce an acute necrosis of myocytes, intramuscular nerves and other cellular components of the skeletal muscle fibers. The cellular debris is removed by macrophages, producing a network of coaxially directed tubes of muscle basal lamina, lowering physical resistance and facilitating nerve regeneration.⁴¹

Numerous studies have confirmed the efficiency of frozen and thawed muscle grafting in experimental models and animals.⁴²

The first clinical trials to repair digital nerves and mixed sensory-motor nerves were encouraging as well. However, motor nerve recovery remained poor in those studies, probably because of considerable delay in repair.

The main concern regarding muscle grafts is the risk that nerve fibers can grow out of the muscle tissue during regeneration, resulting in a decreased number of axons reaching the end organ.⁴¹

Muscle can be harvested at the time of nerve repair by excising a rectangular muscle block from the inferior border of the great pectoral muscle in the anterior axillary fold. The length of harvested muscle can be approximately twice the nerve gap, to allow for shrinkage during preparation. The block of muscle is frozen in liquid nitrogen until thermal equilibrium has been obtained and then thawed in sterile distilled water. The graft is then trimmed to the appropriate size to bridge the gap, keeping its long axis aligned and leaving it about 2 mm wider in each plane than the diameter of the nerve. The prepared graft is positioned using 4 to 5 monofilament interrupted nylon stitches (Ethilon 8-0) to join the epinevrium of the nerve and the extreme periphery of the muscle graft.³³

4.3.1 Vein grafts filled with muscle

It is accepted that the use of vein or muscle graft alone is a good solution for nerve reconstruction but suitable only for bridging limited nerve defects (<3 cm). Conversely, these two techniques present important disadvantages for longer distances, such as the collapse of the vein or dispersion of the regenerating axons out of the muscle. To allow for the reconstruction of longer nerve defects and avoid vein collapse, filling of the vein with muscle, or even slices of nerve has been suggested.

In 1993, Brunelli et al. described the use of vein conduits, filled with fresh skeletal muscle, to bridge nerve defects in rats, with functional results better than those obtained with muscle or vein grafts alone and similar to those found with nerve graft.⁴³ This technique was abandoned for 7 years until Battiston et al. published a clinical report in 2000⁴⁴ and a review in 2005.⁴⁵ To avoid the dispersion of regenerating axons from the muscle guide, it may be advisable to insert the muscle into the vein or even into artificial conduits.

Even though early experimental and clinical results were good, it is not clear why muscle-in-vein conduit did not convince hand surgeons to proceed with further clinical application of this technique. Perhaps lack of clear indications and limits of use (motor or sensory nerves, or both) or difficulty in assembling the conduit itself could explain the rare application of this technique.

5. Conclusion

It has been clearly demonstrated that the influence of the distal stump can be equally well exerted using a conduit or a nerve graft over short distances less than 3 cm. A vein conduit graft is a good alternative to a nerve graft. Limitations to success are probably due to the medium inside the conduit. Substrates containing components of the extracellular matrix, fibronectin and laminin have been shown to be important as scaffolding for supporting axonal regeneration. Furthermore, several neurotrophic factors and some of their receptors have been shown to be capable of facilitating nerve regeneration. With the advancement of knowledge in the field of neurobiology, researchers are starting to report successes in the progress of regeneration beyond the critical 3 cm gap barrier.

In clinical practice, conduits can be safely used only for gaps of less than 3 cm in reconstructions of exclusively sensory nerves in patients who refuse harvesting of autologous nerve grafts. However, nerve conduits will certainly play a much more important clinical role in the future.

6. References

- [1] Bunnell S. Surgery of nerves of the hand. *Gynaecology and Obstetrics*, 1927, 44, 145-152
- [2] Beazley WC, Milek MA and Reiss BH. Results of nerve grafting in severe soft tissue injuries. *Clinical Orthopaedics and Related Research* 1984 Sep;(188):208-12.
- [3] Sunderland S, Ray L. The selection and use of autografts for bridging gaps in injured nerves. *Brain* 1947 Mar;70(1):75-92.
- [4] Higgins JP, Fisher S, Serletti JM, Orlando GS. Assessment of nerve graft donor sites used for reconstruction of traumatic digital nerve defects. *J Hand Surg Am.* 2002 Mar;27(2):286-92.
- [5] Schonauer F., Taglialatela Scafati S., LaRusca I, Molea G. Digital nerve reconstruction by multiple Y-shaped nerve grafts at the metacarpophalangeal joint level. *Plast. Reconstr Surg.* 2006 Apr. 15; 117 (5); 1661-2.
- [6] Dellon AL, Seif SS. Anatomic dissections relating the posterior interosseous nerve to the carpus, and the etiology of dorsal wrist ganglion pain. *J Hand Surg Am.* 1978 Jul; 3 (4):326-32.

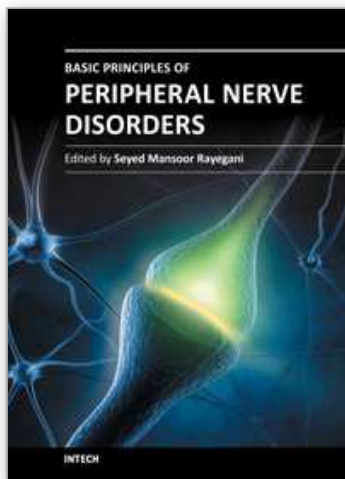
- [7] Ortigüela ME, Wood MB, Cahill DR. Anatomy of the sural nerve complex. *J Hand Surg Am.* 1987 Nov;12 (6):1119-23.
- [8] Matsuyama T, Mackay M, Midha R. Peripheral nerve repair and grafting techniques: a review. *Neurol Med Chir (Tokyo).* 2000 Apr; 40(4): 187-99.
- [9] Capek L, Clarke HM, Zuker RM. Endoscopic sural nerve harvest in the pediatric patient. *Plast Reconstr Surg.* 1996 Oct; 98(5): 884-8.
- [10] Chang DW. Minimal incision technique for sural nerve graft harvest experience with 61 patients. *J Reconstr Microsurg.* 2002 Nov, 18(8): 671-6.
- [11] Rindell K. and Telaranta T. A new atraumatic and simple method of taking sural nerve grafts. *Ann. Chir. Gynaecol.* 1984, 73:40.
- [12] Hill HL, Vasconez LO, and Jurkiewicz MJ. Method for obtaining a sural nerve graft. *Plast. Reconstr. Surg.* 1978, 61:177.
- [13] Hankin, F. M., Jaeger, S. H., and Beddings, A. Autogenous sural nerve grafts: A harvesting technique. *Orthopedics* 1985, 8:1160.
- [14] Kobayashi, S., Akizuki, T., Sakai, Y., and Ohmori, K. Harvest of sural nerve grafts using the endoscope. *Ann. Plast. Surg.* 1995, 35:249.
- [15] Eich, B. S., II, and Fix, R. J. New technique for endoscopic sural nerve graft. *J. Reconstr. Microsurg.* 2000, 16:329.
- [16] Lin CH, Mardini S, Levin SL, Lin YT, Yeh JT. Endoscopically assisted sural nerve harvest for upper extremity posttraumatic nerve defects: an evaluation of functional outcomes. *Plast Reconstr Surg.* 2007 Feb; 119(2):616-26.
- [17] Taylor G, Ham F. The free vascularized nerve graft. *Plast Reconstr Surg* 1976; 57: 413-26
- [18] Bonney G, Birch R, Jamieson AM, Eames RA. Experience with vascularized nerve graft. *Clin Plast Surg.* 1984 Jan;11(1):137-42
- [19] Gilbert A. Vascularized sural nerve graft. *Clin Plast Surg.* 1984 Jan;11(1):73-7
- [20] Terzis JK, Kostopolous VK. Vascularized nerve grafts for lower extremity nerve reconstruction. *Ann Plast Surg.* 2010 Feb;64(2):169-76
- [21] Taras JS, Nanavati V, Steelman P. Nerve conduits. *J Hand Ther* 2005 Apr-Jun; 18(2): 191-7.
- [22] Suematsu N, Atsuta Y, Hirayama T. Vein graft for repair of peripheral nerve gap. *J Reconstr Microsurg.* 1988;4:313-8.
- [23] Chiu DT, Strauch B. A prospective clinical evaluation of autogenous vein grafts used as a nerve conduit for distal sensory nerve defects of 3 cm or less. *Plast Reconstr Surg.* 1990 Nov;86(5):928-34.
- [24] Chiu D.T. Autogenous venous nerve conduits. *A review Hand Clinics* 1999 15, 667-71
- [25] Risitano G, Cavallaro G, Merrino T, Coppolino S, Ruggeri F. Clinical results and thoughts on sensory nerve repair by autologous vein graft in emergency hand reconstruction. *Chir Main.* 2002; 21: 194-7
- [26] Schonauer F, La Rusca I, Molea G. Homolateral digital artery nerve graft. *Plast Reconstr Surg.* 2006 Apr 15;117(5):1661-2.
- [27] Chiu DT, Janecka I, Krizek TJ, Wolff M, Lovelace RE. Autogenous vein graft as a conduit for nerve regeneration. *Surgery* 1982;91:226-

- [28] Walton RL, Brown RE, Matory WE Jr, Borah GL, Dolph JL. Autogenous vein graft repair of digital nerve defects in the finger: A retrospective clinical study. *Plast Reconstr Surg* 1989;84:944-949
- [29] Tang JB, Gu YQ, Song YS. Repair of digital nerve defect with autogenous vein graft during flexor tendon surgery in zone 2. *J Hand Surg B* 1993;18:449-453.
- [30] Tseng CY, Hu G, Ambron RT, Chiu DT. Histologic analysis of Schwann cell migration and peripheral nerve regeneration in the autogenous venous nerve conduit (AVNC). *J Reconstr Microsurg*. 2003;19:331-340.
- [31] Strauch B, Ferder M, Lovelle-Allen S, Moore K, Kim DJ, Llena J. Determining the maximal length of a vein conduit used as an interposition graft for nerve regeneration. *J Reconstr Microsurg* 1996;12:521-527.
- [32] Pu LL, Syed SA, Reid M, Patwa H, Goldstein JM, Forman DL, Thomson JG. Effects of nerve growth factor on nerve regeneration through a vein graft across a gap. *Plast Reconstr Surg* 1999;104: 1379-1385
- [33] Tang JB. Vein conduits with interposition of nerve tissue for peripheral nerve defects. *J Reconstr Microsurg* 1995;11:21-26.
- [34] Levine MH, Yates KE, Kaban LB. Nerve growth factor is expressed in rat femoral vein. *J Oral Maxillofac Surg* 2002;60:729-733
- [35] Dahlin LB, Lundborg G Use of tubes in peripheral nerve repair. *Neurosurg Clin N Am* 2001; 12: 341-352
- [36] Itoh S, Shinomiya K, Samejima H, Ohta T, Ishizuki M, Ichinose S. Experimental study on nerve regeneration through the basement membrane tubes of the nerve, muscle, and artery. *Microsurgery* 1996;17: 525-534
- [37] Rodrigues Ade C, Silva MD. Inside-out versus standard artery graft to repair a sensory nerve in rats. *Microsurgery* 2001;21(3):102-7.
- [38] Kosutic D, Krajnc I, Pejkoivic B, Solman L. Autogenous digital artery graft for repair of digital nerve defects in emergency hand reconstruction: two-year follow-up. *J Plast Reconstr Aesthet Surg*. 2009 Apr;62(4):553. Epub 2008 Dec 30
- [39] Chen LE, Seaber AV, Urbaniak JR, Murrell GA. Denatured muscle as a nerve conduit: a functional, morphologic, and electrophysiologic evaluation. *J Reconstr Microsurg* 1994; 10: 137-144
- [40] Roganovic Z., Ilic S, Savic M. Acta Radial nerve repair using an autologous denatured muscle graft: comparison with outcomes of nerve graft repair. *Neurochir (Wien)* (2007) 149: 1033-1039
- [41] Meek MF, Varejao AS, Geuna S. Use of skeletal muscle tissue in peripheral nerve repair: review of the literature. *Tissue Eng* 2004; 10: 1027- 1036
- [42] Glasby MA, Gschmeissner SE, Huang CL, De Souza BA. Degenerated muscle grafts used for peripheral nerve repair in primates. *J Hand Surg* 1986; 11: 347-351
- [43] Brunelli G, Battiston B, Vigasio A, Brunelli G, Marocolo D. Bridging nerve defects with combined skeletal muscle and vein conduits. *Microsurgery* 1993;14:247-251.
- [44] Battiston B, Tos P, Cushway TR, Geuna S. Nerve repair by means of vein filled with muscle grafts. I. Clinical results. *Microsurgery* 2000; 20:32-36.

- [45] Battiston B, Geuna S, Ferrero M, Tos P. Nerve repair by means of tubulization: literature review and personal clinical experience comparing biological and synthetic conduits for sensory nerve repair. *Microsurgery* 2005;25:258 -267.

IntechOpen

IntechOpen



Basic Principles of Peripheral Nerve Disorders

Edited by Dr. Seyed Mansoor Rayegani

ISBN 978-953-51-0407-0

Hard cover, 278 pages

Publisher InTech

Published online 28, March, 2012

Published in print edition March, 2012

Peripheral nerve disorders are comprising one of the major clinical topics in neuromusculoskeletal disorders. Sharp nerve injuries, chronic entrapment syndromes, and peripheral neuropathic processes can be classified in this common medical topic. Different aspects of these disorders including anatomy, physiology, pathophysiology, injury mechanisms, and different diagnostic and management methods need to be addressed when discussing this topic. The goal of preparing this book was to gather such pertinent chapters to cover these aspects.

How to reference

In order to correctly reference this scholarly work, feel free to copy and paste the following:

Fabrizio Schonauer, Sergio Marlino, Stefano Avvedimento and Guido Molea (2012). Peripheral Nerve Reconstruction with Autologous Grafts, Basic Principles of Peripheral Nerve Disorders, Dr. Seyed Mansoor Rayegani (Ed.), ISBN: 978-953-51-0407-0, InTech, Available from: <http://www.intechopen.com/books/basic-principles-of-peripheral-nerve-disorders/peripheral-nerve-reconstruction-with-autologous-grafts>

INTECH
open science | open minds

InTech Europe

University Campus STeP Ri
Slavka Krautzeka 83/A
51000 Rijeka, Croatia
Phone: +385 (51) 770 447
Fax: +385 (51) 686 166
www.intechopen.com

InTech China

Unit 405, Office Block, Hotel Equatorial Shanghai
No.65, Yan An Road (West), Shanghai, 200040, China
中国上海市延安西路65号上海国际贵都大饭店办公楼405单元
Phone: +86-21-62489820
Fax: +86-21-62489821

© 2012 The Author(s). Licensee IntechOpen. This is an open access article distributed under the terms of the [Creative Commons Attribution 3.0 License](https://creativecommons.org/licenses/by/3.0/), which permits unrestricted use, distribution, and reproduction in any medium, provided the original work is properly cited.

IntechOpen

IntechOpen