

We are IntechOpen, the world's leading publisher of Open Access books Built by scientists, for scientists

6,900

Open access books available

186,000

International authors and editors

200M

Downloads

Our authors are among the

154

Countries delivered to

TOP 1%

most cited scientists

12.2%

Contributors from top 500 universities



WEB OF SCIENCE™

Selection of our books indexed in the Book Citation Index
in Web of Science™ Core Collection (BKCI)

Interested in publishing with us?
Contact book.department@intechopen.com

Numbers displayed above are based on latest data collected.
For more information visit www.intechopen.com



Second Malignancies in Retinoblastoma: The Real Problem

Basil K. Williams Jr. and Amy C. Scheffler

*Bascom Palmer Eye Institute, Department of Ophthalmology,
University of Miami Miller School of Medicine
USA*

1. Introduction

Retinoblastoma accounts for 6% of pediatric malignancies under the age of 5 years in the United States, (Broaddus et al., 2008) and epidemiological data suggest that the incidence is standard across populations (Kivelä, 2009). Despite its rarity, observations about the pathogenesis of this disease have enhanced our understanding of genetic cancer syndromes. Germinal or hereditary cases comprise approximately 40% of retinoblastoma cases, and all patients with the germinal *RB1* mutation are at risk for secondary malignancies. According to recent reports, some retinoblastoma patients exhibit varying degrees of mosaicism for the *RB1* mutation, allowing them to develop second primary malignancies in addition to those with standard hereditary retinoblastoma. These cancers occur in various anatomic locations such as the skull and long bones, soft tissues, skin, nasal cavity, brain, lung, and breast. The pattern of development and risk for these tumors are heavily influenced by the methods of treatment for retinoblastoma, which have shifted from enucleation to external-beam radiation to systemic chemotherapy with focal treatments. Investigations of the benefits of intra-arterial chemotherapy are ongoing with the hopes of reducing the morbidities associated with systemic therapy. Due to these improving treatment techniques, 10-year survival rates of primary retinoblastoma have been among the highest of all childhood cancers at greater than 92% in the United States and other developed countries since 1975 (Kaatsch, 2010; Linabery & Ross, 2008). Secondary malignancies have thus become an increasingly significant topic of interest as they are the leading cause of death of germinal retinoblastoma survivors in the United States.

2. History

The number of retinoblastoma survivors and their offspring increased during the mid-twentieth century as methods of detection and treatment regimens improved. This increased survival greatly enhanced insight into the pathology of retinoblastoma, including the identification of the somatic and germ-line mutation variants of sporadic retinoblastoma (Albert, 1987). Examination of the differences between unilateral and bilateral disease prompted the two-hit model of retinoblastoma by Knudson in 1971 (Knudson, 1971). This proposal led to the realization that hereditary patients carry a germinally inactivated *RB1* allele in all cells of the body before somatically suffering inactivation of the normal allele in

a retinal cell or cells. Without the tumor suppressive activity of a functional pRB, these patients become susceptible to developing second nonocular cancers. Before the 1970s, the majority of new malignancies in survivors of retinoblastoma arose in the prior radiation fields, and could be labeled as radiation-induced neoplasias (Zimmerman, 1985). Secondary tumors arising from non-irradiated areas were initially reported by Jensen and Miller (Jensen & Miller, 1971) in 1971. In 1976 Abramson et al (Abramson, 1976) demonstrated the association of the risk of nonocular cancers with heritable retinoblastoma. Jakobiec et al. (Jakobiec et al., 1977) and Bader et al. (Bader et al., 1980) are responsible for the initial identification of trilateral retinoblastoma, the occurrence of a tumor in the pineal gland or parasellar region in addition to having hereditary retinoblastoma. Subsequently, the types of second cancers, risk factors for development of second cancers, and survival after development of second cancers have been extensively reviewed.

3. Epidemiology

Survivors of retinoblastoma who carry the *RB1* mutation are not at an increased risk of dying from any cause when compared to those who have not had retinoblastoma, with the exception of second non-ocular cancers. The incidence of secondary malignancies in germinal retinoblastoma survivors has been the topic of study in many reports, (Abramson et al., 2001; Eng et al., 1993; Fletcher et al., 2004; Kleinerman et al., 2005; MacCarthy et al., 2009; Marees et al., 2008; Moll et al., 1997; Wong et al., 1997; & Yu et al., 2009) but the variance of sample size and study design in these reports has made interpretation of the cumulative incidence difficult. Using reported cumulative risk rates from sizeable studies with appreciable long-term follow-up, incidence rates are approximately 0.5% to 1% per year. These are gross estimates used for comparison across studies (Fletcher et al., 2004). Long-term follow-up of a large cohort of 1,601 retinoblastoma survivors in the United States revealed a cumulative risk of a second cancer among hereditary patients of 36% at 50 years compared to only 5.7% in patients with sporadic retinoblastoma (Kleinerman et al., 2005). Similar results were observed in a large cohort of 1927 retinoblastoma survivors in Britain with a cumulative overall incidence of second cancer among hereditary patients of 43% at 50 years compared to only 4.9% in nonhereditary retinoblastoma survivors (MacCarthy et al., 2009).

Epidemiologic evidence has indicated that incidence rates may vary based on the treatment received by the patient and the age at which it is received. It has been well documented that patients who were irradiated for retinoblastoma have a higher incidence of secondary malignancies than those who were not irradiated. Furthermore, 50% of patients who developed retinoblastoma within the first month of life and were treated with radiotherapy developed second cancers by 24 years of age (Abramson et al., 2002a). The incidence of retinoblastoma has remained stable over the last 30 years in the United States, (Broaddus et al., 2008) but the cumulative incidence of new cancers has declined as the dosage and use of radiotherapy continues to decrease (Kleinerman et al., 2005). As new and better therapies are developed this trend is likely to continue.

4. Types of second tumors

4.1 Benign

In a survey of 898 retinoblastoma survivors, Li et al. (Li et al., 1997) reported a surprising number of lipomas in patients with this hereditary disease. Rieder et al. (Rieder et al., 1998)

further promoted the idea that a predisposing *RB1* gene mutation may play a role in the development of lipomas in retinoblastoma patients, by demonstrating the recurrent loss of the same *RB1* allele in two different lipomas in the same patient. Others have reported a genetic linkage between a specific *RB1* mutation and the development of multiple lipomas, postulating that there is a linked polymorphic allele which acts as a modifying factor by affecting expression of the *RB1* gene mutation (Genuardi et al., 2001). These lipomas, when found in hereditary retinoblastoma patients, are preferentially located on the face, neck, shoulders, and upper chest (Genuardi et al., 2001). Li et al. (Li et al., 1997) additionally, found twice as many patients with hereditary retinoblastoma and lipomas developed secondary malignancies when compared to those without lipomas. These results suggest that the presence of lipomas may indicate an elevated second cancer risk and that certain germline mutations in the *RB1* gene may predispose the patient to both lipomas and secondary tumors. This finding may have future implications on follow up and screening of retinoblastoma survivors for second malignancies.

4.2 Malignant

The most common second malignancies appear to be closely related to the initial method of treatment for retinoblastoma. In the United States and the Netherlands, where external beam radiation was commonly used as primary therapy, osteosarcomas of the skull and long bones, soft tissue sarcomas, cutaneous melanomas, brain tumors including trilateral retinoblastoma, tumors of the nasal cavity, Hodgkin's disease, lung cancer, and breast cancer predominate (Kleinerman et al., 2005; MacCarthy et al., 2009; Marees et al., 2008; Wong et al., 1997). In Britain, where the majority of retinoblastoma survivors did not undergo external beam radiation, epithelial cancers were more common, especially as follow-up extended into the seventh decade (Fletcher et al., 2004). As trends in treatment continue to change and the length of follow-up continues to increase, the rate of bone and soft tissue cancer development may decline while the rate of epithelial cancers are likely to increase.

Studies on the development of additional tumors (third, fourth and fifth) in survivors of retinoblastoma and second malignancies have been performed, although without consistent results (Abramson et al., 2001; Marees et al., 2010). Epidemiologically, Abramson et al. (Abramson et al., 2001) demonstrated an incidence rate of approximately 2% per year from the time of diagnosis of the second malignancy. Marees et al. (Marees et al., 2010) reported an 8-fold increase in the risk for a third primary neoplasm compared to the general population. The latency period decreases as each additional cancer is diagnosed. Historically, male retinoblastoma survivors were reported to have a higher incidence of third malignancies, primarily because females had an increased overall mortality rate from second malignancies (Abramson et al., 2001; Eng et al., 1993). More recent studies, however, have no longer identified an increase in female mortality from second malignancies (Marees et al., 2009; Yu et al., 2009). Abramson et al. (Abramson et al., 2001) reported a predictable pattern for third, fourth, and fifth malignancy development based on location of the second tumor. In that study, patients with second malignancies of the skin or skull were more likely to develop an additional tumor in the skin and skull, respectively. Marees et al. (Marees et al., 2010) did not find this predictable pattern in a Dutch cohort.

4.3 Trilateral retinoblastoma

Trilateral retinoblastoma is a well-recognized syndrome that consists of unilateral or bilateral retinoblastoma associated with an intracranial primitive neuroectodermal tumor. The intracranial mass is often located in the pineal region, but may also be a suprasellar or parasellar tumor. A specific subset of patients are more likely to develop these lesions including those with a family history of retinoblastoma, bilateral disease, diagnosis within the first 6 months of life, and prior treatment with external beam radiation. Reviews of published cases of trilateral retinoblastoma from 1966 through 1998 and 1977 through 1997 demonstrated a poor prognosis with a median survival of 6 to 9 months (Kivelä, 1999, Paulino, 1999). More recently, a small series from Brazil corroborated the dismal prognosis by reporting a median survival of 10 months (Antoneli et al., 2007). As such, these tumors are the most frequent cause of death in retinoblastoma survivors between the ages of 5 to 10 years (Blach et al., 1994). However, promising new studies indicate that treatment of trilateral retinoblastoma with intensive chemotherapy may offer an improved prognosis (Dimaras et al., 2011; Dunkel et al., 2009).

The incidence of trilateral retinoblastoma has decreased recently, but the underlying cause for this shift remains controversial. Shields et al. (Shields et al., 2001) suggested that chemoreduction therapy may reduce the incidence of pineoblastoma. Of the 99 at risk patients treated with chemoreduction in that study, none developed pineoblastoma. However, 1 of 18 (5.5%) at risk patients not treated with chemoreduction developed trilateral retinoblastoma, which is consistent with the rate of development in other published series. None of the patients in the chemoreduction group were treated with radiotherapy, prompting some to suggest that the declining incidence of pineoblastomas may be due to the declining use of external-beam radiation therapy (Moll et al., 2002). An analysis of the published literature by Woo et al. in 2010 reported an approximately equal number of pinealomas in irradiated patients and those who were not irradiated, suggesting that radiation therapy may not play as significant a role in trilateral retinoblastoma as previously suspected (Woo & Harbour, 2010). Additional studies are needed to elucidate the relationship between chemoreduction and trilateral retinoblastoma.

It is important to note that the classification of these tumors as a second malignancy as opposed to a variant of the primary tumor is controversial. They often cannot be differentiated from retinoblastoma histologically and have occasionally been documented to occur prior to the development of ocular manifestations in some patients (Jurkiewicz et al., 2009; Moll et al., 2001). For these reasons, some studies have not included trilateral retinoblastoma as a second malignancy, but the classification has varied over the years causing some discrepancy in the literature.

4.4 Independent second non-ocular retinoblastoma

Soh et al. (Soh et al., 2011) reported a case of an independent retinoblastoma located in the ovary of a bilateral ophthalmic retinoblastoma survivor. Eighteen years after radiation of the right eye and enucleation of the left eye, the patient was found to have a large left ovarian tumor involving the fallopian tube, mesentery, and lymph nodes. Histologically, the concurrent presence of Homer Wright and Flexner-Wintersteiner rosettes confirmed the identification as retinoblastoma. Additionally, molecular analysis demonstrated mutations of both *RB1* alleles, but a different pattern of post-*RB1* mutational events from the tumors in

the eye in this patient. This difference suggests that the ovarian tumor was of a separate clonal origin from the original eye tumor. While the reasons for retinoblastoma arising ectopically in ovarian tissue are unclear, primitive neuroectodermal tumors (trilateral retinoblastoma) have been documented as second malignancies in survivors of retinoblastoma.

5. Risk factors for the development of second malignancies

5.1 Rb1 mutation

Studies have indicated that all retinoblastoma survivors who develop second malignancies carry the germinal *RB1* mutation, which inactivates the tumor suppressor gene that is expressed in all adult tissues. The protein encoded by *RB1* functions in multiple cellular processes including proliferation, DNA replication, DNA repair, and cell-cycle checkpoint control. The timing of initiation of the expression of pRB varies in each cell type, rendering patients who carry the *RB1* mutation at risk of developing malignancies in nonocular tissues.

Patients who carry the germ-line *RB1* mutation (approximately 40% of total retinoblastoma patients) have bilateral disease in up to 85% of cases. The remaining 15%, with unilateral disease, are also at increased risk for developing second cancers (Abramson et al., 2001). Patients with unilateral disease who are at high risk for carrying the germinal mutation, and therefore at increased risk for developing a second malignancy, have been identified by clinical observation. They consist of patients with a family history of retinoblastoma, patients diagnosed within the first 6 months of life, and patients with multifocal disease. Advances in mutation analysis have shown that mosaic *RB1* mutations are more common than previously thought, accounting for at least 5.5 and 3.8% of bilateral and unilateral cases, respectively (Rushlow et al., 2009). This has implications for genetic counseling conversations, as many patients likely fall on a spectrum of risk for the development of second cancers.

Long-term studies of retinoblastoma survivors in the Netherlands demonstrated a 20.4-fold increase in second malignancy compared with the general population (Marees et al. 2008). There was not a significant difference in risk of second malignancies between nonhereditary survivors and the general population.

5.2 Retinoma

Retinoma or retinocytoma is a rare intraocular malignancy that appears to be a benign variant of retinoblastoma. These lesions display inactivations of both *RB1* alleles and represent a step towards retinoblastoma development (Dimaras et al., 2008; Sampieri et al., 2008). At least 6 cases of patients with a retinoma and a second primary tumor have been published in the literature, indicating there is likely an increased risk of second malignancies in this population (Korswagen et al., 2004).

5.3 External beam radiation therapy

As the primary treatment method for retinoblastoma through much of the latter half of the 20th century, external beam radiation and its effects on second primary malignancies have

been extensively studied. Numerous studies of varying designs have reported a clear increase in second nonocular malignancies in patients who have undergone external beam radiation (Aerts et al., 2004; Marees et al., 2008; Moll et al., 2001; Wong et al., 1997). Kleinerman et al. (Kleinerman et al., 2005) reported that the cumulative risk of a second cancer among irradiated hereditary patients was 38% at 50 years compared to 21% among non-irradiated hereditary patients. Due to the proximity to the radiation field and consequent radiation exposure, there is an increase in head and neck tumors and brain tumors in retinoblastoma patients who have been previously irradiated (Abramson, 2005; Aerts et al., 2004; Kleinerman et al., 2005; Marees et al., 2009). More recent studies with longer follow-up have also demonstrated an increased risk of epithelial neoplasms in this population, but these may not be attributed to the effects of radiation (Marees et al., 2008). In addition to affecting the location of subsequent tumor development, radiation exposure appears to cause an earlier onset of second malignancies (Abramson, 2005; Chauveinc et al., 2001). Mortality has also been reported to occur earlier as irradiated hereditary retinoblastoma patients died sooner than their non-irradiated counterparts with a median age of death of 20.5 years and 40 years, respectively (Yu et al., 2009). The dose-dependent relationship of radiation administration and the development of second malignancies was established over 40 years ago, (Sagerman et al., 1969) and more recent studies have confirmed this analysis (Kleinerman et al., 2005; Wong et al., 1997). The age at which radiation therapy is administered seems to influence the incidence of second tumor development, as patients treated under the age of 1 year were twice as likely to develop a second malignancy than those radiated after the age of 1 year (Abramson & Frank, 1998). In fact, patients treated with radiation therapy after the first year of life do not seem to have an increased risk of second tumor development when compared to those who were never irradiated. Because of these effects and advancements in the use of chemotherapy, use of external beam radiation therapy has decreased significantly over the last decade. Moreover, when it is used, there is a focus on minimizing the radiation dose and limiting the field of radiation as much as possible (Chan et al., 2009; Munier et al., 2008).

5.4 Preventable risk factors

5.4.1 Sun exposure

The degree of sunlight exposure has not been directly correlated to the development of cutaneous melanoma specifically in survivors of retinoblastoma. However, the known association between ultraviolet radiation and cutaneous melanoma in the general population combined with the increased incidence of cutaneous melanomas in retinoblastoma survivors is sufficient evidence to recommend avoidance of sunlight (Trappey et al., 2010).

5.4.2 Smoking

Retinoblastoma survivors should be aggressively counseled to refrain from smoking as multiple studies have indicated an excess incidence of lung cancer and risk of death from lung cancer in relatives of retinoblastoma patients who are carriers of the *RB1* gene mutation (Sanders et al., 1989; Strong et al., 1984). The elevated risk of lung cancer and the greater risk of death from lung cancer were also demonstrated in survivors of hereditary retinoblastoma (Fletcher et al., 2004; Kleinerman et al., 2000; Marees et al., 2008; Yu et al., 2009). Moreover,

the risk of death in the hereditary survivor population was sevenfold greater than in the general population (Fletcher et al., 2004). In 2000, Kleinerman et al. (Kleinerman et al., 2000) demonstrated similar smoking rates between the general population and survivors of both hereditary and nonhereditary retinoblastoma. However more recently, Foster et al. (Foster et al., 2006) reported that hereditary survivors actually smoked significantly less than nonhereditary survivors and less than the general United States population. While smoking rates in retinoblastoma survivors appear to be improving, it is imperative that physicians encourage survivors to quit or abstain from smoking. Counseling on abstinence for smoking may also have an effect on the development of bladder cancer in this population, as an increased risk for bladder cancer in retinoblastoma survivors has been demonstrated when compared with the general population (Frobisher et al., 2010; Kleinerman et al., 2005; Marees et al., 2008). While smoking was not specifically associated with bladder cancers in this cohort, it has been shown to be the most important environmental risk factor in the general population (Hirao et al., 2009).

5.4.3 CT scans

The risk of carcinogenesis secondary to radiation exposure from computed tomography (CT) has become the focus of increased investigation over the last few decades. Epidemiological data suggests that there is a larger attributable lifetime cancer mortality risk for children undergoing radiation when compared to adults (Brenner et al., 2001; Mills et al., 2006). In fact, radiation doses above 50 millisieverts (mSv) in children and 100 mSv in adults, which can be attained with repeated imaging, increases the risk for cancer (Pauwels & Bourguignon, 2011). The effective dose of CT scans vary from approximately 2 mSv for a head CT scan to approximately 20mSv for a CT-based coronary angiography study (Pauwels & Bourguignon, 2011). With the amount of scans required for appropriate cancer surveillance, retinoblastoma survivors will likely reach doses that increase the risk of cancer. Considering the increased risk of developing radiation-induced cancers in patients with a germinal *RB1* mutation and the increased sensitivity to the carcinogenic effects of radiation in children, this cohort should avoid all forms of unnecessary radiation. For these reasons, some radiologists are recommending the avoidance of ionizing radiation altogether in retinoblastoma survivors and other populations at risk for secondary cancers (Vazquez et al., 2003).

5.5 Controversial risk factors

5.5.1 Chemotherapy

Chemotherapy has been part of the treatment regimen for retinoblastoma since the 1950s (Reese et al., 1954). Triethylene melamine was the chemotherapeutic agent of choice, often in conjunction with radiotherapy, throughout the 1950s and 1960s and was shown to increase the development of second tumors outside the field of radiation (Schlienger et al., 2004). In the 1990s, many centers began to shift from radiation towards systemic chemotherapy with an increasing focus on intra-arterial chemotherapy over the last 5 years. Because of the recent shift in management, there are not many long-term studies examining the effects on second primary neoplasms. As a result, the role of chemotherapy in the development of second cancers remains controversial. Most often current chemotherapy regimens consist of vincristine, carboplatin, and an epipodophyllotoxin, either etoposide or teniposide.

Cyclosporine has been used in addition to this combination to decrease the development of multidrug resistance. Both platinum-based drugs and topoisomerase inhibitors have been reported to increase the risk of second tumors in other primary malignancies (Hijiya et al., 2009; Klein et al., 2003; Travis et al., 1999). Some studies have reported the development of acute myelogenous leukemia and secondary leukemia in retinoblastoma survivors treated with epipodophyllotoxins and alkylating agents, respectively (Gallegos-Castorena et al., 2002; Gombos et al., 2007; Nishimura et al., 2001; Weintraub et al., 2007). In a study of 187 patients with hereditary retinoblastoma treated with carboplatin, vincristine +/- etoposide, 6 patients developed second malignancies (Turaka et al., 2011). Only 1 of these 6 developed acute myelogenous leukemia, and that patient was also treated with external beam radiation. While this study had a relatively short follow-up, the patients were followed for longer than the average latency for development of chemotherapy-related acute myelogenous leukemia. Considering this, the authors suggest that the low incidence of therapy-based leukemia in this study is reassuring. With the increased use of intra-arterial chemotherapy, direct administration via the ophthalmic artery, over the last 5 to 6 years, the systemic exposure to chemotherapy is significantly reduced. This may reduce the carcinogenic risk of chemotherapy in this population. Further studies are needed to elucidate the relationship between both intra-arterial and systemic chemotherapy and second malignant neoplasms.

5.5.2 Growth hormone

Growth hormone (GH), a treatment often administered to pediatric oncology survivors, has mitogenic and proliferogenic properties that may theoretically lead to disease recurrence or increased development of secondary neoplasms. Sklar et al. (Sklar et al., 2002) reported that treatment with GH for pediatric cancer patients may increase the risk of a secondary solid tumor, although the overall increased risk was driven largely by a small subgroup of acute leukemia survivors. A follow-up study by Ergun-Longmire et al. (Ergun-Longmire et al., 2006) concurred with the increased risk of secondary neoplasms but suggested that the risk appears to diminish with increasing length of follow-up. In 2002, Abramson et al. (Abramson et al., 2002b) reported a case of a metastatic germinal retinoblastoma survivor treated with GH who subsequently developed an osteogenic sarcoma. A more recent study by Bell et al. (Bell et al., 2009) reported 4.6 second tumor cases per 1000 patient-years of GH exposure. Leukemia was the most common primary malignancy associated with secondary tumors after growth hormone, but proportionately, retinoblastoma had a higher frequency of neoplasms. Five of the sixteen patients with retinoblastoma as the primary neoplasm developed secondary cancers. Of these, 4 were previously treated with radiation therapy, and only 3 occurred in patients with bilateral retinoblastoma. While these findings are of some concern, larger studies examining the risk of secondary cancers in retinoblastoma survivors need to be performed to derive conclusive results.

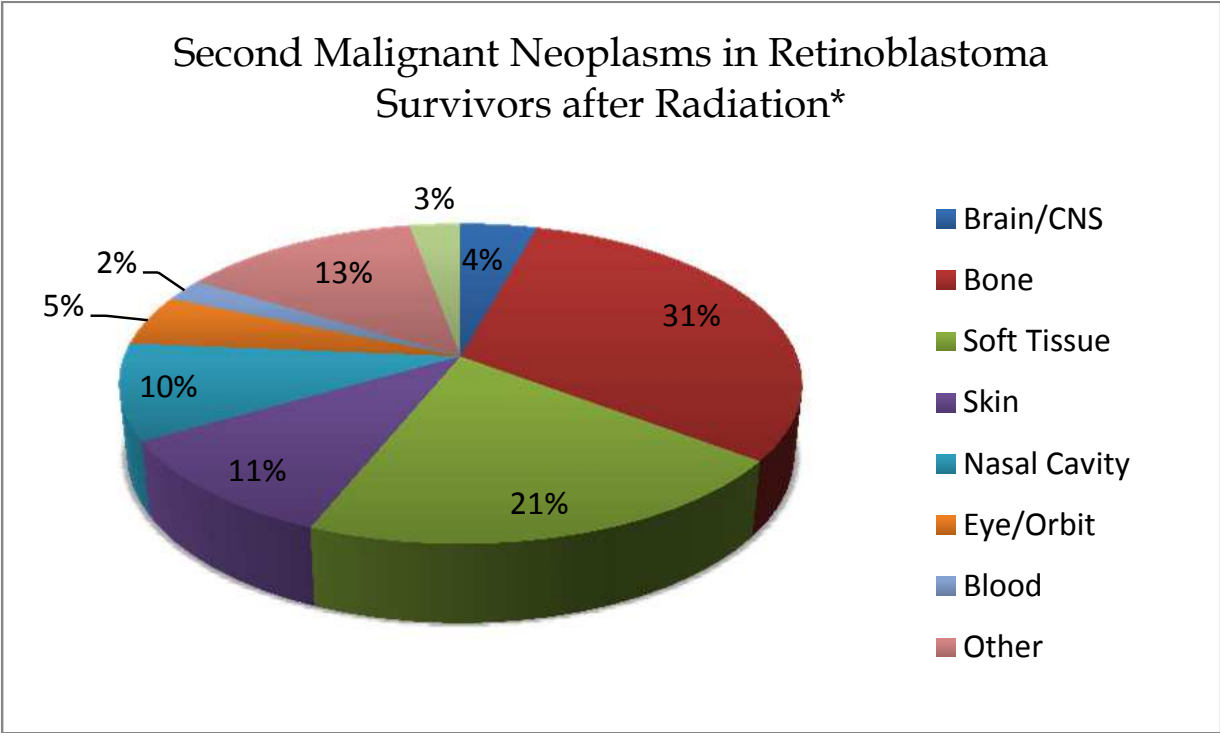
6. Survival

Although the survival rates of primary retinoblastoma are continually improving, the outcome of second malignancies does not appear to be improving with time. Reulen et al. (Reulen et al., 2010) examined the long-term cause-specific mortality among 18,000 survivors of childhood cancer in Britain, and reported a standardized mortality ratio of 24.7

Study	Location	Period	Number of Hereditary Rb Patients	Number of SMN	Cumulative Risk of SMN Development	Number of Sporadic Rb Patients	Number of SMN	Cumulative Risk of SMN Development	Number of Total Rb Patients	Number of SMN	Cumulative Risk of SMN Development
Acquaviva et al., 2006 ^o	Italy	1923-2003	408	31		703	7		1111	38	
Araki et al. 2011	Japan	1964-2007	372		33.8% at 40 years after diagnosis	382		1% at 30 years after diagnosis	754	21	19.1% at 40 years after treatment*
Fletcher et al., 2004§	United Kingdom	?	144		68.8% at 84 years of age						
Kleinerman et al., 2005	United States	1914-1984	963	260	36% at 50 years after diagnosis	638	17	5.69% at 50 years after diagnosis	1601	277	
MacCarthy et al., 2009	United Kingdom	1951-2004	809	102	48.3% at 50 years after diagnosis*	1118	13	4.9% at 50 years after diagnosis*	1927	115	
Marees et al., 2008	Netherlands	1945-2005	298	62	28% at 40 years after diagnosis	370	12	1.44% at 40 years after diagnosis	668	74	

Abbreviation: Rb, retinoblastoma; SMN, secondary malignant neoplasm. §Included hereditary patients only. ^o Included pineoblastoma as a secondary malignancy. *Adjusted for competing risk of death.

Table 1. Reported Risk of Second Nonocular Cancers in Retinoblastoma Survivors



*Radiation included external beam radiation and brachytherapy in all studies except Marees et al., 2008, which did not include brachytherapy as radiation.

Fig. 1. Pie chart demonstrating the histologic type of reported second malignant neoplasms in patients treated with radiation (Acquaviva et al., 2006; Aerts et al., 2004; Kleinerman et al., 2005; Marees et al., 2008; & Turaka et al., 2011). Some of these patients may have been treated with chemotherapy, but this information was not identified in all of the studies.

due to second cancer deaths for hereditary retinoblastoma. In the Netherlands, Marees et al. (Marees et al., 2009) reported an almost 13-fold increase of second malignancy death comparing hereditary retinoblastoma survivors to the general population. As previously stated, outcome is particularly grim in patients with trilateral retinoblastoma who have a median survival of less than 12 months. A recent long-term study of 1854 retinoblastoma survivors from the United States reported a cause-specific cumulative mortality from subsequent malignant neoplasms of 26% in hereditary survivors and 1% for nonhereditary survivors 50 years after retinoblastoma diagnosis (Yu et al., 2009). An excess in overall cancer mortality has also been reported in unilateral sporadic retinoblastoma survivors, likely because some of these patients are unilaterally affected *RB1* mutation carriers (Acquaviva et al., 2006; Yu et al., 2009). While earlier studies reported a higher mortality from second tumors in females, more recent studies have indicated an equivalent mortality in males and females.

7. Screening

Screening practices for secondary tumors in retinoblastoma survivors have not been extensively studied and no universal protocol has been determined to date. Sheen et al. (Sheen et al., 2008) examined the cancer screening behavior in 875 retinoblastoma survivors. The rates of patients ≥40 years who underwent a mammogram within the past 2 years and

≥18 years who underwent a Papanicolaou smear within the past 3 years were comparable between retinoblastoma survivors, other childhood cancer survivors who had received chest or mantle irradiation, and the general US population. Hereditary survivors were 3 times more likely to undergo an MRI or CT scan as a screening tool for second cancers. Neuroimaging with MRI has been recommended as the primary imaging modality, particularly in young retinoblastoma survivors, because of the increased risk for second malignancies with repeated exposure to ionizing radiation (ie. CT scans). However, a prospective study of routine screening with MRI performed in 226 retinoblastoma patients did not yield improved outcomes in patients who developed trilateral retinoblastoma (Duncan et al., 2001).

8. Conclusion

As treatment methods for retinoblastoma continue to evolve, the type and distribution of second non-ocular malignancies will continue to change. External beam radiation, once the mainstay of primary retinoblastoma management, increases the incidence of and mortality from second neoplasms, especially in the head and neck area. With an increased use of chemotherapy and longer duration of follow-up, malignancies of epithelial origin may become more common in this cohort. The potential for an increase in therapy-related leukemia is present with the use of chemotherapy, but additional long-term studies are required to assess the validity of this relationship. Survivors of retinoblastoma, particularly patients carrying a germinal *RB1* mutation or who have a retinoma, should undergo lifelong surveillance for second primary tumors. They should also avoid smoking, damaging exposure to sunlight, and ionizing radiation when possible.

9. References

- Abramson, D.H., Ellsworth, R.M., & Zimmerman, L.E. (1976). Nonocular cancer in retinoblastoma survivors. *Trans Sect Ophthalmol Am Acad Ophthalmol Otolaryngol*, Vol.81, No.3 Pt.1, (May-Jun 1976), pp. 454-457
- Abramson, D.H., & Frank, C.M. (1998). Second nonocular tumors in survivors of bilateral retinoblastoma: a possible age effect on radiation-related risk. *Ophthalmology*, Vol.105, No.4, (Apr 1998), pp. 573-579, ISSN 0161-6420
- Abramson, D.H., Melson, M.R., Dunkel, I.J., & Frank, C.M. (2001). Third (fourth and fifth) nonocular tumors in survivors of retinoblastoma. *Ophthalmology*, Vol.108, No.10, (Oct 2001), pp. 1868-1876, ISSN 0161-6420
- Abramson, D.H., Du, T.T., & Beaverson, K.L. (2002a). (Neonatal) retinoblastoma in the first month of life. *Arch Ophthalmol*, Vol.120, No.6, (Jun 2002), pp. 738-742, ISSN 0003-9950
- Abramson, D.H., Lee, T.C., & Driscoll, C. (2002b). Osteogenic sarcoma in a survivor of metastatic germline retinoblastoma: the possible influence of human growth hormone. *J Pediatr Ophthalmol Strabismus*, Vol.39, No.6, (Nov-Dec 2002), pp. 347-348, ISSN 0191-3913
- Abramson, D.H. (2005). Retinoblastoma in the 20th century: past success and future challenges the Weisenfeld lecture. *Invest Ophthalmol Vis Sci*, Vol.46, No.8, (Aug 2005), pp. 2683-2691, ISSN 0146-0404


- Acquaviva, A., Ciccolallo, L., Rondelli, R., et al. (2006). Mortality from second tumour among long-term survivors of retinoblastoma: a retrospective analysis of the Italian retinoblastoma registry. *Oncogene*, Vol.25, No.38, (Aug 2006), pp. 5350-5357, ISSN 0950-9232
- Aerts, I., Pacquement, H., Doz, F., et al. (2004). Outcome of second malignancies after retinoblastoma: a retrospective analysis of 25 patients treated at the Institut Curie. *Eur J Cancer*, Vol.40, No.10, (Jul 2004), pp. 1522-1529, ISSN 0959-8049
- Albert, D.M. (1987). Historic review of retinoblastoma. *Ophthalmology*, Vol.94, No.6, (Jun 1987), pp. 654-662, ISSN 0161-6420
- Antoneli, C.B., Ribeiro Kde, C., Sakamoto, L.H., et al. (2007). Trilateral retinoblastoma. *Pediatr Blood Cancer*, Vol.48, No.3, (Mar 2007), pp. 306-310, ISSN 1545-5009
- Araki, Y., Matsuyama, Y., Kobayashi, Y., et al. (2010). Secondary neoplasms after retinoblastoma treatment: retrospective cohort study of 754 patients in Japan. *Jpn J Clin Oncol*, Vol.41, No.3, (Mar 2011), pp.373-379, ISSN 0368-2811
- Bader, J.L., Miller, R.W., Meadows, A.T., et al. (1980). Trilateral retinoblastoma. *Lancet*, Vol.2, No.8194, (Sep 1980), pp. 582-583, ISSN 0140-6736
- Bell, J., Parker, K.L., Swinford, R.D., et al. (2009). Long-term safety of recombinant human growth hormone in children. *J Clin Endocrinol Metab*, Vol.95, No.1, (Jan 2010), pp. 167-177, ISSN 0021-972X
- Blach, L.E., McCormick, B., Abramson, D.H., & Ellsworth, R.M. (1994). Trilateral retinoblastoma--incidence and outcome: a decade of experience. *Int J Radiat Oncol Biol Phys*, Vol.29, No.4, (Jul 1994), pp. 729-733
- Brenner, D., Elliston, C., Hall, E., & Berdon, W. (2001). Estimated risks of radiation-induced fatal cancer from pediatric CT. *AJR Am J Roentgenol*, Vol.176, No.2, (Feb 2001), pp. 289-296, ISSN 0360-3016
- Broadus, E., Topham, A., & Singh, A.D. (2008). Incidence of retinoblastoma in the USA: 1975-2004. *Br J Ophthalmol*, Vol.93, No.1, (Jan 2009), pp. 21-23, ISSN 0007-1161
- Chan, M.P., Hungerford, J.L., Kingston, J.E., & Plowman, P.N. (2009). Salvage external beam radiotherapy after failed primary chemotherapy for bilateral retinoblastoma: rate of eye and vision preservation. *Br J Ophthalmol*, Vol.93, No.7, (Jul 2009), pp. 891-894, ISSN 0007-1161
- Chauveinc, L., Mosseri, V., Quintana, E., et al. (2001). Osteosarcoma following retinoblastoma: age at onset and latency period. *Ophthalmic Genet*, Vol.22, No.2, (Jun 2001), pp. 77-88, ISSN 1381-6810
- Dimaras, H., Khetan, V., Halliday, W., et al. (2008). Loss of RB1 induces non-proliferative retinoma: increasing genomic instability correlates with progression to retinoblastoma. *Hum Mol Genet*, Vol.17, No.10, (May 2008), pp. 1363-1372, ISSN 0964-6906
- Dimaras, H., Héon, E., Doyle, J., et al. (2011). Multifaceted chemotherapy for trilateral retinoblastoma. *Arch Ophthalmol*, Vol.129, No.3, (Mar 2011), pp. 362-365, ISSN 0003-9950
- Duncan, J.L., Scott, I.U., Murray, T.G., et al. (2001). Routine neuroimaging in retinoblastoma for the detection of intracranial tumors. *Arch Ophthalmol*, Vol.119, No.3, (Mar 2001), pp. 450-452, ISSN 0003-9950

- Dunkel, I.J., Jubran, R.F., Gururangan, S., et al. (2010). Trilateral retinoblastoma: potentially curable with intensive chemotherapy. *Pediatr Blood Cancer*, Vol.54, No.3, (Mar 2010), pp. 384-387, ISSN 1545-5009
- Eng, C., Li, F.P., Abramson, D.H., et al. (1993). Mortality from second tumors among long-term survivors of retinoblastoma. *J Natl Cancer Inst*, Vol.85, No.14, (Jul 1993), pp. 1121-1128, ISSN 0027-8874
- Ergun-Longmire, B., Mertens, A.C., Mitby, P., et al. (2006). Growth hormone treatment and risk of second neoplasms in the childhood cancer survivor. *J Clin Endocrinol Metab*, Vol.91, No.9, (Sep 2006), pp. 3494-3498, ISSN 0021-972X
- Fletcher, O., Easton, D., Anderson, K., et al. (2004). Lifetime risks of common cancers among retinoblastoma survivors. *J Natl Cancer Inst*, Vol.96, No.5, (Mar 2004), pp. 357-363, ISSN 0027-8874
- Foster, M.C., Kleinerman, R.A., Abramson, D., et al. (2006). Tobacco use in adult long-term survivors of retinoblastoma. *Cancer Epidemiol Biomarkers Prev*, Vol.15, No.8, (Aug 2006), pp. 1464-1468, ISSN 1055-9965
- Frobisher, C., Gurung, P.M., Leiper, A., et al. (2010). Risk of bladder tumours after childhood cancer: the British Childhood Cancer Survivor Study. *BJU Int*, Vol.106, No.7, (Oct 2010), pp. 1060-1069, ISSN 1464-4096
- Gallegos-Castorena, S., Medina-Sansón, A., González-Montalvo, P., et al. (2002). Letter to the editor: acute myeloid leukemia in a patient surviving retinoblastoma. *Med Pediatr Oncol*, Vol.38, No.6, (Jun 2002), pp. 450, ISSN 0098-1532
- Genuardi, M., Klutz, M., Devriendt, K., et al. (2001). Multiple lipomas linked to an RB1 gene mutation in a large pedigree with low penetrance retinoblastoma. *Eur J Hum Genet*, Vol.9, No.9, (Sep 2001), pp. 690-694, ISSN 1018-4813
- Gombos, D.S., Hungerford, J., Abramson, D.H., et al. (2007). Secondary acute myelogenous leukemia in patients with retinoblastoma: is chemotherapy a factor? *Ophthalmology*, Vol.114, No.7, (Jul 2007), pp. 1378-1383, ISSN 0161-6420
- Hijiya, N., Ness, K.K., Ribeiro, R.C., & Hudson, M.M. (2009). Acute leukemia as a secondary malignancy in children and adolescents: current findings and issues. *Cancer*, Vol.115, No.1, (Jan 2009), pp. 23-35, ISSN 0008-543X
- Hirao, Y., Kim, W.J., & Fujimoto, K. (2009). Environmental factors promoting bladder cancer. *Curr Opin Urol*, Vol.19, No.5, (Sep 2009), pp. 494-499, ISSN 0963-0643
- Jakobiec, F.A., Tso, M.O., Zimmerman, L.E., & Danis, P. (1977). Retinoblastoma and intracranial malignancy. *Cancer*, Vol.39, No.5, (May 1977), pp. 2048-2058, ISSN 0008-543X
- Jensen, R.D., & Miller, R.W. (1971). Retinoblastoma: epidemiologic characteristics. *N Engl J Med*, Vol.285, No.6, (Aug 1971), pp. 307-311, ISSN 0028-4793
- Jurkiewicz, E., Pakula-Kościesz, I., Rutynowska, O., & Nowak, K. (2009). Trilateral retinoblastoma: an institutional experience and review of the literature. *Childs Nerv Syst*, Vol.26, No.1, (Jan 2010), pp. 129-132, ISSN 1433-0350
- Kaatsch, P. (2010). Epidemiology of childhood cancer. *Cancer Treat Rev*, Vol.36, No.4, (Jun 2010), pp. 277-285, ISSN 0305-7372
- Klein, G., Michaelis, J., Spix, C., et al. (2003). Second malignant neoplasms after treatment of childhood cancer. *Eur J Cancer*, Vol.39, No.6, (Apr 2003), pp. 808-817, ISSN 0959-8049

- Kleinerman, R.A., Tucker, M.A., Tarone, R.E., et al. (2005). Risk of new cancers after radiotherapy in long-term survivors of retinoblastoma: an extended follow-up. *J Clin Oncol*, Vol.23, No.10, (Apr 2005), pp. 2272-2279, ISSN 0732-183X
- Kivelä, T. (1999). Trilateral retinoblastoma: a meta-analysis of hereditary retinoblastoma associated with primary ectopic intracranial retinoblastoma. *J Clin Oncol*, Vol.17, No.6, (Jun 1999), pp. 1829-1837, ISSN 0732-183X
- Kivelä, T. (2009). The epidemiological challenge of the most frequent eye cancer: retinoblastoma, an issue of birth and death. *Br J Ophthalmol*, Vol.93, No.9, (Sep 2009), pp. 1129-1131, ISSN 0007-1161
- Knudson, A.G. Jr. (1971). Mutation and cancer: statistical study of retinoblastoma. *Proc Natl Acad Sci U S A*, Vol.68, No.4, (Apr 1971), pp. 820-823, ISSN 0027-8424
- Korswagen, L.A., Moll, A.C., Imhof, S.M., & Schouten-van Meeteren, A.Y. (2004). A second primary tumor in a patient with retinoma. *Ophthalmic Genet*, Vol.25, No.1, (Mar 2004), pp. 45-48, ISSN 1381-6810
- Li, F.P., Abramson, D.H., Tarone, R.E., et al. (1997). Hereditary retinoblastoma, lipoma, and second primary cancers. *J Natl Cancer Inst*, Vol.89, No.1, (Jan 1997), pp. 83-84, ISSN 0027-8874
- Linabery, A.M., & Ross, J.A. (2008). Childhood and adolescent cancer survival in the US by race and ethnicity for the diagnostic period 1975-1999. *Cancer*, Vol.113, No.9, (Nov 2008), pp. 2575-2596, ISSN 0008-543X
- MacCarthy, A., Bayne, A.M., Draper, G.J., et al. (2009). Non-ocular tumours following retinoblastoma in Great Britain 1951 to 2004. *Br J Ophthalmol*, Vol.93, No.9, (2009), pp. 1159-1162, ISSN 0007-1161
- Marees, T., Moll, A.C., Imhof, S.M., et al. (2008). Risk of second malignancies in survivors of retinoblastoma: more than 40 years of follow-up. *J Natl Cancer Inst*, Vol.100, No.24, (Dec 2008), pp. 1771-1779, ISSN 0027-8874
- Marees, T., van Leeuwen, F.E., de Boer, M.R., et al. (2009). Cancer mortality in long-term survivors of retinoblastoma. *Eur J Cancer*, Vol.45, No.18, (Dec 2009), pp. 3245-3253, ISSN 0959-8049
- Marees, T., van Leeuwen, F.E., Schaapveld, M., et al. (2010). Risk of third malignancies and death after a second malignancy in retinoblastoma survivors. *Eur J Cancer*, Vol.46, No.11, (Jul 2010), pp. 2052-2058, ISSN 0959-8049
- Mills, D.M., Tsai, S., Meyer, D.R., & Belden, C. (2006). Pediatric ophthalmic computed tomographic scanning and associated cancer risk. *Am J Ophthalmol*, Vol.142, No.6, (Dec 2006), pp. 1046-1053, ISSN 0002-9394
- Moll, A.C., Imhof, S.M., Bouter, L.M., & Tan, K.E. (1997). Second primary tumors in patients with retinoblastoma. A review of the literature. *Ophthalmic Genet*, Vol.18, No.1, (Mar 1997), pp. 27-34
- Moll, A.C., Imhof, S.M., Schouten-Van Meeteren, A.Y., et al. (2001). Second primary tumors in hereditary retinoblastoma: a register-based study, 1945-1997: is there an age effect on radiation-related risk? *Ophthalmology*, Vol.108, No.6, (Jun 2001), pp. 1109-1114, ISSN 0161-6420
- Moll, A.C., Imhof, S.M., Schouten-Van Meeteren, A.Y., & Boers, M. (2002). Screening for pineoblastoma in patients with retinoblastoma. *Arch Ophthalmol*, Vol.120, No.12, (Dec 2002), pp. 1774, ISSN 0003-9950

- Munier, F.L., Verwey, J., Pica, A., et al. (2008). New developments in external beam radiotherapy for retinoblastoma: from lens to normal tissue-sparing techniques. *Clin Experiment Ophthalmol*, Vol.36, No.1, (Jan-Feb 2008), pp. 78-89, ISSN 1442-6404
- Nishimura, S., Sato, T., Ueda, H., & Ueda, K. (2001). Acute myeloblastic leukemia as a second malignancy in a patient with hereditary retinoblastoma. *J Clin Oncol*, Vol.19, No.21, (Nov 2001), pp. 4182-4183, ISSN 0732-183X
- Paulino, A.C. Trilateral retinoblastoma: is the location of the intracranial tumor important? *Cancer*, Vol.86, No.1, (Jul 1999), pp. 135-141, ISSN 0008-543X
- Pauwels, EK, Bourguignon, M. (2011). Cancer induction caused by radiation due to computed tomography: a critical note. *Acta Radiol*, (Jul 2011), [Epub ahead of print]
- Reese, A.B., Hyman, G.A., Merriam, G.R. Jr., et al. (1954). Treatment of retinoblastoma by radiation and triethylenemelamine. *AMA Arch Ophthalmol*, Vol.53, No.4, (Apr 1954), pp. 505-513
- Reulen, R.C., Winter, D.L., Frobisher, C., et al; British Childhood Cancer Survivor Study Steering Group. (2010). Long-term cause-specific mortality among survivors of childhood cancer. *JAMA*, Vol.304, No.2, (Jul 2010), pp. 172-179, ISSN 0098-7484
- Rieder, H., Lohmann, D., Poensgen, B., et al. (1998). Loss of heterozygosity of the retinoblastoma (RB1) gene in lipomas from a retinoblastoma patient. *J Natl Cancer Inst*, Vol.90, No.4, (Feb 1998), pp. 324-326, ISSN 0027-8874
- Rushlow, D., Piovesan, B., Zhang, K., et al. Detection of mosaic RB1 mutations in families with retinoblastoma. *Hum Mutat*, Vol.30, No.5, (May 2009), pp. 842-851, ISSN 1059-7794
- Sagerman, R.H., Cassady, J.R., Tretter, P., & Ellsworth, R.M. (1969). Radiation induced neoplasia following external beam therapy for children with retinoblastoma. *Am J Roentgenol Radium Ther Nucl Med*, Vol.105, No.3, (Mar 1969), pp. 529-535, ISSN 0002-9580
- Sampieri, K., Mencarelli, M.A., Epistolato, M.C., et al. (2008). Genomic differences between retinoma and retinoblastoma. *Acta Oncol*, Vol. 47, No. 8, (2008), pp. 1483-1492, ISSN 0284-186X
- Sanders, B.M., Jay, M., Draper, G.J., & Roberts, E.M. (1989). Non-ocular cancer in relatives of retinoblastoma patients. *Br J Cancer*, Vol.60, No.3, (Sep 1989), pp. 358-365, ISSN 0007-0920
- Schlienger, P., Campana, F., Vilcoq, J.R., et al. (2004). Nonocular second primary tumors after retinoblastoma: retrospective study of 111 patients treated by electron beam radiotherapy with or without TEM. *Am J Clin Oncol*, Vol.27, No.4, (Aug 2004), pp. 411-419, ISSN 0277-3732
- Sheen, V., Tucker, M.A., Abramson, D.H., et al. (2008). Cancer screening practices of adult survivors of retinoblastoma at risk of second cancers. *Cancer*, Vol.113, No.2, (Jul 2008), pp. 434-441, ISSN 0008-543X
- Shields, C.L., Meadows, A.T., Shields, J.A., et al. (2001). Chemoreduction for retinoblastoma may prevent intracranial neuroblastic malignancy (trilateral retinoblastoma). *Arch Ophthalmol*, Vol.119, No.9, (Sep 2001), pp. 1269-1272, ISSN 0003-9950
- Sklar, C.A., Mertens, A.C., Mitby, P., et al. (2002). Risk of disease recurrence and second neoplasms in survivors of childhood cancer treated with growth hormone: a report from the Childhood Cancer Survivor Study. *J Clin Endocrinol Metab*, Vol.87, No.7, (Jul 2002), pp. 3136-3141, ISSN 0021-972X

- Soh, S.Y., Dimaras, H., Gupta, A., et al. (2011). Adult ovarian retinoblastoma genomic profile distinct from prior childhood eye tumor. *Arch Ophthalmol*, Vol.129, No.8, (Aug 2011), pp. 1101-1104
- Strong, L.C., Herson, J., Haas, C., et al. (1984). Cancer mortality in relatives of retinoblastoma patients. *J Natl Cancer Inst*, Vol.73, No.2, (Aug 1984), pp. 303-311, ISBN 0027-8874
- Trappey, A., Fernando, A., Gaur, R., et al. (2010). The shady side of sunlight: current understanding of the mechanisms underlying UV-induction of skin cancers. *Front Biosci (Schol Ed)*, Vol.2, (Jan 2010), pp. 11-17
- Travis, L.B., Holowaty, E.J., Bergfeldt, K., et al. (1999). Risk of leukemia after platinum-based chemotherapy for ovarian cancer. *N Engl J Med*, Vol.340, No.5, (Feb 1999), pp. 351-357, ISSN 0028-4793
- Turaka, K, Shields, CL, Meadows, AT, Leahey, A. (2011). Second malignant neoplasms following chemoreduction with carboplatin, etoposide, and vincristine in 245 patients with intraocular retinoblastoma. *Pediatr Blood Cancer*, (Aug 2011), [Epub ahead of print]
- Vázquez, E., Castellote, A., Piqueras, J., et al. (2003). Second malignancies in pediatric patients: imaging findings and differential diagnosis. *Radiographics*, Vol.23, No.5, (Sep-Oct 2003), pp. 1155-1172, ISSN 0271-5333
- Weintraub, M., Revel-Vilk, S., Charit, M., et al. (2007). Secondary acute myeloid leukemia after etoposide therapy for retinoblastoma. *J Pediatr Hematol Oncol*, Vol.29, No.9, (Sep 2007), pp. 646-648, ISSN 1077-4114
- Wong, F.L., Boice, J.D. Jr., Abramson, D.H., et al. Cancer incidence after retinoblastoma. Radiation dose and sarcoma risk. *JAMA*, Vol. 278, No. 15, (Oct 1997), pp. 1262-1267, ISSN 0098-7484
- Woo, K.I., & Harbour, J.W. (2010). Review of 676 second primary tumors in patients with retinoblastoma: association between age at onset and tumor type. *Arch Ophthalmol*, Vol.128, No.7, (Jul 2010), pp. 865-870, ISSN 1538-3601
- Yu, C.L., Tucker, M.A., Abramson, D.H., et al. (2009). Cause-specific mortality in long-term survivors of retinoblastoma. *J Natl Cancer Inst*, Vol.101, No.8, (Apr 2009), pp. 581-591, ISSN 0027-8874
- Zimmerman, L.E. (1985). Retinoblastoma and retinocytoma. In: *Ophthalmic Pathology: An Atlas and Textbook*. W.H. Spencer, (Ed.), pp. 1292-1351, W.B. Saunders, ISBN 9780721685106, Philadelphia, Pennsylvania



**Retinoblastoma: An Update on Clinical, Genetic Counseling,
Epidemiology and Molecular Tumor Biology**

Edited by Prof. Govindasamy Kumaramanickavel

ISBN 978-953-51-0435-3

Hard cover, 170 pages

Publisher InTech

Published online 28, March, 2012

Published in print edition March, 2012

Retinoblastoma is the first tumor suppressor gene discovered ever. The discovery opened a new avenue in the field of oncology leading to the identification of 35 tumor suppressor genes, till date in our genome. This book is an excellent compilation of both clinical and basic science information that meets the needs of a young clinician and a researcher at the same time. It also has abundant information on recent advances and cutting-edge knowledge in intracellular molecular cross-talking of retinoblastoma protein with various cellular viral-like proteins.

How to reference

In order to correctly reference this scholarly work, feel free to copy and paste the following:

Basil K. Williams Jr. and Amy C. Scheffler (2012). Second Malignancies in Retinoblastoma: The Real Problem, Retinoblastoma: An Update on Clinical, Genetic Counseling, Epidemiology and Molecular Tumor Biology, Prof. Govindasamy Kumaramanickavel (Ed.), ISBN: 978-953-51-0435-3, InTech, Available from:
<http://www.intechopen.com/books/retinoblastoma-an-update-on-clinical-genetic-counseling-epidemiology-and-molecular-tumor-biology/second-malignancies-in-retinoblastoma-the-real-problem>

INTECH
open science | open minds

InTech Europe

University Campus STeP Ri
Slavka Krautzeka 83/A
51000 Rijeka, Croatia
Phone: +385 (51) 770 447
Fax: +385 (51) 686 166
www.intechopen.com

InTech China

Unit 405, Office Block, Hotel Equatorial Shanghai
No.65, Yan An Road (West), Shanghai, 200040, China
中国上海市延安西路65号上海国际贵都大饭店办公楼405单元
Phone: +86-21-62489820
Fax: +86-21-62489821

© 2012 The Author(s). Licensee IntechOpen. This is an open access article distributed under the terms of the [Creative Commons Attribution 3.0 License](https://creativecommons.org/licenses/by/3.0/), which permits unrestricted use, distribution, and reproduction in any medium, provided the original work is properly cited.

IntechOpen

IntechOpen