

We are IntechOpen, the world's leading publisher of Open Access books Built by scientists, for scientists

6,900

Open access books available

186,000

International authors and editors

200M

Downloads

Our authors are among the

154

Countries delivered to

TOP 1%

most cited scientists

12.2%

Contributors from top 500 universities



WEB OF SCIENCE™

Selection of our books indexed in the Book Citation Index
in Web of Science™ Core Collection (BKCI)

Interested in publishing with us?
Contact book.department@intechopen.com

Numbers displayed above are based on latest data collected.
For more information visit www.intechopen.com



Transplant-Associated Thrombotic Microangiopathy in Childhood

Fatih Erbey

Medicalpark Bahcelievler Hospital, Department of Pediatric Hematology/Oncology & Pediatric BMT Unit, Istanbul, Turkey

1. Introduction

Transplant-associated thrombotic microangiopathy (TMA) among early complications after hematopoietic stem cell transplantation (HSCT) in children was first described in 1980 (1). Incidence varies between centers with an average of 7.9% (0.5-63.6%) (2-4).

Vascular endothelium is damaged by toxic agents during the preparation regimen for stem cell transplantation. Microthrombi develop in small arterioles and capillaries and cause partial obstruction. Erythrocytes are subjected to mechanical trauma, and as a result, to hemolysis and fragmentation. Patients have clinical symptoms similar to thrombotic thrombocytopenic purpura (TTP) and Hemolytic Uremic Syndrome (HUS).

2. Pathology

TMA is a pathological definition and characterized by fibrinoid necrosis in vessel walls and arteriolar thrombus (5). Following intravascular thrombocyte activation due to microscopic damage, thrombus rich in thrombocytes develops in microcirculation. This process depletes thrombocytes. On the other hand, blood cells are mechanically damaged due to microcirculation obstructed by fibrin particles or microthrombus. The clinical picture is microangiopathic hemolytic anemia and thrombocytopenia.

3. Pathogenesis

TMA has the characteristics of TTP and HUS. It is seen not only in HSCT but also in all patients who had chemotherapy or radiotherapy, in systemic sclerosis, systemic lupus erythematosus, antiphospholipid syndrome, malign hypertension, preeclampsia-eclampsia, infections, cancers, renal transplantation and with drugs (5-8).

In primary TTP, there is a deficiency of metalloproteinases which adhere to the very large Von Willebrand factor (UL vWF) multimers in vivo and sweep them away from the endothelial cells (8-10). This protease is called as "ADAMTS13" and belongs to a disintegrin and metalloproteinase with thrombospondin type 1 repeats family (11-15). Severe ADAMTS13 deficiency (activity <5%) is seen in 33-100% of patients with primary TTP (16). Consequently, newly formed autoantibodies in primary TTP inhibit ADAMTS13 and thus

the unswept vWF multimers and thrombocytes aggregate causing a thrombocyte-rich-thrombus formation in microvascular bed. ADAMTS13 deficiency is found rarely in TMA associated with other causes excluding TTP (4).

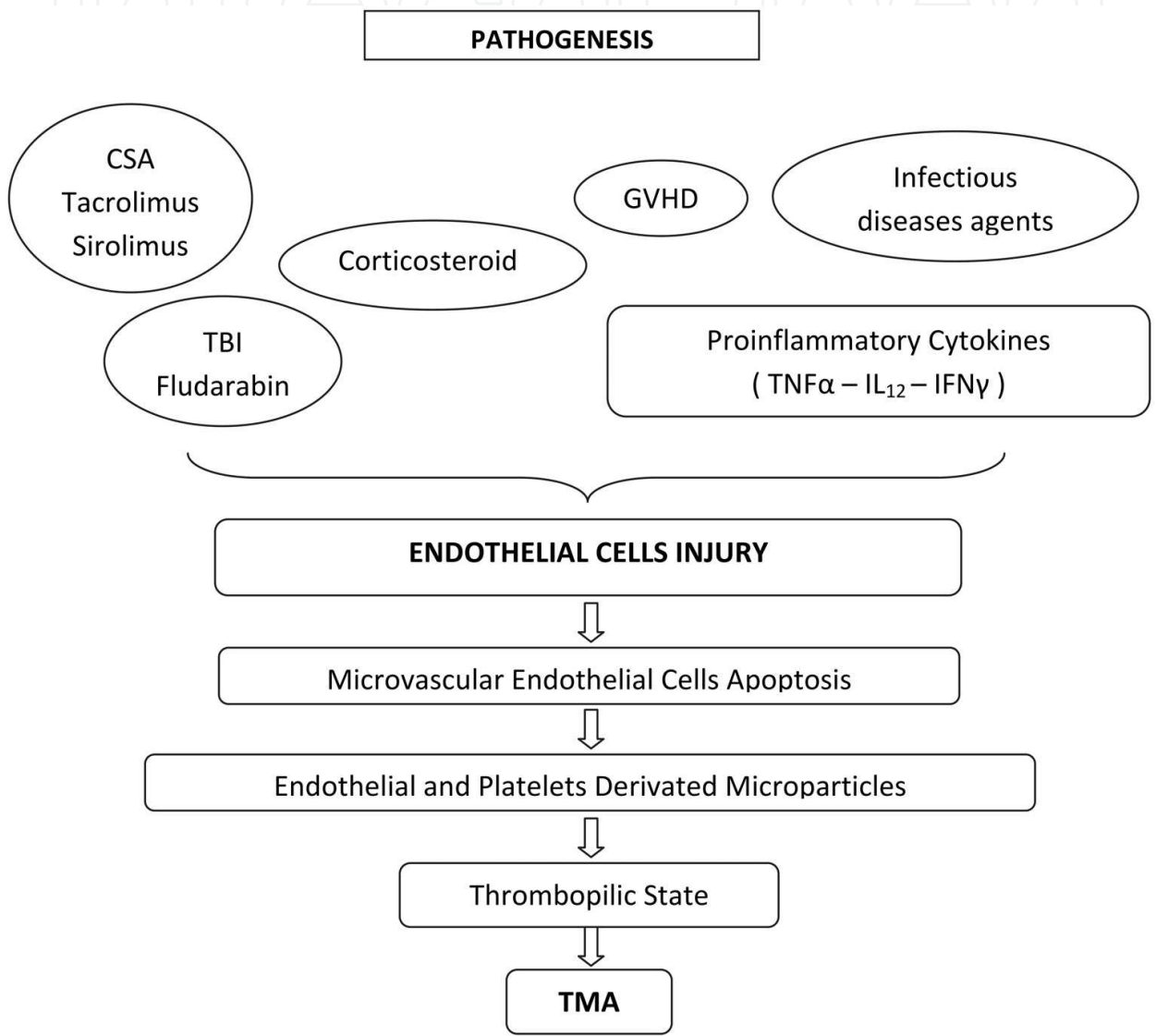
While the pathogenesis in transplant-associated TMA is not very clear, it is believed that the disease process starts with endothelial damage. In this case, the abnormalities in vascular endothelium are independent from ADAMTS13 deficiency. Laurence et al (17), showed that apoptosis in microvascular endothelial cells can be induced by plasma from patients with primer TTP and HUS in vitro (18). They also demonstrated enhanced apoptosis of microvascular endothelial cells in vivo in patient with TTP (19). These studies revealed induction of Fas (CD95) in endothelial cells after exposure to TTP plasma, which results in apoptosis of human cells (17-19). On the basis of their findings, they proposed that induction of endothelial cell injury was an important component of the pathogenesis of TMA. This form of injury has been shown to correlate with the generation of platelet microparticles in vitro and in patients with classical TTP (20). The mechanism of apoptosis appears to be linked to the rapid induction of Fas (CD95) on cultured microvascular endothelium and can be blocked in vitro by anti-Fas antibodies, normal cryo-poor plasma and low concentrations of the nonspecific protease and endonuclease inhibitor aurintricarboxylic acid. Inhibitors of caspases-1 and 3 and overexpression of Bcl-X_L in cultured microvascular endothelial cells suppress the induction of apoptosis in these cells by TTP plasma (21). Apoptosis of microvascular endothelial cells may represent a final common pathway of injury leading to the clinical expression of microangiopathic hemolytic anemia.

Endothelial damage causes the secretion of thrombocyte aggregating agent to the microvascular circulation. There is an increase in thrombomodulin, P-selectin (GMP-140) and tissue plasminogen activator levels (22). Causes of endothelial damage include cyclophosphamide, nitrosureas (busulfan), chemotherapeutics, such as platin based agents, radiotherapy, cyclosporine and tacrolimus for greft versus host disease (GVHD) prophylaxis, cytokines secreted in acute GVHD and infections (fungal, CMV, HHV-6) (Figure 1) (23,24).

The development of the scenario after 3-6 months following chemotherapy/ radiotherapy suggests that direct antibodies are formed against the endothelium and thrombocyte glycoprotein IV (CD 36) or other intracellular endothelial antigenic targets. IL-1, IL-6, soluble IL-2 receptor and TNF α plasma levels are increased in primary TTP. The histopathologic determinant for TTP/HUS is the presence of intravascular thrombocyte aggregating agents with abundant vWF content as seen in disseminated intravascular coagulation (DIC) [without soluble coagulation factor activation (eg. fibrin deposition)]. There's abnormal vWF profile in plasma of the patients with primary and transplant-associated disease. The affinity of vWF multimers to bind thrombocytes is high. Specifically, in arteriolar vessels where the flow is high, the aggregated thrombocytes form nidus onto which the ULvWF multimers cling. Cryoprecipitate with reduced plasma causes less thrombocyte aggregation activity by reducing the ULvWF. Due to this reductase activity, blood exchange using cryoprecipitate with reduced plasma is performed in severe TTP/HUS (23-25). In addition, thrombomodulin which is related to endothelial cell damage, plasminogen activator inhibitor-1 and soluble intercellular adhesion molecule increase in patients' serum (26-31). Increased levels of IL-1, IL-8, TNF α and IFN γ expand the inflammation mediated tissue damage via direct toxicity to

endothelium. This may lead to acute GVHD or hepatic veno-occlusive disease (VOD) (32-36). Some investigators even think that the transplant-associated TMA is an endothelial form of GVHD (37).

Cyclosporine when used in GVHD prophylaxis, increases the thromboxane A₂ production and decreases the prostaglandin I₂ production (38, 39). Cyclosporine and most probably tacrolimus show direct toxicity to endothelium (40-45) and addition of sirolimus to calcinorin inhibitors potentializes these toxic effects (46-48).



Endothelial cell injury and apoptosis have been associated with generation of endothelial microparticles that may be released in to the circulation. Release of endothelial microparticles has been associated with procoagulant activity. Furthermore, endothelial microparticles induce platelet aggregation, and thus by inducing microthrombosis could predispose to TMA.

Abbreviations: CSA; cyclosporin-A, GVHD; Graft-versus-host disease, TBI; Total body irradiation, TMA; thrombotic microangiopathy

Fig. 1. Pathogenesis of Transplantation associated thrombotic microangiopathy.

4. Risk factors for TMA

1. Female gender
2. Age: less frequent in children compared to adults.
3. Donor type: more frequent in unrelated donors and mismatch related donors.
4. Severity of the primary disease.
5. Nonmyeloablative transplant (Fludarabine based conditioning regimens)
6. High dose busulfan use (16 mg/kg)
7. Use of antithymocyte globulin or total body irradiation
8. Presence of 2nd or more degree acute GVHD
9. Cyclosporine, tacrolimus, sirolimus use
10. Neuroblastoma patients specifically with a history of cisplatin treatment
11. Presence of an infection, especially CMV. We reported that in a patient who developed TMA together with CMV infection, TMA signs resolved completely after successful treatment of CMV infection (49).
12. Stem cell source; Elliott et al. (12) reported that 4 of the 25 (16 %) bone marrow transplantations from a HLA full matched sibling resulted in TMA, however, none of the 45 peripheral stem cell transplantations from a HLA full matched sibling resulted in TMA. They defined the use of bone marrow as a stem cell source as a risk factor. They also stated that prospective, large and comparative studies were needed in order to understand the relationship between TMA and the stem cell source. As opposed to their results, 3 of the 18 patients (16.6. %) in our study who used peripheral blood for the source of stem cells developed TMA while none of the 32 patients who used the bone marrow developed it. We concluded that the use of the peripheral stem cell was a risk factor for TMA (50). Like Elliott et al., we also think that prospective, large and comparative studies are needed in order to understand the relationship between TMA and the stem cell source.

5. Clinical signs

Signs develop in an average of 44-171 days after the transplantation. In 2/3 of the cases, the disease occurs before 100 days (51). Erythrocytes are fragmented by microangiopathic damage and erythrocyte turnover increases without immune mediated hemolysis or DIC. Peripheral smear shows fragmented erythrocytes (schistocytes). Mild hemolysis, severe anemia, thrombocytopenia, fever, hematuria, mental disability, and kidney failure requiring dialysis may be present in patients. Biochemically, serum lactate dehydrogenase (LDH) is increased, haptoglobin level is decreased. In addition, indirect hyperbilirubinemia and hemoglobinuria may be seen.

Fragmented erythrocyte ratio is 4-10% in transplant-associated TMA. Nucleated erythrocytes may be found in peripheral circulation. Thrombocyte consumption is increased although DIC is not present. Plasma vWF level is high albeit not pathognomonic. Studies demonstrate that vWF level increases more in allogeneic stem cell recipients compared to autologous recipients. The highest levels of vWF are seen in 3-4 months after the transplantation when TMA is also clinically presented.

6. Diagnostic criteria for transplant-associated TMA

In a study by George et al (2), a total of 28 parameters were detected to be used for diagnosis in various centers. It is also observed that such a wide range of diagnostic criteria use caused

variability in incidence ranging from 0.5-63.6%. As a result, an international research group was organized and a consensus on diagnostic criteria was reached. According to this consensus, the following diagnostic criteria were determined (3).

1. Presence of schistocytes
2. Presence of prolonged or progressive thrombocytopenia ($<50 \times 10^9/l$) or 50% or more decrease in the previous thrombocyte count)
3. Sudden and persistent LDH increase
4. Decrease in hemoglobin concentration or increase in transfusion needs
5. Decrease in serum haptoglobin level

Each criteria needs to be fulfilled for diagnosis. Sensitivity and specificity are 80% (3).

7. Differential diagnosis

7.1 Cyclosporine toxicity

Isolated microangiopathy: 1-2% erythrocyte fragmentation is seen in most patients treated with cyclosporine or tacrolimus after transplantation. At toxic serum levels of these drugs, fragmented erythrocytes increase to 3-4%, indirect bilirubin is increased and reticulocytosis is observed. When cyclosporine dose is decreased and the serum drug levels turn to therapeutic levels, hemolysis and renal effects return to normal. Vitamin E may treat hemolysis after transplantation.

Cyclosporine associated central nervous system dysfunction: This picture is frequently mistaken as TMA in the first 6 months after transplantation. Seizures, alterations in consciousness, apraxia/ataxia or cortical blindness may be seen in patients. These symptoms are usually related with uncontrolled hypertension, renal tubular acidosis and magnesium loss. Symptoms resolve within 48-72 hours with the reduction of cyclosporine dose. In treatment, cyclosporine should be stopped temporarily, another drug should be used for GVHD prophylaxis, hypertension should be controlled, magnesium should be replaced and if necessary an antiepileptic drugs should be used. If cyclosporine is restarted in patients with cortical blindness, speech disturbance or coma, symptoms may reappear. In some patients cyclosporine may be replaced by tacrolimus uneventfully. Behavioural disturbances, alterations in consciousness level and seizures are observed both in cyclosporine toxicity and TMA. Cortical blindness and apraxia/ataxia are more frequently associated with cyclosporine toxicity and are reversible (23).

7.2 Immune hemolytic anemia

Immune hemolytic anemia may develop after transplantation, especially in patients who had received multiple transfusions prior to HSCT (eg patients with hemoglobinopathies). There is increased need for erythrocyte supplementation in these patients. Fragmented erythrocytes are detected in peripheral smear, reticulocyte count, LDH and indirect bilirubin levels are increased, haptoglobin is decreased. While direct antiglobulin (direct coombs) test is positive in these patients, it is negative in transplant-associated TMA.

7.3 Disseminated intravascular coagulation

Hemostatic system is a dynamic system that under normal conditions is balanced by thrombus formation via the conversion of prothrombin to thrombin and thrombus

degradation via elimination of thrombin with antithrombin before it promotes coagulation. Disturbance of this balance by any reason leads to aggregation of fibrin and thrombin and thus, to this clinical condition secondary to the activation of fibrinolysis which may result in death. Fibrin is widely accumulated (microthrombus) in small vessels of various organs due to thrombin effect. Fibrin accumulation leads to consumption of mainly thrombocytes and fibrinogen, several coagulation factors (II, V, VIII) and erythrocytes. Accumulated fibrin in vessels is lysed when the fibrinolytic system is activated and fibrin degradation products (FDP) pass to the circulation (secondary fibrinolysis). Fibrin aggregates in small vessels may cause ischemic tissue necrosis (bilateral renal necrosis, surrenal necrosis) and in some instances where fibrin ligaments have accumulated to completely obstruct the vessel lumen, microangiopathic hemolytic anemia may develop.

Clinical presentation may vary from being asymptomatic to shock. Bleeding occurs as a result of coagulation factors and platelet depletion. It may be observed as petechiae and echymosis, oozing from injection sites and gums, subcutaneous hematomas, nasal bleeding, hematuria, gastrointestinal and intracranial hemorrhage.

Ischemic organ damage due to intravascular thrombosis may be seen. Furthermore, in chronic DIC, due to fibrin deposition in glomerules, renal insufficiency characterized by oliguria frequently accompanies the case.

Thrombi and fibrin materials formed as a result of the damage that erythrocytes have incurred during their flow through the vessels, block the vessel lumen. This condition causes microangiopathic hemolytic anemia.

In the diagnosis of DIC; fibrinogen level is low, prothrombin time is prolonged, activated partial thromboplastin time is prolonged, factor II, V, VIII and XIII levels are low and thrombocytopenia is present. Final diagnosis is made by the demonstration of fibrinogen-fibrin degradation products in serum using immunoassay. FDP has high levels and fibrin monomer polymerization is prolonged. The D-dimer test is specific for fibrin proteolysis. Fibrin complexes are high in circulation. If the fibrinogen is lower than 1 g/L, thrombin time is prolonged, however if fibrinogen level is higher than 1 g/L and thrombin time is prolonged, this means the FDP is increased.

When microangiopathic hemolytic anemia develops, fragmented erythrocytes are found in peripheral blood smear. Reticulocyte count is increased secondary to hemolysis. Thrombocytopenia and absence of thrombocyte aggregates in peripheral smear may be seen as a result of platelet consumption in microvascular thrombosis and platelet activation of circulating thrombin. Antithrombin III is decreased, euglobulin lysis time is shortened. Search for fibrin monomer formation and fibrinopeptide measurements are more complicated tests however used rarely for confirmation of diagnosis.

8. Treatment

Currently there is no any consensus on the therapy of TMA. However, there is no any randomized trials regarding to treatment. Once transplant-associated TMA is suspected, the potentially blamed drugs such as cyclosporine, tacrolimus or sirolimus should be seized. Necessary immunosuppression should be provided by corticosteroid, mycophenolate and azathiopurine. In a patient using cyclosporine, the drug may be replaced by tacrolimus but this usually does not help (52).

8.1 Plasma exchange

Despite limited data, many centers use plasma exchange as part of the treatment in transplant-associated TMA. Plasma exchange using cryoprecipitate with reduced plasma or fresh frozen plasma may be used alone or in combination with staphylococcal protein immunoabsorption. Its efficiency is controversial. Response rate to plasma exchange, when compared with primary TTP (75%), is significantly less in transplant-associated TMA (<50%) (32, 53). Furthermore, the mortality in transplant-associated TMA is greater than 80% when plasma exchange used whereas it is 20% in idiopathic TTP (16, 32, 53-55). Limited response to plasma exchange and high mortality rate despite plasma exchange are associated with ADAMTS13 levels. In primary TTP, ADAMTS13 activity is inhibited by autoantibodies is restored by plasma exchange, thus the underlying disease mechanism is reversed and clinical outcome is positive. However, in transplant-associated TMA, since the case is independent from ADAMTS13 activity the response rates are low in spite of plasma exchange. On the other hand, 28% of patients treated with plasma exchange had complications such as infections due to plasmapheresis catheter or transfused plasma, thrombosis, hemorrhage, pneumothorax, pericardial tamponade, hypoxia, hypotension, serum sickness, and anaphylaxis (56-58).

Based on the absence of convincing data in published series and high complication rates, some researchers emphasize not to use plasma exchange routinely for transplant-associated TMA until new clinical study results are available or at least to rule out other factors that could cause TMA (eg. infections, GVHD) before use (54, 59).

8.2 Defibrotide

Recently, the most pronounced agent is defibrotide, a polideoxyribonucleotide salt. Defibrotide has antithrombotic and thrombolytic activity and inhibits the TNF α mediated endothelial cell apoptosis in-vitro (60). Defibrotide's main effect is local on vascular bed. It does not have a significant effect on systemic coagulation. Defibrotide has protective effects on damaged or activated endothelial cells especially in small vessels. Defibrotide once bound to vascular endothelial cells decreases their procoagulant activity and increases their fibrinolytic potentials. The drug also has anti-inflammatory and anti-ischemic effects (35, 61). The effectivity of defibrotide has been shown in hepatic VOD treatment (35-36). In a study by Corti et al, 12 TMA patients were reported to be treated with defibrotide, 6 patients had complete remission, 3 had partial remission (61). In conclusion, considering the similarity between VOD and transplant-associated TMA and that the endothelial damage is held mainly responsible for pathogenesis, large scale randomized studies with defibrotide are required.

8.3 Other therapeutic approaches

Literature reveals a few other treatment approaches with different outcomes (Table 1). Wollf et al, described complete remission in 9 out of 13 patients with TMA and GVHD whose treatments for GVHD by calcinorin inhibitors were stopped and replaced with anti-CD25 antibody (daclizumab). Five of those patients with complete remission for TMA also had complete remission for GVHD. While 4 patients were still alive 266 days after the transplantation, 1 died due to relapse of the primary disease and the rest 8 died due to infections, GVHD or multiorgan dysfunction (62).

Au et al, treated 5 patients refractory to plasma exchange and high dose corticosteroid therapy with a total of 4 doses of rituximab once a week. Four patients had complete remission, one of which later died due to sepsis. The patient without remission died 3 weeks later due to multiorgan failure (63). The mechanism of action for rituximab in transplant-associated TMA is not clear, nevertheless, is thought to be related with the immunomodulator effectivity of the drug.

Takatsuka et al, used eicosapentanoic acid (EPA) to decrease the inflammation related complication such as TMA in peritransplantation period. Sixteen patients were enrolled in this study. EPA was started 3 weeks prior to the transplantation in 7 patients who have undergone allogeneic transplantation from unrelated donors and continued up to 180 days after the procedure. EPA was not given to the other 9 patients. All patients had similar preparation regimes and GVHD prophylaxis. Four patients developed TMA and 5 patients died in the group not receiving EPA. In the group receiving EPA, non developed TMA and all survived until 143 days after the transplantation (64).

Kajume et al used transdermal isosorbide successfully in a case and have not reported any side effects (65).

8.4 Future approaches

TNF α inhibitors such as etanercept and infliximab are demonstrated to be effective in acute GVHD treatment. Theoretically they are thought to be effective in transplant-associated TMA as well (66-71). However, TNF α inhibitors' potentially increasing the risk of opportunistic infections such as fungal and viral infections limits their use (67-70).

Statins decrease the endothelial inflammatory response and myocardial ischemia (72-75). Iloprost is a prostacycline analogue decreasing the endothelial cell damage and the markers increasing during its activation (76). Endothelin receptor antagonists reverse the microvascular damage induced by cyclosporine in vitro (77), shows protective effect against endothelial damage due to ischemia/reperfusion in vivo (78). Edaravone is a free radical scavenger inhibiting the vascular endothelial cell damage in patients with myocardial ischemia and cerebrovascular trauma. In animal models, it decreases the thrombogenesis associated with damaged endothelium via increasing the nitric oxide synthesis (79). Also in animal models, edaravone was found to decrease cisplatin induced renal toxicity (80). Currently edaravone is approved for ischemic stroke treatment only. Table 2 shows agents that have not been used for transplant-associated TMA but have a certain potential to be used.

9. Prognosis

Being a feared complication of HSCT, transplant-associated TMA has bad prognosis. Literature search yields a mortality rate of more than 60% (2). High mortality rate is multifactorial; related not only with TMA associated kidney failure, myocardial dysfunction and brain ischemia but also with other confounding severe complications of transplantation (eg. infections, GVHD). In several series, prognostic factors were evaluated and bad prognostic criteria were listed below (37, 46, 81, 82).

1. Age equal to or greater than 18.
2. Unrelated or haploidentical donor
3. Increased TMA index (LDH/platelet ratio)
4. Schistocyte count > 5-10 hpf
5. Patients not exposed to sirolimus
6. Presence of nephropathy

Additionally, some authors think that delays in diagnosis and/or treatment are also associated with high mortality.

In conclusion, TMA is a severe complication yet to be investigated thoroughly since the pathogenesis is not clear, there is no consensus on treatment and morbidity-mortality rates are high.

10. References

- [1] Powles RL, Clink HM, Spence D, Morgenstern G, Watson JG, Selby HJ, et al. Cyclosporine A to prevent graft-versus-host disease in man after allogeneic bone marrow transplantation. *Lancet* 1980;1:327-9.
- [2] George JN, Li X, McMinn JR, Terrell DR, Vesely SK, Selby GB. Thrombotic thrombocytopenic purpura - hemolytic uremic syndrome following allogeneic HPC transplantation: a diagnostic dilemma. *Transfusion* 2004;44:294-304.
- [3] Ruutu T, Barosi G, Benjamin RJ, Clark RE, George JN, Grathwohl A, et al. Diagnostic criteria for hematopoietic stem cell transplant-associated microangiopathy: results of a consensus process by an International Working Group. *Haematologica* 2007;92:95-100.
- [4] Batts ED, Lazarus HM. Diagnosis and treatment of transplantation-associated thrombotic microangiopathy: real progress or are we waiting? *Bone Marrow Transplant* 2007;40:709-19.
- [5] Laszik Z, Silva F. Hemolytic-uremic syndrome, thrombotic thrombocytopenic purpura, and systemic sclerosis (systemic scleroderma). In: Jennet JC, Olson JL, Schwartz MM, Silva FG (eds). *Heptinstall's Pathology of the Kidney*. Lippincott-Raven: Philadelphia, 1998, 1003-57.
- [6] Sadler JE, Poncz M. Antibody-mediated thrombotic disorders: idiopathic thrombotic thrombocytopenic purpura and heparin-induced thrombocytopenia. In: Lichtman MA, Beutler E, Kipps TJ, Seligsohn U, Kaushansky K, Prchal J (eds). *Williams Hematology*. McGraw-Hill: New York, 2006, 2031-54.
- [7] Arslan Ş. Hemolitik üremik sendromlar. *T Klin Pediatri Özel* 2004; 2:104-11.
- [8] Çelik A. Trombotik trombositopenik purpura ve Hemolitik üremik sendrom. *T Klinikleri J Int Med Sci* 2007; 3(4):30-35.
- [9] Furlan M, Robles R, Solenthaler M, Wassmer M, Sandoz P, Lammle B. Deficient activity of von Willebrand factor-cleaving protease in chronic relapsing thrombotic thrombocytopenic purpura. *Blood* 1997;89:3097-103.
- [10] Furlan M, Robles R, Galbusera M, Remuzzi G, Kyrle PA, Brenner B, et al. Von Willebrand factor-cleaving protease in thrombotic thrombocytopenic purpura and the hemolytic-uremic syndrome. *New Engl J Med* 1998;339:1578-84.
- [11] Gerritsen HE, Robles R, Lammle B, Furlan M. Partial amino acid sequence of purified von Willebrand factor-cleaving protease. *Blood* 2001;98:1654-61.


- [12] Fujikawa K, Suzuki H, McMullen B, Chung D. Purification of human von Willebrand factor-cleaving protease and its identification as a new member of the metalloproteinase family. *Blood* 2001;98:1662–66.
- [13] Levy GG, Nichols WC, Lian EC, Foroud T, McClintock JN, McGee BM, et al. Mutations in a member of the ADAMTS gene family cause thrombotic thrombocytopenic purpura. *Nature* 2001;413:488–94.
- [14] Soejima K, Mimura N, Hirashima M, Maeda H, Hamamoto T, Nakagaki T, et al. A novel human metalloprotease synthesized in the liver and secreted into the blood: possibly, the von Willebrand factor-cleaving protease? *J Biochem (Tokyo)* 2001;130:475–80.
- [15] Zheng X, Chung D, Takayama TK, Majerus EM, Sadler JE, Fujikawa K. Structure of von Willebrand factor-cleaving protease (ADAMTS13), a metalloprotease involved in thrombotic thrombocytopenic purpura. *J Biol Chem* 2001;276:41059–63.
- [16] Sadler JE. Thrombotic thrombocytopenic purpura: a moving target. *Hematology (Am Soc Hematol Educ Program)* 2006, 415–20.
- [17] Laurence J, Mitra D, Steiner M, Staiano-Coico L, Jaffe E. Plasma from patients with idiopathic and human immunodeficiency virus-associated thrombotic thrombocytopenic purpura induces apoptosis in microvascular endothelial. *Blood* 1996;87:3245–54.
- [18] Mitra D, Jaffe E, Weksler B, Hajjar KA, Soderland C, Laurence J. Thrombotic thrombocytopenic purpura and sporadic hemolytic-uremic syndrome plasmas induced apoptosis in restricted lineages of human microvascular endothelial cells. *Blood* 1997;89:1224–34.
- [19] Dang CT, Magid M, Weksler B, Chadburn A, Laurence J. Enhanced endothelial apoptosis in splenic tissue of patients with thrombotic thrombocytopenic purpura. *Blood* 1999;93:1264–70.
- [20] Jimenez JJ, Jy W, Mauro L, Horstman LL, Ahn YS. Elevated endothelial microparticles in thrombotic thrombocytopenic purpura: findings from brain and renal microvascular cell culture and patients with active disease. *Br J Haematol* 2001;112:81–90.
- [21] Mitra D, Kim J, MacLow C, Karsan A, Laurence J. Role of caspases 1 and 3 and Bcl-2-related molecules in endothelial cell apoptosis associated with thrombotic microangiopathies. *Am J Hematol* 1998;59:279–87.
- [22] Valilis PN, Zeigler ZR, Shadduck RK. A prospective study of bone marrow transplant-associated thrombotic microangiopathy (BMT-TM) in autologous (Auto) and allogeneic (Allo) BMT. *Blood* 1995;86:970a (abstract).
- [23] Sniecinski IJ, O'Donnel MR. Hemolytic complications of hematopoietic cell transplantation. In: Thomas ED, Blume KG, Forman SJ (eds). *Hematopoietic cell transplantation* 2nd ed. Blackwell Science, USA, 1999, 674–84.
- [24] Juckett M, Perry EH, Daniels BS, Weisdorf DJ. Hemolytic uremic syndrome following bone marrow transplantation. *Bone Marrow Transplant.* 1991;7:405–9.
- [25] Moake JL. Studies in the pathophysiology of thrombotic thrombocytopenic purpura. *Semin Hematol.* 1997;34:83–9.
- [26] Testa S, Manna A, Porcellini A, Maffi F, Morstabilini G, Denti N, et al. Increased plasma level of vascular endothelial glycoprotein thrombomodulin as an early indicator of

- endothelial damage in bone marrow transplantation. *Bone Marrow Transplant* 1996;18:383–8.
- [27] Richard S, Seigneur M, Blann A, Adams R, Renard M, Puntous M, et al. Vascular endothelial lesion in patients undergoing bone marrow transplantation. *Bone Marrow Transplant* 1996;18:955–9.
- [28] Salat C, Holler E, Kolb HJ, Pihusch R, Reinhardt B, Hiller E. Endothelial cell markers in bone marrow transplant recipients with and without acute graft versus host disease. *Bone Marrow Transplant* 1997;19:909–14.
- [29] Nurnberger W, Michelmann I, Burdach S, Gobel U. Endothelial dysfunction after bone marrow transplantation: increase of soluble thrombomodulin and PAI-1 in patients with multiple transplant-related complications. *Ann Hematol* 1998;76:61–5.
- [30] Kanamori H, Maruta A, Sasaki S, Yamazaki E, Ueda S, Katoh K, et al. Diagnostic value of hemostatic parameters in bone marrow transplant-associated thrombotic microangiopathy. *Bone Marrow Transplant* 1998;21:705–9.
- [31] Takatsuka H, Wakae T, Mori A, Okada M, Fujimori Y, Takemoto Y, et al. Endothelial damage caused by cytomegalovirus and human herpesvirus-6. *Bone Marrow Transplant* 2003;31:475–9.
- [32] Daly AS, Xenocostas A, Lipton JH. Transplantation associated thrombotic microangiopathy: twenty-two years later. *Bone Marrow Transplant* 2002;30:709–15.
- [33] Takatsuka H, Wakae T, Mori A, Okada M, Suehiro A, Okamoto T, et al. Thrombotic thrombocytopenic purpura and hemolytic uremic syndrome following allogeneic bone marrow transplantation. *Bone Marrow Transplant* 2002;29:907–11.
- [34] Qu L, Kiss JE. Thrombotic microangiopathy in transplantation and malignancy. *Semin Thromb Hemost* 2005;31:691–9.
- [35] Richardson PG, Murakami C, Jin Z, Warren D, Momtaz P, Hoppensteadt D, et al. Multi-institutional use of defibrotide in 88 patients after stem cell transplantation with severe venoocclusive disease and multisystem organ failure: response without significant toxicity in a high-risk population and factors predictive of outcome. *Blood* 2002;100:4337–43.
- [36] Corbacioglu S, Greil J, Peters C, Wulffraat N, Laes HJ, Dilloo D, et al. Defibrotide in the treatment of children with veno-occlusive disease (VOD): a retrospective multicentre study demonstrates therapeutic efficacy upon early intervention. *Bone Marrow Transplant* 2004;33:189–95.
- [37] Martinez MT, Bucher CH, Stussi G, Heim D, Buser A, Tsakiris DA, et al. Transplant-associated microangiopathy (TAM) in recipients of allogeneic hematopoietic stem cell transplants. *Bone Marrow Transplant* 2005;36:993–1000.
- [38] Rosenthal RA, Chukwuogo NA, Ocasio VH, Kahng KU. Cyclosporine inhibits endothelial cell prostacyclin production. *J Surg Res* 1989;46:593–6.
- [39] Voss BL, Hamilton KK, Samara EN, McKee PA. Cyclosporine suppression of endothelial prostacyclin generation: a possible mechanism for nephrotoxicity. *Transplantation* 1988;45:793–6.
- [40] Lau DC, Wong KL, Hwang WS. Cyclosporine toxicity on cultured rat microvascular endothelial cells. *Kidney Int* 1989;35:604–13.
- [41] Benigni A, Morigi M, Perico N, Zoja C, Amuchastegui CS, Piccinelli A, et al. The acute effect of FK506 and cyclosporine on endothelial cell function and renal vascular resistance. *Transplantation* 1992;54:775–80.

- [42] Nitta K, Uchida K, Tsutsui T, Horita S, Hayashi T, Ozu H, et al. Cyclosporin A induces glomerular endothelial cell injury in vitro. *Acta Pathol Jpn* 1993;43:367-71.
- [43] Azizian M, Ramenaden ER, Shah G, Wilasrusmee C, Bruch D, Kittur DS. Augmentation of ischemia/reperfusion injury to endothelial cells by cyclosporine A. *Am Surg* 2004;70:438-42.
- [44] Nacar A, Kiyici H, Ogun E, Zagyapan R, Demirhan B, Ozdemir H, et al. Ultrastructural examination of glomerular and tubular changes in renal allografts with cyclosporine toxicity. *Ren Fail* 2006;28:543-7.
- [45] Burke GW, Ciancio G, Cirocco R, Markou M, Olson L, Contreras N, et al. Microangiopathy in kidney and simultaneous pancreas/kidney recipients treated with tacrolimus: evidence of endothelin and cytokine involvement. *Transplantation* 1999;68:1336-42.
- [46] Cutler C, Henry NL, Magee C, Li S, Kim HT, Alyea E, et al. Sirolimus and thrombotic microangiopathy after allogeneic hematopoietic stem cell transplantation. *Biol Blood Marrow Transplant* 2005;11:551-7.
- [47] Couriel DR, Saliba R, Escalon MP, Hsu Y, Ghosh S, Ippoliti C, et al. Sirolimus in combination with tacrolimus and corticosteroids for the treatment of resistant chronic graft-versus-host disease. *Br J Haematol* 2005;130:409-17.
- [48] Fortin MC, Raymond MA, Madore F, Fugere JA, Paquet M, St-Louis G, et al. Increased risk of thrombotic microangiopathy in patients receiving a cyclosporine-sirolimus combination. *Am J Transplant* 2004;4:946-52.
- [49] Erbey F, Bayram I, Yilmaz S, Tanyeli A. The overview of diagnostic criteria and treatment options of transplantation associated thrombotic microangiopathy with two case reports. *Int J Hematol Oncol* 2010;20(2):110-114.
- [50] Erbey F, Bayram I, Kuskonmaz B, Yilmaz S, Cetin M, Uckan D, Tanyeli A. Thrombotic microangiopathy in allogeneic stem cell transplantation in childhood. *Exp Clin Transplant* 2010;8(3):237-244.
- [51] Pettitt AR, Clark RE. Thrombotic microangiopathy following bone marrow transplantation. *Bone Marrow Transplant* 1994;14:495-504.
- [52] Furlong T, Storb R, Anasetti C, Appelbaum FR, Deeg HJ, Doney K, et al. Clinical outcome after conversion to FK 506 (tacrolimus) therapy for acute graft-versus-host disease resistant to cyclosporine or for cyclosporine-associated toxicities. *Bone Marrow Transplant* 2000;26:985-91.
- [53] Rock G, Shumak KH, Sutton DM, Busckard NA, Nair RC. Cryosupernatant as replacement fluid for plasma exchange in thrombotic thrombocytopenic purpura. Members of the Canadian Apheresis Group. *Br J Haematol* 1996;94:383-6.
- [54] Ho VT, Cutler C, Carter S, Martin P, Adams R, Horowitz M, et al. Blood and marrow transplant clinical trials network toxicity committee consensus summary: thrombotic microangiopathy after hematopoietic stem cell transplantation. *Biol Blood Marrow Transplant* 2005;11:571-5.
- [55] Elliott MA, Nichols WL, Plumhoff EA, Ansell SM, Dispenzieri A, Gastineau DA, et al. Posttransplantation thrombotic thrombocytopenic purpura: a single-center experience and a contemporary review. *Mayo Clin Proc* 2003;78:421-30.
- [56] Rizvi MA, Vesely SK, George JN, Chandler L, Duvall D, Smith JW, et al. Complications of plasma exchange in 71 consecutive patients treated for clinically suspected

- thrombotic thrombocytopenic purpura-hemolytic-uremic syndrome. *Transfusion* 2000;40:896–901.
- [57] McMinn JR, Thomas IA, Terrell DR, Duvall D, Vesely SK, George JN. Complications of plasma exchange in thrombotic thrombocytopenic purpura-hemolytic uremic syndrome: a study of 78 additional patients. *Transfusion* 2003;43:415–6.
- [58] Howard MA, Williams LA, Terrell DR, Duvall D, Vesely SK, George JN. Complications of plasma exchange in patients treated for clinically suspected thrombotic thrombocytopenic purpura-hemolytic uremic syndrome. *Transfusion* 2006;46:154–6.
- [59] George JN, Selby GB. Thrombotic microangiopathy after allogeneic bone marrow transplantation: a pathologic abnormality associated with diverse clinical syndromes. *Bone Marrow Transplant* 2004;33:1073–4.
- [60] Schroder H. Defibrotide protects endothelial cells, but not L929 tumour cells, from tumour necrosis factor- α -mediated cytotoxicity. *J Pharm Pharmacol* 1995;47:250–2.
- [61] Corti P, Uderzo C, Tagliabue A, Della Volpe A, Annaloro C, Tagliaferri E, et al. Defibrotide as a promising treatment for thrombotic thrombocytopenic purpura in patients undergoing bone marrow transplantation. *Bone Marrow Transplant* 2002;29:542–3.
- [62] Wolff D, Wilhelm S, Hahn J, Gentilini C, Hilgendorf I, Steiner B, et al. Replacement of calcineurin inhibitors with daclizumab in patients with transplantation-associated microangiopathy or renal insufficiency associated with graft-versus-host disease. *Bone Marrow Transplant* 2006;38:445–51.
- [63] Au WY, Ma ES, Lee TL, Ha SY, Fung AT, Lie AK, et al. Successful treatment of thrombotic microangiopathy after haematopoietic stem cell transplantation with rituximab. *Br J Haematol* 2007;137:475–8.
- [64] Takatsuka H, Takemoto Y, Iwata N, Suehiro A, Hamano T, Okamoto T, et al. Oral eicosapentaenoic acid for complications of bone marrow transplantation. *Bone Marrow Transplant* 2001;28:769–74.
- [65] Kajiume T, Nagita A, Yoshimi S, Kobayashi K, Kataoka N. A case of hemolytic-uremic syndrome improved with nitric oxide. *Bone Marrow Transplant* 2000;25:109–10.
- [66] Kobbe G, Schneider P, Rohr U, Fenk R, Neumann F, Aivado M, et al. Treatment of severe steroid refractory acute graft-versus-host disease with infliximab, a chimeric human/mouse anti-TNF α antibody. *Bone Marrow Transplant* 2001;28:47–9.
- [67] Couriel D, Saliba R, Hicks K, Ippoliti C, de Lima M, Hosing C, et al. Tumor necrosis factor- α blockade for the treatment of acute GVHD. *Blood* 2004;104:649–54.
- [68] Patriarca F, Sperotto A, Damiani D, Morreale G, Bonifazi F, Olivieri A, et al. Infliximab treatment for steroid refractory acute graft versus host disease. *Haematologica* 2004;89:1352–9.
- [69] Uberti JP, Ayash L, Ratanatharathorn V, Silver S, Reynolds C, Becker M, et al. Pilot trial on the use of etanercept and methylprednisolone as primary treatment for acute graft-versus-host disease. *Biol Blood Marrow Transplant* 2005;11:680–7.
- [70] Kennedy GA, Butler J, Western R. Combination antithymocyte globulin and soluble TNF α inhibitor (etanercept) +/- mycophenolate mofetil for treatment of steroid refractory acute graft-versus-host disease. *Bone Marrow Transplant* 2006;37:1143–7.

- [71] Busca A, Locatelli F, Marmont F, Ceretto C, Falda M. Recombinant human soluble tumor necrosis factor receptor fusion protein as treatment for steroid refractory graft-versushost disease following allogeneic hematopoietic stem cell transplantation. *Am J Hematol* 2007;82:45-52.
- [72] Ambrosi P, Aillaud MF, Habib G, Kreitmann B, Metras D, Luccioni R, et al. Fluvastatin decreases soluble thrombomodulin in cardiac transplant recipients. *Thromb Haemost* 2000;84:46-8.
- [73] Chello M, Carassiti M, Agro F, Mastroberto P, Pugliese G, Colonna D, et al. Simvastatin blunts the increase of circulating adhesion molecules after coronary artery bypass surgery with cardiopulmonary bypass. *J Cardiothorac Vasc Anesth* 2004;18:605-9.
- [74] Chello M, Goffredo C, Patti G, Candura D, Melfi R, Mastrobuoni S, et al. Effects of atorvastatin on arterial endothelial function in coronary bypass surgery. *Eur J Cardiothorac Surg* 2005;28:805-10.
- [75] Patti G, Chello M, Pasceri V, Colonna D, Nusca A, Miglionico M, et al. Protection from procedural myocardial injury by atorvastatin is associated with lower levels of adhesion molecules after percutaneous coronary intervention: results from the ARMYDA-CAMs (Atorvastatin for Reduction of Myocardial Damage during Angioplasty-Cell Adhesion Molecules) substudy. *J Am Coll Cardiol* 2006;48:1560-6.
- [76] Boehme MW, Gao IK, Norden C, Lemmel EM. Decrease in circulating endothelial cell adhesion molecule and thrombomodulin levels during oral iloprost treatment in rheumatoid arthritis patients: preliminary results. *Rheumatol Int* 2006;26:340-7.
- [77] Wilasrusmee C, Ondocin P, Bruch D, Shah G, Kittur S, Wilarusmee S, et al. Amelioration of cyclosporine A effect on microvasculature by endothelin inhibitor. *Surgery* 2003;134:384-9.
- [78] Bohm F, Settergren M, Gonon AT, Pernow J. The endothelin-1 receptor antagonist bosentan protects against ischaemia/reperfusion-induced endothelial dysfunction in humans. *Clin Sci (Lond)* 2005;108:357-63.
- [79] Yamshita T, Shoge M, Oda E, Yamamoto Y, Giddings JC, Kashiwagi S, et al. The free-radical scavenger, edaravone, augments NO release from vascular cells and platelets after laser-induced, acute endothelial injury in vivo. *Platelets* 2006;17:201-6.
- [80] Sueishi K, Mishima K, Makino K, Itoh Y, Tsuruya K, Hirakata H, et al. Protection by a radical scavenger edaravone against cisplatin-induced nephrotoxicity in rats. *Eur J Pharmacol* 2002;451:203-8.
- [81] Ruutu T, Hermans I, Niederwieser D, Gratwohl A, Kiehl M, Volin L, et al. Thrombotic thrombocytopenic purpura after allogeneic stem cell transplantation: a survey of the European Group for Blood and Marrow Transplantation (EBMT). *Br J Haematol* 2002;118:1112-9.
- [82] Uderzo C, Bonanomi S, Busca A, Renoldi M, Ferrari P, Iacobelli M, et al. Risk factors and severe outcome in thrombotic microangiopathy after allogeneic hematopoietic stem cell transplantation. *Transplantation* 2006;82:638-44.



Microangiopathy

Edited by Prof. Raimondo De Cristofaro

ISBN 978-953-51-0419-3

Hard cover, 82 pages

Publisher InTech

Published online 23, March, 2012

Published in print edition March, 2012

Microangiopathies are pathological processes causing degenerative disorders of small vessels. The circulatory problems caused by microangiopathies may be responsible for failure of individual or multiple organs. These pathological processes are indeed one of the most common disorders characterized by high morbidity and mortality in the affected patients. Many studies have revealed very complicated processes both at cellular and molecular level. However, much work remains to define the diversity of different pathogenetic mechanisms leading to microangiopathic disorders to provide appropriate prevention and treatment strategies. The aim of this volume is providing illustrative examples of relevant mechanisms responsible for different forms of microangiopathies and how this body of evidences can be harnessed to define new strategies of therapeutic intervention.

How to reference

In order to correctly reference this scholarly work, feel free to copy and paste the following:

Fatih Erbey (2012). Transplant-Associated Thrombotic Microangiopathy in Childhood, Microangiopathy, Prof. Raimondo De Cristofaro (Ed.), ISBN: 978-953-51-0419-3, InTech, Available from:
<http://www.intechopen.com/books/microangiopathy/transplant-associated-thrombotic-microangiopathy-in-childhood>

INTech
open science | open minds

InTech Europe

University Campus STeP Ri
Slavka Krautzeka 83/A
51000 Rijeka, Croatia
Phone: +385 (51) 770 447
Fax: +385 (51) 686 166
www.intechopen.com

InTech China

Unit 405, Office Block, Hotel Equatorial Shanghai
No.65, Yan An Road (West), Shanghai, 200040, China
中国上海市延安西路65号上海国际贵都大饭店办公楼405单元
Phone: +86-21-62489820
Fax: +86-21-62489821

© 2012 The Author(s). Licensee IntechOpen. This is an open access article distributed under the terms of the [Creative Commons Attribution 3.0 License](https://creativecommons.org/licenses/by/3.0/), which permits unrestricted use, distribution, and reproduction in any medium, provided the original work is properly cited.

IntechOpen

IntechOpen