

We are IntechOpen, the world's leading publisher of Open Access books Built by scientists, for scientists

6,900

Open access books available

185,000

International authors and editors

200M

Downloads

Our authors are among the

154

Countries delivered to

TOP 1%

most cited scientists

12.2%

Contributors from top 500 universities



WEB OF SCIENCE™

Selection of our books indexed in the Book Citation Index
in Web of Science™ Core Collection (BKCI)

Interested in publishing with us?
Contact book.department@intechopen.com

Numbers displayed above are based on latest data collected.
For more information visit www.intechopen.com



Intestinal Thrombotic Microangiopathy After Hematopoietic Stem Cell Transplantation

Hiroto Narimatsu

*Advanced Molecular Epidemiology Research Institute, Faculty of Medicine,
Yamagata University, Yamagata,
Japan*

1. Introduction

Thrombotic microangiopathy (TMA) is a significant complication following hematopoietic stem-cell transplantation (HSCT), which is also described as transplant-associated microangiopathy (TAM). Endothelial injuries from multiple factors contribute to the formation of widespread platelet thrombi within the microvasculature, causing hemolytic anemia and damage to various organs (Daly *et al*, 2002a; Daly *et al*, 2002b; Nishida *et al*, 2004; Pettitt & Clark, 1994; Shimoni *et al*, 2004; Zeigler *et al*, 1996; Zeigler *et al*, 1995). Owing to the difficulty in making a definitive diagnosis of TMA in HSCT recipients, it is usually diagnosed based on clinical and laboratory findings, such as serum lactic dehydrogenase (LD) levels and the percentage of fragmented erythrocytes (Martinez *et al*, 2005; Oran *et al*, 2007; Zeigler *et al*, 1995).

However, these findings are frequently nonspecific, because they are influenced by many other clinical events. Some research group has been reported case series involving TMA with steroid-refractory diarrhea. They showed that TMA frequently involves the gastrointestinal tract in HSCT recipients (Inamoto *et al*, 2009; Narimatsu *et al*, 2005; Nishida *et al*, 2004).

The transplantation-related TMA has different clinical features and outcomes from TMA in the patients with other situations. In this chapter, I describe clinical feature and treatment of the transplantation-related TMA.

2. Classic and intestinal TMA – Clinical manifestations

The most common criteria for classic TMA diagnosis following HSCT are the signs of microangiopathic hemolysis (Martinez *et al*, 2005; Oran *et al*, 2007). On the other hand, in the patients with intestinal TMA, red cell fragmentation and serum LD elevation were usually mild or absent, and serum haptoglobin levels were detectable (Inamoto *et al*, 2009; Narimatsu *et al*, 2005; Nishida *et al*, 2004). Postmortem studies failed to find any evidence of TMA other than in the intestine (Narimatsu *et al*, 2005). Neither renal dysfunction nor neurologic abnormalities were not usually present in those patients. Based on the conventional pentad of HUS/TTP, TMA was not diagnosed in any of them in intestinal TMA. These findings suggest a difference in pathogenesis between intestinal TMA (Inamoto *et al*, 2009; Narimatsu

et al, 2005; Nishida *et al*, 2004) following HSCT and either classic TTP (Furlan *et al*, 1998) or classic TMA following HSCT (Allford *et al*, 2002; Nishida *et al*, 2004).

The differences in the observations between classic TMA and intestinal TMA can be explained by several reasons, such as the conditioning agents and patients' backgrounds. It may be also explained by following reasons. Clinicians and pathologists might not be commonly aware of TMA and could possibly have misinterpreted it as GVHD or infectious colitis. A pathological diagnosis of TMA can be difficult to make. Thrombolysis, which might occur after death, might have masked the pathological findings of TMA at autopsy (Iwata *et al*, 2001). However, those explanations failed to explain this reason. Thus, further investigation can allow a proper interpretation of the various published reports.

3. Diagnosis of intestinal TMA

Total colonoscopy from the rectum to the terminal ileum with biopsy is required for the diagnosis of intestinal TMA. The patients had focal TMA lesions of various distributions. Thus, biopsy of the rectum alone might have missed the diagnosis of TMA. Colonoscopic findings of TMA were diverse (Narimatsu *et al*, 2005). It was difficult to differentiate TMA from intestinal GVHD (Iqbal *et al*, 2000; Martin *et al*, 2004) and CMV colitis (Meyers *et al*, 1986). Furthermore, TMA was complicated with GVHD and CMV colitis in many patients (Inamoto *et al*, 2009; Narimatsu *et al*, 2005). Macroscopic observation alone is not sufficient to make a diagnosis of TMA. Laboratory findings alone are also not useful in previous studies (Inamoto *et al*, 2009; Narimatsu *et al*, 2005; Nishida *et al*, 2004). Clinically available risk factors were also not identified in previous studies; laboratory data such as LD at the time of colonoscopy were not significantly different between patients with and without TMA. Thus, a biopsy and a pathological examination extending from the rectum to the terminal ileum are probably necessary to make a definite diagnosis in patients with diarrhea.

4. Pathological features

Suggested mechanisms on onset of intestinal TMA was shown in Figure 1; there is limited information on the pathogenesis of intestinal TMA (Inamoto *et al*, 2009; Narimatsu *et al*, 2005; Nishida *et al*, 2004). Classic TMA after myeloablative HSCT has a multifactorial etiology that includes immunosuppressive agents (Pham *et al*, 2000; Trimarchi *et al*, 1999) total body irradiation (TBI) (Ballermann, 1998), CMV infection (Takatsuka *et al*, 2003), and acute GVHD (Ertault-Daneshpouy *et al*, 2004). These factors injure the vascular endothelium of many organs (Pettitt & Clark, 1994). In contrast, particular factors specifically affecting the gastrointestinal system are largely involved in the etiology of intestinal TMA after HSCT. It should be noted that most patients with intestinal TMA had overlapping gastrointestinal GVHD and/or CMV colitis (Narimatsu *et al*, 2005). An animal study has demonstrated that the vascular endothelium is a target of alloimmunity (Ertault-Daneshpouy *et al*, 2004). The previous report by us supports this hypothesis (Narimatsu *et al*, 2005). GVHD was associated with gastrointestinal TMA, and the association could partly explain why TMA was located in the gut. It is reasonable to assume that GVHD damages the gastrointestinal endothelium, leading to the development of intestinal TMA. Regimen-related toxicity (RRT) of the gut is known to increase the risk of intestinal GVHD (Goldberg *et al*, 2005). Gastrointestinal damage due to preparative regimens might contribute to the development of intestinal TMA. In our

previous study, CMV infection, which is another putative etiology of TMA,(Takatsuka *et al*, 2003) was documented in 4 patients, and all were located in the gut. (Narimatsu *et al*, 2005) CMV colitis might be associated with intestinal TMA following HSCT.

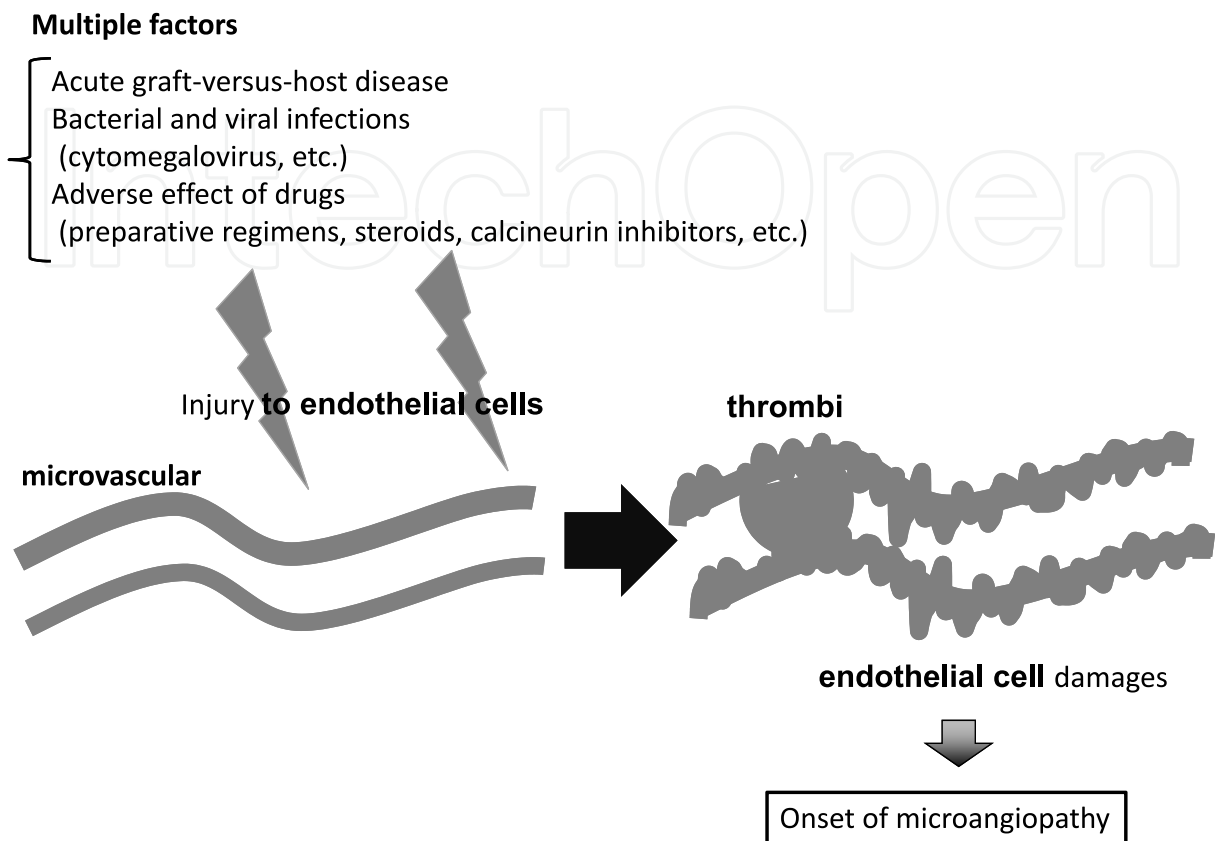


Fig. 1. Suggested mechanisms on onset of intestinal TMA

Inamoto *et al* presented the usefulness of Immunostainings(Inamoto *et al*, 2009). They made histopathological diagnosis of “intestinal TAM” by the presence of microangiopathy with ischemic (noninflammatory) crypt loss. Microangiopathy was confirmed by hematoxylin-eosin staining and CD34 immunostaining. The clues for endothelial injury are swollen endothelial cells and denuded endothelial cells. Ischemic changes followed by microangiopathy included individual non-inflammatory crypt degeneration with detachment and apoptosis of epithelial cells, wedge-shaped segmental injury and interstitial edema with hemorrhage or fragmented RBCs. Although, pathological definition of intestinal TMA is uncertain, these pathological findings are worth investigating.

5. Treatment

While the appropriate treatment of intestinal TMA is unknown, a published series of cases suggests that reducing the dose of immunosuppressants may be effective for intestinal TMA as well as classic TMA.(Inamoto *et al*, 2009; Nishida *et al*, 2004) On the other hand, our study group suggested that patients with intestinal GVHD and TMA could be improved without immunosuppressant reduction. This observation would indicate that the management of GVHD, rather than immunosuppressant reduction, is important in the treatment of intestinal TMA. In fact, the reduction of immunosuppressants to prevent vascular

endothelial damage would aggravate GVHD, and increase the risk of TMA progression. (Narimatsu et al, 2005) Considering these possibilities, one should be vigilant when deciding on the dose of immunosuppressant for TMA after HSCT.

The treatments used for classic TTP, such as fresh frozen plasma and plasma exchange, have been tried for TMA after bone marrow transplantation.(Allford *et al*, 2002) However, the efficacy of these treatments in patients with intestinal TMA remains unclear. Minimizing the damage to the intestinal mucosa and the vascular endothelium would be more desirable for the management of intestinal TMA than the treatments designed for classic TTP.

6. Conclusion and future direction

The intestinal TMA is a significant complication after HSCT. When transplant recipients develop refractory diarrhea, Intestinal TMA needs to be included in the differential diagnoses. However, conventional diagnostic criteria can overlook TMA. Thus, the diagnosis of intestinal TMA after HSCT requires endoscopy with biopsy.


7. References

- Allford SL, Bird JM, Marks DI (2002) Thrombotic thrombocytopenic purpura following stem cell transplantation. *Leuk Lymphoma* Vol. 43 No.(10): pp 1921-6,
- Ballermann BJ (1998) Endothelial cell activation. *Kidney Int* Vol. 53 No.(6): pp 1810-26,
- Daly AS, Hasegawa WS, Lipton JH, Messner HA, Kiss TL (2002a) Transplantation-associated thrombotic microangiopathy is associated with transplantation from unrelated donors, acute graft-versus-host disease and venoocclusive disease of the liver. *Transfus Apher Sci* Vol. 27 No.(1): pp 3-12, 1473-0502 (Print) 1473-0502 (Linking)
- Daly AS, Xenocostas A, Lipton JH (2002b) Transplantation-associated thrombotic microangiopathy: twenty-two years later. *Bone Marrow Transplant* Vol. 30 No.(11): pp 709-15, 0268-3369 (Print) 0268-3369 (Linking)
- Ertault-Daneshpouy M, Leboeuf C, Lemann M, Bouhidel F, Ades L, Gluckman E, Socie G, Janin A (2004) Pericapillary hemorrhage as criterion of severe human digestive graft-versus-host disease. *Blood* Vol. 103 No.(12): pp 4681-4,
- Furlan M, Robles R, Galbusera M, Remuzzi G, Kyrle PA, Brenner B, Krause M, Scharrer I, Aumann V, Mittler U, Solenthaler M, Lammle B (1998) von Willebrand Factor-Cleaving Protease in Thrombotic Thrombocytopenic Purpura and the Hemolytic-Uremic Syndrome. *N Engl J Med* Vol. 339 No.(22): pp 1578-1584,
- Goldberg J, Jacobsohn DA, Zahurak ML, Vogelsang GB (2005) Gastrointestinal toxicity from the preparative regimen is associated with an increased risk of graft-versus-host disease. *Biol Blood Marrow Transplant* Vol. 11 No.(2): pp 101-7,
- Inamoto Y, Ito M, Suzuki R, Nishida T, Iida H, Kohno A, Sawa M, Murata M, Nishiwaki S, Oba T, Yanada M, Naoe T, Ichihashi R, Fujino M, Yamaguchi T, Morishita Y, Hirabayashi N, Kodera Y, Miyamura K (2009) Clinicopathological manifestations and treatment of intestinal transplant-associated microangiopathy. *Bone Marrow Transplant* Vol. 44 No.(1): pp 43-9, 1476-5365 (Electronic) 0268-3369 (Linking)

- Iqbal N, Salzman D, Lazenby AJ, Wilcox CM (2000) Diagnosis of gastrointestinal graft-versus-host disease. *Am J Gastroenterol* Vol. 95 No.(11): pp 3034-8,
- Iwata H, Kami M, Hori A, Hamaki T, Takeuchi K, Mutou Y (2001) An autopsy-based retrospective study of secondary thrombotic thrombocytopenic purpura. *Haematologica* Vol. 86 No.(6): pp 669-70,
- Martin PJ, McDonald GB, Sanders JE, Anasetti C, Appelbaum FR, Deeg HJ, Nash RA, Petersdorf EW, Hansen JA, Storb R (2004) Increasingly frequent diagnosis of acute gastrointestinal graft-versus-host disease after allogeneic hematopoietic cell transplantation. *Biol Blood Marrow Transplant* Vol. 10 No.(5): pp 320-7,
- Martinez MT, Bucher C, Stussi G, Heim D, Buser A, Tsakiris DA, Tichelli A, Gratwohl A, Passweg JR (2005) Transplant-associated microangiopathy (TAM) in recipients of allogeneic hematopoietic stem cell transplants. *Bone Marrow Transplant* Vol. 36 No.(11): pp 993-1000, 0268-3369 (Print) 0268-3369 (Linking)
- Meyers JD, Flournoy N, Thomas ED (1986) Risk factors for cytomegalovirus infection after human marrow transplantation. *J Infect Dis* Vol. 153 No.(3): pp 478-88,
- Narimatsu H, Kami M, Hara S, Matsumura T, Miyakoshi S, Kusumi E, Kakugawa Y, Kishi Y, Murashige N, Yuji K, Masuoka K, Yoneyama A, Wake A, Morinaga S, Kanda Y, Taniguchi S (2005) Intestinal thrombotic microangiopathy following reduced-intensity umbilical cord blood transplantation. *Bone Marrow Transplant* Vol. 36: pp 517-23,
- Nishida T, Hamaguchi M, Hirabayashi N, Haneda M, Terakura S, Atsuta Y, Imagama S, Kanie T, Murata M, Taji H, Suzuki R, Morishita Y, Kodera Y (2004) Intestinal thrombotic microangiopathy after allogeneic bone marrow transplantation: a clinical imitator of acute enteric graft-versus-host disease. *Bone Marrow Transplant* Vol. 33 No.(11): pp 1143-50, 0268-3369 (Print) 0268-3369 (Linking)
- Oran B, Donato M, Aleman A, Hosing C, Korbl M, Detry MA, Wei C, Anderlini P, Popat U, Shpall E, Giralt S, Champlin RE (2007) Transplant-associated microangiopathy in patients receiving tacrolimus following allogeneic stem cell transplantation: risk factors and response to treatment. *Biology of blood and marrow transplantation : journal of the American Society for Blood and Marrow Transplantation* Vol. 13 No.(4): pp 469-77, 1083-8791 (Print) 1083-8791 (Linking)
- Pettitt AR, Clark RE (1994) Thrombotic microangiopathy following bone marrow transplantation. *Bone Marrow Transplant* Vol. 14 No.(4): pp 495-504, 0268-3369 (Print) 0268-3369 (Linking)
- Pham PT, Peng A, Wilkinson AH, Gritsch HA, Lassman C, Pham PC, Danovitch GM (2000) Cyclosporine and tacrolimus-associated thrombotic microangiopathy. *Am J Kidney Dis* Vol. 36 No.(4): pp 844-50,
- Shimoni A, Yeshurun M, Hardan I, Avigdor A, Ben-Bassat I, Nagler A (2004) Thrombotic microangiopathy after allogeneic stem cell transplantation in the era of reduced-intensity conditioning: The incidence is not reduced. *Biology of blood and marrow transplantation : journal of the American Society for Blood and Marrow Transplantation* Vol. 10 No.(7): pp 484-93, 1083-8791 (Print) 1083-8791 (Linking)

- Takatsuka H, Wakae T, Mori A, Okada M, Fujimori Y, Takemoto Y, Okamoto T, Kanamaru A, Kakishita E (2003) Endothelial damage caused by cytomegalovirus and human herpesvirus-6. *Bone Marrow Transplant* Vol. 31 No.(6): pp 475-9,
- Trimarchi HM, Truong LD, Brennan S, Gonzalez JM, Suki WN (1999) FK506-associated thrombotic microangiopathy: report of two cases and review of the literature. *Transplantation* Vol. 67 No.(4): pp 539-44,
- Zeigler ZR, Rosenfeld CS, Andrews DF, 3rd, Nemunaitis J, Raymond JM, Shadduck RK, Kramer RE, Gryn JF, Rintels PB, Besa EC, George JN (1996) Plasma von Willebrand Factor Antigen (vWF:AG) and thrombomodulin (TM) levels in Adult Thrombotic Thrombocytopenic Purpura/Hemolytic Uremic Syndromes (TTP/HUS) and bone marrow transplant-associated thrombotic microangiopathy (BMT-TM). *Am J Hematol* Vol. 53 No.(4): pp 213-20, 0361-8609 (Print)0361-8609 (Linking)
- Zeigler ZR, Shadduck RK, Nemunaitis J, Andrews DF, Rosenfeld CS (1995) Bone marrow transplant-associated thrombotic microangiopathy: a case series. *Bone Marrow Transplant* Vol. 15 No.(2): pp 247-53, 0268-3369 (Print)0268-3369 (Linking)

IntechOpen



Microangiopathy

Edited by Prof. Raimondo De Cristofaro

ISBN 978-953-51-0419-3

Hard cover, 82 pages

Publisher InTech

Published online 23, March, 2012

Published in print edition March, 2012

Microangiopathies are pathological processes causing degenerative disorders of small vessels. The circulatory problems caused by microangiopathies may be responsible for failure of individual or multiple organs. These pathological processes are indeed one of the most common disorders characterized by high morbidity and mortality in the affected patients. Many studies have revealed very complicated processes both at cellular and molecular level. However, much work remains to define the diversity of different pathogenetic mechanisms leading to microangiopathic disorders to provide appropriate prevention and treatment strategies. The aim of this volume is providing illustrative examples of relevant mechanisms responsible for different forms of microangiopathies and how this body of evidences can be harnessed to define new strategies of therapeutic intervention.

How to reference

In order to correctly reference this scholarly work, feel free to copy and paste the following:

Hiroto Narimatsu (2012). Intestinal Thrombotic Microangiopathy After Hematopoietic Stem Cell Transplantation, Microangiopathy, Prof. Raimondo De Cristofaro (Ed.), ISBN: 978-953-51-0419-3, InTech, Available from: <http://www.intechopen.com/books/microangiopathy/intestinal-thrombotic-microangiopathy-after-hematopoietic-stem-cell-transplantation>

INTECH
open science | open minds

InTech Europe

University Campus STeP Ri
Slavka Krautzeka 83/A
51000 Rijeka, Croatia
Phone: +385 (51) 770 447
Fax: +385 (51) 686 166
www.intechopen.com

InTech China

Unit 405, Office Block, Hotel Equatorial Shanghai
No.65, Yan An Road (West), Shanghai, 200040, China
中国上海市延安西路65号上海国际贵都大饭店办公楼405单元
Phone: +86-21-62489820
Fax: +86-21-62489821

© 2012 The Author(s). Licensee IntechOpen. This is an open access article distributed under the terms of the [Creative Commons Attribution 3.0 License](https://creativecommons.org/licenses/by/3.0/), which permits unrestricted use, distribution, and reproduction in any medium, provided the original work is properly cited.

IntechOpen

IntechOpen