

We are IntechOpen, the world's leading publisher of Open Access books Built by scientists, for scientists

6,900

Open access books available

186,000

International authors and editors

200M

Downloads

Our authors are among the

154

Countries delivered to

TOP 1%

most cited scientists

12.2%

Contributors from top 500 universities



WEB OF SCIENCE™

Selection of our books indexed in the Book Citation Index
in Web of Science™ Core Collection (BKCI)

Interested in publishing with us?
Contact book.department@intechopen.com

Numbers displayed above are based on latest data collected.
For more information visit www.intechopen.com



Repair of Incisional Hernias of the Midline Under Local Anesthesia in an Ambulatory Basis

Alberto F. Acevedo

*Hernia Center, Reference Health Center "Cordillera", Santiago
Universidad de Chile, Medicine Faculty, Surgical Department
Salvador Hospital, Santiago
Chile*

1. Introduction

1.1 General considerations

1. The selection of patients is important when performing this rather big surgical procedures with local anesthesia. Those who prefer general or regional anesthesia and patients with adverse reactions to LA should be excluded, as well as patients with psychological and psychiatric conditions.
2. An experienced surgeon in the use of local anesthesia will not only perform a better anesthesia but will positively influence his patient during the intervention. The surgeon-patient relationship is relevant in these cases.
3. The surgeon should be experienced in the management of the abdominal wall in order to realize a technically adequate procedure in a short time, with a careful and delicate management of tissues.
4. In these midline incisional hernias the hole length of the scar should be excised and the midline explored because of the multisacularity condition of these defects (7).
5. New surgical techniques to be used under local anesthesia should be ideally be developed and submitted to clinical tests in specialized centers, by experts and tested scientifically. Our hernia center gathers all these conditions (8).

1.2 Our experience

Patients with hernial-sacs smaller as 15cm and a width of the hernial-ring smaller as 4cm. were accepted in our program to be operated in an ambulatory basis, under local anesthesia Fig. 1.

Patients accomplishing the social, financial, psychological and health conditions requirable for these procedures signed an informed consensus and in general accepted gladly to be incorporated to the program (8).

Obesity with a BMI up to 45 and compensated diabetes mellitus were not considered a motive for exclusion of patients from the program

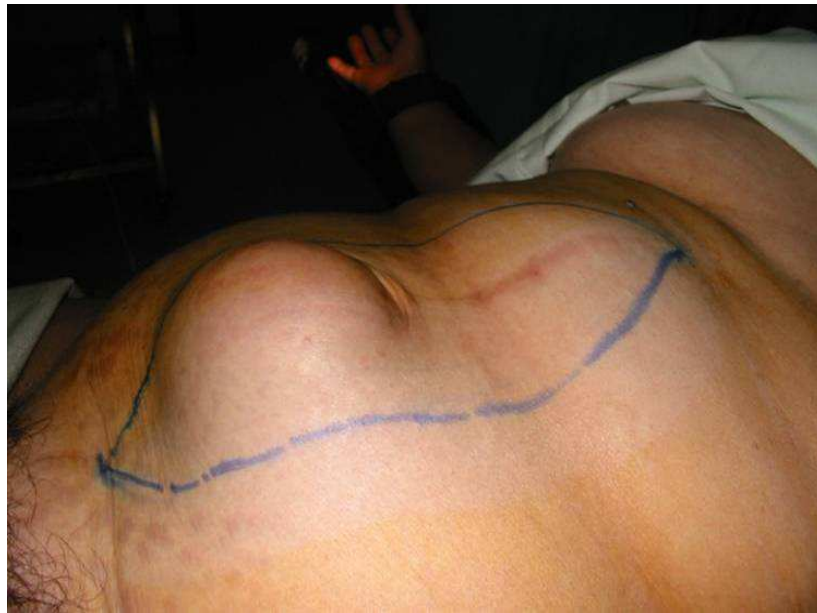


Fig. 1. Incisional hernia of the midline and umbilical hernia. The blue line shows the skin incision.

1.3 Anesthesia

The day of surgery patients were allowed to drink water or tea, but no solid meals. Medications for chronic conditions as diabetes mellitus and hypertension were not suspended. Patients got their skin prepared as usual, entered the op room and were placed supine at the operation table with a light head down tilt. The anesthetist applied sedation and kept control of vital signs, ECG, O₂ and CO₂.

Antiseptic preparation of the skin and local anesthesia was applied before the preparation of the operation field in order to obtain a deeper anesthesia.

For these big operation fields we performed local anesthesia by means of a quite diluted Lidocaine solution (0,3 - 0,5%), alkalized with sodium bicarbonate and with adrenalin addition.

It's recommendable that the surgeon traces a line over the skin lozenge to be excised over the hernial sac, because it's going to exceed as the underlying rectus sheaths are approached to each other to build a new "linea alba". In lean patients the skin excision should be narrower as in obese (Fig 1).

1.4 Summary of local anesthesia repair

1. Subcuticular injection of anesthetic. It's performed in the whole length of the skin incision (40 - 60ml).
2. Infiltration of the subcutaneous tissue in all the length of the surgical wound (60 - 100ml).
3. Infiltration of the rectus muscle through the aponeurosis (Fig. 2). The surgeon makes the skin incision down to the rectus sheath. Deposits of 2 - 3ml Lidocaine solution should be realized each 2 - 3cm, in all the length of the wound at both sides (30 - 40ml).

4. The skin and subcutaneous tissue lozenge is excised together. Small amounts of anesthesia may be necessary at the point where the nerves perforate the rectus Sheath to achieve the skin. (10 – 20ml)
5. At this point the hernial sacs are exposed and the surgeon can recognize its number and the width of the hernial rings.
6. The Double Invaginating Isotensional Repair (DIIR) technique proposed makes it unnecessary to perform an incision in the “linea alba”. The sacs are simply individually reduced as the first isotensional suture is performed (Fig. 4 - a).
7. While the second and third suture line of the DIIR are performed (Fig. 4 - b, c), it is possible that further Lidocain deposits in the rectus muscle are needed (10 – 20ml).
8. This surgery needs sedation performed by the anesthetist whose presence in the operation theatre is mandatory.

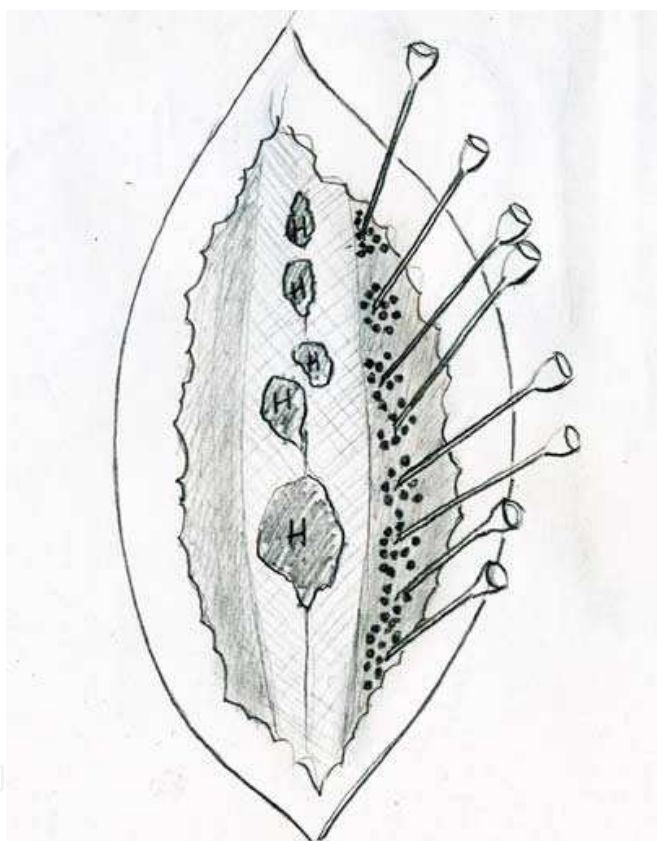


Fig. 2. Deposits of local anestheticum in the rectus muscle.

1.5 Concomitant umbilical, epigastric hernia and middle line diastases repair

These pathologies may coexist with the incisional hernia and can be simultaneously treated with this technique under local anesthesia (9). In these cases it is necessary to act up on the umbilicus which in small defects can be preserved. In bigger ones it is better to extirpate it and build a new one with a skin plastic.

In this case local anesthesia and skin incision should be prolonged some 3 – 4cm under the umbilicus. The umbilical and epigastric hernial sacs are treated similarly as the incisional hernia ones (Figs. 1,3).

1.6 Intraoperative monitoring

Through the operation the anesthesia assistant nurse stays by the patient attending his necessities and maintaining his attention away from the operative procedure. She keeps a written report of the evolution of the vital signs, well being of the patients, as well of the adverse reactions and their treatment.

The stress reaction during local anesthesia varies considerably from patient to patient and manifests itself through the vital signs (hypertension, tachycardia) and through nervousness and restlessness that should be managed by the anesthetist with the required pharmacological support.

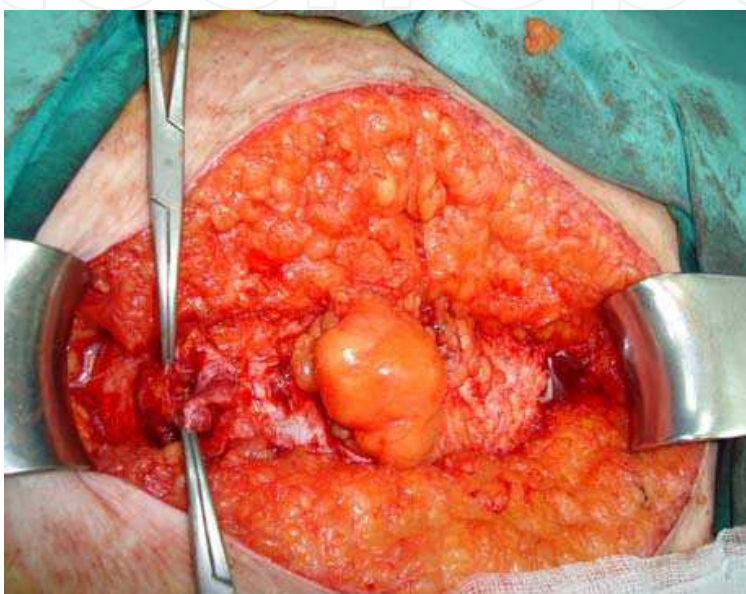


Fig. 3. Multisacral incisional hernia of the midline. The umbilical hernia has been already reduced.

1.7 Postoperative care

The surgical wound is dressed and covered by an elastic girdle. Immediately after the operation the patient sits in the operation table, stays up and walks some 10 meters to the postoperative care station where he sits in a comfortable armchair. At this point the anesthetist and the postoperative care nurse take care of the patient.

At this stage the patient is allowed to take a breakfast in the company of a family member. As a precaution a saline vein-infusion is maintained during this period.

After an observation time of 2 – 4 hours the patient dresses and is carried in a wheel chair to the CRS entry to be translated to his home.

Detailed indications are provided to the patient and his family as well as a telephone number in order to stay in touch with the CRS Hernia Center. Bed rest is restricted and moving, walking and activities at home are enhanced.

The patient is appointed to a personal control at the CRS the day after the operation where the wound is inspected and the evolution kept under careful observation. Controls are made a week and a month after the intervention.

2. Operative technique

Consideration should be paid to the fact that multisacularity is a frequent condition in theses hernias (Fig. 3). Among our patients it affects 83% if the hernias of the midline (Table 1). This fact makes it imperative to explore the scar in all its length (6).

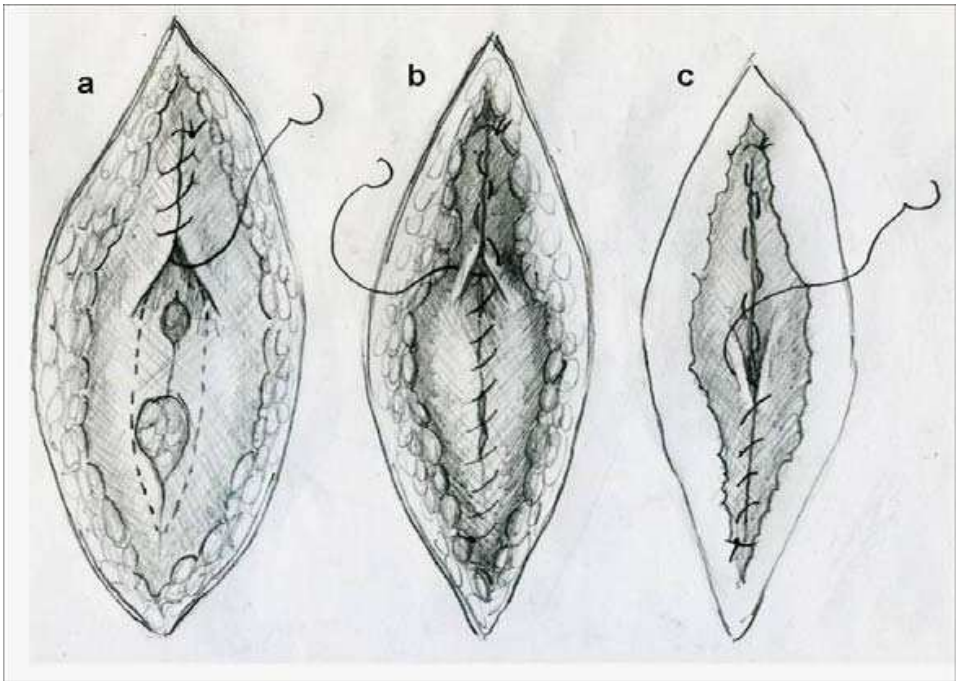


Fig. 4. a.- The midline defect is closed by means of an isotensional suture in al the length of the xifo-umbilical midline; b.- first row of invaginating suture; c.- second row of invaginating suture.

We considered the performance of tissue repair by means of an original technique developed in our Hernia Center (9). This technique pursue a reconstruction of the “linea alba” by means of an isotensional repair followed by a double invaginating suture (DIIR) (Fig 3).

This tissue technique is performed if the hernial ring borders can be sutured without tension (usually in defects not wider as 3cm). In wider defects a flat Prolene mesh patch was installed in a sub-lay position and fixed to the aponeurosis with transfixing Prolene sutures.

In a prospective study performed in these patients(10) we could demonstrate that the drainage can be replaced with slowly absorbable interrupted subcutaneous sutures anchored to the aponeurosis (10) (Fig. 5, 6).

Number of hernial sacs	n patients	%
1	44	17
2	129	49.5
3	47	18.1
4 or more	40	15.4
Total	260	100

Table 1. Multisacularity of incisional hernias of the midline

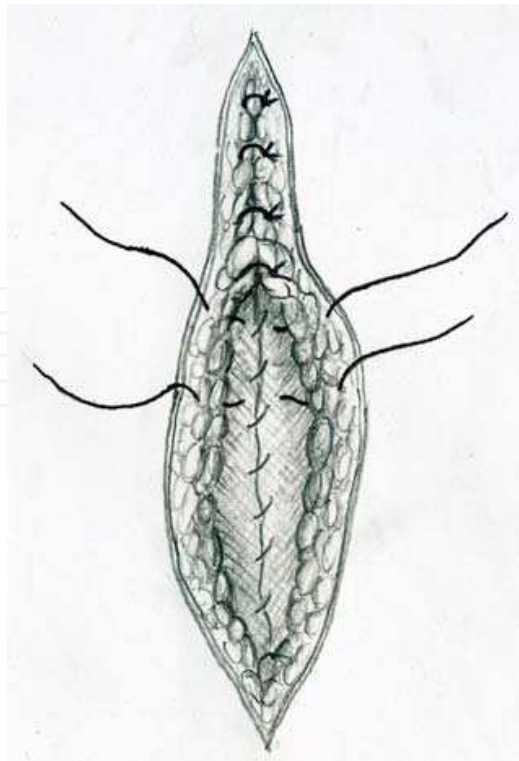


Fig. 5. Schematic representation of the subcutaneous anchored suture

The skin is closed with an intradermal continuous suture (Fig. 7)

3. Clinical experience

The preoperative, operative and postoperative evolution of our patients was kept in the data base of the CRS Hernia Center constructed with the software of epidemiologic calculus "Epi Info".

We give account of a study performed recently (9) on 260 patients with incisional hernias of the midline. At first we started a controlled clinical trial between mesh and tissue repair of midline incisional hernias, but this study developed with time to an observational one because of the obvious benefits obtained with the tissue repair performed with the DIIS. A mesh was installed in 71 patients, while 189 cases received a DIIR (Tables 2, 3).

Characteristics and associated pathologies were similar in patients treated with mesh and tissue repair.

This patients-series is composed by 207 women and 53 men with a middle age of 54 +/- 8,6 years. Obesity (BMI>30) was present in 51.2% of the patients, being observed in a significantly higher proportion among women ($P<0.021$).

A first repair of the incisional hernia was performed in 86% of the patients; a recurrent hernia was present in the rest.

The hernial sac was bigger as 10 cm in 64% of patients and smaller in the rest. Obese patients showed a significantly higher proportion of sacs bigger as 10cm ($P<0,03$).

The number of sacs observed in our series varies considerably (Table 1).

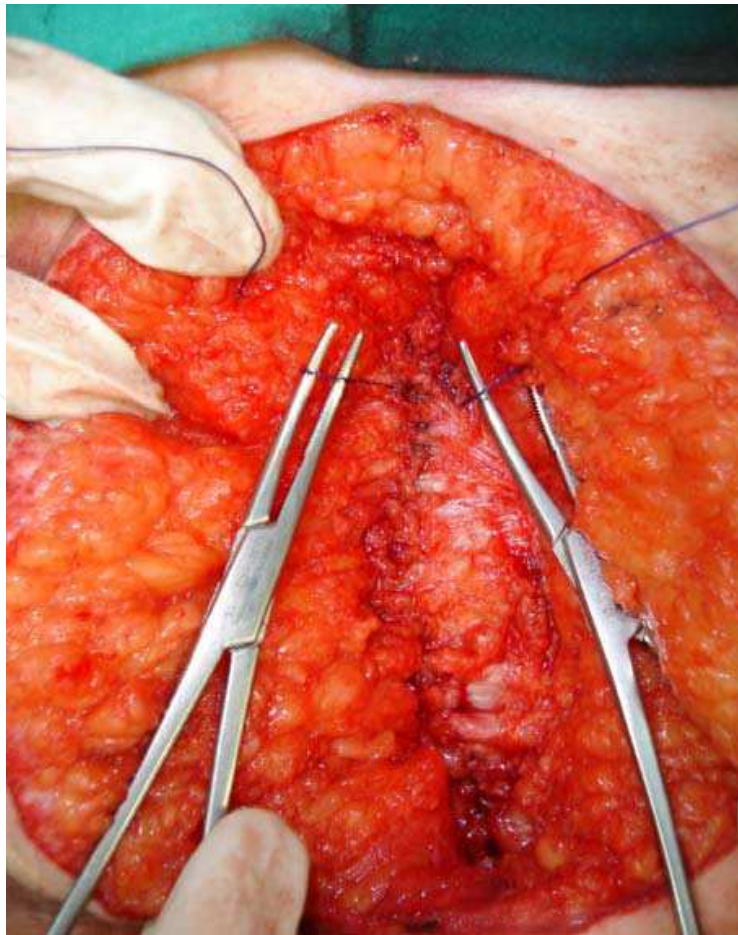


Fig. 6. Subcutaneous anchored suture.

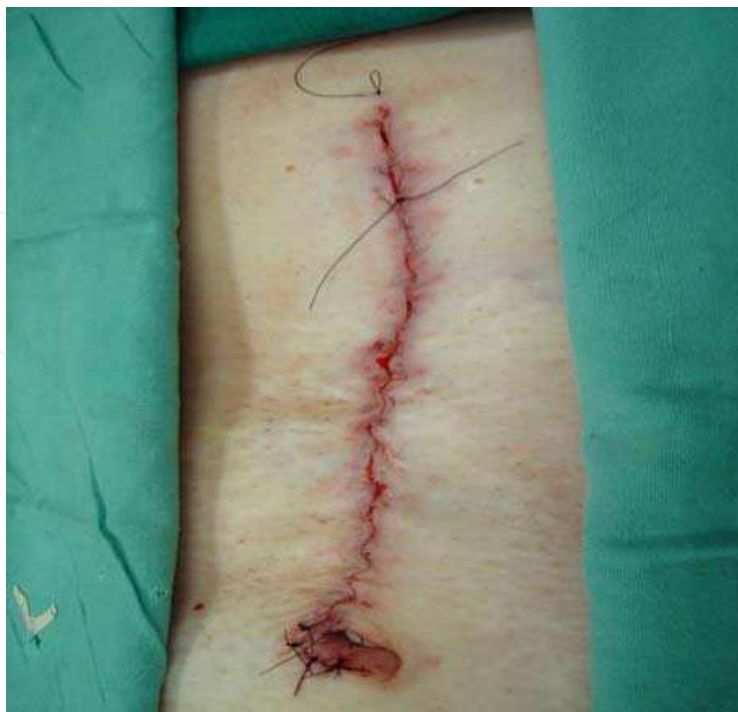

Fig. 7. Skin intradermal continuous suture.

YEARS	Mesh (%)	Tissue (%)
1998 - 2000	25 (62.5)	15 (37.5)
2001 - 2003	20 (27)	54 (73)
2004 - 2006	19 (20.7)	73 (79.3)
2007 - 2009	7 (7.9)	47 (82.1)
TOTAL	71	189

Table 2. Distribution of our patients in the years

TECHNIQUES	n
Mesh	71
DIIS	160
Simple suture	29
TOTAL	260

Table 3. Techniques performed in our series

3.1 Intraoperative evolution (Table 4)

Care was paid to follow the technique previously described.

Under theses circumstances the intraoperative pain and discomfort referred by the patients was comparable with the one observed in the repair of huge and complex inguinal hernias.

Although we have performed some interventions in patients with xifo-pubic incisional hernias, a spinal anesthesia is better option in theses cases. We would recommend local anesthesia only when the general condition of the patient demands it.

The presence of the anesthetist is mandatory in these procedures, especially in obese patients. Aside from troubles derived from the surgery it's self, the surgery lasts longer in obese patients that feel uncomfortable in a supine position at the operation table.

3.2 Postoperative evolution (Table 4)

The first control was realized 24 hours after the operation. Our purpose was to control the mobility of patients and to have a look to the performance of daily activities at home. Motility, respiratory and digestive tract functions were evaluated.

At this early stage of the evolution, abdominal pain was the principal complaint of patients, understandable because of the traction of the flat muscles of the abdominal wall upon the suture in the midline. It decreases after the third day, especially in patients that remain active.

The postoperative analgesia in incisional herniorrhaphy is a very important issue. Every group of surgeons will have its one approach to this fundamental point of surgical treatment.

We mind that patients should be informed that pain is the natural consequence of surgery. A patient that has been prepared to his postoperative evolution will have a better control and management of pain the days after surgery.

We are recommending Ketoprofen 100mg each 12 hours and Paracetamol 500mg each 8 hours for the first 3 or 4 days after surgery.

At the thirtieth day it is possible to obtain a more realistic impression of the patient over his surgical treatment. Impressive is the high proportion of patients being very satisfied with the herniorrhaphy performed under local anesthesia in an ambulatory basis.

Infections were present in mesh and tissue techniques that were treated ambulatory with drainage and antibiotics. The two infected prosthetic repairs healed without removal of the mesh.

Information	mesh	tissue	p-value
Intraoperative			
Op duration minutes (St)	73 (12)	49 (18)	<0,02
Pain (VAS)	2,1 (0,4)	2,2 (0,3)	ns
Postoperative (24hours)			
Pain (VAS < 3)	79%	71%	<0,04
Satisfaction (VAS>7)	97%	87%	<0,032
Recommend this surgery	89.2%	83%	ns
Nausea	4,2%	3,8%	ns
Bed rest the first day	9,6%	12,1%	ns
Self sufficiency at home	76%	83,6%	ns
Alimentary intolerance	2,1%	3,2%	ns
Urine retention	0,4%	1,2%	ns
Emergency unit attendance	1,2%	0	ns
Re-admittance	0,2%	0	ns
Postoperative (30 days)			
Pain (VAS <3)	98,2%	97,1%	ns
Satisfaction (VAS>7)	98.2%	96,5%	ns
Infection	3,6	3,2	ns
Hematomas	0	1,2	ns

Table 4. Intra and postoperative follow-up of the patients

3.3 Long time follow-up

In a study published 2009 we gave account of a follow-up performed in 85% of 116 patients treated with the DIIR and 23 with sub-lay mesh hernioplasty (10). Seventeen DIIS and 3 mesh hernioplasty patients were not available for this study for different reasons. The study performed following the strict criteria proposed by Israelsson (11).

Patients treated with prosthetic and tissue repair were personally controlled by a staff member after a follow-up period of 6 (2,8 – 8) years. The recurrence rate was 12% for the mesh repairs and of 6% for the DIIR.

A high proportion of patients was satisfied or highly satisfied with ambulatory surgery under local anesthesia (98%) and would recommend it. The two unsatisfied patients had pain in the lateral abdomen with restriction of usual activities.

4. Final commentary


A surgeon with experience in abdominal wall surgery and in the performance of local anesthesia is imperative for the success in the treatment of these more complex hernias of the abdominal wall under local anesthesia.

The tissue repair under local anesthesia for small size incisional hernias with the proposed DIIR technique has become the standard treatment for these patients. It simplifies and shortens the surgical repair of these hernias and makes possible its realization in an ambulatory basis.

Surgical complications are seldom and the acceptance of patients operated in our Centrum has proven to be very good.

5. References

- [1] Chevrel JP, Rath AM. Classification of incisional hernias of the abdominal wall. *Hernia* 2000; 4: 7 - 11
- [2] Herszage L. Indication and limitations of suture closure. Significance of relaxing incisions. In Schumpelick V, Kingsnorth AM. *Incisional hernia*. Springer Verlag, Berlin Heidelberg, 1999, pp279 - 286
- [3] Muysoms FE, Miserez M, Berrevoet F, Campanelli G, Champault GG, Chelala E, et al. Classification of primary and incisional abdominal wall hernias. *Hernia* 2009; 13: 407 - 14
- [4] Flament JB, Rives J. Major incisional hernias. In Chevrel JP, *hernias and surgery of the abdominal wall*. Springer Verlag, Berlin, 1998, pp128 - 158
- [5] Stoppa RE. The treatment of complicated groin and incisional hernias. *World J Surg* 1989;13: 545 554
- [6] Wantz GE. Incisional hernioplasty with Mersilene. *Surg Gynecol Obstet* 1991; 172: 129 - 137
- [7] Acevedo A. Multisacularidad de las eventraciones de la línea media. Cuaderno de resúmenes del LXXVII Congreso Chileno de Cirugía, Pucón, 2004
- [8] Acevedo A, Viterbo A, Bravo J, Dellepiane V. Eventraciones, cirugía ambulatoria con anestesia local. *Rev Chil Cir* 2006; 58: 354 - 358
- [9] Acevedo A, Lombardi J, Leon J, López J, Schultz E, Dellepiane V. Eventraciones. Reconstrucción plástica de la línea alba mediante doble sutura invaginante isotensional (DSII). *Rev Chil Cir*. 2009; 61: 339 - 344
- [10] Acevedo A, Viterbo A, Cápona R, Dellepiane V. Prescindencia de drenaje en la eventrorrafia ambulatoria. *Rev Chil Cir*. 2008; 60: 291 - 296
- [11] Israelsson LA, Smedberg S, Montgomery A, Nordin P, Spangen L. Incisional hernia repair in Sweden 2002. *Hernia* 2006; 10: 256 - 261



Clinical Use of Local Anesthetics

Edited by Dr. Asadolah Saadatniaki

ISBN 978-953-51-0430-8

Hard cover, 102 pages

Publisher InTech

Published online 23, March, 2012

Published in print edition March, 2012

Local anesthetics are being increasingly applied in different surgeries. Lower side effects of neuroaxial anesthesia, regional anesthesia, and field block, in comparison to general anesthesia (volatile and intravenous agents), are the main reasons why physicians prefer to conduct surgeries under local anesthesia, especially in outpatient and day care surgeries. It is important to emphasize the presence of an anesthesiologist, and vigilant monitoring of the hemodynamic parameters, in decreasing a patient's anxiety, exerting other modalities for analgesia and increasing the safety margin in many procedures.

How to reference

In order to correctly reference this scholarly work, feel free to copy and paste the following:

Alberto F. Acevedo (2012). Repair of Incisional Hernias of the Midline Under Local Anesthesia in an Ambulatory Basis, *Clinical Use of Local Anesthetics*, Dr. Asadolah Saadatniaki (Ed.), ISBN: 978-953-51-0430-8, InTech, Available from: <http://www.intechopen.com/books/clinical-use-of-local-anesthetics/incisional-hernias-of-the-midline-ambulatory-surgery-under-local-anesthesia-in->

INTECH
open science | open minds

InTech Europe

University Campus STeP Ri
Slavka Krautzeka 83/A
51000 Rijeka, Croatia
Phone: +385 (51) 770 447
Fax: +385 (51) 686 166
www.intechopen.com

InTech China

Unit 405, Office Block, Hotel Equatorial Shanghai
No.65, Yan An Road (West), Shanghai, 200040, China
中国上海市延安西路65号上海国际贵都大饭店办公楼405单元
Phone: +86-21-62489820
Fax: +86-21-62489821

© 2012 The Author(s). Licensee IntechOpen. This is an open access article distributed under the terms of the [Creative Commons Attribution 3.0 License](#), which permits unrestricted use, distribution, and reproduction in any medium, provided the original work is properly cited.

IntechOpen

IntechOpen