

# We are IntechOpen, the world's leading publisher of Open Access books Built by scientists, for scientists

6,900

Open access books available

185,000

International authors and editors

200M

Downloads

Our authors are among the

154

Countries delivered to

TOP 1%

most cited scientists

12.2%

Contributors from top 500 universities



WEB OF SCIENCE™

Selection of our books indexed in the Book Citation Index  
in Web of Science™ Core Collection (BKCI)

Interested in publishing with us?  
Contact [book.department@intechopen.com](mailto:book.department@intechopen.com)

Numbers displayed above are based on latest data collected.  
For more information visit [www.intechopen.com](http://www.intechopen.com)



# Iatrogenic Complications Following Laser Ablation of Varicose Veins

Carolina Vaz et al.\*

*Department of Angiology and Vascular Surgery, Hospital de Santo António,  
Centro Hospitalar do Porto,  
Portugal*

## 1. Introduction

During the past decade, Endovenous Laser Ablation (EVLA) has been introduced as a minimally invasive alternative to high ligation and open surgical stripping of the incompetent Great Saphenous Vein (GSV) or Short Saphenous Vein (SSV). There is great variability in EVLA protocols and at the present time there is data from more than 60 publications with more than 15000 EVLA treatments reporting good clinical results but also undesired side effects. Post-operative pain in the operated area is rated from slight to moderate by most patients (81, 5%), post-operative induration of the truncal vein can be expected in 78, 1% of patients and perivenous ecchymosis and hematoma are observed in an average of 52% of patients. Further complications such as persistent dysesthesia after nerve lesions (0, 8%) and burns on the skin (0, 2%) are reported in a minority of cases. Great care must be taken to ensure adequate tumescent anesthesia and light dosimetry in order to avoid post-operative paresthesia.

Thrombus propagation to the deep venous system (0, 2%) or pulmonary embolism (0, 02%) are seldom observed. Careful sonographic examination of the sapheno-femoral or sapheno - popliteal junctions is required during the procedure. Inappropriate energy densities can lead to side effects such as transmural ablations, perforations and alteration in perivenous tissue. So far it has not been possible to establish general valid recommendations for appropriate energy density nevertheless it seems clear that the use of laser systems with longer wavelengths will lead to a reduction of undesired tissue side effects.

## 2. Endovenous laser therapy

The first application of endoluminal laser was described by Bone in 1999 (Bone, 1999). EVLA received Food and Drug Administration approval in January 2002 and acts through a mechanism of nontrombotic venous occlusion of the target vein through the delivery of laser energy into the vein lumen via a laser fiber. Laser (light amplification by stimulated emission of radiation) creates high-energy bundled light that is monochromatic (of a unique wavelength) and releases direct thermal energy that heats both the blood and

---

\* Arlindo Matos, Maria do Sameiro C. Pereira, Clara Nogueira, Tiago Loureiro, Luís Loureiro, Diogo Silveira and Rui de Almeida

adjacent vein wall (Van den Bos et al. 2008). The tip fiber reaches temperatures in the region of 800°C. This results in destruction of the intima, collagen denaturation of the media and eventually fibrotic occlusion of the vein. Lasers with wavelengths of 810, 940, 980 (haemoglobin specific) and 1319, 1320 and 1470 nm (water specific) have been successfully used. The light of these wavelengths are not visible to the human eye and for orientation purposes, visible light is additionally emitted as a pilot beam. In the last ten years EVLA has evolved into an accepted option for the treatment of underlying truncal vein reflux causing varicose veins.

## 2.1 Preoperative duplex imaging

Duplex ultrasound has become the reference standard in assessing the morphology and hemodynamics of the lower limb veins. Preoperative duplex planning for EVLA is extremely important in order to avoid potential complications. Almost all modern ultrasound scanners used for imaging peripheral venous disease should be suitable for preoperative imaging and for guiding endovenous procedures. Typically linear array transducers with a frequency in the range of 5-12 MHz are suitable. During this examination it is important to evaluate the anatomy and the physiology of both the superficial and deep venous systems. EVLA is a good treatment option for eliminating reflux in a straight superficial venous segment. Indications for ablation include reflux in a truncal vein of a duration greater than 0,5 seconds, that is responsible for patient symptoms or skin changes. Measurement of the vein diameter should be carried out during the course of pre-operative ultrasound for the calculation of the appropriate energy density. The duplex ultrasound inclusion criteria for this treatment are: veins with a 2mm or more diameter but preferably with 3mm or more and a treatable length of at least 10-12 cm. The course of the saphenous vein, from the saphenofemoral or saphenopopliteal junction to the insertion site is mapped by ultrasound. An indelible marking pen is used to mark incompetent sources of venous reflux under duplex ultrasound guidance before the procedure (figure 1).

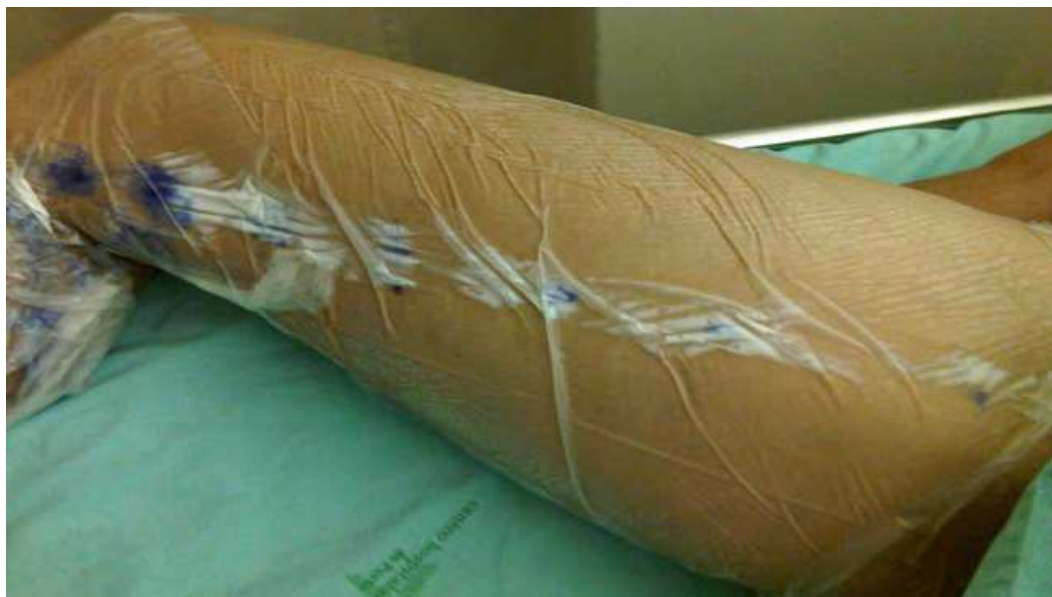

Fig. 1. Pre-operative marking of the vein, topic anesthetic on the length of the vein being treated

Veins with acute thrombophlebitis or partially obstructed saphenous vein on the duplex examination are exclusion criteria for this kind of treatment. Patients with ropy varicose veins located immediately under the skin or those with aneurismal dilations of the sapheno-femoral junction are probably better served with conventional surgery (Gloviczki et al 2011). The use of EVLA to close incompetent perforating veins has been described. At this point, the indications and contraindications, as well as the success rates and safety of this approach have only recently begun to be evaluated (Proebstle et al 2009). The use of EVLA to directly close surface varicose veins is not encouraged. These veins are usually too tortuous for current generation devices to pass through. Also these veins are very superficial; EVLA of these veins carries a high risk of thermal skin injury.

## 2.2 The procedure

EVLA begins with ultrasound evaluation and disinfection of the skin. The area to be operated on is covered with sterile dressings. The groin area has to be accessible as a sonographic examination of the sapheno-femoral junction is required. In addition, an intra-operative switch to conventional open surgery with high ligation and stripping must be possible if necessary. The patient is placed in the reverse Trendelenburg position and an insertion site is chosen to maximize the treatment length. For GSV, this is around the knee level where the vein is usually superficial, the portion below the knee being in close proximity to the saphenous nerve carrying an increased risk of paresthesia from the puncture or thermal nerve injury by the laser energy delivered.

After infiltration with local anesthetic at the insertion site, an introducer needle is inserted into the vein or a small incision is made and the vein is elevated with a phlebotomy hook. Although efficient this second approach is not preferred because of the increased risk of trauma or venospasm. A microguidewire is inserted into the vein, followed by the placement of a 4F microsheath. With the help of a floppy guidewire, the sheath is exchanged for a 5F sheath. The wire is advanced so it that runs across the SFJ, always with ultrasound guidance. It is not uncommon for the wire to loop, especially in dilated areas of the vein. The laser fiber is then introduced through the sheath into the GSV or SSV and advanced proximally to the SFJ or SPJ. The fiber tip extends proximally 1-2 cm beyond the end of the sheath, and its position should be marked. This is important since the fiber tip can be heated up to several hundred degrees Celsius during the procedure and if there is no sufficient distance between them, this can lead to the melting of the sheath material. To treat reflux of the GSV beginning at the SFJ, the device is generally positioned just below the junction of a competent *epigastric vein*. Theoretically this preserves flow at the junction and prevents thrombus from extending upwards. For SSV ablation, the tip of the device is positioned just beyond the take-off point of a gastrocnemius vein. If this vein is not identified by ultrasound evaluation, ablation generally begins at the cephalic end of the intrafascial SSV before it passes below the muscular fascia.

Once the device is appropriately placed for ablation, the patient is placed in Trendelenburg position to facilitate vein emptying and perivenous tumescent anesthesia is then delivered. Optimal delivery of this fluid into the saphenous space is accomplished with real time duplex ultrasound examination. The tumescence has four main goals; firstly it provides cooling and offers some perivascular tissue protection against heating or burns. Secondly it provides pain relief. Thirdly, the vein tends to collapse, removing blood and improving surface contact between the laser and the vein wall and finally it will ensure that there is at

least 1 cm between the vein and the skin surface to avoid skin burns. Once the vein is surrounded by tumescence, the position of the laser tip must be rechecked to ensure it has not been accidentally displaced. The thermal energy is then delivery using protocols inherent to each device (Table 1). Currently 50 to 80 J/cm is the average treatment energy most often used for EVLA procedures.

Laser Generators	Wavelength	Recommended Pullback
<i>Diomed</i>	810 nm	1 cm every 3-5 seconds
<i>Varilaser</i>	810 nm	50-70 J/cm
<i>Dornier</i>	940 nm	1 cm every 3-5 seconds
<i>AngioDynamics</i>	980 nm	50-80 J/cm
<i>Sciton</i>	1319 nm	Unknown
<i>Cool Touch</i>	1320 nm	Automated fiber pullback device at 1 mm/second
<i>Biolitec</i>	1470 nm	UnKnown

Table 1. Endolaser Ablation Devices

The goal is to achieve successful ablation while at the same time minimizing the incidence of postoperative pain and bruising.

Ultrasound should be used to follow the catheter pullback, the energy supplied to the laser tip also heats the surrounding blood and this can be clearly seen as echogenic areas.

At the end of the procedure, ultrasound can then be used to ensure the patency of the common femoral vein, and to confirm successful obliteration of the saphenous vein. Its lumen is usually reduced and filled with strongly echoing thrombus material.

If a patent segment is identified, re-treatment is advisable.

Ancillary ambulatory phlebectomy or sclerotherapy may be performed immediately after the EVLA procedure or several weeks later to treat any residual branch varicose veins (figure 2).

2.3 Post-procedural care

The entry site is covered with a SteryStrip bandage as well as the phlebectomy sites, if performed. Graduated compression stockings with an ankle pressure of 30-40 mmHg or an elastic wrap is placed on the limb at the end of the procedure and should be kept at least one week after the procedure. (Figure 3)

Immediately following EVLA, patients are instructed to ambulate regularly to promote the vessel occlusion process and decrease the incidence of deep venous thrombosis (DVT). But vigorous exercise is generally discouraged for the first week.

There is no convincing data to support the routine use of anticoagulants with EVLA. Selected patients with a history of thrombophlebitis, DVT, or obesity are candidates for thrombosis prophylaxis (Geerts et al 2008). In Europe the use of a short course of post procedural prophylactic dose of low molecular weight heparin is common (Proebstle 2003). The complication rate following its use does not seem substantially increased.



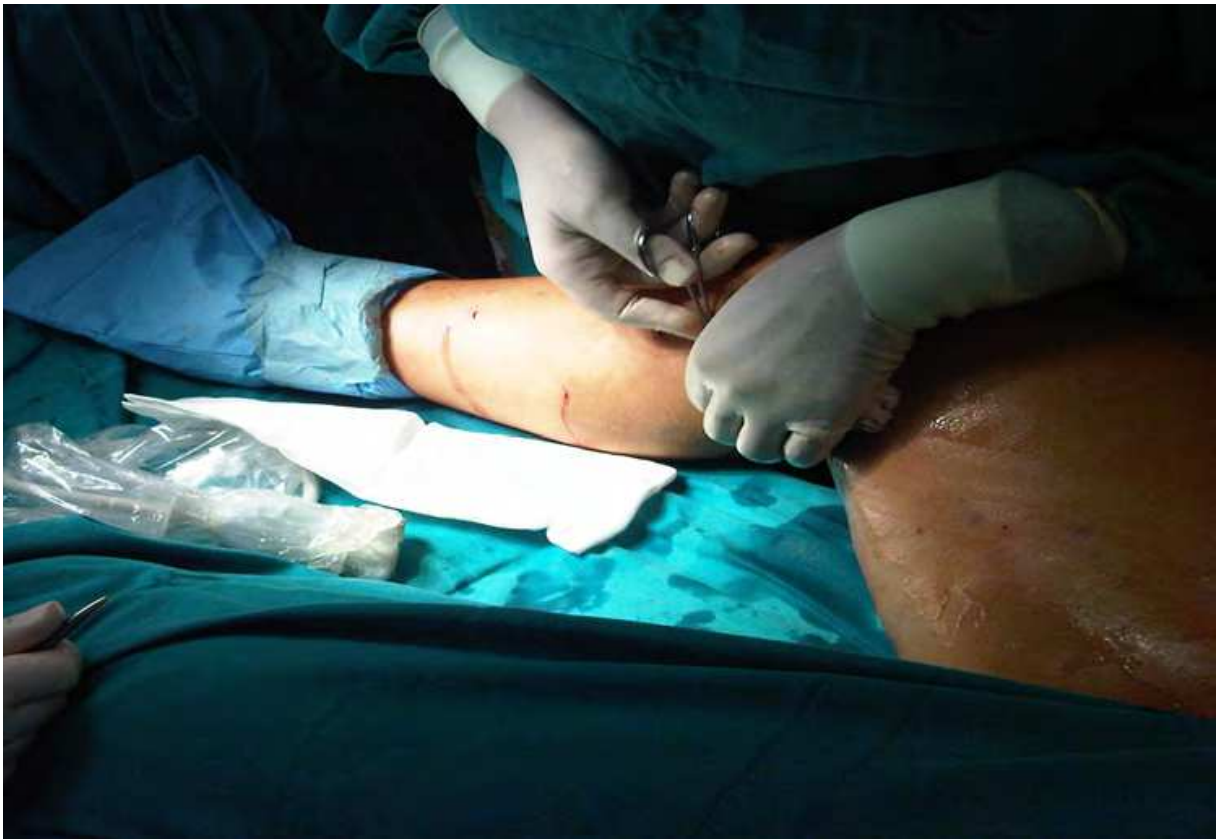

Fig. 2. Ancillary ambulatory phlebectomy performed immediately after the EVLA procedure

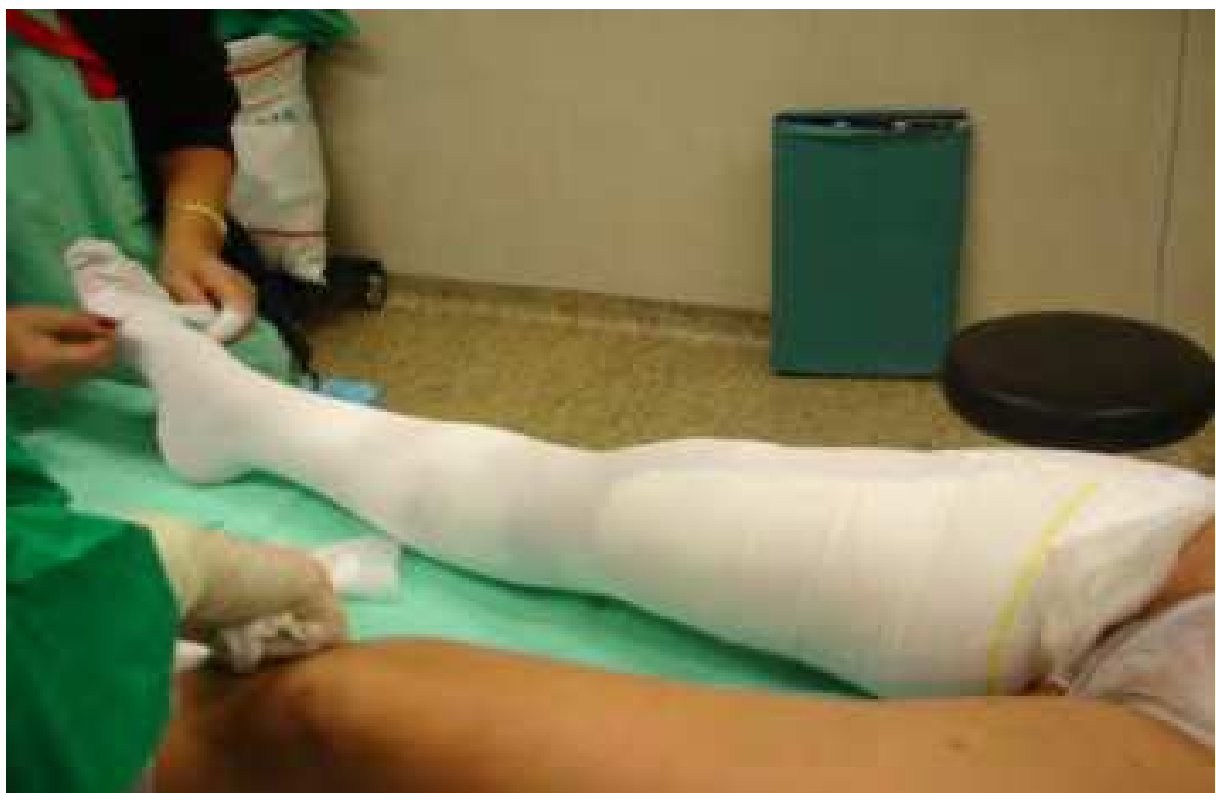

Fig. 3. Graduated compression stockings placed at the end of the procedure

Some patients will experience mild discomfort over the treated vein, beginning a few hours after the procedure that usually resolves in 24 to 48 hours and a nonsteroidal anti-inflammatory drug may be taken daily as needed.

## 2.4 Follow - up

Clinical success after EVLA is defined as permanent occlusion of the treated vein segments with improvement in clinical symptomatology. Patients should return for periodic clinical and duplex ultrasound evaluation to confirm vein closure and exclude early complications. At minimum, patients should be examined at 1 week, 6 months and one year following laser ablation of the saphenous vein. But if a physician is trying to identify thrombus extension across the SPJ or SFJ, duplex ultrasound in the first 72 hours after EVLA should be performed.

The natural history of a successfully treated truncal vein includes acute vein wall thickening without significant intraluminal thrombus in the first weeks after treatment followed over the next months by progressive vein shrinkage and eventual disappearance on ultrasound examination (Min et al 2003). This venous contraction, produces a delayed (4 to 6 weeks after the procedure) sensation described by the patient as "pulling". This pain is most likely secondary to venous fibrosis as the treated vein undergoes permanent closure. Follow up duplex will no longer be needed when the treated vein is no longer visible.

Additional periodic follow up may be necessary to evaluate the aetiology of any new tributary varicosities to determine whether they are related to a recurrence of reflux in the treated vein segment or progression of the disease in a different venous pathway.

## 3. Clinical outcomes

Success rates with EVLA of the GSV have generally been reported between 72% and 100%, and the follow up for these evaluations varies from 3 months to 4 years. Currently there is data from more than 60 publications with altogether more than 15000 EVLA treatments available. With the appropriate selection of patients, EVLA treatment can technically be carried out in more than 99 % of the patients. (Elmore, 2008)

In a large single center, Myers and Jolley treated 509 limbs with an 810 nm laser during a 5 year period. The rate of primary occlusion at 4 years was 76% and the secondary occlusion rate was 97%. (Myers et al 2009). A systematic review of EVLA for varicose veins by Mundy et al found an early saphenous occlusion rate of 88% to 100%. (Mundy et al 2005).

There is fewer data for the SSV but the published results are qualitatively similar. Proebstle et al observed a 100% occlusion rate at 6 months by using 940 nm diode laser to treat SSV in 41 patients. (Proebstle et al 2008). In a prospective cohort study, Huisman et al treated the SSV in 169 limbs with an 810 nm diode laser. The treated length averaged 23 cm (range 6 - 53 cm). Occlusion of the SSV after 3 months was achieved in 98%. (Huisman et al 2009)

It has been reported that most incompletely ablated veins will develop reflux recurrence in the first few months following treatment.

Most EVLA recanalizations occur in the first 6 months, and all occurred in the first 12 months. This has been interpreted as suggesting that recanalization may be related to insufficient thermal energy delivered to the segment of the vein being treated.

On the majority of the cases the 1-2 cm proximal segment of the vein below the SFJ or the SPJ remains patent. Inferior success rates of closure of this proximal vein segment may be related to an increased likelihood of insufficient thermal transfer to this portion that is usually of larger caliber than the remaining vein, more difficult to empty, and less likely to develop spasm during tumescent anaesthetic administration. As a result, it is difficult to obtain device and vein wall apposition in this segment.

There is a correlation between the amount of thermal energy delivered and the occlusion rate. Energy deposition has been described as the amount of energy delivered per centimetre of vein length (J/cm). Durable vein occlusion was demonstrated as more likely when the energy applied was a mean of 80 J/cm. (Sadick et al 2004).

As previously said successfully treated veins have been demonstrated to occlude and shrink with time. The average mean duration for a treated GSV to shrink to a fibrous cord of less than 2,5 mm diameter is 6 months. (Yang Ch 2006).

Late clinical recurrence is extremely unlikely in an occluded vein that has shrunk to a non compressible cord. Based on this and on surgical data that demonstrates that the pathologic events that lead to recurrence usually take place within 2 years, later clinical recurrences are more likely related to development of incompetence in untreated veins. It seems that late clinical success after EVLA is predicted by the natural history of the venous insufficiency and the ability of the physician to identify and eliminate all incompetent pathways.

Comparing two wavelengths of delivered laser energy (940 nm and 1320 nm) in a retrospective analysis, showed equivalent occlusion rates, when used at similar rates of energy deposition. (Proebstle 2005)

Several studies have documented significant and durable improvements in validated assessments of Quality of Life (QOL) following EVLA. Some studies demonstrated significant improvements in the Aberdeen Varicose Veins Questionnaire (AVVQ) as long as 6 months following laser ablation. (Mekako et al 2006); (Rasmussen et al 2007)

Ulcer healing has been reported after EVLA. One report documented an 84% success in ulcer healing with a combination of EVLA and microphlebectomy, with 77% of these healings occurring within 2 weeks after the procedure (Ravi et al 2006).

Several studies have reported that EVLA is more effective than venous stripping and other endovenous procedures in terms of obliteration and lower recurrence rates in the range of 1 to 5%. (Bos et al 2009) It is also important to mention that cosmetic results are in the majority of the cases very good when compared with high ligation and stripping.

As with as other treatment options for superficial venous insufficiency, EVLA treatments and indications are in constant evolution. Neglen et al, demonstrated good outcomes combining laser ablation with deep vein stenting for superficial venous insufficiency and concomitant deep vein obstruction. (Neglen et al 2006)



As above indicated EVLA for the treatment of venous superficial reflux is an efficient treatment option.

4. Complications

Complications after EVLA may be divided into early and late complications (Table 2 and 3). The most serious potential complication involves misidentification of the anatomy with duplex ultrasound leading to the placement of the tip in a wrong position or even in a deep vein.

Complications	
Early Complications	Vessel Perforation
	Vein Spasm
	Vein Trombosis
	Excessive Pain
	Skin Burns
	Hematoma
	Hemorrhage
	Irradiation of Nontarget tissue
	Thromboplhebitis
	Deep vein Thrombosis
	Pulmonary Embolism
	Arteriovenous fistula

Table 2. Early complications of EVLA Procedure

Complications	
Late Complications	Recanalization of the Vein
	Skin Necrosis
	Paresthesia
	Infection

Table 3. Late complications of EVLA Procedure

In an international endovascular working group registry that included 3696 procedures, bruising after EVLA was observed in 75% of the cases, paresthesia in 3%, thrombophlebitis in 1,87%, skin burns in 0,46% and DVT in 0,27% and there is a single report of pulmonary embolism (Kabnick et al 2006). But in majority of the series reported in the literature the complication rates are variable (Table 4).

Study	Number of veins treated	Complication Rate
Navarro et al	40	Any
Proebstle et al	41	6% thrombophlebitis
Chang and Chua	252	1,6% thrombophlebitis 36,5% paresthesia 4,8% skin burn
Timperman et al	111	1% deep vein thrombosis 1% skin burn
Huang et al	230	1% skin burn 7% paresthesia
Vuylsteke et al	118	4% skin burn 14% paresthesia
Almeida and Raines	819	0,2% deep vein thrombosis 0,2% paresthesia 2% thrombophlebitis
Min et al	121	Any
Meyers et al	404	0,2% severe pain

Table 4. Complications after EVLA reported in the literature

Ecchymosis (Figure 4) over the treated segment frequently occurs and normally can last approximately ten days. The mechanism of the EVLA procedure that causes ecchymosis remains unclear, although some experts speculate that these complications are due to perforation of the vein wall by laser energy.

Superficial phlebitis is another uncommon side effect that is reported in approximately 5% of procedures (Min 2003). The major complications more frequently reported are neurologic injuries, skin burns and DVT. But the overall rate of these complications has been shown to be higher in low volume hospitals compared with high – volume hospitals. The nerves at highest risk include the saphenous nerve, adjacent to the GSV below the Knee and the Sural nerve adjacent to the SSV, but both of these nerves have only sensory components, and the most common manifestation of nerve injury is paresthesia or dyesthesia, which is often transient (Rutherford 2010). The nerve injury can occur with sheath and catheter introduction, during the delivery of tumescent anaesthesia, or by direct thermal injury. The rates of permanent paresthesias typically reported for laser are approximately 0-10% for GSV treatment. Only a few series look at the SSV nerve injuries and the reported rates of temporary paresthesia following SSV EVLA are 0-10% in some series. It is reported that the rate of paresthesia is inversely related to the operator experience with perivenous ultrasound –guided anesthesia( Morrison et al 2011). It has also been suggested that greater volumes of tumescence may be required during ablation of the SSV to prevent any thermal injury to the sural nerve which is in close proximity to the vein.

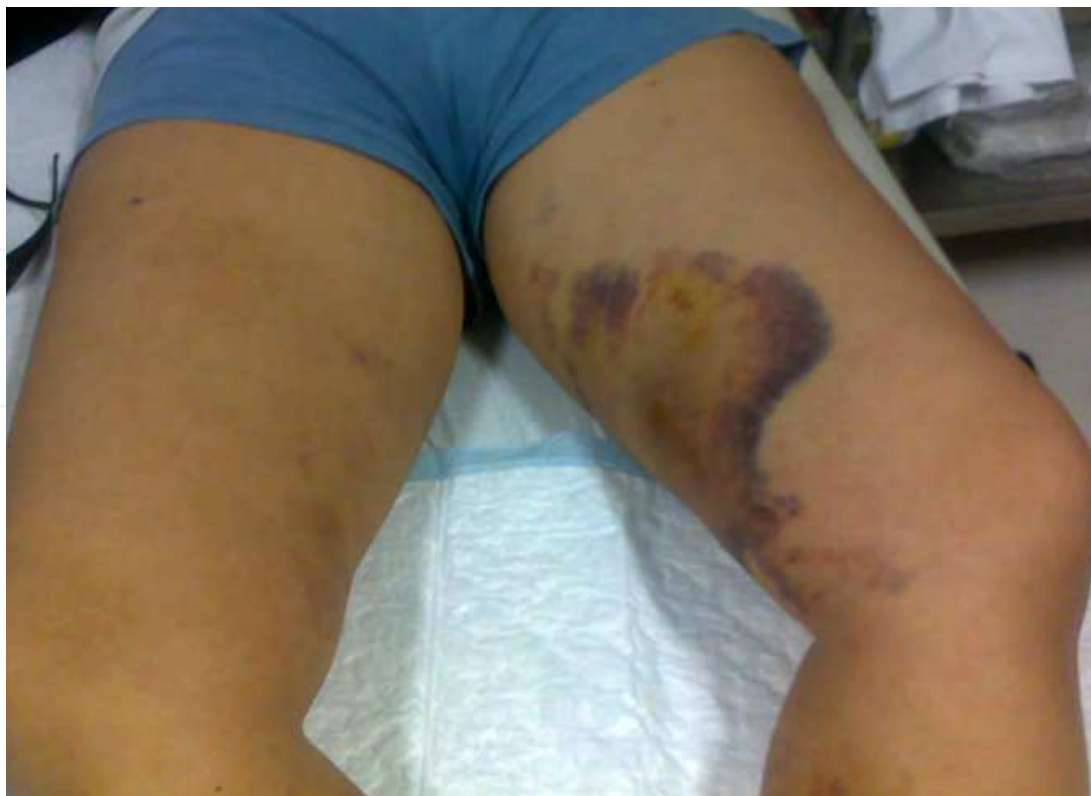

Fig. 4. Ecchymosis on the left lower limb after a bilateral EVLA procedure

Skin burns following EVLA have been reported but are relatively rare and seem avoidable with adequate tumescent anesthesia.

DVT following EVLA is unusual and can occur as an extension of thrombus formation from the treated truncal vein across the junctional connection into the deep vein or in the calf or femoral popliteal veins. The reported rates of junctional thrombosis following GSV EVLA are variable. This variability may relate to the ultrasound duplex timing after the EVLA procedure. Most series using early duplex ultrasound document a proximal thrombus extension of approximately 1% and those performing the ultrasound duplex later (after 72 hours) identify a lower rate. But it is also possible that this different thrombus propagation rates are variable because the ultrasound is performed by different operators. Data from different series suggests that the incidence of DVT is approximately of 0,3% after laser ablation. But this type of DVT is almost universally asymptomatic. The significance of this type of thrombus extension into the femoral vein seems to be different from the native deep vein thrombosis (Kabnick et al 2006). But treatment should be started immediately usually in an outpatient basis with compression, ambulation, anti - inflammatory medication and anticoagulation. A close follow up evaluation with ultrasound should be performed. Reports in the literature based on careful follow up evaluation of these thrombo extensions concluded that they retract over the course of 7-10 days and none produced clinical symptoms suggestive of pulmonary embolus. (Morrison et al 2011). The incidence of junctional extension of thrombus after SSV ablation has been described to be inferior to 6 % (Ravi et al 2006). In a particular study the rate of popliteal extension of SSV thrombus after EVLA was thought to be related to the anatomy of the SPJ (sapheno-popliteal junction) (Gibson et al 2007). The incidence of DVT in other peripheral deep veins after EVLA has not been well evaluated.

There are some case reports in the literature of an arteriovenous fistula between a small popliteal artery branch and the SSV (Vaz et al 2008). Although thought to be related to a heat induced injury caused by thermal energy from the laser device, an arteriovenous fistula could be caused by a needle injury during tumescent anaesthetic administration. To minimize the risk of these arteriovenous fistulas is necessary a careful advancement of the intravascular devices, atraumatic delivery of the tumescent fluid, the use of adequate amounts of tumescent fluid and the subfascial portion of the SSV where the popliteal artery branches exist, should be avoided. (figure 5).

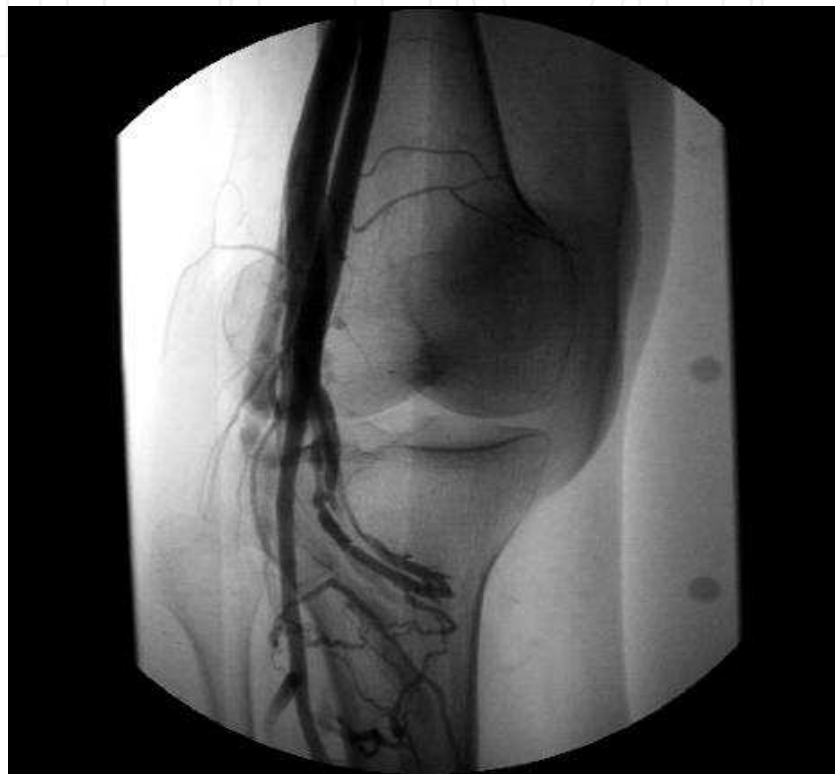

Fig. 5. Popliteal stage arteriography depicting an AV fistula between branches of the popliteal artery and a genicular vein after an EVLA procedure.

If there is evidence of a perivenous structure (artery or nerve) that is impossible to isolate from the vein by the tumescent anesthesia, probably skipping this venous segment and use a combination of concomitant therapies would be a more prudent choice( Perrin et al 2007).

During the procedure, adverse patient events may occur, which are rarely reported. A transient vagal reaction is often described secondary to the patient's anxiety, there are some reports of dysrhythmia and transient pain due to inadequate anesthetic infiltration.

Infection is extremely rare, but there is one case report of septic thrombophlebitis following an EVLA procedure requiring surgical intervention (Dunst et al 2006).

Neovascularization has been reported only in one case on the literature three years after the EVLA procedure (Morrison et al 2011). The endovenous laser ablation procedure deliberately leaves the superficial epigastric vein intact, which, it is believed, has contributed

to the lack of neovascularisation reported so far. More case reports are necessary to establish a mechanism of this type of neovascularisation after an EVLA procedure.

Laser fracture or retained venous access sheaths have been reported on the literature (Ravi et al 2007). Caution in handling the laser should help to minimize these situations, and the possibility of a laser fracture should always be considered with the removal of the device. Care to deliver thermal energy only beyond the introducer is essential to avoid damage of some segments of these catheters.

Some evidence suggests that higher wavelength lasers produce less pain and bruising as well as minimize other types of complications; however a large scale study evaluating all wavelengths available is needed to confirm these initial findings.

A new adaptation of the laser fibbers has emerged, that appears to have some beneficial effect on the vein wall perforation, the jacket tipped fibers. This newly advance constitutes on a stainless steel or a ceramic jacket that completely covers the tip of the fiber, with the end of the tip being recessed within the jacket, thus preventing the tip contact with the vein wall. One study has been described on the literature comparing the efficacy and the complications of jacket tipped fibers versus bare tipped fibers. At 72 hours after the procedure, both groups demonstrated 100% success treatment and in the jacket tipped group pain and ecchymoses scores appeared to be lower.

## 5. Discussion

Endovascular techniques have been introduced as minimally invasive alternatives to high ligation and open surgical stripping of the incompetent GSV or SSV. The Endovenous laser therapy has established itself in the last few years among the range of endovascular therapy options for the treatment of truncal vein insufficiency. Nevertheless the significance of this reflux in itself still remains a matter of debate. A duplex ultrasound detected reflux should not be in itself an indication for treatment. We think that EVLA, as well as other treatment modalities, is only indicated in patients with clear symptoms and clinical signs of chronic venous insufficiency (varicose veins, skin changes or ulcer).

Studies looking specifically at the success and complication rates associated with laser ablation are extensively being reported. But the effects of laser on tissue, and therefore on clinical results, are clearly very variable because of the use of different wavelengths, different pull back protocols and different energy densities and so EVLA can hardly be standardized. Mechanisms to determine the accurate energy density to be used in EVLA are lacking. This makes the appropriate dosage of light for the sufficient thermal alteration of tissue harder to achieve. In addition to transmural damage, wall perforation is being reported with great variability in most of the series.

In order to eliminate these disadvantages and create endothermal occlusion more effectively and in a more reproducible fashion, EVLA continues to find itself in a dynamic process of development. Treatment planning, technical details and postprocedural care is of paramount importance to this procedure and to the operator. Every patient undergoing endovenous procedures should do an early post-operative duplex scan to rule out major complications (Perrin et al 2007). The learning curve in EVLA treatment of the SSV is still going up, and further experience and research with this modality will better delineate its risks, complications and long term efficacy.



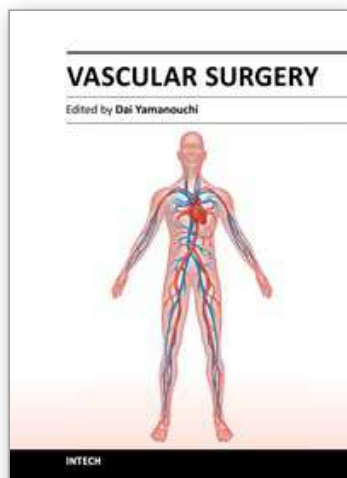
## 6. Conclusion

The Endovascular technology has transformed the evaluation and treatment of venous disease during the past decade. As with any new technique, there is a learning curve in terms of patient selection and the different steps of the procedure itself. Once mastered it seems that EVLA can safely eradicate GSV and SSV reflux with a low rate of minor complications and a lower rate of major complications.

## 7. References

- Almeida J, Raines J et al (2006) *Radiofrequency ablation and laser ablation in the treatment of varicose veins*, *Ann Vasc Surgery*, 20 :547-52
- Bone, C. (1999). *Tratamiento endoluminal de las varices con laser de Diodo. Estudio preliminary*, *Review Patology vascular*, 5, 35-46
- Bos, RVD, Arends L et al (2009) *Endovenous therapies of lower extremity varicosities are at least as effective as surgical stripping or foam sclerotherapy : meta – analysis and meta – regression of case series and randomized clinical trails*, *Journal of vascular Surgery*, 49 :230-239
- Chang CJ, Chua JJ et al, (2002) *Endovenous laser photocoagulation (EVLP) for varicose veins*. *Laser Surg Med* 31 :257-62
- Dunst K, Huemer G et al.(2006) *Diffuse phlegmonous phlebitis after endovenous laser treatment of the greater saphenous vein*. *J Vasc Surg* 43 : 1056-8
- Elmore FA, Lackey D,(2008) *Effectiveness of endovenous laser treatment in eliminating superficial venous reflux*, *Phlebology* 23 :21-31
- Gibson Kd, Ferris Bl et al, (2007), *Endovenous laser treatment of the short saphenous vein : efficacy and complications*, *J Vasc Surg* 45 :795-801
- Geerts, Wh, Bergqvist D, et al,(2008) *Prevention of venous Thromboembolism : American College of Chest Physicians Evidence – based Clinical Practice Guidelines*. *Chest* ; 133 :381-453s
- Gloviczki et al (2011), *The care of patients with varicose veins and associated chronic venous diseases : Clinical practice guidelines of the society for vascular Surgery and the American venous Forum*, *Journal of Vascular Surgery*, 53 :16s 2-27
- Huang Y, Jiang M et al.( 2005) *Endovenous laser treatment combined with a surgical strategy for treatment of venous insufficiency in lower extremity : a report of 208 cases*, *J Vasc Surg* 42 :494-501
- Huisman LC, Bruins Rm et al ( 2009), *Endovenous laser ablation of the small saphenous vein : prospective analysis of 150 patients, a cohort study*. *Euro J vasc Endovasc Surg* 38 : 199-202
- Kabnick LS, Ombrellino M et al, (2006) *Endovenous heat induced thrombus ( EHIT) at the superficial deep venous junction : a new post-treatment clinical entity, classification and patient treatment strategies*. Presented at the American Venous Forum 18 th Annual Meeting February 23
- Kabnick LS. (2006) *Complications of endovenous therapies : statistics and treatment*. *Vascular*, 14 ( suppl1) : S31-2
- Mekako AI, HattfieldJ, et al (2006), *A nonrandomized controlled trial of endovenous laser therapy and surgery in the treatment of varicose veins*, *Annals of Vascular Surgery* ;20 :451-457
- Min Rj, Khilnani NM et al (2003), *Duplex ultrasound evaluation of lower extremity venous insufficiency*, *Journal of Vascular Intervention Radiology*, 14 :1233 – 1241
- Min Rj, Khilnani NM et al (2003), *Endovenous laser treatment of saphenous vein reflux : Long term results* *J Vasc Interv Radiology*, 14 : 991-6
- Myers K, Fris R et al (2006) *Treatment of Varicose veins by endovenous laser therapy : assessment of results by ultrasound surveillance*, *Med J Aust* 85 :199-202

- Myers KA, Jolley D. (2009) *Outcome of endovenous laser Therapy for saphenous reflux and varicose veins : medium – term results assessed by ultrasound surveillance*, Eur J Vasc Endovasc Surg 37 :239-45
- Mundy L, Merlin TL et al (2005), *Systematic review of endovenous laser treatment for varicose veins*, Br J Surg 92 : 1189-94
- Navarro L, Min R, et al.(2001) *Endovenous laser : a new minimally invasive method of treatment for varicose veins – preliminary observations using an 810 nm diode laser*. Dermatology Surgery 27 :118-22
- Neglén P, Hollis K et al,(2006) *Combined saphenous ablation and iliac sten placement for complex severe chronic venous disease*, J Vasc Surg 44 :828-33
- M.Perrin (2007) *Traitement Chirurgical endovasculaire des varices des membrers inférieurs. Techniques et resultants*. EMC, Techniques chirurgicales – Chirurgie vasculaire, 43-161
- Proebstle TM, Gul D et al, (2003), *Endovenous laser treatment of the lesser saphenous vein with a 940 – nm diode laser :early results*. Dermatology Surgery 29 :357-61
- Proebstle TM, Gul D et al, (2003), *Infrequent early recanalization of greater saphenous vein after endovenous laser Treatment*, Journal of vascular surgery, 38 :511-516
- Proebstle TM, Moehler T et al (2005), *Endovenous treatment of the great saphenous vein using a 1,320nm Nd : yag laser causes fewer side effects than using a 940 nm diode laser*, Dermatology Surgery, 31 :1678-1683
- Proebstle TM, Vago B et al (2008), *Threatment of the incompetent great saphenous vein by endovenous radiofrequency powered segmental thermal ablation : first clinical experience*, J Vasc Surg, 47 :151-6
- Proebstle, Thomas M. (2009), *Handbook of venous Disorders, Guidelines of the American Venous Forum*, pp-390-398, Hodder Arnold(Ed)
- Ravi R, Rodriguez – Lopez JA et al (2006) *Endovenous Ablation of incompetent saphenous veins : a large single center experience*. J Endovascular Therapy 13 : 244-248
- Ravi R,Bhutani A et al(2007) *No sheath left behind*, J Endovasc Ther, 14 :265-267
- Rasmussen LH, Bjoern L, Lawaetz et al, (2007), *Randomized trial comparing endovenous laser ablation of the great saphenous vein with high ligation and stripping in patients with varicose veins : short term results*, Journal of Vascular Surgery ; 46 :308-315
- Rutherford (2010). *Rutherford's Vascular Surgery*, Sauders Elsevier, ISBN 871-888, Philadelphia, USA
- Sadick Ns, Waser S. (2004) *Combined endovascular laser with ambulatory phlebectomy for threatment of superficial venous incompetence : a 2 – Year perspective*. J Cosmet Laser Therapy, 24 :149-153
- Timperman P, Sichlau M et al(2004) *Greater energy delivery improves treatment sucess of endovenous laser treatment of incompetent saphenous veins*. J Vasc Interv Radiol 15 :1061-3
- Van den Bos R, Kockaert M, Neumann H et al (2008) *Technical review of endovenous laser Therapy for varicose veins*. European Jounal of vascular and Endovascular Surgery 35 : 88-95
- Vaz C, Matos A. et al (2009), *Iatrogenic arteriovenous Fistula following endovenous laser therapy of the short saphenous vein*, Annals of Vascular Surgery, 412
- Vuylsteke M, Van den Bussche D et al (2006) *Endovenous Laser obliteration for the treatment of primary varicose veins*. Phlebology 21 : 80-7
- Yang CH, Chou HS et al (2006) *Incompetent great saphenous Veins treated with endovenous 1,320 nm laser: results for 71 legs and morphologic evolvement study*. Dermatology Surgery; 32:1453 - 1457



## **Vascular Surgery**

Edited by Dr. Dai Yamanouchi

ISBN 978-953-51-0328-8

Hard cover, 262 pages

**Publisher** InTech

**Published online** 04, April, 2012

**Published in print edition** April, 2012

This book aims to provide a brief overview of conventional open vascular surgery, endovascular surgery and pre- and post-operative management of vascular patients. The collections of contributions from outstanding vascular surgeons and scientists from around the world present detailed and precious information about the important topics of the current vascular surgery practice and research. I hope this book will be used worldwide by young vascular surgeons and medical students enhancing their knowledge and stimulating the advancement of this field.

### **How to reference**

In order to correctly reference this scholarly work, feel free to copy and paste the following:

Carolina Vaz, Arlindo Matos, Maria do Sameiro C. Pereira, Clara Nogueira, Tiago Loureiro, Luís Loureiro, Diogo Silveira and Rui de Almeida (2012). Iatrogenic Complications Following Laser Ablation of Varicose Veins, Vascular Surgery, Dr. Dai Yamanouchi (Ed.), ISBN: 978-953-51-0328-8, InTech, Available from: <http://www.intechopen.com/books/vascular-surgery/iatrogenic-complications-following-laser-ablation-of-varicose-veins->

**INTech**  
open science | open minds

### **InTech Europe**

University Campus STeP Ri  
Slavka Krautzeka 83/A  
51000 Rijeka, Croatia  
Phone: +385 (51) 770 447  
Fax: +385 (51) 686 166  
[www.intechopen.com](http://www.intechopen.com)

### **InTech China**

Unit 405, Office Block, Hotel Equatorial Shanghai  
No.65, Yan An Road (West), Shanghai, 200040, China  
中国上海市延安西路65号上海国际贵都大饭店办公楼405单元  
Phone: +86-21-62489820  
Fax: +86-21-62489821

© 2012 The Author(s). Licensee IntechOpen. This is an open access article distributed under the terms of the [Creative Commons Attribution 3.0 License](https://creativecommons.org/licenses/by/3.0/), which permits unrestricted use, distribution, and reproduction in any medium, provided the original work is properly cited.

IntechOpen

IntechOpen