

We are IntechOpen, the world's leading publisher of Open Access books Built by scientists, for scientists

6,900

Open access books available

186,000

International authors and editors

200M

Downloads

Our authors are among the

154

Countries delivered to

TOP 1%

most cited scientists

12.2%

Contributors from top 500 universities



WEB OF SCIENCE™

Selection of our books indexed in the Book Citation Index
in Web of Science™ Core Collection (BKCI)

Interested in publishing with us?
Contact book.department@intechopen.com

Numbers displayed above are based on latest data collected.
For more information visit www.intechopen.com



Decompressive Craniectomy: Surgical Indications, Clinical Considerations and Rationale

Dare Adewumi and Austin Colohan
Loma Linda University Medical Center Department of Neurosurgery
Loma Linda
USA

"If there's no CSF pressure, but brain pressure exists, then pressure relief must be achieved by opening the skull" -Kocher 1901

1. Introduction

The management of increased intracranial pressure is a common clinical scenario encountered in a large portion of medicine. It is encountered more often in the practices of trauma, neurology and neurological surgery and as such is very common in intensive care settings. Treatment approaches remain one of the more controversial fields in medicine. In this chapter we will address the treatment approaches for elevated intracranial pressure. Indications for assessment, clinical considerations and approaches to proper management of elevated pressures focusing mainly on the decompressive craniectomy. We will address the role of the decompressive craniectomy in trauma stroke and address the option of lumbar drainage.

2. Intracranial pressure

Intracranial pressure is defined as the pressure within the cerebral vault that the systemic perfusion must overcome in order to adequately perfuse the brain. A mathematical expression of this relationship is that of CPP (Cerebral Perfusion Pressure) = MAP (Mean Arterial Pressure) - ICP (Intracranial Pressure). This relationship predicts that under settings where intracranial pressure approaches or surpasses mean arterial pressure the perfusion pressure declines resulting in hypoxic brain injury. The Monro-Kellie doctrine is often highlighted in illustrations of intracranial pressure. It holds that the adult cranial vault is a rigid structure composed of brain parenchyma, cerebrospinal fluid, and blood. The cranial vault being a rigid bony structure offers very little compliance and is not easily subject to shifts in space composition. As such, expansion in any of these compartments results in an increase in the amount of pressure contained within the rigid vault. There are inherent safeguards that allow for an element of expansion without excessive effects on the intracranial pressure. However once a certain threshold is surpassed further expansion

results in marked elevation in intracranial pressure. As intracranial pressure rises beyond adequate perfusion, the resultant effect is reduced perfusion and oxygen availability to the cerebrum resulting in hypoxic injury and cell death. The autolytic cascade leads to an increase in cell volume as the cell membrane is unable to maintain the electrochemical gradient due to a break down of the ATP dependent Na/K ATPase pump. Water and calcium influx leads to the expansion in the cell volume and a feed-forward positive cycle where cell death causes more edema and swelling, which causes increased intracranial pressure, which in turn causes less brain perfusion and results in further cell death. CSF flow through normal pathways can also be obstructed resulting in further elevation in intracranial pressure. The end result is often herniation as pressure becomes greater than the resistance of surrounding structures and brain structures actively transgress the boundaries established by dura mater and bone. There exist several ways to manage the complication of elevated intracranial pressure. Most of these are subdivided into a step wise systematic approach. One of such divides ICP management into two categories. Category 1 involves volume reduction. This utilizes the principles of the Monroe-Kellie doctrine. Removal of volume either in the form of CSF drainage or hyperosmotic diuresis will allow for more expansion of the edematous parenchyma. Category 2 describes the removal of mechanical constraints. This category primarily relies on the decompressive craniectomy. Removal of the rigid limitations preventing brain expansion would allow for more swelling thereby limiting and or preventing herniation (Scmidek H 2006). The AANS guidelines approach the management of elevated ICP similarly. The treatment paradigm is divided into 2 Tiers. Tier 1 involves the use of sedatives, paralytics, ventricular drainage, hyperosmolar therapy and mild hyperventilation. Tier 2 involves hypothermia, longer acting sedatives such as barbiturates, lumbar drainage via an intrathecal catheter and surgical decompression of the cranial vault. The decompressive craniectomy as we will discuss later allows for an outward herniation of brain structures as the limitations of the cranial vault are expanded theoretically minimizing any further injury the brain tissue would suffer by being forced into other compartments.

3. Management of elevated intracranial pressure

In this chapter we will focus primarily on the management of intracranial pressure in patients suffering from either stroke or traumatic brain injury. There remain other clinical scenarios where patients could suffer from elevated intracranial pressure. They include but are not limited to: infection, either meningeal or encephalitic, spontaneous intracerebral hemorrhage, and aneurysmal subarachnoid hemorrhage. Although decompressive craniectomy may play a role in these settings, it is beyond the scope of this chapter. The application of decompressive craniectomy in the posterior fossa will also not be addressed in this chapter.

Various cutoff values are used at different centers above which treatment of elevated intracranial pressure is indicated. Levels of 15, 20 and 25 are quoted but most centers use ICP > 20-25mmHg as the upper limit (Bullock 1995). There is a high mortality and even higher morbidity in patients with ICP persistently above 20mmHg. The physician's clinical discretion remains paramount in these settings. A 25 year-old trauma victim with an ICP of 30 but is awake, not intubated and following commands briskly is not as concerning as a 45 year-old with an ICP of 20 but has become acutely unresponsive. Several measurements can

be employed in the management of elevated intracranial pressure. 1. Ensure adequate patient head positioning. The position of the patient's head can either optimize or hinder venous drainage. Venous congestion can lead to increased intracranial pressure. 2. Optimize the patient's vitals, specifically avoiding hypercarbia and hyperthermia. 3. Osmotic diuretics such as mannitol and hypertonic saline can also be utilized. In settings where adequate control of elevated ICP remains difficult, another option that can be employed is lumbar drainage. Lumbar drainage plays a role after ventriculostomy drainage has proven insufficient. At our institution we ensure patency of the ventriculostomy catheter with adequate drainage. If ICP remains elevated at this point a lumbar drain is placed. Initially the lumbar drain is left clamped and in most cases ICP control improves. However in situations where ICP elevation persists the lumbar drain is unclamped and placed at the same level as the ventriculostomy drain to minimize risk of brainstem herniation. The placement of lumbar drain plays a very valuable role in the reduction of elevated intracranial pressure (Munch E 2001; Murad A 2008).

4. Assessment of the trauma patient

The initial assessment of the trauma patient often begins in the emergency department. The basics must not be forgotten. Obtain a thorough history paying particular attention to mechanism of injury. Enough emphasis cannot be placed on obtaining a good overview of the situation. Even in the presence of an experienced trauma team the alert neurosurgeon can still play an additive role in helping to ensure that all bases are covered. A trauma team focused on placing a chest tube may not initially notice a lack of movement in a patient's lower extremities. The alert neurosurgeon would function well to inform the trauma team of this finding and help facilitate the appropriate imaging modality needed. Pay attention to the patient as a whole without focusing on the brain alone. In every trauma setting ensure that the ABC's of trauma (airway, breathing and circulation) are addressed before moving on to secondary surveys. A thorough physical and neurologic exam is always paramount. Initial head CT is indicated in settings where there are any moderate or high risk factors including but not limited to unresponsiveness, amnesia, altered mental status, deteriorating mental status (including intoxication), signs of calvarial fracture, focal neurologic deficits, penetrating skull injury, progressive headache, posttraumatic seizure, unreliable or inadequate history, multi-system trauma, severe facial injury, and significant subgaleal swelling (Stein S C 1992). Follow up Head CT remains at the clinical discretion of the physician and in the context of the nature of the presenting injury. A non-surgical epidural hematoma may require earlier follow up head CT than a small focal contusion. There exist practice guidelines and indications for ICP monitoring in the trauma setting. For salvageable patients with severe traumatic brain injury (GCS<8 after cardiopulmonary resuscitation), level II evidence dictates a need for ICP monitoring in patients with an abnormal Head CT. Level III evidence states a need for ICP monitoring in patients with a normal Head CT but with risk factors of elevated intracranial pressure, such as: age > 40 years, SBP < 90 mmHg, flexor or extensor posturing (Bullock 1995). However the final decision remains at the clinical discretion of the physician. Radiographic information can be used as an adjunct in determining a need for ICP monitoring but should not be used as a sole determinant. In one study 13% of patients with a normal CT scan will have elevated ICP, however patients with a normal CT and risk factors for elevated ICP have a 60% chance of elevated ICP (Narayan R

K 1082) . Decompressive craniectomy in trauma unlike in stroke remains controversial. In animal studies with artificially induced intracranial lesions, craniectomy has been linked to increased cerebral edema hemorrhagic infarcts and cortical necrosis (Moody R 1968; Cooper P 1979; Forsting M 1995). However decreased intracranial pressure, improved cerebral perfusion pressure and increased oxygen tension are also reported following craniectomy in trauma (Moody R 1968; Burkert W 1988). A review of more than 30 articles failed to demonstrate a clear benefit for craniectomy in the setting of trauma (Munch E 2000). A definitive answer to benefit of decompressive craniectomy still requires definitive randomized trials. At this point there does appear to be benefit especially in young patients with GCS >4.

Until the recently published DECRA trial (Cooper D 2011) no class I evidence supporting or disputing decompressive craniectomy in trauma existed. All previous evidence is class III at best. One of the more cited articles supporting decompressive craniectomy is a study designed at the University of Virginia (Polin 1997). In this study 35 bifrontal decompressive craniectomies were performed on patients with post-traumatic edema but no mass lesions between 1984 and 1993. The results were matched to control patients from the Traumatic Coma Data Bank. Their results showed good recovery and moderate disability in 37% of patients with mortality in 23% of patients as opposed to 16% moderate disability and 34% mortality in the Traumatic Coma Data Bank control. Post operative ICP control was better than the preoperative group and the control group. The study also found that patients with ICP >40 who underwent surgery >48hrs after time of injury did poorly.

A separate study published by the University of Maryland in Baltimore (Aarabi B 2006) discussed the findings of decompressive craniectomies performed between 2000-2004. 50 decompressive craniectomies were performed to control elevated ICP. 10 of these were performed before ICP elevation and 40 performed after ICP elevation. They found that decompressive craniectomies lowered the ICP to lower than 20 in 85% of patients. 14 of 50 patients died, 16 remained in a vegetative or severely disabled state, 20 had what was defined as a good outcome. Decompressive craniectomy was associated with a better than expected functional outcome in patients with medically uncontrollable ICP and or brain herniation compared with outcomes in other control cohorts reported in the literature.

A study out of Italy (Chibbaro S 2007) retrospectively reviewed 48 decompressive craniectomies and compared their outcomes to the Traumatic Coma Data Bank. They found that decompressive craniectomy reduced the midline shift and ameliorated basal cistern effacement. Younger patients (mean age of 31 years) had a better outcome. They also found that patients with early surgery, less than 16hrs of injury had, a better outcome than late intervention.

The DECRA trial as described earlier remains the only Class I evidence to date. The trial ran from December 2002 to April 2010. Eligibility criteria for inclusion in the study were patients between 15 and 59 years, patients with severe non-penetrating traumatic brain and patients with a GCS of 3 to 8. They excluded patients with dilated un-reactive pupils and those with mass lesions, including, but not limited to subdural and epidural hematomas. All patients had ICP monitoring and were treated medically if ICP was greater than 20. They defined early refractory ICP as a spontaneous elevation for more than 15 minutes continuously or intermittently within a 1 hour period despite first tier intervention. Patients were randomized within 72 hours to either surgery or standard care. The bifrontoparietal craniectomy technique used was based on the bifrontal craniectomy technique described by

Polin (Polin 1997). They randomly assigned 155 adults with severe traumatic brain injury and ICP refractory to first tier therapy to undergo either bifrontotemporoparietal decompressive craniectomy or standard medical care. 73 patients were enrolled in the surgical arm and 82 patients were enrolled in the medical arm. Patients in the surgical group were found to have less time with elevated intracranial pressure, required fewer interventions for increased ICP post op and spent fewer days in the ICU. However patients undergoing craniectomy were found to have a worse outcome on the Glasgow outcome scale than those receiving standard care. The rates of death at 6 months were similar, 19% in the surgical arm and 18% in the medical arm.

The DECRA trial came under a large amount of criticism primarily related to the study design. The greatest word of caution arises in defining refractory ICP elevation as having reached levels greater than 20 for 15 minutes continuously or intermittently. Most neurosurgeons, neurologists and neurointensivists would address this as being too low a threshold for aggressive management of raised ICP. Some centers advocate the use of hyperosmotics such as Mannitol as a drip over 30 minutes instead of a bolus. Although "time is brain", operating on a patient based on an ICP elevation of 15 minutes can be seen as being very rapid and somewhat rash. Another criticism lies in the screening of 3,478 patients over a 7 year period to only enroll 155 patients. Finally the exclusion of patients with mass lesions is also a concern. Several of the patients involved in the DECRA trial with no mass lesion might fall into a category of diffuse axonal injury that did not require and would not be expected to benefit from a surgical decompression.

The RESCUEicp trial is a currently ongoing international prospective multi-center randomized controlled trial comparing the efficacy of decompressive craniectomy versus optimal medical management for the treatment of refractory intracranial hypertension following brain trauma. This study differs from the DECRA trial in terms of ICP threshold (25 vs 20 mmHg), timing of surgery (any time after injury vs within 72 hours post injury) and the acceptance of mass lesions. The RESCUEicp also holds a longer follow up period, 2 years as opposed to 6 months with the DECRA trial and a larger patient population with a goal of 400 (300 enrolled as of April 2011).

5. Assessment of the stroke patient

Decompressive craniectomy plays a vital role in patients diagnosed with malignant cerebral infarction. Malignant cerebral infarction refers to large territorial parenchymal strokes with ischemic edema and associated herniation. They typically involve occlusion of the MCA or ICA distribution causing infarction of the supplied territory. They account for approximately 15% of all strokes but mortality ranges from 50-80%. Patients typically present with rapid neurologic deterioration, gaze preference towards the infarcted hemisphere, contralateral hemiplegia and progressive decline in level of consciousness. Patients can rapidly progress from a state of being awake, alert, oriented and following commands to an obtunded state. The validity of decompressive craniectomy in stroke patients has been better studied and thereby better accepted in stroke patients than in trauma patients. Decompressive craniectomy in stroke patients has been shown to reduce mortality from 50% to as low as 32% in non-dominant hemisphere strokes with reduction of hemiplegia and in dominant hemisphere strokes only a mild-moderate aphasia. Better results occur with earlier surgery (Carter BS 1997). In 2007, three key landmark articles were published that proposed

class I evidence supporting the use of decompressive craniectomy as valid treatment in the management of patients with malignant MCA infarction. The DECIMAL trial (Vahedi K 2007) was a study conducted in France after a poll of 47 neurology departments showed that only 2 departments were convinced of the efficacy of the decompressive craniectomy. The decompressive craniectomy in malignant MCA infarction trial was a multi center prospective randomized open but with blind evaluation of the primary end point study comparing early decompressive craniectomy versus standard medical therapy. It was conducted in 13 selected stroke centers including a stroke unit and a neurosurgery department from 2001 to 2005. Patients selected were between the ages of 18 and 55.

They included strokes as defined by an NIHSS > 16 within 24 hours of initial symptoms. The imaging criteria included head CTs that showed greater than a 50% MCA distribution involvement and MRI-DWI showing > 145 cm infarct volume. Exclusion criteria included patients with significant contralateral infarction, secondary hemorrhage of more than 50% of MCA territory pre-infarct significant disability, coagulopathy or use of tPA. For patients in the surgical arm of the study, decompressive craniectomy was performed less than 6hrs after randomization and up to 30hrs after initial onset of symptoms. 38 pts from 7 centers had been end enrolled when the study was prematurely ended (18 medical therapy, 20 surgical therapy). The study was ended due to slow recruitment of patients, a high difference in mortality between the 2 groups and to organize pooled data from the other ongoing trials, the DESTINY(Juttler E 2007) and HAMLET(Hotmeijer J 2009) trials. With the results gathered it was noted that the early decompression increased by more than half the number of patients with moderate disability and reduced by more than half the mortality rate at 1 year (mRS <3 of 50% in surgical group and 22% in medical group). The DECIMAL trial was able to conclude that in young patients (55yrs or younger) with malignant MCA infarction, early decompressive craniectomy had a great benefit on survival and led to a better functional outcome. No patients remained bedridden or had severe residual disability. Young patients had a significantly better outcome after surgery. However no patient had a complete recovery.

The DESTINY trial (Juttler E 2007) was a prospective, multi center, randomized, controlled clinical trial also based on a sequential design that used mortality after 30 days as the first end point. Although this trial was also ended prematurely it was able to show a statistically significant reduction in mortality after 32 patients had been enrolled. 15 of 17 patients randomized to the surgical group as opposed to 7 of 15 in the medical group survived after 30 days. DESTINY showed that hemicraniectomy reduces mortality in large hemispheric stroke patients. With only 32 patients enrolled the study was unable to demonstrate statistical superiority in functional outcome however the trial was terminated in light of the results of its joint analysis of the 3 European hemicraniectomy trials.

The HAMLET trial (Hotmeijer J 2009) was the third European trial and its aim was to assess the effect of decompressive surgery within 4 days of symptoms in patients with space-occupying hemispheric infarction. It showed that surgical decompression reduces fatality and poor outcome in patients with space occupying infarctions who are treated within 48hrs of stroke onset. The results however, showed no evidence that functional outcome is improved when decompression is delayed for up to 96hrs after stroke onset. They stress that the decision to operate should depend on the emphasis patients and relatives attribute to survival and dependency. Patient's lives can be saved but functional independence will either be severely impaired or completely lost.

A Meta-Analysis of the 3 randomized controlled trials found that hemicraniectomy within 48hrs after stroke onset resulted in reduced mortality and more favorable functional outcome. The trials were ongoing when the pooled analysis was planned. DESTINY and DECIMAL were stopped due to a clear reduction in mortality. HAMLET was still ongoing. The goal was to obtain results as soon as possible to avoid ongoing randomization in unnecessary and unethical situations. Indications include age <60 years. Stronger consideration in right hemisphere strokes and radiographic evidence of acute ICA or MCA infarcts with signs of impending severe brain swelling (Vahedi K 2007). 93 patients were included in the pooled analysis, (DESTINY 32pts, DECIMAL 38pts and HAMLET 23pts). More patients in the surgery group than in the medical group had mRS <4 (78% vs 24%). Also more patients in the surgical group survived than in the medical group (78% vs 29%). Interestingly certain rehab centers describe better improvement in patients with dominant hemisphere infarctions than in non-dominant hemisphere infarctions.

Perhaps this can be attributed to a retained capacity to learn activities of daily living. The most compelling argument for craniectomy in stroke patients regards the timing of surgery. This is supported by the 3 European trials as well as a retrospective study of 52 decompressions stratified by time of surgery into groups with intervention in under 6 hours from injury, intervention 6 hours after injury and no intervention. These showed mortality rates of 8%, 36% and 80% respectively. The average length of ICU stay was 12 days, 18 days and 7 days (shortened due to fatality)(Cho D 2003). A separate but similar study retrospectively stratified 63 interventions into decompression within 24 hours (early, 31 patients) and after 24 hours (late, 32 patients) of initial injury. Mortality was 16% for early decompression and 34% for late decompression. The average length of intensive care stay was 7 days for early decompression and 13 days for late decompression (Schwab S 1998). However early detection is only capable and confirmatory with adequate radiographic evidence.

MRI with DWI offers the best correlation to stroke severity and clinical outcome. The 90% sensitivity and 96% specificity of predictive value of malignant cerebral infarction with MRI-DWI are superior to the 60% and 70 to 90% specificity reported with Head CT (Arenillas J 2002; Manno E 2003). Given the limited availability of MRI either due to hospital constraints or patient co-morbidities, as well as the time restraints imposed by timely use of tPA in the setting of hyperacute stroke, the Head CT remains the most available and widely used radiographic reference tool.

At our institution we have developed a standard protocol applied to patients with malignant MCA stroke to assess their eligibility for decompressive craniectomy:

- LLUMC Protocol for Decompressive Craniectomy in Stroke
- Patients < 60 years old
- Large MCA stroke (greater than 145ml volume on DWI or greater than 50% MCA territory)
- Presentation within 48hrs of initial symptoms
- Exclude dilated un-reactive pupils
- Exclude bleeding diathesis
- Ventriculostomy placement ipsilateral to infarcted brain
- Lumbar drain if ICP remains elevated
- Cranioplasty between 6 weeks and 6 months

These parameters although not standardized nationally take into consideration the findings of other institutions and several published works. The ubiquity of factors such as age and

timing of intervention are far reaching, as exhibited by the findings of Eghwrujakpor and Allison (Eghwrujakpor P 2010). They describe a glasgow coma core of 8 and above, age less than 50 years and early intervention as being the most significant determinants of prognosis.

6. Surgical considerations

A wide variety of surgical techniques have been reported for decompressive craniectomy. All approaches can be performed either unilaterally or bilaterally. The bone flap can be stored in various locations, the patients abdominal subcutaneous fat, cryopreservation and in situ using the hinge craniectomy method (Ko 2007). A standard trauma flap skin incision is made with the goal of exposing the following margins: anteriorly to the superior border of the orbital roof, avoiding entry into the frontal sinus, posteriorly to at least 2cm posterior to the external meatus, medially to a point 2cm lateral to the midline to avoid the sagittal sinus and inferiorly to the floor of the middle cranial fossa (Scmidek H 2006). The temporalis muscle is reflected anteriorly. Burrholes are placed at the keyhole, the root of the zygoma and as preferred along the planned craniotomy route. A high speed drill is used for the craniotomy. The lesser wing of the sphenoid is fractured and removed to the superior orbital fissure. The dural edges can be tacked up to the skull to minimize formation of epidural hematoma. Dura can be opened in several manners but typically is done in a stellate fashion. Dura closure is not mandatory at this point and can either be left open, with mild approximation of dural leaflets or replaced with dural substitute. The decompressive craniectomy alone without durotomy reduces the intracranial pressure by 15%. A duraplasty further reduces the intracranial pressure by an additional 55% (Scmidek H 2006). At our institution we rely more on the rapid closure technique as described by Guresir et al. This technique has been found to significantly shorten operation time without increased complication rates or additional complications (Guresir E 2011). There have been incidences of CSF leak attributed to open dural leaflets but this has not been our experience. In the setting of trauma, evacuation of hematoma or contusion can proceed as indicated by the nature of the injury.

The size of the craniectomy directly correlates with degree of expansion (Gaa M 1990; Yoo D 1999). Small craniectomies are associated with further infarction and hemorrhage at the sites of the craniectomy margin. Mortality rates have also been reported as elevated in small diameter craniectomies (Wagner S 2001). This is due to the venous congestion that occurs in the herniated brain tissue as it is restricted and compressed by the bony boundary of the skull defect. Brain parenchyma herniates through the bony defect which in essence is the desired effect but compression of parenchyma adjacent to the bony boundary in a small craniectomy leads to venous congestion, venous infarction and further damage to brain tissue. This is more common in craniectomies smaller than 8cm in diameter.

Doubling the diameter of a craniectomy from 6cm to 12cm increases the decompressed brain volume from 9ml to 86ml. A lower margin of craniectomy relative to the floor of the middle fossa has also been described with improved outcomes. This can be related to the state of decompression of the mesencephalic cisterns. Compression of the basal cisterns is known to impair clinical outcome, a larger craniectomy to the base of the brainstem could minimize brain stem compression (Toutant S 1984; Munch E 2000). The state of the mesencephalic cisterns correlates greatly with the distance of the craniectomy to the temporal cranial floor. As such decompression or out-fracturing of the temporal floor after removal of the bone flap remains exceedingly important. Compression of the cisterns impairs clinical outcome and a

large craniectomy to the base of the cranium could minimize brain stem compression. A mortality rate of 77%, 39% and 22% as been described in those with absent, compressed and normal cisterns respectively. Patients presenting with a GCS of 7-8 who were expected to fair well did not recover as expected if the basal cisterns were compressed or absent in studies evaluated within the first 48hrs of admission(Toutant S 1984). As such recommendations for craniectomy size are typically in the range of 10x15cm with the lower margin extending to less than 1cm from the floor of the middle cranial fossa.

The frontal craniotomy is typically used in cases of frontal contusions or infarction. Bifrontal craniectomy is the most widely used. The surgical technique involves placing the patient supine. A bicoronal skin incision is planned posterior to the coronal suture. After incision the temporalis muscle is reflected inferiorly. Burr holes are made at the keyhole and at the root of the zygoma. Burr holes are also placed on either side of the sagittal sinus and along the planned craniectomy. Bilateral craniectomies are performed leaving a strip of bone covering the sagittal sinus. This strip of bone is then removed after freeing the sagittal sinus. A separate technique involves placing burrholes directly on the superior sagittal sinus and a burr hole at each key hole. The dura is then stripped from the bone, taking particular caution at the sinus. A bone flap is created connecting the keyhole burrholes with the most posterior burrhole at the sinus. Bilateral U shaped durotomies are created.

If the sinus is to be ligated and sacrificed, tributary veins are coagulated as they drain into the sinus. The sinus is then ligated at the most anterior margin as dictated by the craniotomy margin and posteriorly to a maximum of 1/3 of the length of the entire superior sagittal sinus. The ligated sinus can then be separated from the falx as it dives into the intercerebral hemisphere. Further consideration and care must be taken in settings of trauma with frontal skull fractures and frontal contusions. Bony structures may serve a tamponade effect on a lacerated sinus and may need to be left in place or anterior portions of the sinus may need to be sacrificed for adequate decompression. Bilateral dural openings are made into U-shaped flaps extending to the anterior portion of the sagittal sinus followed by ligation of the sinus. Some authors advocate preservation of the strip of bone overlying the sagittal sinus, others argue that sacrificing the anterior 1/3 of the sinus could lead to increased venous pressure and worsening cerebral edema (Polin 1997).

The removal of large areas of contused, infarcted or hemorrhagic theoretically further enhances the decompression. It also removes regions of disrupted blood brain barrier that could lead to further edema. Temporal lobectomy can be performed with removal of no more than 4-5cm of brain from the temporal tip on the dominant side and 6-7cm on the non-dominant side. Frontal lobectomy has also been described but neither has shown great therapeutic promise (Nussbaum E S 1991).

7. Recovery after hemicraniectomy

Decompressive hemicraniectomy, although life saving typically leaves survivors with severe disability. The alternative to this however being death. Most patients fail to ever re-attain functional independence. Patients typically have their bone flap replaced 6 weeks to 6 months after the initial injury to ensure resolution of the initial insult. Patients suffering from the post craniectomy syndrome may have their bone flap replaced sooner rather than latter.

Complications include but are not limited to intracerebral hematoma formation, extra-axial collections, cerebrospinal fluid leakage and cranioplasty failure. Post craniectomy hematoma formation primarily occurs due to inadequate surgical hemostasis or rupture of

friable vessels as herniating brain tissue is compressed along the craniotomy margin. This is seen more often in small hemicraniectomies (Wagner S 2001).. The vast majority of these are clinically silent. Extra axial fluid accumulations occur as a result of CSF leakage through the dural leaflets or secondary to post traumatic extra axial hydrocephalus. Some patients may require a ventricular or sub-dural shunt.

CSF leak occurs in conjunction with open dura and inadequate closure of galea and skin. The incidence of this is in the range of 3% to 5% (Polin 1997; Wagner S 2001). Cranioplasty failure occurs as a result of bone flap resorption or infection. This occurs in 2% to 6% of cases. Poor graft fixation and approximation, excessive use of bone wax and a poorly vascularized or infected scalp can lead to this (Polin 1997). Patients with a compromised flap could subsequently require an acrylic bone flap. Postoperative seizure disorder are also reported in the range of 5% to 30%. The etiology of these remain unclear but can be attributed to the initial injury, resultant decompression, and a complicated hospital course.

8. Non-traumatic brain injury

In the setting of non-traumatic brain injury, the role of decompressive craniectomy remains unclear similar to traumatic brain injury. These include patients in categories including but not limited to subarachnoid hemorrhage secondary to ruptured aneurysm, intracerebral hemorrhage (ICH), and infectious processes. Kim et al (Ki-Tae Kim 2008) describe a series in which 75 patients underwent decompressive craniectomy and were analyzed retrospectively. In this group 28 patients were classified as traumatic brain injury, 24 as intracerebral hemorrhage and 23 with major infarction. Patients with a GCS score less than 8 and midline shift on head CT greater than 6mm were considered surgical candidates. Patients outcomes at 6 months revealed a mortality rate of 21.4% in TBI, 25% in ICH and 60.9% in major infarction.

Favorable outcomes defined by glasgow outcome score of 4-5 (moderate disability or better) were observed in 57.1% of patients with TBI, 50% with ICH and 30.4% with major infarction. They also describe changes in intracranial pressure that were further increased with dural opening regardless of the disease group. Although this study describes the decompressive craniectomy as being more effective in ICH and TBI patients, we would encourage the reader to bear in mind these findings relate to retrospective studies. As described earlier in the chapter there exists class I evidence supporting the use of decompressive craniectomy in major infarction or stroke patients provided certain parameters are met.

Hitchings and Delaney further describe a series of patients who underwent decompressive craniectomy for non trauma related conditions (Hitchings L 2010). They describe 54 patients who underwent 56 procedures. They noted that although intracranial pressure was reduced by the procedure. patients had long hospital stays and consumed a very significant amount of resources. Among survivors, two-thirds sustained a good outcome however most patients suffered residual deficits. They noted a mortality rate of 39%. These findings remain in concordance with the general concordance regarding decompressive craniectomies in that patients lives typically can be saved but functionality and quality of life suffer greatly.

9. Conclusion

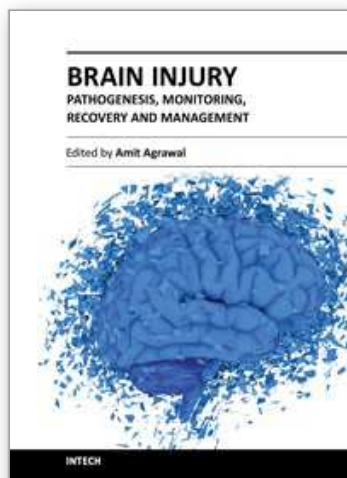
Intracranial hypertension is a common sequelae of several illnesses and traumatic injury. Decompressive craniectomy provides an effective means of reducing and managing

intracranial pressure. Lumbar drainage is also a useful adjunct in addition. Selection criteria remains in evolution primarily in the trauma setting but at the present time it appears the best outcomes are in young otherwise healthy patients. The decision to proceed with decompressive craniectomy should take into consideration several factors including family wishes and reasonable expectations of level of recovery.

10. References

- Aarabi B, H. D., Ahn E, Aresco C, Scalea T, Eisenberg H (2006). "Outcome following decompressive craniectomy for malignant swelling due to severe head injury." *Journal of Neurosurgery* 104: 469-479.
- Arenillas J, R. A., Molina C, et al (2002). "Prediction of early neurological deterioration using diffusion and perfusion weighted imaging in hyperacute middle cerebral artery stroke." *Stroke* 33: 2120-2197.
- Bullock, R. C. R. M., Clifton G, et al (1995). Guidelines for the management of severe head injury. *The Brain Trauma Foundation*
The American Association of Neurological Surgeons
The Joint Section of Neurotrauma and Critical Care. New York, Park Ridge, Illinois.
- Burkert W, P. H. (1988). "Decompressive trephination in therapy refractory brain edema." *Zentralbl Neurochir* 50: 318-323.
- Carter BS, O. C., Candia GJ, et al (1997). "One year outcome after decompressive surgery for massive nondominant hemisphere infarction." *Neurosurgery* 40: 1168-1176.
- Chibbaro S, T. L. (2007). "Role of decompressive craniectomy in the management of severe head injury with refractory cerebral edema and intractable intracranial pressure, Our experience with 48 cases." *Surgical Neurology* 68: 632-638.
- Cho D, C. T., Lee H (2003). "Ultra-early decompressive craniectomy for malignant middle cerebral artery infarction." *Surgical Neurology* 60: 227-232.
- Cooper D, R. J., Murray L, Arabi Y, Davies A, D'Urso P, Kossman T, Ponsford J, Seppelt I, Reilly P, Wolfe R (2011). "Decompressive Craniectomy in Diffuse Traumatic Brain Injury." *The New England Journal of Medicine* 364: 1493-1502.
- Cooper P, H. H., Clark W, et al (1979). "Enhancement of experimental cerebral edema after decompressive craniectomy: Implications for the management of severe head injuries." *Neurosurgery* 4: 296-300.
- Eghwrudjakpor P, A. A. (2010). "Decompressive Craniectomy Following Brain Injury: Factors Important to Patient Outcome." *Libyan Journal of Medicine* 5(4620).
- Forsting M, R. W., Schabitz W, et al (1995). "Decompressive Craniectomy for cerebral infarction: An experimental study in rats." *Stroke* 26: 259-264.
- Gaa M, R. M., Lorenz M, et al (1990). "Traumatic brain swelling and operative decompression: A prospective investigation." *Acta Neurochirurgica Supplementum* 51: 326-328.
- Guresir E, V. H., Schuss P, Oszvald A, Raabe A, Seifert V, Beck J (2011). "Rapid closure technique in decompressive craniectomy." *Journal of Neurosurgery* 114: 954-960.
- Hitchings L, D. A. (2010). "Decompressive Craniectomy for patients with severe non-traumatic brain injury: a retrospective cohort study." *Critical Care Resuscitation* 12: 16-23.
- Hotmeijer J, K. L., Algra A, Amelink G, Van Gijn J, Van Der Worp H (2009). "Surgical decompression for space-occupying cerebral infarction (the Hemicraniectomy After Middle Cerebral Artery infarction with Life-threatening Edema Trial [HAMLET]): a multicentre, open, randomised trial." *The Lancet* 8(4): 326-333.

- Juttler E, S. S., Schiedek P, Unterberg A, Hennerici M, Woitzk J, Witte S, Ekkehart J, Hacke W (2007). "Decompressive Surgery for the Treatment of Malignant Infarction of the Middle Cerebral Artery (DESTINY)." *Stroke* 38: 2518-2525.
- Ki-Tae Kim, J.-K. P., Seok-Gu Kang, Kyung-Suck Cho, Do-Sung Yoo, Dong-Kyu Jang, Pil-Woo Huh, Dal-Soo Kim (2008). "Comparison of the effect of decompressive craniectomy on different neurosurgical diseases." *Acta Neurochirurgica* 151(1): 21-30.
- Ko, S. (2007). "In situ Hinge Craniectomy." *Neurosurgery* 60: 255-259.
- Manno E, N. D., Fulgham J, et al (2003). "Computed tomographic determinants of neurologic deterioration in patients with large middle cerebral artery infarctions." *Mayo Clinic Proc* 78: 156-160.
- Moody R, R. S., Mullan S (1968). "An evaluation of decompression in experimental head injury." *Journal of Neurosurgery* 29: 586-590.
- Munch E, B. C., Horn P, Roth H, Schmiedek P, Vajkoczy P (2001). "Therapy of malignant intracranial hypertension by controlled lumbar cerebrospinal fluid drainage." *Critical Care Medicine* 29: 976-981.
- Munch E, H. P., Schurer, L et al (2000). "Management of severe traumatic brain injury by decompressive craniectomy." *Neurosurgery* 47: 315-322.
- Murad A, G. S., Colohan AR (2008). "Controlled lumbar drainage in medically refractory increased intracranial pressure. A safe and effective treatment " *Acta Neurochirurgica Supplementum* 102: 89-91.
- Narayan R K, K. P. R. S., Becker D P, et al (1982). "Intracranial Pressure: To monitor or not to monitor?" *Journal of Neurosurgery* 56: 650-659.
- Nussbaum E S, W. A. L., Sebring L, et al (1991). "Complete temporal lobectomy for surgical resuscitation of patients with transtentorial herniation secondary to unilateral hemispheric swelling." *Neurosurgery* 29: 62-66.
- Polin, R., Shaffrey M, Bogaev Ce, et al (1997). "Decompressive bifrontal craniectomy in the treatment of severe refractory posttraumatic cerebral edema." *Neurosurgery* 41: 84-92.
- Schwab S, S. T., Aschoff A, et al (1998). "Early hemicraniectomy in patients with complete middle cerebral artery infarction." *Stroke* 29: 1888-1893.
- Scmidek H, R. D., Ed. (2006). *Operative Neurosurgical Techniques Indications, Methods and Results*. Decompressive Craniectomy: Physiologic Rationale, Clinical Indications and Surgical Considerations. Philadelphia PA, Elsevier.
- Stein S C, R. S. E. (1992). "Moderate head injury: A guide to initial management." *Journal of Neurosurgery* 77: 652-654.
- Toutant S, K. M., Marshall L, et al (1984). "Absent of compressed basal cisterns on first CT scan: Ominous Predictors of outcome in severe head injury." *Journal of Neurosurgery* 61: 84-92.
- Vahedi K, e. a. (2007). "Sequential-Design, Multicenter, Randomized, Controlled Trial of Early Decompressive Craniectomy in Malignant Middle Cerebral Artery Infarction (DECIMAL Trial)." *Stroke* 38: 2506-2517.
- Vahedi K, H. J., Juettler E; et al (2007). "Early decompressive surgery in malignant infarction of the middle cerebral artery: A pooled analysis of three randomized controlled trials." *Lancet Neurology* 6: 215-222.
- Wagner S, S. H., Aschoff A, et al (2001). "Suboptimum hemicraniectomy as a cause of additional cerebral lesions in patients with malignant infarction of the middle cerebral artery." *Journal of Neurosurgery* 94: 693-696.
- Yoo D, K. D., Cho K et al (1999). "Ventricular pressure monitoring during bilateral decompression with dural expansion." *Journal of Neurosurgery* 91: 953-959.



Brain Injury - Pathogenesis, Monitoring, Recovery and Management

Edited by Prof. Amit Agrawal

ISBN 978-953-51-0265-6

Hard cover, 522 pages

Publisher InTech

Published online 23, March, 2012

Published in print edition March, 2012

The present two volume book "Brain Injury" is distinctive in its presentation and includes a wealth of updated information on many aspects in the field of brain injury. The Book is devoted to the pathogenesis of brain injury, concepts in cerebral blood flow and metabolism, investigative approaches and monitoring of brain injured, different protective mechanisms and recovery and management approach to these individuals, functional and endocrine aspects of brain injuries, approaches to rehabilitation of brain injured and preventive aspects of traumatic brain injuries. The collective contribution from experts in brain injury research area would be successfully conveyed to the readers and readers will find this book to be a valuable guide to further develop their understanding about brain injury.

How to reference

In order to correctly reference this scholarly work, feel free to copy and paste the following:

Dare Adewumi and Austin Colohan (2012). Decompressive Craniectomy: Surgical Indications, Clinical Considerations and Rationale, Brain Injury - Pathogenesis, Monitoring, Recovery and Management, Prof. Amit Agrawal (Ed.), ISBN: 978-953-51-0265-6, InTech, Available from: <http://www.intechopen.com/books/brain-injury-pathogenesis-monitoring-recovery-and-management/decompressive-craniectomy-surgical-indications-clinical-considerations-and-rationale>

INTECH
open science | open minds

InTech Europe

University Campus STeP Ri
Slavka Krautzeka 83/A
51000 Rijeka, Croatia
Phone: +385 (51) 770 447
Fax: +385 (51) 686 166
www.intechopen.com

InTech China

Unit 405, Office Block, Hotel Equatorial Shanghai
No.65, Yan An Road (West), Shanghai, 200040, China
中国上海市延安西路65号上海国际贵都大饭店办公楼405单元
Phone: +86-21-62489820
Fax: +86-21-62489821

© 2012 The Author(s). Licensee IntechOpen. This is an open access article distributed under the terms of the [Creative Commons Attribution 3.0 License](https://creativecommons.org/licenses/by/3.0/), which permits unrestricted use, distribution, and reproduction in any medium, provided the original work is properly cited.

IntechOpen

IntechOpen