

We are IntechOpen, the world's leading publisher of Open Access books Built by scientists, for scientists

6,900

Open access books available

186,000

International authors and editors

200M

Downloads

Our authors are among the

154

Countries delivered to

TOP 1%

most cited scientists

12.2%

Contributors from top 500 universities



WEB OF SCIENCE™

Selection of our books indexed in the Book Citation Index
in Web of Science™ Core Collection (BKCI)

Interested in publishing with us?
Contact book.department@intechopen.com

Numbers displayed above are based on latest data collected.
For more information visit www.intechopen.com



Basic Knowledge of Bone Grafting

IntechOpen

Nguyen Ngoc Hung
Hanoi Medical University,
Military Academy of Medicine,
Pediatric Orthopaedic Department - National Hospital of Pediatrics,
Dong Da District, Ha Noi,
Vietnam

1. Introduction

Bone grafting is a surgical procedure that replaces missing bone in order bone fractures that are extremely complex, pose a significant health risk to the patient, or fail to heal properly.

Bone grafting is a very old surgical procedure. The first recorded bone implant was performed in 1668. Bone grafts are used to treat various disorders, including delayed union and nonunion of fractures, congenital pseudoarthrosis, and osseous defects from trauma, infection, and tumors. Bone grafts are also used in plastic and facial surgery for reconstruction.

Bone generally has the ability to regenerate completely but requires a very small fracture space or some sort of scaffold to do so. Bone grafts may be autogenous (bone harvested from the patient's own body, often from iliac crest), allograft (cadaveric bone usually obtained from a bone bank), or synthetic (often made of hydroxyapatite or other naturally occurring and biocompatible substances) with similar mechanical properties to bone. Most bone grafts are expected to be reabsorbed and replaced as the natural bone heals over a few month's time.

The principles, indications, and techniques of bone grafting procedures were well established before "the metallurgic age" of orthopaedic surgery. Because of the necessity of using autogenous materials such as bone pegs or, in some cases, using wire loops, fixation of grafts was rather crude. Lane and Sandhu introduced internal fixation; Albee and Kushner, Henderson, Campbell, and others added osteogenesis to this principle to develop bone grafting for nonunion into a practical procedure. The two principles, fixation and osteogenesis, were not, however, efficiently and simply combined until surgeons began osseous fixation with inert metal screws. Then came the bone bank with its obvious advantages. Much work, both clinical and experimental, is being done to improve the safety and results of bone grafting: donors are being more carefully selected to prevent the transmission of HIV and other diseases; tissue typing and the use of immunosuppressants are being tried; autologous bone marrow is being added to autogenous and homogenous bone grafts to stimulate osteogenesis; and bone graft substitutes have been developed.

Bone graft are involved in successful bone graft include osteoconduction (guiding the reparative growth of the natural bone), osteoinduction (encouraging undifferentiated cells

to become active osteoblast), and osteogenesis (living bone cells in the graft material contribute to become remodeling). Osteogenesis only occurs with autografts.

Bone grafts may be used for the following purposes:

1. To fill cavities or defects resulting from cysts, tumors, or other causes
2. To bridge joints and thereby provide arthrodesis
3. To bridge major defects or establish the continuity of a long bone
4. To provide bone blocks to limit joint motion (arthrorisis)
5. To establish union in a pseudarthrosis
6. To promote union or fill defects in delayed union, malunion, fresh fractures, or osteotomies
7. To plastical arthrosis of acetabulum for Congenital Dislocation of the Hip and Perthes disease

2. Basic knowledge of bone grafting

Phemister introduced the term creeping substitution [1, 2]. He believed that transplanted bone was invaded by vascular granulation tissue, causing the old bone to be resorbed and subsequently replaced by the host with new bone. Phemister's concept remains valid; however, Abbott and associates have shown that, in addition, surface cells in the bone graft survive and participate in new bone formation [3]. Ray and Sabet [4] and Arora and Laskin [5] also confirmed the fact that superficial cells in the bone graft probably survive transplantation and contribute to new bone formation. The percentage of cells that survive transplantation is unknown, but cell survival seems to be improved by minimizing the interval between harvest and implantation and by keeping the graft moist and at physiologic temperatures.

In cancellous bone grafts, the necrotic tissue in marrow spaces and haversian canals is removed by macrophages. Granulation tissue, preceded by the advance of capillaries, invades the areas of resorption [6]. Pluripotential mesenchymal cells differentiate into osteoblasts, which begin to lay seams of osteoid along the dead trabeculae of the bone graft. Osteoclasts resorb the necrotic bone, and eventually most of the bone graft is replaced by new host bone. Finally, the old marrow space is filled by new marrow cells [7].

In cortical bone, the process of incorporation is similar but much slower, because invasion of the graft must be through the haversian canals of the transplant [8]. Osteoclasts resorb the surface of the canals, creating larger spaces into which granulation tissue grows. As this granulation tissue penetrates the center of the cortical graft, new bone is laid throughout the graft along enlarged haversian canals. Depending on the size of the graft, complete replacement may take many months to a year or more [9].

2.1 Biological mechanism

Osteoconduction

Osteoconduction occurs when the bone graft material serves as a scaffold for new bone growth that is perpetuated by the native bone. Osteoblasts from the margin of the defect that is being grafted utilize the bone graft material as a framework upon which to spread and generate new bone. In the very least, a bone graft material should be osteoconductive.

Osteoinduction

Osteoinduction involves the stimulation of osteoprogenitor cells to differentiate into osteoblasts that then begin new bone formation. The most widely studied type of osteoinductive cell mediators are bone morphogenetic proteins (BMPs). A bone graft material that is osteoconductive and osteoinductive will not only serve as a scaffold for currently existing osteoblasts but will also trigger the formation of new osteoblasts, theoretically promoting faster integration of the graft.

Osteogenesis

Osteogenesis occurs when vital osteoblasts originating from the bone graft material contribute to new bone growth along with bone growth generated via the other two mechanisms.

Osteopromotion

Osteopromotion involves the enhancement of osteoinduction without the possession of osteoinductive properties. For example, enamel matrix derivative has been shown to enhance the osteoinductive effect of demineralized freeze dried bone allograft (DFDBA), but will not stimulate *denovo* bone growth alone [3].

2.2 Structure of grafts

Cortical bone grafts are used primarily for structural support, and cancellous bone grafts for osteogenesis. Structural support and osteogenesis may be combined; this is one of the prime advantages of using bone graft. These two factors, however, vary with the structure of the bone. Probably all or most of the cellular elements in grafts (particularly cortical grafts) die and are slowly replaced by creeping substitution, the graft merely acting as a scaffold for the formation of new bone. In hard cortical bone this process of replacement is considerably slower than in spongy or cancellous bone. Although cancellous bone is more osteogenic, it is not strong enough to provide efficient structural support. When selecting the graft or combination of grafts, the surgeon must be aware of these two fundamental differences in bone structure. Once a graft has united with the host and is strong enough to permit unprotected use of the part, remodeling of the bone structure takes place commensurate with functional demands.

Bone grafts may be cortical, cancellous, or corticocancellous. If structural strength is required, cortical bone grafts must be used. However, the process of replacement produces resorption as early as 6 weeks after implantation; in dogs, it may take up to 1 year before the graft begins to regain its original mechanical strength [10]. Drilling holes in the graft does not appear to accelerate the process of repair, but it may lead to the early formation of biologic pegs that enhance graft union to host bone [11].

2.3 Sources of grafts

Bone graft terminology has changed, leading to some confusion. In this text, we use the new terminology. For most applications, autogenous bone graft is indicated. Other types of bone grafts are indicated only if autogenous bone graft is unavailable or if it is insufficient and must be augmented. Another exception is when structural whole or partial bones, with or

without joint articular surfaces, are needed for reconstruction of massive whole or partial bone defects [12 - 15].

Autogenous grafts, when the bone grafts come from the patient, the grafts usually are removed from the tibia, fibula, or ilium. These three bones provide cortical grafts, whole bone transplants, and cancellous bone, respectively.

When internal or external fixation appliances are not used, which is rare now, strength is necessary in a graft used for bridging a defect in a long bone or even for the treatment of pseudarthrosis. The subcutaneous anteromedial aspect of the tibia is an excellent source for such grafts. In adults, after removal of a cortical graft, the plateau of the tibia supplies cancellous bone. Apparently, leaving the periosteum attached to the graft has no advantage; however, suturing to the periosteum over the defect has definite advantages.

3. Type and tissue sources

3.1 Autograft

Autologous (or autogenous) bone grafting involves utilizing bone obtained from the same individual receiving the graft.

When a block graft will be performed, autogenous bone is the most preferred because there is less risk of the graft rejection because the graft originated from the patient's own body [16]. As indicated in the chart above, such a graft would be osteoinductive and osteogenic, as well as osteoconductive. A negative aspect of autologous grafts is that an additional surgical site is required, in effect adding another potential location for post-operative pain and complications [17].

All bone requires a blood supply in the transplanted site. Depending on where the transplant site and the size of the graft, an additional blood supply may be required. For these types of grafts, extraction of the part of the periosteum and accompanying blood vessels along with donor bone is required. This kind of graft is known as a vital bone graft.

An autograft may also be performed without a solid bony structure, for example using bone reamed from the anterior superior iliac spine. In this case there is an osteoinductive and osteogenic action, however there is no osteoconductive action, as there is no solid bony structure.

3.2 Allografts

Allograft bone, like autogenous bone, is derived from humans; the difference is that allograft is harvested from an individual other than the one receiving the graft. Allograft bone is taken from cadavers that have donated their bone so that it can be used for living people who are in need of it; it is typically sourced from a bone bank.

In small children the usual donor sites do not provide cortical grafts large enough to bridge defects, or the available cancellous bone may not be enough to fill a large cavity or cyst; furthermore, the possibility of injuring a physis must be considered. Therefore grafts for small children usually were removed from the father or mother.

Heterogeneous Grafts. Because of the undesirable features of autogenous and allogenic bone grafting, heterogenous bone, that is, bone from another species, was tried early in the development of bone grafting and was found to be almost always unsatisfactory. The material more or less retained its original form, acting as an internal splint but not stimulating bone production. These grafts often incited an undesirable foreign body reaction. Consistently satisfactory heterogenous graft material still is not commercially available, and its use is not recommended.

Cancellous Bone Substitutes. Hydroxyapatite and tricalcium phosphate, synthetic and naturally occurring materials, are now being used as substitutes for cancellous bone grafts in certain circumstances. These porous materials are invaded by blood vessels and osteogenic cells, provide a scaffold for new bone formation, and are, in theory, eventually replaced by bone. Their primary usefulness is in filling cancellous defects in areas where graft strength is not important. Bucholz et al. found hydroxyapatite and tricalcium phosphate materials to be effective alternatives to autogenous cancellous grafts for grafting tibial plateau fractures. A synthetic bone graft substitute composed of biphasic ceramic (60% hydroxyapatite and 40% tricalcium phosphate) plus type I bovine collagen and marketed as Collagraft (Zimmer, Warsaw, Ind.) has recently undergone clinical trials.

3.3 Synthetic variants

Artificial bone can be created from ceramics such as calcium phosphates (e.g. hydroxyapatite and tricalcium phosphate), Bioglass and calcium sulphate; all of which are biologically active to different degrees depending on solubility in the physiological environment [18]. These materials can be doped with growth factors, ions such as strontium or mixed with bone marrow aspirate to increase biological activity. Some authors believe this method is inferior to autogenous bone grafting [16] however infection and rejection of the graft is much less of a risk, the mechanical properties such as Young's modulus are comparable to bone.

3.4 Xenografts

Xenograft bone substitute has its origin from a species other than human, such as bovine. Xenografts are usually only distributed as a calcified matrix. In January 2010 Italian scientists announced a breakthrough in the use of wood as a bone substitute, though this technique is not expected to be used for humans until at the earliest [19]

3.5 Alloplastic grafts

Alloplastic grafts may be made from hydroxylapatite, a naturally occurring mineral that is also the main mineral component of bone. They may be made from bioactive glass. Hydroxylapatite is a Synthetic Bone Graft, which is the most used now among other synthetic due to its osteoconduction, hardness and acceptability by bone. Some synthetic bone grafts are made of calcium carbonate, which start to decrease in usage because it is completely resorbable in short time which make the bone easy to break again. Finally used is the tricalcium phosphate which now used in combination with hydroxylapatite thus give both effect osteoconduction and resorbability.

3.6 Bone bank

Opinions differ among orthopaedic surgeons regarding the use of preserved allogenic bone, although its practical advantages are many. Fresh autogenous bone must generally be obtained through a second incision, which adds to the size and length of the operation and to the blood loss. After removal of a cortical graft from the tibia, the leg must be protected to prevent fracture at the donor site. At times it is not possible to obtain enough autogenous bone to meet the needs of the operation.

If osteogenesis is the prime concern, fresh autogenous bone is the best graft. Autogenous bone is preferable when grafting nonunions of fractures of the long bones. If stability is not required of a graft, cancellous autogenous iliac grafts are superior to autogenous grafts from the tibia. Allografts are indicated in small children, aged persons, patients who are poor operative risks, and patients from whom enough acceptable autogenous bone is not available. Autogenous cancellous bone can be mixed in small amounts with allograft bone as "seed" to provide osteogenic potential. Mixed bone grafts of this type will incorporate more rapidly than allograft bone alone.

To efficiently provide safe and useful allograft material, a bone banking system is required that uses thorough donor screening, rapid procurement, and safe, sterile processing. Standards outlined by the American Association of Tissue Banks must be followed. Donors must be screened for bacterial, viral (including HIV and hepatitis), and fungal infection. Malignancy (except basal cell carcinoma of the skin), collagen-vascular disease, metabolic bone disease, and the presence of toxins are all contraindications to donation.

Nearly one third of all bone grafts used in North America are allografts [18]. Allografts have osteoconductive properties and can serve as substitutes for autografts but carry the risk of disease transmission. The risk for transmission of human immunodeficiency virus (HIV) is 1:1,500,000; for hepatitis C, the risk is 1:60,000; and for hepatitis B, it is 1:100,000 [17].

The U.S. Food and Drug Administration (FDA) requires testing for HIV-1, HIV-2, and hepatitis C; many states require additional testing for hepatitis B core antibody [5]. The American Association of Tissue Banks additionally tests for antibodies to human T-cell lymphotropic virus (HTLV-I and HTLV-II) [18].

4. Growth factors

Growth Factor enhanced grafts are produced using recombinant DNA technology. They consist of either Human Growth Factors or Morphogens (Bone Morphogenic Proteins in conjunction with a carrier medium, such as collagen).

5. Position of bone grafting is harvested

5.1 Sources of cancellous bone

In treating small bone defects secondary to trauma or small tumors, it may be most convenient to harvest the graft from the ipsilateral extremity undergoing operation. The graft can often be taken through the same incision or through a small, separate incision. Most of these sites can be harvested through a small, 2.5 to 5.0 cm longitudinal incision placed over the subcutaneous surface of the end.

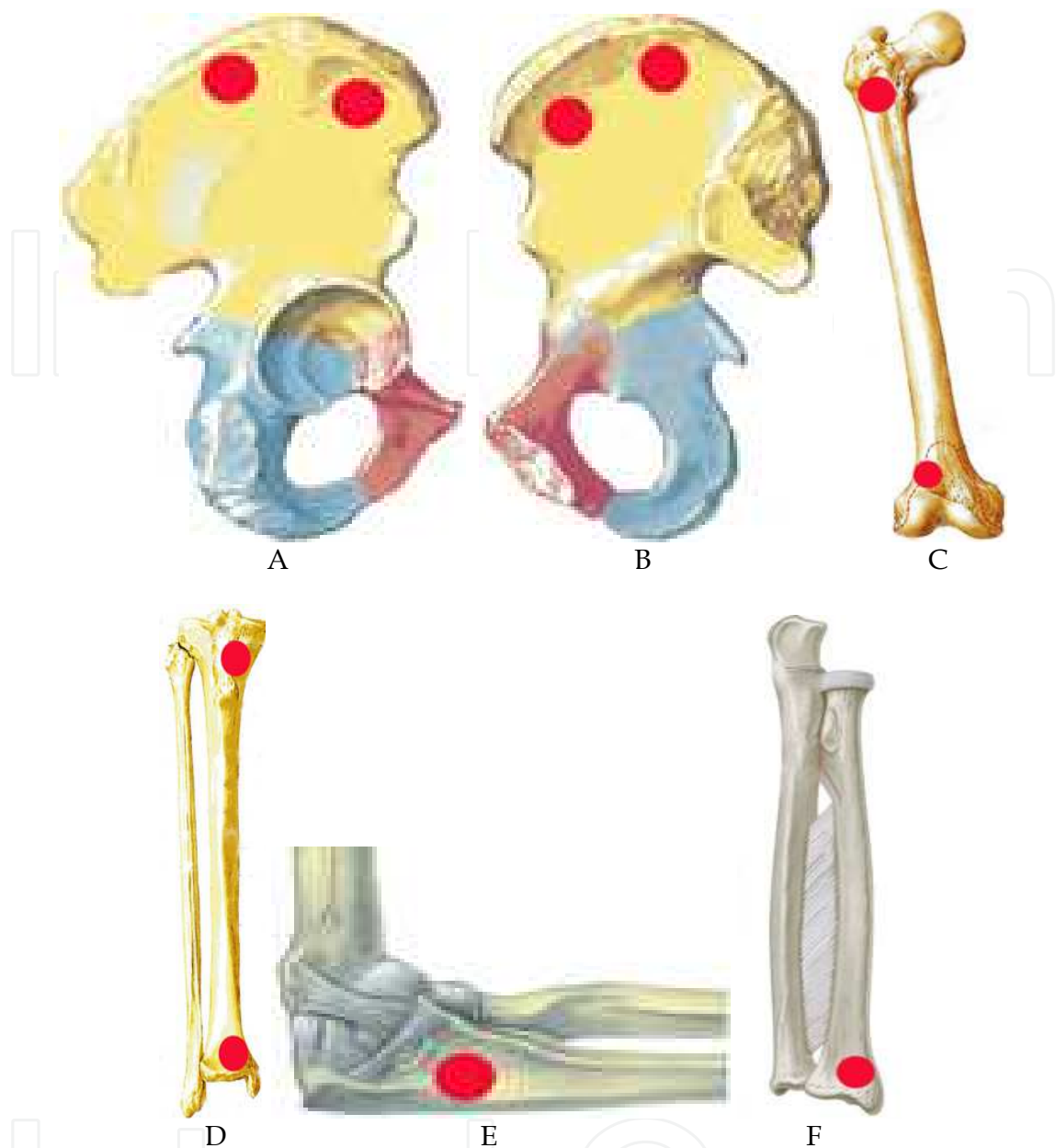


Fig. 1. Peripheral sources of cancellous bone graft are illustrated. If only a small amount of cancellous bone is needed or if it is contraindicated or inconvenient to use the iliac crest, other sites of cancellous bone are the anterior aspect of the greater trochanter and the distal femoral condyle (C), the proximal and distal tibia (D), the olecranon (E), and the styloid of the radius (F).

5.2 Removal of tibial graft

Make a slightly curved longitudinal incision over the anteromedial surface of the tibia, placing it so as to prevent a painful scar over the crest. Because of the shape of the tibia, the graft is usually wider at the proximal end than at the distal [20]. The periosteum over the tibia is relatively thick in children and can usually be sutured as a separate layer. In adults,

however, it is often thin, and closure may be unsatisfactory; suturing the periosteum and the deep portion of the subcutaneous tissues as a single layer is usually wise.

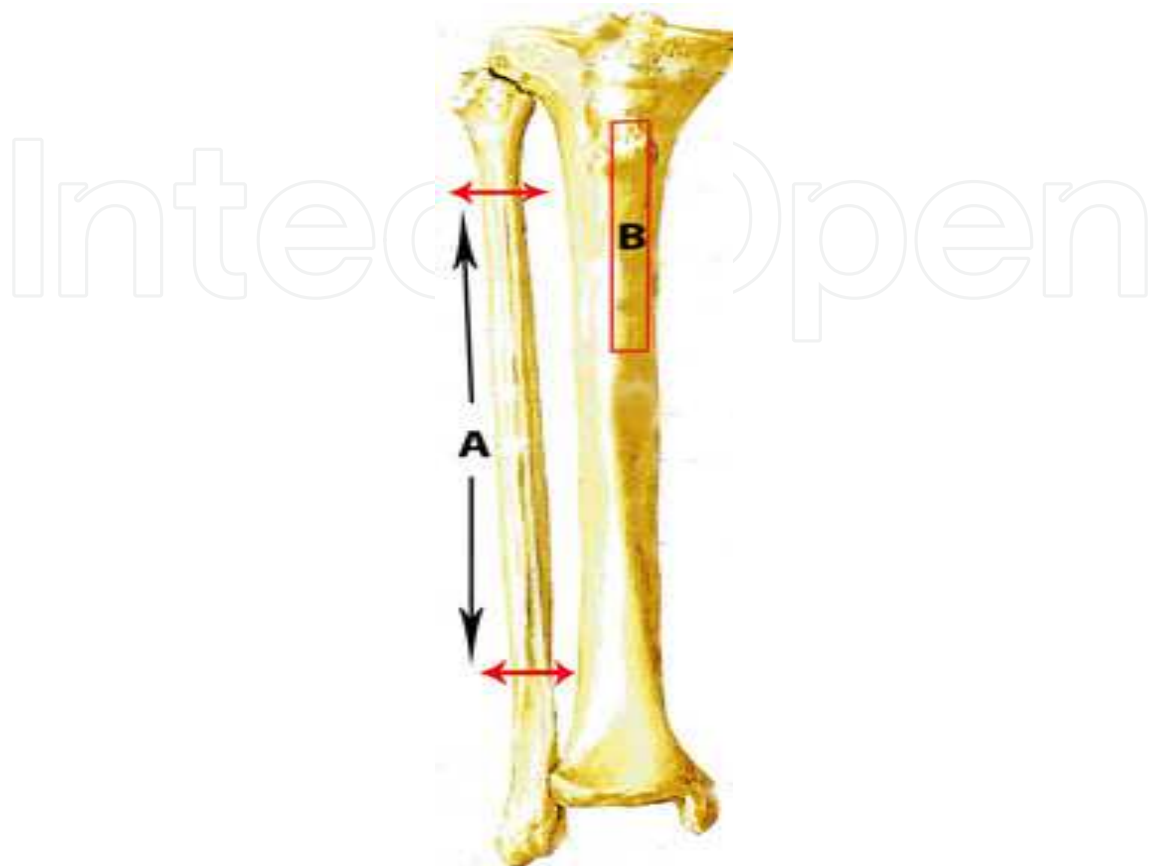


Fig. 2. A – Fibula can be harvested longitudinal bone; B- tibial graft is shown: a large, corticocancellous graft can be removed from the proximal tibia on its anteromedial surface.

5.3 Removal of fibular graft

In the removal of a fibular graft three points should receive consideration: (1) the peroneal nerve must not be damaged; (2) the distal fourth of the bone must be left to maintain a stable ankle; and (3) the peroneal muscles should not be cut.

The entire proximal two thirds of the fibula may be removed without materially disabling the leg. However, a study by Gore et al. indicates that most patients have complaints and mild muscular weakness after removal of a portion of the fibula. The configuration of the proximal end of the fibula is an advantage: the proximal end has a rounded prominence, which is partially covered by hyaline cartilage, and thus forms a satisfactory transplant to replace the distal third of the radius or the distal third of the fibula.

The middle one third of the fibula also can be used as a vascularized free autograft based on the peroneal artery and vein pedicle using microvascular technique. This graft is recommended by Simonis, Shirall, and Mayou for the treatment of large defects in congenital pseudarthrosis of the tibia. Portions of iliac crest also can be used as free vascularized autograft. The use of free vascularized autografts has limited indications, requires expert microvascular technique, and is not without donor site morbidity.

5.4 Removal of iliac bone graft

Ilium

The iliac crest is an ideal source of bone graft because it is relatively subcutaneous, has natural curvatures that are useful in fashioning grafts, has ample cancellous bone, and has cortical bone of varying thickness. Removal of the bone carries minimal risk and usually there is no significant residual disability. The posterior third of the ilium is thickest, and this is confirmed by computer tomography (CT) scans (Fig. 3).

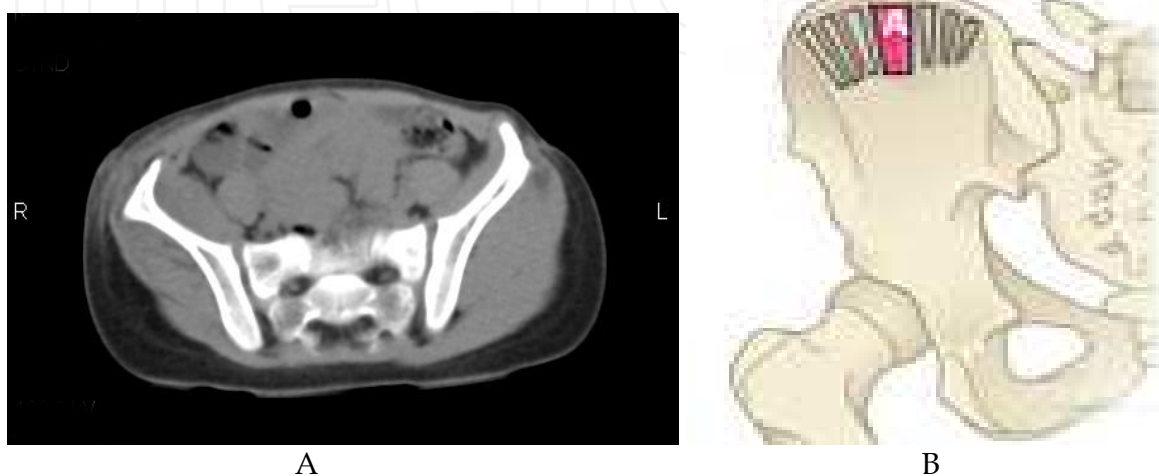

Fig. 3. A: This CT scan of the pelvis at the level of the posterosuperior iliac spine illustrates the thickness of the ilium posteriorly and the amount of cancellous bone available; B: The central section of the ilium at point A is quite thin and is of no use in bone grafting

5.5 Cancellous grafts

Unless considerable strength is required, the cancellous graft fulfills almost any requirement. Regardless of whether the cells in the graft remain viable, clinical results indicate that cancellous grafts incorporate with the host bone more rapidly than do cortical grafts.

Large cancellous and corticocancellous grafts may be obtained from the anterosuperior iliac crest and the posterior iliac crest. Small cancellous grafts may be obtained from the greater trochanter of the femur, femoral condyle, proximal tibial metaphysis, medial malleolus of the tibia, olecranon, and distal radius. At least 2 cm of subchondral bone must remain to avoid collapse of the articular surface.

5.6 Removal of iliac bone graft

When removing a cortical graft from the outer table, first outline the area with an osteotome or power saw. Then peel the graft up by slight prying motions with a broad osteotome.

Wedge grafts or full-thickness grafts may be removed more easily with a power saw; this technique also is less traumatic than when an osteotome and mallet are used. For this purpose an oscillating saw or an air-powered cutting drill is satisfactory. Avoid excessive heat by irrigating with saline at room temperature. Avoid removing too much of the crest anteriorly and leaving an unsightly deformity posteriorly (Figure 4).

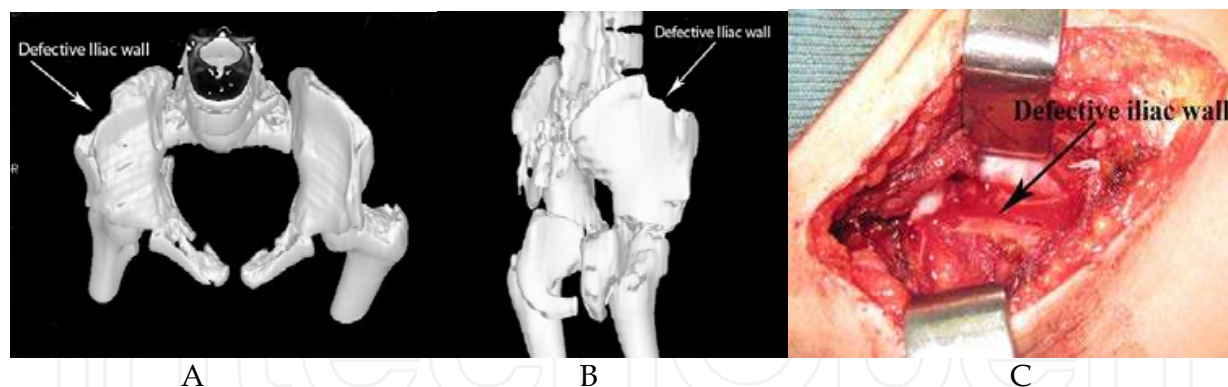


Fig. 4. A: CT scan 3D, Anteroposterior ilium and CT scan 3D, B: oblique posterior ilium with defect in iliac wall after iliac bone is harvested; C: The Iliac wall with defect.

5.7 Posterior iliac grafts

The region of the posterosuperior iliac spine is the best source of cancellous bone.

- Make a straight vertical incision directly over the posterosuperior iliac spine or a curvilinear incision that parallels the iliac crest (Fig. 5). To prevent injury to the cluneal nerves, avoid straight transverse incisions and try not to carry incisions too far laterally. A transverse incision is more likely to result in dehiscence and can be painful if it lies along the belt line.
- Identify the origin and fascia of the gluteus maximus insertion on the crest. With a cautery knife, incise the origin of the gluteus maximus and dissect it free from the crest subperiosteally. If the entire posterior iliac area is to be harvested, take down the gluteus from approximately 2.5 cm superior to the posterosuperior iliac spine and inferior as far as the posteroinferior spine.
- The outer wall of the ilium is removed by first outlining the area to be harvested by cutting through the outer table of the ilium with a sharp osteotome. If an onlay cancellous bone graft is to be performed, harvest corticocancellous strips with a curved gouge. Remove all underlying cancellous bone down to the inner table of the ilium with a curved gouge and curets of an appropriate size.

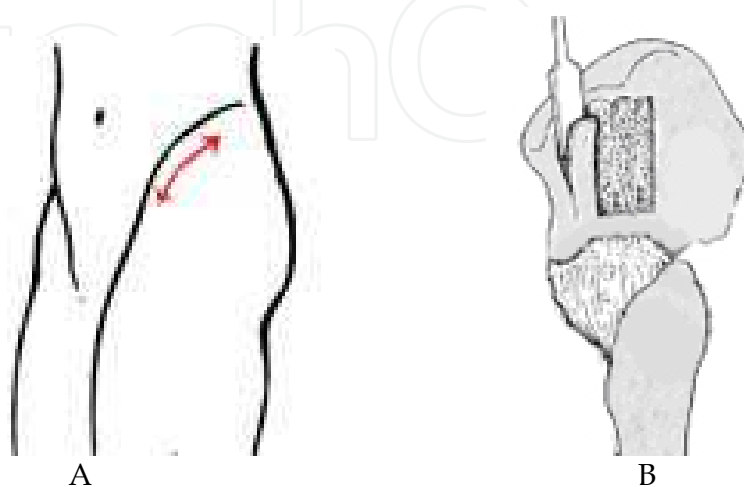


Fig. 5. A: Incision line; B: posterior iliac graft is shown.

5.8 Anterior iliac grafts

Large grafts of cancellous and corticocancellous bone can be harvested from the anterior ilium.

Incise with a cautery knife along the iliac crest, avoiding muscle. Subperiosteally, dissect the abdominal musculature and, subsequently, the iliacus from the inner wall of the ilium.

- Outline the area to be harvested with straight and curved osteotomes. Cut the strips, which will be removed. The middle ilium is paper thin, but the anterior column just above the acetabulum is quite thick.
- Harvest the corticocancellous strips with a gouge.
- Remove additional cancellous bone with gouges and curets. Do not broach the outer table.

5.9 Bicortical grafts

Full-thickness bicortical grafts may be necessary for spinal fusion or for replacement of major bone defects in metaphyseal regions, such as in nonunions of the distal humerus or in opening wedge osteotomies.

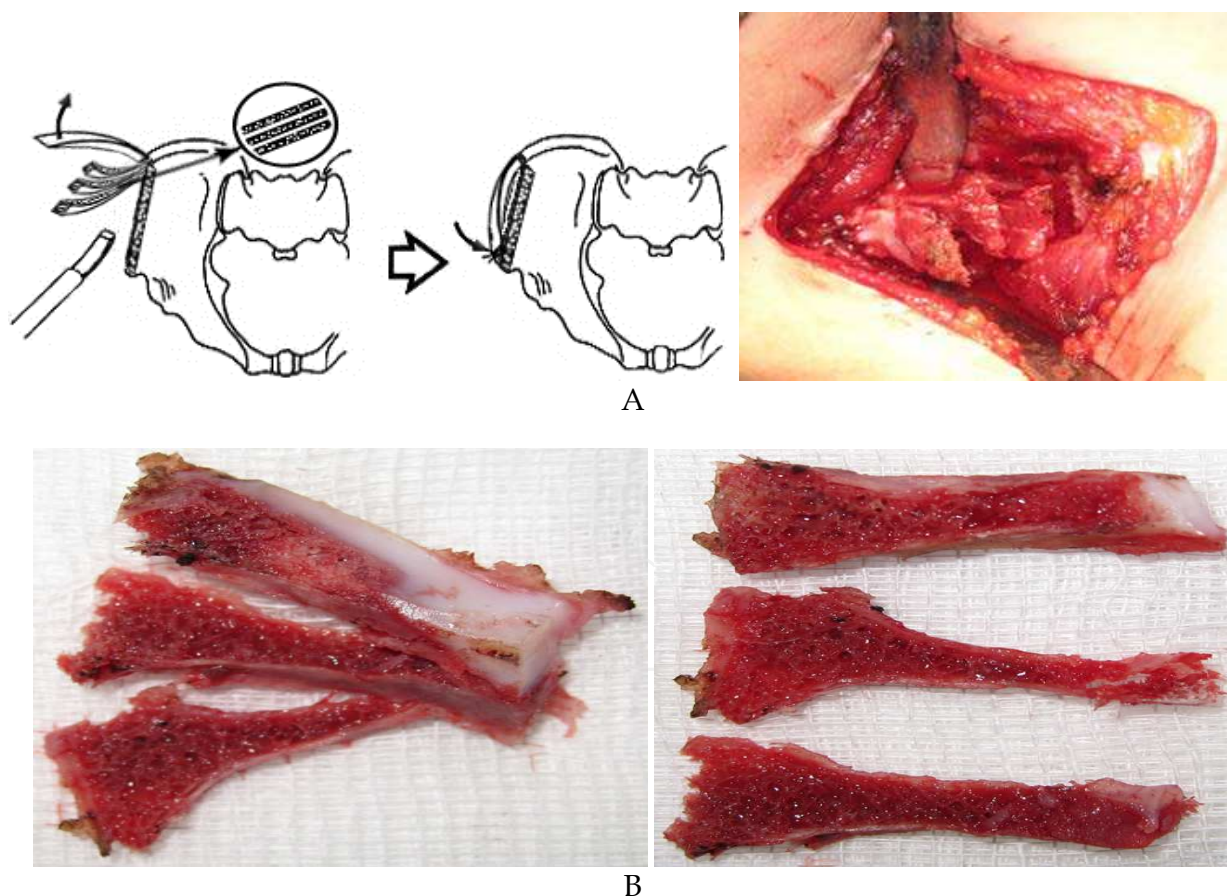


Fig. 6. A and B: Thin bicorticalcancellous grafts is harvested for Congenital pseudarthrosis of the tibia (From Author - Hung NN. Use of an intramedullary Kirschner wire for treatment of congenital pseudarthrosis of the tibia in children. *Journal of Pediatric Orthopaedics B* 2009; 18:79–85 [21])

6. Practical bone grafting

6.1 Bone grafting fundamentals

Bone grafting refers to a wide variety of surgical methods augmenting or stimulating the formation of new bone where it is needed.

There are five broad clinical situations in which bone grafting is performed:

1. To stimulate healing of fractures either fresh fractures or fractures that have failed to heal after an initial treatment attempt.
2. To stimulate healing between two bones across a diseased joint. This situation is called "arthrodesis" or "fusion".
3. To regenerate bone which is lost or missing as a result of trauma, infection, or disease. Settings requiring reconstruction or repair of missing bone can vary from filling small cavities to replacing large segments of bone 12 or more inches in length.
4. To improve the bone healing response and regeneration of bone tissue around surgically implanted devices, such as artificial joints replacements (e.g. total hip replacement or total knee replacement) or plates and screws used to hold bone alignment.
5. To plastical arthrosis of acetabulum (Congenital Dislocation of the Hip or Perthes disease)

6.2 Indications for various techniques

Single Onlay Cortical Grafts. Until relatively inert metals became available, the onlay bone graft was the simplest and most effective treatment for most ununited diaphyseal fractures. Usually the cortical graft was supplemented by cancellous bone for osteogenesis. The onlay graft is still applicable to a limited group of fresh, malunited, and ununited fractures and after osteotomies.

Cortical grafts also are used when bridging joints to produce arthrodesis, not only for osteogenesis but also for fixation. Fixation as a rule is best furnished by internal or external metallic devices. Only in an extremely unusual situation would a cortical onlay graft be indicated for fixation, and then only in small bones and when little stress is expected. For osteogenesis the thick cortical graft has largely been replaced by thin cortical and cancellous bone from the ilium.

The single-onlay cortical bone graft was used most commonly before the development of good quality internal fixation and was employed for both osteogenesis and fixation in the treatment of nonunions (Fig. 7).

Dual Onlay Grafts. Dual onlay bone grafts are useful when treating difficult and unusual nonunions or for the bridging of massive defects. The treatment of a nonunion near a joint is difficult, since the fragment nearest the joint is usually small, osteoporotic, and largely cancellous, having only a thin cortex. It is often so small and soft that fixation with a single graft is impossible because screws tend to pull out of it and wire sutures cut through it. Dual grafts provide stability because they grip the small fragment like forceps.

The advantages of dual grafts for bridging defects are as follows: (1) mechanical fixation is better than fixation by a single onlay bone graft; (2) the two grafts add strength and stability;

(3) the grafts form a trough into which cancellous bone may be packed; and (4) during healing the dual grafts, unlike a single graft, prevent contracting fibrous tissue from compromising transplanted cancellous bone.

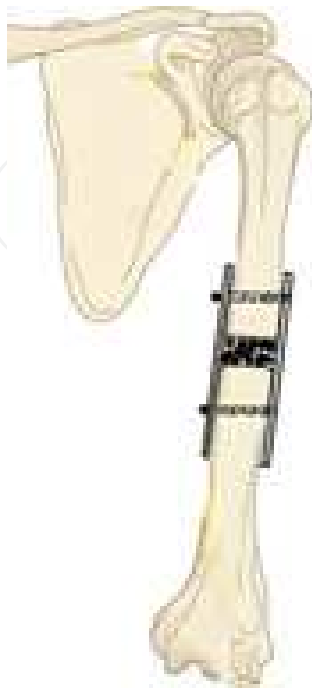

Fig. 7. A single-onlay cortical bone graft is shown for humeral pseudarthrose.

The disadvantages of dual grafts are the same as those of single cortical grafts: (1) they are not as strong as metallic fixation devices; (2) an extremity must usually serve as a donor site if autogenous grafts are used; and (3) they are not as osteogenic as autogenous iliac grafts, and the surgery necessary to obtain them has more risk.

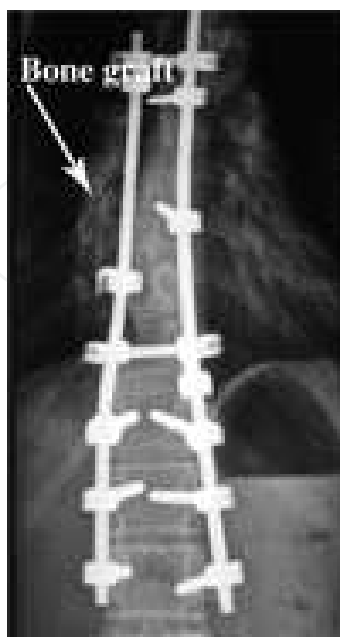


Fig. 8. Cortical cortical cancellous bone graft is harvested from Ilium for scoliosis

Inlay Grafts. By the inlay technique a slot or rectangular defect is created in the cortex of the host bone, usually with a power saw. A graft the same size or slightly smaller is then fitted into the defect. In the treatment of diaphyseal nonunions, the onlay technique is simpler and more efficient and has almost replaced the inlay graft. The latter is still occasionally used in arthrodesis, particularly at the ankle.

Albee popularized the inlay bone graft for the treatment of nonunions [22, 23]. Inlay grafts are created by a sliding technique, graft reversal technique, or as a strut graft. Although originally designed for the treatment of nonunion of the tibia, these techniques are also used for arthrodesis and epiphyseal arrest.

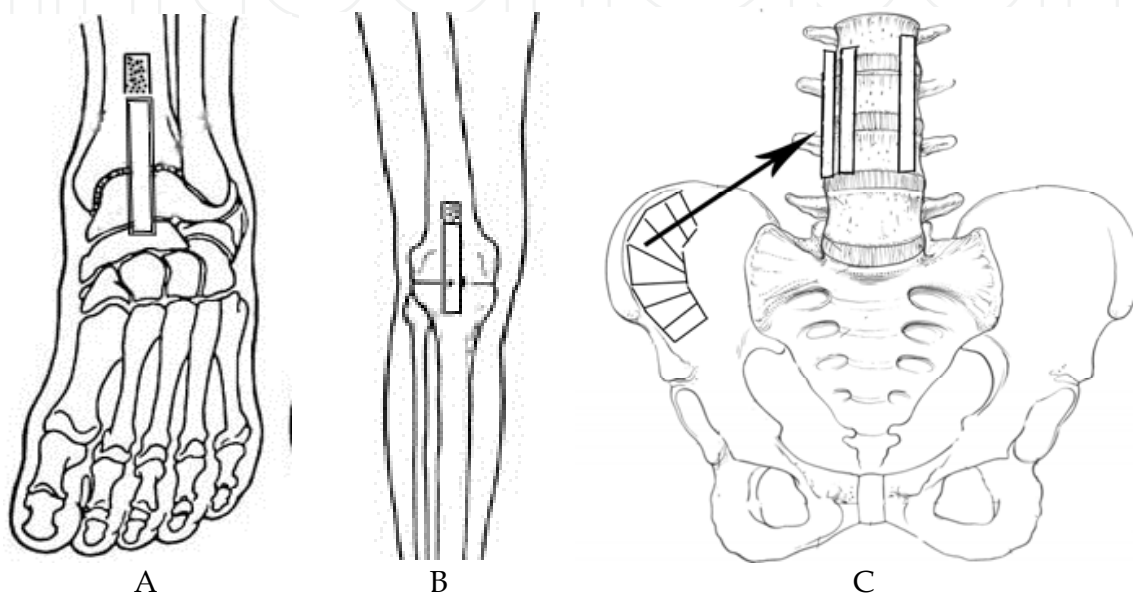


Fig. 9. A-C. A: In this case, a sliding graft is used as a component of ankle arthrodesis. This type of graft is more likely to be used for a previously failed ankle fusion or for fusion in the absence of the body of the talus; B: a sliding graft is used as a component of knee arthrodesis. This type of graft is more likely to be used for a previously failed knee fusion; C: Strut grafts for anterior spinal fusion. Strut grafts are very useful for bridging defects in the anterior spine and for providing support for anterior spinal fusion. Grafts from the ribs, fibula, and bicortical iliac crest are useful for strut grafting, depending on the size of the graft needed.

Dormans et al. reviewed their experience with the treatment of fourteen children who had osteoblastoma. The mean age at the time of diagnosis was nine years, and the lesions were most frequently seen in the lower extremities (43%) or the spine (36%). The patients were treated with open incisional biopsy and intralesional curettage, and those with a spinal lesion were also treated with spinal fusion and instrumentation. The local recurrence rate was 28%, and all recurrences were in young children who were less than six years of age.

7. Tumor

Medullary Grafts. Medullary bone grafts were tried early in the development of bone grafting techniques for nonunion of the diaphyseal fractures. Fixation was insecure, and healing was rarely satisfactory. This graft interferes with endosteal circulation and consequently can interfere with healing.

Medullary grafts are not indicated for the diaphysis of major long bones. Grafts in this location interfere with restoration of endosteal blood supply; because they are in the central axis of the bone, they resorb rather than incorporate. The only possible use for a medullary graft is in the metacarpals and the metatarsals, where the small size of the bone enhances incorporation. Even in this location, however, internal fixation with onlay or intercalary cancellous bone grafting may be a superior method.

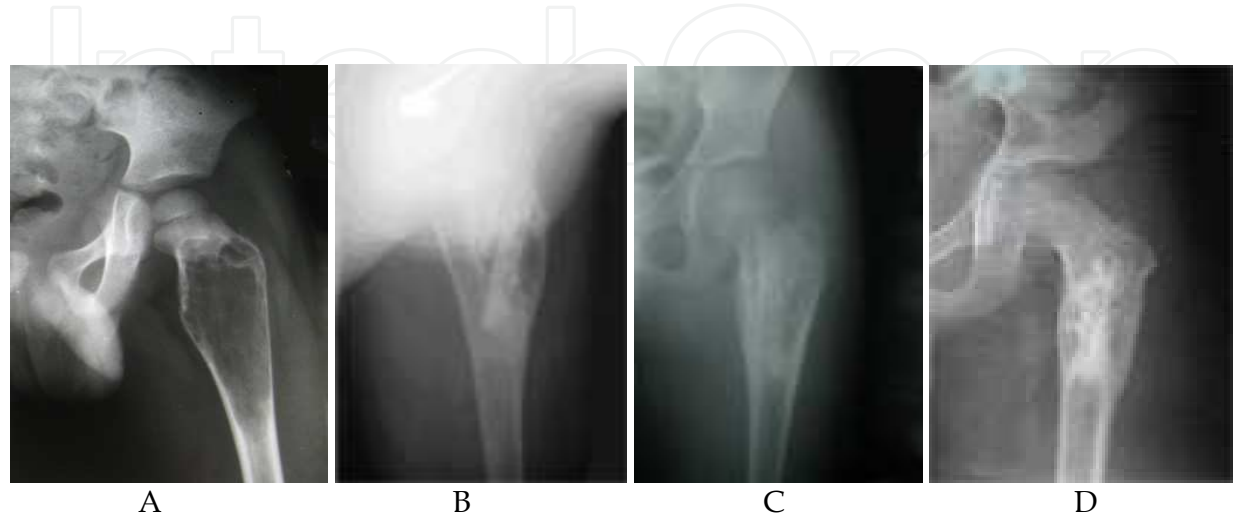

Fig. 10. A - D. A: Anteroposterior radiographs show an Giant cell tumor in proximal femur of 7-year-old child. B: the cavity of the proximal femur after curettage and the fibula strut autograft in cavity and the cavity is completely packed with particulate autograft around the fibula strut; C: Eight month after operation; D: Twenty-six months after operation, remodeling of bone tissue is evident.

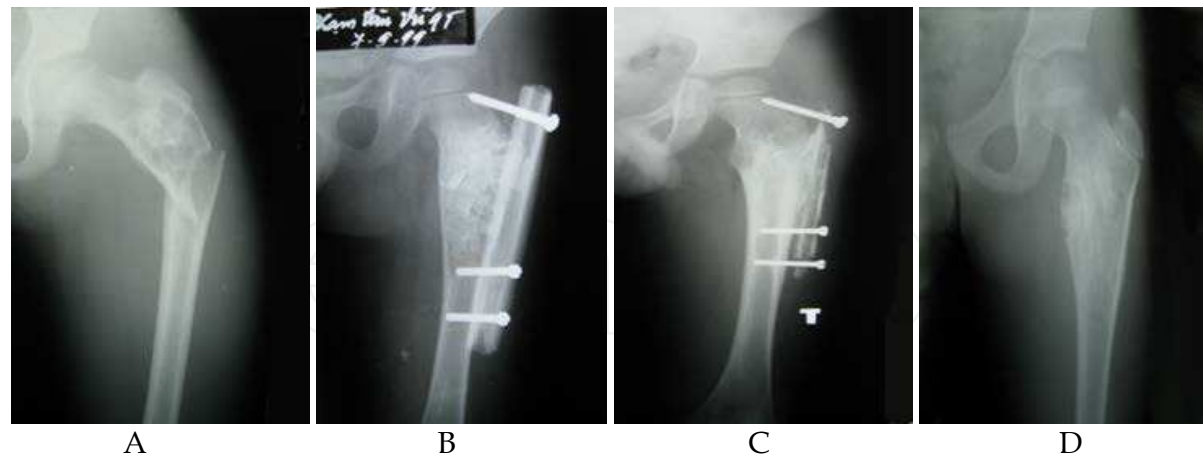


Fig. 11. A - D. A: Anteroposterior radiographs show an osteoblastoma with an associated aneurysmal bone cyst and pathology fracture in the neck and proximal femu; B: the cavity of the neck and proximal femur after curettage and the fibula strut allograft in lateral femur, the cavity is shown after being completely packed with particulate bone graft; C: Anteroposterior radiographs show postoperative result 28 months; D: Roentgenogram at 9 years follow-up showing incorporation of graft, remodeling, and full range of motion of hip joint.

7.1 Osteoperiosteal grafts

In osteoperiosteal grafts, the periosteum is harvested with chips of cortical bone. These grafts have not been proven to be superior to onlay cancellous bone grafting, are more difficult than cancellous bone to harvest, and may involve greater morbidity; they are rarely used today.

7.2 Pedicle grafts

Pedicle grafts may be local [24] or moved from a remote site using microvascular surgical techniques. In local muscle-pedicle bone grafts, an attempt is made to preserve the viability of the graft by maintaining muscle and ligament attachments carrying blood supply to the bone or, in the case of diaphyseal bone, by maintaining the nutrient artery. Two examples are the transfer of the anterior iliac crest on the muscle attachments of the sartorius and rectus femoris for use in the Davis type of hip fusion and the transfer of the posterior portion of the greater trochanter on a quadratus muscle pedicle for nonunions of the femoral neck [25-27].

Osteoperiosteal Grafts. Osteoperiosteal grafts are less osteogenic than multiple cancellous grafts and are now rarely used.

Multiple Cancellous Chip Grafts. Multiple chips of cancellous bone are widely used for grafting. Segments of cancellous bone are the best osteogenic material available. They are particularly useful for filling cavities or defects resulting from cysts, tumors, or other causes, for establishing bone blocks, and for wedging in osteotomies. Being soft and friable, this bone can be packed into any nook or crevice. The ilium is a good source of cancellous bone, and if some rigidity and strength are desired, the cortical elements may be retained.

In most bone-grafting procedures that use cortical bone or metallic devices for fixation, supplementary cancellous bone chips or strips are used to hasten healing. Cancellous grafts are particularly applicable to arthrodesis of the spine, since osteogenesis is the prime concern [28].

Hemicylindrical Grafts. Hemicylindrical grafts are suitable for obliterating large defects of the tibia and femur. A massive hemicylindrical cortical graft from the affected bone is placed across the defect and is supplemented by cancellous iliac bone. A procedure of this magnitude has only limited use, but it is applicable for resection of bone tumors when amputation is to be avoided.

The fibula provides the most practical graft for bridging long defects in the diaphyseal portion of bones of the upper extremity, unless the nonunion is near a joint. A fibular graft is stronger than a full-thickness tibial graft, and when soft tissue is a wound that could not be closed over dual grafts may be closed over a fibular graft.

7.3 Sliding graft

This technique is rarely used today, because internal fixation combined with onlay cancellous bone graft provides a better result. This technique may be combined with internal fixation if there is limited space to place a cancellous graft. The disadvantages of the sliding or reversed bone graft are that, after the cuts are made, the graft fits loosely in the bed, and it creates stress risers proximally and distally to the nonunion site

7.4 Peg and Dowel grafts

Dowel grafts were developed for the grafting of nonunions in anatomic areas, such as the scaphoid and femoral neck, where onlay bone grafting was impractical. In the carpal scaphoid, the dowel is fashioned from dense cancellous bone. The use of the dowel graft for the management of nonunion of the femoral neck. Free microvascularized fibula grafts are more commonly used today. A corticocancellous graft of appropriate length and approximately 25 mm wide is harvested from the ilium or the tibia. The curvature of the ilium often makes it difficult to obtain a straight graft of sufficient length.

7.5 Fibular bone grafting for defect of tibia cause osteomyelitis

The rules of bone grafting for long defects in the diaphyseal portion of extremity due to osteomyelitis are: (1). General status is stable: ESR: < 10 mm/h; CRP: < 10 mg/L ; WBC: < 10,000; Neutrophil: < 60%; (2) Local extremity with bone defect: no swelling, no hot-temperature, no pain, and no pus fistula for at least 3 months; (3) Remove sclerosis bone until bone bleeding; (4) Solid fixation of bone graft into bone bed by Kirschner wire or plate and screw and plaste cast ; (5) The Kirschner wire will be removed when clear clinical and radiographic evidence of solid union were apparent (mean more than 18 months); and (6) Prolonged orthotic protection was required when ankle transfixation had been performed and A knee-ankle-foot orthosis was worn until the patient reached skeletal maturity.

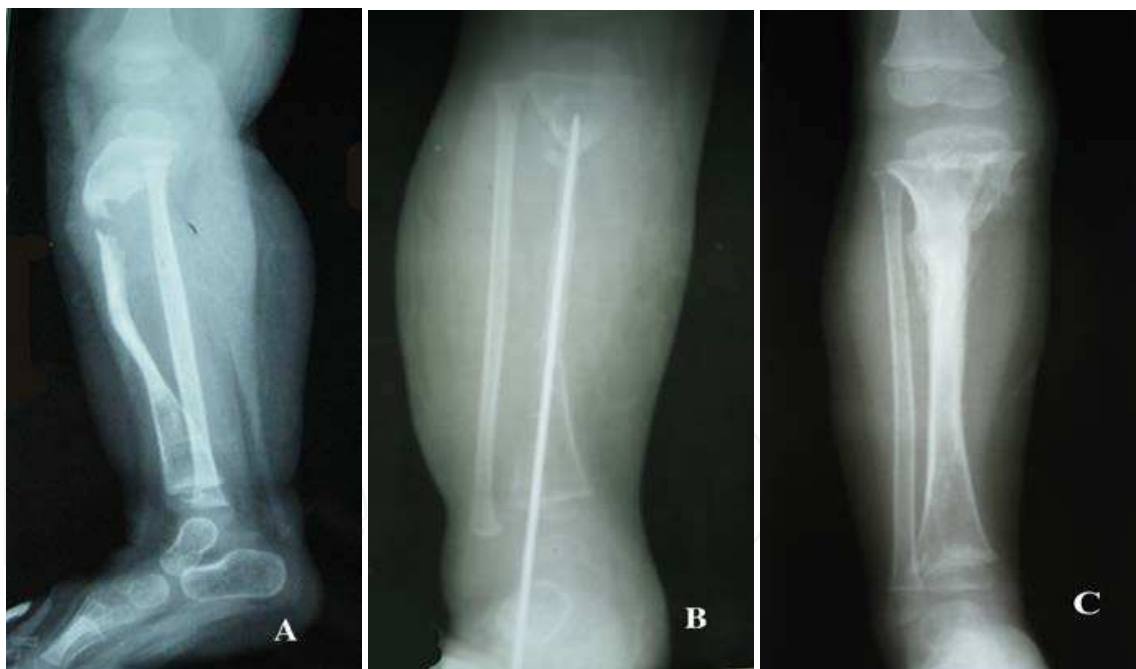

Fig. 16. A-C: A: Preoperative bone grafting; B: Postoperative 6 months; C: Postoperative 5 years 9 months.

7.6 Dual-onlay cortical cancellous bone graft is harvested Ilium for congenital pseudarthrosis of the tibia

The rules of bone grafting for Congenital Tibial Pseudarthrosis: (1) The bone and fibrous tissue at the site of the pseudarthrosis are excised completely until normal bone of the

tibial shaft; (2) The medullary canal of both tibial fragments is reamed with a drill or a small curet, or both; (3) The autogenous iliac crest bone graft was applied to anterolateral and posterior part of the tibia; (4) Solid fixation bone graft into bone bed by Kirschner wire or plate and screw and plaster cast; (5) The needed length of the Kirschner wire is calculated on the basis of the expected length of the leg after the affected bone and fibrous tissues have been removed and after the angular deformity has been corrected; (6) The Kirschner wire will be removed when solid clinical and radiographic union were apparent (mean more than two years); and (7) Prolonged orthotic protection was required when ankle transfixation had been performed and a knee-ankle-foot orthosis was worn until the patient reached skeletal maturity.

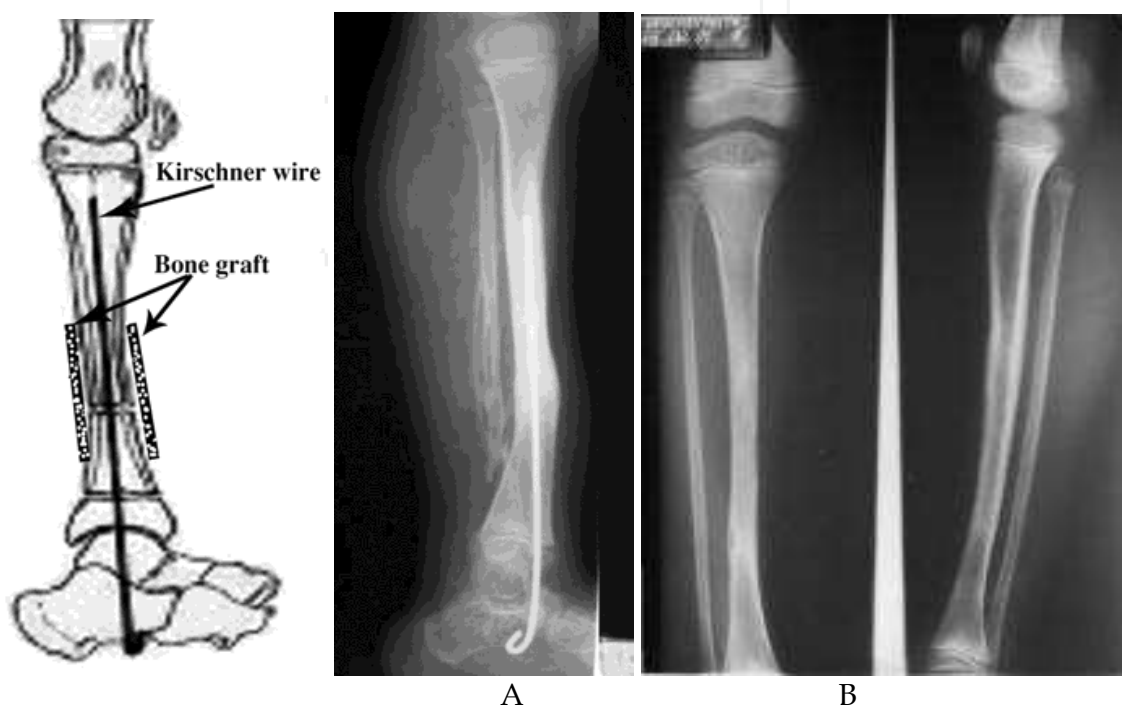

Fig. 17. A. Postoperative 6 months; B. Postoperative union of Pseudarthrosis 12 years 8 months (From Author - Hung NN. Use of an intramedullary Kirschner wire for treatment of congenital pseudarthrosis of the tibia in children. *Journal of Pediatric Orthopaedics B* 2009; 18:79–85 [21]).

8. Complications

Complications for grafts from the iliac crest

Some of the potential risks and complications of bone grafts employing the iliac crest as a donor site include:

8.1 Anterior Ilium

Pain

Pain after bone graft harvest from the anterior ilium has multiple origins. It can result from hematoma, wound infection, neuropraxia of cutaneous nerves, stress fracture, or from the

dissection itself. Pain, from whatever the source, has been noted to last on average 3.75 weeks. In 90% of patients, symptoms resolve in less than 1 month but 2.8% may have persistent pain lasting over 3 months [29]

Cosmesis

Obtaining bone from the anterior ilium most often requires an additional incision from the recipient site incision. The overall cosmesis has been rated as good in 86.1%, fair in 10.4% and poor in 3.5%. Additionally, it has been observed that worse ratings are given by women and those who are obese [29]. Methods to improve cosmesis include using a trap door or subcrestal window technique to remove the graft allowing for preservation of the natural contour of the ilium [30]

Wound healing

Wound healing complications are not uncommon after bone graft harvest and have multiple origins, including infection, hematoma and wound dehiscence. Even with the use of thrombin-soaked gel foam and bone wax, residual bleeding often occurs from the cancellous bone. Studies have shown the presence of hematomas in 4-10% of patients [30]. Additionally, multiple vessels, including the deep circumflex, iliolumbar, and fourth lumbar arteries, may be damaged.

Nerve damage

Injury to the lateral femoral cutaneous and the ilioinguinal nerves is not an uncommon complication from anterior graft harvest. Meralgia paresthetica may occur when the lateral femoral cutaneous nerve is injured. There are three origins of injury to this nerve: neurotmesis of the nerve as it crosses the crest, neuropraxia from retraction of the iliacus and crush injury during stripping of the outer table muscles [30]. Symptoms include pain and numbness over the anterolateral thigh immediately postoperatively, and these symptoms are commonly worse with walking [31]. For this reason it is recommended to stop the skin incision and dissection 2 cm lateral to the ASIS.

Hernia

Herniation of abdominal contents through a bone graft site has been reported and can be a potentially serious complication requiring reoperation [30]. Abdominal wall muscles attach to the iliac crest and prevent abdominal contents from migrating over the crest, and the iliacus muscle prevents contents from penetrating through a defect in the iliac wing. The hernia forms when there has been a violation of these muscles with an inadequate repair [30]. It can be diagnosed clinically with confirmation by CT scan.

Pelvic fracture

The sartorius and tensor fascia lata originate on the ASIS and have been reported to cause an avulsion fracture to the ASIS. Hu and Bohlman [32] examined this and found that a graft taken 30mm posterior to the ASIS was 2.4 times the strength of a graft taken at 15mm. Therefore, it is recommended that any vertical cut into the ilium be at least 3 cm posterior to the ASIS [33]. Osteoporotic, elderly women have been found to be at a higher risk for this complication [34].

Gluteal gait

A gluteal gait is an abductor lurch seen as a result of abductor weakness, especially the gluteus medius. This may be found in up to 3% of patients after graft harvest [30]. Its incidence can be minimized through a less extensive stripping of the outer table muscles of the ilium and by careful reapproximation and secure reattachment of the gluteal fascia to the periosteum.

8.2 Posterior Ilium

Pain

Chronic pain, hyperesthesia and dysesthesia are among the most common complaints after posterior iliac bone graft harvest. Studies have shown that 29% of patients complain of chronic pain for longer than 1 year. It also has been shown that patients who have the bone graft taken for spinal reconstruction surgery have twice the incidence of pain compared with those who have the graft taken for spinal trauma purposes.

Hematoma or wound Infection

Hematomas have been found to be less problematic with posterior compared with anterior iliac graft harvests. This is thought to be secondary to the hemostatic effect of the body placing pressure on the surgical site.^{3,6} Although this may decrease hematoma formation, it has been observed that more than 10% of patients present with wound healing problems. Although the overall majority of complications are mild to moderate wound dehiscence, a 2.7% deep infection rate has been observed that required treatment with intravenous antibiotics [35].

Nerve injury

The nerves most commonly at risk are the superior cluneal nerves. Injury to the superior cluneal nerves may result in pain, hyperesthesia or paresthesia of the buttock region [30]. These nerves pierce the lumbodorsal fascia and cross the posterior iliac crest 6-8 cm lateral to the PSIS. They travel in the inferolateral direction [36, 37]. These nerves are intimately associated with the lumbodorsal fascia making their identification difficult. Previously it was believed that a vertical midline incision avoided the superior cluneal nerves and resulted in less postoperative pain than a lateral oblique incision. Fernyhough et al [36] failed to show a statistically significant difference in pain between the use of the lateral oblique incision and the vertical incision, thus concluding that either approach is appropriate.

Vascular injury

The superior gluteal artery exits the sciatic notch in the superior most portion and sends branches to the gluteal muscles. Careless placement of a retractor or removal of graft from the sciatic notch may result in laceration of the artery or arteriovenous fistula formation [30, 36]. In a cadaver study by Xu et al [37] the anatomic distances between the superior gluteal vessels and the pelvic landmarks were measured. The vessels were found to be an average of 62mm from the PSIS and 102mm from the iliac crest [37]. Injury can best be avoided by knowing the anatomy. The inferior margin of the roughened area just anterior and lateral to

the PSIS should be the caudal limit for bone harvest, and should a retractor be used, it should not be blindly inserted into the sciatic notch. When vascular injury occurs, the artery may retract into the pelvis making visibility difficult.

Sacro-iliac (SI) joint instability

Cases of instability and dislocation of the SI joint have been reported after posterior iliac bone harvest. There are many ligaments that make up the SI joint complex. Most notably are the dense interosseous ligaments that are more numerous superiorly and offer the primary support. In addition, there are the short and long posterior ligaments and the thin anterior ligaments, which assist in the support. Compromise of these ligaments can result in instability and over time may result in pubic rami fractures and possible dislocation of the SI joint [38]

Ureteral injury

Ureteral injury is a very rare complication but important because of its severity. The ureters run deep through the sciatic notch and use of electrocautery or careless placement of a retractor can cause injury. Presenting symptoms may include fever, ileus, hematuria and hydronephrosi [30, 36].

8.3 Proximal tibial graft

Fracture

The most feared complication of tibial bone graft is the risk of fracture. O'Keeffe et al [39] reported one nondisplaced fracture of the tibial eminence. This was treated with nonweightbearing in a knee immobilizer and healed without further complication. Thor [40] and Van Damme and Merckx [41] reported fractures of the tibial metaphysis in the early postoperative period [42]. One was after a fall and required operative fixation. The other two were secondary to running and playing tennis, which led to the recommendation that impact activities and sports be avoided for 4-6 weeks postoperatively.

Removal of fibular graft

In the removal of a fibular graft three points should receive consideration: (1) the peroneal nerve must not be damaged; (2) the distal fourth of the bone must be left to maintain a stable ankle; and (3) the peroneal muscles should not be cut. (4) Nonunion of fibula is removed.

Peroneal injury

If the transplant is to substitute for the distal end of the radius or for the distal end of the fibula, resect the proximal third of the fibula through the proximal end of the Henry approach and take care to avoid damaging the peroneal nerve. Expose the nerve first at the posteromedial aspect of the distal end of the biceps femoris tendon and trace it distally to where it winds around the neck of the fibula. In this location the nerve is covered by the origin of the peroneus longus muscle. Peroneal injury could be reduction of movement some anterolateral leg muscles.

Knee instability

With the back of the knife blade toward the nerve, divide the thin slip of peroneus longus muscle bridging it. Then displace the nerve from its normal bed into an anterior position. As

the dissection continues, protect the anterior tibial vessels that pass between the neck of the fibula and the tibia by subperiosteal dissection. After the resection is complete, must to suture the biceps tendon and the fibular collateral ligament to the adjacent soft tissues to create knee stability.

Ankle instability

If the distal fourth of the bone is removed, must be left to maintain a stable ankle by apply a cast from below the knee to the base of the toes or distal tibia-fibula fixation by screw. The cast or screw were removed when solid clinical and radiographic fibular union was apparent

Muscular weakness after removal of a portion of the fibula

The entire proximal two thirds of the fibula may be removed without materially disabling the leg. However, a study by Gore et al [43] indicates that most patients have complaints and mild muscular weakness after removal of a portion of the fibula. The configuration of the proximal end of the fibula is an advantage: the proximal end has a rounded prominence, which is partially covered by hyaline cartilage, and thus forms a satisfactory transplant to replace the distal third of the radius or the distal third of the fibula. After transplantation the hyaline cartilage probably degenerates rapidly into a fibrocartilaginous surface; even so, this surface is preferable to raw bone.

9. Complications of allograft

Nonunion

Nonunion, by convention, implies nonhealing of the graft-host junction at 1 year and has been reported from 11 to 30% [44 - 47]. Factors that have been implicated are age (older age), type of graft (highest in arthrodesis), location (worse for diaphyseal junction), stage of disease (higher for stage 2 or 3), requirement of adjuvant therapy (higher for chemotherapy or radiotherapy), infection, fracture, type and stability of fixation, and revision surgery (worse as number of procedures increase) [44, 47, 48]. Infection and fracture rates are higher in patients with nonunions and subsequent outcomes are poorer. Apart from these mechanical reasons, immunological response may also play a part in nonunion [44, 49]. To treat nonunions, various procedures have been recommended, including autogenous bone graft, double plating for stable fixation, and vascularized fibular grafts [44].

Fractures

Allograft fracture has been seen in 12-54% of cases, depending on the variables involved and the definition of fracture [49 - 55]. Fractures generally occur after 6 months, around the time of revascularization; most fractures (75%) occur during the first 3 years of implantation [51]. Chemotherapy, radiation, cortical penetrating internal fixation, nonunion at host-graft junction, infection, type of graft (higher for osteoarticular and arthrodesis transplant), location (more for femur), gap more than 2 mm, and larger grafts (more than 14.5 cm) have been linked with fracture in various studies [15, 47, 51, 53 - 58].

Infection

Infection is the most devastating complication after allograft transplant, often the leading cause of graft failure. It is associated with other complications and a worse outcome. The

incidence has been reported to be 9–30% [45, 59 - 64]. About 75% were diagnosed within the first 4 months after implantation in the study by Lord et al. [62] and 70% within the first month in a study by Dick and Strauch [61]. Polymicrobial infection may be present in 50% of the cases and *Staphylococcus epidermidis* may be the most common single organism [61, 63]. Factors associated with local wound problems are an extensive surgery (tumor stage, more bone, soft tissue or skin loss, duration of surgery, postoperative hematoma or drainage), adjuvant therapy, the patient's immune status and multiple surgeries [61, 63]. Late infection is unrelated to adjuvant therapy and may happen anytime [65].

Graft disease transmission

Donor screening is the first step in preventing the use of contaminated grafts [66]. Both the FDA and AATB have detailed guidelines regarding the medical history as well as clinical test results of the donor. Screening is currently done for HIV, hepatitis B virus, hepatitis C virus, human transmissible spongiform encephalopathy, syphilis, human T-lymphotropic virus, and cytomegalovirus. Bone allograft contamination is rare, and in a previous study had been estimated to be less than 0.3% [67]. The number of actual infections from allografts is very low: two reports of HIV in 1988, 1992; three reports of hepatitis, hepatitis B in 1954, hepatitis C in 1992, 1993. and one fatal *Clostridium* transmission in 1995 [68]. When examining graft tissue, however, one study reported five (18.5%) of 27 femoral heads from live donors and three (37.5%) of eight allografts from cadavers to be infected [69].

10. Conclusion

Autogenous bone graft continues to be the gold standard for the filling of bone defects in spinal surgery, trauma and treatment of malunions, nonunions and tumors. Each site of autologous bone graft has its advantages and disadvantages, including the anatomic location, which may make one site preferable over another, depending on the graft recipient site. With the increasing use of bone substitutes, it is important to understand all the risks of autogenous bone harvest before possibly exposing a patient to one of the rare but potentially serious complications.

In 2005, over 0.8 million bone and tissue allografts were distributed in the United States [70]. All orthopedic surgeons should understand not only the biologic properties of grafts, but also the methods and regulation of tissue collection. In 85% of the 340 surveyed institutions, grafts were selected by nonorthopedic personnel [45]. It is incumbent on the surgeon to make an informed decision in order to achieve the best outcome each time an allograft is used.

11. Acknowledgements

I would like to thank assistance of our two research assistants in the Orthopaedic Department at National Hospital for Paediatrics, Dr. Le Tuan Anh and Dr. Hoang Hai Duc are greatly appreciated in general assistance in manuscript preparation.

In particular, I thank Dr. Tran Phan Ninh and Dr. Do Thanh Tung in the Diagnostic Imaging Department at National Hospital for Paediatrics for the enormous effort they put in to locate suitable illustrations for the book by sifting through thousands of images.

I am grateful to my wife, Do Ngoc Yen, and my daughters, HienTan and HongCuong, for tolerating my absences to the study to put those ramblings onto the computer.

12. Dedication

To my dearest wife, Do Ngoc Yen, and my daughters, HienTan and HongCuong, who have accepted, with great tolerance and understanding, the lack of a husband and father due to firstly the demands of a medical career and secondly to help prepare this text.

13. References

- [1] Harkins HN, Phemister DB. Simplified Technic of Onlay Grafts. JAMA. 1937;109:1501
- [2] Phemister DB. The Fate of Transplanted Bone and Regenerative Power of Its Various Constituents. Surg Gynecol Obstet 1914;19:303
- [3] Abbott LC, Schottstaedt ER, Saunders JB, et al. The Evaluation of Cortical and Cancellous Bone as Grafting Material. A Clinical and Experimental Study. J Bone Joint Surg. 1947; 29:381 - 414
- [4] Ray RD, Sabet TY. Bone Grafts: Cellular Survival Versus Induction. J Bone Joint Surg. 1963;45-A: 337 - 344
- [5] Arora BK, Laskin DM. Sex Chromatin as a Cellular Label of Osteogenesis by Bone Grafts. J Bone Joint Surg. 1964; 46-A: 1269 - 1276
- [6] Ray RD. Vascularization of Bone Grafts and Implants. Clin Orthop. 1972; 87: 43 - 51
- [7] Chase SW, Herndon CH. The Fate of Autogenous and Homogenous Bone Grafts: A Historical Review. J Bone Joint Surg. 1955; 37-A: 809 - 841
- [8] Delloye C, Verhelpen M, d' Hemricourt J, et al. Morphometric and Physical Investigations of Segmental Cortical Bone Autografts in Canine Ulnar Defects. Clin Orthop. 1992; 282: 273 - 885
- [9] Enneking WF, Morris JL. Human Autologous Cortical Bone Transplants. Clin Orthop. 1972; 87: 28 - 39
- [10] Enneking WF, Burchardt H, Puhl J, et al. Physical and Biologic Aspects of Repair in Dog Cortical Bone Transplants. J Bone Joint Surg. 1975; 57-A: 237 - 252
- [11] Burchardt H, Glowczewskie FP, Enneking WF. Allogenic Segmental Fibular Transplants in Azathioprine-immunosuppressed Dogs. J Bone Joint Surg. 1977; 59-A: 881-894.
- [12] Brien RE, Terek RM, Healey JH, Lane JM. Allograft Reconstruction after Proximal Tibial Resection for Bone Tumors. Clin Orthop. 1994; 303: 116 - 128
- [13] Buttermann GR, Glazer PA, Bradford DS. The Use of Bone Allografts in the Spine. Clin Orthop. 1996; 324: 75 - 89
- [14] Gross AE, Silverstein EA, Fal J, et al. The Allotransplantation of Partial Joints in the Treatment of Osteoarthritis of the Knee. Clin Orthop. 1975;108:7 - 21
- [15] Ottolenghi CE. Massive Osteoarticular Bone Grafts. Technique and Results of 62 Cases. Clin Orthop. 1972; 87: 156 - 170
- [16] Albee FH. Transplantation of a Portion of the Tibia into the Spine for Pott's Disease. JAMA. 1911; 57: 85 - 98

- [17] Albee FH. Evolution of Bone Graft Surgery. *Am J Surg*. 1944; 63: 421 - 536
- [18] Aurori BF, Weierman RJ, Lowell HA, et al. Pseudarthrosis after Spinal Fusion for Scoliosis. *Clin Orthop*. 1985; 199: 153 - 167
- [19] Bassett CAL. Clinical Implications of Cell Function in Bone Grafting. *Clin Orthop*. 1972; 87: 49 - 63
- [20] Boyd HB, Lapinski SP. Causes and Treatment of Non union of the Shafts of the Long Bones. In *American Academy of Orthopaedic Surgeons: Instructional Course Lectures*, Vol. 17. St. Louis: C.V. Mosby; 1960
- [21] Hung NN. Use of an intramedullary Kirschner wire for treatment of congenital pseudarthrosis of the tibia in children. *Journal of Pediatric Orthopaedics B*. 2009; 18: 79-85
- [22] Albee FH. Transplantation of a Portion of the Tibia into the Spine for Pott's Disease. *JAMA*. 1911; 57: 85 - 108
- [23] Albee FH. Evolution of Bone Graft Surgery. *Am J Surg*. 1944; 63:421 - 436
- [24] Shapiro MS, Endrizzi DP, Cannon RM, Dick HM. Treatment of Tibial Defects and Nonunions Using ipsilateral Vascularized Fibular Transposition. *Clin Orthop*. 1993;296:207 - 223
- [25] Meyers MH, Harvey JP, Moore TM. Treatment of Displaced Subcapital and Transcervical Fractures of the Femoral Neck by Muscle-Pedicle Bone Graft and Internal Fixation. *J Bone Joint Surg*. 1973; 55-A:257 - 274
- [26] Meyers MH, Harvey JP, Moore TM. The Muscle-Pedicle Bone Graft in the Treatment of Displaced Fractures of the Femoral Neck: Indications, Operative Technique, and Results. *Orthop Clin North Am*. 1974;5:779 - 794
- [27] McMaster PE, Hohl M. Tibiofibular Cross-peg Grafting. *J Bone Joint Surg*. 1965; 47-A:1146 - 1158.
- [28] Langenskiöld A: Pseudarthrosis of the Fibula and Progressive Valgus Deformity of the Ankle in Children: Treatment by Fusion of the Distal Tibial and Fibular Metaphyses REVIEW OF THREE CASES. *The Journal Bone and Joint Surg*. 1967 ; 49-A (3): 463-470
- [29] Schnee CL, Freese A, Weil RJ, Marcotte PJ. Analysis of harvest morbidity and radiographic outcome using autograft for anterior cervical fusion. *Spine*. 1997; 22: 2222- 2227
- [30] Kurz LT, Garfin SR, Booth RE. Harvesting autogenous iliac bone grafts: a review of complications and techniques. *Spine*. 1989; 14:1324-1331.
- [31] Weikel AM, Habal MB. Meralgia paresthetica: a complication of iliac bone procurement. *Plast Reconstr Surg*. 1977; 60:572-574
- [32] Hu RW, Bohlman HH. Fracture at the iliac bone graft harvest site after fusion of the spine. *Clin Orthop Relat Res*. 1994; 309: 208-213.
- [33] Ebraheim NA, Yang H, Lu J, Biyani A. Anterior iliac crest bone graft: anatomic considerations. *Spine*. 1997; 22: 847-849
- [34] Alt V, Nawab A, Seligson D. Bone grafting from the proximal tibia. *Trauma*. 1999; 47:555-557.
- [35] Sasso RC, Williams JL, Dimasi N, Meyer PR . Postoperative drains at the donor sites of iliac-crest bone grafts. *J Bone Joint Surg*. 1998; 80-A: 631-635.


- [36] Fernyhough JC, Schimandle JJ, Weigel MC, Edwards CC, Levine AM . Chronic donor site pain complication bone graft harvesting from the posterior iliac crest for spinal fusion. *Spine*. 1992; 17:1474-1480.
- [37] Xu R, Haman SP, Ebraheim NA, Yeasting RA:. Anatomic considerations for posterior iliac bone harvesting. *Spine*. 1996; 21:1017-1020.
- [38] Lichtblau S. Dislocation of the sacro-iliac joint: a complication of bone grafting. *J Bone Joint Surg*. 1962; 44-A:193-198
- [39] O'Keeffe RM, Riemer BL, Butterfield SL. Harvesting of autogenous cancellous bone graft from the proximal tibial metaphysis: a review of 230 cases. *J Orthop Trauma*. 1991; 5: 469-474
- [40] Thor A, Farzad P, Larsson S. Fracture of the tibia: complication of bone grafting to the anterior maxilla. *Brit J Oral Maxillofac Surg*. 2006; 44: 46-48.
- [41] Van Damme PA, Merckx MA. A modification of tibial bone-graft harvesting technique. *Int J Oral Maxillofac Surg*. 1996; 25: 346-348.
- [42] Younger EM, Chapman MW. Morbidity at bone graft donor sites. *J Orthop Trauma*. 1989; 3:192-195.
- [43] Gore DR, Brechbuler M. Treatment of nonunions following anterior cervical discectomy and fusion with interspinous wiring and bone grafting. *J Surg Orthop*. 2003;12(4): 214-221.
- [44] Hornicek FJ, Gebhardt MC, Tomford WW, et al. Factors affecting nonunion of the allograft-host junction. *Clin Orthop Relat Res*. 2001; 382: 87-98.
- [45] Mankin HJ, Gebhardt MC, Jennings LC, et al. Long-term results of allograft replacement in the management of bone tumors. *Clin Orthop Relat Res*. 1996; 324:86-97.
- [46] Ortiz-Cruz E, Gebhardt MC, Jennings LC, et al. The results of transplantation of intercalary allografts after resection of tumors. A long-term follow-up study. *J Bone Joint Surg Am*. 1997; 79A: 97-106.
- [47] Vander Griend RA. The effect of internal fixation on the healing of large allografts. *J Bone Joint Surg Am*. 1994; 76A:657-663.
- [48] Muscolo DL, Ayerza MA, Aponte-Tinao L, et al. Intercalary femur and tibia segmental allografts provide an acceptable alternative in reconstructing tumor resections. *Clin Orthop Relat Res*. 2004; 426:97-102.
- [49] Malinin TI, Buck BE, Temple HT, et al. Incidence of clostridial contamination in donors' musculoskeletal tissue. *J Bone Joint Surg Br*. 2003; 85B:1051-1054.
- [50] Alman BA, De Bari A, Krajchich JI. Massive allografts in the treatment of osteosarcoma and Ewing sarcoma in children and adolescents. *J Bone Joint Surg Am*, 1995; 77A:54-64
- [51] Berrey BH Jr, Lord CF, Gebhardt MC, Mankin HJ. Fractures of allografts. Frequency, treatment, and end-results. *J Bone Joint Surg Am*. 1990; 72A:825-833.
- [52] San-Julian M, Canadell J. Fractures of allografts used in limb preserving operations. *Int Orthop*. 1998; 22:32-36.

- [53] Sorger JL, Hornicek FJ, Zavatta M, et al. Allograft fractures revisited. *Clin Orthop Relat Res.* 2001; 382:66–74
- [54] Thompson RC Jr, Garg A, Clohisy DR, Cheng EY. Fractures in large-segment allografts. *Clin Orthop Relat Res.* 2000; 370: 227–235.
- [55] San-Julian M, Canadell J. Fractures of allografts used in limb preserving operations. *Int Orthop.* 1998; 22:32–36.
- [56] Thompson RC Jr, Pickvance EA, Garry D. Fractures in large-segment allografts. *J Bone Joint Surg Am.* 1993; 75A: 1663–1673
- [57] Deijkers RL, Bloem RM, Kroon HM, et al. Epidiaphyseal versus other intercalary allografts for tumors of the lower limb. *Clin Orthop Relat Res.* 2005; 439:151–160.
- [58] Lietman SA, Tomford WW, Gebhardt MC, et al. Complications of irradiated allografts in orthopaedic tumor surgery. *Clin Orthop Relat Res.* 2000; 375: 214–217
- [59] Donati D, Capanna R, Campanacci D, et al. The use of massive bone allografts for intercalary reconstruction and arthrodeses after tumor resection. A multicentric European study. *Chir Organi Mov.* 1993; 78: 81–94.
- [60] Donati D, Di Liddo M, Zavatta M, et al. Massive bone allograft reconstruction in high-grade osteosarcoma. *Clin Orthop Relat Res.* 2000; 377: 186–194.
- [61] Dick HM, Strauch RJ. Infection of massive bone allografts. *Clin Orthop Relat Res.* 1994; 306:46–53.
- [62] Gebhardt MC, Flugstad DI, Springfield DS, Mankin HJ. The use of bone allografts for limb salvage in high-grade extremity osteosarcoma. *Clin Orthop Relat Res.* 1991; 270:181–196
- [63] Lord CF, Gebhardt MC, Tomford WW, Mankin HJ. Infection in bone allografts. Incidence, nature, and treatment. *J Bone Joint Surg Am.* 1988; 70A:369–376.
- [64] Mankin HJ, Friedlaender GE, Tomford WW. Massive allograft transplantation following tumor resection. In: Friedlaender GE, Mankin HJ, Goldberg VM, editors. *Bone grafts and bone graft substitutes*; 2006. Rosemont: American Academy of Orthopaedic Surgeons; pp. 39–47
- [65] Matejovsky Z Jr, Matejovsky Z, Kofranek I. Massive allografts in tumour surgery. *Int Orthop.* 2006; 30: 478–483.
- [66] Eastlund T. Bacterial infection transmitted by human tissue allograft transplantation. *Cell Tissue Bank.* 2006; 7: 147–166.
- [67] Tomford WW, Starkweather RJ, Goldman MH. A study of the clinical incidence of infection in the use of banked allograft bone. *J Bone Joint Surg Am.* 1981; 63A: 244–248
- [68] Tomford WW. Transmission of disease through transplantation of musculoskeletal allografts. *J Bone Joint Surg Am.* 1995; 77A:1742–1754.
- [69] Chapman PG, Villar RN. The bacteriology of bone allografts. *J Bone Joint Surg Br.* 1992; 74B: 398–399.
- [70] Delloye C, Cornu O, Druetz V, Barbier O. Bone allografts. What they can offer and what they cannot. *J Bone Joint Surg Br.* 2007; 89B: 574–579.

- [71] Lavernia CJ, Malinin TI, Temple HT, Moreyra CE. Bone and tissue allograft use by orthopaedic surgeons. *J Arthroplasty*. 2004; 19: 430–435.

IntechOpen

IntechOpen



Bone Grafting

Edited by Dr Alessandro Zorzi

ISBN 978-953-51-0324-0

Hard cover, 214 pages

Publisher InTech

Published online 21, March, 2012

Published in print edition March, 2012

Bone grafting is the surgical procedure in which new bone (bone graft) or a replacement material (graft substitute), is placed into bone fractures or bone defects to aid in healing. Bone grafting is in the field of interest of many surgical specialties, such as: orthopedics, neurosurgery, dentistry, plastic surgery, head and neck surgery, otolaryngology and others. In common, all these specialties have to handle problems concerning the lack of bone tissue or impaired fracture healing. There is a myriad of surgical techniques nowadays involving some kind of bone graft or bone graft substitute. This book gathers authors from different continents, with different points of view and different experiences with bone grafting. Leading researchers of Asia, America and Europe have contributed as authors. In this book, the reader can find chapters from the ones on basic principles, devoted to students, to the ones on research results and description of new techniques, experts will find very beneficial.

How to reference

In order to correctly reference this scholarly work, feel free to copy and paste the following:

Nguyen Ngoc Hung (2012). Basic Knowledge of Bone Grafting, Bone Grafting, Dr Alessandro Zorzi (Ed.), ISBN: 978-953-51-0324-0, InTech, Available from: <http://www.intechopen.com/books/bone-grafting/basic-knowledge-of-bone-grafting>

INTECH
open science | open minds

InTech Europe

University Campus STeP Ri
Slavka Krautzeka 83/A
51000 Rijeka, Croatia
Phone: +385 (51) 770 447
Fax: +385 (51) 686 166
www.intechopen.com

InTech China

Unit 405, Office Block, Hotel Equatorial Shanghai
No.65, Yan An Road (West), Shanghai, 200040, China
中国上海市延安西路65号上海国际贵都大饭店办公楼405单元
Phone: +86-21-62489820
Fax: +86-21-62489821

© 2012 The Author(s). Licensee IntechOpen. This is an open access article distributed under the terms of the [Creative Commons Attribution 3.0 License](https://creativecommons.org/licenses/by/3.0/), which permits unrestricted use, distribution, and reproduction in any medium, provided the original work is properly cited.

IntechOpen

IntechOpen