

We are IntechOpen, the world's leading publisher of Open Access books Built by scientists, for scientists

6,900

Open access books available

186,000

International authors and editors

200M

Downloads

Our authors are among the

154

Countries delivered to

TOP 1%

most cited scientists

12.2%

Contributors from top 500 universities



WEB OF SCIENCE™

Selection of our books indexed in the Book Citation Index
in Web of Science™ Core Collection (BKCI)

Interested in publishing with us?
Contact book.department@intechopen.com

Numbers displayed above are based on latest data collected.
For more information visit www.intechopen.com



Emergency Surgery for Colorectal Cancer Complications: Obstruction, Perforation, Bleeding

Gelu Osian

*University of Medicine and Pharmacy "Iuliu Hatieganu" Cluj-Napoca
Romania*

1. Introduction

Colorectal cancer represents the third most common cause of malignancy in men and the fourth most common cause of malignancy in women. Prevalence is estimated at 25 to 100,000 inhabitants (1).

Left colon cancer is more frequent than right colon cancer with half of colorectal cancers being situated at the level of the sigmoid colon.

There is a higher incidence of this form of malignancy in developed countries with higher living and is thought to be mainly due to environmental factors. An improvement in survival of the patients has been obtained thanks to national screening programs which enables diagnosis in the early stages which allows for treatment.

Despite current screening guidelines a large number of cases present to the surgical clinic as complications of colorectal cancer in the advanced, such as are tumoral obstruction, colon perforation, and lower GI hemorrhage.

The age of patients presenting with these complications is generally advanced, a factor which contributes to a high post-operative mortality of patients. Malignant processes evolve over a longer period in order for these complications to be produced, which is why patients are usually found to be in advanced stages of oncologic evolution with peritoneal carcinomatosis or distance metastasis. Despite this fact, radical treatment for the complicated colorectal cancer is recommended whenever possible.

2. Obstruction from colorectal cancer

The great majority of colorectal cancers have an asymptomatic or paucisymptomatic evolution over an extended period of time until they succeed in being clinically determined by a major complication. This is often a lower intestinal occlusion. Several cases have been cited whereby patients have been completely asymptomatic but have a sudden clinical onset. This was reported as a result of air flights, but without establishing a correlation between the flight and onset of disease (2).

Of the total colorectal cancers (CRC) 8-10% present as bowel occlusions, their variability being registered depending on the specificity of the surgical service. They do not tend to

have a favorable prognosis due to the increased age of patients, the advanced stage and the emergency nature of the surgical intervention (3).

Cancer represents the most frequent cause of large bowel obstruction, comprising 60% of the occlusions in elderly patients. Two thirds of colorectal cancers are situated at the left colon level and one third at right colon level (4).

Intestinal occlusion due to CRC has always raised problems regarding surgical treatment. Due to the fact that most of these patients are operated as an emergency, their metabolic state is insufficiently assessed and mechanically, the colon is not ready for surgical intervention. Surgical teams must make an ongoing choice between surgical treatments in one operative session and serialized surgical interventions. At present the most common choice is usually made for resection with primary anastomosis (5).

2.1 Presentation

Patients present to surgical clinic with abdominal colic pains, abdominal distension, altered mental status, and cessation of bowel transit of gas and feces. The patient is usually elderly, with altered general state, signs of neoplastic toxicity, and rich hyperseptic colon content.

As opposed to small bowel occlusions, colic-like pains are less frequent and less intense. Intestinal distension comprises solely the colic framework for a long period of time and only later does it extend to the small bowel. At this point, fecal vomiting occurs. The mechanism of vomiting is through a reflex mechanism present in abdominal colic. On exam, distension of the abdomen on the colic frame shows dullness on percussion. In older occlusions, distension with dullness comprises the whole abdomen.

The abdomen is slightly sensitive spontaneously and to palpation. On auscultation, can be noted accentuated bowel sounds are detected. In older occlusive forms, the absence of sounds due to the presence of paralytic ileus.

At the per rectum examination, an empty rectal ampule is detected, without fecal matter. Quite often in lower rectal cancers, the tumor, which is completely stenotic, may be palpated by the exploratory finger.

Following fecal vomiting and abdominal fluid sequestration, the patient shows signs of dehydration and shock with cold, cyanotic, dried teguments and low blood pressure .

2.2 Diagnosis

Abdominal X-ray emphasizes few hydro-aeric levels situated in the colonic frame, and having a large diameter vertically. This investigation can therefore make a diagnosis of a large bowel obstruction. Abdominal ultrasound shows dilated intestinal loops with liquid content and bracing movements. It can also reveal free liquid in the peritoneal cavity, can highlight the mass formed at the colon level if it is of significant size and can also observe potential metastatic disseminations to other abdominal organs.

Abdominal CT diagnoses the obstruction and can detect the primary tumor with its potential secondary determinations with a greater precision than abdominal ultrasound.

When the general state of the patients enables, a colonoscopy can be performed, highlighting the colorectal cancer, taking a biopsy and also perform potential trans-tumoral drilling which can relieve the obstruction with the possibility of a delayed emergency surgical intervention.

A chest X Ray can also detect potential secondary pulmonary metastasis.

Due to the older age of patients and their multiple co-morbidities, an extensive pre-operative assessment is necessary, measuring creatinine, urea and electrolytes and arterial blood gases. Patients are usually dehydrated suffering from severe metabolic imbalances which must be treated at the preoperative stage.

The ECG is Compulsory part of the surgical preoperative protocol.

2.3 Differential diagnosis

A diagnosis of large bowel obstruction can be made with the aid of history taking, the objective examination, and also the additional investigations performed. However, a differential diagnosis is required mainly having to rule out small bowel obstructions with higher intestinal occlusions. These usually determine a more painful and prominent symptomatology, with more frequent and intense colicky pains, with frequent food vomiting and only later, in neglected obstructions, they become fecaloid. Abdominal X Ray highlights hydroaeric levels with central disposition, having a large diameter on the horizontal plane. Other causes must also be ruled out including intussusception, sigmoid volvulus, engagement of the colon in a hernia sac with strangulation, invasion of the colon in the framework of extension of a neoplastic process from proximity (stomach, genital, urinary, pancreas etc).

Once the tumoral cause of the obstruction is established, a differential diagnosis of causes of colonic tumors is necessary, namely stenosed vegetating benign tumors, phytobezoar etc. Often the decision for surgical treatment is made in an emergency and the final diagnosis is only made intra-operative.

2.4 Preoperative treatment

Preoperative assessment and treatment must be carefully and rapidly undertaken, in order to avoid delay of a surgical intervention in patients who may have altered mental status or unstable vital signs. Metabolic acidosis, hypo or hyperglycemia and electrolyte imbalances are corrected based on the previous investigations performed. Antibiotics are administered prophylactically at this stage and the choice is usually a second or third generation cephalosporin in conjunction with Metronizadole or Vancomycin. Also, prophylaxis of deep venous thrombosis prophylaxis is achieved with low molecular weight heparin. Symptomatic treatment may be given to relieve the distress and may includes, analgesics, antiemetics, gastric antisecretion drugs and anticholinergics (6).

Oral laxatives are contra indicated.

If there is a probability that the surgical intervention includes a colostomy, it is advisable to mark the pre-operated place of colostomy.

All other co-morbidities must be optimized whenever possible.

2.5 Treatment options

In the therapeutic strategy of obstructive colorectal cancer, application of palliative methods and other radical treatment methods are advised.. Whenever possible, treatment has to be radical.

Palliative treatment is recommended in patients with severely altered general health and advanced stage disease with hepatic non-resectable metastasis (7).

Palliative treatment can be carried out as follows: pneumatic dilation of the tumorally stenosed region with the help of a balloon or rechanneling with laser Nd-YAG which can be effective as a palliative method in 80-90% of patients.

Endoscopic setting of the auto expandable metallic prosthesis has been used more and more with greater success in the preparation of the radical or palliative surgery for a non-resectable obstructive cancer. If this procedure is performed by an experienced surgeon, the success rate is over 90% (8).

In the operable cases, the implanted stent allows the gastrointestinal transit to restart while resolving the obstruction at the same time. Subsequently, the patient's condition and biological parameters improve, also permitting the delivery of neoadjuvant therapy where needed (9).

The affected bowel reduces its dimensions, the edema disappears and blood perfusion to the bowel improves. All of these changes create the premise for a planned radical intervention to be performed. A study done by Tekkis (8) looked at two groups of patients with obstructive colon cancer and similar tumor stages. One group had an initial surgical treatment and the other group had the endoscopic prosthesis as a first step followed by a surgical intervention. In the group who received the stent prosthesis, there were 87% of cases who ended up having resection and anastomosis, compared to 41% of cases in the non-stented group.

The specific complications associated with stoma care have to be considered, as they potentially increase co-morbidities, hospital admission, and also the costs of the intervention. The post-operative evolution was better in the group of patients who received the endoscopic stent, and they also had a shorter hospital admission (8). Performing elective surgical interventions also proved to decrease post-operative mortality.

Inserting expandable metallic stents is the intervention of choice for tumors in the advanced stages, with metastasis and peritoneal carcinomatosis.

A study done by Jeffrey H. Lee et al (10) showed that this method is safe and feasible. When it was performed by an experienced team, it had a success rate of 94%. Re-obstruction caused by the tumoral proliferation was noted in 7.3% cases. Death occurred due to specific complications related to the neoplastic process rather than surgical interventions.

Some of the disadvantages of the stenting process are related to the iatrogenic complications as a result of inserting the prosthesis in emergency conditions. Watt et al (11) noted that the rate of complications was of 27%. These include stent migration (11%), perforation (4.5%) and tumoral growth with stent obstruction (12%).

Radical treatment can be performed during a surgical intervention or during serialized interventions. In the course of history, the following were performed: at the end of the 19th century Paul-Mikulicz performed the intervention in one single operative session through externalizing the colon together with the tumor, which was resected postoperatively and an external anastomosis with a special clamp was performed. This operation was performed in one single intervention and has the advantage of lowering operative mortality by 70% compared to previous procedures, but also has the disadvantage of a high local recurrence. At the beginning of the 20th century the procedure used was one completed in three separate interventions:

1. colostomy which resolved the occlusion,
2. resection of the tumor and ultimately
3. restoring the intestinal transit. The advantage of this method is that it was performed on a mechanically stable colon but had the great disadvantage of a high morbidity rate of 30% (30% the morbidity rate) and mortality of 7% for each operative intervention. In 1921, Hartmann proposed a procedure divided into two phases: resection of the tumor with terminal colostomy subsequently followed by restoring of the intestinal transit. The advantage consists of rapid removal of the tumor and resolving the occlusion. The anastomosis is not performed on unfavorable terms, but the disadvantage is that of summation of mortality and morbidity indexes for each operative session, given that reintegration in transit is made through a new laparotomy.

The objective of analyzing the historical data was to avoid serialized operative disadvantages and surgical intervention in one operative session with primary anastomosis as the preferred option (12), (13).

2.6 Surgical options in obstructive colorectal cancers

Surgical attitude is different depending on the localization of tumor.

In right colon cancers the indicated operation is right hemicolectomy with primary ileotransverse anastomosis. In elderly patients with increasing age, a significantly altered general state or peritoneal carcinomatosis, the accepted operation is ileotransverse anastomosis with short circuiting of the tumoral obstacle.

In transverse colon cancers, the unanimously accepted surgical intervention is the single resection with a primary anastomosis. In special cases with very significant colon distension, elderly patients with multiple organic deficiencies, a very altered general state or peritoneal carcinomatosis, two phases are indicated for the intervention: colostomy immediately upwards from the tumor then followed by segmentary resection with colo-colonic anastomosis.

Cancers localized to the left colon level have the greatest number of controversies regarding operations in a single session or in two sessions. It is ideal to have a left hemicolectomy with primary colo-rectal anastomosis. If there is an insufficient preparation of the colon, there is a leakage at the hydro-pneumatic test, or anastomosis tension, a protection colostomy is recommended for execution or a provisional ileostomy. If there is severe distension of the colon, technical difficulties in resecting the tumor or ASA (American Society of Anesthesiologists) score >3 (high operative risk), a two step surgical intervention is recommended. The primary step consists of a colostomy, which frees the patient from occlusion, or Hartmann type operation, and resection with anastomosis, or anastomosis as secondary step, respectively. Due to the fact that many patients with left colon cancer are admitted for surgical intervention with an obstruction which evolves over a longer period and therefore there is marked distension of the entire colonic frame, in such cases subtotal colectomy with primary anastomosis was proposed. The advantages of the procedure consisted of removing potential synchronous cancers which were left undiagnosed at the preoperative stage due to the urgent nature of the surgical intervention. Also there is a small risk of fistula for the ileo-colonic anastomosis, similar to that of elective surgery. The procedure eliminates the necessity for post operative follow-up colonoscopy. Disadvantages consist of extending the surgical intervention with a subsequent increase in operative risk.

and in the presence of numerous stools postoperatively. There are still a multitude of controversies regarding the treatment of such lesions.

In rectal cancers surgical attitude is dictated by the patient's general state, localization and oncologic stage of the tumor. Either an anterior rectum resection of the tumor with primary anastomosis, a Hartmann operation or a simple colostomy can be performed.

2.7 Postoperative treatment

At the post operative stage, intensive rebalancing of the patient is continued, low molecular weight heparin is administered prophylactically to prevent thromboembolic complications and a further prophylactic dose of antibiotic is administered.

Drainage disturbances are monitored and suppressed as early as possible. Nutrition with liquid intake is restarted upon resolution of the ileus, followed by solid food once intestinal transit is restored.

Skin threads are suppressed 7 to 10 days post operatively.

The results of surgical treatment are less effective because they are performed in emergency situations and add multiple surgical risk factors. In 2005, Coco detected a 44% morbidity and a 4% mortality in emergency surgery of these tumors compared to 12% morbidity and 0% mortality in the elective surgery of the of tumors in the same locations (14).

Zhang MS and his collaborators (15) highlighted the fact that the prognosis of patients with occlusive neoplasms of the left colon and of the rectum depends on the TNM stage of the disease, the preoperative level of CEA, and the radical nature of the surgical intervention.

Localization of the occlusive tumor does not influence the prognosis (16).

2.8 Personal experience

In the Surgery Clinic No III from Cluj-Napoca, the treatment approach of occlusive colorectal cancers is surgical. In all situations where the disease is potentially treatable and the general and local state of the patient enables, resection is performed within oncologic safety limits as well as regional lymphadenectomy with reconstruction of continuity through primary anastomosis. If the bowel is highly distended and edematous, a Hartmann type intervention is performed or a resection with anastomosis and protective ileostomosis. In patients with severely altered general state, in those with a surgically surpassed disease, an upward colostomy or internal derivation is performed.

2.9 Conclusion

Occlusive colorectal cancers are severe forms of disease which represent a serious problem of therapeutic strategy, that is still intensely debated at present. Whenever possible, a radical surgical treatment is indicated with a single operative resection and primary anastomosis.

3. Perforated CRC

The incidence of perforated colorectal cancer is approximately 2.3-2.5% of the total number of surgically treated colorectal cancers (3). This is not a very common complication; however it is

very serious due to the severe peritonitis that results. Perforations of the colon have been documented in the literature after administration of bevacizumab for malignant tumors of the colon (17).

3.1 Introduction

Colorectal cancer can present emergently as a colonic perforation as a result of leakage of the hyperseptic content into the peritoneal cavity and subsequently causing localized or generalized peritonitis. The perforation can be produced in a juxtatumoral position or at some distance from the tumor, the so-called diastatic perforation. It usually appears in large neoplasms which evolve over a longer period of time, being therefore advanced from a regional perspective. Diastatic perforation appears in left colon cancers which undergo complete stenosis and result in upwards colon distension. The vascularization of the cecum where the perforation occurs, results in the outflow of the hyperseptic stasis content into the peritoneal cavity with consecutive peritonitis. Juxtatumoral perforation appears most frequently in right colon cancers and causes an abscess which subsequently perforates into the free peritoneum.

Tumoral perforation appears in the advanced stages of the disease. In the study conducted by Masaichi Ogawa and his collaborators (18) it is shown that in 53% of cases the disease is in stage IV, while in 37% it is in stage IIb and in 10% stage IIIa.

3.2 Presentation

Patients are referred to the hospital showing signs of an acute surgical abdomen. Abdominal pain is intense and diffused with low blood pressure, cold cyanotic teguments, and altered general health state. The history taking reveals colon distress manifested as diarrhea alternating with constipation, weight loss and stools with blood, mucus and pus.

On exam, patients can show signs of septic shock, with general abdominal muscular contraction and peritoneal irritation. In the later stages they can present with a distended abdomen without intestinal peristalsis with an intensely altered general state and signs of shock.

In the case of intra peritoneal abscess which has not yet opened into the entire peritoneal cavity, signs of peritonitis are localized at the tumor level which may be palpated on exam. If the perforation has led to the formation of a retroperitoneal abscess, the patient usually presents with a septic state associated to subcutaneous emphysema and abdominal wall cellulites.

3.3 Diagnosis

The diagnosis is mainly clinical and demands urgent surgical treatment.

Abdominal X-rays display pneumoperitoneum in the case of free perforation in the peritoneal cavity. Marked cecum distension can be discerned with diastatic perforation imminence even before its onset.

X-rays and abdominal CT scan show a consecutive intraperitoneal abscess in the blocked tumor perforation. Laboratory investigations reveal an important leukocytosis with potential signs of secondary renal failure from the emergent peritonitis.

3.4 Differential diagnosis

The juxtatumoral perforation of the cecum with consecutive abscess must be distinguished from a gangrenous and blocked appendicitis. This situation is especially due to the fact that this form of appendicitis can be seen in the elderly patients. In addition to cancer of the cecum may present in this manner. The ultimate diagnosis can often be established only after the histopathological examination of the surgical resection piece.

Perforated cancer of the sigmoid colon must be differentiated from perforated sigmoid diverticulitis with abscess, which often presents with a similar clinical picture. In this case too, the final diagnosis is histopathological.

Retroperitoneal abscess following perforation of left or right colon cancer must be differentiated from a retroperitoneal abscesses of renal origin. This differentiation can be performed following imaging explorations which reveal renal modifications.

3.5 Preoperative preparation

The preoperative preparation needs to be short but thorough insofar as generalized peritonitis is concerned, so as not to delay the surgical intervention and miss the appropriate moment for surgical intervention. Shock therefore needs to be treated and patients require a wide spectrum antibiotic prophylaxis, and finally basic preoperative protocols (ECG, biochemistry, arterial blood gases, chest X-ray, etc).

3.6 Treatment

Due to the neoplastic background on which the hyperseptic peritonitis occurs, any large-scale surgical intervention resulting in anastomosis must be avoided as it is shown to have poor outcomes.

It is crucial for the treatment to be marked as high emergency. Together with the extended resections, this can improve the prognosis (19).

Treatment of the peritonitis mainly consists of abundant washing of the peritoneal cavity, multiple drains, and broad spectrum antibiotics.

The approach of the perforated tumor is different depending on the local situation. If it can be removed easily, that can be done without an anastomosis, and instead through an upward terminal colostomy with closure of the remaining distal end (Hartmann type intervention) (20). If the tumor cannot be easily resected, a simple upwards derivative colostomy is performed or an ileostomy associated with the aforementioned peritonitis treatment. After the general condition of the patient improves, surgical intervention is performed and completed to remove the perforated tumor, if possible.

In case of diastatic perforation of the cecum, surgical treatment is a subtotal colectomy with ileostomy followed by the reconstruction of intestinal transit through an ileocolic or ileorectal anastomosis when the patient's condition improves.

3.7 Postoperative treatment

In the postoperative stage, the antibiotic treatment of peritonitis continues, as well as the hydroelectrolytic and acid-base rebalancing as and venous thrombosis. Drains and colostomies are monitored and drains should be discontinued when deemed appropriate.

An improved survival rate at 5 years is associated with administration of postoperative chemotherapy, compared with patients who did not receive this following release from hospital (21).

3.8 Prognosis

Prognosis of this complication is linked to the evolution and stage of tumor and to the severity of the peritonitis. In general, this complication carries an unfavorable prognosis, especially in case of diastatic perforation (22).

Mortality reaches 30 to 40% in cases of tumor perforation. In cases of diastatic perforation, mortality is between 50% and 68% (23), (24). If cases of death are excluded shortly after the intervention, the prognosis of perforated colorectal cancers is similar to that of unperforated cancers in the same stage (25).

4. Colorectal haemorrhagic cancers

4.1 Introduction

Hemorrhagic cancers are those cancers of the rectum and colon which manifest as colorectal bleeding. This usually presents as melena for those cancers situated at the right colon level or as rectorrhagia with fresh blood for those situated in more distal positions, especially those situated at the recto-sigmoid level (1). Cancers that present as severe hemorrhage are rare; but they usually manifest through rectorrhagia and are extremely critical (26). Such cases require emergency surgery due to hemorrhage and the immediate goal of the treatment is obtaining hemostasis. Radical treatment of colorectal cancer is encouraged whenever possible.

4.2 History

The patient is referred to a physician in order to determine the presence of blood in the stool, either as dark stool (melena), or as fresh blood. Symptoms usually appear in a patient with previous stool disturbances, with alternating diarrhea-constipation, weight loss over a couple of months and altered general condition. The patient also may have a history of abdominal pains often colicky-like. For recto-sigmoid cancers the patient can present with rectal tenesmus and pathological products in the stool (eg. mucus). Usually patients are pale and frail, showing signs of acute or chronic anemia. At the rectal examination, fecal occult blood may be detected.

4.3 Diagnosis

In the presence of lower gastro-intestinal hemorrhage, colonoscopy is performed and highlights the presence of colorectal cancer with localization of the hemorrhagic source. Biopsies are collected for the histopathological diagnosis. Abdominal ultrasound and CT scan establishes the lesional abdominal record by emphasizing the local and regional extension of the lesion. Pulmonary radiologic exploration detects any eventual pulmonary disseminations of the colorectal cancer.

The TC99 scintigraphy has a reliability of 100% and a sensitivity of 91% in establishing the source of hemorrhage (27).

Biochemical and hematological explorations are compulsory for the preoperative inventory. Microcytic hypochromic anemia is usually detected, requiring preoperative correction with blood transfusion.

4.4 Differential diagnosis

A differential diagnosis has to be made between lower and upper gastro-intestinal tract hemorrhage. Upper digestive hemorrhage originates above the ligament of Treitz and it is usually manifested through hematemesis and melena. If the hemorrhage is significant it can manifest itself as a rectorrhagia, but is usually associated with hematemesis. Emergency colonoscopy branches out the diagnosis. Apart from colorectal cancer there are other diseases which can evolve with rectorrhagia, for example ulcerohemorrhagic rectocolitis, benign tumors which can cause bleeding, intestinal mesenteric infarct, intestinal invagination, etc. However, the clinical picture is different to that of colorectal cancer, as there can be present signs of peritonitis and shock (intestinal-mesenteric infarct) or of bowel obstruction (invagination). At the distal gastro-intestinal tract, the cause of rectorrhagia can be represented by hemorrhoids or anal fissure, which can be detected through anoscopy and rectal examination.

4.5 Preoperative treatment

The preoperative assessment and treatment is usually performed as an emergency in order not to delay surgical intervention. Correction of anemia is necessary through transfusion of packed red blood cells, often rh- because of the emergent nature.

Electrolytes should be monitored and corrected as appropriate.

4.6 Treatment

The objective is to remove the source of hemorrhage, i.e. the source of colorectal cancer. If possible, an intervention with radical aim is performed when the patient's general condition allows it.

Therefore, in right colon hemorrhagic cancers a right hemicolectomy is performed, while in left colon cancers a left hemicolectomy. In recto-sigmoid cancers a resection or rectum amputation is planned depending on the distance from the tumor to the anal margin.

There are situations when the cancer is in the advanced stages, making it impossible to be removed. In these cases a derivative process can be performed with an upward colostomy type or the colo-colonic or entero-colonic derivation thus putting the colon to rest in the hope that in the absence of local trauma represented by the fecal discharge, the hemorrhage will stop.

4.7 Postoperative treatment

Resuscitation procedures initiated at the pre operative stage are continued with whole blood transfusions or packed red blood cells and prophylactic antibiotics aiming to correct the hemorrhagic shock.

The stoma and the surgical trauma are appropriately treated.

4.8 Results and prognosis

These depend on the stage of evolution of the colorectal cancer and advanced forms with marked regional invasion have a poor prognosis.

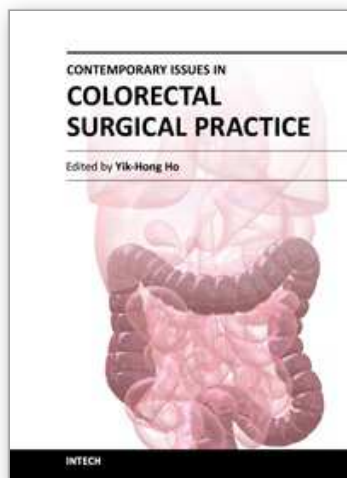
5. Conclusions

Fortunately, complicated colorectal cancers with significant hemorrhage are rare. They usually present with occult bleeding and chronic signs of anemia.. The advanced regional forms with severe hemorrhage from the necrosed tumor unfortunately have little therapeutic options and results are poor.

6. References

- [1] Osian G. Cancerul colorectal-De la Genetica la Chirurgia Robotica. Editura Medicala Universitara Iuliu Hatieganu 2011. pp 116-120.
- [2] Kingsley C Ekwueme, Malcolm A West, Paul S Rooney. Emergency first presentation of colorectal cancer following air travel: a case series J R Soc Med Sh Rep May 2011 2:36; doi:10.1258/shorts.2011.011002
- [3] Beuran M., Grigorescu M. Actualitati in patologia colonului. Editura Medicala Universitara Iuliu Hatieganu 2007. pp.68-72.
- [4] Kronborg O., Backer O., Sprechler M. Acute obstruction in cancer of the colon and rectum. Dis colon Rectum 1975; 18: 22-27.
- [5] Smithers BM, Theile D.E., Cohen JR.,et al. Emergency surgery for obstructing colorectal cancers: a comparison between right-sided and left-sided lesions. J AM Coll Surg 2001; 193(6): 717.
- [6] O'Connor B, Creedon B. Pharmacological treatment of bowel obstruction in cancer patients. Expert Opin Pharmacother. 2011 Oct;12(14):2205-14. Epub 2011 Jun 30.
- [7] Dalal KM, Gollub MJ, Miner TJ, Wong WD, Gerdes H, Schattner MA, Jaques DP, Temple LK. Management of patients with malignant bowel obstruction and stage IV colorectal cancer. J Palliat Med. 2011 Jul;14(7):822-8. Epub 2011 May 19.
- [8] P. P. Tekkis, J. D. Poloniecki, M. R. Thompson, J. D. Stamatakis. Operative mortality in colorectal cancer: prospective national study. British Medical Journal, vol. 327, no. 7425, pp. 1196-1199, 2003.
- [9] D. Williams,¹ R. Law,² and A. M. Pullyblank. Colorectal Stenting in Malignant Large Bowel Obstruction: The Learning Curve. International Journal of Surgical Oncology.vol 2011 (2011), Article ID 917848, 4 pages doi:10.1155/2011/917848
- [10] Jeffrey H. Lee, William A. Ross, Raquel Davila, George Chang, E. Lin, Alexander Dekovich and Marta Davila. Self-Expandable Metal Stents (SEMS) Can Serve as a Bridge to Surgery or as a Definitive Therapy in Patients with an Advanced Stage of Cancer: Clinical Experience of a Tertiary Cancer Center. Digestive Diseases and Sciences. vol. 55, no. 12, pp. 3530-3536, 2010.
- [11] A. M. Watt, I. G. Faragher, T. T. Griffin, N. A. Rieger, and G. J. Maddern. Self-expanding metallic stents for relieving malignant colorectal obstruction: a systematic review. Annals of Surgery, vol. 246, no. 1, pp. 24-30, 2007.

- [12] Ansaloni L, Andersson RE, Bazzoli F, Catena F, Cennamo V, Di Saverio S, Fuccio L, Jeekel H, Leppäniemi A, Moore E, Pinna AD, Pisano M, Repici A, Sugarbaker PH, Tuech JJ. Guidelenines in the management of obstructing cancer of the left colon: consensus conference of the world society of emergency surgery (WSES) and peritoneum and surgery (PnS) society. *World J Emerg Surg.* 2010 Dec 28;5:29.
- [13] Sasaki K, Kazama S, Sunami E, Tsuno NH, Nozawa H, Nagawa H, Kitayama J. One-stage segmental colectomy and primary anastomosis after intraoperative colonic irrigation and total colonoscopy for patients with obstruction due to left-sided colorectal cancer. *Dis Colon Rectum.* 2012 Jan;55(1):72-8
- [14] Claudio Coco, Alessandro Verbo, Alberto Manno, Claudio Mattana, Marcello Covino, Giorgio Pedretti, Luigi Petito, Gianluca Rizzo and Aurelio Picciocchi. Impact of Emergency Surgery in the Outcome of Rectal and Left Colon Carcinoma. *World J Surg* (2005) 29: 1458-1464.
- [15] Zhang MS, Mao WZ, Zhou YB, Wang PG, Zhang BY. Surgical treatment and prognostic factors for obstructing left colorectal cancer. *Zhonghua Wei Chang Wai Ke Za Zhi* 2011 Aug; 14(8):620-622.
- [16] Frago R, Biondo S, Millan M, Kreisler E, Golda T, Fracalvieri D, Miguel B, Jaurrieta E. Differences between proximal and distal obstructing colonic cancer after curative surgery. *Colorectal Dis* 2011 Jun; 13(6):e116-22.
- [17] Bevacizumab-induced bowel perforation. Sliesoraitis S, Tawfik B. *J Am Osteopath Assoc.* 2011 Jul;111(7):437-41.
- [18] Masaichi Ogawa, Michiaki Watanabe, Ken Eto, Takahiro Omachi, Makoto Kosuge, ... Ken Hanyu, Lohta Noaki, Tetsuji Fujita, Katsuhiko Yanaga. Clinicopathological features of perforated colorectal cancer. *Anticancer Research* (2009) Volume: 29, Issue: 5, Pages: 1681-1684.
- [19] Carraro PG, Segala M, Orlotti C, Tiberio G. Outcome of large-bowel perforation in patients with colorectal cancer. *Dis Colon Rectum.* 1998 Nov; 41(11):1421-6.
- [20] Meyer F, Grundmann RT. Hartmann's procedure for perforated diverticulitis and malignant left-sided colorectal obstruction and perforation. *Zentralbl Chir.* 2011 Feb; 136(1):25-33. Epub 2011 Feb 18.
- [21] Min Sang Kim, Seung Woo Lim, Sung Jin Park, Geumhee Gwak, Keun Ho Yang, Byung Noe Bae, Ki Hwan Kim, Sewhan Han, Hong Joo Kim, Young Duck Kim, Hong Yong Kim. Survival Rate and Prognostic Factors in Perforated Colorectal Cancer Patients: A Case-Control Study. *J Korean Soc Coloproctol: Vol. 26, No. 1, 69-75, 2010.*
- [22] Khan S, Pawlak SE, Eggenberger JC, Lee CS, Szilagyi EJ, Margolin DA. Acute colonic perforation associated with colorectal cancer. *Am Surg.* 2001 Mar; 67(3):261-4.
- [23] Peregudov SI, Sinenchenko GI, Kurygin AA, Pirogov AV. Experience in surgery of diastatic ruptures of the colon. *Vestn Khir Im I I Grek.* 2008; 167(3):49-53.
- [24] Renoux B, Herbault GF, Jean E. Diastatic perforations of the colon of neoplastic origin. Apropos of 15 cases. *J Chir (Paris).* 1986 Nov; 123(11):644-50.
- [25] Zielinski MD, Merchea A, Heller SF, You YN. Emergency Management of Perforated Colon Cancers: How Aggressive Should We Be? *Journal of Gastrointestinal Surgery* (Sep 2011).
- [26] Iwata T, Konishi K, Yamazaki T, Kitamura K, Katagiri A, Muramoto T, Kubota Y, Yano Y, Kobayashi Y, Yamochi T, Ohike N, Murakami M, Gokan T, Yoshikawa N, Imawari M. Right colon cancer presenting as hemorrhagic shock. *World J Gastrointest Pathophysiol.* 2011 Feb 15; 2(1):15-8.
- [27] Schwartz S et al. Principles of Surgery. Ed I, Teora 2005.pp. 1066-1072



Contemporary Issues in Colorectal Surgical Practice

Edited by Dr. Yik- Hong Ho

ISBN 978-953-51-0257-1

Hard cover, 126 pages

Publisher InTech

Published online 16, March, 2012

Published in print edition March, 2012

In recent years, significant progress in colorectal surgery has been made which includes laparoscopic techniques, pre-operative management, emergency colorectal surgery, fast track multimodal recovery, management of complex wound problems and colorectal cancer follow-up. "Contemporary Issues in Colorectal Surgical Practice" aims to bridge the gap between the journal article and the traditional textbook in these areas.

How to reference

In order to correctly reference this scholarly work, feel free to copy and paste the following:

Gelu Osian (2012). Emergency Surgery for Colorectal Cancer Complications: Obstruction, Perforation, Bleeding, Contemporary Issues in Colorectal Surgical Practice, Dr. Yik- Hong Ho (Ed.), ISBN: 978-953-51-0257-1, InTech, Available from: <http://www.intechopen.com/books/contemporary-issues-in-colorectal-surgical-practice/emergency-surgery-for-colorectal-cancer-complications>

INTECH
open science | open minds

InTech Europe

University Campus STeP Ri
Slavka Krautzeka 83/A
51000 Rijeka, Croatia
Phone: +385 (51) 770 447
Fax: +385 (51) 686 166
www.intechopen.com

InTech China

Unit 405, Office Block, Hotel Equatorial Shanghai
No.65, Yan An Road (West), Shanghai, 200040, China
中国上海市延安西路65号上海国际贵都大饭店办公楼405单元
Phone: +86-21-62489820
Fax: +86-21-62489821

© 2012 The Author(s). Licensee IntechOpen. This is an open access article distributed under the terms of the [Creative Commons Attribution 3.0 License](https://creativecommons.org/licenses/by/3.0/), which permits unrestricted use, distribution, and reproduction in any medium, provided the original work is properly cited.

IntechOpen

IntechOpen