

# We are IntechOpen, the world's leading publisher of Open Access books Built by scientists, for scientists

6,900

Open access books available

186,000

International authors and editors

200M

Downloads

Our authors are among the

154

Countries delivered to

TOP 1%

most cited scientists

12.2%

Contributors from top 500 universities



WEB OF SCIENCE™

Selection of our books indexed in the Book Citation Index  
in Web of Science™ Core Collection (BKCI)

Interested in publishing with us?  
Contact [book.department@intechopen.com](mailto:book.department@intechopen.com)

Numbers displayed above are based on latest data collected.  
For more information visit [www.intechopen.com](http://www.intechopen.com)



# Hyperinfection Syndrome in Strongyloidiasis

Cristiane Tefé-Silva<sup>1,\*</sup>, Eleuza R. Machado<sup>2</sup>,  
Lúcia H. Faccioli<sup>2</sup> and Simone G. Ramos<sup>1</sup>

<sup>1</sup>Department of Pathology, Faculty of Medicine of Ribeirão Preto

<sup>2</sup>Department of Clinical Analyses, Toxicology and Bromatology Faculty of  
Pharmaceutics Sciences of Ribeirão Preto, University of São Paulo  
Brazil

## 1. Introduction

Strongyloidiasis is an intestinal parasitosis found in tropical and subtropical areas, where the warm climates are suitable for parasite survival (Barr, 1978). It is a common cause of morbidity and mortality, particularly in developing countries, and infects over one-quarter of the world's population (Genta, 1989). Approximately 52 species are known to infect mammals, birds, reptiles and amphibians (Speare, 1989). The most common globally distributed human pathogen of clinical importance is *Strongyloides stercoralis* (Schad, 1989). Another species, *Strongyloides fuelleborni*, is a zoonotic parasite that infects primates and is found sporadically in humans in Africa (Pampiglione & Ricciardi, 1972). *S. stercoralis* is a ubiquitous soil-transmitted intestinal nematode that was first reported in 1876 in French soldiers working in Vietnam. It is unique among helminths in that it completes its life cycle inside a single human host. A unique feature of strongyloidiasis is the ability of the parasite to autoinfect the host, which makes *S. stercoralis* a significant public health problem (Grove, 1989).

## 2. Epidemiology

The epidemiology of *Strongyloides* infection is poorly understood because it is difficult to detect and can be underestimated (Albonico et al., 1999; Viney & Lok, 2007). However, it is estimated that from 30 a 100 million people are infected worldwide with *Strongyloides*, and can range from asymptomatic to multiorgan failure (Genta, 1989). *Strongyloides* is found in tropical and subtropical areas and requires specific soil and climate conditions for its development. In North America, Latin America, Africa and Southeast Asia, the infection is endemic (Roxby et al., 2009). The risk of acquiring strongyloidiasis is higher in rural areas, among people who work with soil, and among lower socioeconomic groups (Vadlamudi et al., 2006; Viney & Lok, 2007). Walking barefoot in areas where human faeces containing the parasite are deposited increases the probability of acquiring the infection (Grove, 1994).

## 3. Parasite

*S. stercoralis* has free-living and parasitic life cycles, and the morphology of each differs. Parasitic worms are female adults that reproduce by parthenogenesis and measure approximately 1 - 10 mm in length by 27 -95 µm in width. Free-living adults are

approximately 1 mm, live in the soil, and reproduce sexually; females are slightly larger than males (Speare, 1989). Embryonated eggs are thin-shelled and measure approximately 55 - 60  $\mu\text{m}$  in length and 28 - 32  $\mu\text{m}$  in width. Rhabditiform larvae are the first-stage larvae (210  $\mu\text{m}$ ) and develop into free-living larvae or third-stage infective larvae that measure approximately 490-630  $\mu\text{m}$  and are capable of infecting the host (Schad, 1989).

#### 4. Life cycle

The life cycle of *S. stercoralis* includes a parasitic cycle (within human hosts) and an environmental cycle (free-living larvae). The parasitic cycle occurs when the infective filariform larvae penetrate the skin and secrete metalloproteases that facilitate penetration. The main larval route is via the bloodstream to the lungs, where they break into the alveolar spaces within hours after infection, promote haemorrhage, ascend the respiratory tree, are swallowed, and migrate to the intestine. Alternatively, the larvae may migrate directly through connective tissues (Grove, 1994, 1996).

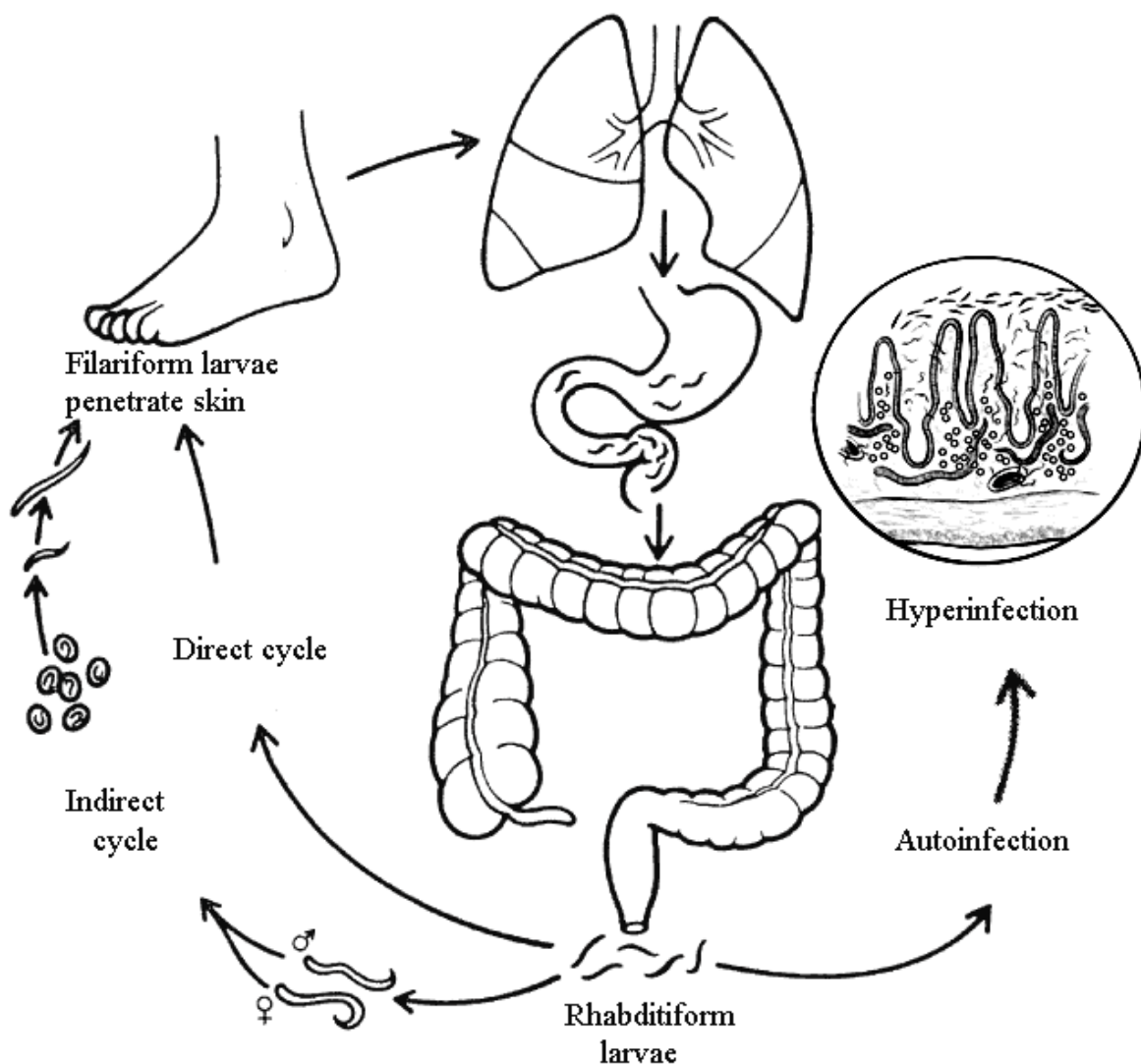


Fig. 1. Life cycle of *Strongyloides stercoralis* (modified from Carvalho & Da Fonseca Porto, 2004, and <http://emedicine.medscape.com/article/229312-overview#a0104>).

The infective larvae reach the small intestine, where they moult twice to become female adult worms. These females reproduce in the absence of males by parthenogenesis. The females are embedded in the intestinal mucosa and produce eggs in the duodenum. The rhabditiform larvae emerge from the hatching eggs and migrate into the intestinal lumen, then pass into the external environment with the faeces. Depending on temperature and humidity, the rhabditiform larvae may have two different life cycles in the environment: an indirect (heterogonic) life cycle, in which the rhabditiform larvae differentiate into free-living adults and release eggs that hatch and transform into infective larvae, or a direct (homogonic) life cycle, in which the rhabditiform larvae may moult directly into filariform larvae and repenetrate the host skin, restarting the cycle (Schad, 1989).

One characteristic that differentiates *S. stercoralis* from almost all other worms is its capacity to replicate within the host. Rhabditiform larvae in the bowel lumen transform into filariform larvae before excretion and invade the intestinal wall or the perianal skin, permitting ongoing cycles of autoinfection, an important feature of strongyloidiasis (Concha et al., 2005).

## 5. Clinical manifestation

The clinical presentation of strongyloidiasis varies with the status of the host's immune system, and the infection is classified as acute, chronic or severe. Acute infections of strongyloidiasis manifest as a wide spectrum of clinical features ranging from asymptomatic disease to cutaneous (larva currens and urticaria), pulmonary (cough and tracheal irritation), and gastrointestinal symptoms (diarrhoea and constipation), although the majority of *S. stercoralis* infections are resolved (Mahmoud, 1996).

The ability of *S. stercoralis* to establish a cycle of autoinfection within the host results in chronic infections that can persist in an individual for decades. Chronic infections are often asymptomatic, but when symptoms occur they are usually mild, episodic and prolonged, including nausea, vomiting, diarrhoea, constipation, weight loss or cutaneous reactions (Grove, 1989).

Uncontrolled autoinfection of *S. stercoralis* is more likely to occur in immunosuppressed patients, leading to hyperinfection syndrome. The pulmonary phase of hyperinfection due to migrating larvae resembles Löffler syndrome with coughing and wheezing, asthma-like symptoms, haemorrhaging and pneumonia. In the intestine, symptoms include diarrhoea, nausea, vomiting, abdominal pain, and weight loss (Concha et al., 2005; Viney & Lok, 2007). Bacteremia is a common complication of hyperinfection syndrome and is caused by filariform larvae that may lead bacteria from the bowel to the bloodstream with subsequent secretion into the host circulation (Bamias et al., 2010). Pathogens such as *Streptococcus bovis*, *Escherichia coli*, *Klebsiella pneumonia* or *Enterobacter cloacae* are found during fatal complications of strongyloidiasis (Link & Orenstein, 1999). The mortality rate of dissemination associated with bacterial infections can reach approximately 90% (Igra-Siegmán et al., 1981).

Dissemination occurs upon larval migration to organs beyond the range of the pulmonary phase, such as the liver, heart, lymph nodes, gallbladder, kidneys, pancreas, and brain (Keiser & Nutman, 2004). Petechiae and purpura have also been reported in disseminated cases as a result of larval migration through vessel walls, which promotes haemorrhage (Basile et al., 2010). Others complications of disseminated strongyloidiasis can occur and include syndromes such as cholecystitis, pancreatitis, paralytic ileus, intestinal perforation

or infarction, peritonitis, and sepsis (Krishnan et al., 2006). Although unusual, brain involvement can occur in disseminated infections, with symptoms including headache, focal seizures, altered mental state, secondary bacterial meningitis and coma (Dutcher et al., 1990).

## 6. Hyperinfection syndrome

Since 1966, studies have reported that autoinfection may result in the dissemination of worms; denoted hyperinfection syndrome, the number of worms increases significantly, and worms are detectable in extraintestinal regions, with a mortality rate above 80% (Siddiqui & Berk, 2001). High-risk factors for hyperinfection and dissemination include corticosteroid therapy, malignancies, transplantation, malnutrition, hypogammaglobulinemia, and viral infections such as HIV (Human Immunodeficiency Virus) and HTLV-1 (Human T-Lymphotropic Virus Type 1) (Concha et al., 2005).

### 6.1 Corticosteroids

In recent decades, hyperinfection syndrome has increased significantly with the use of immunosuppressive drug therapy. Corticosteroids are widely prescribed drugs with potent immunosuppressive effects and are a major risk factor for the transformation of chronic strongyloidiasis into hyperinfection, which has a higher index of mortality (Armignacco et al., 1989; Al Maslamani et al., 2009). Corticosteroids are involved in the treatment of several diseases that are considered immunological abnormalities, such as lymphoma, rheumatoid arthritis, leprosy, chronic obstructive pulmonary disease (COPD), and polymyositis, leading to fatal hyperinfection in many cases (Keiser & Nutman, 2004).

However, the role of corticosteroids in susceptibility to severe *S. stercoralis* infection is poorly understood. One hypothesis is that both endogenous and exogenous corticosteroids promote immunosuppression by decreasing the number of inflammatory cells, such as eosinophils and mast cells, and suppressing the transcription of several cytokines. In addition, corticosteroids increase the apoptosis of Th2 lymphocytes (Genta, 1989). Corticosteroids may also have a direct effect on female worms by increasing the production of ecdysteroid-like molecules, hormones that control moulting in insects and possibly helminths (Genta, 1992). An increase in these molecules increases the moulting rate and transforms rhabditiform larvae into filariform larvae, increasing the worm burden and promoting hyperinfection and dissemination (Genta, 1992; Siddiqui et al., 2000).

### 6.2 Hematologic and others malignancies

Patients with hematologic malignancies have a high prevalence of *S. stercoralis* infection when compared with the global index. The reported cases of hematologic malignancies and *S. stercoralis* hyperinfection syndrome are associated with glucocorticoid treatment. The malignancy usually associated with *S. stercoralis* is lymphoma that is being treated with chemotherapy. Moreover, lung cancer has been associated with hyperinfection during the administration of immunosuppressive chemotherapy (Keiser & Nutman, 2004).

### 6.3 Transplantation

Hyperinfection syndrome is associated with transplants, and the progression of chronic intestinal infection before transplantation appears to be the most common mechanism.



Hyperinfection cases following organ transplant principally occur during the initial months after transplantation, but the infection was acquired before transplantation in the majority of cases (Roxby et al., 2009). Higher mortality rates occur from extraintestinal strongyloidiasis, which in most of these cases are related to corticosteroid therapy to treat rejection (Keiser & Nutman, 2004).

Renal transplants are most commonly associated with hyperinfection, which is related to immunosuppressive treatments (Devault et al., 1990; Rajapurkar et al., 2007; Valar et al., 2007). Cases of hyperinfection have been described in transplant recipients of other organs, such as the liver (Vilela et al., 2008; Rodrigues-Hernandez et al., 2009), heart (Schaeffer et al., 2004), pancreas (Ben-Yousseff et al., 2005), lung (Balagopal et al., 2009), and intestine (Patel et al., 2008). Hyperinfection in hematopoietic stem cell transplant patients may be due to immunosuppressive therapies (Dulley et al., 2008; Wirk & Wingard, 2008).

#### 6.4 Malnutrition

An important cause of immunodeficiency that is related to hyperinfection is malnutrition, particularly in developing countries. Malnutrition promotes disruption of the intestinal mucosa, impairing the host's ability to expel the parasite from the gut (Olsen et al., 2009).

#### 6.5 Hypogammaglobulinemia

Patients with immunodeficient conditions, such as hypogammaglobulinemia, may develop fatal hyperinfection. Case reports show that hypogammaglobulinemia is refractory to prolonged anthelmintic therapy (Brandt de Oliveira et al., 1981; Seet et al., 2005).

#### 6.6 HIV

Although HIV infection predisposes a patient to hyperinfection due to immunosuppression, few cases of *S. stercoralis* and AIDS have been described (Marcos et al., 2008). The association between *S. stercoralis* and HIV principally occurs in endemic areas (Siddiqui & Berk, 2001). The hyperinfection syndrome can occur in patient with HIV with immune reconstruction syndromes increased after starting of highly active antiretroviral therapy (Brown et al., 2006). On the other hand, the infection with *Strongyloides* may contribute to serious nutritional deficiencies in HIV-infected individuals, such as anorexia and malabsorption (Lindo et al., 1998). However, the immunobiological and immunoregulatory mechanisms involving HIV and strongyloidiasis remain unclear.

#### 6.7 HTLV-1

HTLV-1 is a virus that infects T cells and induces lymphocyte proliferation with the production of a Th1-type immune response in humans. The genome of the HTLV-1 virus is diploid and, following interaction with the immune system, HTLV-1 enables the transcription of the viral DNA by integrating into the host genome effectively evading immune surveillance without killing the host (Iriemenan et al., 2010). Strongyloidiasis is strongly associated with HTLV-1, which predisposes patients to severe infections by depressing cell-mediated immunity or IgE responses (Grove, 1996; Carvalho & Da Fonseca Porto, 2004). *Strongyloides* and HTLV-1 may promote the Th1-type response in patients, increasing interferon levels and decreasing Th2-type responses, such as interleukin 4 (IL-4), IL-5, IL-13, and IgE, important host defences against helminths, and a decrease in this response allows not only an increasing in autoinfection but also decreased parasite killing.

In addition, this association reduces the efficacy of anthelmintic drugs, increasing the prevalence of infection (Montes et al., 2009; Iriemenam et al., 2010). Stool examinations should be performed with special attention to detect *S. stercoralis* larvae in all patients infected by HTLV-1 (Carvalho & Da Fonseca Porto, 2004).

## 7. Host-parasite interaction

The relationship between *S. stercoralis* and its host is complex, and little is known about the immunomodulatory mechanisms that regulate this interaction. Different factors are involved, including the capacity of the parasite to replicate, the adequacy of the host immune response, and the ability of the parasite to evade those responses (Grove, 1994; Trajman et al., 1997).

### 7.1 Cellular immune response

During helminthic infection, Th2-type cell-dependent host defences that involve CD4 cells are developed (Maizels & Yazdanbakhsh, 2003; Anthony et al., 2007). In human hosts and animal models, the cellular immune response to *Strongyloides* infection is characterised by intraepithelial and tissue eosinophils, neutrophils and mast cells with Th2-type production of cytokines such as IL-4, IL-5 and IL-13. Conversely, Th1-type responses are down-regulated during nematode infection (El-Malky et al., 2003; Paterson et al., 2008; Iriemenam et al., 2010).

#### 7.1.1 Eosinophils

Eosinophils are essential against nonphagocytosable parasites, such as *Strongyloides*, that cannot be ingested because of their large size. Eosinophils defend the host by attacking the parasite via the FcεRI receptor, capturing antigens from the worms and presenting the antigens to T cells to initiate an antigen-specific immune response (Galioto et al., 2006; Padigel et al., 2006; Iriemenam et al., 2010). Others mechanisms may be involved, including antibody-dependent cellular cytotoxicity (ADCC) mediated by eosinophils on the parasite surface, which releases toxic molecules in an attempt to eliminate the parasite (Ligas et al., 2003; Klion & Nutman, 2004).

#### 7.1.2 Mast cells

Mast cells have an important role in the defence against *S. stercoralis* by inhibiting the invasion of the adult worm into the intestinal epithelium, promoting the stimulation of gut motility, mucus release and expulsion of the parasites. In addition, mast cells induce the attraction and modulation of eosinophils (Kobayashi et al., 1998; Concha et al., 2005).

### 7.2 Cytokines

Strongyloidiasis promotes the robust Th2-type immune response with the production of cytokines, such as IL-3, IL-4, IL-5, IL-6, IL-9, IL-10 and IL-13. Contrarily, Th1-type responses are reduced during nematode infection (Wilkes et al., 2007; Patel et al., 2009).

IL-3 is important during *Strongyloides* infection stimulates the synthesis of potent mast cells and basophils enhancing the function of these cells (Abe et al., 1993). In addition, IL-3 can enhance the levels of intra-cellular IL-4 upon activating basophils, with anti-IgE and IL-3 contributing to an increase in eosinophils (Kimura et al., 2006; Lantz et al., 2008).

IL-4 has multiple immunoregulatory functions, including T-cell growth factor activity, B-cell regulation, serum IgE level enhancement, and stimulation of the growth and/or differentiation of macrophages, hematopoietic cells, and mast cells (Urban et al., 1991; Negrão-Correa et al., 2006; Wilkes et al., 2007). IL-4 decreases the fecundity and survival of adult worms and increases intestinal smooth muscle contraction, facilitating the expulsion of the parasite (Concha et al., 2005).

IL-5 regulates the production of eosinophil myelocyte precursors in bone marrow, the development of mature eosinophils after helminth infection and, in most instances, the production of a number of other cytokines, including IL-4 and IL-13, and chemokines such as RANTES and eotaxin (Herbert et al., 2000; Klion & Nutman, 2004; Mir et al., 2006).

IL-13 also participates in the defence mechanisms against helminths, promoting an increase in the intestinal fluid content and increased smooth muscle contractility, a phenomenon that may contribute to worm expulsion (Porto et al., 2001; Shea-Donohue & Urban, 2004; Patel et al., 2009).

### 7.3 Humoral immune response

The humoral immune response complements defence mechanisms against strongyloidiasis with the production of immunoglobulins by plasma cells. Several immunoglobulins, such as IgE, IgG and IgM, are essential for the elimination of the parasite (Ligas et al., 2003; Machado et al., 2005).

IgE antibodies can mediate the activation of accessory cells and the recognition of parasite antigens, promoting goblet cell mucus secretion and the degranulation of mast cells that release mediators affecting parasite survival (Machado et al., 2009). IgG and IgM can transfer immunity against the human parasite in the presence of the complement system and neutrophils (Abraham et al., 1995; Vadlamudi et al., 2006).

Laboratory models have suggested that both T and B cells mediate the immune response through an increase in immunoglobulins, eosinophils and mast cells and hyperplasia of goblet cells, which require interleukins and chemokines for their development and activation. In strongyloidiasis, dexamethasone seems to primarily suppress cytokines such as IL-1 $\beta$ , IL-4, VEGF, TNF- $\alpha$ , IFN- $\gamma$ , IL-3, IL-4, IL-5, IL-10 and IL-12 and decreases the production of IgG and IgE antibodies during *S. venezuelensis* infection (Machado et al., 2011; Tefé-Silva et al., 2012).

### 7.4 Other responses

The complement system activates both classical and alternative pathways with chemoattraction and binding of granulocytes in association with effector cells, which are essential against *S. stercoralis* (Vadlamudi et al., 2006). Studies have reported that complement component C3 is required during *S. stercoralis* infection and facilitates eosinophil degranulation and larval death during the innate immune response (Kerepesi et al., 2006).

*Strongyloides* infection induces the production of leukotrienes, which are required to invoke the protective expulsion of parasites. Leukotrienes play an important role in controlling parasite burdens, as well as in altering the parasite reproductive cycle and eliminating the *S. venezuelensis* parasite (Machado et al., 2005).

## 8. Pathology

The pathology of strongyloidiasis differs in different stages of infection.



### 8.1 Acute infection

The obligate pulmonary phase of the parasite's life cycle typically occurs within hours after infection. During larval passage through the lungs, the parasite induces haemorrhage in the alveolar spaces, inflammatory infiltrate, and, occasionally, granuloma (Kinjo et al., 1998).

Histopathological analyses of human intestines have shown that *S. stercoralis* eggs and adult females colonise the duodenum and upper jejunum. Studies have also demonstrated the presence of oedema, duodenal villous atrophy, and crypt hyperplasia with disrupted epithelium due to the inhibition of cell proliferation and apoptosis (Coutinho et al., 2006; Werneck-Silva et al., 2006). Surface damage, ulceration, an increase in mucus secretion and functional changes in the intestine have also been reported. In many cases, the eosinophil infiltrates are associated with the intensity of the infection (Rivasi et al., 2006; Kishimoto et al., 2008).

### 8.2 Hyperinfection syndrome

The histology of lungs affected by hyperinfection syndrome revealed alveolar haemorrhage with large numbers of larvae in the alveoli, septa, pleurae and blood vessels. Many larvae were present throughout the walls of the tracheobronchial tree, with an increase in number toward the upper respiratory tract. Larvae in the lungs provoked inflammatory infiltrate

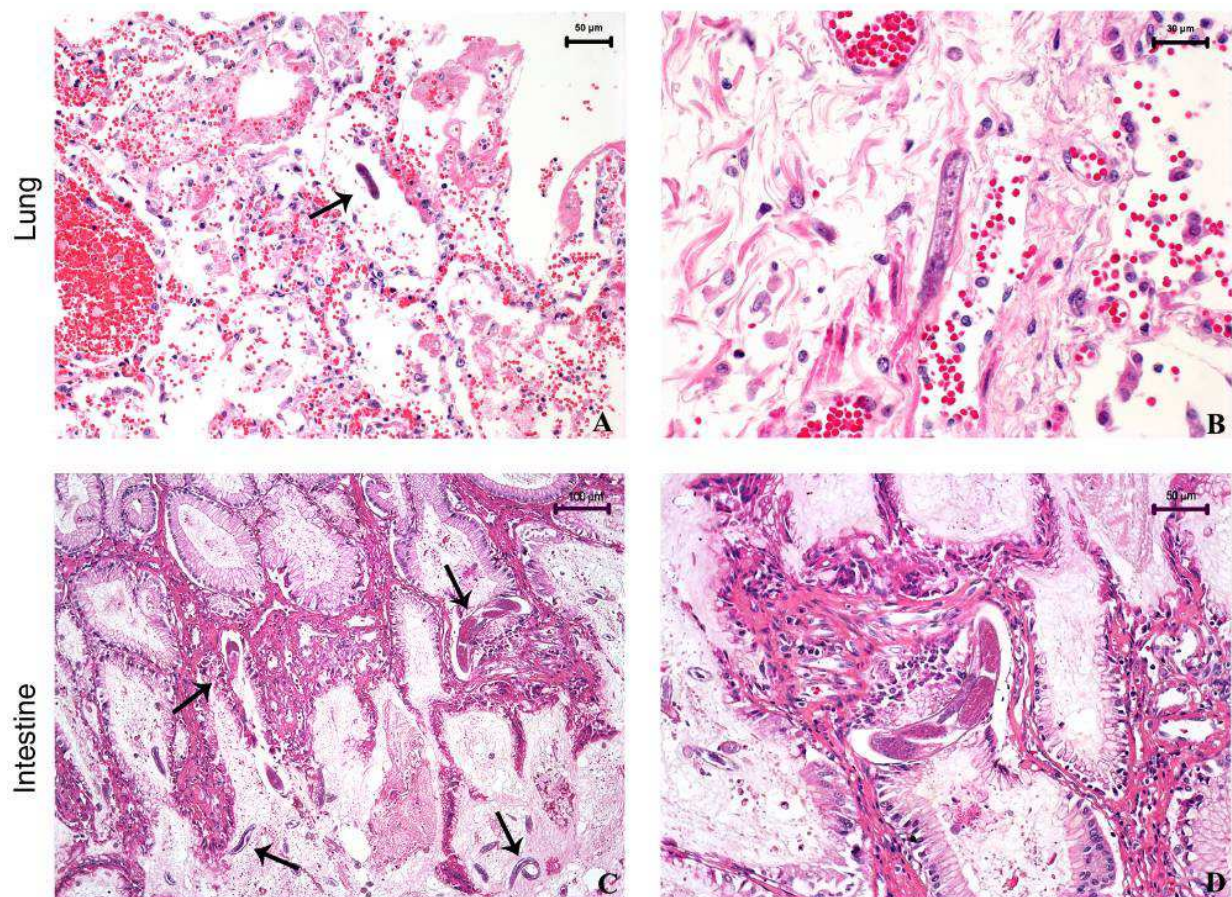


Fig. 2. Histopathology of *Strongyloides stercoralis* in the lungs and intestine of a 48-year-old woman with a gastric carcinoid tumor treated with chemotherapy. A and B: Pulmonary parenchyma. Note the presence of larvae in alveolar space (arrow). C and D: Female worms in the duodena (arrows). HE stain.



and were occasionally walled off by granulomas. Bronchopneumonia is probably a consequence of tissue damage inflicted by the invading larvae (Zumla & James, 2002). In the human intestine, hyperinfection results in mucosal oedema, acute inflammation, mucosal haemorrhage, and focal ulceration with numerous *S. stercoralis* larvae, adult worms and ova embedded within the small bowel villi (Sathe & Madiwale, 2006; Al Maslamani et al., 2009).

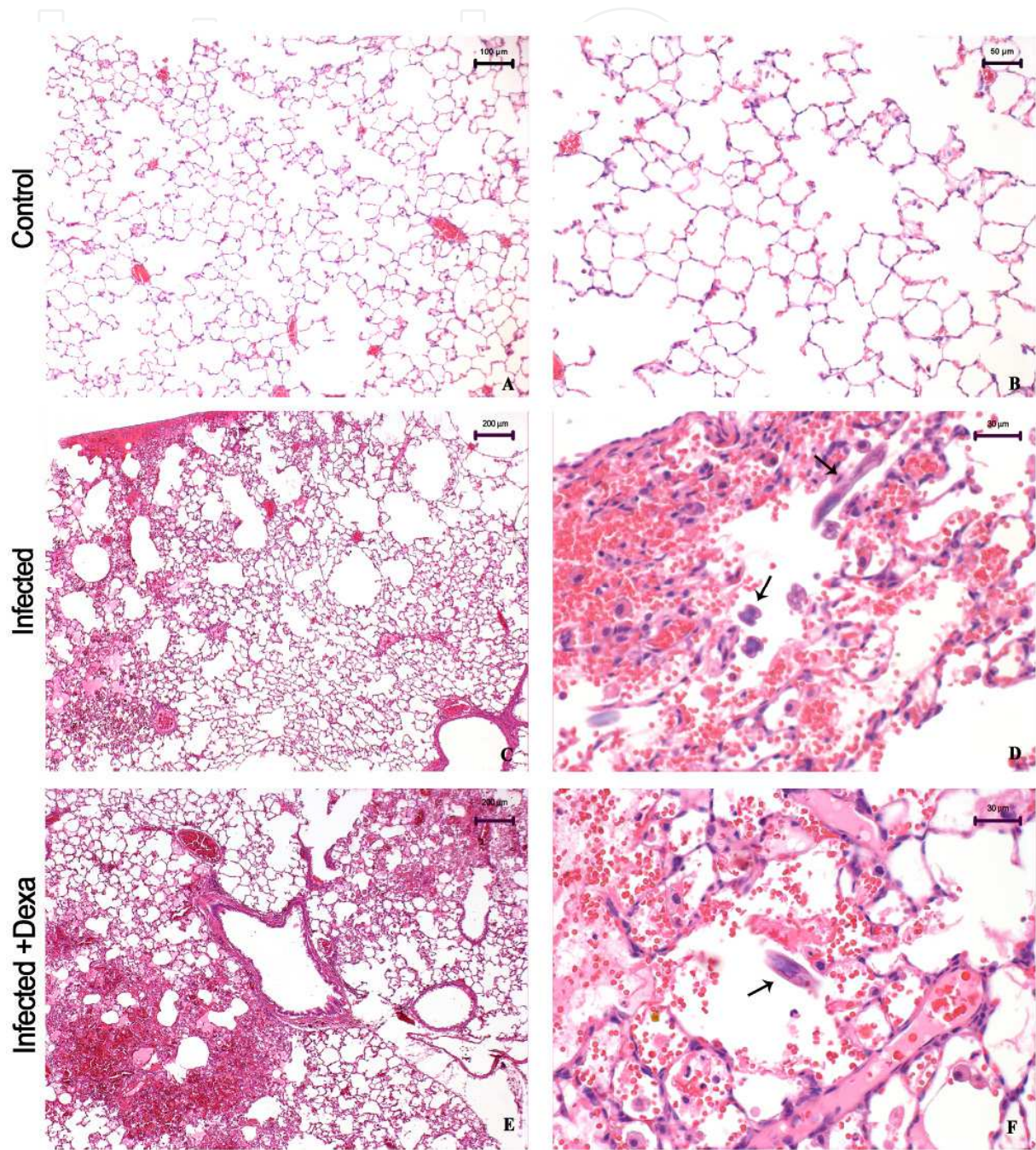


Fig. 3. Histopathology of the lungs of rats in an experimental model of strongyloidiasis on day 3 post-infection: A and B: Controls; C and D: Infected with *S. venezuelensis*. Note the scarce hemorrhagic foci with larvae in the alveolar spaces (arrows); E and F: Infected with *S. venezuelensis* and treated with dexamethasone. Note the prominent hemorrhagic foci showing larvae in the alveolar spaces (arrow). HE stain.



### 8.3 Hyperinfection syndrome in experimental models

Animal models are important for understanding the mechanism of hyperinfection. Studies in experimental models of *S. venezuelensis* infection have reported that filariform larvae were surrounded by inflammation mediated by eosinophils and mast cells in the lungs. The infection also promoted an important granulomatous response, sometimes entrapping the larvae, which is probably an attempt by the host to contain the parasite. In addition, airway

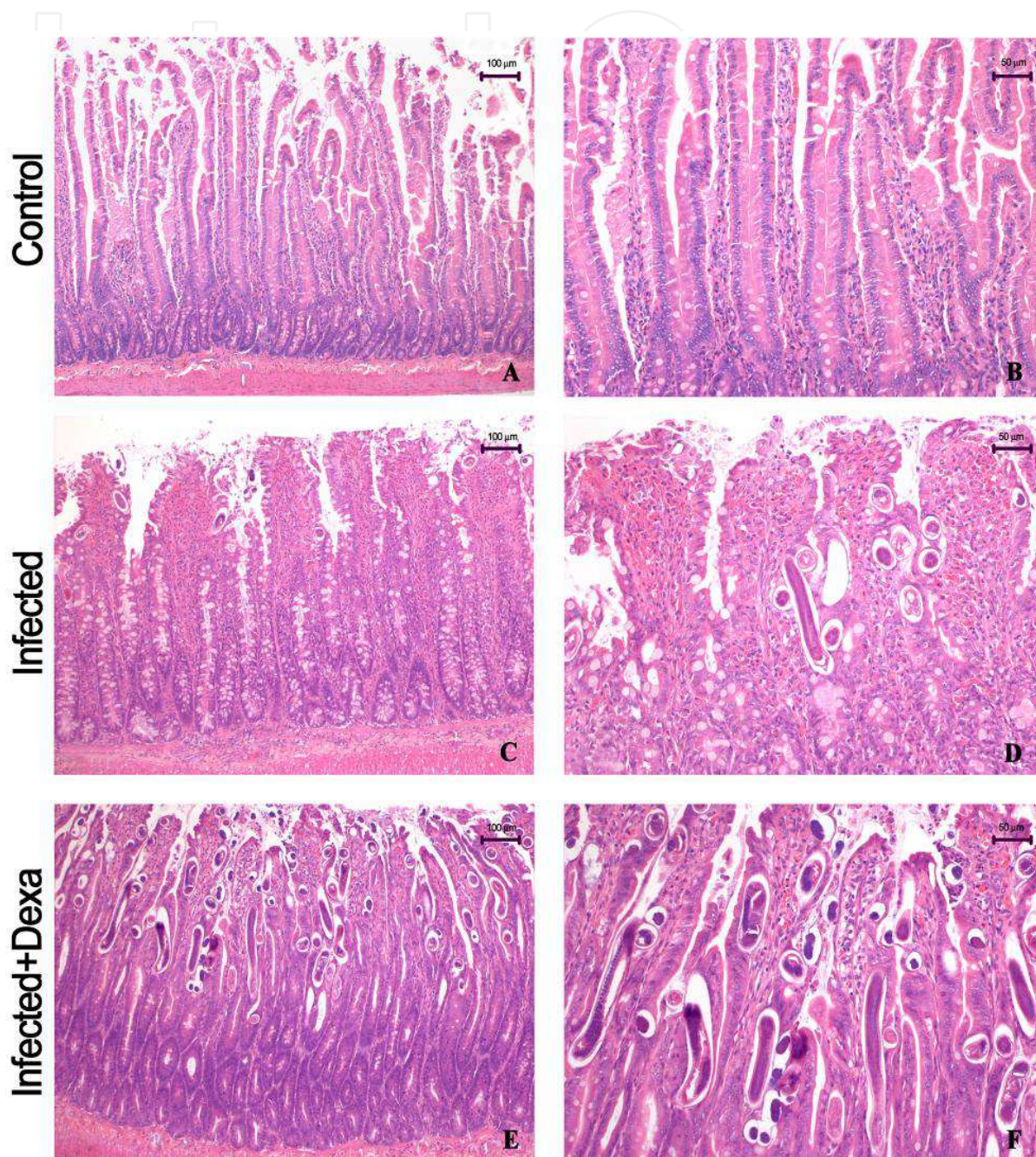


Fig. 4. Histopathology of the duodena of rats in an experimental model of strongyloidiasis on day 14 post-infection: A and B: Controls; C and D: Infected with *S. venezuelensis*. E and F: Infected with *S. venezuelensis* and treated with dexamethasone on day 14 post-infection. Note the massive mucosal invasion of fertile eggs and adult parasites, accompanied by erosion of the intestinal epithelial layer. HE stain.

remodelling similar to asthma, characterised by hyperplasia of goblet cells and increased bronchiolar wall thickness caused by oedema, hypertrophy of smooth muscle cells, neovascularisation and collagen deposition, was reported. In contrast, immunosuppression with dexamethasone interferes with the pulmonary cycle of *Strongyloides venezuelensis* infection and promotes greater haemorrhage, which is provoked by the substantial quantities of larvae that pass into the alveolar spaces, accompanied by a decrease in eosinophil and mast cell migration and impaired formation of granulomas (Tefé-Silva et al., 2008). In addition, dexamethasone treatment inhibited airway remodelling, contributing to the dissemination of the parasite (Tefé-Silva et al., 2012).

In the small intestine of rodents infected with *S. venezuelensis*, females and fertile eggs were observed in the wall of the gastrointestinal tract and invading the intestinal mucosa, with increased inflammatory exudate and eosinophils (Machado et al., 2005). Dexamethasone treatment promoted increased mucus production, which progressed to a massive mucosal invasion of fertile eggs and adult parasites that was accompanied by the erosion of the intestinal epithelial layer. Interestingly, the inflammatory response was relatively inconspicuous. Proliferative activity increased in the crypts and the villous fusion, resulting in an apparent reduction in the number of intestinal epithelial cells. In addition, dexamethasone enhanced parasite fertility and proliferation, with dissemination of the larvae to other visceral organs, such as the spleen, kidneys, heart, liver and brain (Machado et al., 2011).

Mice infected with *S. venezuelensis* and treated with dexamethasone showed increased blood neutrophil numbers and a reduction in eosinophil and mononuclear cell numbers in the blood, bronchoalveolar cells, and peritoneum when compared to *S. venezuelensis* infection in the absence of dexamethasone. In addition, dexamethasone impaired the host immune response, decreasing the production of cytokines such as tumour necrosis factor (TNF), interferon (IFN), interleukin-3 (IL-3), IL-4, IL-5, IL-10, and IL-12 in the lungs and circulating antibodies such as IgG, and IgE but increasing the overall parasite burden in the intestines and faeces (Machado et al., 2011).

## 9. Diagnosis

Strongyloidiasis is diagnosed on the basis of suspicion in patients with clinical signs and symptoms of the disease; however, in approximately 50% of cases, the infection is asymptomatic, complicating diagnosis. In some cases, diagnosis is difficult despite a low intestinal worm load and larval excretion in the faeces (Rajapurkar et al., 2007).

The classic triad of urticaria, abdominal pain and diarrhoea is suggestive of a diagnosis of strongyloidiasis. Parasites are usually found in the faeces; they are sometimes also seen in other body fluids or in tissue samples (Basile et al., 2010). The parasitological diagnosis is usually made after an examination of the faeces, and several diagnostic methods can be used to detect *S. stercoralis*, including stool examination, a modified Baermann technique, and stool culture on a blood agar plate. Enzyme-linked immunosorbent assays (ELISA) are used for serological diagnosis and have proven valuable in detecting both symptomatic and asymptomatic strongyloidiasis infection, with a high specificity for detecting IgG antibodies to *S. stercoralis* (Basile et al., 2010).

In patients with a disseminated infection, the diagnosis is relatively straightforward, given the high numbers of larvae that exist in the stool and, usually, in the sputum. White blood



cell numbers may be elevated. Although an increase in eosinophils frequently occurs during infection, studies have shown that an absence of eosinophilia does not exclude a diagnosis of strongyloidiasis (Krishnan et al., 2006). Diagnosis through imaging is usually possible. Chest radiographs of some patients have shown infiltrate consistent with Loeffler's syndrome. Methods such as bronchoalveolar lavage and sputum culture are used to diagnose disseminated strongyloidiasis (Williams et al., 1988, Yassin et al., 2010). Duodenal fluid aspiration and intestine biopsy or the use of Enterotest® may be required to detect the *Strongyloides* parasite (Yassin et al., 2010).

## 10. Treatment

Early identification of the disease and anthelmintic treatment results in a better prognosis for strongyloidiasis and, in many cases, prevents a fatal infection (Basile et al., 2010). *S. stercoralis* is resistant to anthelmintic drugs, and the parasite has the capacity to replicate and increase the worm burden again (Grove, 1996).

Thiabendazole, albendazole, and mebendazole are effective drugs against *S. stercoralis*. Thiabendazole was the drug of choice for treatment of strongyloidiasis, with a cure rate of up to 80%. Albendazole has variable therapeutic efficacy but has been used in hyperinfection syndrome and remains a viable treatment alternative to ivermectin. Mebendazole can be used to treat strongyloidiasis but is not recommended because of an association with liver dysfunction (Rajapurkar et al., 2007). Recently, there has been a change in the treatment of strongyloidiasis, as more studies support the choice of the drug ivermectin, which is effective at killing worms in the intestine. In patients with hyperinfection syndrome, ivermectin is considered the first-line therapy, and longer courses of treatment are indicated (Roxby et al., 2009).

Efficient treatment of strongyloidiasis depends on several factors that can decrease the efficacy of the drugs used for treatment, such as immunodeficiency, corticosteroid use, or co-infection with HTLV-1 (Vadlamudi et al., 2006). Prolonged or repeated treatment may be required in patients receiving immunosuppressive drugs.

Other measures, including decreasing the dosage of corticosteroids, discontinuing immunosuppressive therapies and treating bacterial infections, are essential elements in the treatment of these patients. In all cases, patients with strongyloidiasis, regardless of the severity of symptoms, must be treated to prevent long-term complications (Montes et al., 2010).

## 11. Control

Like other soil-transmitted nematode infections, strongyloidiasis can be controlled by improving sanitary conditions and properly disposing of faeces. Infected patients should be treated, even if they are asymptomatic, to preclude the possible onset of autoinfection. Immunosuppressants are contraindicated in these patients. Personal hygienic measures like proper protection of the skin to prevent contact with infected soil, community education about protective and hygienic measures, and prompt treatment of diagnosed cases would help prevent the disease (Vadlamudi et al., 2006).

## 12. Conclusion

Strongyloidiasis is an infection with a tendency to become chronic with an indolent course. However, in immunocompromised patients, especially those treated with corticosteroids,



hyperinfection syndrome can compromise the prognosis of the patient. The mortality rates of hyperinfection are high, making *Strongyloides* infection an important global health problem. It is important to understand the biology and immunology of infection with *S. stercoralis* and the altered courses of infection that may occur when immune regulation is compromised. Clinicians who are aware of the possibility of hyperinfection are better equipped to diagnose, treat, or altogether prevent the fatal consequences of this lethal nematode.

### 13. Acknowledgments

We wish to thank Elaine Medeiros Floriano for excellent technical assistance and Mara R. Celes and Marcela S. Oliveira for photography assistance.

**Financial support:** This study was supported by the FAPESP (Fundação de Amparo à Pesquisa do Estado de São Paulo) and CNPq (Conselho Nacional de Desenvolvimento Científico e Tecnológico). Cristiane Tefé-Silva is supported by a scholarship through CNPq. Simone G. Ramos and Lúcia H. Faccioli are investigators at CNPq.

### 14. References

- Abe, T., Sugaya, H., & Yoshimura, K. (1998). Analysis of T cell populations and IL-3 mRNA expression in mesenteric lymph node cells and intestinal intraepithelial lymphocytes in *Strongyloides ratti*-infected mice. *Journal of Helminthology*, Vol.72, No.1, (March), pp. 1-8, ISSN 0022-149X
- Abraham, D., Rotman, H.L., Haberstroh, H.F., Yutanawiboonchai, W., Brigandi, R.A., Leon, O., Nolan, T.J., & Schad, G.A. (1995). *Strongyloides stercoralis*: protective immunity to third-stage larvae in BALB/cByJ mice. *Experimental Parasitology*, Vol.80, No.2, (March), pp. 297-307, ISSN 1090-2449
- Al Maslamani, M.A., Al Soub, H.A., Al Khal, A.L., Al Bozom, I.A., Abu Khattab, M.J., & Chacko, K.C. (2009). *Strongyloides stercoralis* hyperinfection after corticosteroid therapy: a report of two cases. *Annals of Saudi of Medicine*, Vol.29, No.5, (September-October), pp. 397-401, ISSN 0975-4466
- Albonico, M., Crompton, D.W.T., & Savioli, L. (1999). Control strategies for human intestinal nematode infections. *Advances in Parasitology*, Vol.42, pp. 277-341, ISSN 0065-308X
- Anthony, R.M., Rutitzky, L.I., Urban, J.F. Jr., Stadecker, M.J., & Gause, W.C. (2007). Protective immune mechanisms in helminth infection. *Nature Reviews Immunology*, Vol.7, pp. 975-987, ISSN 1474-1733
- Armignacco, O., Capecchi, A., De Mori, P., & Grillo, L.R. (1989). *Strongyloides stercoralis* hyperinfection and the acquired immunodeficiency syndrome. *American Journal of Medicine*, Vol.86, No.2, (February), pp. 258, ISSN 0002-9343
- Balagopal, A., Mills, L., Shah, A., & Subramanian, A. (2009). Detection and treatment of *Strongyloides* hyperinfection syndrome following lung transplantation. *Transplant Infectious Disease*, Vol.11, No.2, (April), pp. 149-154, ISSN 1399-3062
- Bamias, G., Toskas, A., Psychogiou, M., Delladetsima, I., Siakavellas, S.I., Dimarogona, K., & Daikos, G.L. (2010). *Strongyloides* hyperinfection syndrome presenting as

- enterococcal meningitis in a low-endemicity area. *Virulence*, Vol.1, No.5, (September-October), pp. 468-470, ISSN 2150-5608
- Barr, J.R. (1978). *Strongyloides stercoralis*. *Canadian Medical Association Journal*, Vol.118, No.8, (April), pp. 933-935, ISSN 1488-2329
- Basile, A., Simzar, S., Bentow, J., Antelo, F., Shitabata, P., Peng, S.K., & Craft, N. (2010). Disseminated *Strongyloides stercoralis*: hyperinfection during medical immunosuppression. *Journal of the American Academy of Dermatology*, Vol.63, No.5, (November), pp. 896-902, ISSN 0190-9622
- Ben-Youssef, R., Baron, P., Edson, F., Raghavan, R., & Okechukwu, O. (2005). *Strongyloides stercoralis* infection from pancreas allograft: case report. *Transplantation*, Vol.80, No.7, (October), pp. 997-998, ISSN 1534-0608
- Brandt de Oliveira, R., Voltarelli, J.C., & Meneghelli, U.G. (1981). Severe strongyloidiasis associated with hypogammaglobulinaemia. *Parasite Immunology*, Vol.3, No.2, (Summer), pp. 165-169, ISSN 1365-3024
- Brown, M., Cartledge, J.D., & Miller, R.F. (2006). Dissemination of *Strongyloides stercoralis* as an immune restoration phenomenon in an HIV-1-infected man on antiretroviral therapy. *International Journal of STD & AIDS*, Vol.15, No.8, (August), pp.560-661, ISSN 0956-4624
- Carvalho, E.M. & Da Fonseca Porto, A. (2004). Epidemiological and clinical interaction between HTLV-1 and *Strongyloides stercoralis*. *Parasite Immunology*, Vol.26, No.11-12, (November-December), pp. 487-497, ISSN 1365-302
- Concha, R., Harrington, W.Jr., & Rogers, A.I. (2005). Intestinal strongyloidiasis: recognition, management, and determinants of outcome. *Journal of Clinical Gastroenterology*, Vol.39, No.3, (March), pp. 203-211, ISSN 1539-2031
- Coutinho, HB., Robalinho, T.I., Coutinho, V.B., Almeida, J.R., Filho, J.T., King, G., Jenkins, D., Mahida, Y., Sewell, H.F., & Wakelin, D. (1996). Immunocytochemistry of mucosal changes in patients infected with the intestinal nematode *Strongyloides stercoralis*. *Journal of Clinical Pathology*, Vol.49, No.10, (October), pp. 717-720, ISSN 1472-4146
- DeVault, G.A.Jr., King, J.W., Rohr, M.S., Landreneau, M.D., Brown, S.T.III., & McDonald, J.C. (1990). Opportunistic infections with *Strongyloides stercoralis* in renal transplantation. *Reviews of Infectious Diseases*, Vol.12, No.4, (July-August), pp. 653-671, ISSN 0162-0886
- Dulley, F.L., Costa, S., Cosentino, R., Gamba, C., & Saboya, R. (2009). *Strongyloides stercoralis* hyperinfection after allogeneic stem cell transplantation. *Bone Marrow Transplantation*, Vol.43, No.9, (May), pp. 741-742, ISSN 1476-5365
- Dutcher, J.P., Marcus, S.L., Tanowitz, H.B., Wittner, M., Fuks, J.Z., & Wiernik, P.H. (1990). Disseminated strongyloidiasis with central nervous system involvement diagnosed antemortem in a patient with acquired immunodeficiency syndrome and Burkitts lymphoma. *Cancer*, Vol.66, No.11, (December), pp. 2417-2420, ISSN 1097-0142
- El-Malky, M., Maruyama, H., Hirabayashi, Y., Shimada, S., Yoshida, A., Amano, T., Tominaga, A., Takatsu, K., & Ohta, N. (2003). Intraepithelial infiltration of eosinophils and their contribution to the elimination of adult intestinal nematode,

- Strongyloides venezuelensis* in mice. *Parasitology International*, Vol.52, No.1, (March), pp. 71-79, ISSN 1383-5769
- Galioto, A.M., Hess, J.A., Nolan, T.J., Schad, G.A., Lee, J.J., & Abraham, D. (2006). Role of eosinophils and neutrophils in innate and adaptive protective immunity to larval *Strongyloides stercoralis* in mice. *Infection and Immunity*, Vol.74, No.10, (October), pp. 5730-5738, ISSN 1098-5522
- Genta, R.M. (1989). Global prevalence of strongyloidiasis: critical review with epidemiologic insights into the prevention of disseminated disease. *Reviews of Infectious Diseases*, Vol.11, No.5, (September-October), pp. 755-767, ISSN 0162-0886
- Genta, R.M. (1992). Dysregulation of strongyloidiasis: a new hypothesis. *Clinical Microbiology Reviews*, Vol.5, No.4, (October), pp. 345-355, ISSN 1098-6618
- Grove, D.I. (1994). Strongyloidiasis: a conundrum for gastroenterologists. *Gut*, Vol.35, No.4, (April), pp. 437-440, ISSN 1468-3288
- Grove, D.I. (1996). Human strongyloidiasis. *Advances in Parasitology*, Vol.38, pp. 251-309, ISBN 0-12-031738-9, London United Kingdom
- Grove, D.I. (1989a). Clinical manifestations. In: Strongyloidiasis a major roundworm infection of man, D.I. Grove (Ed.), 155-174, Taylor and Francis, ISBN 0-85066-732-1, London, United Kingdom
- Herbert, D.R., Lee, J.J., Lee, N.A., Nolan, T.J., Schad, G.A., & Abraham, D. (2000) Role of IL-5 in innate and adaptive immunity to larval *Strongyloides stercoralis* in mice. *Journal of Immunology*, Vol.165, No.8, (October), pp. 4544-4551, ISSN 1550-6606
- Igra-Siegmán, Y., Kapila, R., Sem, P., Kaminski, Z.C., & Louria, D.B. (1981). Syndrome of hyperinfection with *Strongyloides stercoralis*. *Reviews of Infectious Diseases*, Vol.3, No.3, (May-June), pp. 397-407, ISSN 0162-0886
- Iriemenam, N.C., Sanyaolu, A.O., Oyibo, W.A., & Fagbenro-Beyioku, A.F. (2010). *Strongyloides stercoralis* and the immune response. *Parasitology International*, Vol.59, No.1, (March), pp. 9-14, ISSN 1383-5769
- Keiser, P.B. & Nutman, T.B. (2004). *Strongyloides stercoralis* in the immunocompromised population. *Clinical Microbiology Reviews*, Vol.17, No.1, (January), pp. 208-217, ISSN 1098-6618
- Kerepesi, L.A., Hess, J.A., Nolan, T.J., Schad, G.A., & Abraham, D. (2006). Complement component C3 is required for protective innate and adaptive immunity to larval *Strongyloides stercoralis* in mice. *The Journal of Immunology*, Vol. 176, No.7, (April), pp. 4315-4322, ISSN 1550-6606
- Kimura, K., Song, C.H., Rastogi, A., Dranoff, G., Galli, S.J., & Lantz, C.S. (2006). Interleukin-3 and c-Kit/stem cell factor are required for normal eosinophil responses in mice infected with *Strongyloides venezuelensis*. *Laboratory Investigation*, Vol.86, No.10, (October), pp. 987-996, ISSN 1530-0307
- Kinjo, T., Tsuchiko, K., Nakazato, I., Ito, E., Sato, Y., Koyanagi, Y., & Iwamasa, T. (1998). Extensive intra-alveolar haemorrhage caused by disseminated strongyloidiasis. *International Journal for Parasitology*, Vol.28, No.2, (February), pp. 323-330, ISSN 1879-013
- Kishimoto, K., Hokama, A., Hirata, T., Ihama, Y., Nakamoto, M., Kinjo, N., Kinjo, F., & Fujita, J. (2008). Endoscopic and histopathological study on the duodenum of *Strongyloides*

- stercoralis* hyperinfection. *World Journal of Gastroenterology*, Vol.14, No.11, (March), pp. 1768-1773, ISSN 1007-9327
- Klion, A.D. & Nutman, T.B. (2004). The role of eosinophils in host defense against helminth parasites. *Journal of Allergy and Clinical Immunology*, Vol.113, No.1, (January), pp. 30-37, ISSN 0091-6749
- Krishnan, S., Barger, G., & Chandrasekar, P. (2006). Recurrent *Strongyloides stercoralis* hyperinfection syndrome case report and a brief review. *Infectious Diseases in Clinical Practice*, Vol.14, No.4, (July), pp. 240-243, ISSN 1056-9103
- Kobayashi, T., Tsuchiya, K., Hara, T., Nakahata, T., Kurokawa, M., Ishiwata, K., Uchiyama, F., & Nawa, Y. (2008). Intestinal mast cell response and mucosal defence against *Strongyloides venezuelensis* in interleukin-3-hyporesponsive mice. *Parasite Immunology*, Vol.20, No.6, (June), pp. 279-284, ISSN 1365-3024
- Lantz, C.S., Min, B., Tsai, M., Chatterjea, D., Dranoff, G., & Galli, S.J. (2008). IL-3 is required for increases in blood basophils in nematode infection in mice and can enhance IgE-dependent IL-4 production by basophils in vitro. *Laboratory Investigation*, Vol.88, No.11, (November), pp. 1134-1142, ISSN 1530-0307
- Ligas, J.A., Kerepesi, L.A., Galioto, A.M., Lustigman, S., Nolan, T.J., Schad, G.A., & Abraham, D. (2003). Specificity and mechanism of immunoglobulin M (IgM)- and IgG-dependent protective immunity to larval *Strongyloides stercoralis* in mice. *Infection and Immunity*, Vol.71, No.12, (December), pp. 6835-6843, ISSN 1098-5522
- Lindo, J.F., Dubon, J.M., Ager, A.L., de Gourville, E.M., Solo-Gabriele, H., Klaskala, W.I., Baum, M.K., & Palmer, C.J. (1998). Intestinal parasitic infections in human immunodeficiency virus (HIV)-positive and HIV-negative individuals in San Pedro Sula, Honduras. *American Journal of Tropical Medicine and Hygiene*. Vol.58, No.4, (April), pp. 431-435, ISSN 0002-9637
- Link, K. & Orenstein, R. (1999). Bacterial complications of strongyloidiasis: *Streptococcus bovis meningitis*. *Southern Medical Journal*, Vol.72, No.7, (July), pp. 728-731, ISSN 0038-4348
- Machado, E.R., Ueta, M.T., Lourenço, E.V., Anibal, F.F., Sorgi, C.A., Soares, E.G., Roque-Barreira, M.C., Medeiros, A.I., & Faccioli, L.H. (2005). Leukotrienes play a role in the control of parasite burden in murine strongyloidiasis. *Journal of Immunology*, Vol.175, No.6, (September), pp. 3892-3899, ISSN 1550-6606
- Machado, E.R., Carlos, D., Lourenço, E.V., Sorgi, C.A., Silva, E.V., Ramos, S.G., Ueta, M.T., Aronoff, D.M., & Faccioli, L.H. (2009). Counterregulation of Th2 immunity by interleukin 12 reduces host defenses against *Strongyloides venezuelensis* infection. *Microbes and Infection*, Vol.11, No.5, (April), pp. 571-578, ISSN 1286-4579
- Machado, E.R., Carlos, D., Sorgi, C.A., Ramos, S.G., Souza, D.I., Soares, E.G., Costa-Cruz, J.M., Ueta, M.T., Aronoff, D.M., & Faccioli, L.H. (2011). Dexamethasone effects in the *Strongyloides venezuelensis* infection in murine model. *American Journal of Tropical Medicine and Hygiene*, Vol.84, No.6, (June), pp. 957-966, ISSN 0002-9637



- Mahmoud, A.A. (1996). Strongyloidiasis. *Clinical Infectious Diseases*, Vol.23, No.5, (November), pp. 949-952, ISSN 1537-6591
- Maizels, R.M. & Yazdanbakhsh, M. (2003). Immune regulation by helminth parasites: cellular and molecular mechanisms. *Nature Reviews Immunology*, Vol.3, (September), pp. 733-744, ISSN 1474-1733
- Marcos, L.A., Terashima, A., Dupont, H.L., & Gotuzzo, E. (2008). *Strongyloides* hyperinfection syndrome: an emerging global infectious disease. *Transaction of the Royal Society of Tropical Medicine and Hygiene*, Vol.102, No.4, (April), pp. 314-318, ISSN 0035-9203
- Mir, A., Benahmed, D., Igual, R., Borrás, R., O'Connor, J.E., Moreno, M.J., & Rull, S. (2006). Eosinophil-selective mediators in human strongyloidiasis. *Parasite Immunology*, Vol.28, No.8, (August), pp. 397-400, ISSN 1365-3024
- Montes, M., Sanchez, C., Verdonck, K., Lake, J.E., Gonzalez, E., Lopez, G., Terashima, A., Nolan, T., Lewis, D.E., Gotuzzo, E., White, & A.C.Jr. (2009). Regulatory T cell expansion in HTLV-1 and strongyloidiasis co-infection is associated with reduced IL-5 responses to *Strongyloides stercoralis* antigen. *PLoS Neglected Tropical Diseases*, Vol.9, No.6, (June), pp. e456, ISSN 1935-2735
- Negrão-Corrêa, D., Pinho, V., Souza, D.G., Pereira, A.T., Fernandes, A., Scheuermann, K., Souza, A.L., & Teixeira, M.M. (2006). Expression of IL-4 receptor on non-bone marrow-derived cells is necessary for the timely elimination of *Strongyloides venezuelensis* in mice, but not for intestinal IL-4 production. *International Journal for Parasitology*, Vol.36, No.10-11, (September), pp. 1185-1195, ISSN 1879-0135
- Olsen, A., van Lieshout, L., Marti, H., Polderman, T., Polman, K., Steinmann, P., Stothard, R., Thybo, S., Verweij, J.J., & Magnussen, P. (2009). Strongyloidiasis-the most neglected of the neglected tropical diseases? *Transaction of the Royal Society of Tropical Medicine and Hygiene*, Vol.103, No.10, (October), pp. 967-972, ISSN 0035-9203
- Padigel, U.M., Lee, J.J., Nolan, T.J., Schad, G.A., & Abraham, D. (2006). Eosinophils can function as antigen-presenting cells to induce primary and secondary immune responses to *Strongyloides stercoralis*. *Infection and Immunity*, Vol.74, No.6, (June), pp. 3232-3238, ISSN 1098-5522
- Pampiglione, S. & Ricciardi, M.L. (1972). Geographic distribution of *Strongyloides fuelleborni* in humans in tropical Africa. *Parasitologia*, Vol.14, pp. 329-338
- Patel, N., Kreider, T., Urban JF Jr., & Gause, W.C. (2009). Characterisation of effector mechanisms at the host: parasite interface during the immune response to tissue-dwelling intestinal nematode parasites. *International Journal for Parasitology*, Vol.39, No.1, (January), pp. 13-21, ISSN 1879-0135
- Paterson, S., Wilkes, C., Bleay, C., & Viney, M.E. (2008). Immunological responses elicited by different infection regimes with *Strongyloides ratti*. *PLoS One*, Vol.3, No.6, (June), pp. e2509, ISSN 1932-6203
- Porto, A.F., Neva, F.A., Bittencourt, H., Lisboa, W., Thompson, R., Alcântara, L., & Carvalho, E.M. (2001). HTLV-1 decreases Th2 type of immune response in patients with



- strongyloidiasis. *Parasite Immunology*, Vol.23, No.9, (September), pp. 503-507, ISSN 1365-3024
- Rajapurkar, M., Hegde, U., Rokhade, M., Gang, S., & Gohel, K. (2007). Respiratory hyperinfection with *Strongyloides stercoralis* in a patient with renal failure. *Nature Clinical Practice Nephrology*, Vol.3, No.10, (October), pp. 573-577, ISSN 1745-8331
- Rivasi, F., Pampiglione, S., Boldorini, R., & Cardinale, L. (2006). Histopathology of gastric and duodenal *Strongyloides stercoralis* locations in fifteen immunocompromised subjects. *Archives of Pathology & Laboratory Medicine*, Vol.130, No.12, (December), pp. 1792-1798, ISSN 1543-2165
- Rodriguez-Hernandez, M.J., Ruiz-Perez-Pipaon, M., Cañas, E., Bernal, C., & Gavilan, F. (2009). *Strongyloides stercoralis* hyperinfection transmitted by liver allograft in a transplant recipient. *American Journal of Transplantation*, Vol.9, No.11, (November), pp. 2637-2640, ISSN 1600-6143
- Roxby, A.C., Gottlieb, G.S., & Limaye, A.P. (2009). Strongyloidiasis in transplant patients. *Clinical Infection Diseases*, Vol.49, No.9, (November), pp. 1411-1423, ISSN 1537-6591
- Sathe, P.A. & Madiwale, C.V. (2006). Strongyloidiasis hyperinfection in a patient with membranoproliferative glomerulonephritis. *Journal of Postgraduate Medicine*, Vol.52, No.3, (July-September), pp. 221-222, ISSN 0022-3859
- Schad, G.A. (1989). Morphology and life history of *Strongyloides stercoralis*. In: Strongyloidiasis a major roundworm infection of man, D.I. Grove (Ed.), 85-104, Taylor and Francis, ISBN 0-85066-732-1, London, United Kingdom
- Schaeffer, M.W., Buell, J.F., Gupta, M., Conway, G.D., Akhter, S.A., & Wagoner, L.E. (2004). *Strongyloides* hyperinfection syndrome after heart transplantation: case report and review of the literature. *The Journal of Heart and Lung Transplantation*, Vol.23, No.7, (July), pp. 905-911, ISSN 1053-2498
- Seet, R.C., Lau, L.G., & Tambyah, P.A. (2005). *Strongyloides* hyperinfection and hypogammaglobulinemia. *Clinical and Diagnostic Laboratory Immunology*, Vol.12, No.5, (May), pp. 680-682, ISSN 1098-6588
- Shea-Donohue; T.B. & Urban, J.F.Jr. (2004). Gastrointestinal parasite and host interactions. *Current Opinion in Gastroenterology*, Vol.20, No.1 (January), pp. 3-9, ISSN 1531-7056
- Siddiqui, A.A. & Berk, S.L. (2001). Diagnosis of *Strongyloides stercoralis* infection. *Clinical Infectious Diseases*, Vol.33, No.7, (October), pp. 1040-1047, ISSN 1537-6591
- Siddiqui, A.A., Stanley, C.S., Skelly, P.J., & Berk, S.L. (2000). A cDNA encoding a nuclear hormone receptor of the steroid/thyroidhormone-receptor superfamily from the human parasitic nematode *Strongyloides stercoralis*. *Parasitology Research*, Vol.86, No.1, (January), pp. 24-29, ISSN 1432-1955
- Speare, R. (1989). Identification of species of *Strongyloides*. In: Strongyloidiasis a major roundworm infection of man, D.I. Grove (Ed.), 11-84, Taylor and Francis, ISBN 0-85066-732-1, London, United Kingdom
- Tefé-Silva, C., Souza, D.I., Ueta, M.T., Floriano, E.M., Faccioli, L.H., & Ramos, S.G. (2008). Interference of dexamethasone in the pulmonary cycle of *Strongyloides venezuelensis*

- in rats. *American Journal of Tropical Medicine and Hygiene*, Vol.79, No.4, (October), pp. 571-578, ISSN 0002-9637
- Tefé-Silva, C., Beneli, C.T., Celes, M.R., Machado, E.R., Ueta, M.T., Sorgi, C.A., Floriano, E.M., Faccioli, L.H., & Ramos, S.G. (2012). Dexamethasone reduces bronchial wall remodeling during pulmonary migration of *Strongyloides venezuelensis* larvae in rats. *Parasitology International*, Accepted, ISSN 1383-5769
- Trajman, A., MacDonald, T.T., & Elia, C.C. (1997). Intestinal immune cells in *Strongyloides stercoralis* infection. *Journal of Clinical Pathology*, Vol.50, No.12, (December), pp. 991-995, ISSN 1472-4146
- Urban, J.F.Jr., Madden, K.B., Svetić, A., Cheever, A., Trotta, P.P., Gause, W.C., Katona, J.M., & Finkelman, F.D. (1992). The importance of Th2 cytokines in protective immunity to nematodes. *Immunology Reviews*, Vol.127, (June), pp. 205-220, ISSN 1600-065X
- Vadlamudi, R.S., Chi, D.S., & Krishnaswamy, G. (2006). Intestinal strongyloidiasis and hyperinfection syndrome. *Clinical and Molecular Allergy*, Vol.4, No.8, (May), ISSN 1476-7961
- Valar, C., Keitel, E., Dal Prá, R.L., Gnatta, D., Santos, A.F., Bianco, P.D., Sukiennik, T.C., Pegas, K.L., Bittar, A.E., Oliveira, K.T., & Garcia, V.D. (2007). Parasitic infection in renal transplant recipients. *Transplantation Proceedings*, Vol.39, No.2, (March), pp. 460-462, ISSN 0041-1345
- Vilela, E.G., Clemente, W.T., Mira, R.R., Torres, H.O., Veloso, L.F., Fonseca, L.P, de Carvalho E Fonseca, L.R., Franca, M.C., & Lima, A.S. (2009). *Strongyloides stercoralis* hyperinfection syndrome after liver transplantation: case report and literature review. *Transplant Infectious Disease*, Vol.11, No.2, (April), pp. 132-136, ISSN 1399-3062
- Viney, M.E. & Lok, J.B. (2007). *Strongyloides* spp. *WormBook*, Vol.23, No.2, (April), pp. 1-15, ISSN 1551-8507
- Werneck-Silva, A.L., Alvares, E.P., Gama, P., Damiao, A.O., Osaki, L.H., Ogias, D., & Sipahi, A.M. (2006). Intestinal damage in strongyloidiasis: the imbalance between cell death and proliferation. *Digestive Diseases Sciences*, Vol.51, No.6, (June), pp. 1063-1069, ISSN 1573-2568
- Wilkes, C.P., Bleay, C., Paterson, S., & Viney, M.E. (2007). The immune response during a *Strongyloides ratti* infection of rats. *Parasite Immunology*, Vol.29, No.7, (July), pp. 339-346, ISSN 1365-3024
- Williams, J., Dralle, W., Berk, S.L., & Verghese, A. (1988). Diagnosis of pulmonary strongyloidiasis by bronchoalveolar lavage. *Chest*, Vol.94, No.3, (September), pp. 643-644, ISSN 1931-3543
- Wirk, B., & Wingard, J.R. (2009). *Strongyloides stercoralis* hyperinfection in hematopoietic stem cell transplantation. *Transplant Infectious Disease*, Vol.11, No.2, (April), pp. 143-148, ISSN 1399-3062
- Yassin, M.A., El Omri, H., Al-Hijji, I., Taha, R., Hassan, R., Aboudi, K.A., & El-Ayoubi, H. (2010). Fatal *Strongyloides stercoralis* hyper-infection in a patient with multiple myeloma. *The Brazilian Journal of Infectious Diseases*, Vol.14, No.5, (October), pp. 536-539, ISSN 1678-4391

Zumla, A.I. & James, D.G. (2002). Immunologic aspects of tropical lung disease. *Clinics in Chest Medicine*, Vol.23, No.2, (June), pp. 283-308, ISSN 1557-8216

IntechOpen

IntechOpen



### **Current Topics in Tropical Medicine**

Edited by Dr. Alfonso Rodriguez-Morales

ISBN 978-953-51-0274-8

Hard cover, 564 pages

**Publisher** InTech

**Published online** 16, March, 2012

**Published in print edition** March, 2012

Tropical Medicine has emerged and remained as an important discipline for the study of diseases endemic in the tropic, particularly those of infectious etiology. Emergence and reemergence of many tropical pathologies have recently aroused the interest of many fields of the study of tropical medicine, even including new infectious agents. Then evidence-based information in the field and regular updates are necessary. Current Topics in Tropical Medicine presents an updated information on multiple diseases and conditions of interest in the field. It includes pathologies caused by bacteria, viruses and parasites, protozoans and helminths, as well as tropical non-infectious conditions. Many of them are considering not only epidemiological aspects, but also diagnostic, therapeutic, preventive, social, genetic, bioinformatic and molecular ones. With participation of authors from various countries, many from proper endemic areas, this book has a wide geographical perspective. Finally, all of these characteristics, make an excellent update on many aspects of tropical medicine in the world.

#### **How to reference**

In order to correctly reference this scholarly work, feel free to copy and paste the following:

Cristiane Tefé-Silva, Eleuza R. Machado, Lúcia H. Faccioli and Simone G. Ramos (2012). Hyperinfection Syndrome in Strongyloidiasis, Current Topics in Tropical Medicine, Dr. Alfonso Rodriguez-Morales (Ed.), ISBN: 978-953-51-0274-8, InTech, Available from: <http://www.intechopen.com/books/current-topics-in-tropical-medicine/hyperinfection-syndrome-in-strongyloidiasis>

**INTeCH**  
open science | open minds

#### **InTech Europe**

University Campus STeP Ri  
Slavka Krautzeka 83/A  
51000 Rijeka, Croatia  
Phone: +385 (51) 770 447  
Fax: +385 (51) 686 166  
[www.intechopen.com](http://www.intechopen.com)

#### **InTech China**

Unit 405, Office Block, Hotel Equatorial Shanghai  
No.65, Yan An Road (West), Shanghai, 200040, China  
中国上海市延安西路65号上海国际贵都大饭店办公楼405单元  
Phone: +86-21-62489820  
Fax: +86-21-62489821

© 2012 The Author(s). Licensee IntechOpen. This is an open access article distributed under the terms of the [Creative Commons Attribution 3.0 License](https://creativecommons.org/licenses/by/3.0/), which permits unrestricted use, distribution, and reproduction in any medium, provided the original work is properly cited.

IntechOpen

IntechOpen