

We are IntechOpen, the world's leading publisher of Open Access books Built by scientists, for scientists

6,900

Open access books available

186,000

International authors and editors

200M

Downloads

Our authors are among the

154

Countries delivered to

TOP 1%

most cited scientists

12.2%

Contributors from top 500 universities



WEB OF SCIENCE™

Selection of our books indexed in the Book Citation Index
in Web of Science™ Core Collection (BKCI)

Interested in publishing with us?
Contact book.department@intechopen.com

Numbers displayed above are based on latest data collected.
For more information visit www.intechopen.com



SAPHO Syndrome

Gunter Assmann
*University Medical School of Saarland
 Germany*

1. Introduction

In 1987, Chamot et al attempted to unify the various descriptions of osteoarticular disease associated with skin manifestations into a syndrome with the acronym SAPHO: synovitis, acne, pustulosis, hyperostosis, and osteitis (Chamot et al., 1987). Furthermore, the clinical feature of aseptic chronic recurrent multiple osteomyelitis (CRMO) accompanied by pustulosis with its typical presentation in the pediatric population justifies the inclusion of CRMO into the same nosologic group as the SAPHO syndrome according to several authors (Juri et al., 1988, Kahn et al., 1994). The differentiating clinical features of pediatric CRMO and adult hyperostosis with osteitis in patients with SAPHO syndrome seem to be mainly in localization of inflammation: in pediatric CRMO more often the extremities, in adults the axial skeleton preferentially with costosternoclavicular region (Rohekar et al., 2006). The wide spectrum of SAPHO syndrome describes overlapping clinical radiologic and pathologic characteristics that SAPHO shares with well-defined rheumatologic and dermatologic disorders, such as psoriatic arthritis (PsA) and ankylosing spondylitis (AS). Against this background the SAPHO syndrome has been often controversially discussed and more than 50 competing terms have been proposed for these or for very similar entities, among others pustulotic arthro-osteitis and acquired hyperostosis syndrome (AHS) (Kirchhoff et al., 2003). With the increase in reports dealing with growing numbers of patients with SAPHO syndrome, this disease entity should be suspected in patients who fulfil one of the following diagnostic criteria (Assmann et al., 2011): (1) Osteoarticular manifestations with dermatosis like acne conglobata, acne fulminans, or palmoplantar pustulosis (PPP); (2) axial or appendicular osteitis and hyperostosis with or without dermatosis; (3) CRMO involving the axial or appendicular skeleton with or without dermatosis. However, in this broad spectrum of osteoarticular and chronic dermatological manifestations, osteitis seems to be the leading characteristic finding to determine the entity of SAPHO syndrome.

2. Epidemiologic data

The question of the frequency of the SAPHO syndrome is first of all an issue of history: In the 1960s, there were several reports of patients with musculoskeletal disorders and associated dermatologic lesions that were related to neutrophilic dermatitis (acne, PPP, pyoderma gangrenosum) (Windom et al., 1961). In 1972, a very rare pathological entity of unknown aetiology, CRMO, was first described – with or without PPP (Giedion et al., 1972; Bjorksten et al., 1978). Subsequently, several similar cases of pustulotic arthro-osteitis have

been reported and have been called by a variety of different terms such as Koehler's disease, pyogenic sterile arthritis, or PAPA syndrome. However, only with the introduction of the acronym SAPHO as a unifying concept adequate data about the prevalence of this syndrome have been available: in the beginning of 1990, only 225 cases of SAPHO were described in Germany, Austria and Switzerland, and about 400 cases in France. Astonishingly enough, in 2009 there were estimates that the prevalence of SAPHO syndrome was probably no greater than 1 in 10,000 based on several reports about the disease from Japan and north-western Europe (Kahn et al., 1994a, 2009b). SAPHO can occur at any age, but demographic data show that it is a disease of children, young adults or middle-aged individuals, with a female predilection (Mueller-Richter et al., 2009). The disease has been reported mainly from Japan and Northern Europe, rarely from Anglo-Saxon countries. It rarely occurs beyond the sixth decade of life (Van Doornum et al., 2000). However, it is difficult to determine whether this observation of geographic characteristics is related to immunogenic or ethnic differences or just to the failure to clinically recognize this syndrome in other areas than Japan or Europe.

3. Etiology

The aetiology of SAPHO syndrome is still not known but various theories have been postulated including genetic considerations, a possible link with an infectious agent and/or immune dysfunction.

3.1 Genetics

Several genetic abnormalities have been identified in patients with SAPHO syndrome. The association with the positivity for HLA B27 is only evident in cases with SAPHO syndrome and AS for the overall observation any association is not firmly established (Colina et al., 2009; Earwaker et al., 2003, Kahn et al., 1994). A murine model developed for displaying the characteristic chronic multifocal aseptic osteomyelitis seen in SAPHO syndrome showed a mutation mapped to chromosome 18 affecting the proline-serine-threonine phosphatase interacting protein 2 (PSTPIP2). These results were confirmed by the localisation of the susceptibility gene from CRMO patients to chromosome 18q21.3-18q22 (Ferguson et al., 2006; Golla et al., 2002). Similarly, pyogenic sterile arthritis, pyoderma gangrenosum, and acne syndrome (PAPA syndrome) has characteristics that may lend insight to the pathogenesis of SAPHO syndrome. PAPA has been found to be transmitted in an autosomal dominant fashion, and the predisposing genetic variation is located on chromosome 15 affecting CD2-binding protein/PSTPIP1 (Yeon et al., 2000; Wise et al., 2002). The Majeed syndrome, an inherited disease first described in 1989, is characterized by neutrophilic dermatosis, multiple osteitic lesions, and abnormalities of erythropoiesis (Majeed et al., 1989). It is caused by a mutation on gene LPIN2, which encodes lipin 2. Lipin 2 may be involved in the apoptosis of polymorphonuclear neutrophils (PMN) (Ferguson et al., 2005). Another pathway of putative importance is the NOD2/CARD15 system leading to an exaggerated response to intestinal bacteria through an up-regulation of the pro-inflammatory transcription factor NFκB (Hayem et al., 2007). Recent studies have shown that p53 as an important negative regulator of NFκB can in turn be blocked by its own negative regulator, the E3 ubiquitin ligase human murine double minute Mdm2 (Gudkov et al., 2007). In this context, one of these studies reported susceptibility for SAPHO syndrome

due to the Mdm2 SNP T309G allele causing higher Mdm2 levels and thus a less efficient p53 response with possibly higher NFκB activity (Assmann et al., 2010).

3.2 Infectious agent

Numerous investigations have brought forth the theory that osteitis and its dermatologic manifestations in patients with SAPHO syndrome are results of persisting pathogen of low virulence, or that the syndrome is triggered by a pathogen and sustained by an autoimmune response subsequent to that infectious challenge (Rohekar et al., 2006; Kahn et al., 1995). The infectious theory has long been proposed with conflicting reports, most of them implicating *Propionibacterium acnes* (*P. acnes*), a slowly growing anaerobic microorganism usually found in acne lesions and considered to be a normal inhabitant of the skin (Kotilainen et al., 1996). Furthermore, a part of coagulase negative *staphylococcus aureus*, *haemophilus parainfluenzae*, and *actinomyces* were reported to be associated with SAPHO syndrome (Rozin et al., 2007; Eyrich et al., 2000). However, positive cultures could not be found in all procedures of bone biopsy specimen. A possible explanation might be the ability of *P. acnes* to persist in bone lesions in a form that does not permit culturing. Although the bone lesions are often sterile, several recent studies have reported an association between SAPHO and *P. acnes* in 42% of the cases in total (Assmann et al., 2011). In particular, a recent study by Assmann et al. (2009) showed positive microbiological cultures for *P. acnes* in 67% of the bone biopsies. However, the mechanism that potentially leads to osteitis or arthritis by microbes is still unknown. The *ex vivo* effect of *P. acnes* on blood PMN isolated from patients with SAPHO syndrome was found to be dose dependant but impaired compared with rheumatoid arthritis (RA) or PsA patients. Interestingly, the PMN capacity for interleukin (IL-8) and tumor necrosis factor α (TNFα) production upon *P. acnes* stimulation was drastically lower in SAPHO patients, suggesting hyporeactivity to *P. acnes*, probably related to chronic exposure to this semi-pathogenic bacterium. In which way this potential desensitization to bacterial challenge plays a pathological role in the etiology of osteitis and/or dermatitis (acne, PPP) remains to be proved (Amital et al., 2008; Hurtado-Nedelec et al., 2008).

3.3 Immune dysfunction

According to this observation the SAPHO syndrome seems to be associated with inflammatory cytokine release and global neutrophil activation. In comparison with other rheumatologic disorders the SAPHO syndrome suggests a comparable hyperstimulation of innate immune response, as reflected by increased levels of IL-8 and TNFα by neutrophils in response to *ex vivo* stimulation (Magrey et al., 2009; Hurtado-Nedelec et al., 2008). Furthermore, elevated plasma levels of IL-8 and IL-18, but not IL-10 could be observed.

Together with the above outlined hyporeactivity to *P. acnes* the scenario indicates an altered immune mechanism in patients with SAPHO syndrome. With regard to the characteristic lesion of the SAPHO syndrome, osteitis with hyperostosis and/or CRMO, respectively, bone biopsy showed hypercellular bone marrow with large numbers of plasma cells and neutrophile polymorphs in different samples (Gikas et al., 2009). However, a paucity of inflammation with predominant sclerosis and fibrosis frequently occurs in the chronic phase. Wagner et al. (2002) demonstrate an elevated level of TNFα expression in bone biopsy specimens. Generally, the bone lesions in SAPHO syndrome have to be described as a histologically nonspecific inflammation. Accordingly, osteitic lesions may preferentially

occur due to auto-amplified reaction to a low-virulence infection (Edlund et al., 1988). In this context, a comparison of T-cell stimulatory activity in skin lesions showed that *P. acnes* may trigger the non-specific activation of cell-mediated immunity, an immunological response that may be an attempt to eliminate the germ perpetuating the inflammation (Jappe et al., 2004); a comparable investigation with bone specimens has not been conducted so far. In conclusion, the autoimmune inflammatory situation especially the one concerning the bone, bone marrow, and the skin cannot be classified into a predominately B-cell, plasma cell or T-cell mediated disease.

4. Clinical features

The clinical features of SAPHO can approximately be summarized by its descriptive acronym: synovitis, acne, pustulosis, hyperostosis, and osteitis.

4.1 Skin manifestations

The typical skin lesions seen in patients with SAPHO syndrome include PPP and acne (Kahn et al., 1994). Acne often manifests itself in its severe form with acne conglobata, acne fulminans or hidradenitis suppurativa. In addition, pyoderma gangrenosum, particularly in patients with concomitant Crohn's disease, Sweet syndrome and other neutrophilic disorders are observed (Yamasaki et al., 2003). The association of SAPHO syndrome with different manifestations of psoriasis is typical, predominately the pustular psoriasis that shows the same histological pattern as the PPP (Hayem et al., 1999). Approximately two-thirds of the patients with osteoarthritic lesions developed skin manifestations which could be defined as SAPHO syndrome. However, in some cases, the osteoarticular manifestations precede the skin features by years, making the clinical picture more suggestive of different rheumatologic disorders than of the SAPHO syndrome. In most cases, the time interval between the onset of skin and osteoarticular manifestations is less than two years, however, intervals of more than 20 years have been recorded as well (Sugimoto et al., 1998; Davies et al., 1999).

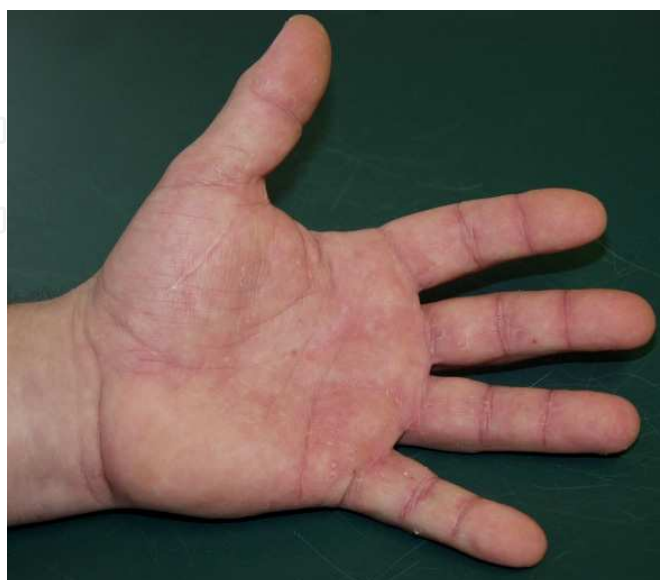

Fig. 1. 53 year old female SAPHO patient: hand with pustulosis palmoplantaris

4.2 Osteoarticular manifestations

The osteoarticular manifestations in patients with SAPHO syndrome implicate synovitis, hyperostosis and osteitis. Synovitis manifests in oligo- or polyarthritis; a monoarthritis seems to be a rare clinical rheumatologic symptom. In terms of peripheral arthritis concerning the knees, hips and ankles synovitis is a frequent manifestation. Moreover, the axial arthritis is more common, reported in up to 91% of cases. In the same patients the clinically appearing arthritis of the mandibular joint is seen as well as a unilateral sacroileitis (Earwaker et al., 2003). Colina et al. (2009) presented data of peripheral arthritis in patients preferentially younger than 25 years.

However, the characteristic features of SAPHO syndrome are the aseptic osteitis and hyperostosis. The proof of the *P. acnes* in bone biopsies did not change the character of an inflammation missing typically histological signs of the bacterial septic osteomyelitis. Osteitis refers to inflammation of bone, which may involve the cortex and the medullary cavity. Clinically, the patient complains bone pain and tenderness. The anterior chest wall is a classic location of involvement in adult patients, in particular, the clavicles, sternum, and sterno-costo-clavicular (SCC) joints. The pattern of osteoarticular involvement seems to be age dependent and more frequently occurring in young and middle-aged adults (Hayem et al., 1999). The hyperostosis and osteitis often cause a tumor with hyperthermia of the skin in this region (Kahn et al., 1991). Although the SCC manifestation is typical, it is not exclusive

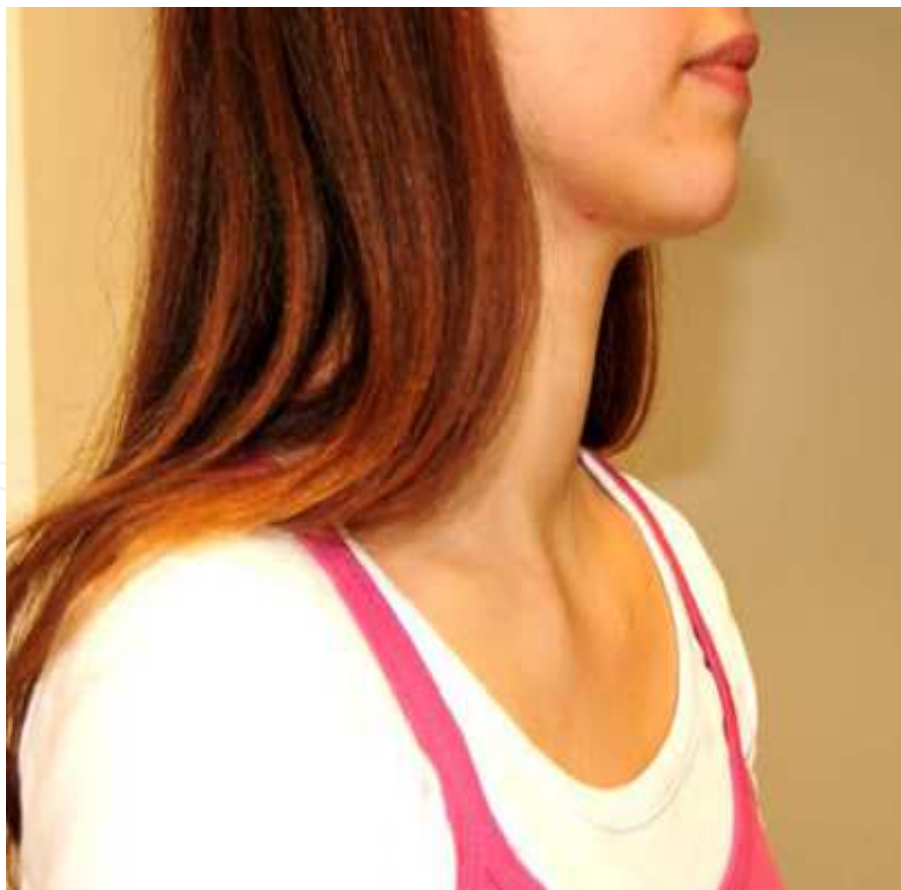

Fig. 2. 23 year old female SAPHO patient: bilateral sternocostoclavicular osteitis and hyperostosis

nor pathognomonic (Kahn, 2002). The singular or multiple involvement of the spine, pelvic girdle, sacroiliac joint, peripheral joint, long bones, and the mandibles is frequent, but not common (Mueller-Richter et al, 2009; Gikas et al., 2009). The clinical presentation of synovitis and osteitis in axial manifestation can not clearly distinguish between the two different entities. The CRMO, as manifestation of the SAPHO syndrome more common in children, appears often in the long bones, followed by clavicle and the spine. In those cases, the patients usually show localized swelling and pain accompanied by commonly generalized inflammation signs like fever and grippal symptoms.

5. Radiological findings

The predominant radiologic features of SAPHO syndrome include osteitis and hyperostosis with cortical thickening, periostitis, and cortical erosions in the concerned area. A variety of imaging tests are basically available for diagnosis and follow up SAPHO patients.

Plain radiographs reveal nonspecific features suggestive of osteomyelitis in the regions of osteitis and hyperostosis. Imaging of osteitis and hyperostosis - typically located in the clavicle bone - reveals a characteristic poorly defined, moth-eaten, destructive lesion typically involving the medial and middle third of the bone, with expansion, sclerosis, and a solid or multi-laminated periosteal reaction. Flat bones, such as the ileum and mandible, also can be involved, displaying predominantly diffuse sclerosis. Peripheral arthritis is seen, but radiographic joint destruction as it occurs in RA is rare. However, early radiographic changes including juxtaarticular osteoporosis may be seen; as well as later changes such as joint space narrowing (Rohekar et al., 2006; Earwaker et al., 2003). With regard to osteitis and hyperostosis, the manifestation in the typical region of the SCC joint is commonly not clearly detectable by conventional radiographic imaging.

Bone scintigraphy by technetium-99m phosphate is highly sensitive to detect the anterior chest wall lesions, and the characteristic “bull’s head” pattern of increased inflammatory activity. Furthermore, this tool of imaging is also suitable to detect occult and asymptomatic osteitis lesions in the skeletal system; the procedure is basically recommended to exclude multiple appearances of osteitis manifestations in the bones. Performing this investigation a highly detectable activity is commonly seen in the early phase of application of the technetium-99 isotope. However, the scintigraphy can not achieve a reliable differentiation between bacterial osteomyelitis, malignant tumor or osteitis/CRMO.

X-ray computed tomography (CT) nicely demonstrates the osteoarticular lesions. The value of CT is that it demonstrates the location of the lesion and pattern of destruction in an area that may be poorly demonstrated radiographically as well as the nature of the periosteal response (Gikas et al., 2009). On CT, the mentioned pathological changes in osteitis lesions and hyperostosis appear as sharply defined hyperdense osteosclerosis of the periarticular bone, in some cases with lytic areas. CT can be clearly recommended as the primary diagnostic tool in cases of complications caused by osteitis and hyperostosis in the anterior chest wall, such as compression of the large vessels in the thoracic aperture; furthermore, the CT is basically employed for the imaging-guided bone biopsy of osteitis lesions if required.

The magnetic resonance imaging (MRI) is in wide use to identify the osteitis in its exact enlargement and inflammatory activity. MRI using fat-suppressed, T2-weighted, or short-t inversion recovery sequences reveals bone marrow edema as well as arthritis changes, and helps differentiate active from chronic less active lesions. MRI demonstrates bone expansion, marrow heterogeneity with bone, and adjacent soft tissue edema resulting in reduced T1-weighted signal intensity and increased T2-weighted modulus. Furthermore, the MRI can be employed to identify the bone regions with the most pronounced inflammatory changes in order to carry out further diagnostic such as CT-guided bone biopsy (Kirchhoff et al., 2003). In addition, the MRI is supposed to be the most reliable diagnostic tool in the follow-up of osteitis activity under anti-inflammatory treatment.

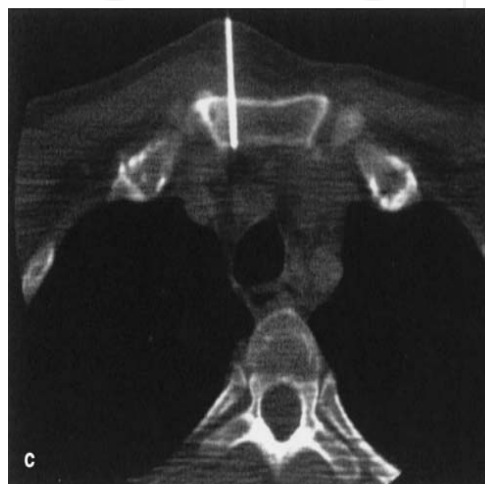


Fig. 3. 58 year old male SAPHO patient with osteitis of the right sternoclavicular region and CT-guided biopsy of the sclerotic region (Kirchhoff et al, 2003)

6. Laboratory diagnostic

Patients with SAPHO syndrome often show symptoms of humoral inflammatory activity. C reactive protein (CRP) and erythrocyte sedimentation rate (ESR) are usually normal or slightly elevated during exacerbations. Abnormal levels are observed in only one third of the cases (Colina et al., 2009). Apart from reports of positive anti nuclear antibody (ANA) in 30% of patients with CRMO (Janson et al., 2007) and anti-thyroid antibodies in 28% of patients with SAPHO, the data on autoimmunity in SAPHO is rather scant. A recent study investigated the prevalence of the autoantibody patterns classically associated with RA and PsA. Though their prevalence was increased compared to the general population, a specific antibody-profile could not be found (Grosjean et al., 2010). Extended investigations of numerous antibodies found that RA markers (rheumatoid factor (RF) and anti-cyclic citrulline peptides antibodies (anti-CCP2) were absent in SAPHO (Hurtado-Nedelec et al., 2008). A pathway that might play a role in the bone damage observed in SAPHO syndrome is TNF α and RANKL-mediated osteoclast differentiation (Ritchlin et al., 2003). Jansson et al. recently reported elevated TNF α levels in two thirds of patients with CRMO. Furthermore, a different pattern of immunoglobulins with significantly higher levels of immunoglobulin A was observed compared to healthy controls. In conclusion the observed laboratory findings are somewhat contradictory. Nevertheless the co-occurrence of other immune-mediated conditions like psoriasis vulgaris, inflammatory bowel disease (IBD) and pyoderma

gangrenosum suggest a self-amplifying inflammatory response, possibly involving autoimmune mechanisms (Assmann et al., 2011). The possible role of infectious agents in SAPHO was already considered in the 1980’s when pathogens were isolated from different sites, namely anterior chest wall, spine, synovial fluid, bone tissue and skin pustules. A range of bacteria have been identified, including *Staphylococcus aureus*, *Haemophilus parainfluenzae*, *Actinomyces*, and even *Treponema pallidum*. However, it may be supposed that *P. acnes* play the major role, because they have been found more often than other microorganisms (Assmann et al., 2009). However, an extensive bacterial diagnostic procedure for detecting microbes like the *P. acnes* out of blood specimen, skin lesions, or bone-biopsy could not be recommended so far.

7. SAPHO syndrome and psoriasis

Regarding the definition of SAPHO syndrome as an arthro-osteo-cutaneus disease it is clear that SAPHO is an entity that fits into a variety of already established disease categories. There are aspects of SAPHO that are common in AS, in particular, the most frequently involvement of the axial skeleton. Furthermore, the radiologic findings often show sacroileitis which cannot be distinguished from typical AS in 13-52% cases (Earwaker eta al., 2003). In addition, the skin osteoarticular manifestations could often lead to the diagnosis of PsA with axial skeleton manifestation and pustular psoriasis, a special subgroup of psoriatic disease. Furthermore, the PPP is histologically identical to that of the pustular psoriasis. However, the radiographic signs of osteitis with hyperostosis are not often seen in PsA (Rohekar et al., 2006). On the other hand, Kahn et al. (1994) have already demonstrated in a

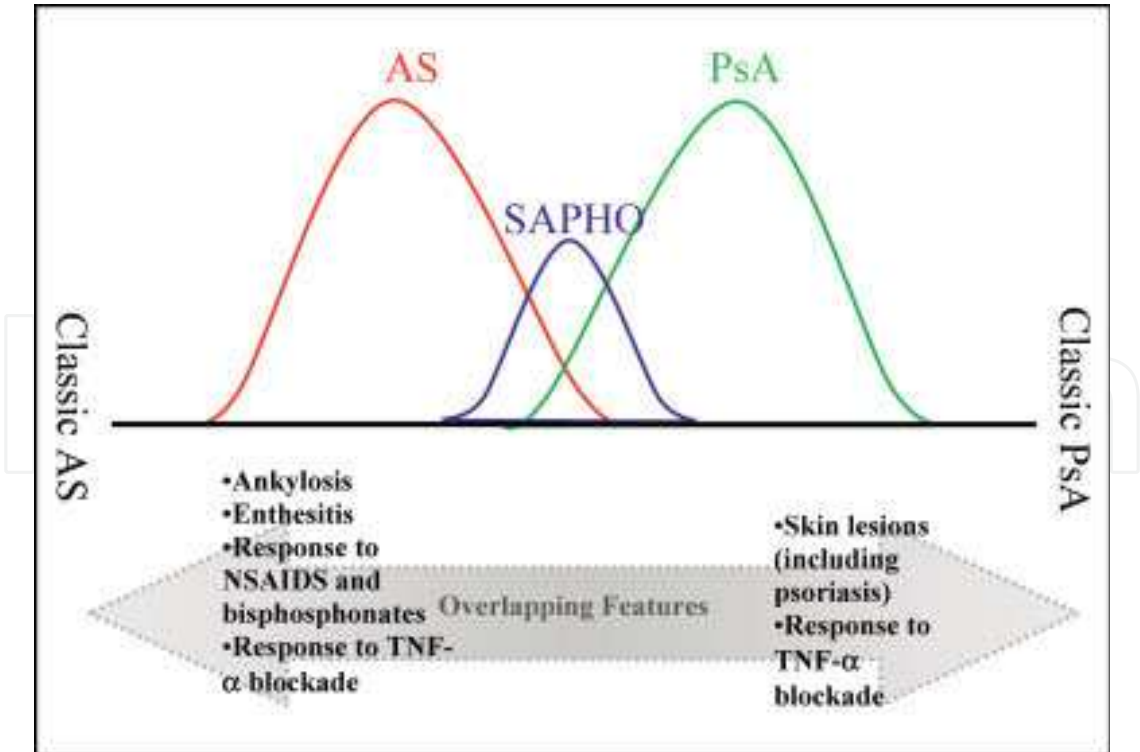


Fig. 4. Model of overlapping features in a spectrum of disease. (AS: ankylosing spondylitis; PsA: psoriatic arthritis; NSAIDs: nonsteroidal anti-inflammatory drugs; TNFα: tumor necrosis factor α) (Rohekar et al., 2006)

multicenter study that the amount of psoriasis among the SAPHO patients is three times as much, compared with the general population. In some cases, psoriasis vulgaris has developed months or years after initial skin lesions with PPP together with osteoarthritic manifestations. With regard to clinical presentations of SAPHO patients figure four demonstrates a model for overlapping features in a spectrum of disease between AS and PsA.

8. Strategy for management

The knowledge of the clinical and the radiographic characteristics of SAPHO syndrome allows a relatively prompt and correct diagnosis; however, the observation of the long-term follow-up of SAPHO patients demonstrates that patients have often been diagnosed first for other rheumatologic disorders such as RA, PsA, or AS – commonly with the additional remark “seronegative” and/or “atypical”. The key to a correct diagnosis of SAPHO is the diagnosis of osteitis and, in addition, in most of the cases, the observation of an interrelation or connection with cutaneous and osteoarticular manifestations. The diagnosis can be particularly difficult in patients with an isolated symptomatic bone lesion, when multiple differential diagnoses such as bacterial osteomyelitis, Langerhans cell histiocytosis, benign or malignant bone tumors (e.g. Ewing’s sarcoma), Paget’s disease, infectious arthritis or AS have to be taken into consideration. Further diagnostic problems may arise due to other incomplete manifestations of SAPHO. In addition to a careful physical examination, a total body skeleton scintigraphy is therefore strongly advised in patients with pain in the anterior chest wall and suspicion of SAPHO. Completing the reasonable diagnostic procedure includes laboratory tests with ESR and CRP, RA markers (rheumatoid factor (RF) and anti-CCP2 antibodies); with regard to diagnostic imaging X-radiograph of the bone region concerned (clavicle, vertebral column, iliosacral joints, skeleton regions with peripheral arthritis) should be performed. In case of osteitis suspicious lesions further imaging with MRI in specific technical setting modalities is recommended. (see above).

9. Treatment options

Although the classification of SAPHO syndrome exists as a distinct disease entity, the overlap and similarities with other rheumatic diseases form the basis for trials investigating anti-rheumatic drugs that are the accepted standard for the treatment of PsA and other spondyloarthritides. Studies have been published with small numbers of patients treated with NSAIDs (Girschick et al., 1998), steroids (Benhamou et al., 1988; Schultz et al., 1999), and immunosuppressive agents that showed only partial efficacy. In detail, the SAPHO specific lesions like osteitis and/or CRMO often show therapeutic resistance against the established anti-rheumatic drugs including the disease modifying anti rheumatic drugs (DMARDs), whereas an accompanying arthritis and/or spondylarthritis seems to respond positively to the therapy. Investigations of methotrexate and azathioprine yielded no convincing results (Handrik et al., 1998; Kalke et al., 2001). However, several reports presenting promising results, obtained with bisphosphonates (Marshall et al., 2002; Kopterides et al., 2004; Just et al., 2008) or biologicals like TNF α -blockers (Olivieri et al., 2002; Wagner et al., 2002, Magrey 2009), have recently been published. In this context, it has been found that infliximab could show good therapeutic efficacy. Some cases, however, were reported with an amelioration of skin manifestations together with improvement of osteoarticular symptoms. With regard to a possible link to an infectious etiology of SAPHO

syndrome, several studies with small numbers of patients treated with antibiotics reported contradictory results (Schilling et al., 2000; Wagner et al., 1997). However, recently published data based on a prospective interventional study in 27 SAPHO patients show an effect of a four-month treatment with the antibiotic azithromycin (also with doxycycline and clindamycin in one patient each) with respect to MRI findings and to the activity of skin disease and osteitis (Figure 5). Three months after the end of antibiotic treatment, however, these effects had disappeared (Assmann et al., 2009). In rare cases SAPHO syndrome develops serious complications mostly based on vascular compression followed by blood stasis and venous thrombosis. In these cases a surgical intervention is often required. There are no data for the efficacy of radiation therapy available.

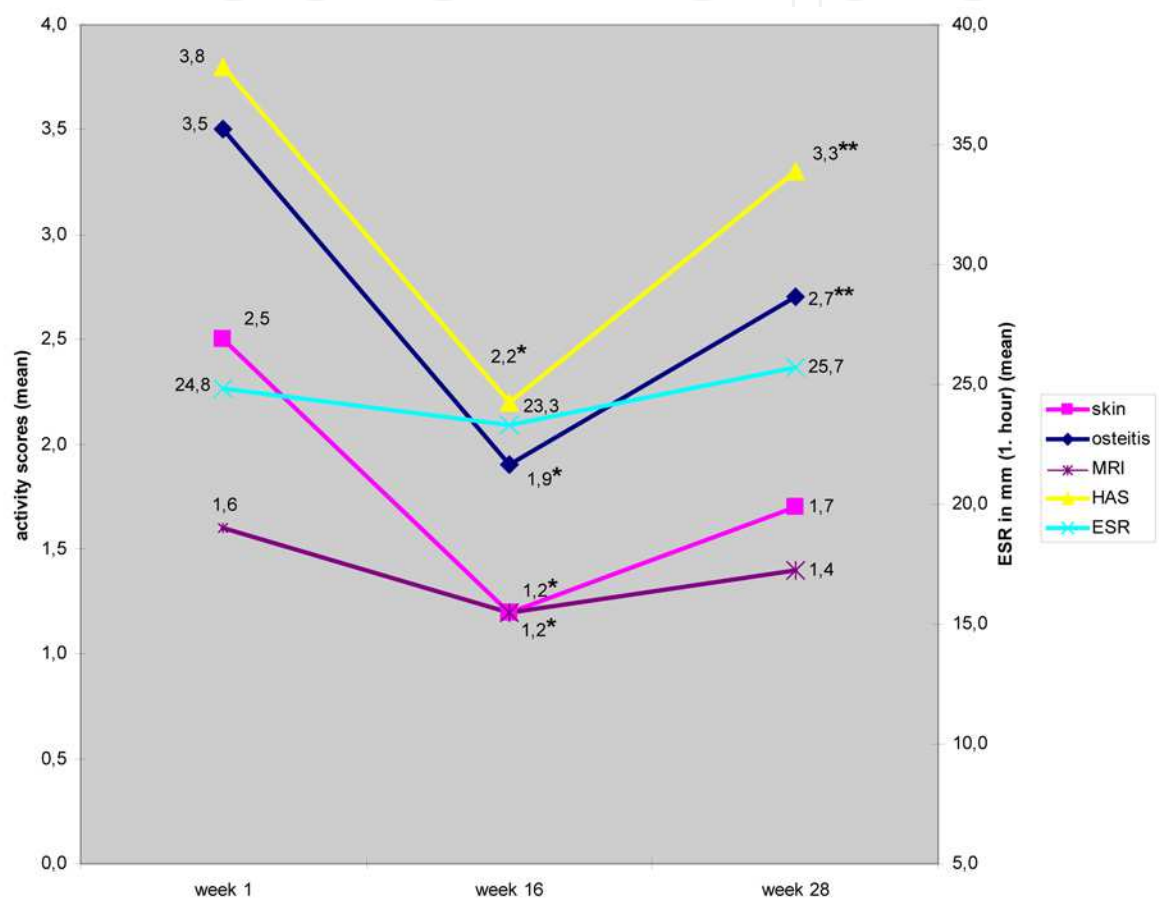


Fig. 5. Activity scores and erythrocyte sedimentation rate (ESR) values (mean) of SAPHO patients treated with antibiotics. * differences of values between week 1 and week 16: $p<0.05$; ** differences of values between week 16 and week 28: $p<0.05$; HAS=health assessment score; MRI=magnet resonance imaging) (Assmann et al., 2009)

10. Conclusions

The SAPHO syndrome represents a constellation of overlapping osteoarticular and cutaneous manifestations. Its clinical presentation is heterogeneous and often incomplete, resulting in diagnostic difficulties. Although controversy still exists regarding its relation to the spondylarthropathies, SAPHO is now recognized as a distinct clinical entity. However, SAPHO continues to represent a nosologic enigma. Further examinations and a better

understanding of the underlying pathogenetic mechanisms are essential for the development of appropriate therapies. Especially with regard to osteitis as the characteristic manifestation of the SAPHO syndrome, data concerning the existing treatment options are conflicting. The use of antibiotics has shown contradictory results in several reports although some patients are obviously responsive to this therapy.

11. References


- Amital H, Govoni M, Maya R, Meroni PL, Ori B, Shoenfeld Y, Tincani A, Trotta F, Sarzi-Puttini P, Atzeni F. Role of infectious agents in systemic rheumatic diseases. *Clin Exp Rheumatol*. 2008 Jan-Feb;26(1 Suppl 48):S27-32.
- Assmann G, Wagner AD, Monika M et al. Single-nucleotide polymorphisms p53 G72C and Mdm2 T309G in patients with psoriasis, psoriatic arthritis and SAPHO syndrome. *Rheumatol Int* 2010 Aug;30(10):1273-6
- Assmann G, Kueck O, Kirchhoff T et al. Efficacy of antibiotic therapy for SAPHO syndrome is lost after its discontinuation: Interventional study. *Arthritis Res Ther*. 2009;11:R140
- Assmann G, Simon P. The SAPHO syndrome - Are microbes involved. *Best Practice and Research Clinical Rheumatology* 2011, doi:10.1016/j.berh.2011.01.0017
- Benhamou CL, Chamot AM, Kahn MF: Synovitis - acne - pustulosis hyperostosis - osteomyelitis syndrome (SAPHO). A new syndrome among the spondyloarthropathies? *Clin Exp Rheumatol* 1988, 6:109-112.
- Björkstén B, Gustavson KH, Eriksson B, Lindholm A, Nordström S. Chronic recurrent multifocal osteomyelitis and pustulosis palmoplantaris. *J Pediatr*. 1978 Aug;93(2):227-31.
- Chamot AM, Benhamou CL, Kahn MF, Beranek L, Kaplan G, Prost A. Acne-pustulosis-hyperostosis-osteitis
- Colina M, Govoni M, Orzincolo C, Trotta F. Clinical and radiologic evolution of synovitis, acne, pustulosis, hyperostosis, and osteitis syndrome: a single center study of a cohort of 71 subjects. *Arthritis Rheum*. 2009 Jun 15;61(6):813-21.
- Davies AM, Marins AJ, Evans N et al. SAPHO syndrome: 20 year follow up. *Skeletal Radiol* 1999;28:159-162
- Earwaker JW, Cotten A. SAPHO: syndrome or concept? Imaging findings *Skeletal Radiol*. 2003 Jun;32(6):311-27. Epub 2003 Apr 29
- Eklund E, Johnsson U, Lidgren L, Pettersson H, Sturfelt G, Svensson B, Theander J, Willén H. Palmoplantar pustulosis and sternocostoclavicular arthro-osteitis. *Ann Rheum Dis*. 1988 Oct;47(10):809-15
- Eyrich GK, Langenegger T, Bruder E, Sailer HF, Michel BA: Diffuse chronic sclerosing osteomyelitis and the synovitis, acne, pustulosis, hyperostosis, osteitis (SAPHO) syndrome in two sisters. *Int J Oral Maxillofac Surg*. 2000, 29:49-53.
- Ferguson PJ, Bing X, Vasef MA, Ochoa LA, Mahgoub A, Waldschmidt TJ, Tygrett LT, Schlueter AJ, El-Shanti H. A missense mutation in *pstpip2* is associated with the murine autoinflammatory disorder chronic multifocal osteomyelitis. *Bone*. 2006 Jan;38(1):41-7. Epub 2005 Aug 24.

- Ferguson PJ, Chen S, Tayeh MK et al. Homozygous mutations in LPIN2 are responsible for the syndrome of CRMO and congenital dyserythropoietic anaemia (Majeed Syndrome). *J Med Genet* 2005;42:551-7
- Giedion A, Holthusen W, Masel LF, Vischer D. Subacute and chronic "symmetrical" osteomyelitis. *Ann Radiol (Paris)*. 1972 Mar-Apr;15(3):329-42
- Gikas PD, Islam L, Aston W, Tirabosco R, Saifuddin A, Briggs TW, Cannon SR, O'Donnell P, Jacobs B, Flanagan AM. Nonbacterial osteitis: a clinical, histopathological, and imaging study with a proposal for protocol-based management of patients with this diagnosis. *J Orthop Sci*. 2009 Sep;14(5):505-16. Epub 2009 Oct 3.
- Girschick HJ, Krauspe R, Tschammler A, Huppertz HI. Chronic recurrent osteomyelitis with clavicular involvement in children: diagnostic value of different imaging techniques and therapy with non-steroidal anti-inflammatory drugs. *Eur J Pediatr* 1998, 157:28-33.
- Golla A, Jansson A, Ramser J, Hellebrand H, Zahn R, Meitinger T, Belohradsky BH, Meindl A. Chronic recurrent multifocal osteomyelitis (CRMO): evidence for a susceptibility gene located on chromosome 18q21.3-18q22. *Eur J Hum Genet*. 2002 Mar;10(3):217-21
- Grosjean C, Hurtado-Nedelec M, Nicaise-Roland P et al. Prevalence of autoantibodies in SAPHO syndrome: a single-center study of 90 patients. *J Rheumatol* March 2010;37:639-643
- Gudkov AV, Komarova EA. Dangerous habits of a security guard: the two faces of p53 as a drug target. *Hum Mol Genet* 2007;16:67-72
- Handrick W, Hörmann D, Voppmann A, Schille R, Reichardt P, Tröbs RB, Möritz RP, Borte M. Chronic recurrent multifocal osteomyelitis - report of eight patients. *Pediatr Surg Int* 1998, 14:195-198.
- Hayem G. Valuable lesson from SAPHO syndrome. *Joint Bone Spine* 2007;74:123-6
- Hayem G, Bouchaud-Chabot A, Benali K, Roux S, Palazzo E, Silbermann-Hoffman O, Kahn MF, Meyer O. SAPHO syndrome: a long-term follow-up study of 120 cases. *Semin Arthritis Rheum*. 1999 Dec;29(3):159-71
- Hurtado-Nedelec M, Chollet-Martin S, Nicaise-Roland P, Grootenboer-Mignot S, Ruimy R, Meyer O, Hayem G. Characterization of the immune response in the synovitis, acne, pustulosis, hyperostosis, osteitis (SAPHO) syndrome. *Rheumatology (Oxford)*. 2008 Aug;47(8):1160-7. Epub 2008 Jun 17.
- Jansson A, Renner ED, Ramser J et al. Classification of nonbacterial osteitis: retrospective study of clinical, immunological and genetic aspects in 89 patients. *Rheumatology (Oxford)* 2007;46:154-60
- Jappe U, Boit R, Farrar MD, Ingham E, Sandoe J, Holland KT. Evidence for diversity within *Propionibacterium acnes*: a comparison of the T-cell stimulatory activity of isolates from inflammatory acne, endocarditis and the laboratory. *J Eur Acad Dermatol Venereol*. 2004 Jul;18(4):450-4.
- Jurik AG, Helmig O, Ternowitz T, Møller BN. Chronic recurrent multifocal osteomyelitis: a follow-up study. *J Pediatr Orthop*. 1988 Jan-Feb;8(1):49-58.
- Just A, Adams S, Brinkmeier T, Barsegian V, Lorenzen J, Schilling F, Frosch P. Successful treatment of primary chronic osteomyelitis in SAPHO syndrome with bisphosphonates. *J Dtsch Dermatol Ges* 2008, 6:657-660.
- Kahn MF. Why the "SAPHO" syndrome? *J Rheumatol*. 1995 Nov;22(11):2017-9.

- Kahn MF, Hayem F, Hayem G, Grossin M. Is diffuse sclerosing osteomyelitis of the mandible part of the synovitis, acne, pustulosis, hyperostosis, osteitis (SAPHO) syndrome? Analysis of seven cases. *Oral Surg Oral Med Oral Pathol.* 1994 Nov;78(5):594-8.
- Kahn MF, Bouvier M, Palazzo E, Tebib JG, Colson F. Sternoclavicular pustulotic osteitis (SAPHO). 20-year interval between skin and bone lesions. *J Rheumatol.* 1991 Jul;18(7):1104-8.
- Kahn MF, Khan MA. The SAPHO syndrome. *Baillieres Clin Rheumatol.* 1994 May;8(2):333-62.
- Kalke S, Perera SD, Patel ND, Gordon TE, Dasgupta B: The sternoclavicular syndrome: experience from a district general hospital and results of a national postal survey. *Rheumatology (Oxford)* 2001, 40:170-177.
- Khan MA. Update on spondylarthropathies. *Ann Int Med* 2002;135:896-907
- Kirchhoff T, Merkesdal S, Rosenthal H, Prokop M, Chavan A, Wagner A, Mai U, Hammer M, Zeidler H, Galanski M. Diagnostic management of patients with SAPHO syndrome: use of MR imaging to guide bone biopsy at CT for microbiological and histological work-up. *Eur Radiol.* 2003 Oct;13(10):2304-8. Epub 2003 Mar 13.
- Kopterides P, Pikazis D, Koufos C: Successful treatment of SAPHO syndrome with zoledronic acid. *Arthritis Rheum* 2004, 50:2970-2973.
- Kotilainen P, Merilahti-Palo R, Lehtonen OP, Manner I, Helander I, Möttönen T, Rintala E. *Propionibacterium acnes* isolated from sternal osteitis in a patient with SAPHO syndrome. *J Rheumatol.* 1996 Jul;23(7):1302-4.
- Majeed HA, Kalaawi M, Mohanty D et al. Congenital dyserythropoietic anemia and chronic recurrent multifocal osteomyelitis in three related children and the association with Sweet syndrome in two siblings. *J Pediatr* 1989;115:730-4
- Magrey M, Khan MA. New insights into synovitis, acne, pustulosis, hyperostosis, and osteitis (SAPHO) syndrome. *Curr Rheumatol Rep.* 2009 Oct;11(5):329-33
- Marshall H, Bromilow J, Thomas AL, Arden NK: Pamidronate: a novel treatment for the SAPHO syndrome? *Rheumatology (Oxford)* 2002, 41:231-233.
- Muller-Richter UDA, Roldan JC, Mortl M et al. SAPHO syndrome with ankylosis of the temporomandibular joint. *Int J Oral Maxill of Surg* 2009;38:1335-1341
- Olivieri I, Padula A, Ciancio G, Salvarani C, Niccoli L, Cantini F: Successful treatment of SAPHO syndrome with infliximab: report of two cases. *Ann Rheum Dis* 2002, 61:375-376.
- Ritchlin CT, Haas-Smith SA, Li P et al. Mechanisms of TNF-alpha and RANKL mediated osteoclastogenesis and bone resorption in psoriatic arthritis. *J Clin Invest* 2003;111:821-31
- Rohekar G, Inman RD. Conundrums in nosology: synovitis, acne, pustulosis, hyperostosis, and osteitis syndrome and spondylarthritis. *Arthritis Rheum.* 2006 Aug 15;55(4):665-9.
- Rozin AP, Nahir AM: Is SAPHO syndrome a target for antibiotic therapy? *Clin Rheumatol.* 2007, 26: 817-820.
- Schilling F, Wagner AD: Azithromycin: an anti-inflammatory effect in chronic recurrent multifocal osteomyelitis? A preliminary report. *Z Rheumatol* 2000, 59:352-353.
- Schultz C, Holterhus PM, Seidel A, Jonas S, Barthel M, Kruse K, Bucskey P: Chronic recurrent multifocal osteomyelitis in children. *Pediatr Infect Dis J* 1999, 18:1008-1013.

- Sugimoto H, Tamura K, Fujii T. The SAPHO syndrome: defining the radiological spectrum of disease comprising the syndrome. *Eur Radiol* 1998;8:800–806
- Van Doornum S, Barraclough D, McColl G, Wicks I. SAPHO: rare or just not recognized? *Semin Arthritis Rheum* 2000;30:70-7
- Wagner AD, Andresen J, Hülsemann J, Zeidler H: Long-term antibiotic therapy successful in patients with SAPHO-syndrome [abstract]. *Arthritis Rheum* 1997, 40:S62.
- Wagner AD, Andresen J, Jendro MC, Hülsemann JL, Zeidler H. Sustained response to tumor necrosis factor alpha-blocking agents in two patients with SAPHO syndrome. *Arthritis Rheum*. 2002 Jul;46(7):1965-8. No abstract available.
- Windom RE, Sanford JP, Ziff M. Acne conglobata and arthritis. *Arthritis Rheum*. 1961 Dec;4:632-5. Results of a national survey. 85 cases. *Rev Rhum Mal Osteoartic*. 1987 Mar;54(3):187-96.
- Wise CA, Gillum JD, Seidman CE, Lindor NM, Veile R, Bashardes S, Lovett M. Mutations in CD2BP1 disrupt binding to PTP PEST and are responsible for PAPA syndrome, an autoinflammatory disorder. *Hum Mol Genet*. 2002 Apr 15;11(8):961-9.
- Yamasaki O, Iwatsuki K, Kaneko F. A case of SAPHO syndrome with pyoderma gangrenosum and inflammatory bowel disease masquerading as Behçet's disease. *Adv Exp Med Biol*. 2003;528:339-41
- Yeon HB, Lindor NM, Seidman JG, Seidman CE Pyogenic arthritis, pyoderma gangrenosum, and acne syndrome maps to chromosome 15q *Am J Hum Genet*. 2000 Apr;66(4):1443-8. Epub 2000 Mar 21.

IntechOpen



Psoriasis - A Systemic Disease

Edited by Dr. Jose O' Daly

ISBN 978-953-51-0281-6

Hard cover, 216 pages

Publisher InTech

Published online 16, March, 2012

Published in print edition March, 2012

The purpose of this book is to present a comprehensive analysis of Psoriasis, a disease that affects approximately 2-3% of humanity in all countries. Psoriasis existence is surveyed since the clay tablets of Assyrians and Babylonians 3.000-5.000 years ago, thru the middle ages, the renaissance, XIX and XX centuries.

How to reference

In order to correctly reference this scholarly work, feel free to copy and paste the following:

Gunter Assmann (2012). SAPHO Syndrome, Psoriasis - A Systemic Disease, Dr. Jose O' Daly (Ed.), ISBN: 978-953-51-0281-6, InTech, Available from: <http://www.intechopen.com/books/psoriasis-a-systemic-disease/sapho-syndrome>

INTECH
open science | open minds

InTech Europe

University Campus STeP Ri
Slavka Krautzeka 83/A
51000 Rijeka, Croatia
Phone: +385 (51) 770 447
Fax: +385 (51) 686 166
www.intechopen.com

InTech China

Unit 405, Office Block, Hotel Equatorial Shanghai
No.65, Yan An Road (West), Shanghai, 200040, China
中国上海市延安西路65号上海国际贵都大饭店办公楼405单元
Phone: +86-21-62489820
Fax: +86-21-62489821

© 2012 The Author(s). Licensee IntechOpen. This is an open access article distributed under the terms of the [Creative Commons Attribution 3.0 License](https://creativecommons.org/licenses/by/3.0/), which permits unrestricted use, distribution, and reproduction in any medium, provided the original work is properly cited.

IntechOpen

IntechOpen