

# We are IntechOpen, the world's leading publisher of Open Access books Built by scientists, for scientists

6,900

Open access books available

186,000

International authors and editors

200M

Downloads

Our authors are among the

154

Countries delivered to

TOP 1%

most cited scientists

12.2%

Contributors from top 500 universities



WEB OF SCIENCE™

Selection of our books indexed in the Book Citation Index  
in Web of Science™ Core Collection (BKCI)

Interested in publishing with us?  
Contact [book.department@intechopen.com](mailto:book.department@intechopen.com)

Numbers displayed above are based on latest data collected.  
For more information visit [www.intechopen.com](http://www.intechopen.com)



# The Application of Breast MRI on Asian Women (Dense Breast Pattern)

Ting Kai Leung

*Taipei Medical University & Hospital, Taipei,  
Taiwan*

## 1. Introduction

### 1.1 Increase incidence of breast cancer in Taiwan and Asia

Although the incidence of breast cancer is lower in Asian countries, the cause-specific mortality in most Asian countries is much higher as compared to western countries (Agarwal et al., 2007; Shibuya et al., 2002). Although the overall picture of breast cancer is variable among different Asian countries and in different ethnic groups within individual countries, breast cancer has emerged as the largest cancer problem in Asian women. Breast cancer is also the largest cause of cancer-related deaths. It remains the second commonest malignancy in women in the rural areas of developing Asian countries (Agarwal et al., 2007). Breast cancer is gradually become one of the major public health problem and the most important issue to concern in order to decrease cancer mortality.

Base on the data from the Bureau of Health Promotion, Department of Health, Executive Yuan, Taiwan, indicate that the incidence of breast cancer in Taiwan increased from 27.9 to 49.2 per 100,000 women in the decade from 1995 to 2005, which is an annual increase of approximately 7%. As the decrease incidence of cervical cancer in the meanwhile, breast cancer is already the highest new number of malignancy diagnosis in Taiwan. Moreover, according to the data released from the World Health Organization, an incidence of Taiwanese breast cancer is reported as 52.8 per 100,000 women in 2008, which is the second place in Asia, only slightly lower than that seen in Singapore.

## 2. Characteristics and difficulty of early detection of breast tumor in Asian women

There are higher proportions of breast cancer patients in developing Asian countries are younger than patients in developed Asian and western countries (Agarwal et al., 2007; Amr et al., 1995). Given the huge population in the developing Asian nations, and the fact that up to 25% of all breast cancer patients in Asian countries are young, and also, young age by itself is a known indicator of poor prognosis in breast cancer patients (Agarwal et al., 2007; Amr et al., 1995). The first nation-wide mammographic screening program in Asia was started in Singapore during 2002 (Chuwa et al., 2009). By 2009, there is still no significant survival benefit could be demonstrated in the country, in the meanwhile, rapid increase of breast cancer incidence was reported. Singapore government choose for longer period of

follow-up, expect for the benefit of mortality reduction in the population resulted from their mass mammography screening program (Chuwa et al., 2009). As we know, many therapeutic options for early detected breast cancer with small tumor size, the success rate of therapy for early stage cancer is higher than advanced stage disease.

In Taiwan, a national project of 2-year interval screening mammograms for 45- to 70-year-old women has detected significantly more early breast cancers (Chen et al., 2008). However, the major source of breast cancer detection is not arise from this screening program. The overall average detection size of breast cancer tumors in Taiwan is over 2 cm, which is larger than that detectable with the diagnostic capabilities in Europe and North America (Ng et al., 1998; Shen et al., 2005). The median age at diagnosis of breast cancer is 45–49 years in Taiwan, and this age group is more likely to present with a dense breast parenchyma pattern (DBPP). This median age is significantly lower than that of Caucasian women in Western countries, where breast cancer peaks between the ages of 70 and 74 years, and this older age group is more likely to present with a non-dense parenchyma pattern (NDBPP) (Huang et al., 2001; Shen et al., 2005). Breast cancer in this age group is reportedly more aggressive (Kwong et al., 2008). This pathological pattern is also commonly seen in our clinical practice in Taiwan (Leung et al., 2010b). Previous study have demonstrated that the prevalence of NDBPP (ACR types 1 and 2; ACR: American College of Radiology classification of breast parenchymal density in digital mammography) could be as high as 78%, compared with 22% for DBPP (ACR types 3 and 4), which is representative of most Western countries (Table 1) (Van Gils et al., 1999). The ratio of NDBPP to DBPP is reversed compared with their previous results. Although the case number is small, we believe that the results are representative of developed Asian countries such as Taiwan, Hong Kong, South Korea, Singapore, and Japan.

Breast pattern according to mammography	NDBPP	DBPP
Prevalence (%) in Taiwan (Leung et al in Taipei Medical university Hospital)	20.8	79.2
Prevalence (%) in Western countries	78	22

Table 1. Analysis of the prevalence of breast pattern in Taiwan and Western countries (Leung et al., 2010b; Van Gils et al., 1999).

Breast density is a major factor influencing the incidence of breast malignancy, and has been discussed extensively in the past two decades. In a normal woman, mammographic densities correspond to different amounts of fat and connective and epithelial tissue. Fat appears radiographically dark on film-screen mammograms, and radiographically opaque areas represent epithelial and connective tissues (Gram et al., 1997). Most cases of high mammographic density are not abnormalities, but varied distributions in healthy breast tissue. It was also found that high mammographic density may be related to a fourfold increased risk of developing breast cancer. It was found that the diagnostic sensitivity of mammography in women with a fatty breast pattern is 98% (Boyd et al., 1998; Kolb et al., 2002). Women with high mammographic breast densities are at higher risk of breast cancer; the incidence of breast cancer in NDBPP was 26.4% versus 73.4% in DBPP. It was discussed

and investigated whether the women with DBPP should receive more frequent screening or screening with alternative techniques that increase the length of the preclinical detectable phase to reduce breast cancer mortality (Van Gils et al., 1999).

Data collected in Japan showed the successful result of a mass screening program using mammography on asymptomatic women over 50 years of age. The program had a 0.84 % cancer detection rate. The breast cancer cases screened from the program had not been detected by physical examination (Morimoto et al., 1994). The detection rates were higher in the sixth and seventh decades of life.

In a study of Japanese women, mammography missed 16 % of breast cancer occurrences (Uchida et al., 2008). Breast density was also confirmed as a significant determinant of breast cancer risk. They quantitatively measured the mammographic density, and found that a higher risk was associated with a larger breast size and with a higher proportion of glandular density, especially for extreme densities (Nagata et al., 2005). A study in Singapore showed an increased risk of breast cancer associated with a higher-density pattern with extensive nodular characteristics, and linear densities with a nodular size larger than normal lobules (Jakes et al., 2000).

Although breast cancer is the most common female cancer in South Korea, its early detection rate is low compared to developed Western countries (Ryu et al., 2008). The clinical characteristics of Korean breast cancer patients showed a pattern of a younger age (< 50 years old) and increasing early stage and asymptomatic cases. This finding reflects the need for more effective breast screening programs for young Korean women (Son et al., 2006).

Increased breast parenchyma density correlates with breast cancer risk and obscures the detection with the mammography of early stage, small-sized breast tumors. Asian women have smaller breasts and are affected by breast cancer at a younger age; both factors that are associated with DBPP (Leung et al., 2010b).

### **3. Limitation of conventional mammography in detecting early tumors in young Asian women with dense breast parenchyma pattern**

In Western countries, mammography has been proven to detect breast cancer at an early stage and, when followed up with appropriate diagnosis and treatment, to reduce the mortality rate caused by breast cancer (Saslow et al., 2007).

Asian women have higher breast densities than Caucasian women, in addition, mammography is not a perfect screening tool for Asian women with DBPP. Mammography has lower sensitivity for invasive ductal carcinoma of breasts in patients with DBPP (Kolb et al., 2002).

The percentage of dense tissue to breast volume of both Chinese and Japanese women appeared to be higher than that in Caucasian women (Maskarinec et al., 2001). Despite the considerably smaller proportion of non-dense areas, the overall proportion of dense breast tissue in the breasts of Chinese and Japanese women is 20 % higher than in Caucasian women in the same age group (Huang et al., 2001; Maskarinec et al., 2001). Irrespective of race, women with lower mammographic densities have a lower risk of breast cancer.

Whether the presence of many dense areas in the breasts corresponds to a higher cancer risk is unclear (Boyd et al., 2005; Kolb et al., 2002; Maskarinec et al., 2001; Tseng et al., 2006). In fact, mammographic density usually reflects the opacity of epithelial and stromal tissue in the breast within the lucent background of non-dense fatty tissue. Ductal carcinoma *in situ* and infiltrative ductal carcinomas originate in epithelial cells, and therefore, areas of fibroglandular tissue with a greater number of cells are at a higher risk during increased epithelial proliferation (McCormack & Santos et al., 2006). The masking hypothesis proposed by Egan and Mosteller (1977) may also explain why radiographically dense patterns are associated with an increased risk of breast cancer. They found that breast cancer was easy to detect using mammography in breasts with non-dense glandular parenchyma, though it was unreliable for detecting cancer in dense glandular parenchyma. Cases of missed cancer detection during a first mammographic examination due to the masking effect of dense glandular tissue of the breast may be detected in subsequent mammographic examinations. The apparent excess of cancers detected in this specific group, with initial masking of the tumor in dense breasts, can cause the group to appear to be at a higher risk than those with non-dense breast tissue (Leung et al., 2010). Conventional mammography is also lower sensitivity to detect enlarged axillary and have no information on internal mammary chain. Probably due to some additional reasons, such as the screening program may cause call-back anxiety, psychological trauma by false positive results and radiation exposure (Leung et al., 2002), Hong Kong and most regions of mainland China currently have no mass screening programs for any age group.

Although some limitations of mammographic screening on DBPP women in Asia, we need give applause to health policy planners in the majority of developed Asian countries, such as Japan, Singapore, Taiwan, and South Korea, are believed helping us to bring early breast cancer awareness and provide cost-effective screening to prevent delay diagnosis of Asian breast cancer.

#### **4. Application of breast MRI on Asian women and the dense breast parenchyma pattern**

Digital mammography is reliable as a screening or diagnostic tool for Asian women with NDBPP. Mammography can reliably image microcalcifications and solid tumors with good contrast from the fatty background tissue of the breast. The aim of image production during mammography is to separate fatty tissue from glandular breast tissue of low contrast density based on different X-ray absorption characteristics. Mammographic density estimation is based on a single two-dimensional projection of the breast. In contrast, breast MRI distinguishes different tissue types based on their signal production after radiofrequency stimulation within a strong magnetic field. MRI evaluation of the breast is three-dimensional, and the image analysis is assisted by a post-enhanced kinetic curve, and subtraction techniques only allow contrast-enhanced lesions to be depicted (Figures 1&2).

Figure 1 presents a representative case in the NDBPP group showing that a large tumor and cluster of microcalcifications could be easily detected with both mammography and breast MRI. Figure 2, in contrast, shows a representative case from the DBPP group. The mammograms of the left breast under cranial-caudal and medial-oblique views show diffuse faint nodular shadows without major architectural distortion. The finding of



malignancy could not be concluded due to a dense breast parenchyma background. However, breast MRI with a subtraction image demonstrated an enhanced tumor mass.

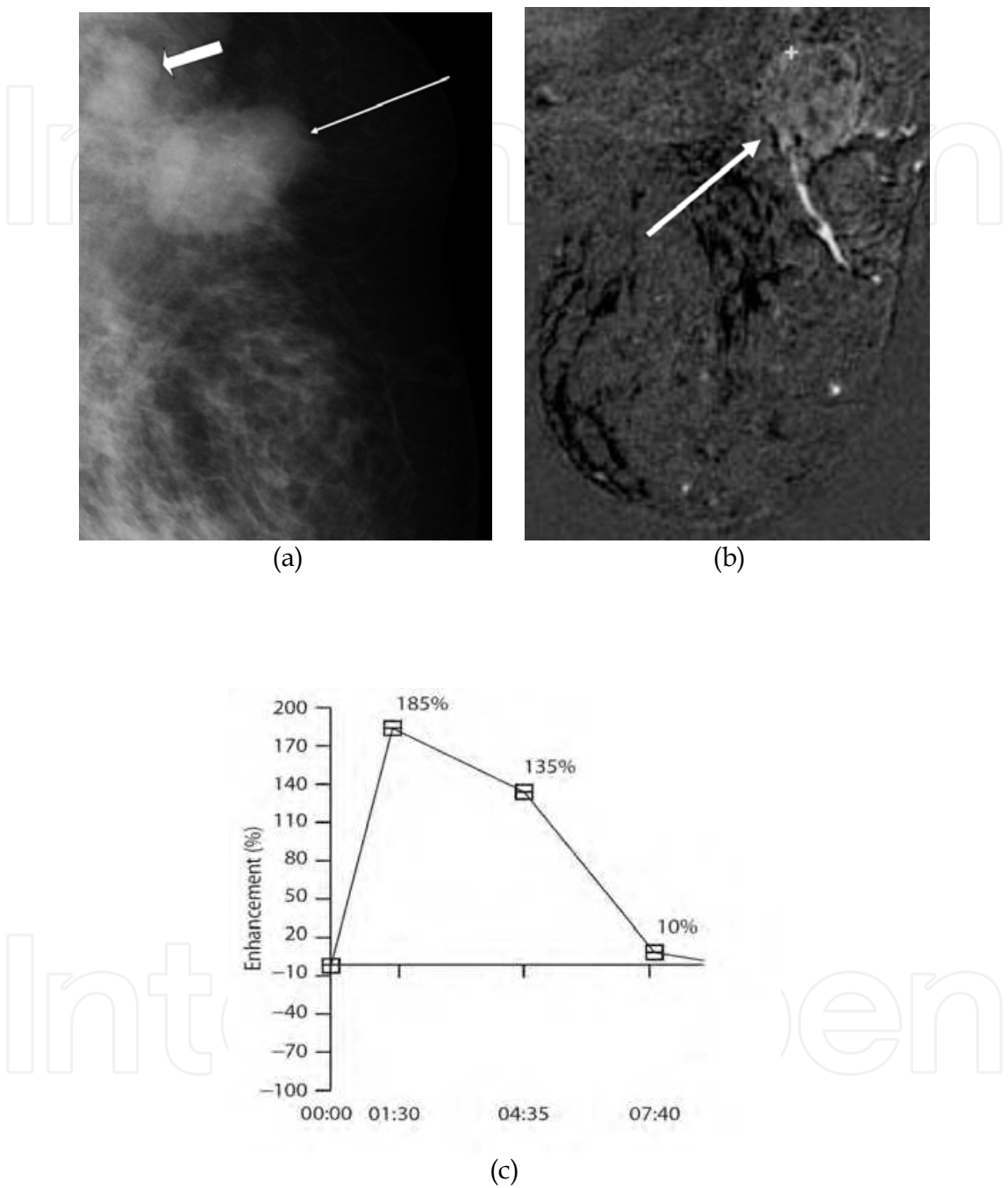


Fig. 1. (a) Mammogram of the non-dense parenchyma pattern group shows a large tumor and cluster of microcalcifications (thin white arrow) at the superior left breast with enlarged lymph nodes (thick white arrow), which was diagnosed as advanced infiltrative ductal carcinoma and lymph node metastasis. (b) The corresponding breast magnetic resonance imaging subtracted image of ESP (white arrow) matched the mammographic interpretation. (c) It shows a characteristic “wash-out” enhancing curve pattern, which is more likely to appear in malignancy.

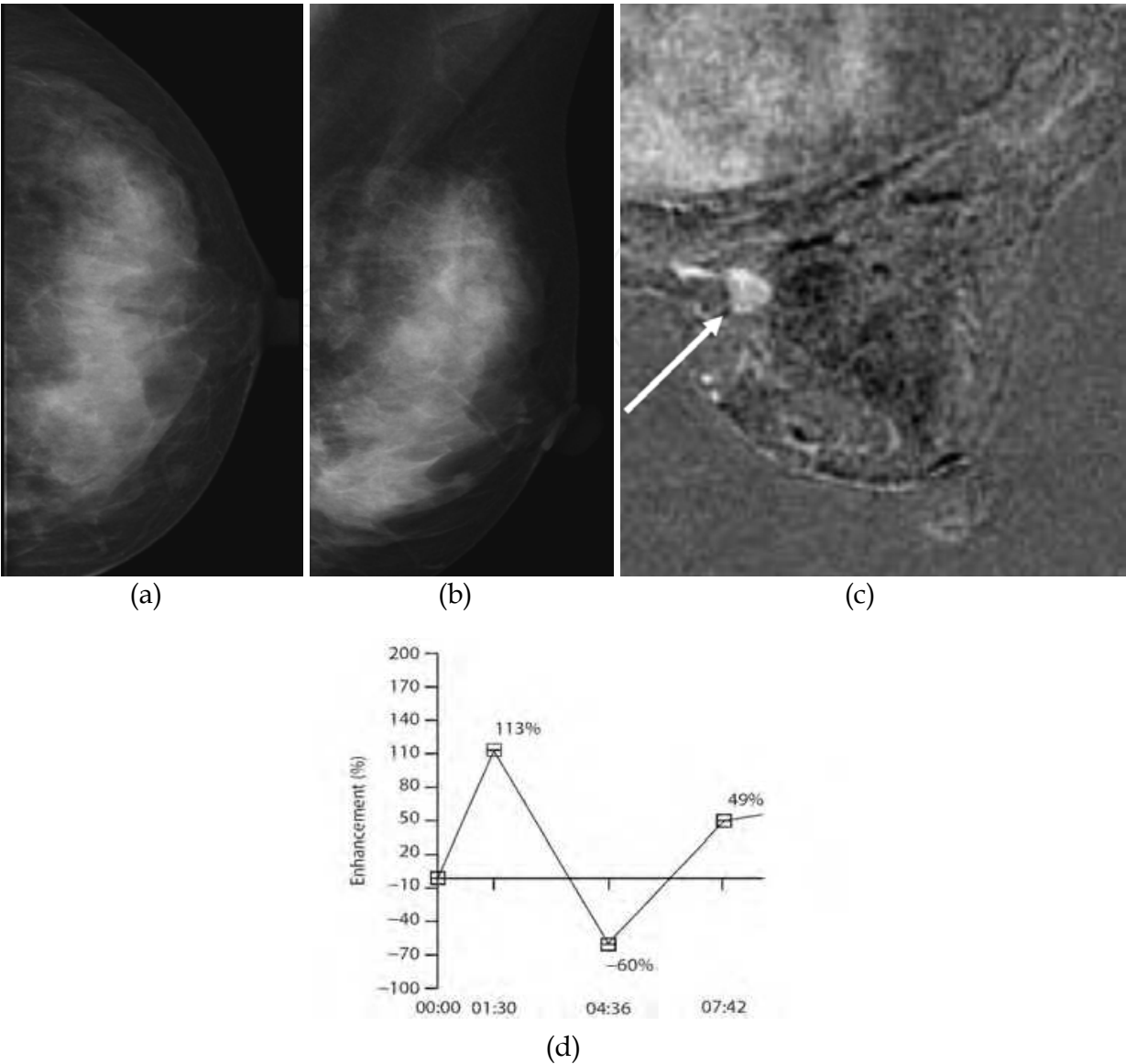


Fig. 2. Mammograms of the left breast under (a) cranial-caudal and (b) medial-oblique views of the dense parenchyma pattern group show diffuse faint nodular shadows without major architectural distortion. The finding of malignancy could not be concluded due to a dense breast parenchyma background. (c) However, follow-up breast magnetic resonance imaging with a subtraction image of ESP demonstrated an enhanced tumor mass (white arrow) at the medial aspect. (d) The corresponding enhanced curve analysis revealed a characteristic “wash-out” pattern.

Because the image is processed by subtraction of all the background tissue, a possible lesion can only be identified in the presence of extremely dense glandular tissue, different types of implantation, or fibrotic changes after chemotherapy with BRMRI (Thompson et al., 2009).

Previous study conducted by Kuhl et al (2010), have indicated that breast MRI is significantly more sensitive than mammography, sonography, and a combination of both. Breast MRI and mammography are more specific than sonography alone or in combination. In addition, the positive predictive value of breast MRI was 48%, higher than 39% of mammography and 36% of ultrasound.

## 5. MRI acts as a screening tool in a population of asymptomatic women

Mammography has well-recognized limitations for early breast cancer detection, especially for Asian women with DBPP. In the United States, MRI is provided as an adjunctive screening tool, mainly for women who may be at increased risk for the development of breast cancer. The Society of Breast Imaging and the Breast Imaging Commission of the ACR issue these recommendations to provide guidance to patients and clinicians on the use of imaging to screen for breast cancer. The recommendations are based on available evidence, or based on consensus opinions of professionals and experts from the executive committee of the Society of Breast Imaging and the members of the Breast Imaging Commission of the ACR. These recommendations are intended to suggest appropriate utilization of breast MRI for screening high-risk groups. They are not intended to replace sound clinical judgment and are not to be construed as representing the standard of care. Mammography should be remembered to be the only imaging modality that has been proven to decrease mortality from breast cancer. Before using breast MRI, the potential benefits, limitations, and harm from this additional screening modality should be reviewed (Lee et al., 2010; Saslow et al., 2007).

Similar to Western countries, a higher proportion of Asian women with breast cancer have at least one relative with breast cancer. This risk can be almost double that of the general population. However, the gene correlated with this is different from that found in Western countries. In addition, gene screening programs and services are poorly developed, even in the wealthiest Asian countries. To define the high-risk group in the population, the national screening mammography program in Taiwan provides services for women aged between 40-45 years with a family history of breast cancer. Considering the low sensitivity of mammography in young women, a more aggressive breast MRI screening at this age or lower is recommended. Adjuvant breast MRI screening should also be considered for women with lymphoma (Hodgkin's disease), women who received radiation treatment between the ages of 10 to 30 years, women with lobular carcinoma *in situ* (LCIS), atypical lobular hyperplasia (ALH), and atypical ductal hyperplasia (ADH), which may range from normal ductal hyperplasia to ductal carcinoma *in situ* (DCIS). Specifically, women with a personal history of breast cancer, including DCIS, should be included. As previously mentioned, DBPP has been shown to be an independent risk factor for breast cancer. Women with the highest breast density were found to have a 4- to 6-fold increased risk compared with women with the least dense breasts. In addition, malignant tumors of the breast are more likely to arise in the areas of greatest mammographic density than in fattier areas of the breast. Although the ACS recommendations for Breast MRI Screening as an adjunct to mammography are more detailed, the most suitable indications for Asian women are provided in the following table (Table 2; Lee et al., 2010; Saslow et al., 2007)

## 6. The value of breast MRI as an adjunct in the diagnosis of breast diseases

Breast MRI can be used as an adjunct in the diagnosis of breast diseases when inconclusive findings in conventional imaging exist, such as with mammography and sonography (BI-RADS 0). Therefore, MRI can be used as a problem-solving modality (Mann et al., 2008). Generally, breast MRI provides a relatively higher negative predictive value for excluding malignancy (Dorrius et al., 2009; Dorrius et al., 2010).



<b>Breast MRI Screening as an adjunct to mammography is advised for women</b> with a family history that may suggest a genetic predisposition to breast cancer (Lee et al., 2010; Saslow et al., 2007)
<b>Breast MRI Screening recommendations for</b> who received radiation therapy to the chest in their 2nd or 3rd decade (Saslow et al., 2007)
<b>Breast MRI Screening recommendations for</b> patients with lobular carcinoma <i>in situ</i> (LCIS) , atypical lobular hyperplasia (ALH), or atypical ductal hyperplasia (ADH) (Saslow et al., 2007)
<b>Breast MRI Screening recommendations for</b> heterogeneously or extremely dense breast tissue, disabling the mammograph from interpretation (Lee et al., 2010; Saslow et al., 2007)
<b>Breast MRI Screening recommendations for</b> personal history of breast cancer, including ductal carcinoma <i>in situ</i> (DCIS) (Lee et al., 2010; Saslow et al., 2007)

Table 2. MRI acts as a screening tool in a population of asymptomatic women with preselection is listed.

MRI is the most reliable imaging technique for measuring the tumor size, and it detects additional foci of the tumor in the ipsilateral breast in 10–30 % of patients (Mann et al., 2008). The sensitivity of breast MRI is, in the setting of preoperational evaluation, close to 100 %. MRI may be considered after breast-conserving therapy (BCT) as an evaluation tool for residual disease after positive tumor margins. Thus, breast MRI acts as a diagnostic tool for all patients who undergo BCT. Breast MRI is superior for evaluating suspected recurrence compared to clinical examination, mammography, or sonography (Kuhl et al., 2010). Postradiation changes usually occur up to 3 months after radiation therapy and do not reduce the accuracy of MRI for identifying residual or recurrent tumors. The presence of an implant does not seem to decrease the sensitivity of breast MRI. MRI is the most accurate modality in the evaluation of implant integrity. Its sensitivity for rupture is between 80 % and 90 %, and its specificity is approximately 90 %, whereas the sensitivity of mammography is approximately 25 %. MRI may aid explanation surgery as it documents the presence and extent of silicone leakage better than any other imaging modality. In patients with prosthesis and prior breast cancer, MRI may be used to evaluate suspected recurrent disease or as a postoperative screening modality (Mann et al., 2008). Although most MRI-detected lesions can be found (and biopsied) with a second sonography, many cannot. The specificity of MRI in a previous study was 88 %; a biopsy was recommended on the basis of a positive MRI in 13.9 % of the women, and 24.8 % of the biopsies resulted in a diagnosis of breast cancer (Lehman et al., 2007a). MRI resulted in 8.2 % of women undergoing biopsy compared with 2.3 % for mammography and 2.3 % for sonography (Lehman et al., 2007b). The Positive Predictive Values (PPVs) of biopsies obtained by using MRI (43 %) and mammography (50 %) were higher than those of the United States (25 %). Of the cancers identified by MRI alone, approximately 75 % were targeted under sonographic guidance. However, approximately 25 % were removed for biopsy under MRI guidance because only MRI demonstrated the accurate location (Lehman et al., 2007b). In addition, breast MRI identified high-grade DCIS and high-risk lesions that were missed by mammography (Hartman et al., 2004). The call-back and biopsy rates of MRI are higher than for mammography in high-risk populations, while the increased sensitivity of MRI leads to a higher call-back rate and a higher number of cancers detected (Saslow et al., 2007). Women

at risk for familial breast cancer have shown an increased detection rate using this modality than with mammographic screening (Lee et al., 2010). Table 3 summarizes these values.

<b>Backup for inconclusive findings and for more detail to evaluate the lesion characterization:</b> Breast MRI may be indicated when other imaging examinations (sonography and mammography) and physical examinations are inconclusive for the presence of breast cancer (Figure 14).
<b>Occluded images:</b> Certain conditions that may impair conventional breast imaging, such as silicone augmentation or radiographically dense breasts, may warrant breast MRI depending on clinical findings (Figures 13,19).
<b>Contralateral breast with breast malignancy:</b> MRI can detect unsuspected disease in the contralateral breast (coincidence positive rate at 4-5% of breast cancer patients), which often provides false negative findings on mammography or sonography (Figure 2).
<b>To differentiate scars from real malignant mass:</b> Breast MRI can help distinguish postoperative scarring or radiation scarring from recurrent cancer.
<b>Suspect of breast cancer recurrence:</b> Breast MRI may be indicated in women with a past history of breast cancer.
<b>Metastatic adenopathy:</b> MRI provides a full field of view in a single position and an image acquisition that covers major positions of the bilateral axillary lymph nodes and internal mammary chains, which may be missed by mammographic or physical findings (Figure 4,5,12).
<b>Determining true tumor extension:</b> Breast MRI can locate the primary area of breast cancer and define the extent of the disease for definitive therapy. A negative breast MRI may exclude the breast as a potential primary site of cancer and avoid a mastectomy or help minimize the invasive procedure (Figure 9,10,11).
<b>For metastasis:</b> Breast MRI helps evaluate the breasts in case of metastases of an unknown primary carcinoma.
<b>For chemotherapy:</b> Breast MRI helps evaluate therapy response in patients treated with neoadjuvant chemotherapy (Figure 7-8).
<b>Silicone and nonsilicone breast augmentation:</b> Breast MRI is useful in the evaluation of patients with silicone implants and silicon injections, in which sonography and mammography are usually inconclusive in defining tumor mass, silicoma, granuloma, and intracapsular or extracapsular implant ruptures (Figure 13,19).

Table 3. The value of breast MRI as an adjunct in the diagnosis of breast diseases (Mann et al., 2008).

7. Ability of MRI to describe multifocality and the extent of the disease

For women with newly diagnosed breast cancer, a single round of screening of the contralateral breast with MRI at the time of diagnosis might detect otherwise occult malignancy in approximately 3 % to 9 % of cases (Lee et al., 2010) (Figure 4).

MRI has been found to be more accurate in assessing tumor extent and multifocality in patients with dense breasts. MRI can improve the detection of cancer in the contralateral breast when added to a thorough clinical breast examination and mammographic evaluation at the time of the initial diagnosis of breast cancer. The increased rate of cancer

detection comes with a false positive rate of 10.9 % and a relatively low risk of detecting benign disease on biopsy (9.4 %) (Lehman et al., 2007a).

## **8. Limitations of the breast MRI technique for screening in its current form**

MRI is inappropriate for women at a low lifetime risk for breast cancer. Breast MRI is not meant to replace mammography (Lee et al., 2010). Under rare circumstances, such as DCIS with typical microcalcification clusters, mammography is superior to MRI for interpretation malignancy, which produces an image that is faint or equivocal (Lee et al., 2010).

The lesion-detecting specificity of MRI is highly influenced by reacted inflammation within a month after surgery. Thus, a time period should elapse post-surgery before an MRI (Mann et al., 2008). In addition, the dynamic breast MRI is highly influenced by hormonal fluctuations during the menstrual cycle, which may cause interpretative difficulties related to the uptake of gadolinium in normal breast tissue (Delille et al., 2005; Kriege et al., 2006). The call-back and biopsy rates of MRI are higher than for mammography in high-risk populations. This is because of the increased sensitivity of MRI. The net harm, benefits, and psychological impact of higher cancer detection rates should be considered (Saslow et al., 2007). Breast MRI screening is almost 10 times more expensive than mammographic screening, and generates higher diagnostic costs (Plevritis et al., 2006). Asian countries adopting unlimited breast MRI can face a heavy financial burden. Some concern exists regarding the clinical safety of the intravenous gadolinium-based contrast media used during breast MRI. In Hong Kong, the adverse reaction rate is reported at 0.48 %, and the incidence of severe anaphylactoid reaction is approximately 0.01 %. Although most of the symptoms are mild and transient, these adverse reactions must be documented and managed accurately (Li et al., 2006).

## **9. Advantages of a dedicated breast MRI (DBMRI) system with parameters of dynamic scan, 3D representation, and post processing techniques**

The recent recommended standard for assessing MRIs to differentiate malignancies from benign lesions is the fourth edition of a breast MR lexicon (Morphological interpretation of BRMRI images using standards of the American College of Radiology's (ACR) BI-RADS-MRI lexicon for malignancy grading) (American College of Radiology, 2003; Erguvan-Dogan et al., 2006), which is a classification scheme used for the interpretation of breast cancer. Although universal standards for integrating different MRI systems and manufacturers are lacking, overall, characteristics based on BIRADS scoring of MRI descriptions depend on certain parameters. This is a report on my experience with a specific MRI system and pulse sequence.

The DBMRI system with a Spiral RODEO pulse sequence of a 1.5 T dedicated spiral breast MRI system (Aurora System; Aurora Imaging Technology Inc., North Andover, MA, USA, using the Spiral RODEO pulse sequence) is equipped with different post-processing techniques, including early subtracted phase (ESP), post-contrast kinetic curve, and MPR with ductal orientation, which can be independently applied in a DBMRI system (Leung et al., 2010a; Leung et al., 2010b; Leung et al., 2010c; Leung et al., in press). Axial and sagittal gradient echo T1 acquisitions were performed for both breasts with a bilateral breast coil. Sequences were performed before and after the infusion of 0.2 mmol/kg gadolinium, administrated as a bolus dose with a power injector followed by a 20 mL saline flush.

**10. Lesion analysis using ESP image, kinetic curve patterns, color mapping, and morphology**

In the DBMRI, for cases suspected of being malignant, an ESP image was obtained based on subtraction of the post-enhanced phase of images from 90 s non-enhanced images. Lesions that could be subtracted in the ESP (by subtraction of the post enhanced image at 90 s from the pre-contrast phase) were almost completely excluded from the possibility of being malignant (Figure 1b). Therefore, the lesions that could not be subtracted in the ESP required further analysis to assess the risk of malignancy.

Using the mean percentage calculation and comparing pre- and post-contrast kinetic data (calculated from 0 s, 90 s, and 4.5 min), the threshold point for lesion enhancement was displayed. According to the diagnostic observations of Dr. Christane Kuhl (1999), curved patterns of the plateau and washout with bound protein water and free water represent possible lesions. A stabilized enhancement without change in signal intensity between 90 s and 4.5 min was termed a “plateau” pattern. A “washout” pattern was indicated by a decline in signal intensity between 90 s and 4.5 min after the injection of contrast. Each lesion was characterized according to the strongest enhancement pattern visible over the entire lesion. Figures 1c show magnetic resonance imaging for differentiating lesions that are normal, benign, or display a washout pattern.

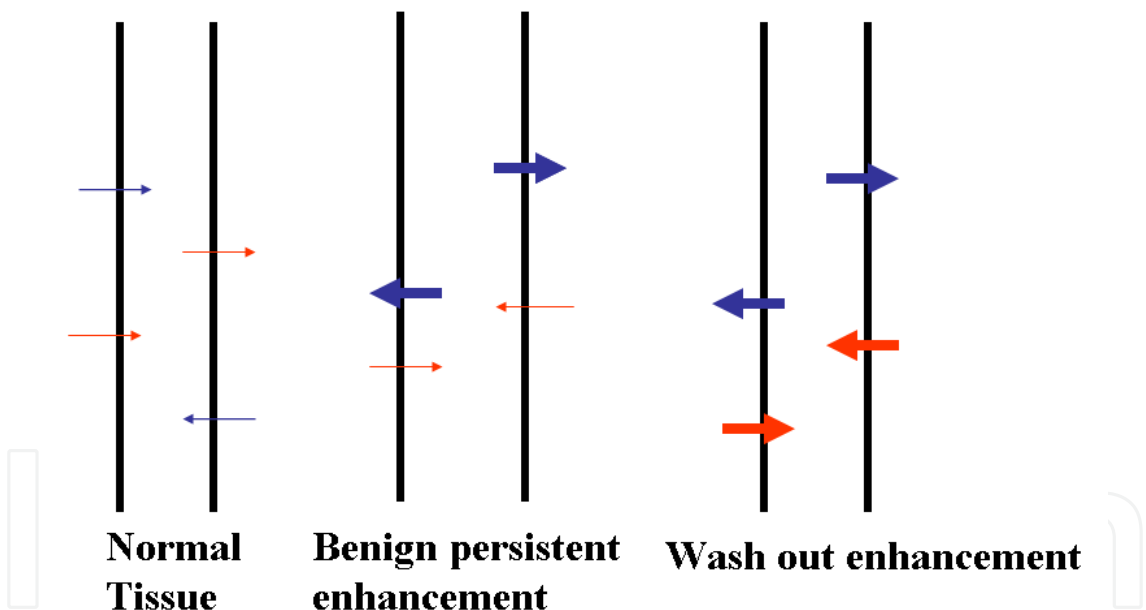


Fig. 3. In normal tissue, the contrast medium equally permeates in and out through the normal gaps in the vascular endothelial cells and interstitial space. In benign neoplasms, contrast does not permeate out of the microvessel to interstitial space, and the progressive accumulate increases the concentration which manifests itself in a progressively increased MRI signal.

The washout curve represents the initial increase in contrast concentration in the interstitial space and then a decrease, as it reverse permeates back through the abnormal gaps in the vascular endothelial cells. A final decreased contrast concentration in the tumor interstitial space can be detected.

A color mapping method was also adopted to assess the possibility of a malignancy. This reflects the overall curved patterns of the persistent-plateau (yellow color) and plateau-washout (red color), which is depends on the permeability of contrast medium through the capillary vessel of the neoplasm (Figure 3). This provided a tool for the subtle distinction of different grades of contrast-enhanced percentages so that the kinetic curve analysis of the region of interest (ROI) would be more convenient (Figure 1,2).

Morphological interpretation of BRMRI images uses standards of the American College of Radiology’s (ACR) BI-RADS-MRI lexicon for malignancy grading (x). In this study, MRI studies were interpreted in conjunction with clinical history, family history of breast cancer, age, and menstrual status. Referring MRI-detected lesions for biopsy depended on characteristics of the ESP image, post-enhanced curve pattern, color mapping, and tumor morphology, such as spiculation, irregular margins, architectural distortion, and ductal or segmental enhancement (Figure 4). The lesion configuration was classified as focal mass enhancement or non-mass-like enhancement. The morphological parameters of focal mass enhancement were evaluated by its lesion shape and mass margin. Lesion shape was classified as round, oval, lobular, and irregular. Mass margins were classified as smooth, irregular, and spiculated. Non-mass-like enhancement included linear, ductal, regional, and segmental enhancement (Figure 4).

Morphological characteristics were considered the most important determining factor for benign or malignant masses. Any suspicious MR-enhanced lesions were described based on lesion shape, borders, distribution, kinetics, and internal architecture. The final MR assessment was classified on a six-point scale, which is summarized in the following table (Table 4).

Category	Interpretation and the suggestion
I	Negative for malignancy
II	Benign findings or benign lesions
IIIa	Probable benign lesion, suggest 6 months follow up with sonography focused on the MRI indicated position or in the other breast
IIIb	Probable benign lesion, suggest 3 months follow up with sonography focused on the MRI indicated position or in the other breast
IV	Could not rule out the possibility of malignancy, suggest biopsy
V	Malignancy is strongly suggested. Tumor staging and therapeutic planning suggested.
VI	Malignancy. Further treatment, including surgery, adjuvant chemical therapy, or radiation therapy is suggested.

Table 4. MRI is believed to be the most sensitive and accurate screening tool for breast cancer in Asian women. Thus, no Category 0 exists in the interpretation of breast MRI, which differs from mammography or sonography.

Examinations that provided an initial assessment of incomplete or 0 received a final MR assessment of Category I-V, based on the results of follow-up procedures. A lesion was identified as suspicious if a focal mass existed with irregular or speculated margins, if enhancement had a ductal distribution, if a solid lesion showed rim enhancement, or if there was intense regional enhancement in less than one quadrant. Benign lesions were identified as having smooth or lobulated margins (Lehman et al., 2007b).



A lesion of < 5 mm of enhancement, even with a washout curve or mixed washout/plateau kinetic curve and reddish color mapping, was not automatically referred for biopsy. This was because a tiny spot of enhancement of < 5 mm is known as a ‘focus,’ as described by the ACR Breast MRI Lexicon, and has a very low possibility of being a malignancy, and is, therefore, suitable for a short-interval follow-up (Lieberman et al., 2006). MRI-guided biopsy, MRI-guided localization for an excisional biopsy, sono-guided biopsy, or surgical excision biopsy is employed in cases suggestive of or strongly suspected of being a malignancy.

The interpretation of breast MRI images using early phase subtraction, kinetic curve patterns, color mapping (based on the summing up of kinetic curve data from corresponding areas), and the morphology of the MR image, is helpful in differentiating malignancies from benign lesions. Dedicated breast MRI with ESP, kinetic curve, and morphology analysis was found to have an over 95% negative predictive value of ruling out malignancy and was helpful in identifying the characteristics of early-stage malignant lesions.

The usual applications, benefits and interpretations of breast MRI images are shown as Figure 4~13.

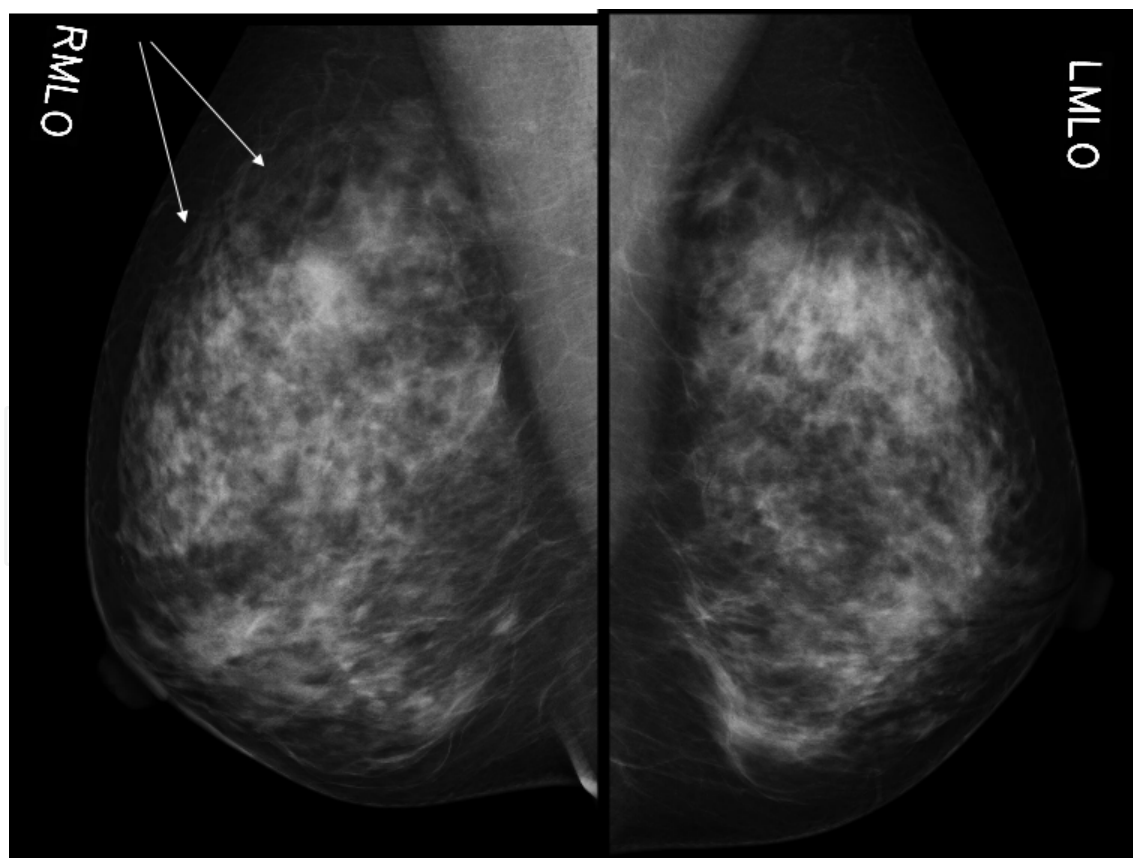


Fig. 4. (a)

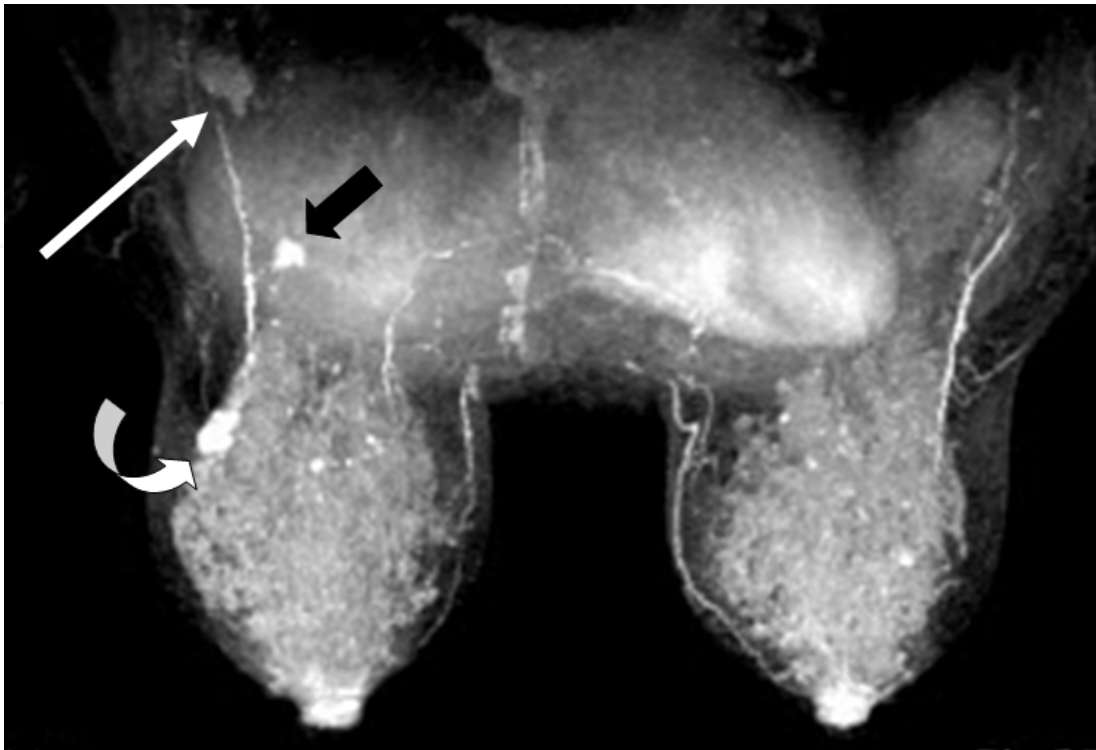


Fig. 4. (b)

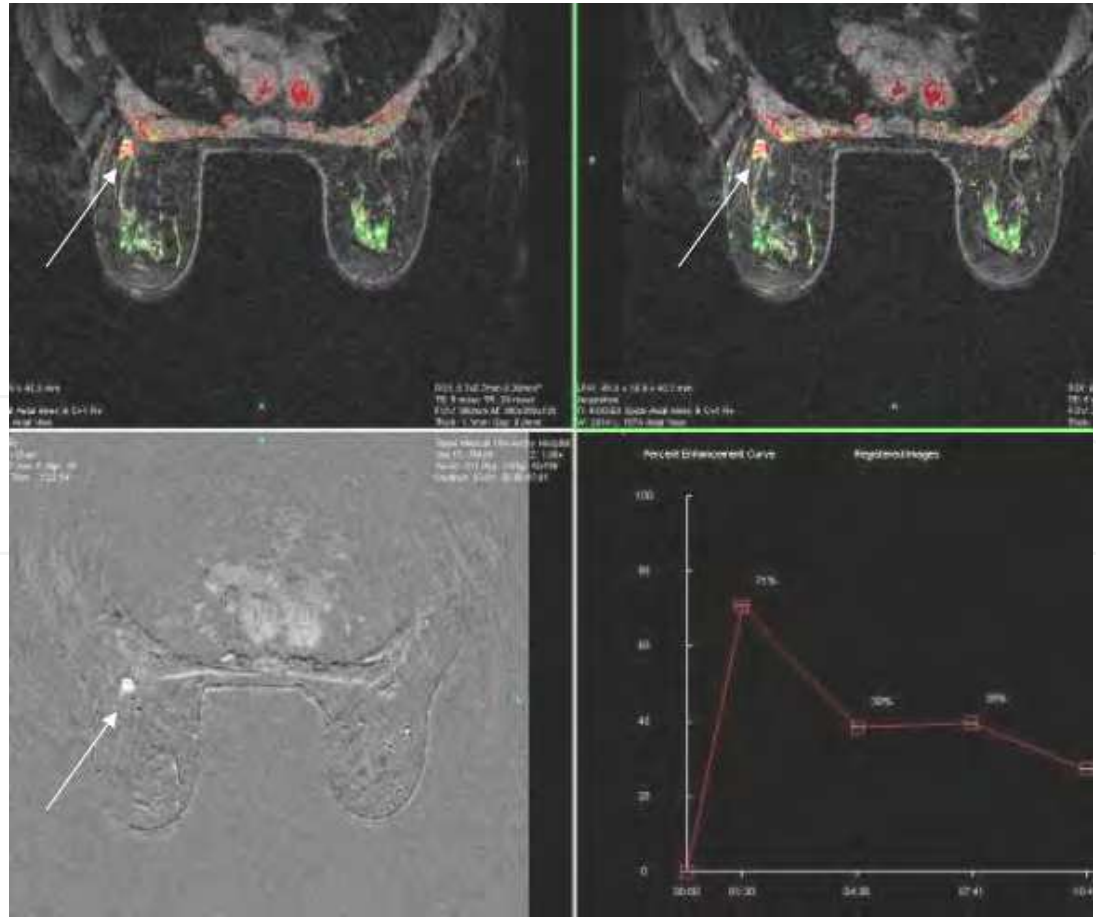


Fig. 4. (c)

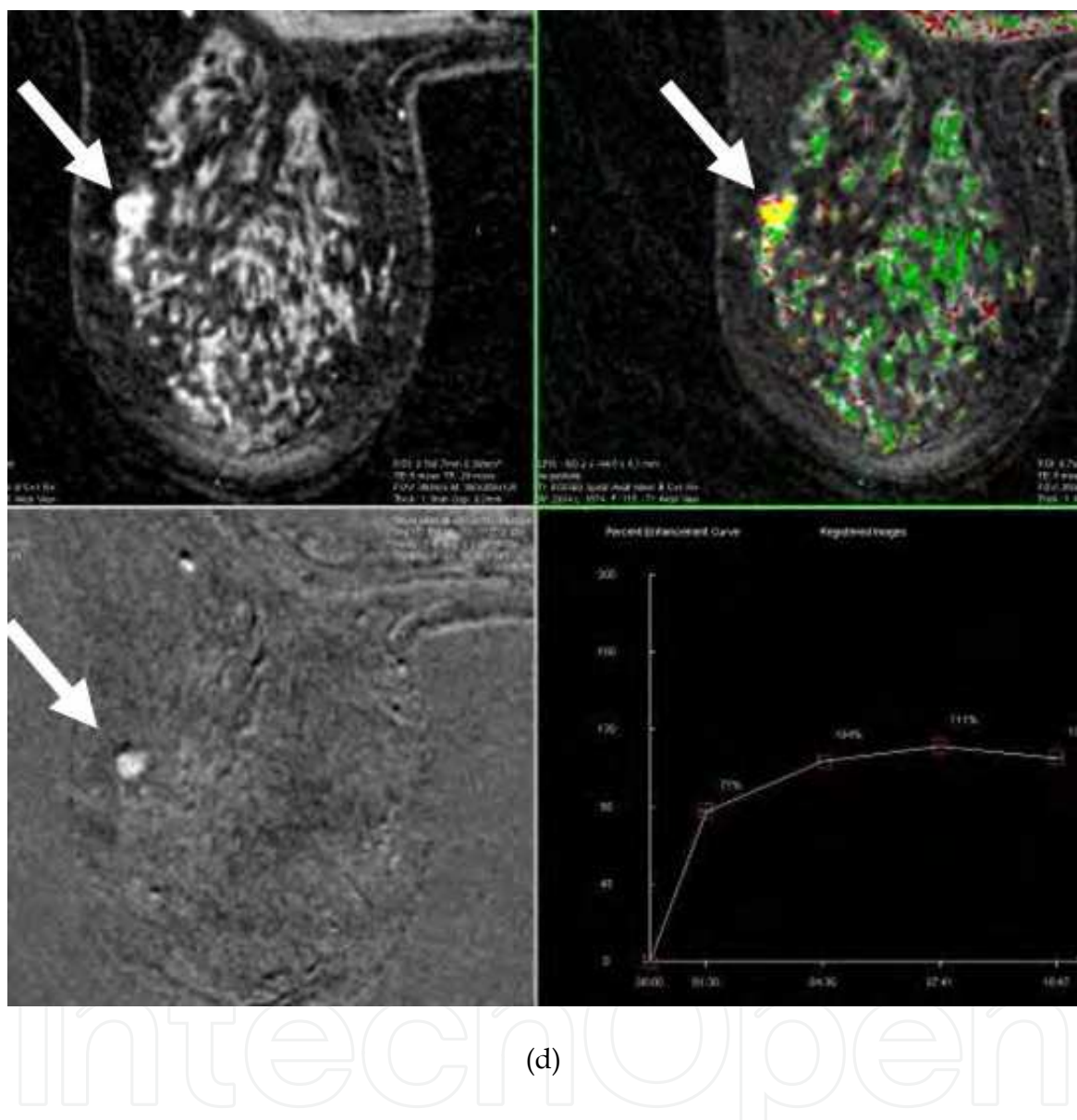


Fig. 4. (a) Digital mammography of an Asian women with DBPP showed two indistinct ill defined dense shadows noted at superior lateral of right breast. There is no enlarged axillary lymph node could be demonstrated. (b) Breast MRI simultaneously showed an enlarged right side axillary lymphadenopathy (long white arrow); first right superior mass (black arrow) and second right superior mass (white curve arrow). (c) Breast MRI with post processing software for analysis shows the first right superior mass remains high signal under ESP and exhibits ‘washout’ curve pattern. Pathological report indicate a small invasive ductal carcinoma. (d) It shows the second right superior mass remains high signal under ESP but exhibits a ‘persistent’ curve pattern. Pathological report as benign fibroadenoma.

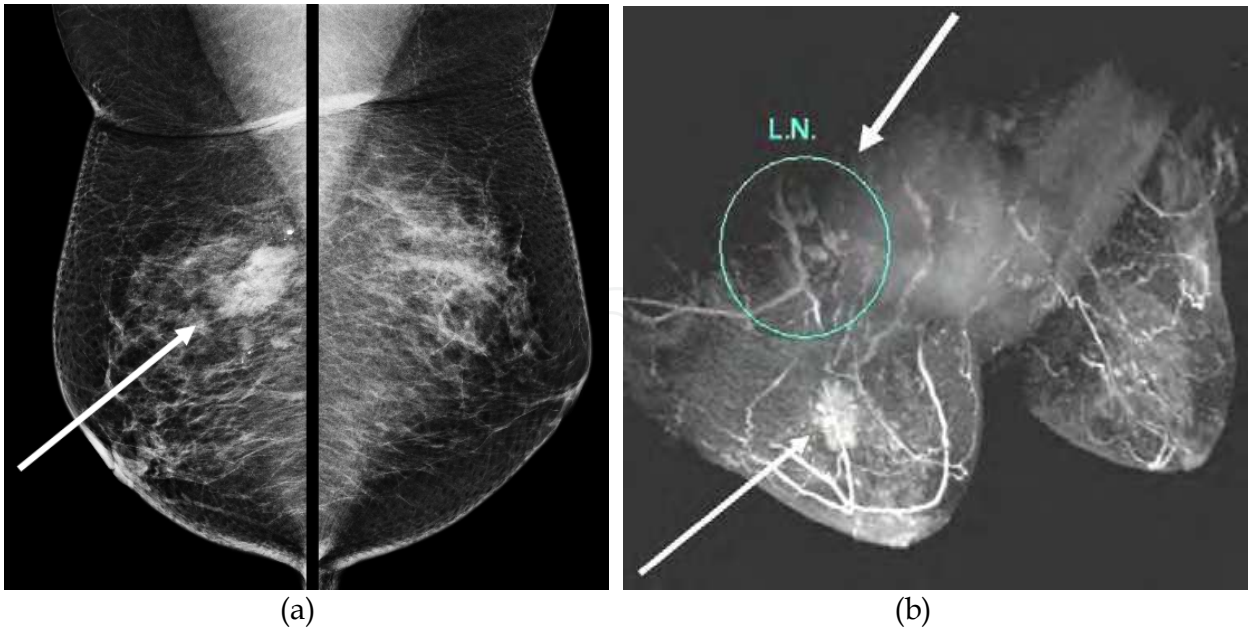


Fig. 5. (a) Digital mammography showed an ill defined hyperdense mass (thin arrow) locate at superior right breast, but it could not demonstrate ipsilateral axillary lymph node. (b) Breast MRI with 3D MIP (maximum intensity projection) shows the first right superior mass remains high signal under ESP and exhibits ‘washout’ curve pattern. Pathological report indicates a small invasive ductal carcinoma.

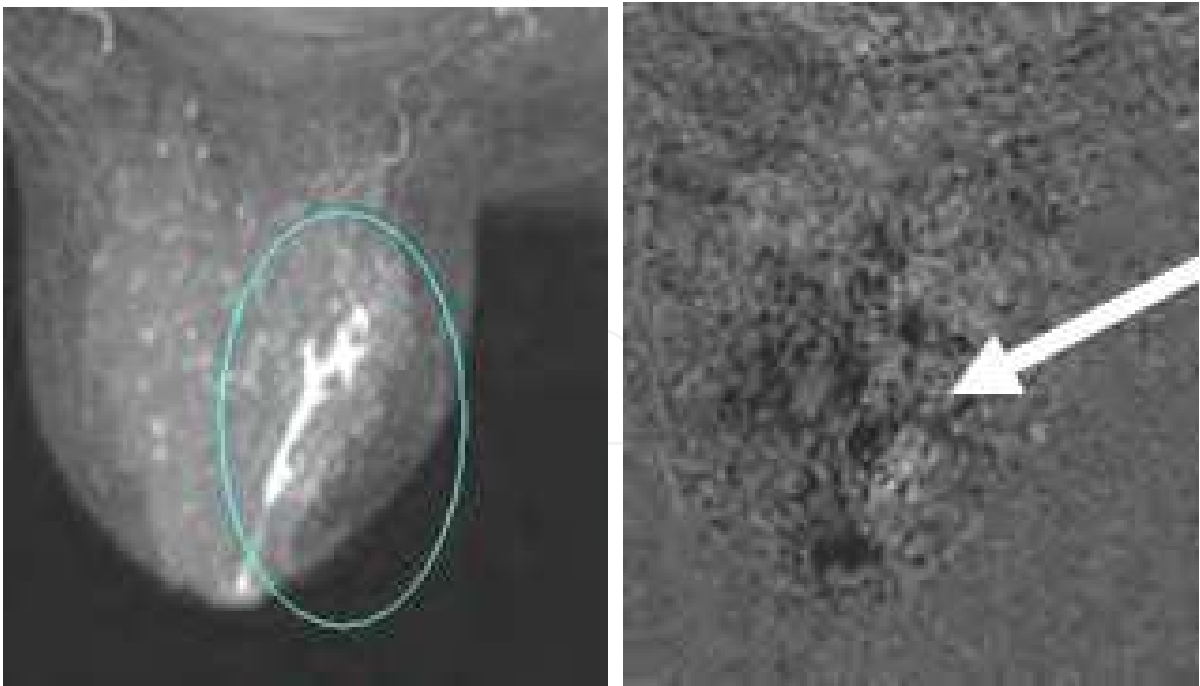

Fig. 6. Breast MRI image of an Asian woman with bloody discharge with clinical diagnosis as malignancy, it shows high signal intensity content within intraductal appearance under 3D MIP (a: with circle); but the signal being almost subtracted under ESP (b: arrow). Pathological report indicates benign papilloma.

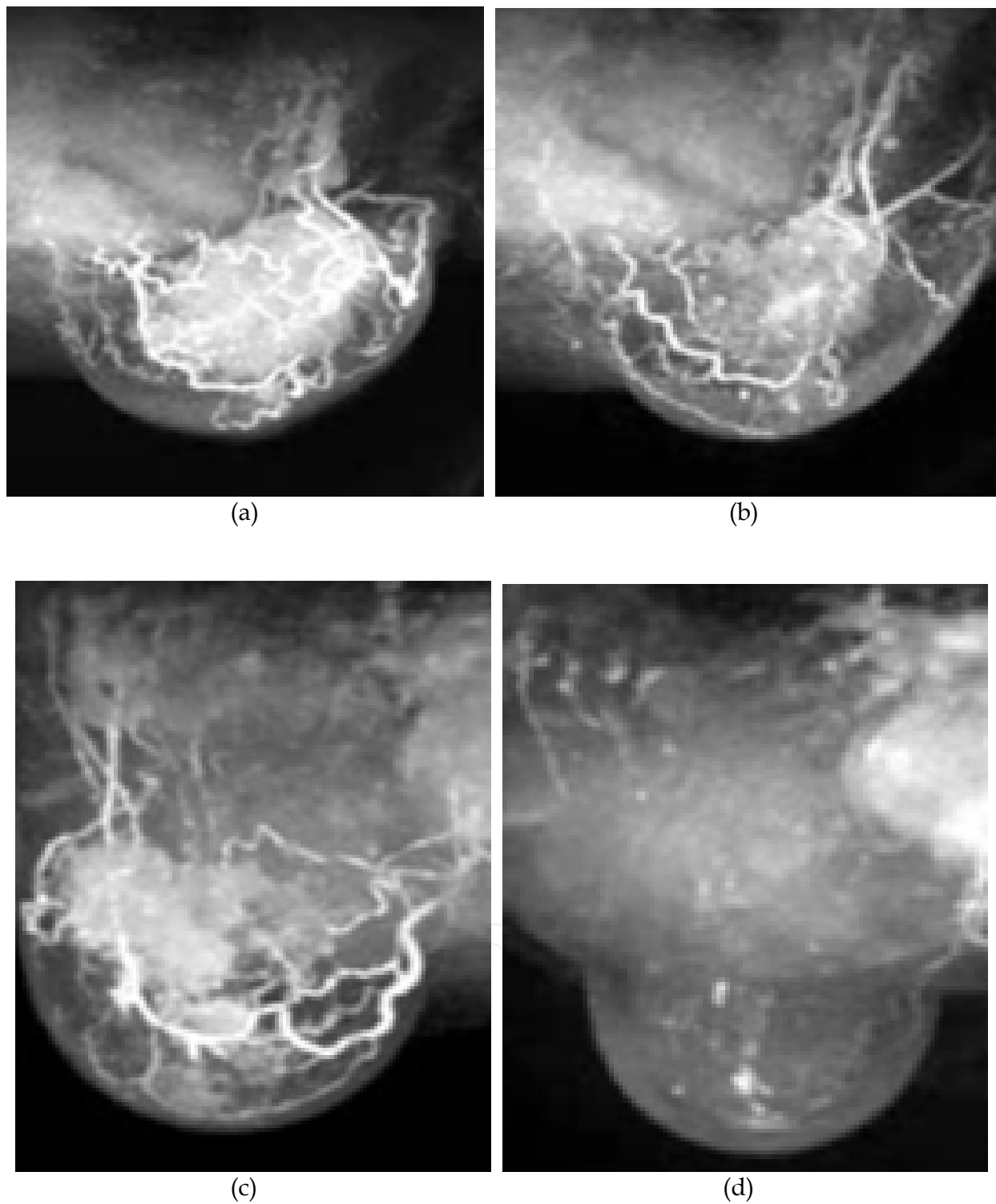


Fig. 7. Breast MRI has the merit on the clinical response assessment for chemotherapy. (a)(b) A patient with a huge size tumor of IDC at the left breast; after five cycles of chemotherapy, the tumor was shrinkage. (c)(d) In another patient, a similar huge size IDC mass in right breast, is finally almost completely regress after adjuvant and targeting chemotherapy.



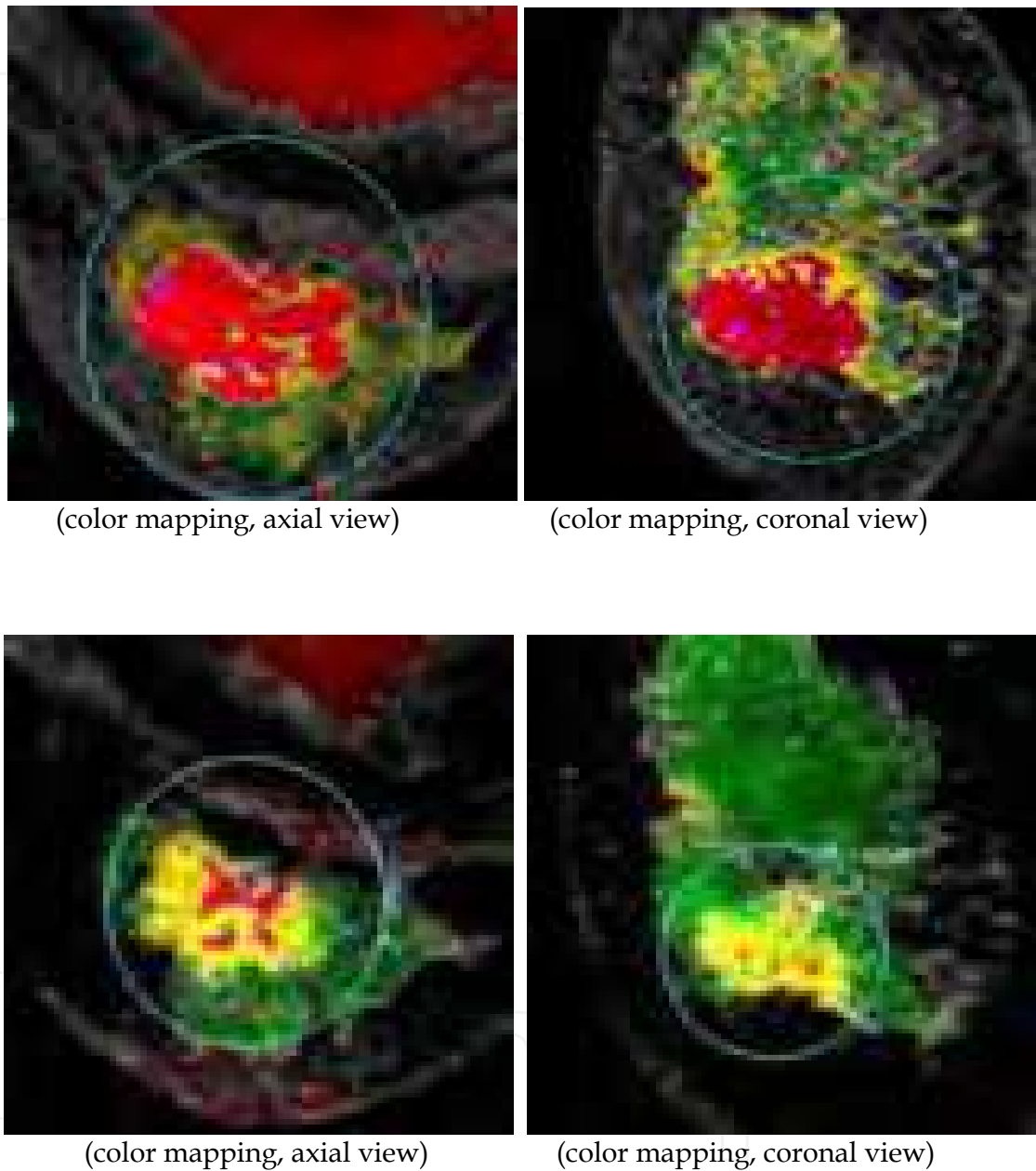


Fig. 8. By using color mapping of post processing breast MRI technique, more lively to demonstrate initial result of chemotherapy, even though the tumor size is not remarkable shrinkage. (a)(b) Red color area (represent active viable malignant cell with 'washout' contrast enhanced kinetic curve pattern) occupy the major part of the IDC tumor, in the right breast. (c)(d) After two cycles of chemotherapy, the red color shrinkage to less than 20% area of the tumor. This result encouraged both clinician and patient to continue this effective protocol of chemotherapy.

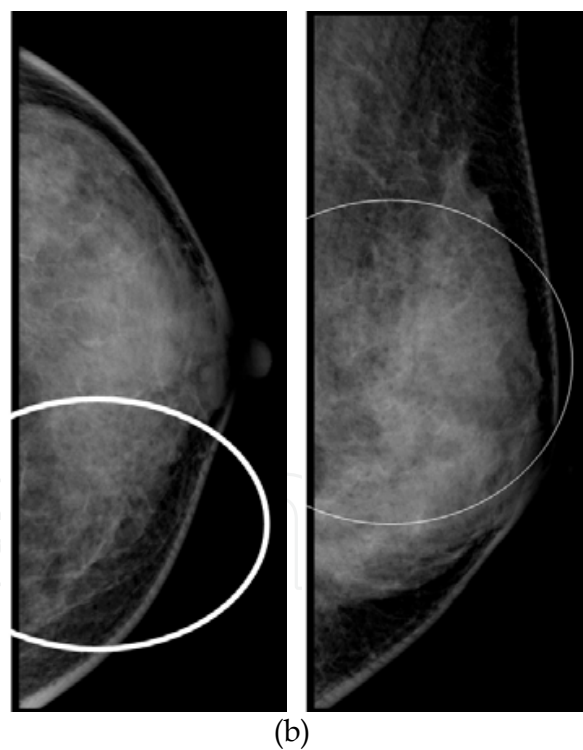
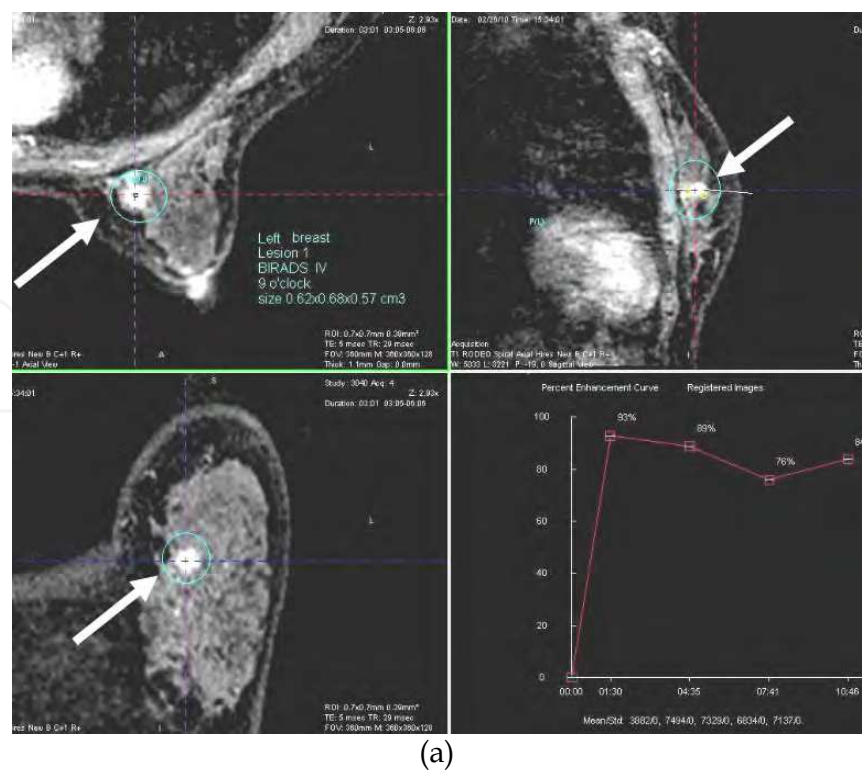


Fig. 9. Breast MRI adjunct the conventional breast modality with no limitation of breast size and breast dense pattern. (a) In this Breast MRI image of Asian woman, a 1.5 cm IDC tumor showed on left breast by all axial, sagittal and coronal views and associate 'washout' kinetic curve pattern. (b) As we retrospectively to review the digital mammography of this patient (both CC & MLO views), the mentioned mass is not capable to demonstrate due to the deep location and dense parenchyma occult effect of the breast.

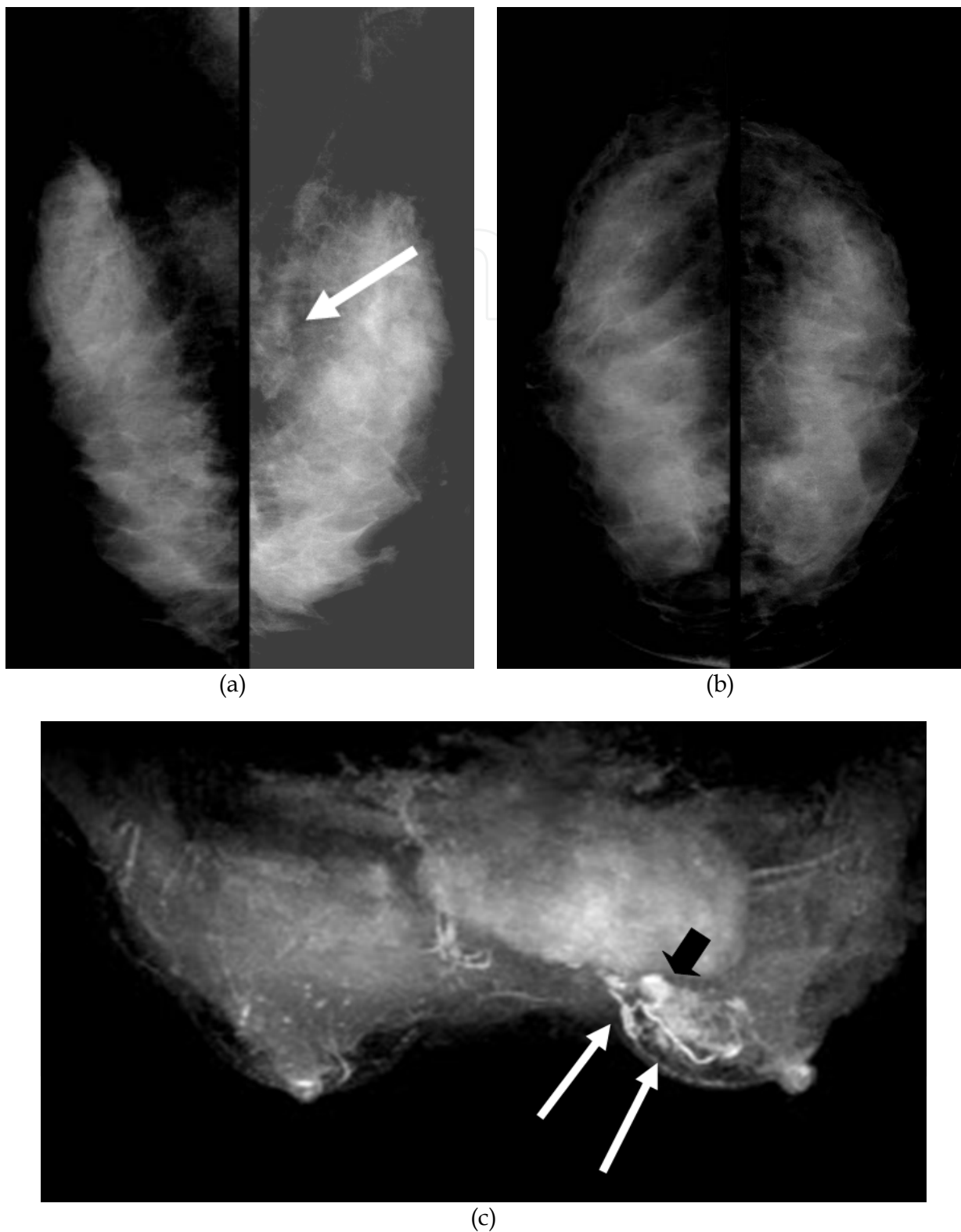


Fig. 10. (a)(b) An Asian woman with DBPP who received digital mammography, it shows suspicious mass locate at deep superior of left breast under MLO view (white arrow), but the CC view could not demonstrate the tumor location. (c) Breast MRI (oblique view of 3D MIP) is more clearly to demonstrate multiple foci of malignant masses by different tumor location and tumor sizes. Pathological proved as IDC and DCIS.

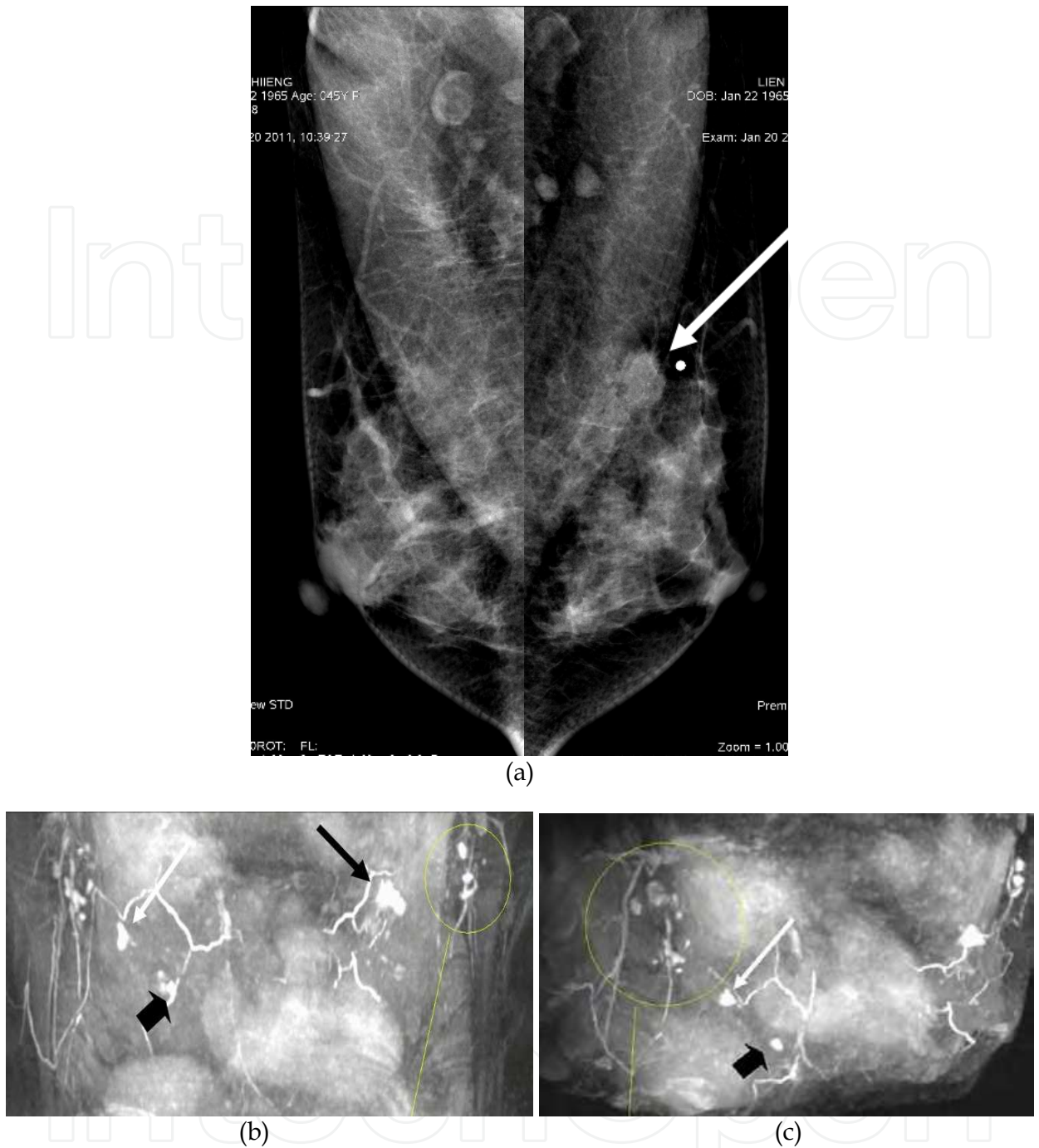


Fig. 11. (a) Breast MRI have the merit on the describing multifocality and the detection of asymptomatic cancer on the contralateral breast. In this Asian patient, digital mammography shows a single isodense palpable mass at superior of left breast (white arrow with metal beam). (b)(c)The follow up breast MRI shows another two enhanced tumor masses, with ill defined margin at superior lateral of right breast (long white arrow), which was proved as IDC. There is also a well defined enhanced mass with smooth margin, locate at paramedial aspect of left breast (black thick arrow), which was proved as fibroadenoma. Besides, the stronger enhancement of left axillary lymph nodes (circle on 11b) indicate the metastasis, compared with the weaker enhancement of right axillary lymph nodes (circle on 11c).

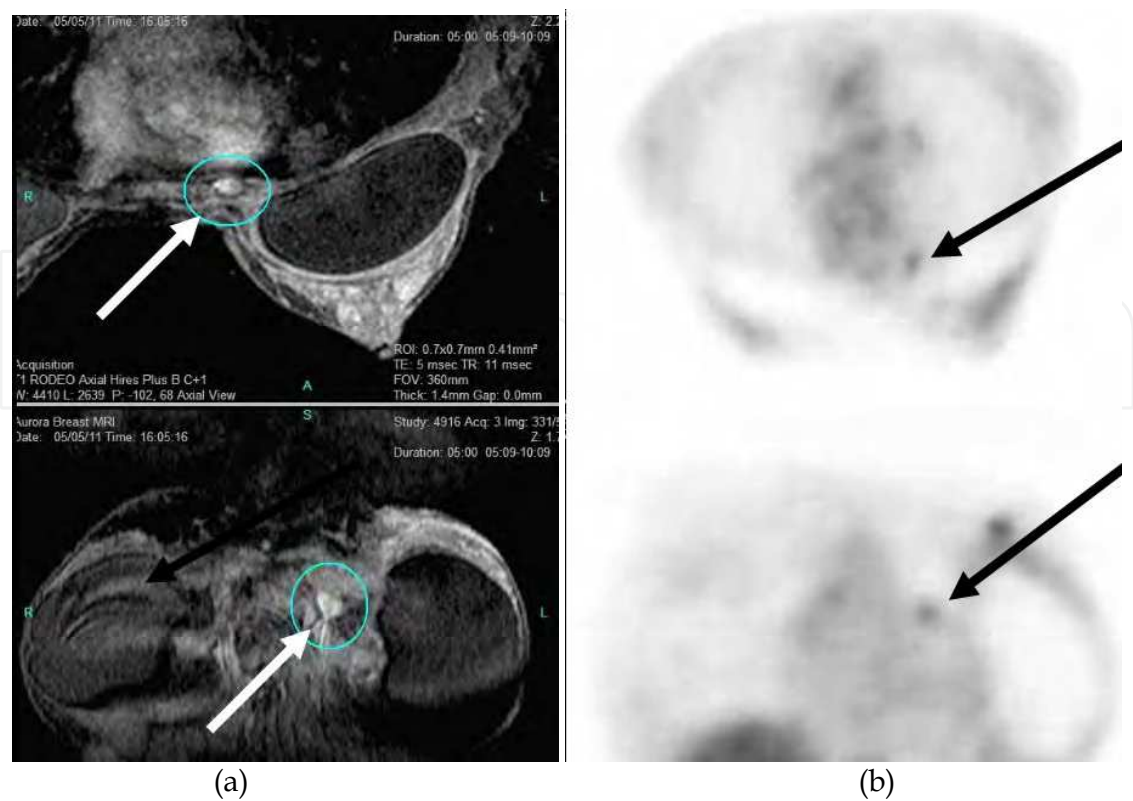


Fig. 12. (a) Breast MRI shows suspect enlarged lymph node at left side internal mammary chain (white arrows), (b) which proven by PET scan (black arrows).

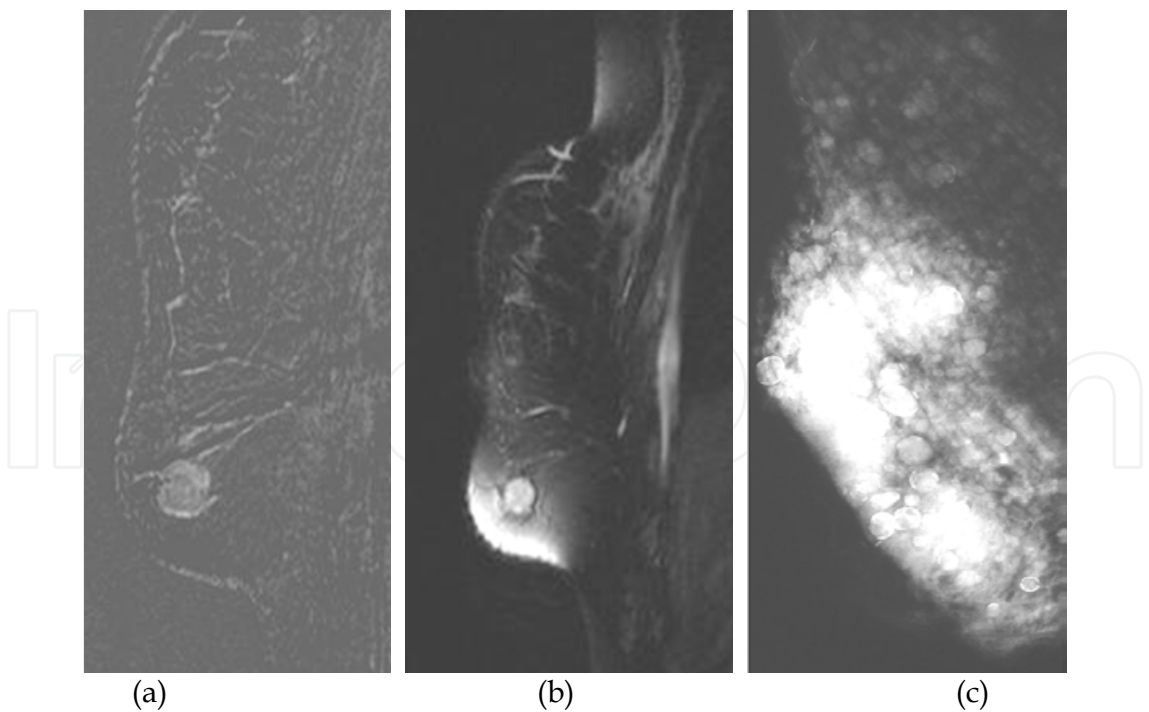


Fig. 13. Free silicon injection with silicoma and calcified granuloma formations usually occult the possible tumor growth on mammography (a); MRI with sagittal T2 plus fat saturation (b) and post enhanced subtracted image (c) provide a satisfactory detective rate on cancer on this group of patient.



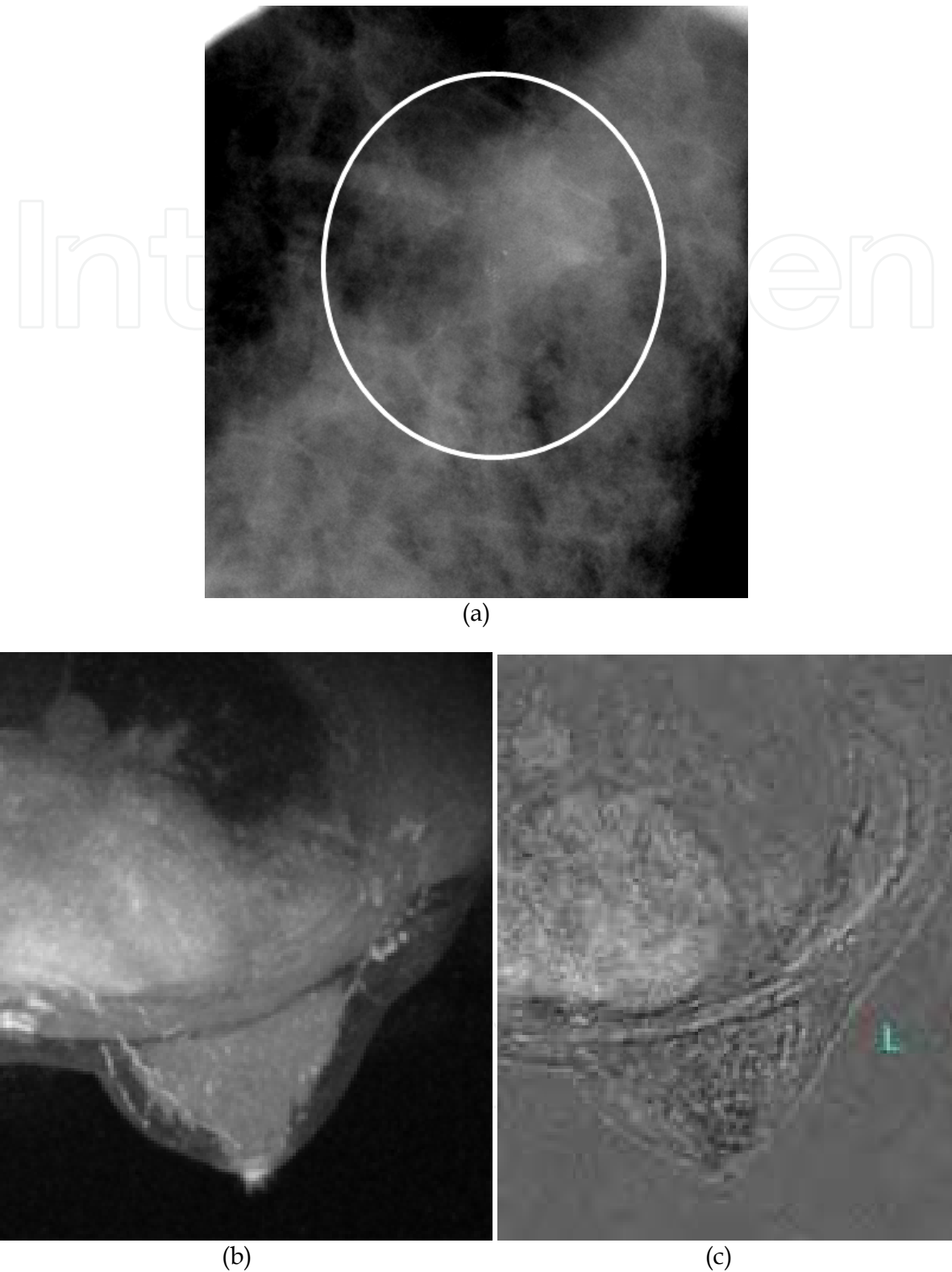


Fig. 14. Breast MRI may decrease unnecessary biopsy base on interpretation of screening mammography. In this Asian patient, digital mammography with spot compression view on left breast (a) demonstrate some cluster of faint microcalcifications. However, the follow up breast MRI shows no enhanced lesion in both 3D MIP (b) and subtracted image (c), thus, the schedule of call-back mammographic guide biopsy was cancelled.

### 11. Using a dedicated breast MRI system with the application of postprocessing techniques for multiplanar reformation (MPR) on mammary ductal orientation, for three-dimensional (3D) anatomical demonstration

Surgeons are required to localize accurately malignant tumors of the breast. Preoperative evaluation using DCIS or IDC is helpful for determining the surgical method and the necessity of lymphadectomy or preoperative chemotherapy. Compared to mammography and sonography, magnetic resonance imaging (MRI) is the most sensitive tool for breast cancer detection. Its ability for 3D anatomical representation has also become more important for pre-surgical evaluation.

Although the incidence of DCIS of the breast seems to be gradually increasing in Taiwan and other Asian countries, the proportion of small tumors detected is lower than in Western countries (Leung et al., 2010c; Huang et al., 2001; Shen et al., 2005).

The early stage of ductal carcinoma in situ (DCIS) appears as a spread-out distribution pattern, extending toward the nipple and is occasionally seen in the breast tissue peripheral to the infiltrating carcinoma. Only 3D imagery demonstrates the correlation of image and pathology. Sonography and mammography are incapable of showing the anatomical and spatial relationship between the lesion and the ductal structures within the breast (Figure 15) (Leung et al., 2010c).

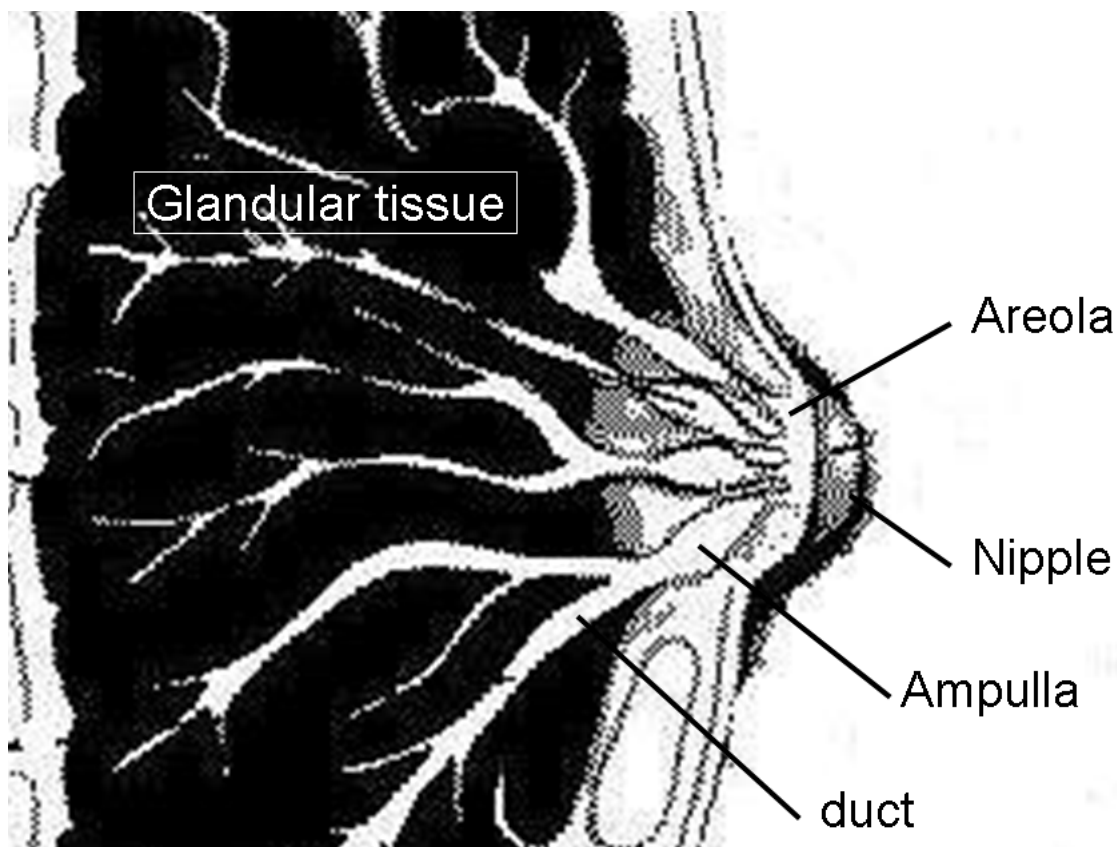


Fig. 15. shows the relationship between the mammary duct, the glandular tissue, and the nipple (Leung et al., 2010c).

The following figures demonstrate the application of DBMRI with the MPR technique, based on the AurorCad 4.0's oblique display protocol (Aurora System; Aurora Imaging Technology Inc., North Andover, MA, USA). The 3D maximum intensity projection (MIP) image outputs the selected plane of orientation as an oblique MPR on side-by-side display windows. The user controls the rotation of the 3D MIP from any angle, and the MPR pane is updated to match the slice, while having the same orientation as the MIP (Figures 16a & 16b).

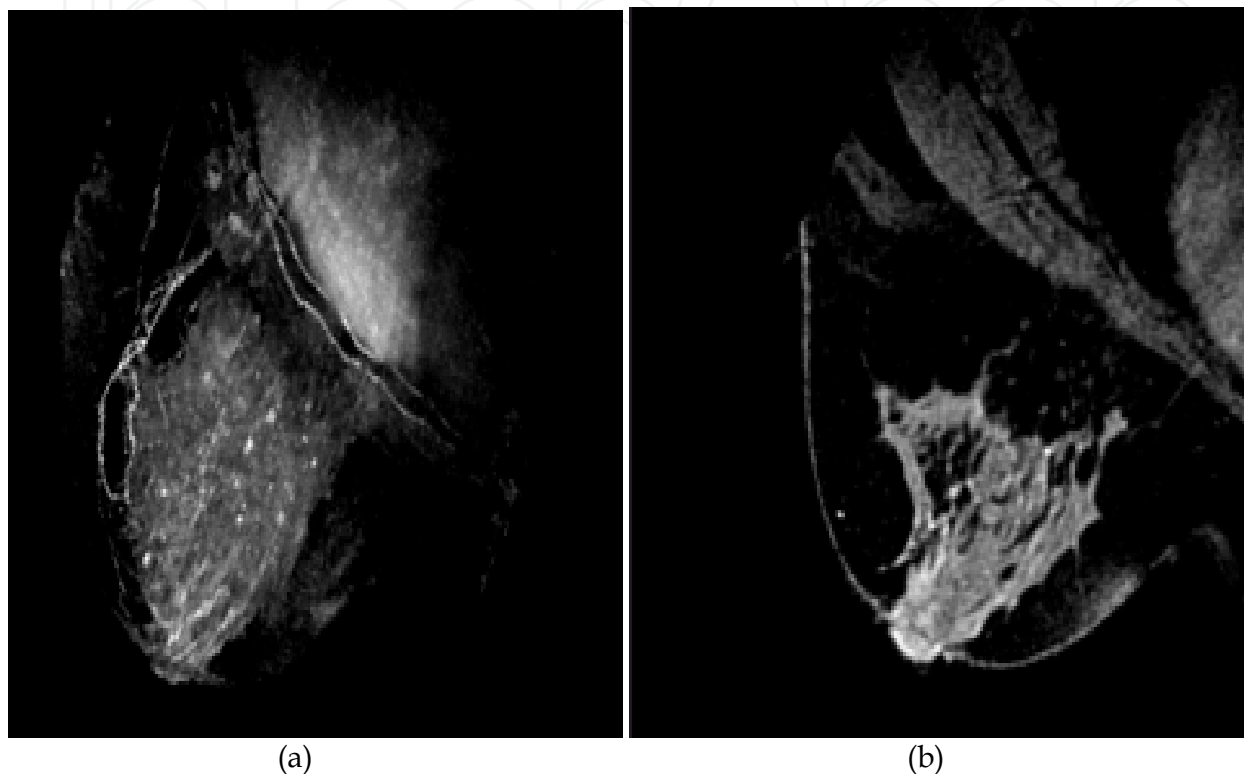


Fig. 16. While controlling the rotation of the 3D MIP (Maximum Intensity Projection) (a) from any angle of rotation, the MPR (multi-planar reformation) pane updates to match the slice in the same orientation as the new orientation of the MIP (b).

Ductal carcinoma *in situ* (DCIS) is a preinvasive condition that appears as tumor lesions of the ducts with severe atypical proliferation of epithelial cells. DCIS shows different grades of malignant potential, and certain subtypes of DCIS are more likely to recur. Approximately 60 % of women with DCIS will progress to invasive ductal carcinoma (IDC) over an 8–10-year period, and poor prognostic outcomes are likely when IDC develops. Thus, the early detection of DCIS through imaging studies that permit accurate assessment of size and distribution is important.

Breast MRI is a useful tool for staging invasive cancers like IDC. However, traditional breast MRI systems have limitations in the analysis of early DCIS using the sagittal and coronal planes. Although MRI provides a 3D representation of the enhanced tissues, the borders between DCIS and its surrounding benign processes are often indistinguishable, especially when DCIS is sparsely scattered. The actual size is also difficult to measure accurately during pathological examinations. This is because of the anatomy of the breast ducts are distributed in three dimensions and histological sections show only two. Measuring

scattered and widely distributed DCIS is difficult, which is one possible explanation for the frequent mismatch between MRI and pathological findings.

Screening for cases with ductogram appearance were performed to find if a significant correlation between DCIS and ductograms exists. The term 'ductogram' was used for image phenomenon that occurred when peri-ductal infiltration in the tissues immediately adjacent to the mammary duct was observed. The ductogram image shows non-contrast ductal structures differing from the enhanced periductal tumor infiltration if the ductal orientation is in phase using multiplanar reformation (MPR) (Leung et al., 2010c) (Figure 17).

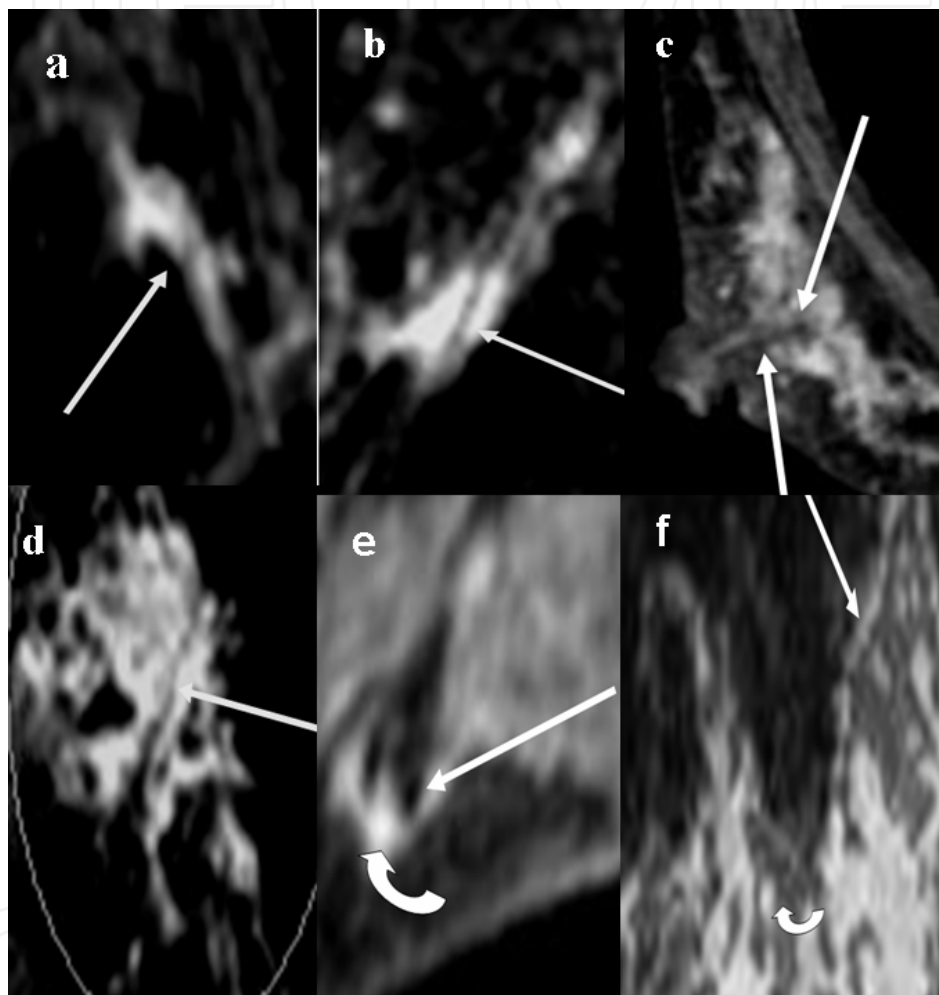


Fig. 17. (a) A characteristic ductogram appearance (long arrow) is visualized in case 1. (b) A characteristic ductogram appearance (long arrow) is visualized in case 2. (c) Case 3 shows characteristics of a ductogram pattern along the lactiferous sinus and duct to the areola, within a background of stripping and non-mass signal intensity. (d) Case 4 shows that pure DCIS is an intermediate grade of malignancy with delayed surgical treatment, in which the ductogram appearance is preserved. The MPR for ductal orientation is visualized by a non-mass with strip appearance, and lesion cross-over glandular tissue. (e) Case 5 shows pure DCIS visualized by its non-mass like intensity (curved arrow) and ductogram appearance. (f) Case 6 shows pure DCIS appearing with non-mass of intensity (arrow is the true DCIS area). The MRI overestimates tumor size over pathological size by over 200% (the curved arrow shows the false area).

Non-DCIS early ductal lesions, including intraductal papilloma, ductal hyperplasia, and early focal IDC, can be visualized using MPR with ductal orientation. Although certain characteristics of the lesion morphology (Figure 18) are similar to the pictures in terms of tumor size and the spreading along glandular tissue, not all lesions exhibit a ductogram appearance. However, additional analysis using early subtracted image and a post-contrast kinetic curve may further confirm the image diagnosis.

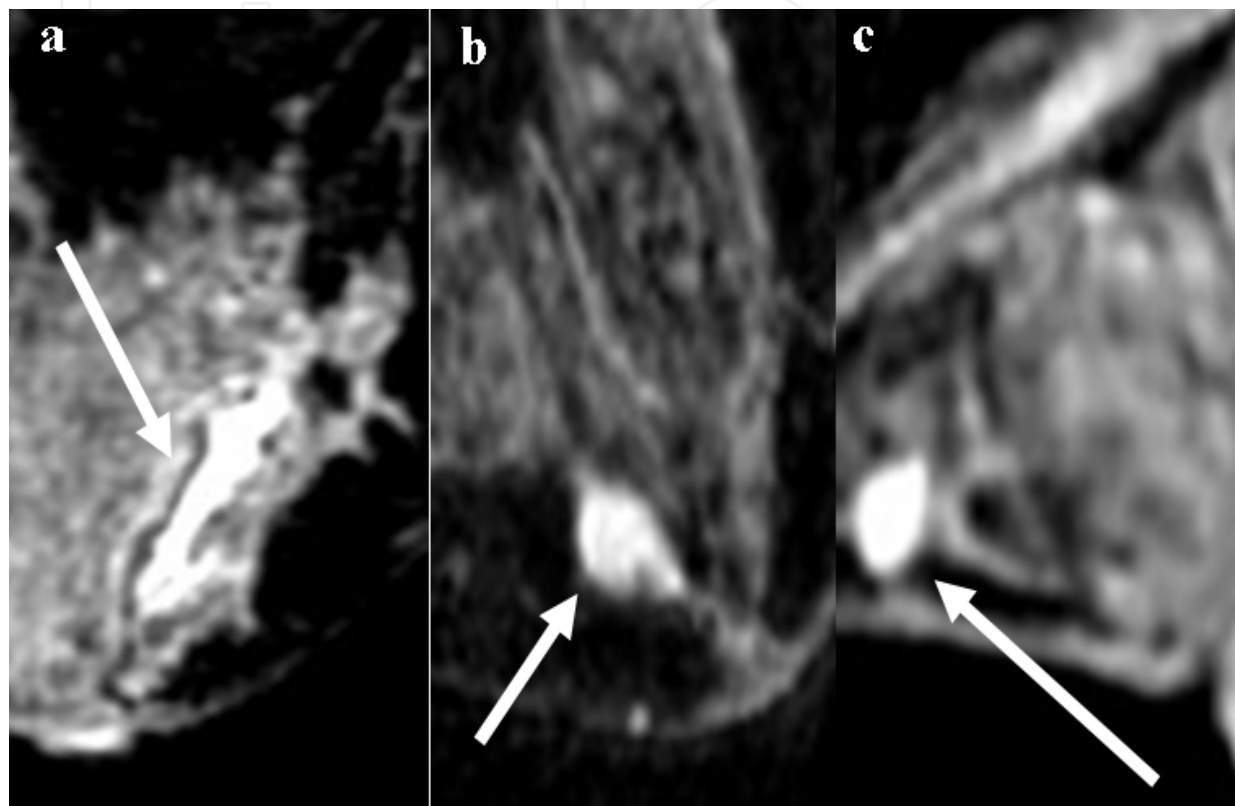


Fig. 18. Three types of non-DCIS lesions, both benign and malignant, under MPR with ductal orientation. (a) MPR shows enhanced thick strip-like intensity with an irregular contour, which spreads along the intraductal structure (arrow) and within the network (intraductal papilloma). (b) MPR shows an enhanced and well-defined smooth nodular lesion with a tadpole morphology, which occupies the intraductal area of the non-dilated side (ductal hyperplasia; arrow). (c) MPR shows a focal lesion with enhancement (arrow), which crosses over the ducts of the surrounding glandular structures and is not continuous with the ductal structures (early focal intraductal carcinoma).

A traditional MRI system can provide coronal, sagittal, and coronal images of the whole breast and is capable of visualizing lesions (Menellet et al., 2005). However, the borders between DCIS and its surrounding benign processes are often indistinguishable, especially when DCIS is sparsely scattered. The actual size, based on the pathologic examination, is also difficult to accurately measure. This is because the anatomy of the breast ducts is distributed in three dimensions, while histological sections are in two dimensions. Measuring scattered and widely distributed DCIS is difficult, which is one possible explanation for the frequent mismatch between MRI and pathologically determined tumor size. In addition, heterogeneous DCIS lesions more often exist alongside benign active tissue or lesions, such as adenosis, sclerosing adenosis, inflammation, and proliferative fibrocystic



changes. Therefore, the image size acquired in DBMRI is usually overestimated and larger than the actual pathological size of the lesion. MPR with a ductal orientation for anatomical localization and 3D demonstration was found to be a useful technique for increasing the detection rate for early stage DCIS. Detection is performed using characteristic findings that include a strip morphology, the spreading along glandular tissue, and a ductogram appearance. Moreover, MPR is excellent for visualizing the anatomical pattern of spreading early intraductal carcinoma which extends towards the nipple. In addition, MPR can show the spatial relationship between the carcinoma and the surrounding breast tissue. These findings should be considered for surgical strategy in segmental resections or partial mastectomy. Breast MRI with MPR for ductal orientation improves the early detection rate and exhibits higher specificity because of improved anatomical interpretation of mammary ducts. However, the existence of adenosis, fibroadenomas, and some specific benign proliferative processes may still interfere with the characteristic pattern of the MRI findings. This can lead to an overestimation of the true size and scope of the distribution (Viehweg et al., 2000). For cases of IDC with a DCIS component, distinguishing the DCIS from the IDC region is difficult. Some pitfalls exist when matching the three-dimensional DCIS distribution with the routine two-dimensional histology sectioning. Using a DBMRI system with Spiral Rodeo pulse sequence, those lesions that could be subtracted in the ESP were almost completely excluded from the possibility of being a malignancy (Figure 6b).

To improve the correlation between image diagnosis of tumor size and pathological size, the pathologist should be notified of the MRI findings, the estimated lesion size, and the mammary ductal orientation before planning sectioning of a specimen that is scheduled for microscopic study. In the future, better integration of radiologists, surgeons, and pathologists to propose working guidelines would create an environment for better correlation of imaging studies and pathology. The accumulation of experience will provide a more accurate estimation of the DCIS volume and improve preoperative image assessment (Mariano et al., 2005; Neubauer et al., 2003).

## **12. Probably benign interpretations of Breast MRI and False positive biopsy results base on MRI interpretation**

Breast MRI is a very sensitive modality for breast lesion, but the specificity for real malignancy is the issue that long been concerned. People may think breast MRI can pick up a lot of things, but these things are not necessarily abnormal. Besides malignant lesions, Breast MRI may also highlight fibrocysts, fibroadenomas, and other benign conditions. Breast MRI reported to have false positive rate, range from 13% to 83% (Hoogerbrugge et al., 2008), which means that it may misdiagnosis for lesions that not cancer. Breast MRI reading radiologists have the responsibility, through restlessly of receiving new MRI knowledge and collecting clinical experience, to achieve higher specificity of tumor differentiation and image diagnosis. By our self assessment in Taipei Medical University hospital, benign lesions reported by pathology accounted for 15.2%, which were initially suspected of being malignancy based on the MRI. In our experience, the pathological results of those false positive MRI interpretations are included atypical ductal hyperplasia, adenosis/apocrine metaplasia, radial scar, sclerosing adenosis, phylloides tumor, infectious mastitis and fat necrosis with hemorrhage.

In both North America and in Asia, the frequency of benign proliferative breast lesions, particularly among women under 40 years of age, is progressively increasing (Schnitt et al.,

1993). Breast neoplasm is a developing disease, and initially the possible risk cannot be precisely determined by a single biopsy result. A study conducted by Liberman et al. demonstrated that 24% of all breast MRI cases studied were interpreted as 'probably benign' in the initial readings. Within seven months, however, nearly 10% of them were subsequently proven to be malignancies (Buadu et al., 1996). One study based on over 120,000 individual cases collected in ten years that received breast biopsies, had been diagnosed as benign disease. However, 50% of the lesions were associated proliferative changes, of which nearly 10% had atypical ductal hyperplasia. Within this latter group, 15% eventually developed invasive carcinoma (London et al., 1992). Atypical hyperplasia and other benign results at the first time of biopsied, is significantly increased risk of breast cancer (London et al., 1992). In another study, about 2% of cases interpreted as probably benign were subsequently identified as malignancies (Liberman et al., 2003).

Accordingly, we cannot negate the possibility to those probably benign lesions or suspected malignant lesions that based on MRI's interpretation that initially proven to be benign (as false positive lesions) may further malignant development, although it is not yet to have a precise predictive percentage value. Thus, of the proven benign cases, it is essential to have long-term imaging follow-up. To our limited knowledge, not able to explain the possible reasons of false positive interpretation of MRI, there is still lack of study on direct biomolecular correlation with MRI images. In the future, we believe that further understanding of tumor transformation will improve our interpretation of dynamically enhanced breast MRI, according to the kinetic curve analysis. This will help in evaluating lesions as well as identifying angiogenesis, microvessel density, and microvascular endothelial permeabilities. The investigation should also include image-pathology correlations of tumor behavior, biological activity, nuclear pleomorphism, mitotic count, and histological grading (Bone et al., 1998; Mussurakis et al., 1997; Narisada et al., 2006; Szabo et al., 2003).

### **13. Screening by DBMRI with breast augmentations**

DBMRI can differentiate breast glandular tissue and pathological lesions from silicone/saline bag implants. It can also better visualize intracapsular rupture of breast implantation. Breast augmentation has become popular among different age groups in Asia, especially in the developed countries. In our breast image center, over 30% of breast MRI candidates have received at least one or two different types of breast implant surgery. Silicon can cause major complications. Silicone compounds primarily consist of fluids, gels, rubbers, sponges, foams, and resins (Ojo-Amaize et al., 1994). Although silicone is relatively inert and biocompatible with biological tissue, it is polymeric, has hydrophobic characteristics, and possesses electrostatic charges. The organic side groups have potentially immunogenic factors, especially over the long-term. Silicone induces inflammatory responses in women with breast implants who have several types of autoantibodies against different self-antigens (Van Gilset et al., 1999). The symptoms and signs of preoperative diagnosis for breast implant rupturing based on physical examination are usually vague, especially when the fibrous capsule encloses the rupture. This situation may become complicated when active inflammation and malignancy are suspected. Image studies are, then, necessary for localization and preoperative differentiation (Scaranelo et al., 2004).

Intense images followed up with sonography may find minor changes in implanted breast pathology. However, in most situations, breast sonography provided no definite way to differentiate benign from malignant conditions. When mammography is arranged, well-trained radiological technicians may help provide good quality pictures as the implantation is being compressed and differentiate the implant from normal breast glandular tissue, in order to detect possible lesions. Poor technique for patients with breast implants are increase the risk of iatrogenic ruptures. In this situation, sonographic guided or mammographic guided biopsy may be indicated. If DBMRI is available, further analysis with noninvasive techniques is preferred before a biopsy is suggested.

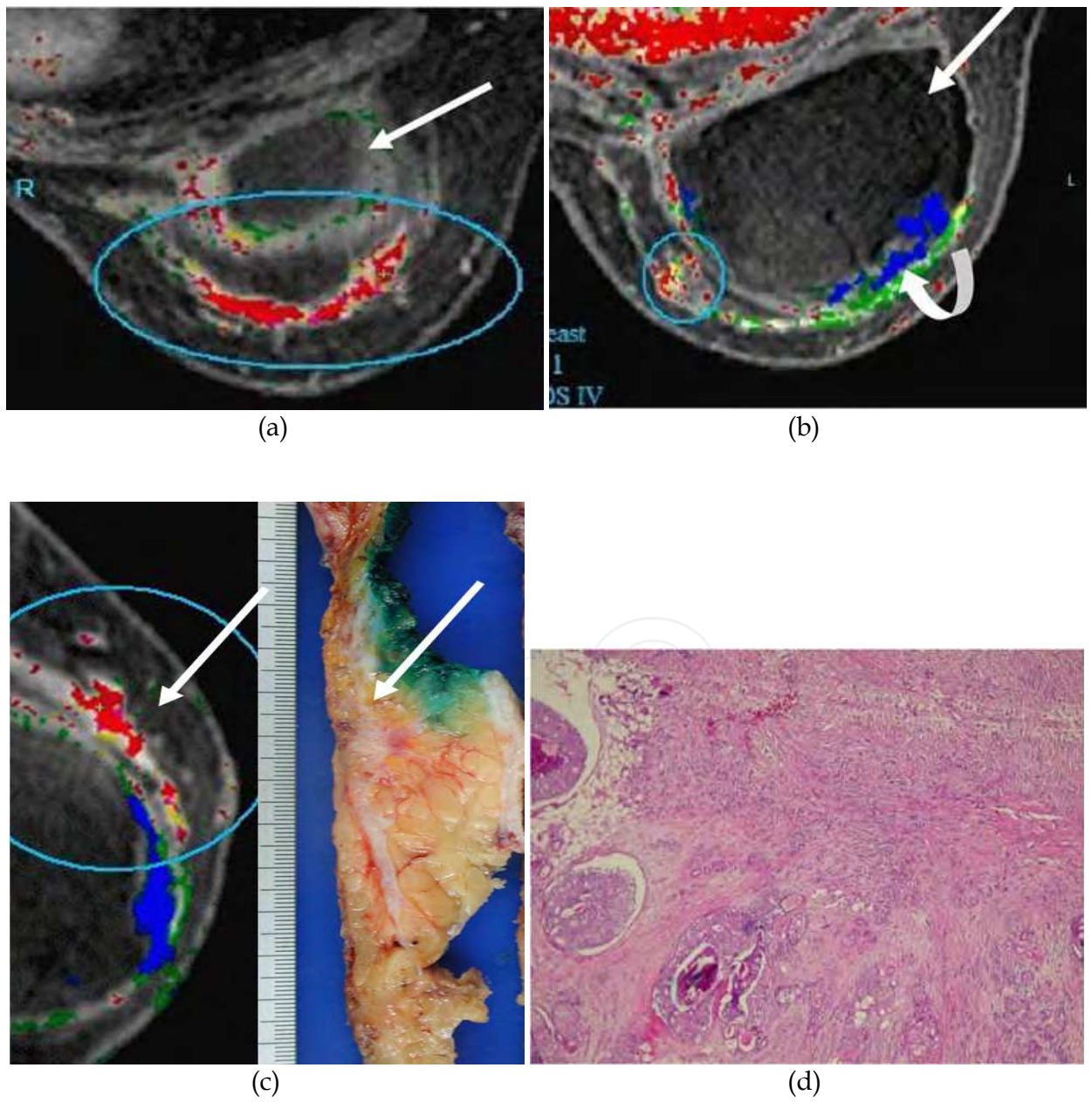
In our center, a breast MRI with a dedicated breast acquisition system was arranged using the Aurora Spiral Rodeo pulse sequence (Figure 19). The Silicone and water Rodeo image mode was adopted to subtract implanted silicone and water bag material as low signal intensity background before and after contrast injection. Post processing of the images could be performed using silicon and water material subtraction techniques followed by the AurorCad 4.0's color mapping display protocol. The same procedure may also apply to other breast augmentation material, such as hyaluronic acid (HA) and an individual's own breast tissue.

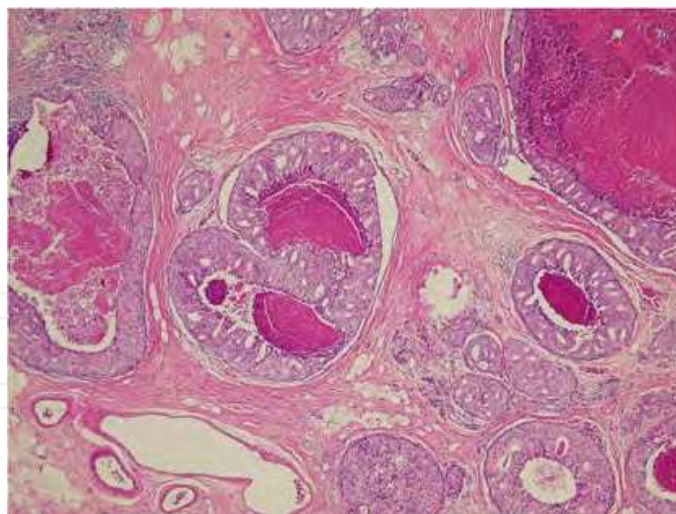
Although it is difficult to identify the malignancies when the rupture of implants was coexisted, MRI is considered the most accurate modality for detecting breast cancer in the presence of silicone (Azavedo & Bone, 1999). The MR images of ruptured implants usually showed low-signal-intensity bands, linguine appearance, and a mass within the gel of the implants, while of malignancies were irregular margin and showed reddish of color mapping. However, free silicone may be hypothesized to induce a foreign body reaction with dense fibrosis and granulomatous formations. In this situation, distinction of inflammation areas and malignancies remains problematic.

In case of rupture, silicone from an implant can leak out into the space around the implant. An intracapsular rupture (silicone contained within the fibrous capsule) can progress to the outside of the, becoming an extracapsular rupture (silicone present outside the fibrous capsule) (Everson et al., 1994). These conditions indicate the need for removal of the implant. Previous study results establish a rupture rate of 8.0 percent at 11 years for silicone breast implants (Hedén et al., 1994). If clinical examination by a skillful surgeon is the only diagnostic tool for identifying implant rupture, it is not reliable, and neither the sensitivity nor the specificity is acceptable (Holmich et al., 2005). Physical examination is inadequate to evaluate a suspected rupture, as experienced plastic surgeons accurately detect only 30% of ruptures in asymptomatic patients, compared to 86% detected by MRI (Hedén et al., 1994). Mammography is a highly sensitive and specific modality for diagnosing extracapsular silicone rupture, and it can detect silicone gel migration through the glandular parenchyma. On the other hand, the diagnosis of intracapsular rupture is difficult to detect via mammography (Gorczyca et al., 1994; Scaranelo et al., 1994). A change in implant shape is the most important mammographic pattern (Gorczyca et al., 1994). Breast sonography has been used in breast implant integrity evaluation for several years. A great variety of sonography signs detect anywhere from 10% to 17% of ruptured implants (Scaranelo et al., 1994). Breast sonography can be the first test in the assessment of breast implants in asymptomatic patients, followed by mammography. This is because breast sonography has greater ability to detect intracapsular rupture than mammography does (Chung et al., 1996;



Harris et al., 1993; Venta et al., 1996). There is limitation for sonogram to rule out extracapsular rupture, but accurate diagnosis requires magnetic resonance imaging (Chung et al., 1996; Harris et al., 1993; Venta et al., 1996). As a result, the FDA has recommended that MRIs be considered for use in screening for silent ruptures starting at three years after implantation, and every two years thereafter (Allergan, 2006; FDA, 2004). The following figures show a special case with initially neither breast sonography nor mammography was able to detect the intracapsular rupture of the implant. Although mammography reveals microcalcifications that might be malignancy, but the final suggestion for surgery is based on MRI images. In our opinion, MRI should be a first-line diagnostic tool for implant rupture when coexisting malignancy is suspected (Paetau et al., 2010) (Figure 19).





(e)

Fig. 19. (a) The breast MRI showed an ill-defined, non-mass enhanced area with red under color mapping, located in the deep superior anterior portion of the left breast (region1); the silicon implantation is showed by white arrow. (b) The breast MRI showed an enhanced focus with heterogenous red and yellow color mapping (marked by blue circle) at about 9 o'clock from the nipple of the left breast (region2); Blue area (by curved arrow) represents intracapsular rupture within the implanted silicon bag (white arrow). (c) The mass (region1) of irregular red and yellow by color mapping (by white arrow) showed by DBMRI is corresponding to the excised specimen and is palpable as firm mass by surgeon (by white arrow). (d) Pathological results revealed a mass of invasive ductal carcinoma (IDC) on the region 1. (e) Pathological results also showed extensive high-grade ductal carcinoma in situ (DCIS) on region 2.

## 14. Reference

- Agarwal, G., Pradeep, P.V., Aggarwal, V., Yip, C.H. & Cheung, P.S. (2007). Spectrum of Breast Cancer in Asian Women. *World Journal of Surgery*, Vol. 31, No. 5, pp. 1031-1040, ISSN 0364-2313.
- Allergan. (2006). *Important Information for Women about Breast Augmentation with INAMED Silicone-Filled Breast Implants*.
- American College of Radiology. (2003). *Breast imaging reporting and data system (BIRADS)*, (fourth ed.), Reston, VA.
- Amr, S.S., Sa'di, A.R., Ilahi, F. & Sheikh, S.S. (1995). The Spectrum of Breast Diseases in Saudi Arab Females: A 26 Year Pathological Survey at Dhahran. *Annals of Saudi Medicine*, Vol. 15, No. 2, pp. 125-132, ISSN 0256-4947.
- Azavedo, E. & Bone, B. (1999). Imaging Breasts with Silicone Implants. *European Radiology*, Vol. 9, No. 2, pp. 349-355.
- Bone, B., Aspelin, P., Bronge, L. & Veress, B. (1998). Contrast-enhanced MR imaging as a prognostic indicator of breast cancer. *Acta Radiologica*, Vol. 39, No. 3, pp. 279-284, ISSN 0284-1851.
- Boyd, N.F., Lockwood, G.A., Byng, J.W., Tritchler, D.L. & Yaffe, M.J. (1998). Mammographic Densities and Breast Cancer Risk. *Cancer Epidemiology, Biomarkers & Prevention*, Vol. 7, pp. 1133-1144.



- Boyd, N.F., Rommens, J.M., Vogt, K., Lee, V., Hopper, J.L., Yaffe, M.J. and Peterson, A.D. (2005). Mammographic Breast Density as an Intermediate Phenotype for Breast Cancer. *Lancet Oncology*, Vol. 6, pp. 798-808, ISSN 1470-2045.
- Buadu, L.D., Murakami, J., Murayama, S., Hashiguchi, N., Sakai, S., Masuda, K., Toyoshima, S., Kuroki, S. & Ohno, S. (1996). Breast Lesions: Correlation of Dynamic Contrast Enhancement Patterns on MR Images with Tumor Angiogenesis. *Radiology*, Vol. 200, No.3, pp. 639-649.
- Chen, C.Y., Tzeng, W.S., Tsai, C.C., Mak, C.W., Chen, C.H. & Chou, M.C. (2008). Adjusting Mammography-Audit Recommendations in a Lower-Incidence Taiwanese Population. *Journal of the American College of Radiology*, Vol. 5, pp. 978-985.
- Chung, K.C., Wilkins, E.G., Beil, R.J., Helvie, M.A., Ikeda, D.M., Oneal, R.M., Forrest, M.E. & Smith, D.J. (1996). Diagnosis of Silicone Gel Breast Implant Rupture by Ultrasonography. *Plastic and Reconstructive Surgery*, Vol. 97, No. 1, pp. 104-109.
- Chuwa, E.W., Yeo, A.W., Koong, H.N., Wong, C.Y., Yong, W.S., Tan, P.H., Ho, J.T., Wong, J.S. & Ho, G.H. (2009). Early Detection of Breast Cancer through Population-Based Mammographic Screening in Asian Women: A Comparison Study between Screen-Detected and Symptomatic Breast Cancers. *The Breast Journal*, Vol. 15, No. 2, pp. 133-139.
- Delille, J.P., Slanetz, P.J., Yeh, E.D., Kopans, D.B. & Garrido, L. (2005). Physiologic Changes in Breast Magnetic Resonance Imaging during the Menstrual Cycle: Perfusion Imaging, Signal Enhancement, and Influence of the T1 Relaxation Time of Breast Tissue. *The Breast Journal*, Vol. 11, No. 4, pp. 236-241.
- Dorrius, M.D., Pijnappel, R.M. & Oudkerk, M. (2009). Breast Magnetic Resonance Imaging as a Problem-Solving Modality? *Imaging Decisions MRI*, Vol. 13, No. 3-4, pp. 126-129.
- Dorrius, M.D., Pijnappel, R.M., Sijens, P.E., van der Weide, M.C. & Oudkerk, M. (2011). The negative predictive value of breast Magnetic Resonance Imaging in noncalcified BIRADS 3 lesions. *European Journal of Radiology*, in press.
- Egan, R.L. & Mosteller, R.C. (1977). Breast Cancer Mammography Patterns. *Cancer*, Vol. 40, pp. 2087-2090.
- Erguvan-Dogan, B., Whitman, G.J., Kushwaha, A.C., Phelps, M.J. & Dempsey, P.J. (2006). BI-RADS-MRI: A Primer. *American Journal of Roentgenology*, Vol. 187, No. 2, pp. W152-W160, ISSN 0361-803X.
- Everson, L.I., Parantainen, H., Detlie, T., Stillman, A.E., Olson, P.N., Landis, G., Foshager, M.C., Cunningham, B. & Griffiths, H.J. (1994). Diagnosis of Breast Implant Rupture: Imaging Findings and Relative Efficacies of Imaging Techniques. *American Journal of Roentgenology*, Vol. 163, No. 1, pp. 57-60, ISSN 0361-803X.
- FDA. (2004). *FDA Breast Implant Consumer Handbook*.
- Gorczyca, D.P., DeBruhl, N.D., Ahn, C.Y., Hoyt, A., Sayre, J.W., Nudell, P., McCombs, M., Shaw, W.W. & Bassett, L.W. (1994). Silicone Breast Implant Ruptures in An animal Model: Comparison of Mammography, MR Imaging, US, And CT. *Radiology*, Vol. 190, No. 1, pp. 227-232.
- Gram, I.T., Funkhouser, E. & Tabar, L. (1997). The Tabar Classification of Mammographic Parenchymal Patterns. *European Journal of Radiology*, Vol. 24, No. 2, pp.131-136.
- Harris, K.M., Ganott, M.A., Shestak, K.C., Losken, H.W. & Tobon, H. (1993). Silicone Implant Rupture: Detection with US. *Radiology*, Vol. 187, No. 3, pp. 761-768.

- Hartman, A.R., Daniel, B.L., Kurian, A.W., Mills, M.A., Nowels, K.W., Dirbas, F.M., Kingham, K.E., Chun, N.M., Herfkens, R.J., Ford, J.M. & Plevritis, S.K. (2004). Breast Magnetic Resonance Image Screening and Ductal Lavage in Women at High Genetic Risk for Breast Carcinoma. *Cancer*, Vol. 100, No. 3, pp. 479-489.
- Hedén, P., Nava, M.B., van Tetering, J.P., Magalon, G., Fourie le, R., Brenner, R.J., Lindsey, L.E., Murphy, D.K. & Walker, P.S. (2006). Prevalence of Rupture in Inamed Silicone Breast Implants. *Plastic and Reconstructive Surgery*, Vol. 118, No. 2, pp. 303-308.
- Holmich, L.R., Fryzek, J.P., Kjoller, K., Breiting, V.B., Jorgensen, A., Krag, C. & McLaughlin, J.K. (2005). The Diagnosis of Silicone Breast-Implant Rupture: Clinical Findings Compared with Findings at Magnetic Resonance Imaging. *Annals of Plastic Surgery*, Vol. 54, No. 6, pp. 583-589.
- Hong Kong Cancer Registry. (2004). *Cancer Registry Annual Report*, Hong Kong SAR: Hong Kong Hospital Authority, Hong Kong.
- Hoogerbrugge, N., Kamm, Y.J., Bult, P., Landsbergen, K.M., Bongers, E.M., Brunner, H.G., Bonenkamp, H.J., de Hullu, J.A., Ligtenberg, M.J. & Boetes, C. (2008). The Impact of a False-Positive MRI on the Choice for Mastectomy in BRCA Mutation Carriers is Limited. *Annals of Oncology*, Vol. 19, No. 4, pp. 655-659.
- Huang, C.S., Chang, K.J. & Shen, C.Y. (2001). Breast Cancer Screening in Taiwan and China. *Breast Disease*, Vol. 13, pp. 41-48.
- Jakes, R.W., Duffy, S.W., Ng, F.C., Gao, F. & Ng, E.N. (2000). Mammographic Parenchymal Patterns and Risk of Breast Cancer at and After a Prevalence Screen in Singaporean Women. *International Journal of Epidemiology*, Vol. 29, No. 1, pp. 11-19, ISSN 0300-5771.
- Kolb, T.M., Lichy, J. & Newhouse, J.H. (2002). Comparison of the Performance of Screening Mammography, Physical Examination, and Breast US and Evaluation of Factors that Influence Them: An Analysis of 27,825 Patient Evaluations. *Radiology*, Vol. 225, No. 1, pp. 165-175.
- Kriege, M., Brekelmans, C., Obdeijn, I., Boetes, C., Zonderland, H., Muller, S., Kok, T., Manoliu, R., Besnard, A., Tilanus-Linthorst, M., Seynaeve, C., Bartels, C., Kaas, R., Meijer, S., Oosterwijk, J., Hoogerbrugge, N., Tollenaar, R., Rutgers, E., Koning, H. & Klijn, J. (2006). Factors Affecting Sensitivity and Specificity of Screening Mammography and MRI in Women with an Inherited Risk for Breast Cancer. *Breast Cancer Research and Treatment*, Vol. 100, No. 1, pp. 109-119.
- Kuhl, C., Weigel, S., Schrading, S., Arand, B., Bieling, H., König, R., Tombach, B., Leutner, C., Rieber-Brambs, A., Nordhoff, D., Heindel, W., Reiser, M. & Schild, H.H. (2010). Prospective multicenter cohort study to refine management recommendations for women at elevated familial risk of breast cancer: the EVA trial. *Journal of Clinical Oncology*, Vol. 28, No. 9, pp. 1450-1457.
- Kuhl, C.K., Mielcareck, P., Klaschik, S., Leutner, C., Wardelmann, E., Gieseke, J. & Schild, H.H. (1999). Dynamic Breast MR Imaging: Are Signal Intensity Time Course Data Useful for Differential Diagnosis of Enhancing Lesions? *Radiology*, Vol. 211, No. 1, pp. 101-110.
- Kwong, A., Cheung, P., Chan, S. & Lau, S. (2008). Breast Cancer in Chinese Women Younger than Age 40: Are They Different from Their Older Counterparts? *World Journal of Surgery*, Vol. 32, No. 12, pp. 2554-2561, ISSN 0364-2313.

- Lee, C.H., Dershaw, D.D., Kopans, D., Evans, P., Monsees, B., Monticciolo, D., Brenner, R.J., Bassett, L., Berg, W., Feig, S., Hendrick, E., Mendelson, E., D'Orsi, C., Sickles, E. & Burhenne, L.W. (2010). Breast Cancer Screening with Imaging: Recommendations from the Society of Breast Imaging and the ACR on the Use of Mammography, Breast MRI, Breast Sonography, and Other Technologies for the Detection of Clinically Occult Breast Cancer. *Journal of the American College of Radiology*, Vol. 7, No. 1, pp. 18-27.
- Lehman, C.D., Gatsonis, C., Kuhl, C.K., Hendrick, R.E., Pisano, E.D., Hanna, L., Peacock, S., Smazal, S.F., Maki, D.D., Julian, T.B., DePeri, E.R., Bluemke, D.A. & Schnall, M.D. (2007). MRI Evaluation of the Contralateral Breast in Women with Recently Diagnosed Breast Cancer. *The New England Journal of Medicine*, Vol. 356, No. 13, pp. 1295-1303.
- Lehman, C.D., Isaacs, C., Schnall, M.D., Pisano, E.D., Ascher, S.M., Weatherall, P.T., Bluemke, D.A., Bowen, D.J., Marcom, P.K., Armstrong, D.K., Domchek, S.M., Tomlinson, G., Skates, S.J. & Gatsonis, C. (2007). Cancer Yield of Mammography, MR, and US in High-Risk Women: Prospective Multi-Institution Breast Cancer Screening Study. *Radiology*, Vol. 244, No. 2, pp. 381-388.
- Leung, G.M., Lam, T.H., Thach, T.Q. & Hedley, A.J. (2002). Will Screening Mammography in the East Do More Harm Than Good? *American Journal of Public Health*, Vol. 92, No. 11, pp. 1841-1846.
- Leung, T.K., Chu, J.S., Huang, P.J., Lee, C.M., Lin, Y.H., Chen, C.S., Tai, C.J. & Wu, C.H. (2010). Breast MRI for Monitoring Images of an 'Adenomyoepithelioma with Malignant Features', Before, During, and After Chemotherapy. *The Breast Journal*, Vol. 16, No. 6, pp. 652-653.
- Leung, T.K., Huang, P.J., Chen, C.S., Lin, Y.H., Wu, C.H. & Lee, C.M. (2010). Is Breast MRI Screening More Effective Than Digital Mammography in Asian Women? *Journal of Experimental & Clinical Medicine*, Vol. 2, No. 5, pp. 245-250.
- Leung, T.K., Huang, P.J., Lee, C.M. & Chen, C.S. Silicone Breast Implant with Intracapsular Rupture Coexisting with Locally Advanced Carcinoma. *The Breast Journal*, in press.
- Leung, T.K., Huang, P.J., Lee, C.M., Chen, C.S., Wu, C.H. & Chao, J.S. (2010). Can Breast Magnetic Resonance Imaging Demonstrate Characteristic Findings of Preoperative Ductal Carcinoma In Situ in Taiwanese Women? *Asian Journal of Surgery*, Vol. 33, No. 3, pp. 143-149.
- Li, A., Wong, C.S., Wong, M.K., Lee, C.M. & Yeung, M.C. (2006). Acute Adverse Reactions to Magnetic Resonance Contrast Media--Gadolinium Chelates. *British Journal of Radiology*, Vol. 79, No. 941, pp. 368-371.
- Lieberman, L., Mason, G., Morris, E.A. & Dershaw, D.D. (2006). Does Size Matter? Positive Predictive Value of MRI-Detected Breast Lesions as a Function of Lesion Size. *American Journal of Roentgenology*, Vol. 186, No. 2, pp. 426-30.
- Lieberman, L., Morris, E.A., Benton, C.L., Abramson, A.F. & Dershaw, D.D. (2003). Probably Benign Lesions at Breast Magnetic Resonance Imaging Preliminary Experience in High-Risk Women. *Cancer*, Vol. 98, No. 2, pp. 377-388.
- London, S.J., Connolly, J.L., Schnitt, S.J. & Colditz GA. (1992). A Prospective Study of Benign Breast Disease and the Risk of Breast Cancer. *Journal of the American Medical Association*, Vol. 267, No. 7, pp. 941-944.

- Mann, R.M., Kuhl, C.K., Kinkel, K. & Boetes, C. (2008). Breast MRI: Guidelines from the European Society of Breast Imaging. *European Radiology*, Vol. 18, No. 7, pp. 1307-18.
- Mariano, M.N., van den Bosch, M.A., Daniel, B.L., Nowels, K.W., Birdwell, R.L., Fong, K.J., Desmond, P.S., Plevritis, S., Stables, L.A., Zakhour, M., Herfkens, R.J. & Ikeda, D.M. (2005). Contrast-enhanced MRI of Ductal Carcinoma *In Situ*: Characteristics of a New Intensity-Modulated Parametric Mapping Technique Correlated with Histopathologic Findings. *Journal of Magnetic Resonance Imaging*, Vol. 22, No. 4, pp. 520-526.
- Maskarinec, G., Menga, L. & Ursin, G. (2001). Ethnic differences in mammographic densities. *International Journal of Epidemiology*, Vol. 30, pp. 959-965, ISSN 0300-5771.
- McCormack, V.A. & dos Santos, S. (2006). Breast Density and Parenchymal Patterns as Markers of Breast Cancer Risk: A Meta-Analysis. *Cancer Epidemiology, Biomarkers & Prevention*, Vol. 15, No. 6, pp. 1159-1169.
- Menell, J.H., Morris, E.A., Dershaw, D.D., Abramson, A.F., Brogi, E. & Liberman, L. (2005). Determination of the Presence and Extent of Pure Ductal Carcinoma in Situ by Mammography and Magnetic Resonance Imaging. *The Breast Journal*, Vol. 11, No. 6, pp. 382-390.
- Morimoto, T., Sasa, M., Yamaguchi, T., Harada, K. & Sagara, Y. (1994). High Detection Rate of Breast Cancer by Mass Screening Using Mammography in Japan. *Japanese Journal of Cancer Research*, Vol. 85, No. 12, pp. 1193-1195.
- Mussurakis, S., Buckley, D.L. & Horsman, A. (1997). Dynamic MR Imaging of Invasive Breast Cancer: Correlation with Tumor Grade and Other Histologic Factors. *British Journal of Radiology*, Vol. 70, No. 833, pp. 446-451, ISSN 0007-1285.
- Nagata, C., Matsubara, T., Fujita, H., Nagao, Y., Shibuya, C., Kashiki, Y. & Shimizu, H. (2005). Mammographic Density and the Risk of Breast Cancer in Japanese Women. *British Journal of Cancer*, Vol. 92, No. 12, pp. 2102-2106.
- Narisada, H., Aoki, T., Sasaguri, T., Hashimoto, H., Konishi, T., Morita, M. & Korogi, Y. (2006). Correlation between Numeric Gadolinium-Enhanced Dynamic MRI Ratios and Prognostic Factors and Histologic Type of Breast Carcinoma. *American Journal of Roentgenology*, Vol. 187, No. 2, pp. 297-306, ISSN 0361-803X.
- Neubauer, H., Li, M., Kuehne-Heid, R., Schneider, A. & Kaiser, W.A. (2003). High Grade and Non-High Grade Ductal Carcinoma *in Situ* on Dynamic MR Mammography: Characteristic Findings for Signal Increase and Morphological Pattern of Enhancement. *British Journal of Radiology*, Vol. 76, No. 901, pp. 3-12.
- Ng, E.H., Ng, F.C., Tan, P.H., Low, S.C., Chiang, G., Tan, K.P., Seow, A., Emmanuel, S., Tan, C.H., Ho, G.H., Ng, L.T. & Wilde, C.C. (1998). Results of Intermediate Measures from A Population-Based, Randomized Trial of Mammographic Screening Prevalence and Detection of Breast Carcinoma Among Asian Women: The Singapore Breast Screening Project. *Cancer*, Vol. 82, No. 8, pp. 1521-1528.
- Ojo-Amaize, E.A., Conte, V., Lin, H.C., Brucker, R.F., Agopian, M.S. & Peter, J.B. (1994). Silicone-Specific Blood Lymphocyte Response in Women with Silicone Breast Implants. *Clinical and Diagnostic Laboratory Immunology*, Vol. 1, No. 6, pp. 689-695.
- Paetau, A.A., McLaughlin, S.A., McNeil, R.B., Sternberg, E., TerKonda, S.P., Waldorf, J.C. & Perdakis, G. (2010). Capsular Contracture and Possible Implant Rupture: Is Magnetic Resonance Imaging Useful? *Plastic and Reconstructive Surgery*, Vol. 125, No. 3, pp. 830-835, ISSN 0032-1052.

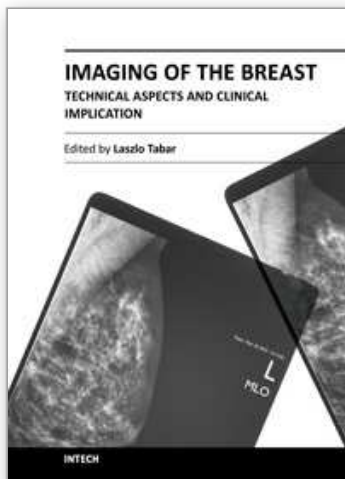


- Plevritis, S.K., Kurian, A.W., Sigal, B.M., Daniel, B.L., Ikeda, D.M., Stockdale, F.E. & Garber, A.M. (2006). Cost-Effectiveness of Screening BRCA1/2 Mutation Carriers with Breast Magnetic Resonance Imaging. *Journal of the American Medical Association*, Vol. 295, No. 20, pp. 2374-2384.
- Ryu, E., Ahn, O., Baek, S.S., Jeon, M.S., Han, S.E., Park, Y.R. & Ham, M.Y. (2008). Predictors of Mammography Uptake in Korean Women Aged 40 Years and Over. *Journal of Advanced Nursing*, Vol. 64, No. 2, pp. 168-175, ISSN 0309-2402.
- Saslow, D., Boetes, C., Burke, W., Harms, S., Leach, M.O., Lehman, C.D., Morris, E., Pisano, E., Schnall, M., Sener, S., Smith, R.A., Warner, E., Yaffe, M., Andrews, K.S. & Russell, C.A. (2007). American Cancer Society guidelines for breast screening with MRI as an adjunct to mammography. American Cancer Society Breast Cancer Advisory Group. *A Cancer Journal for Clinicians*, Vol. 57, No. 2, pp. 75-89.
- Scaranelo, A.M., Marques, A.F., Smialowski, E.B. & Lederman, H.M. (2004). Evaluation of the Rupture of Silicone Breast Implants by Mammography, Ultrasonography and Magnetic Resonance Imaging in Asymptomatic Patients: Correlation with Surgical Findings. *Sao Paulo Medical Journal*, Vol. 122, No. 2, pp. 41-47.
- Scaranelo, A.M., Marques, A.F., Smialowski, E.B. & Lederman, H.M. (2004). Evaluation of the rupture of silicone breast implants by mammography, ultrasonography and magnetic resonance imaging in asymptomatic patients: correlation with surgical findings. *Sao Paulo Medical Journal*, Vol. 122, No. 2, 41-47.
- Schnitt, S.J., Jimi, A. & Kojiro, M. (1993). The Increasing Prevalence of Benign Proliferative Breast Lesions in Japanese Women. *Cancer*, Vol. 71, No. 8, pp. 2528-2531.
- Shen, Y.C., Chang, C.J., Hsu, C., Cheng, C.C., Chiu, C.F. & Cheng, A.L. (2005). Significant Difference in the Trends of Female Breast Cancer Incidence between Taiwanese and Caucasian Americans: Implications from Age-Period-Cohort Analysis. *Cancer Epidemiology, Biomarkers & Prevention*, Vol. 14, No. 8, pp. 1986-1990.
- Shibuya, K., Mathers, C.D., Boschi-Pinto, C., Lopez, A.D. & Murray, C.J. (2002). Global and Regional Estimates of Cancer Mortality and Incidence by Site: II. Results for the Global Burden of Disease 2000. *BMC Cancer*, Vol. 2, No. 37, ISSN 1471-2407.
- Son, B.H., Kwak, B.S., Kim, J.K., Kim, H.J., Hong, S.J., Lee, J.S., Hwang, U.K., Yoon, H.S. & Ahn, S.H. (2006). Changing Patterns in the Clinical Characteristics of Korean Patients with Breast Cancer during the Last 15 Years. *Archives of Surgery*, Vol. 141, No. 2, pp. 155-160.
- Szabo, B.K., Aspelin, P., Kristoffersen, W.M., Tot, T. & Boné, B. (2003). Invasive breast cancer: correlation of dynamic MR features with prognostic factors. *European Radiology*, Vol. 13, No. 11, pp. 2425-2435.
- Thompson, J., Leach, M.O., Kwan-Lim, G., Gayther, S.A., Ramus, S.J., Warsi, I., Lennard, F., Khazen, M., Bryant, E., Reed, S., Boggis, C.R., Evans, D.G., Eeles, R.A., Easton, D.F. & Warren, R.M. (2009). Assessing the Usefulness of a Novel Mribased Breast Density Estimation Algorithm in a Cohort of Women at High Genetic Risk of Breast Cancer: The UK MARIBS Study. *Breast Cancer Research*, Vol. 11, No. 6, pp. R80.
- Tseng, M., Byrne, C., Evers, K.A., London, W.T., Daly, M.B. (2006). Acculturation and Breast Density in Foreign-Born, U.S. Chinese Women. *Cancer Epidemiology, Biomarkers & Prevention*, Vol. 15, No. 7, pp. 1301-1305.



- Uchida, K., Yamashita, A., Kawase, K. & Kamiya, K. (2008). Screening Ultrasonography Revealed 15% of Mammographically Occult Breast Cancers. *Breast Cancer*, Vol. 15, No. 2, pp. 165-168.
- Van Gils, C.H., Otten, J.D., Hendriks, J.H., Holland, R., Straatman, H. & Verbeek, A.L.M. (1999). High Mammographic Breast Density and Its Implications for the Early Detection of Breast Cancer. *Journal of Medical Screening*, Vol. 6, pp. 200-204, ISSN 0969-1413.
- Venta, L.A., Salomon, C.G., Flisak, M.E., Venta, E.R., Izquierdo, R. & Angelats, J. (1996). Sonographic Signs of Breast Implant Rupture. *American Journal of Roentgenology*, Vol. 166, No. 6, pp. 1413-1419, ISSN 0361-803X.
- Viehweg, P., Lampe, D., Buchmann, J. & Heywang-Köbrunner, S.H. (2000). In Situ and Minimally Invasive Breast Cancer: Morphologic and Kinetic Features on Contrast-Enhanced MR Imaging. *Magnetic Resonance Materials in Physics, Biology and Medicine*, Vol. 11, No. 3, pp. 129-137.

IntechOpen



## **Imaging of the Breast - Technical Aspects and Clinical Implication**

Edited by Dr. Laszlo Tabar

ISBN 978-953-51-0284-7

Hard cover, 224 pages

**Publisher** InTech

**Published online** 16, March, 2012

**Published in print edition** March, 2012

Early detection of breast cancer combined with targeted therapy offers the best outcome for breast cancer patients. This volume deal with a wide range of new technical innovations for improving breast cancer detection, diagnosis and therapy. There is a special focus on improvements in mammographic image quality, image analysis, magnetic resonance imaging of the breast and molecular imaging. A chapter on targeted therapy explores the option of less radical postoperative therapy for women with early, screen-detected breast cancers.

### **How to reference**

In order to correctly reference this scholarly work, feel free to copy and paste the following:

Ting Kai Leung (2012). The Application of Breast MRI on Asian Women (Dense Breast Pattern), Imaging of the Breast - Technical Aspects and Clinical Implication, Dr. Laszlo Tabar (Ed.), ISBN: 978-953-51-0284-7, InTech, Available from: <http://www.intechopen.com/books/imaging-of-the-breast-technical-aspects-and-clinical-implication/the-application-of-breast-mri-on-asian-women-dense-breast-pattern->

**INTECH**  
open science | open minds

### **InTech Europe**

University Campus STeP Ri  
Slavka Krautzeka 83/A  
51000 Rijeka, Croatia  
Phone: +385 (51) 770 447  
Fax: +385 (51) 686 166  
[www.intechopen.com](http://www.intechopen.com)

### **InTech China**

Unit 405, Office Block, Hotel Equatorial Shanghai  
No.65, Yan An Road (West), Shanghai, 200040, China  
中国上海市延安西路65号上海国际贵都大饭店办公楼405单元  
Phone: +86-21-62489820  
Fax: +86-21-62489821

© 2012 The Author(s). Licensee IntechOpen. This is an open access article distributed under the terms of the [Creative Commons Attribution 3.0 License](https://creativecommons.org/licenses/by/3.0/), which permits unrestricted use, distribution, and reproduction in any medium, provided the original work is properly cited.

IntechOpen

IntechOpen