

# We are IntechOpen, the world's leading publisher of Open Access books Built by scientists, for scientists

6,900

Open access books available

186,000

International authors and editors

200M

Downloads

Our authors are among the

154

Countries delivered to

TOP 1%

most cited scientists

12.2%

Contributors from top 500 universities



WEB OF SCIENCE™

Selection of our books indexed in the Book Citation Index  
in Web of Science™ Core Collection (BKCI)

Interested in publishing with us?  
Contact [book.department@intechopen.com](mailto:book.department@intechopen.com)

Numbers displayed above are based on latest data collected.  
For more information visit [www.intechopen.com](http://www.intechopen.com)



# Cryopreserved Musculoskeletal Tissue Bank in Dentistry: State of the Art and Perspectives

Luiz Augusto U. Santos<sup>1</sup>, Alberto T. Croci<sup>2</sup>, Nilson Roberto Armentano<sup>3</sup>,  
Zeffer Gueno de Oliveira<sup>4</sup>, Arlete M.M. Giovani<sup>5</sup>,  
Ana Cristina Ferreira Bassit<sup>6</sup>, Graziela Guidoni Maragni<sup>7</sup>,  
Thais Queiróz Santolin<sup>7</sup> and Lucas da Silva C. Pereira<sup>8</sup>

## 1. Introduction

Maxillary and mandibular bone loss has long been a challenge to dental surgeons who seek to reconstruct these lost segments. These lesions lead to deformation of some maxillary and mandibular areas which interferes in the functional rehabilitation process of these structures. The most common cause of these lesions is prolonged use of total prostheses in a large part of the Brazilian population and the searches for surgical techniques and bone substitutes are today proposed and studied by the academic class. In this context, Brazil is starting to distribute allogeneic tissue obtained, processed and qualified by musculoskeletal tissue banks. Such banks already have experience in dispensing tissue to the orthopedic area, which has been using reconstructive techniques with allografts for many years. The first studies proposing the use of bone substitutes for replacement of these faulty parts commenced in the decades subsequent to 1860. (Carrel, 1912; Groves, 1917; Sharrard, Collins, 1961; Urist, 1965; Fischer, 1998; Tomford, 2000).

After the verification of the disadvantages in the use of autologous tissues for this purpose, such as the increase in donor morbidity, greater risk of nerve lesion and of infection inherent to the second surgical procedure and limitation in the availability of the tissue in quantity and variety, the use of homologous tissue became another option that was gradually indicated (Cunningham, Reddi, 1992; Tomford, 2000).

---

<sup>1</sup>Institute of Orthopedics and Traumatology, Hospital das Clínicas of the School of Medicine of the University of Sao Paulo, dentist, Tissue Bank Technical Responsible and. Sao Paulo/SP, Brazil

<sup>2</sup>Institute of Orthopedics and Traumatology, Hospital das Clínicas of the University of São Paulo school of Medicine, Professor and Tissue Bank Director - Sao Paulo/SP, Brazil

<sup>3</sup>School of Dentistry of the University of Santo Amaro- São Paulo, Brazil

<sup>4</sup>Orthopedic Nurse Specialist. São Paulo/SP, Brazil

<sup>5</sup>Nurse, Institute of Orthopedics and Traumatology, Hospital das Clínicas of the University of São Paulo school of Medicine, Tissue Bank Coordinator - São Paulo/SP, Brazil

<sup>6</sup>Veterinarian, Tissue Bank Researcher, University of Florida, Gainesville, FL – Flórida- US

<sup>7</sup>Nurse, Institute of Orthopedics and Traumatology, Hospital das Clínicas of the University of São Paulo school of Medicine, Tissue Bank Team - São Paulo/SP, Brazil

<sup>8</sup>Dental Student, Institute of Orthopedics and Traumatology, Hospital das Clínicas of the University of São Paulo school of Medicine, Tissue Bank Team - São Paulo/SP, Brazil

The good results with the clinical application of allografts in dentistry motivate their use on an increasing scale, until in 2005 Dentistry came into the scene with the use of tissues in maxillary and mandibular pre-prosthetic surgery. A consensus between the National Transplant System and the Federal Board of Dentistry allows the use of allografts by specialists in the areas of Implant Dentistry, Periodontics and Oral and Maxillofacial. The tissue banks, in turn, prepare a tissue processing line geared toward dental needs with a focus on quality control and traceability.

Thus usage has become both abrupt and a tendency in the last 5 years (RBT, 2006-2010). In spite of a significant number of bone transplants in the dental area with good clinical results, the dental profession is still lacking information about activities that involve the area of tissue banks, particularly in the rigid quality control and traceability. Such activities are founded on international standards<sup>2</sup>, literature<sup>3</sup> and legislation<sup>4</sup> and implemented according to Good Manufacturing Practice- GMP.

We consider it very important to gather epidemiological data on bone transplants in dentistry, elucidating the size and the limits of this type of treatment that is already considered a tendency in our field. In addition, to report on our perspectives of investigation into the efficacy and safety of the use of allografts, with tests that can enable us to expand our knowledge about the osseointegration of allografts. In other words, knowledge that allows us to reach what we consider most important in dental treatments: the predictability of treatment.

## 2. Bone tissue

Bone tissue is composed of two portions: 1. Organic, consisting of intrinsic bone cells (osteoblasts, osteoclasts and osteocytes) and the organic matrix synthesized thereby; 2. Inorganic, consisting of hydroxyapatite, deposited amorphously in an initial phase and that in a short space of time is converted into another crystalline hydroxyapatite. Organic matrix corresponds to 35% of the bone volume and inorganic matrix to 65%.

In spite of the resistance and hardness, bone tissue is very plastic and has a high capacity to remodel through various situations to which it is submitted, such as fractures, lesions and bone loss. The bone tissue regeneration process starts from important biological reactions, triggered by the actual tissue lesion. Grafting triggers a mechanism of migration of the bone cells belonging to the receptor bed to the inside of the graft, with the purpose of resorbing it and replacing it with neoformed bone.

---

<sup>2</sup>European Association of Tissue Banks. Common Standards for Tissues and Cells Banking: Berlin: European Association of Tissue Banks; 2004.

American Association of Tissue Banks. Standards for Tissue Banking. 11th ed. McLean : American Association of Tissue Banks; 2007

<sup>3</sup>Phillips GO, Strong DM, Versen RV, Nather A. Advances in Tissue Banking. Vol. 4. World Scientific . New Jersey, 2000.

Bancroft JD, Stevens A. Theory and practice of histological techniques. Fourth Edition. Churchill Livingstone. United Kingdom, 1999.

<sup>4</sup>Law n.9434 of February 5, 1997; Decree n.2268 of June 30, 1997;Administrative Ruling n.1686 of September 20, 2002; Resolution n. 220 of December 27, 2006; Administrative Ruling n. 2600 of October 21, 2009.

The cells belonging to the bone tissue are the osteoblasts, osteocytes and osteoclasts.

The osteoblasts are cuboid, elongated cells of mesenchymal origin that are located in the bone margins; their function is to produce the organic matrix of the bone tissue. In reduced activity these cells assume a more slender shape. The osteocytes are encapsulated osteoblasts, which after maturation became imprisoned inside the mineralized matrix, but that still maintain contact with other cells through cytoplasmic ramifications, thus maintaining physiologic functionality of the tissue (Junqueira, Carneiro, 1999; Davies 2000). This contact with surface cells such as the osteoblasts and lining cells is related bone structure maintenance and to the physiological responses that lead to tissue formation or resorption (Aubin et al., 2006).

The osteoclasts are giant cells with multiple nuclei and their function is related to resorption. In synergy with the osteoblasts they promote bone remodeling.

The interaction and the synergism among bone cells is called creeping substitution, and this occurs through three essential cellular events: osteogenesis (cellular event that favors the synthesis of bone matrix by the osteoblasts), osteoinduction (ability to induce the migration of mesenchymal cells and their differentiation into osteoblasts) and osteoconduction (ability of the tissue to serve as a mold or guide for the cellular processes involved in bone tissue repair).

Moreover, as is the case with others, the bone cells pass through the stages of the cell cycle, which range from formation to cell division (mitosis). Mitosis is susceptible to external interferences, and the cell can either enter a state of rest or continue to split cyclically (Urist, 1965; Enneking et al., 1975; Junqueira, Carneiro, 1999; Perren, Claes, 2002).

3. Bone transplantation

The term transplant is not widely used by the dental community to refer to the use of bone tissue. The common term is bone grafting. The bone graft can receive a nomenclature and be classified according to the origin of its obtainment and on the implant site (Table 1).

Autologous graft or autograft	Graft of tissue from one site to another in the same individual
Isograft	Graft between people with the same genotype (homozygotes; e.g. identical twins)
Allograft or homologous graft	Graft between individuals of the same species with disparate genotype
Xenograft or heterologous graft	Graft from one individual of a species onto a different species

Table 1. Classification of grafts according to their nature. Source: Drumond, 2000

4. Clinical application of grafts over the years

The use of bone tissue for replacement of bone losses is not a recent procedure. Since last century there have been accounts of the use of these tissues in humans and in experiments with animals as a means of assessing their efficacy.

In these studies, many treatments with the use of bone grafts of autologous and homologous nature have been proposed over the years. The first homologous bone transplant is described by William MacEwen in 1878 (Giovani, 2005). At this time the treatment of osteomyelitis was performed by means of surgical resections of the infected segments. Homologous tibial segments (obtained from patients submitted to osteotomies) were used in the reconstruction of a bone defect caused by the resection of part of the humerus of a young man suffering from osteomyelitis (Tomford, 2000). Encouraging results of the consolidation of the bone graft with the receptor bed (MacEwen, 1909) motivated researchers back then. In this period, there was no consensus about which bones can specifically be used for transplantation. Tissues were obtained randomly from donors that were victims of fractures, resections and amputations. For the storage and processing of these tissues, professionals used protocols and equipment that today are not the best suited to this purpose (Tomford, Mankin, 1999; Tomford, 2000). Nowadays a large portion of these studies has only historical value with respect to the pioneer spirit of these researchers.

The clinical use of allografts during this period was in low demand, and occurred on an experimental basis at some centers from all around the world. With the availability of antibiotic therapy, changes occurred in the indication of these tissues, and patients with osteomyelitis were then submitted to pharmacological treatments, to the detriment of surgical procedures (Tomford, 2000). Thus surgical resections of infected segments cease to be a priority, and allografts are then used in the reconstructions of bone defects caused by tumor resections. This change causes the studies from the time to evolve as well, and to give more detailed accounts of the cellular processes involved in the osseointegration of grafts. The consensuses of these first studies serve as guidelines for the first grafts performed at that time.

The use of cryopreserved allografts presents some advantages over autologous tissue, such as the availability of the necessary quantity of tissue and a decrease in postoperative morbidity. As regards morphology, there are some differences in the vascularization process of the cortical and spongy bone grafts. In the cortical bone, the repair is started by the action of osteoclasts and in the spongy bone, by the osteoblasts. Another difference lies in the revascularization time, which is slower for cortical bone and faster for spongy bone.

At that time, Urist (1965) was already describing that the osteoprogenitor cells responsible for the bone repair process are derived from monocytes, present in an elevated number in the repair zone coming from the bone marrow, and that the osseointegration of grafts is achieved, since primitive cells not yet differentiated can differentiate into viable osteoblasts from osteoinductive substances. Perivascular mesenchymal cells disaggregate and migrate to the grafting area, where they reaggregate, proliferate and differentiate to form new bone. (Urist et al, 1983)

Some substances secreted by certain cell types interfere in or even modulate the cellular processes of osseointegration, today known as Cytokines or growth factors.

Urist made important discoveries in this area back in 1965, even proposing a new bone processing procedure aimed at the removal of a calcified layer (demineralization) from the matrix, making this graft more osteoinductive. At the time this kind of tissue was called Demineralized Bone Matrix (DBM), and the name is still in use today. Later, it was

understood that part of this capacity is the responsibility of the superfamilies of proteins (TGF), including the morphogenetic protein (BMP) present in the bone matrix. (Malafaya et al, 2002).

The decade of 1980 was marked by the advent of the acquired immunodeficiency syndrome (AIDS) that gives rise to discussions on the safety of the clinical use of homologous tissues. The biological risk of disease transmission between tissue donors and recipients is the topic of greatest relevance and importance in the period. The tissue banks existing at that time were encouraged to review donor selection protocols with the objective of avoiding the transmission of these diseases. This encouragement was provided mainly by the international public health regulatory agencies, such as the FDA (Food and Drug Administration) and other institutions related to the Haemovigilance and tissue transplantation systems. The result was a standardization of the internal processes of banks with respective preparation of standards by the main global tissue bank associations (American Associating of Tissue Banks - AATB and European Association of Tissue Banks-EATB), which contributes to the gain of quality of tissue made available by these services (Nather, 1991; Galea, Kearney, 2005; Santos, 2007).

With the availability of more reliable grafts by the tissue banks, their use, biological behavior and indication by surgeons become a viable treatment option. (Santos, 2011).

Similar to the repair process in fractures and in the development of the musculoskeletal system, the osseointegration of grafts takes place after a selection of primordial cells that are differentiated into osteoblasts under the influence of osteogenic factors. (Thies et al., 1992). The main objective expected in the use of grafts is the ability to selectively induce the primordial events of the integration process, such as osteoinduction, osteoconduction and osteogenesis (Lindhe et al., 1997).

According to Tomford and Mankin (1999), for cortical bone grafts to be incorporated into the receptor bed, there must be revascularization of this bed. When this process does not occur, the repair area loses balance in resorption and the graft might suffer fatigue fractures. Spongy grafts are consolidated more quickly.

Boldt et al. (2001) evaluate the use of frozen bone graft in 173 acetabular reconstructions and 79 femoral reconstructions in humans. Femoral heads obtained from a local bone bank are particulated and impacted in the faults. After a mean follow-up period of four years, they report acetabular clinical stability in 97.2 % of the cases, graft incorporation in 74% in the acetabula and 61% in the femurs, according to radiological analysis. They conclude that the results obtained with the use of impacted grafts are promising, except for the reconstruction of type III acetabular defects, where a reinforcement cage is recommended.

Janssen et al. (2001) studied the use of homologous cortical rings obtained from femoral diaphysis for reconstruction of intervertebral discs of the lumbar spine in 137 patients. The results show that arthrodesis was achieved in 94% of the cases and they do not report signs of resorption.

Weyts et al. (2003) analyze samples of femoral heads collected after the primary arthroplasty of two human donors. The tissues are cryopreserved at - 80 °C for a minimum period of six months, according to the protocols of the American and European Tissue Bank Associations. After this period, these tissues are biopsied and submitted to cell culture (for survival observation) and PCR (polymerase chain reaction) for genetic screening. The results show the presence of live cells belonging to the donors in the analyzed samples.

Lavernia et al. (2004) researched the adoption and use of allografts by orthopedic surgeons in 340 U.S. hospitals. The frozen graft from tissue banks certified by the American Association of Tissue Banks - AATB is used the most often by orthopedists for the treatment of knee and hip bone loss.

Schreurs et al. (2005) conduct a study to evaluate the use of homologous bone graft from a tissue bank in the reconstruction of 33 femoral defects. Bone graft impaction precedes the fixation of the femoral nail. After a minimum follow-up of eight years there is functional improvement of the joint according to the Harris hip score (from 49 to 85 points from pre- to postoperative period) and good survival according to the Kaplan-Meier method. Although four patients have had femoral fractures, the authors conclude that the graft impaction technique and use of cemented femoral nail results in excellent survival for eight to thirteen years.

Cabrita (2007) studies the treatment of infected hip arthroplasties with and without the use of the antibiotic-impregnated cement spacer. For the reconstruction of bone stock, Cabrita uses the massive particulated homologous graft in 60.9% of the patients treated and does not report complications related to their use.

In a review of concepts, Giannoudis et al. (2005) emphasize the advantages of the use of bone grafts in the area of orthopedics and traumatology. They describe the cellular events present in literature that involves the osseointegration process of autologous, homologous grafts and of biocompatible synthetic substitutes. They stress the osteoinductive characteristic of fresh grafts and the osteoconductive characteristic of frozen and lyophilized grafts. Heyligers and Kleim (2005) verify the presence of live cells with growth potential in samples of femoral heads cryopreserved at - 80 °C, over a minimum period of six months. The authors stress the importance of discussing the osteoconductive potential of grafts and highlight the need to investigate the role of these surviving cells from the frozen tissue in the bone formation process after its implantation. Besides the bone cells, other cells and inflammatory factors play a vital role in the bone repair process. The macrophages and substances such as interleukin one, six, eleven (IL-1, IL-6, IL-11), RANKL and osteoprotegerin (OPG) are found during the first three days after the lesion (Gerstenfeld, Einhorn, 2006). As far as macrophages are concerned, Knighton et al. (1982) explain that these cells are present in the repair zone and are capable of producing growth factors, which, in turn, stimulate the neovascularization, proliferation and migration of other cell types, such as the fibroblasts.

## 5. Evolution of musculoskeletal tissue banks in Brazil

Considering the satisfactory results in the use of allografts obtained from multiple donors of organs and tissues with brain death besides studies showing revascularization, osteointegration and bone formation at sites of graft (Barros Filho, et al., 1989; Croci et al., 2003, Zhang et al., 2004; Dallari et al., 2006, Bitar et al, 2010), an increasing number of orthopedic surgeons and dentists currently opt to use of homologous grafts in our country. This fact is corroborated by the disadvantages already known in the use of autologous tissues, such as the increase in postoperative morbidity, greater risk of infection inherent to the second surgical procedure required for their obtainment, risk of nerve lesion and

limitation of the quantity and variety of graft obtained (Smith et al. 1984; Cunningham, Reddi, 1992; Drumond, 2000).

This tendency, combined with the growing number of patients with bone loss that seek specialized orthopedic and dental services, leverages the creation of some Tissue Banks in the country in an experimental manner.

In Brazil, the standardization of Musculoskeletal Tissue Banks is linked to specific laws of our country. We have a General Coordination Office for the National Transplant System – SNT of the Ministry of Health that discusses and prepares, together with technical chambers, legislations involving the use of tissue by the medical and dental community. The guidelines are based on protocols already developed by some centers and on the standards of international associations (European Association of Tissue Banks - EATB and American Association of Tissue Banks-AATB). The creation of the first reference centers in the large-scale capture, processing and distribution of musculoskeletal tissue and some of these experiences are described. (Amatuzzi et al., 2000, Amatuzzi et al., 2004). Tissue Banks in Brazil are controlled by the General Management of Blood, other Tissues, Cells and Organs - GGSTO of the National Health Surveillance Agency - ANVISA, an institution similar to the U.S. FDA. This agency focuses its activities on health surveillance and on quality control, traceability, appraisal of risks and of adverse effects involving tissue transplants in the country and its guidelines are published in the form of legislation<sup>5</sup> that also defines Musculoskeletal Tissue Bank as “the service that, with physical facilities, equipment, human resources and adequate techniques, has as its duties the performance of clinical, laboratory and serological triage of tissue donors, the removal, identification, transportation, processing, storage and delivery of bones, soft tissues (cartilage, fasciae, serous membranes, muscle tissue, ligaments and tendons) and their derivatives, of human origin for therapeutic purposes, research and teaching”.

## 6. Activities of a musculoskeletal tissue bank

The description of activities of a musculoskeletal tissue bank is summarized in the algorithm below ( **Illustration 01**).

Every activity related to the bank should also be based on the ethical principles inherent to the activities of any organ transplantation. They are:

- **Autonomy and self-determination:** The recipient of tissue from the musculoskeletal system should be provided with information in accessible language about the entire tissue obtainment process, the risks and the chances of success or failure of the treatment. The following stage is the patient's decision, after their evaluation of the information received, set out in an informed consent form. Professionals with specific training provide all the required information, using language exempt from complex or technical terms, enabling the patient to achieve easy understand in order to make the final decision. For this document to be authentic, the consent must be free, that is, not caused by coercion. The professionals of a musculoskeletal tissue bank should be objective and impartial while providing guidance to recipients. Every process is recorded in the Recipient's Form.

---

<sup>5</sup>Administrative Ruling no. 211, of March 24, 2003

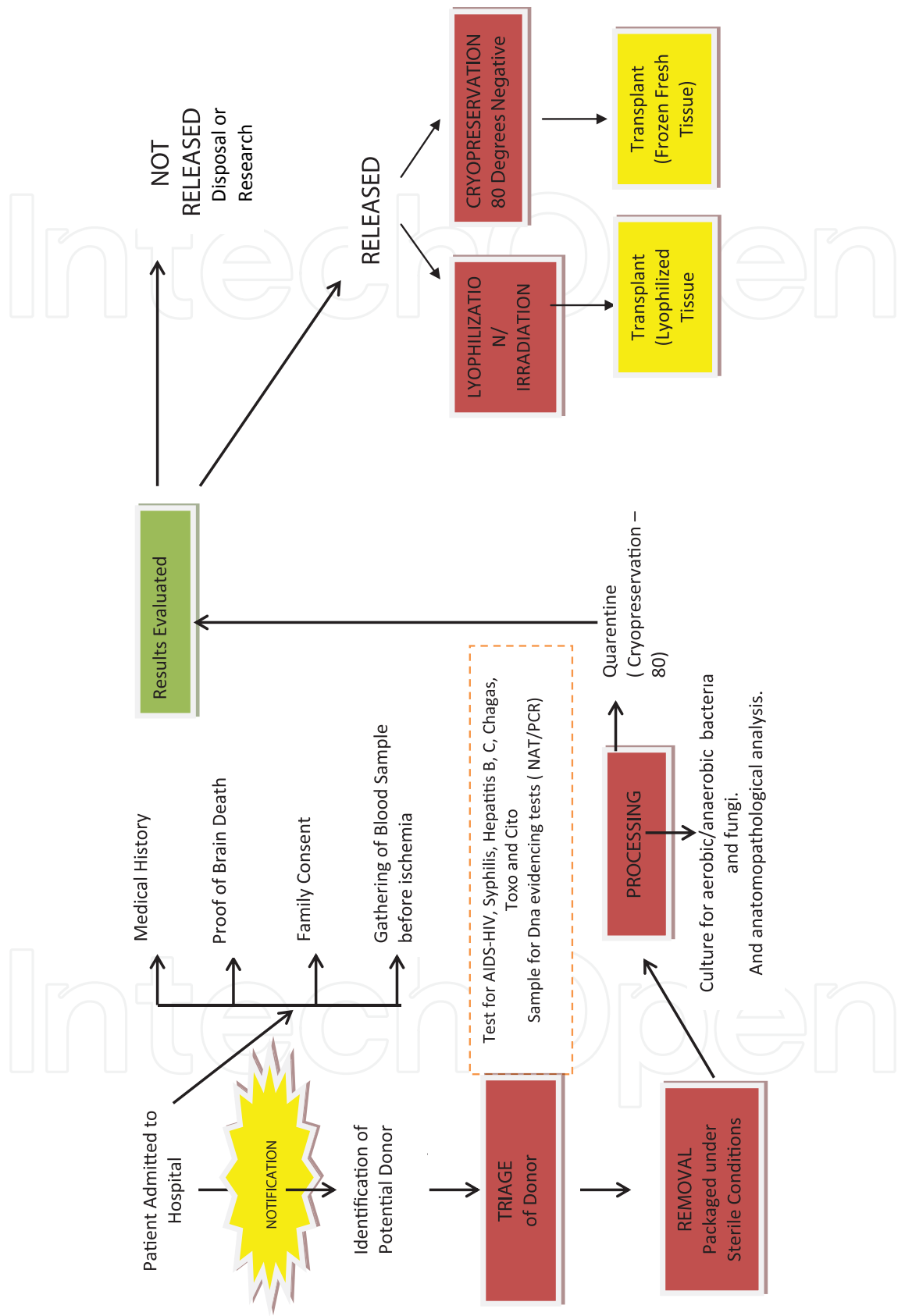


Illustration 01. Algorithm of the Musculoskeletal Tissue Donation and Transplantation Process

- **Justice** – The principle of equal opportunities for the use of available tissues. The definition of ethical parameters in distribution is imperative.
- **Symbolism of the body** – This principle is employed mainly in the reconstruction of the deceased donor's body after removal, which should be performed carefully, with the apparent anatomical parameters respected, thus ensuring that the family receives a body in adequate conditions.

## 7. Obtaining musculoskeletal tissues

The main source of musculoskeletal tissues is the notification of deceased donors to the Transplant Centers, Organ Service Services, and Hospital Transplant Departments. The teams that receive the organs and tissues are only notified after a series of procedures and exams has been carried out to ascertain brain death and obtain the family's consent for the process of organ and tissue donation. Brain death is initially verified by a neurologist, using techniques of physical and imaging (doppler) exams, which are repeated after six hours in the presence of a family member of the potential donor. Once there is no doubt as to the irreversible diagnosis of brain death, the family members are asked whether they would consider donating their loved one's organs. The family interview is done by trained members belonging to an intra-hospital committee, or by an organization that looks for organs. The entire donation process should be recorded and legally signed before the teams are notified to remove each organ (heart, liver, kidney, pancreas, lung, intestine) and tissues (osteocondral and fascial-ligamentous, skin, vessels, cornea, heart valves). Each team should have clearly-defined criteria for selecting, and at the time of notification, accepting or refusing the donor in question.

For donors of musculoskeletal tissue, the selection follows a rigorous control process, with serological tests for antigens and HIV antibodies, Hepatitis A, B and C, HTLV-1 and 2, Syphilis, Chagas disease, Toxoplasmosis and Cytomegalovirus, as well as state-of-the-art tests for evidenciation of D (Nucleic Acid Amplification – NAT) HIV and Hepatitis B and C, bone marrow aspirate smear of the sternum and iliac crest sample, both for histopathological investigation.

Donors with the following criteria were excluded: orthopedic pathologies, such as osteoporosis, osteonecrosis, rheumatoid arthritis, lupus erythematosus, neoplasias, age group that compromises that characteristics of the tissues, blood transfusions, tattoos or piercings within the period of the immunological window, use of illegal drugs, travel to endemic zones, generalized or localized infections, fractures, open sores on the limbs from which the musculoskeletal tissues are to be removed, or any other situation that places in doubt the quality of these tissues, pursuant to the Brazilian legislation.

The whole procedure is carried out in totally antiseptic conditions, just as in surgery. Special gowns made from synthetic material are used, and all the surgical stages of antiseptis are followed.

The removed tissues are immediately packaged in triple packaging, hermetically sealed, and delivered, under refrigeration ( $-4^{\circ}\text{C}$ ) to the Tissue Bank.

A very important stage of the capture process is donor reconstruction. The body should be delivered to the family free from any deformation and as close as possible to its appearance before the tissue removal. This is because the fear of deformation has been one of the main

causes of refusals of bone donation by the family. For a perfect reconstruction the professionals use prostheses especially developed for this purpose, plaster, sutured and gauze. (**Illustration 02**). This rigorous reconstruction is the most laborious stage in the removal procedure. Areas possibly visible during the funeral (face, anterior side of arm, anterior side of shoulder, etc.) are not approached. All the anatomical parameters are respected, and therefore donor deformation does not occur.

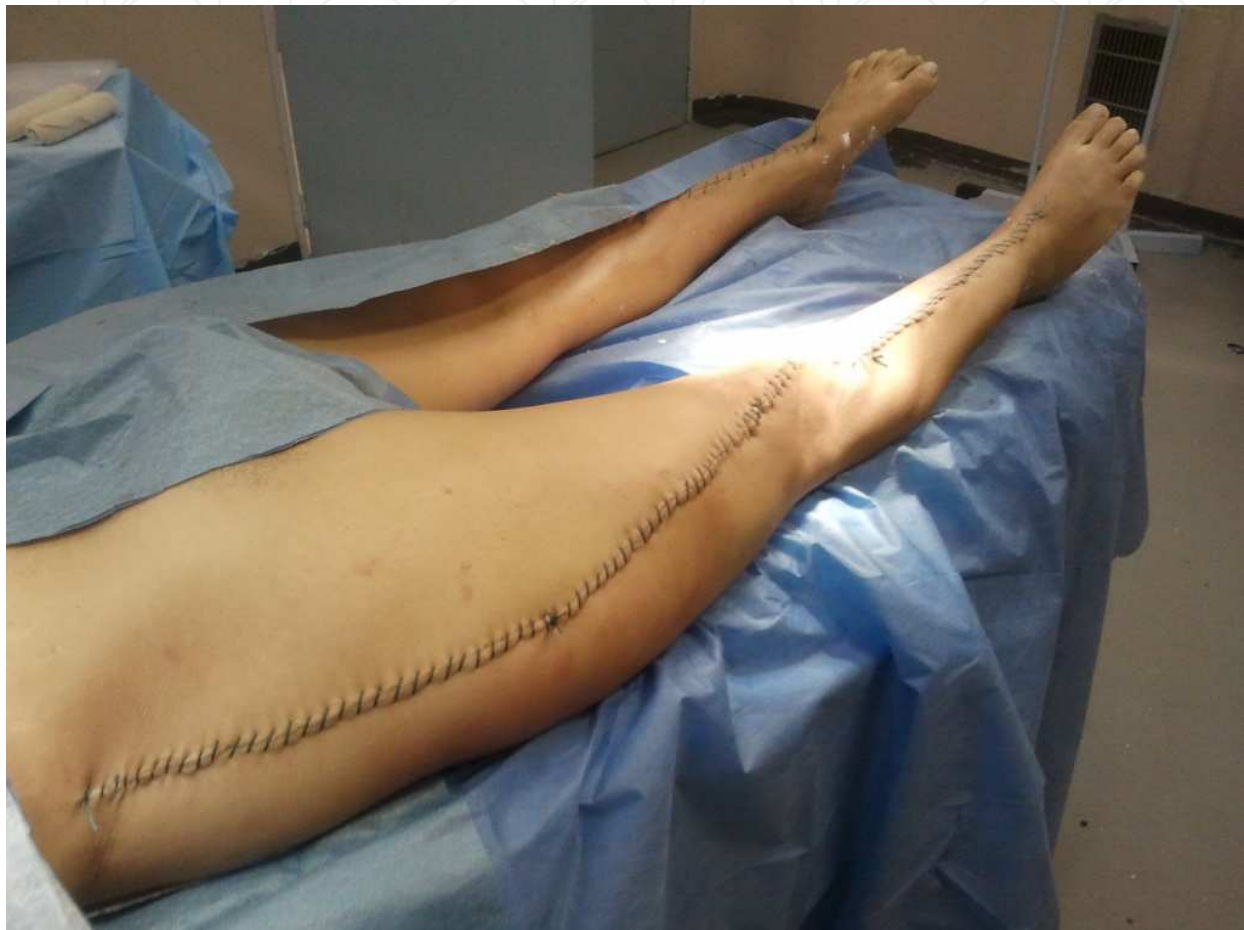

Illustration 02. Limbs reconstructed with prostheses after tissue removal.

## 8. Processing the musculoskeletal tissues

Once the tissues and organs have been obtained, they are delivered to the BTME in portable refrigerators, with temperature monitoring throughout the transport process. The processing stage is preceded by a planning of the activities necessary to accomplish it, such as provision of materials and instruments, summoning the processing team, defining the preparation and dimensions, according to the needs of the service (waiting list) and requests for orthopaedic and odontological surgeons. This stage is done in a special, classified operating theater (class 100 or ISO 5) equipped with a laminar flow module. (Illustration 03). A Class 100 room means it has purity of 100 particules per m<sup>3</sup> of air. For the purposes of comparison, an operating theater should have 10,000 particles/m<sup>3</sup> of air.



Illustration 03. Classified processing room (100 particles/m<sup>3</sup> air: Class 100/ISO 5; HEPA Filters 99.9 %)

The room also has a pass-through anti-chamber, and all the environments have rigorous control of air particles and positive pressure, to ensure the quality of the tissues processed in it. Specific gowning of the professional team is also necessary, using only non-fabric clothing (Spunbond - Meltblown - Spunbond - SMS) to prevent the dispersion of particles given off by conventional cotton clothing. (**Illustration 04**)

In addition to non-fabric gowning; the team must also adopt certain behaviors. For example, sudden movements, use of cosmetic products and exposure of the skin should be avoided while in this room. Adequate conduct is ensured through special training, not only for the processing team that actually carries out the procedure, but also for other professionals who enter the environment (e.g. for cleaning and maintenance purposes).

A BTME carries out various types of tissue, for use in orthopedic and odontological surgery, and each procedure requires careful planning. (**Illustrations 05 ,06 and 07**)

For the processing of fresh, frozen tissues, a process called mechanical processing is carried out, i.e. removal of the adventitious tissues such as the blood, periosteum, subcutaneous tissue, muscles, fasciae, and fibrotic tissue.

The fragments are then submitted **chemical processing**, where they are immersed in hydrogen peroxide based emulsifying solutions and alcoholic solutions under ultrasound stirring. (**Illustrations 08 and 09**)

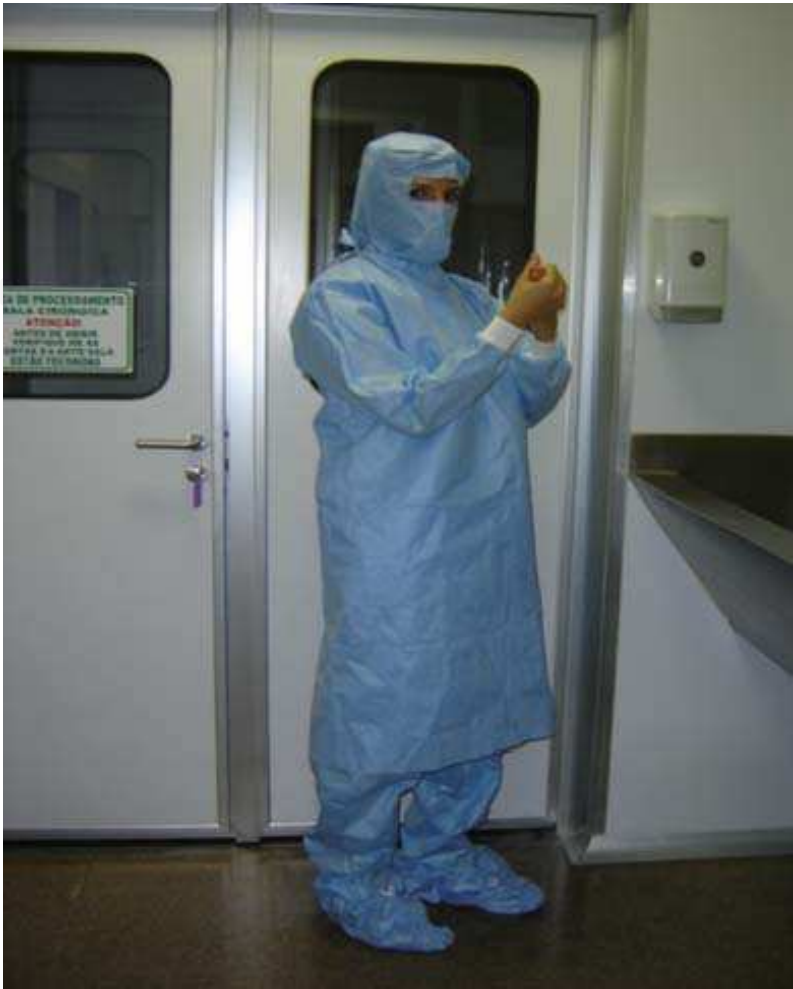

Illustration 04. Specific gowning to work in the classified room.

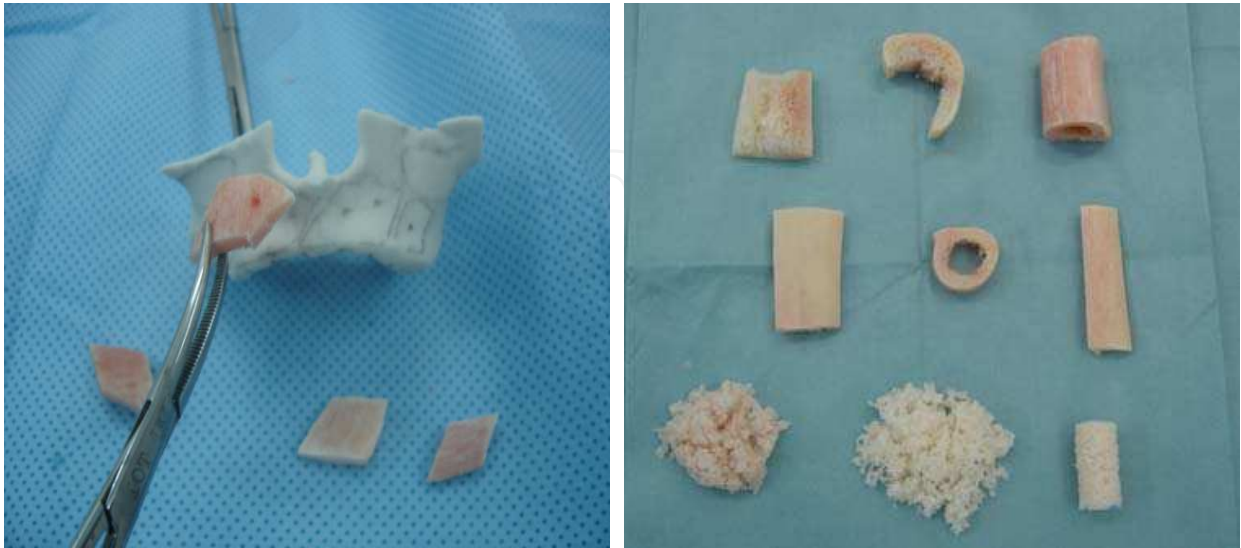

Illustration 05 and 06. Processing of grafts for use in odontological surgery. The photograph on the left shows modeling of maxillary bone defects based on a resin prototype. The one on the right shows fragments of allografts for use in odontological surgery.

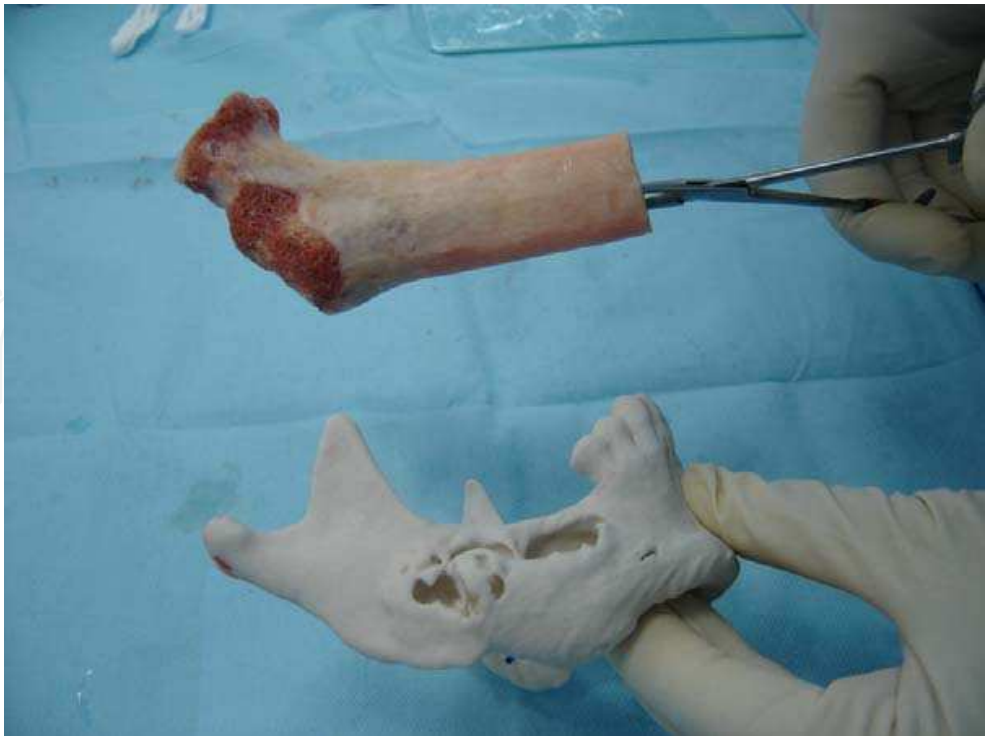


Illustration 07. Modeling of a jaw bone from a segment of proximal femur.



Illustration 08. Ultrasound washing in emulsifying solution.



Illustration 09. Processing Team at work.

Immediately afterwards, samples of bone marrow from the long bones and fragments of each tissue submitted to processing are collected from these resulting solutions, and submitted to microbiological processing (general culture, anaerobic and fungal culture) using the direct inoculation technique. Samples are also obtained for histopathological analysis.

Finally, the packaging procedure is begun for all the grafts processed, which are measured (length, height, diameter, weight volume, perimeter), packed in sterile, triple packaging, vacuum sealed, and duly labeled as analysis tissue. (Figure 8). The tissues are labeled with the following information: donor, exams carried out, batch number, item, validity period, type of conservation, and bar code.

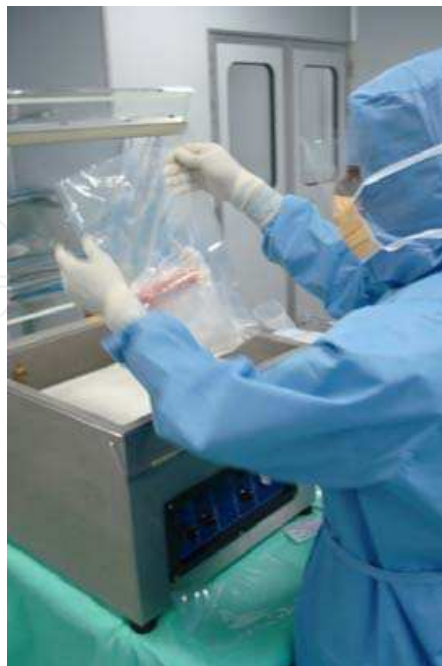

Illustration 10. Vacuum sealing and labeling.

Once they have been labeled, the tissues are submitted to radiography at the BTME, then sent for cryopreservation.

## 9. Cryopreservation of the musculoskeletal tissues

The musculoskeletal tissue cryopreservation process at - 80°C is described in chapter 1 (VALIDATION OF PRIMARY PACKAGING FOR CRYOPRESERVED MUSCULOSKELETAL TISSUES)

## 10. Lyophilization of musculoskeletal tissue

The bones can also be processed in their lyophilized form. The lyophilization process should be validated and be, like all the tissue handling procedures, in conformity with the Manual of Good Manufacturing Practice - GMP and in accordance with international standards<sup>6</sup>, literature<sup>7</sup> and legislation. The procedure involves the use of an automated lyophilization system composed of a Labconco® (**Illustration 11**) freeze drying, or lyophilization chamber with Condensation Chamber/Vacuum. During lyophilization the tissues remain frozen for the prevention of ice crystal liquefaction inside the matrix. The sublimation process should be validated by analyses of the Residual Moisture by automated thermogravimetric method. The lyophilization process is divided into 2 stages: Primary and Secondary Drying. In the primary phase, the largest fraction of water present in the matrix in its solid state (ice crystals) is removed by sublimation induction and gaseous migration. This induction is achieved by the driving force resulting from the difference of pressure gradient between the lyophilization chamber and condenser. The heat generated by this gaseous transportation should be controlled continually by digital sensors strategically positioned inside the lyophilization chamber.

At the end of the sublimation, the aliquot of unfrozen water linked to the organic components of the matrix (proteins) is then removed in the secondary phase, with an increase of pressure in the lyophilization chamber followed by the gradual increase of temperature at positive levels.

The analysis and control of residual moisture are essential to ensure the integrity of the protein matrix. The residual moisture is determined by thermogravimetric method, using an Ohaus® (**Illustration 12,13**) moisture analyzer. This method analyzes the initial weight of the sample on precision scales, followed by the promotion of heating with continuous recording of evaporation and weight. The percentage of residual moisture (**RM**), solid mass (**SM**), initial weight (**IW**) and final weight (**FW**) are analyzed in this method. The limit of RM is < 6 % as described by literature (Phillips, 2000).

---

<sup>6</sup>European Association of Tissue Banks. Common Standards for Tissues and Cells Banking: Berlin: European Association of Tissue Banks; 2004.

American Association of Tissue Banks. Standards for Tissue Banking. 11th ed. McLean : American Association of Tissue Banks; 2007

<sup>7</sup>Phillips GO, Strong DM, Versen RV, Nather A. Advances in Tissue Banking. Vol. 4. World Scientific . New Jersey, 2000.

Bancroft JD, Stevens A. Theory and practice of histological techniques. Fourth Edition. Churchill Livingstone. United Kingdom, 1999.



Illustration 11. Lyophilization chamber: Labconco® equipment from the Tissue Bank of Hospital das Clínicas – Universidade de São Paulo.



Illustrations 12,13. Residual Moisture Analyzer: Ohaus® equipment belonging to the Tissue Bank of Hospital das Clínicas – Universidade de São Paulo.

The result of the lyophilization is a dry tissue, conservable at room temperature and that should receive final sterilization by radiation. The lyophilized tissue radiation process is carried out in a Multi-purpose Irradiator, with gamma radiation from sources of <sup>60</sup>CO. The appropriate radiation dose is 25 kGy, with a dose rate of approximately 7 kGy/h. In order to avoid temperature variation, the samples are radiated in the presence of cooling elements, keeping the temperature between 4 and 8 °C. Red Perspex dosimeters are used for dose control.

Time Interval	Process	Indicators	Sample Temperature
2 hours	Pre-freezing of the lyophilization chamber	Temp. Chamber: - 40 °C	- 80 °C
10 minutes	Vacuum	Chamber Temp.: - 30 °C Chamber Vacuum : 8 x 10 <sup>-3</sup> mBar Condenser Vacuum : 2 x 10 <sup>-3</sup> mBar	- 65 °C
6 hours	Primary Drying	Chamber Temp.: - 30 °C Chamber Vacuum: 8 x 10 <sup>-3</sup> mBar Condenser Vacuum : 1 x 10 <sup>-3</sup> mBar <b>Analysis Final Moisture of Phase 01</b> RM: 6.26% Initial Weight: 0.527g Final Weight: 0.494g Solid: 93.74% <b>Analysis Temperature: 105°C</b>	- 40 °C
4 hours	Secondary Drying	Chamber Temp.: up to + 5 °C  Chamber Vacuum: 7 x 10 <sup>-3</sup> mBar Condenser Vacuum: 1 x 10 <sup>-3</sup> mBar  <b>Analysis Final Humidity of Phase 02</b> RM: 2.32% Initial Weight: 0.732g Final Weight: 0.715g Solid: 97.68% <b>Analysis Temperature: 105°C</b>	+ 5 °C

Table 1. Primary and Secondary Drying Process

## 11. Storage, distribution and quality control of tissue

At the end of any processing mode, the procedures should be documented in a specific file. This file is used to contain all the documentation related to the process, including records of the participant team, inputs used, documents evidencing sterility of instruments and other records that are part of the quality control program and that provide subsidies for traceability of the processes. This stage is imperative in the legislation and recommended by the Standards and Quality Control Manuals.

The tissue stock can be kept both frozen and at room temperature (lyophilized) following the same standards used by the global tissue banks and associations. Other processing methods have been investigated with the purpose of reducing the costs related to banking and maintenance. The glycerolization of bone tissue is presented as a processing methodology able to maintain the viability of the matrix and to prevent bacterial growth, besides enabling storage at room temperature (Giovani, 2006).

Until the transplantation occurs, all the processed tissues should be submitted to rigid quality assurance criteria. It is necessary to have an evaluation of all the data pertaining to the donor, results of exams, maintenance and control of equipment, material and instruments used in all the phases of each procedure. Management software can be used to record all the stages, allowing the fast retrieval of information such as the particulars of the donor, lot, shelf life, exams and status of the tissue (analysis, released, excluded, used) making it easier to trace each graft processed and made available, especially in the presence of evidence of an adverse effect and implementation of corrective and preventive actions.

For a lot of grafts under analysis to be released for use, the qualified technical professional from the Tissue Bank must analyze the results of all the exams performed: NAT or PCR serology for HIV, HBC and HCV, General Culture, Anaerobic Culture, Fungal Culture, Anatomopathological Exam and radiology reports. These exam reports are ultimately evaluated and released by the Qualified Clinical Professional of the service.

Besides exams, it is necessary to consider an evaluation of the printed records of temperature during the banking period. The service should have equipment that detects temperature oscillations even at a distance (satellite monitoring system).

Moreover, the installation of buzzers at strategic points of the hospital as well as Co2 backups ensures the reliability of the system.

After the release of each lot, there should also be a final inspection of each tissue, besides the substitution of tags of tissues under analysis by replaced. The banking logistics of the tissues in the ultra-low temperature (ULT) freezers considers the tissue type and search agility.

Services that execute rigorous quality control use annotation systems featuring checklists with double checking and consent.

All the data pertaining to the donor and to the lot, in compliance with the legislation, should be kept in single folders and stored in specific files of the musculoskeletal tissue bank for a minimum period of 25 years.

A serum bank with samples of donor plasma should also be made available by the musculoskeletal tissue bank in case of the need for counterproof exams.

As soon as the quality criteria have been evaluated and approved, the tissues are made available for use.

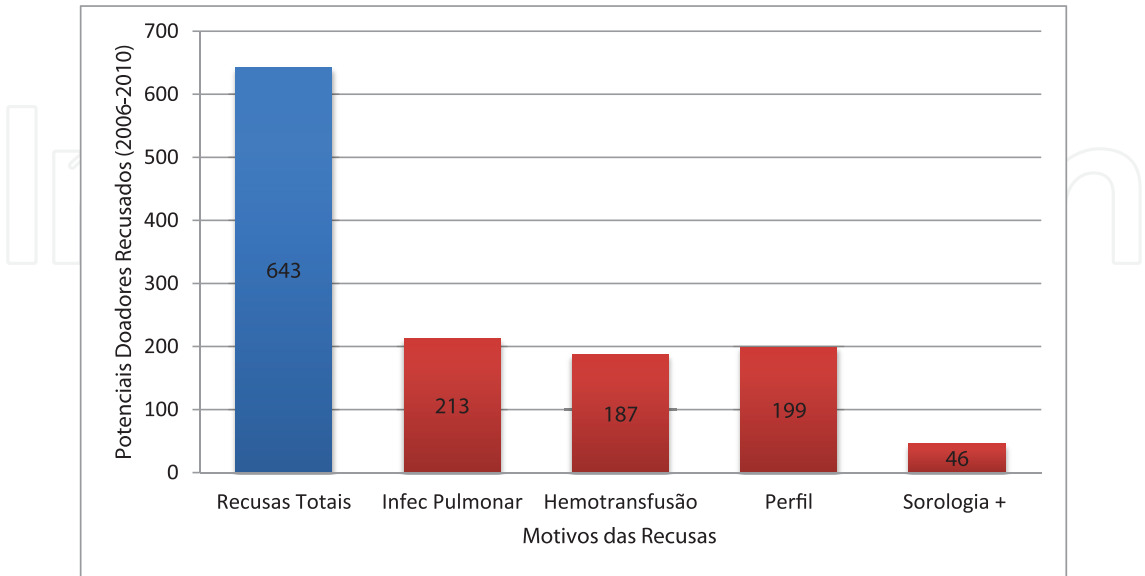
The tissues are distributed to the various specialties (Hip, Knee, Shoulder, Tumors and Dentistry) according to the availability of and requests for grafts.

The transplanter (physician or dentist) places the order for the tissue through a discussion of cases and by sending a specific form. The tissue reservation takes into account the demand for each type of transplant, waiting list and stock. The waiting list for transplantations performed within the Unified Health System - SUS complies with the prevailing legislation and today is organized and managed by the musculoskeletal tissue banks themselves, observing an order by date of inclusion. Urgent cases appointed by the medical team, such as malignant tumors and situations with a risk of severe complications, are communicated to the musculoskeletal tissue bank through an Emergency Form, for immediate response.

In dentistry, transplants have evolved differently and their distribution features some particularities that will be described further on.

12. Global data on tissue transplantation activities in Brazil

Today it can be seen that tissue transplantations in general are on the rise. Events such as officialization in the legislation and the creation of public promotion policies corroborate this evolution. Considering bone transplants alone, 30x growth has been observed in the last 5 years (Brazilian Transplantation Register, 2010), a fact motivated by the start of large-scale distribution of tissues for dental surgery. Although statistics show the number of tissues to be growing, the quantity of donors is still a concern. The vast majority of donors in Brazil are still for the removal of perfused solid organs (heart, kidney, liver, etc. A minority (6% on an average) accept the donation of musculoskeletal tissues. Of these, just 8% on average, become effective donors and the rest are discarded due to the presence of exclusion criteria such as infections, blood transfusion, and inadequate profile (**Graph 1**).



Graph 1. Reasons for refusals of bone donors between 2006-2010.  
(Source: File BTME-HC-USP)

13. Homologous tissue transplants in dentistry

Dentistry has also sought biomaterials usable in the replacement of mandibular and maxillary bone loss over the years. The transplantation of bone portions taken from the iliac crest and menton (autologous transplant) has been broadcast in recent years, yet similarly to what happened in the orthopedic area, the disadvantages related to donor morbidity and the good results observed in the use of allografts in orthopedic patients, motivated professionals and patients to adopt this form of treatment.

In Brazil the use of bone transplants in dentistry started in 2005 after a consensus regarding the need for use and administrative mobilizations with the National Transplant System, Federal Council of Dentistry and Musculoskeletal Tissue Banks. This consensus serves as a starting point for the definition of criteria for requests for these tissues at the existing banks, where the professional must be a specialist in the areas of Implant Dentistry, Periodontics or Oral and Maxillofacial.

Rules related to logistics and traceability were incorporated into the activities of existing tissue banks, which then started to implement the bone tissue processing and distribution programs for dental purposes. In this program it is crucial to record the entire process with a focus on health control, including adverse deeds and traceability from the request to the actual transplantation. Specific forms are used for this purpose, including the Request Form, Terminated Transplantation Form, Non-Conformity Term and Adverse Effect Form.

Once standardized, this type of transplant is initiated in the country with widespread adoption by dentists, as observed in the Brazilian transplantation records. (RBT, 2006-2010)

Naturally, the Maxilla and Mandible are today the main bone tissue receptor areas in dentistry that have very distinctive characteristics when submitted to the osteolysis processes, which, in turn, require distinctive techniques during the bone transplant. The size and shape of the bones are influenced by several factors, which range from the genetic conditions of the individual to the environment in which they live. In other words, age, sex, physical characteristics, health, diet, race and place of residence are aspects to be considered (Moore, 1990).

Maxillary and Mandibular development and growth are determined by the appearance of teeth from the first months of life. It is interesting to note that the mandibular and maxillary bone tissue responds to intrinsic and extrinsic factors throughout the lifetime of an individual, and, therefore is very plastic, which counteracts its rigid and inert appearance.

Pathophysiology of Bone Loss	
Metabolic Factors:	
• Age;	
• Gender;	
• Hormone balance;	
• Osteoporosis;	
• Nutritional disorders.	
Mechanical Factors:	
• Functional (force applied to edge (pressure, compression, tension, shearing)):	

<ul style="list-style-type: none"><li>• Frequency;</li><li>• Direction;</li><li>• Quantity.</li></ul> <p><i>Prosthetic Factors:</i></p> <ul style="list-style-type: none"><li>• Type of prosthesis base;</li><li>• Shape and type of teeth.</li></ul>
---

Table 2. Factors related to the bone loss process (Source: Fonseca & Davis, 1995)

One of the factors most closely related to the indication of bone reconstructions in dentistry are maxillary and mandibular resorptions due to lack of the dental element.

The resorption of the alveolar edge is a chronic, progressive, irreversible and cumulative alteration. This condition, observed in the toothless individual, becomes faster in the first six months after exodontias or dental extractions. Once the function of providing support to the teeth has been lost, the alveolar process tends to undergo resorption due to disuse (Mecall & Rosenfeld, 1991). And this resorption can be exacerbated by local factors (traumatism, infections and pathologies), systemic factors (osteopenia, osteoporosis, osteomalacia, endocrine and nutritional alterations), systemic health problems, prosthetic treatments and others (Fonseca & Davis, 1995; Gassen et al, 2008)

Projections by the Brazilian Institute of Geography and Statistics (IBGE) show that the elderly population in Brazil is set to increase considerably in future years. Life expectancy in 2020 is estimated at 71.2 years (men) and 74.7 years (women) and will represent 13% of the population (IBGE, 2011). Data from the Epidemiological Survey indicate the elderly age bracket as having the highest rates of edentulism and of prosthesis use for prolonged periods. (Ministério da Saúde, 2003)

The previous use not only of total prostheses but also of removable partial prostheses is identified as a predisposing factor of tissue resorption (odds ratio = 2.4), and the flaccid tissue from the edge is related to the severity of resorption (odds ratio = 2.4). (Watzek, 1996, Xie et al, 1997)

In this context, it is noted that the majority of atrophic edentulous cases (total or partial) has increasingly resorted to the adoption of dental implants and for this reason, bone grafts appear as an option of biomaterial used in pre-prosthetic surgery (Galea, 2005).

Frozen homologous bone tissue is biocompatible and can be used successfully in treatments that require maxillary sinus lifting. Its use favors bone neoformation, integration, and absence of inflammatory infiltrate as well as an increase in the percentage of bone volume (Stacchi et al, 2008). In the long term, it is possible to observe the formation of viable and mature bone tissue, providing adequate reconstruction techniques are adopted. (Contar et al, 2009)

Some studies in the dental area have evaluated the efficacy of the use of allografts through an analysis of the biomechanics of implants placed in the grafting zone. This is possible through a resonance frequency analysis (RFA) and removal torque (RT) analysis. The results show that there is no difference in stability between implants installed with autogenous and allogeneic grafts. (Ribeiro, 2009) It is also possible to evaluate the osseointegration process through an evaluation of the neoformed bone volume. Lima (2010) studied homologous

bone grafts processed in a tissue bank with different methods (lyophilized, demineralized and radiated (ALD); mineralized frozen (ACM) besides autogenous grafts (AT) and blood clot (CG). In the Guided Bone Regeneration (GBR) technique, samples of the groups of grafts were placed in 32 cylinders fastened to the calvaria of 08 animals. After 13 weeks the cylinder fill rates (bone volume of the ALD group) were similar to the ACM and superior to the autogenous graft). Bone neoformation also occurs during the use of homologous grafts in maxillary sinus lifting surgery, besides affording lower morbidity levels (Viscioni et al, 2010). Hence it should be considered a valid alternative for the replacement of autologous grafts in patients submitted to implant therapy.

#### **14. Prospects in the application of osseointegration investigation methodologies in grafting areas**

Some techniques can be used today in the analysis of interface sites between receptor and donor bone, which generate information capable of providing subsidies for a greater understanding of the osseointegration process.

##### **14.1 Histomorphometry**

Histomorphometry aims to analyze bone morphology and its components (measurements of volume, area, perimeter etc.). This technique is developed primarily for rock analysis, and is currently employed to analyze cellular behaviors of tissues starting from their structural conformity, expressed in thin slices on a slide. The histological reading and the definition of elements that compose the bone microtexture is the main goal of this procedure. The method can be manual, semiautomatic and automatic. A microscope coupled to a micrometer ruler is used in the first. In the semiautomatic version the microscope is coupled to a computer, which in turn uses software that allows users to record and to quantitatively analyze the images of a slide, seen through the microscope lenses, which are projected onto a digitizing board and drawn manually. The definition of each histological structure is performed by a professional. Finally, the automatic technique allows users to capture the images from the microscope using video cameras and the definition of each structure is determined by the actual computer, which automatically analyzes the coloration of each structure. Although the latter is the fastest technique, it is also the least sensitive. (Jorgetti, 2003; Aaron, Shore, 2003)

This technique permits the analysis of primary or static parameters (extension, number and distance) and the derived parameters, which are divided into structural (analyze bone structure) and kinetic (analyze the dynamics of the bone tissue).

The histomorphometric parameters are measured at 125x zoom. The choice of the analysis area should consider the contact surface of the receptor bone with the allograft.

A microscope equipped with objective, micrometer ruler, cursor, digitizing board and image analysis software is used to quantify the structural static, bone tissue formation and resorption histomorphometric parameters. (**Illustration 22**)

The static histomorphometric parameters are classified as:

##### **STRUCTURAL PARAMETERS**

- Total area (**T.Ar** mm<sup>2</sup>): total area measured;

- Bone Volume (**BV/TV %**): percentage of bone tissue formed by mineralized or unmineralized trabecular bone;
- Thickness of the woven bone (**Tb.Th  $\mu\text{m}$** ): thickness of the bone trabeculae expressed in micra;
- Trabecular number (**Tb.N/mm**): the number of bone trabeculae, by millimeter of tissue, which is also an index that expresses trabecular density;
- Trabecular separation (**Tb.Sp  $\mu\text{m}$** ): the distance between the bone trabeculae expressed in micra;
- Number of osteocytes (**N.Ot**): number of osteocytes present in the area of the bone tissue evaluated.



Illustration 14. Equipment used for histomorphometric analysis (microscope coupled to digitizing board and Osteomeasure® software)

#### FORMATION PARAMETER

- Osteoid volume (**OV/BV %**): percentage of osteoid matrix in relation to the trabecular bone;
- Osteoid surface (**OS/BS %**): percentage of trabecular surface covered by osteoid matrix;
- Osteoblast surface (**Ob.S/BS %**): percentage of the trabecular surface that presents osteoblasts;
- Osteoid thickness (**O.Th  $\mu\text{m}$** ): the thickness of the osteoid matrix deposited on the bone trabeculae, expressed in micra;

- Number of osteoblasts (**N.Ob**): absolute number of osteoblasts present in the measured area;
- Number of osteoblasts by tissue area (**N.Ob/T.Ar**): number of osteoblasts by tissue area analyzed, expressed in square millimeters;
- Number of osteoblasts by bone perimeter (**N.Ob/B.Pm**): number of osteoblasts by bone perimeter analyzed, expressed in millimeters.

#### RESORPTION PARAMETER

- Osteoclast surface (**Oc.S/BS%**): percentage of trabecular surface that presents osteoclasts;
- Number of osteoclasts (**N.Oc**): number of osteoclasts present in the area of the bone tissue evaluated;
- Resorption surface (**ES/BS %**): percentage of surface that presents bone resorption lacunae with or without the presence of osteoclasts.

The histomorphometric parameters adopted in this technique should follow a universal nomenclature agreed upon by the American Society of Bone and Mineral Research - ASBMR (Parfitt et al., 1987).

### 14.2 Immunohistochemistry

With the advent of osseointegrated dental implants it is extremely important for us to know the cellular processes involved in the osseointegration of allografts, as already mentioned, and this is possible with the immunohistochemistry technique. In vivo mineralization on the implant surface is directly related to the components of the extracellular bone matrix, both collagen and non-collagen components. The bone structure is composed of about 70% of inorganic matter (hydroxyapatite), while the rest is the organic matrix, predominantly consisting of collagen (95%), which is responsible for its flexibility and resistance whereas type I collagen provides support to the mineral structure. The non-collagen components include osteocalcin, osteonectin and osteopontin.

Osteocalcin is related to bone matrix mineralization, and is exclusively expressed by osteoblasts (Ducy et al. 1995). Osteonectin influences the synthesis of extracellular matrix components (Bradshaw et al. 2003) and the calcification of the organic matrix as it is selectively linked to hydroxyapatite and type I collagen fibrils (Termine et al. 1981). Osteopontin is strongly linked to hydroxyapatite crystals and is involved in the anchoring of the osteoclasts in the inorganic bone matrix, controlling crystal nucleation and growth.

Hence the evaluation of these proteins in the osseointegration process can provide us with important information about how the allogeneic bone graft used can corroborate for better interaction of the cellular mechanisms between donor and recipient focusing on the maintenance of the bone tissue after the implant installation.

Moreover, the remodeling of this matrix needs specialized enzymes. Matrix metalloproteinases (MMPs) are an important family of endopeptidases, with 25 known human members, and represent the largest class of enzymes that, collectively, are responsible for the degradation or resorption of extracellular matrix components, and are the only enzymes capable of cleaving fibrillar collagens (Curran et al. 1999), several proteins

from the cellular surface and from the pericellular environment and some intracellular proteins.

This technique makes it possible to evaluate bone matrix proteins (type I collagen, osteocalcin, osteopontin and osteonectin) and the MMPs during the osseointegration process of bone grafts in patient to be submitted to future dental implants.

### 14.3 Peripheral quantitative computed bone tomography (pQCT)

Peripheral quantitative computed tomography - pQCT is a method used to measure the appendicular skeleton that, besides furnishing a broad range of data, also makes it possible to evaluate the cortical and trabecular bones separately.

The obtainment of images is performed by a scanner (ex Stratec XCT Research M instrument scanner (Norland Medical Systems, Fort.) specifically for the analysis of small grafting sites.

The parameters evaluated in this technique are:

- total BMC - total bone mineral content, mg/mm;
- total BMD - total bone mineral density, mg/cm<sup>3</sup>;
- trabecular BMC - trabecular mineral content, mg/mm;
- trabecular BMD - trabecular mineral density, mg/cm<sup>3</sup>;
- cortical content, mg/mm;
- cortical density, mg/cm<sup>3</sup>;
- total area, mm<sup>2</sup>;
- trabecular area, mm<sup>2</sup>.
- periosteal circumference, mm;
- endosteal circumference, mm.

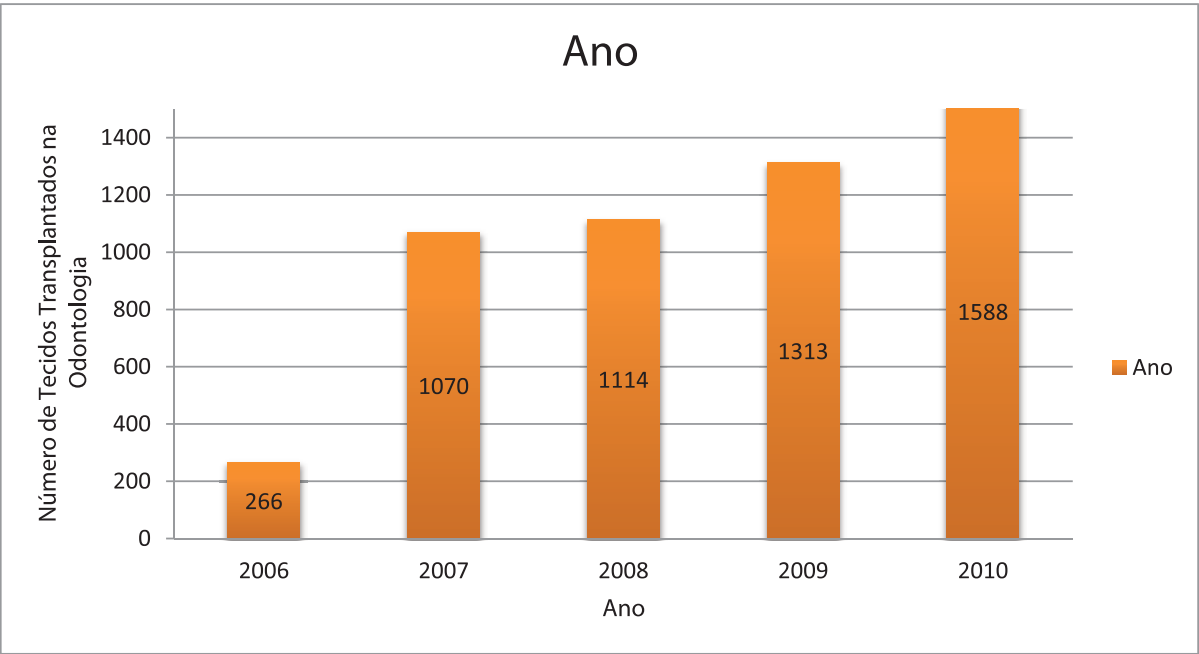
## 15. Discussion

There have been many differences in bone tissue preparation techniques since the first tests in the 30s, yet the desire for the recovery of lost bone tissue among physicians and dentists still remains. The Ministry of Health has recently expressed interest in increasing and promoting this kind of transplant in the country. It is a fact that an increasing number of patients with bone loss for various reasons have approached specialized orthopedics and dentistry services in pursuit of reconstructive solutions. This context includes procedures involving the use of allografts made available by musculoskeletal tissue banks.

In dentistry, the officialization of allograft use arrives very late in 2005. Dental transplanters were curtailed in their use of this kind of treatment for more than a decade. Public policies of oral health were also very late in arriving. The result is perceptible in the statistics that evidence a high rate of edentulism in our population. (Ministerio da Saúde, 2003). In response to this situation, we can also observe high rates of prosthetic rehabilitations in the Brazilian population.

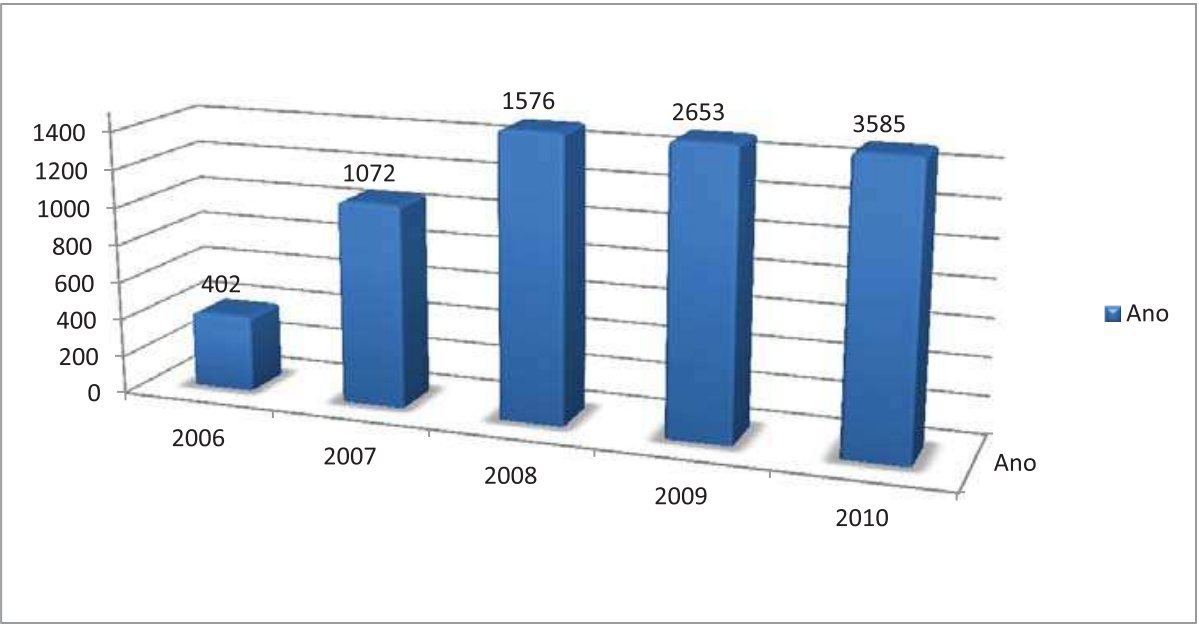
Data from the Epidemiological Oral Health Survey in Brazil (2003) shows that about 67% of the population between 65 and 74 years of age use some kind of prosthesis as a form of edentulism treatment. We know that edentulism and the prolonged use of these prostheses lead to maxillary and mandibular bone resorption over the years (Davis, 1995; Gassen et al,

2008). The high rate of individuals with this necessity, the greater economic access of the population to treatments with osseointegrated implants and to the start of authorization of allograft use in dentistry, corroborated the abrupt growth of bone transplants in dentistry at around 600% in these last 5 years (Graph 2).



Graph 2. Annual Distribution of homologous tissues made available by a tissue bank that serves as a national reference for Dental Transplants (2006 to 2010).

Such a situation was also observed in our study in relation to the number of transplanting dentists, whose number climbed steeply from 22 to 3585 also in 5 years (Graph 3).



Graph 3. Absolute Frequency of dentists accredited for transplants over the years (2006-2010)

In the next few years we will observe growth of the elderly population in our country (around 13% in 2020), motivated by the increase in life expectancy. It is estimated that in 2020 this expectancy will be 71.2 years for men and 74.7 years for women (IBGE, 2011). Considering that the elderly population is exposed to factors accumulated during their lifetimes that lead to the need for pre-prosthetic reconstructive bone interventions (edentulism, prolonged use of prostheses, osteoporosis, hypothyroidism) we can reflect here on a possible influence over prosthetic rehabilitations of the elderly population in future years, and that in some of them the use of biomaterials (including allograft) may be indicated.

What then has become an obvious trend gives rise to the need to discuss the future of dental transplants. Public health surveillance policies seek, together with trade associations (Regional Federal Council of Dentistry) and tissue banks, the assurance of traceability in procedures of this nature. This is undoubtedly the major challenge for tissue banks. Unlike other kinds of transplants, where the data are compiled and made available by hospitals, in dental transplantations there is the need for total involvement of the transplanting professional in disclosing and informing the adverse effects detected in the treatment. Following the example of the national policy implemented by ANVISA in the area of hemoderivates transfusion, the intention is to create a similar system for the surveillance of tissue transplants in the country, which will include dental transplants. In this model, the adverse effects can be notified nationwide (electronically), enabling the construction of a database that will serve as a source for the definition of corrective and preventive actions of complications in dental surgeries with the use of allografts. Such information is extremely valuable to banks, particularly in the quality control of the tissues produced thereby.

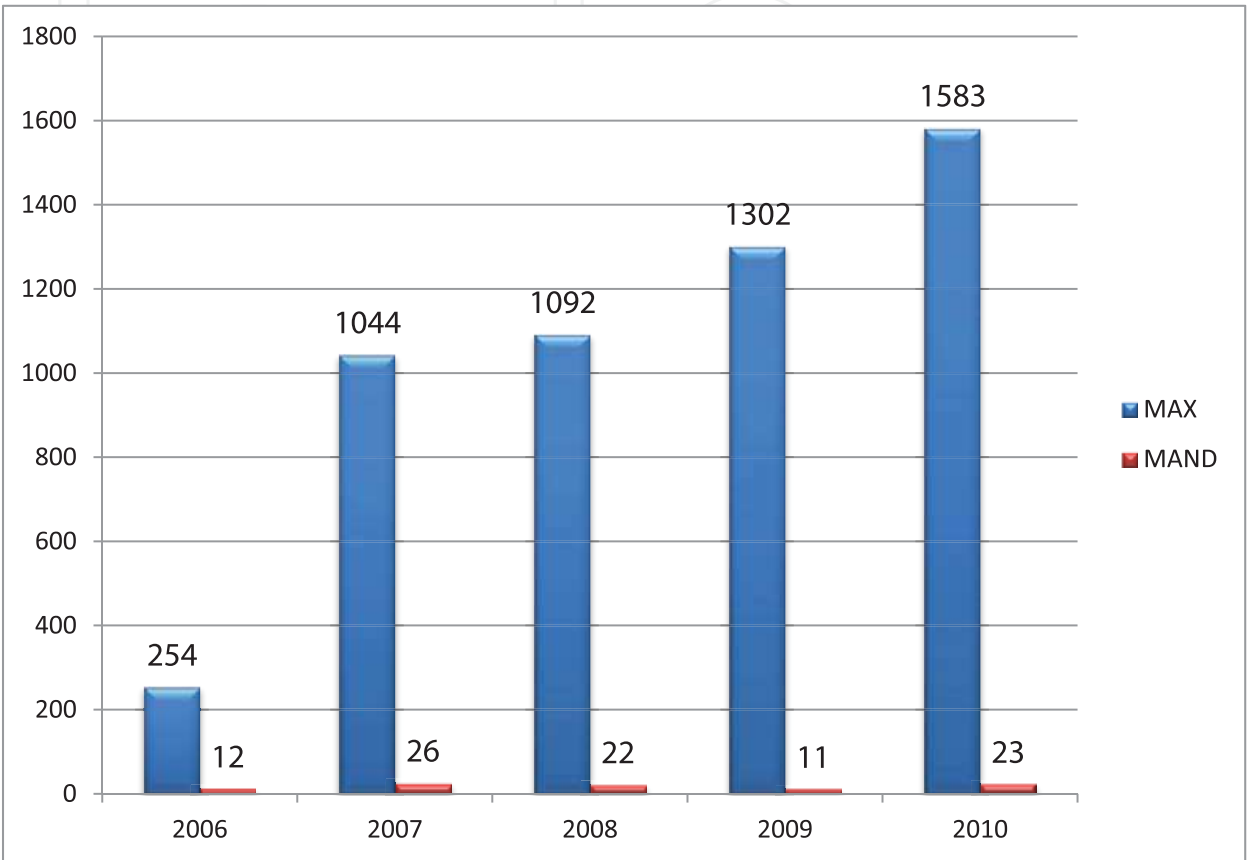
After a more detailed analysis of dental transplants, we detected that approximately 76% are related to the use of cortical tissues, which in our understanding is expected due to the greater availability of this type of tissue at banks. While a spongy segment of a long bone such as the femur and tibia (metaphyseal region) yields 10 to 15 units of spongy blocks, 50 to 60 units of cortical blocks are processed from a diaphysis. It should also be considered that due to the lesser availability of spongy tissues, surgeons have opted in particular for cortical blocks, especially for use in sinus lifting surgery preceding implant installation.

GRAFT MORPHOLOGY	Relative Frequency (%)
Cortical	75.64 %
Spongy	15.86 %
Cortico-Spongy	8.5 %
TOTAL	100.00

Table 3. Distribution of Grafts in Terms of Morphology. BTM (musculoskeletal tissue bank) - HCFMUSP, 2006 to 2010.

The most frequent surgical site was undoubtedly the maxilla (98.2%- Graph 4) and we hereby emphasize the main reasons for this finding. Firstly, edentulism in the Brazilian population has appeared to affect the maxilla more than the mandible which certainly leads to the greater use of upper prostheses (57.9%) versus lower prostheses (34.18%) by the population aged between 65 and 74 years (Ministério da Saúde, 2003). Secondly, the actual anatomy of the maxilla due to the presence of maxillary sinuses that are grafted during the

sinus lifting technique. This technique is very frequent in the branch in implant dentistry. Thirdly, the lower bone quality of the maxilla in comparison to the mandible, focusing on the primary stability of implants and propensity for resorption after the prolonged use of prostheses. (Mezzomo et al, 2010) It is also worth emphasizing that the maxilla appears as a more esthetic area that demands more attention from individuals concerned about its rehabilitation.



Graph 4. Distribution of Type and Surgical Site of use of the tissues made available by a bank that serves as a national reference from 2006 to 2010.

Although epidemiological data shows the increasing use of homologous tissues in dental surgery, few studies in our field assess their efficacy, hence the need to establish consensuses on their applicability and more importantly, predictability of treatments with the use of allografts. We take predictability to mean knowledge of the responses of bone tissue to the interventions performed in our areas of specialty. Thus in this study we have highlighted a chapter on possible lines of investigation enforceable in our field, which can help us in our search for answers related to the osseointegration process of allografts at sites of dental interest.

The analysis of grafting area by histomorphometry allows us to accurately quantify the structure of the grafted tissue (area, volume) and how much tissue was formed after interaction with the recipient's body (osteoid volume, osteoid surface), to judge the participation of each bone cell (number of osteoblasts and osteocytes) and also to quantify resorptions that have occurred (resorption surface) as a result of this interaction. This data is supplemented by peripheral quantitative computed tomography - pQCT, which unlike histomorphometry, allows us to evaluate the density of the tissue before and after the

grafting period. Data of extreme importance, in view of the need for assurance of mechanical stability of dental implants, when implanted in the newly formed bone.

And finally, immunohistochemistry solves some mysteries related to the cellular processes involved in osseointegration. The technique allows us to evaluate, by means of reaction by selected antibodies, the expression of proteins related to the mineralization process (osteocalcin, collagen) and remodeling of bone grafts (osteopontin, osteonectin).

As the basis for all these cellular events, the use of specific antibodies (Tartrate-resistant Acid Phosphatase - TRAP, Osteoprotegerin, Rank-L and Cd34) also allows us to evaluate the inflammation and the vascularization of grafting areas throughout the osseointegration period.

Nowadays in Brazil we are experiencing a time of transition in the indication of these transplants, and studies with this information content are certainly necessary for better knowledge and indication of allografts in dentistry, as well as the criteria and methodologies that can be used to analyze osseointegration.

## 16. References

- [1] Aaron JE, Shore PA. Bone histomorphometry: concepts and common techniques. In: An YH, Martin KL. Handbook of histology methods for bone and cartilage. New Jersey: Humana Press; 2003. p. 331-51.
- [2] Amatuuzzi MM, Croci AT, Giovani AMM, Santos LAU, Maragni GG, Shinzato JC. Banco de tecidos: estruturação e normatização. In: Amatuuzzi, Joelho: articulação dos membros inferiores. São Paulo: Roca; 2004. p.687-99.
- [3] Amatuuzzi MM, Croci AT, Giovani AMM, Santos LAU. Banco de tecidos: estruturação e normatização. *Rev Bras Ortop.* 2000; 35(5):165-72.
- [4] American Association of Tissue Banks. Standards for Tissue Banking. 11th ed. McLean : American Association of Tissue Banks; 2007.
- [5] Aubin JE, Lian JB, Stein GS. Bone formation: maturation and functional activities of osteoblast lineage cells. In: American Society for Bone and Mineral Research. Primer on the metabolic bone diseases and disorders of mineral metabolism. 6th ed. Washington: ASBMR; 2006. p.20-9.
- [6] Bancroft JD, Stevens A. Theory and practice of histological techniques. Fourth Edition. Churchill Livingstone. United Kingdom, 1999.
- [7] Barros Filho TEP, Rossi JDMBA, Rodrigues CJ, Lage LA, Reis PR. Poder osteogênico dos enxertos ósseos: estudo experimental comparativo entre enxertos autólogo, homólogo irradiado e homólogo AAA. *Rev Bras Ortop.* 1989; 24(1-2):36-40.
- [8] Bitar AC, Santos LAU, Croci AT, Pereira JARM, França Bisneto EN, Giovani AMM, Oliveira CRGCM. Histological Study of Fresh versus Frozen Semitendinous Muscle Tendon Allografts. *CLINICS* 2010;65(3):297-303
- [9] Boldt JG, Dilawari P, Agarwal S, Drabu KJ. Revision total hip arthroplasty using impaction bone grafting with cemented nonpolished stems and Charnley cups. *J Arthroplasty.* 2001; 16(8):943-52.
- [10] Bradshaw, A.D., Graves, D.C., Motamed, K., & Sage, E.H. 2003. SPARC-null mice exhibit increased adiposity without significant differences in overall body weight. *Proc.Natl.Acad.Sci.U.S.A.*, 100, (10) 6045-6050 available from: PM:12721366
- [11] Brasil, Leis etc. Decreto n.2268 de 30 de junho de 1997. Dispõe sobre a remoção de órgãos, tecidos e partes do corpo humano para fins de transplantes e tratamento. *Diário Oficial da União*, Brasília (DF). 1997 30 jun; seção 1:1.

- [12] Brasil, Leis etc. Lei n.9434 de 5 de fevereiro de 1997. Dispõe sobre a remoção de órgãos, tecidos e partes do corpo humano para fins de transplantes e tratamento. *Diário Oficial da União*, Brasília (DF). 1997 5 fev; seção 1:25.
- [13] Brasil, Leis etc. Portaria n.1686 de 20 de setembro de 2002. Dispõe sobre a regulamentação para funcionamento de banco de tecidos músculo esqueléticos. *Diário Oficial da União*, Brasília (DF). 2002 24 jul; seção 1:1.
- [14] Brasil, Leis etc. PORTARIA Nº 2.600, DE 21 DE OUTUBRO DE 2009. Aprova o Regulamento Técnico do Sistema Nacional de Transplantes. *Diário Oficial da União*, Brasília (DF). 2009 21out.
- [15] Brasil, Leis etc. Resolução n. 220 de 27 de dezembro de 2006. Dispõe sobre o Regulamento Técnico para o Funcionamento de Bancos de Tecidos Musculoesqueléticos e de Bancos de Pele de origem humana. *Diário Oficial da União*, Brasília (DF). 2006 29 dez.
- [16] Cabrita, H.B., et al., Prospective study of the treatment of infected hip arthroplasties with or without the use of an antibiotic-loaded cement spacer. *Clinics (Sao Paulo)*, 2007. 62(2): p. 99-108.
- [17] Carrel A. The preservation of tissues and its applications in surgery. 1912. *Clin Orthop Relat Res*. 1992; 278:2-8
- [18] Contar CM, Sarot JR, da Costa MB, Bordini J, de Lima AA, Alanis LR, Trevilatto PC, Machado MÁ. Fresh-frozen bone allografts in maxillary ridge augmentation: histologic analysis. *J Oral Implantol*. 2011 Apr;37(2):223-31.
- [19] Croci AT, Camargo OP, Oliveira CRGC, Baptista AD, Sorrilha A. Estudo histológico dos enxertos ósseos homólogos humanos. *Acta Ortop Bras*. 2003b; 11(4):220-4.
- [20] Cunningham N, Reddi AH. Biologic principles of bone induction: application to bone grafts. In: Habal MB, Reddi AH. Bone grafts and bone substitutes. Philadelphia: W.B. Saunders C; 1992. p.93-8.
- [21] Curran, S. & Murray, G.I. 1999. Matrix metalloproteinases in tumour invasion and metastasis. *J.Pathol.*, 189, (3) 300-308 available from: PM:10547590
- [22] Drumond SN. Transplantes ósseos. In: Pereira WA. *Manual de transplantes de órgãos e tecidos*. 2a ed. Rio de Janeiro: Medsi; 2000. p.359-80.
- [23] Ducy, P. & Karsenty, G. 1995. Two distinct osteoblast-specific cis-acting elements control expression of a mouse osteocalcin gene *Mol.Cell Biol.*, 15, (4) 1858-1869 available from: PM:7891679
- [24] Enneking WF, Burchardt H, Puhl JL, Piotrowski G. Physical and biological aspects of repair in dog cortical-bone transplants. *J Bone Joint Surg Am*. 1975; 57:237-52.
- [25] European Association of Tissue Banks. Common Standards for Tissues and Cells Banking; Berlin: European Association of Tissue Banks; 2004.
- [26] Fischer LP, Fischer-Athiel C, Fischer BS. One hundred years of bone surgery in the Lyons Teaching Hospitals (1897-1997). *Ann Chir*. 1998; 52(3):264-78.
- [27] Fonseca RJ, Davis WH. *Reconstructive Preprosthetic Oral and Maxillofacial Surgery*, ed 2. Philadelphia, WB Saunders, 1995, pp 498-510
- [28] Galea G, Kearney. Clinical effectiveness of processed and unprocessed bone. *Transfus Med*. 2005; 15(3):165-74.
- [29] Gassen, Humberto Thomazi; Filho, Rolf Muner; Siqueira, Bianca Munari de; Oliveira, Samia Bohm; Junior, Aurelício Novaes Silva. Reconstrução óssea de maxila atrófica utilizando enxerto de ramo mandibular. *Stomatol*, v.14, n.26, jan./jun. 2008.
- [30] Gerstenfeld LC, Einhorn TA. Fracture healing: the biology of bone repair and regeneration. In: American Society for Bone and Mineral Research. *Primer on the*

- metabolic bone diseases and disorders of mineral metabolism. 6th ed. Washington: ASBMR; 2006. p.42-48.
- [31] Giannoudis PV, Dinopoulos H, Tsiridis E. Bone substitutes: an update. *Injury*. 2005; 36S:S20-27.
- [32] Giovani AMM, Croci AT, Oliveira CRGCM, Filippi RZ, Santos LAU, Maragni GG. Comparative study of cryopreserved bone tissue and tissue preserved in a 98% glycerol solution. *Clinics*. 2006;61(6):565-70.
- [33] Giovani AMM. *Estudo comparativo entre o tecido ósseo criopreservado e o conservado em glicerol a 98% [dissertação]*. São Paulo: Faculdade de Medicina, Universidade de São Paulo; 2005.
- [34] Groves EWH. Methods and results of transplantation of bone in the repair of defects caused by injury or disease. *Br J Surg*. 1917; 5(18):185-242.
- [35] Heyligers IC, Klein-Nulend J. Detection so living cells in non-processed but deep-frozen bone allografts. *Cell Tissue Bank*. 2005; 6 :25-31.
- [36] IBGE: Instituto Brasileiro de Geografia e Estatística: <http://www.ibge.gov.br/home/> . Acessado em 15 de julho de 2011.
- [37] Janssen ME, Lam C, Beckham R. Outcomes of allogenic cages in anterior and posterior lumbar interbody fusion. *Eur Spine J*. 2001; 10(Suppl 2):158-68.
- [38] Jorgetti V. Biópsia óssea e análise histomorfométrica. Manual Fleury de diagnóstico de doenças ósteo-metabólicas. 2003. Disponível em: <http://www.fleury.com.br/htmls/cdrom/capitulo5.htm>.
- [39] Junqueira LC, Carneiro J. Histologia básica. 9a ed. Rio de Janeiro :Guanabara-Koogan; 1999. Cap.8, p.111-28: Tecido ósseo.
- [40] Knighton DR, Hunt TK, Thakral KK, Goodson WH 3rd. Role of platelets and fibrin in the healing sequence: an in vivo study of angiogenesis and collagen synthesis. *Ann Surg*. 1982; 196 (4): 379-88.
- [41] Lavernia CJ, Malinin TI, Temple HT, Moreyra CE. Bone and tissue allograft use by orthopaedic surgeons. *J Arthroplasty*. 2004; 19(4):430-35.
- [42] Lindhe J, Karring T, Lang NP. Tratamento periodontal regenerativo. Tratado de periodontia clínica e implantologia oral. 3a ed. Rio de Janeiro: Guanabara Koogan; 1997. p.428-62.
- [43] Malafaya, PB, G. A. Silva, E. T. Baran, R. L. Reis, Curr.Opin. Solid State Mater. Sci. 2002, 6, 283.
- [44] Mecall RA, Rosenfeld AL. The influence of residual ridge resorption patterns on implant fixture placement and tooth position. Part I. *Int J Periodontics Restorative Dent*. 1991; 11(1): 8-23
- [45] Mezzomo RJ, Garbin CA, Schuh C, Rigo L. Critical analysis of studies of immediately loaded implants supporting fixed prostheses in the edentulous maxilla. *Implantnews* 7 (4), 2010.
- [46] Ministério da Saúde : Levantamento das condições de saúde bucal da população brasileira; 2003. Disponível em : <http://dab.saude.gov.br/CNSB/vigilancia.php>
- [47] Moore KL. Anatomia Orientada para a Clínica. 2ª ed. Rio de Janeiro - RJ: Editora Guanabara. 1990.
- [48] Nather A. Organisation, operational aspects and clinical experience of National University of Singapore Bone B. *Ann Acad Med Singapore*. 1991; 20(4):453-7.
- [49] Parfitt AM, Drezner MK, Glorieux FH, Kanis JA, Malluche H, Meunier PJ, et al. Bone histomorphometry: standardization of nomenclature, symbols, and units. Report of the ASBMR Histomorphometry Nomenclature Committee. *J Bone Miner Res*. 1987; 2(6):595-610

- [50] Perren SM, Claes L. Biologia e biomecânica no manejo de fraturas. In: Rüed TP, Murphy WM. *Princípios AO do tratamento de fraturas*. Tradução de Jacques Vissoky. Porto Alegre: Artmed; 2002. p.7-30.
- [51] Phillips GO, Strong DM, Versen RV, Nather A. *Advances in Tissue Banking*. Vol. 4. Worl Scientific . New Jersey, 2000.
- [52] RBT- Registro Brasileiro de Transplantes [ on line] São Paulo: Associação Brasileira de Transplantes de Órgãos; 2006-2010. Disponível em:  
<http://www.abto.org.br/profissionais/profissionais.asp>.
- [53] Santos LAU. Efeito da utilização de plasma rico em plaquetas na osteointegração dos enxertos ósseos homólogos criopreservados : estudo histomorfométrico em coelhos [dissertação]. São Paulo: Faculdade de Medicina, Universidade de São Paulo; 2007. Disponível em:  
<http://www.teses.usp.br/teses/disponiveis/5/5140/tde-16082007-160750/>
- [54] Santos, LAU et al .Banco de Tecidos Musculoesquelético: Da captação ao uso clínico. In: Mancussi e Faro, AC. *Emergencias ortopédicas*. São Paulo. Editora Manole.304p.2011
- [55] Schreurs BW, Busch VJ, Welten ML, Verdonshot N, Slooff TJ, Gardeniers JW. Acetabular reconstruction with impaction bone-grafting and a cemented cup in patients younger than fifty years old. *J Bone Joint Surg Am*. 2004; 86(11):2385-92.
- [56] Sharrard WJW, Collins DH. The fate of human decalcified Bone grafts. *Proc R Soc Med*. 1961; 54:1101-2.
- [57] Smith SE, DeLee JC, Ramamurthy S. Ilioinguinal neuralgia following iliac bone-grafting. Report of two cases and review of the literature. *J Bone Joint Surg Am*.1984;66(8):1306-8.
- [58] Stacchi C, Orsini G, Di Iorio D, Breschi L, Di Lenarda R. Clinical, histologic, and histomorphometric analyses of regenerated bone in maxillary sinus augmentation using fresh frozen human bone allografts. *J Periodontol*. 2008 Sep;79(9):1789-96.
- [59] Thies RS, Bauduy M, Ashton BA, Kurtzberg L, Wozney JM, Rosen V. Recombinant human bone morphogenetic protein-2 induces osteoblastic differentiation in w-20-17 stromal cells. *Endocrinology*. 1992; 130(3):1318-24.
- [60] Tomford WW, Mankin HJ. Bone Banking: Update on methods and materials. *Orthop Clin North Am*. 1999; 30:565-70.
- [61] Tomford WW. Bone allografts: past, present and future. *Cell Tissue Bank*. 2000; 1:105-9.
- [62] Tuominen T. *Native bovine bone morphogenetic protein in the healing of segmental long bone defects* [dissertação]. Oulu: Division of Orthopaedic and Trauma Surgery, University of Oulu; 2001.
- [63] Urist MR, DeLange RJ, Finerman GA. Bone cell differentiation and growth factors. *Science*.1983; 220(4598):680-6.
- [64] Urist MR. Bone formation by auto induction. *Science*.1965; 50:893-99.
- [65] Viscioni A, Dalla Rosa J, Paolin A, Franco M. Fresh-frozen bone: case series of a new grafting material for sinus lift and immediate implants. *J Ir Dent Assoc*. 2010 Aug-Sep;56(4):186-91
- [66]Watzek G. *Endosseous implants:scientific and clinical aspects*. Chicago; Quintessence; 1996.
- [67] Weyts FA, Bos PK, Dinjens WN, van Doorn WJ, van Biezen FC, Weinans H, Verhaar JA. Living cells in 1 of 2 frozen femoral heads. *Acta Orthop Scand*. 2003; 74(6): 661-4.
- [68] Xie Q, Narthi T. Oral status and prosthetic factors related to residual ridge resorption in elderly subjects. *Acta Odonto Scand* 1997; 55:306-13.



## **Current Frontiers in Cryopreservation**

Edited by Prof. Igor Katkov

ISBN 978-953-51-0302-8

Hard cover, 462 pages

**Publisher** InTech

**Published online** 14, March, 2012

**Published in print edition** March, 2012

Almost a decade has passed since the last textbook on the science of cryobiology, *Life in the Frozen State*, was published. Recently, there have been some serious tectonic shifts in cryobiology which were perhaps not seen on the surface but will have a profound effect on both the future of cryobiology and the development of new cryopreservation methods. We feel that it is time to revise the previous paradigms and dogmas, discuss the conceptually new cryobiological ideas, and introduce the recently emerged practical protocols for cryopreservation. The present books, "Current Frontiers in Cryobiology" and "Current Frontiers in Cryopreservation" will serve the purpose. This is a global effort by scientists from 27 countries from all continents and we hope it will be interesting to a wide audience.

### **How to reference**

In order to correctly reference this scholarly work, feel free to copy and paste the following:

Luiz Augusto U. Santos, Alberto T. Croci, Nilson Roberto Armentano, Zeffer Gueno de Oliveira, Arlete M.M. Giovani, Ana Cristina Ferreira Bassit, Graziela Guidoni Maragni, Thais Queiróz Santolin and Lucas da Silva C. Pereira (2012). Cryopreserved Musculoskeletal Tissue Bank in Dentistry: State of the Art and Perspectives, *Current Frontiers in Cryopreservation*, Prof. Igor Katkov (Ed.), ISBN: 978-953-51-0302-8, InTech, Available from: <http://www.intechopen.com/books/current-frontiers-in-cryopreservation/cryopreserved-musculoskeletal-tissue-bank-in-dentistry-state-of-the-art-and-perspectives>

**INTECH**  
open science | open minds

### **InTech Europe**

University Campus STeP Ri  
Slavka Krautzeka 83/A  
51000 Rijeka, Croatia  
Phone: +385 (51) 770 447  
Fax: +385 (51) 686 166  
[www.intechopen.com](http://www.intechopen.com)

### **InTech China**

Unit 405, Office Block, Hotel Equatorial Shanghai  
No.65, Yan An Road (West), Shanghai, 200040, China  
中国上海市延安西路65号上海国际贵都大饭店办公楼405单元  
Phone: +86-21-62489820  
Fax: +86-21-62489821

© 2012 The Author(s). Licensee IntechOpen. This is an open access article distributed under the terms of the [Creative Commons Attribution 3.0 License](https://creativecommons.org/licenses/by/3.0/), which permits unrestricted use, distribution, and reproduction in any medium, provided the original work is properly cited.

IntechOpen

IntechOpen