

We are IntechOpen, the world's leading publisher of Open Access books Built by scientists, for scientists

6,900

Open access books available

186,000

International authors and editors

200M

Downloads

Our authors are among the

154

Countries delivered to

TOP 1%

most cited scientists

12.2%

Contributors from top 500 universities



WEB OF SCIENCE™

Selection of our books indexed in the Book Citation Index
in Web of Science™ Core Collection (BKCI)

Interested in publishing with us?
Contact book.department@intechopen.com

Numbers displayed above are based on latest data collected.
For more information visit www.intechopen.com



Pediatric Cardiac Surgery: A Challenge of Skill and Creativity in Constant Search Results

Miguel Angel Maluf
Cardiovascular Division,
São Paulo Federal University,
Brazil

1. Introduction

Pediatric cardiac surgery has been available for many years in several developing countries, thanks to the hard work and creative adaptation of individuals who were able to stretch the limits of their abilities in spite of the restricted resources. Limited resources were a constant problem forcing us to focus on short-term creativity about tomorrow's needs. A great deal of energy in the form of leadership and negotiations was used in order to encourage people to improve themselves and carry on working diligently despite the low pay.

Leadership, patience, perseverance, dedication, and the capacity to adapt to adversity have been the keys to success. Our sense of mission, commitment, enormous enthusiasm, dedication and clear objectives, supplemented the insufficient support of the institution that never fully met our needs. I have operated more than 4,500 children in Brazil since 1977 when I started my surgical training.

The Department of Pediatric Cardiology, Pediatric Cardiac Surgery and Pediatric Care Unit at São Paulo Federal University (SPFU) – Brazil, started in 1990, an Institutional Program for Diagnosis and Treatment of patients with Congenital Heart Disease.

This Institutional program development by SPFU was established to perform two elective and one emergency surgical procedure per week and complemented with electives operations in others two Private Institutions, performing: 20 operations per months or 250 operations a year.

This program was intended for the care of patients with congenital heart disease, development of protocols and conducts, during the pre-and postoperative period. On the other hand the surgeon's time, taking advantage of his own creativity conceived and developed new surgical techniques or preparation of biological tissue grafts for the construction of new models of heart valves for the remodeling of the right ventricle.

2. New technique in surgical procedure

2.1 Blalock-Taussig shunt in neonates using the brachiocephalic trunk (innominate artery) to ensure long patency

Placement of a Blalock-Taussig (BT) shunt is a "closed-heart" procedure performed as a first stage to correct Tetralogy of Fallot or others cyanotic congenital heart diseases. Placement of

a shunt is usually a temporary measure designed to alleviate symptoms until such time that the patient is in better condition to undergo complete repair. The usual approach is performed by systemic-pulmonary shunts using right or left thoracotomy and today we used median sternotomy approach, for interposition of *polytetrafluoroethylene* (PTFE) vascular graft between the subclavian and pulmonary arteries.

In preterm or low birth weight children it is often found a subclavian artery of small diameter (2.5 to 3.0 mm), which could jeopardize the flow of the shunt due to difference in calibers between this vessel and the PTFE graft, compromising the patient's life. In order to overcome this anatomical difficulty, since 1986, we have been performing technical modifications of the B-T shunt, with PTFE prosthesis anastomosed to the brachiocephalic (innominate artery) trunk, always larger in diameter than the subclavian artery. To this end, the approach by thoracotomy was always done by other side of the descending aorta or the same side of the origin of the brachiocephalic trunk (BCT). This technique is an original contribution of our group.

This approach causes essentially a trauma to the lungs and some difficulty for dissection and definitive surgical ligation during later correction.

Since 1990 we have held the B-T shunt between the innominate artery and the right pulmonary artery, through a median thoracotomy, allowing a more comfortable procedure with hemodynamic and oximetric patient's control.

This technique is viable with advantages over lateral approach due to cutting easier access, vascular structure dissection, avoiding lung trauma; on the other hand, a rapid cardiopulmonary bypass is installed, if hypoxic crisis occurs during the surgical procedure. (Fig. 1)

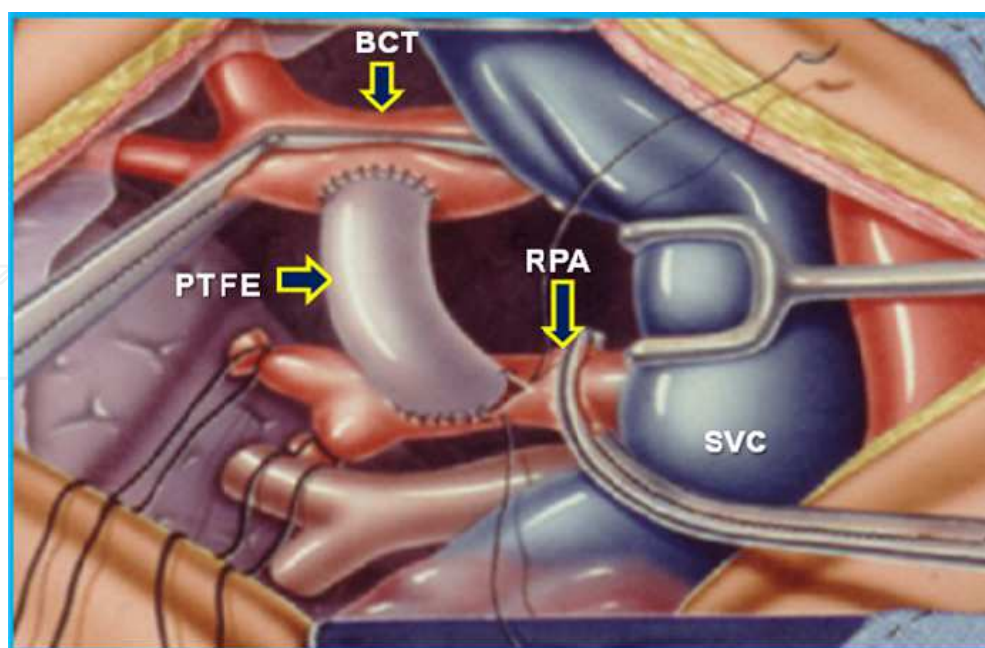


Fig. 1. Plot of the Blalock-Taussig shunt. Right thoracotomy approach and interposition of *polytetrafluoroethylene* (PTFE) graft between the brachiocephalic trunk (BCT) and the right pulmonary artery (RPA). SVC: superior vena cava.

2.2 Patient information

Sixty four patients; mean age of the patients was 29.3 ± 1.0 days (1 day to 17 years-old). Five neonates with mean weigh 2,600 gr (1,800 to 3,000 gr), were operated between 1987 and 1988, with interposition of PTFE graft between the BCT and right pulmonary artery (RPA), due to the reduced diameter of the subclavian artery. Four patients had hospital discharge with pervious BT shunt. The diagnosis of cardiac malformation was: T. of Fallot, pulmonary Atresia with intact ventricular septum, Tricuspid atresia and Univentricular heart.

These first 5 patients were operated by lateral thoracotomy, subsequently, 30 cases were operated using median thoracotomy approach. In all cases it was employed a PTFE graft (3.5 - 4.0 mm) , anastomosed to BCT. (Fig.2)

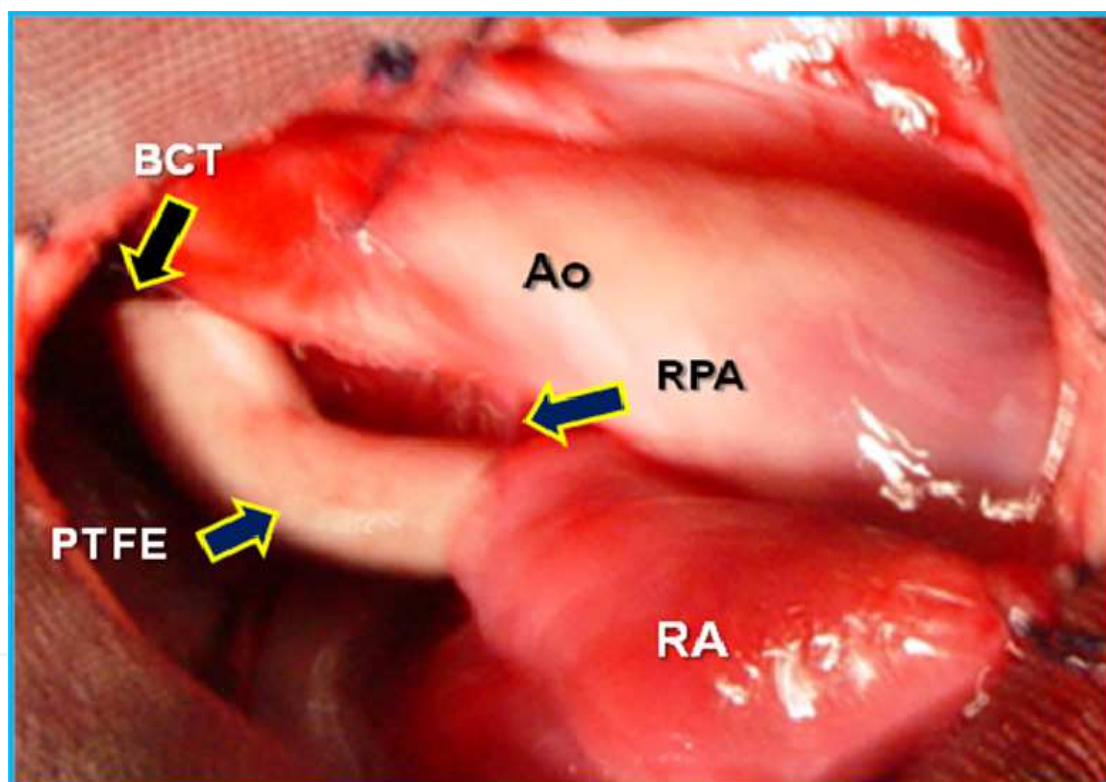


Fig. 2. Surgical picture of Blalock-Taussig shunt in a patient with pulmonary atresia with intact ventricular septum. Median thoracotomy approach: Interposition of polytetrafluoroethylene (PTFE) graft (arrow) between the brachiocephalic trunk (BCT) and the right pulmonary artery (RPA). RA: right atrium, Ao: aorta.

2.3 Results

There were 2 (5.7%) deaths in this group of 35 patients during the early postoperative period by sepsis and respiratory distress. Thirty three patients were submitted to Doppler-echocardiogram exam; all patients presented pervious B-T shunt.

3. Total cavopulmonary connection for treatment of the univentricular heart – Staged strategy

3.1 First stage: Bidirectional Glenn

The Fontan repair and its modifications can be performed in selected groups of patients which report relatively low rates of mortality. Among the later modifications of the Fontan-type procedure, a significant alteration was introduced by de Leval and associates when they described the Intracardiac cavopulmonary connection (ICPC). The modified Fontan procedure represents the final stage for the palliation of hearts with single-ventricle physiology.

The introduction of a bidirectional Glenn (BDG) procedure preceding an ICPC extends the indication for the Fontan procedure. High-risk Fontan candidates who have undergone BDG and staged ICPC (*staged strategy*) have exhibited excellent clinical results. However, the exact mechanism for the superiority of BDG is still poorly understood.

In addition, several management strategies have been incorporated in order to reduce the mortality: universal risk factors that have resulted in better patient selection; the use of tunnel fenestration; and the use of modified ultrafiltration after cardiopulmonary bypass (CPB).

Many reports discussed the importance of the pulmonary artery size and systemic ventricular function in Fontan candidates. A few studies undertaken to investigate in detail the hemodynamic conditions in Fontan circulation focusing on the ventricular efficiency.

When the ICPC was performed, the lower resting heart rate or the higher peak heart rate, are frequently part of the operation history which are each weakly associated with better physical function.

Cardiac arrhythmias are very common in patients submitted to intracardiac lateral tunnel using a long suture line on the right atrial wall.

3.2 Second stage: Inferior vena cava to pulmonary artery connection

3.2.1 Patient information

In our Institution, following the Great Ormond Street Hospital's protocol behavior the total cavopulmonary connection is performed in staged strategy: in March 1990, we performed the first BDG (1st stage) and in April, 1992 the same patient was completed to TCPC (2nd stage), with good results.

This successful technique was adopted, rapidly, by Institutions with Pediatric Cardiovascular Surgery, all over the country, and abandoning the atrio-pulmonary anastomosis.

Between March, 1990 and December, 2008; 105 patients were submitted to BDG in our Institution. In this study we included 52 patients of these series, consisting of 27 females and 25 males, mean age of the patients was 3.3 ± 1.0 years (1 to 8 years-old) and underwent ICPC. These patients were a consecutive series. Table1.

Diagnosis	Patients	(%)
Tricuspid Atresia	25	(48.2)
Single Ventricle	16	(30.7)
Pul. Atresia w / IVS	11	(21.1)

Pul. : pulmonary; w: with; IVS: intact ventricular septum

Table 1. Anatomic Diagnosis

3.3 Hemodynamic variables

The preoperative hemodynamic variables: heart rate, mean pulmonary artery pressure, ejection fraction and Nakata pulmonary arterial index were evaluated in all patients, according to the protocol established by our Institution.

The operative procedures before BDG were as follows: a modified Blalock-Taussig shunt was performed in 39 patients and pulmonary artery banding in 9 patients. In 52 (49.5%) patients the ICPC was indicated after the first stage of the BDG. Figure 3.

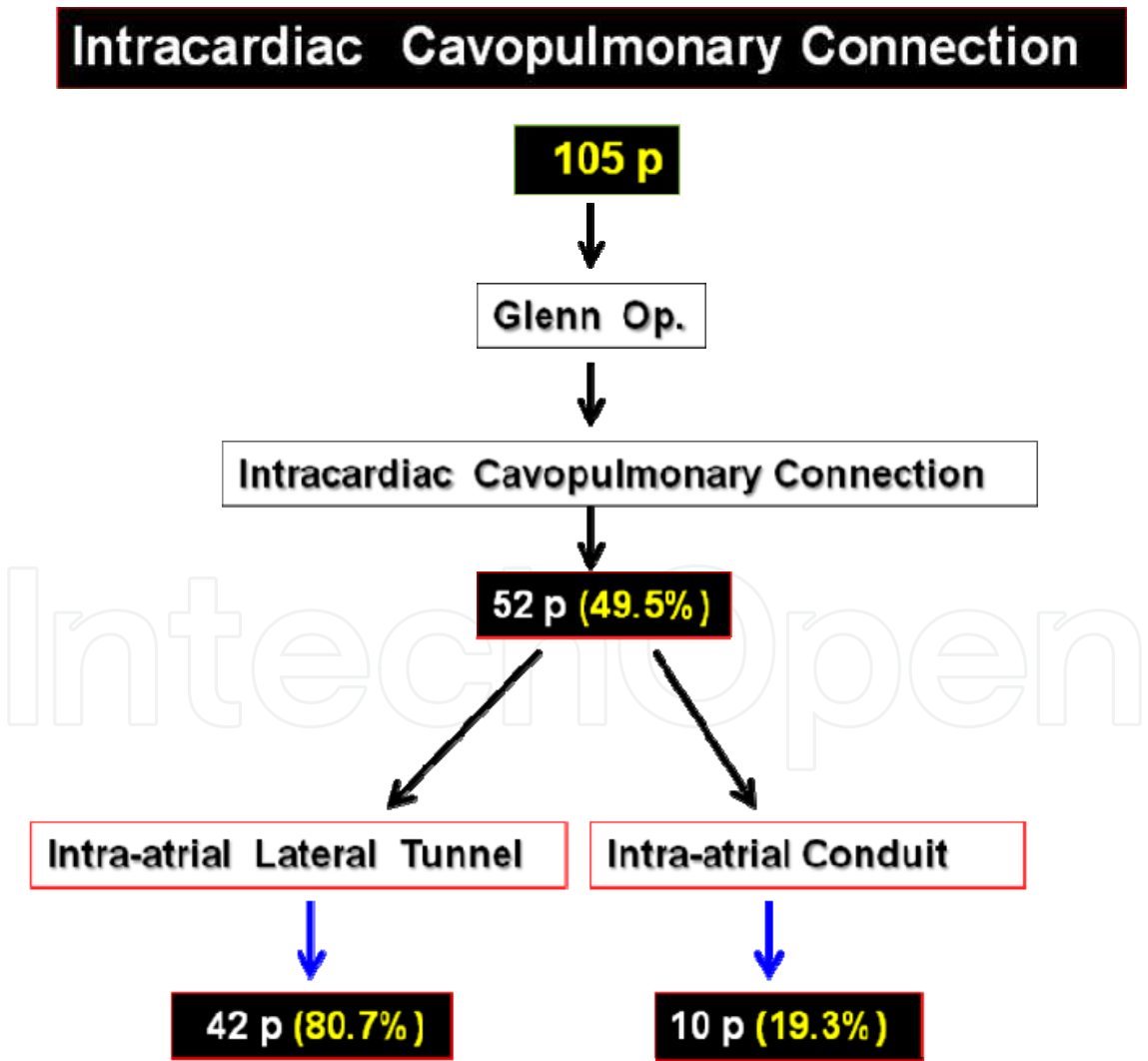


Fig. 3. Staged Intracardiac cavopulmonary connection.

3.4 Patient inclusion criteria

The indication for intra-atrial cavopulmonary anastomosis surgery included patients:

Diagnosed with univentricular heart.

- Previously submitted to BDG.
- Presenting cyanosis and decreased exercise tolerance
- Preserved ventricular function: EF >50 %, end-diastolic pressure of the systemic ventricle <11 mm Hg.
- Pulmonary pressure < 18 mmHg
- Pulmonary resistance < 2.0 wood units
- Nakata index > 250 mm² x m²
- Staged period (BDG – ICPC) < 5 years
- New York Heart Association functional class I-II

3.5 Patient exclusion criteria

- Presence of pulmonary fistulae
- Low ventricle function: EF < 50 %, end-diastolic pressure of the systemic ventricle 11 mm Hg or higher
- Pulmonary pressure > 18 mmHg
- Pulmonary resistance > 2.0 wood units
- Nakata index < 250 mm² x m²
- Staged period (BDG – ICPC) > 5 years
- New York Heart Association functional class III or higher

Fifty two patients had a previous bidirectional cavopulmonary shunt performed by direct end-to-side anastomosis between the SVC and the right pulmonary artery (RPA) (bidirectional Glenn). This group was referred to ICPC 1 to 5 years later: In 42 (80.7 %) cases it was indicated an intra-atrial lateral tunnel and in the last 10 (19.2%) consecutive patients, an intra-atrial conduit technique was performed.

3.6 Operative technique

Anesthesia was performed by the standard intravenous access with fentanyl, midazolam and pancuronium, for muscle relaxation. Although the ICPC was performed by Aortic SVC and inferior vena cava (IVC) cannulation to install a cardiopulmonary bypass (CPB) and perform the surgical approach with beating heart. When heart arrest was necessary, myocardial preservation was achieved with a cold blood cardioplegic solution. We reported our surgical technique in previous publications.

3.7 Intra-atrial lateral tunnel

Forty two (80.7%) patients had a previous BDG shunt performed by direct end-to-side anastomosis between the SVC and the RPA. Figure 4. These patients were operated by the intra-atrial lateral tunnel technique performed with a bovine pericardium patch. Figure 5.

The details of the surgical procedure employed are described as follows: After dissection of BDG, the operation was performed using CPB, moderated hypothermia and beating heart.

After the right atrium approach, the lateral tunnel was performed using a bovine pericardium patch sutured around the IVC *ostium* and on the lateral right atrium wall. The upper tip of the tunnel is connected to the SVC *ostium*. The RPA is open and stitched to the lateral tunnel by the proximal tip of the SVC. Finally, the anastomosis is enlarged using a bovine pericardium patch.

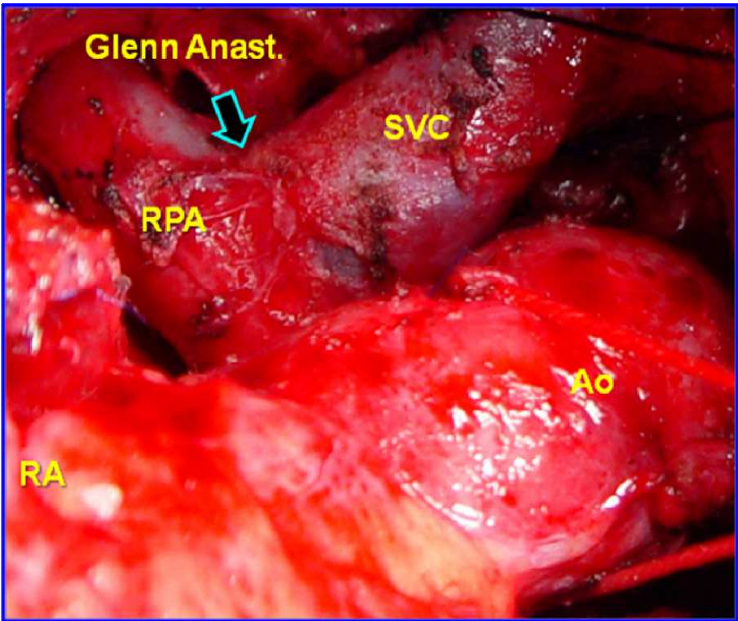


Fig. 4. Surgical photography- Bidirectional Glenn: Anastomosis between distal Superior Vena Cava (SVC) and Right Pulmonary Artery (RPA). RA: right atrium, Ao: aorta.

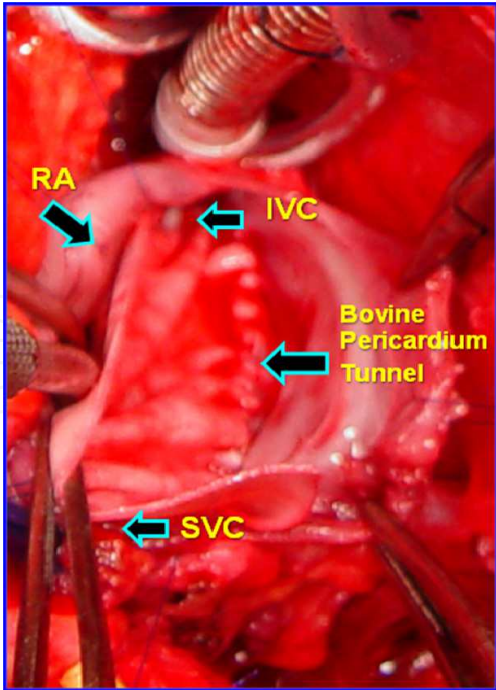


Fig. 5. Surgical photography- An intra-atrial lateral tunnel operation was performed suturing a bovine pericardium patch to the lateral right atrium wall. IVC: Inferior vena cava; SVC: Superior vena cava; RA: Right atrium.

3.8 Intra-atrial conduit

In the last 10 (19.2%) consecutive patients a technique modification was introduced to avoid the lateral suture in the free wall of the right atrium (RA) and cardiac arrhythmias. Figure 6.

After a longitudinal RA approach, a corrugated bovine pericardium tube, measuring 18 to 20 mm of diameter was sutured around the ostium of the IVC and SVC.

Finally, the connection with an RPA was performed using the same technique of the lateral tunnel. This technique is a original contribution of our group.

In both techniques a 4 mm trap-door type fenestration was performed promoting its spontaneous occlusion during the follow-up.

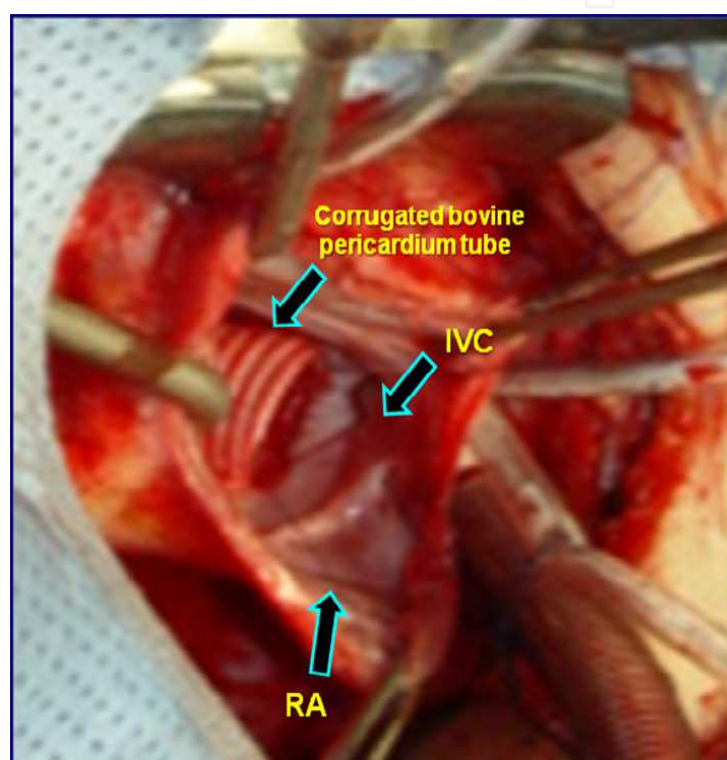


Fig. 6. Surgical photography- The intra-atrial conduit operation is performed, implanting a corrugated bovine pericardium tube around the ostium of the superior and inferior vena cava.

3.9 Statistical analysis

The relations of cardiac arrhythmias between two groups were evaluated with the exact Fisher test. A p value of less than 0.05 or 5% was considered to be significant.

3.10 Results

There were 2 hospital deaths (mortality 2.8%) in the intra-atrial lateral tunnel group: one patient presented acute renal insufficiency not reverted with peritoneal dialysis and compromised ventricular function, resulting in death 30 days after operation. The other patient presented multiple-organ failure resulting in death, 20 days after operation.

There were no records of mortality among the 10 (19.3%) patients submitted to intra-atrial conduit implant.

The mean cardiopulmonary bypass time was 114 ± 27 minutes (range 50 to 152). Thirty patients underwent aortic cross-clamping, and the mean aortic cross-clamp time was 42 ± 33 minutes (range 20 to 80). The mean duration of the mechanical ventilation was 12 hours (range 0 to 204). The average duration of intensive care unit stay was 5 days (range 3 to 29), the average duration of chest tube drainage was 6 days (range 2 to 38), the average duration of postoperative hospital stay was 16 days (range 7 to 60), and the average follow-up period was 87 ± 45 months (range 6 to 204). All of these patients received anti-platelet drug therapy during the follow-up. Table 2

	Variable Time	
	mean	range
CPB (min)	114 ± 27	50 - 152
Aortic Clamping (min)	42 ± 33	20 - 80
Mechanical ventilation (h)	12 ± 7	0 - 204
Intensive Care Unit (days)	5 ± 3	3 - 29
Chest tube drain (days)	6 ± 4	2 - 38
Hospital stay (days)	16 ± 8	7 - 60

CPB: cardiopulmonary bypass; min: minutes

Table 2. Operative date

Postoperative problems were minimal. Medication applied during the hospital stay for symptoms of fluid retention, congestive heart failure or both included digoxin, diuretics and captopril. Five patients had occasional early-morning facial edema; all of them remained on a regimen of diuretics, captopril and milrinone.

There was a significant improvement of O2 saturation after surgery in both groups: Intra-atrial lateral group, SO2: before M=78 %, after M= 92 %; Intra-atrial conduit, SO2: before M= 79 %, after M= 93 %.

The postoperative data were presented at Table 3.

Variables	Intra-atrial lateral tunnel	Intra-atrial conduit	p
Patients	42 pat	10 pat	----
BDG	42 pat	10 pat	----
Fenestration: tunnel/conduit	42 pat	10 pat.(trap-door)	----
Cardiac arrhythmias	13 pat. (30.9%)	0 pat. (0%)	0.048*
Take Down op.	0 pat	0 pat.	----
Death	2 pat	0 pat.	0.649
Mortality	4.76 %	0%	----

*Statistic significant. BDG: bidirectional Glenn; Sat: saturation; pat.: patients; Op: operation

Table 3. Post-operative data

In the intra-atrial lateral tunnel group: consisted of 40 (80%) surviving patients, it was observed the presence of cardiac arrhythmias in 13 (30.9%) cases and there were statistical differences ($p=0.048$) when comparing both groups. Ten (23.8%) patients received anti-arrhythmic drugs daily.

One patient developed late postoperative paroxysmal supraventricular tachycardia and was treated with a selective β blocker.

However, no arrhythmias were detected in the intra-atrial conduit group.

All patients were submitted to periodic clinical and cardiac imaging exam: Doppler-echocardiogram each 6 month; MNR and CT after 2 years of operation. The details of the intra-atrial conduit are shown in the Magnetic nuclear resonance study; in this group there were no reports of open fenestration after 2 years of operation according to the MNR exam. Figure 7.

The Kaplan-Meier actuarial curve shows 96.1 % of surviving patients with Intra-atrial tunnel. In that period of time there had not been detected any thromboembolism events using Doppler-echocardiography criteria.

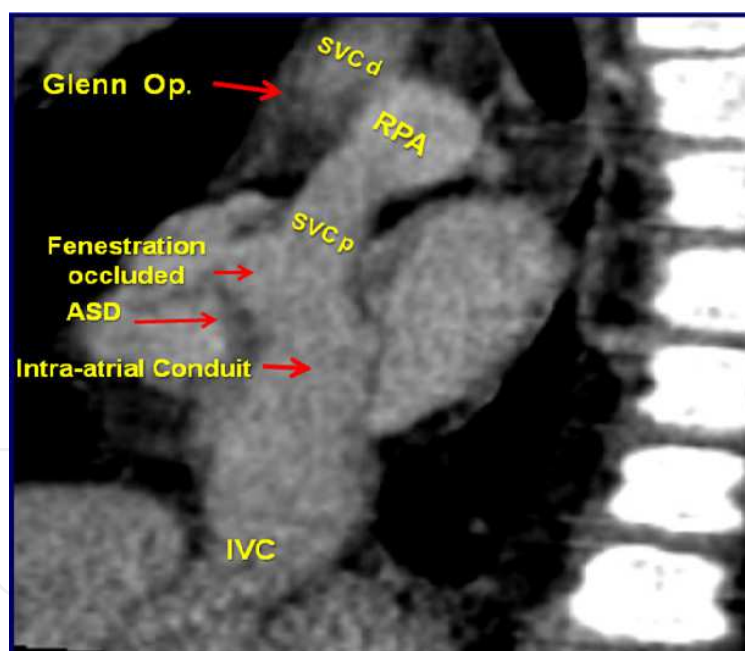


Fig. 7. Image of the Magnetic Nuclear Resonance performed in a patient 3 years after of Intra-atrial conduit implantation (a variant procedure technique). SVC: superior vena cava, p: proximal, d: distal; IVC: inferior vena cava; RPA: right pulmonary artery; ASD: atrial septal defect.

However, no reoperation had been performed at that moment. Figure 8,9.

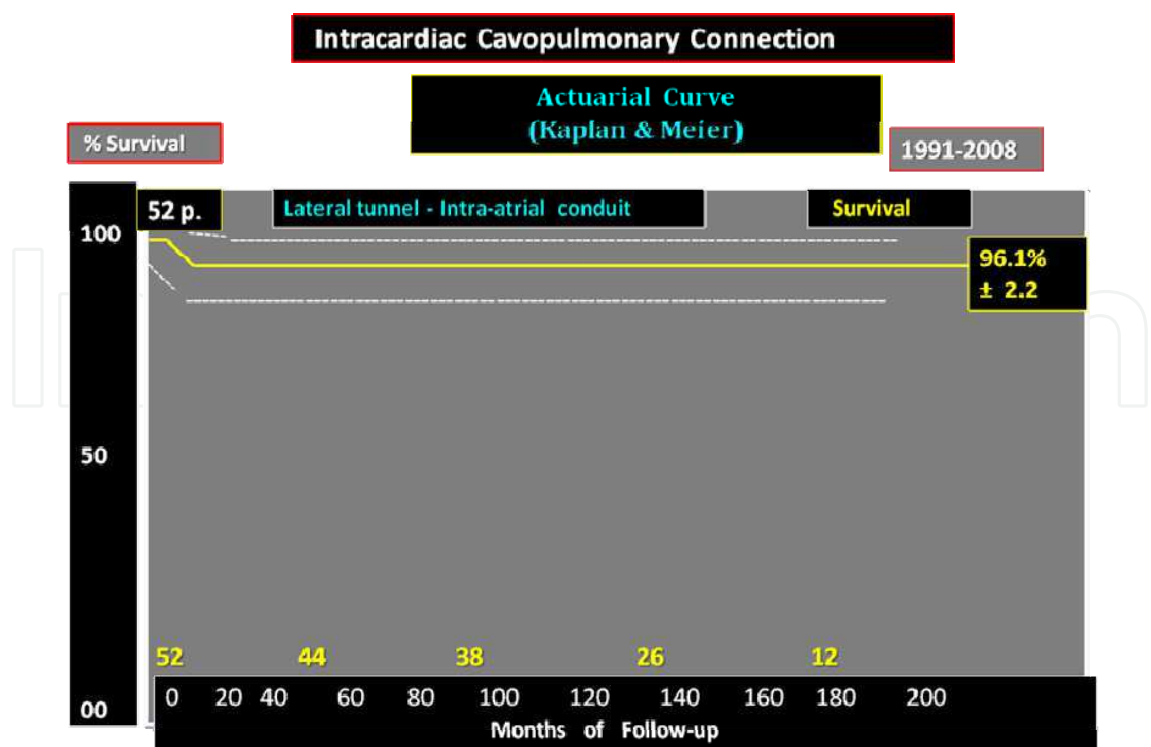


Fig. 8. Actuarial curve using the Kaplan-Meier method to analyze the surgical and follow-up results of Intracardiac cavopulmonary connection.

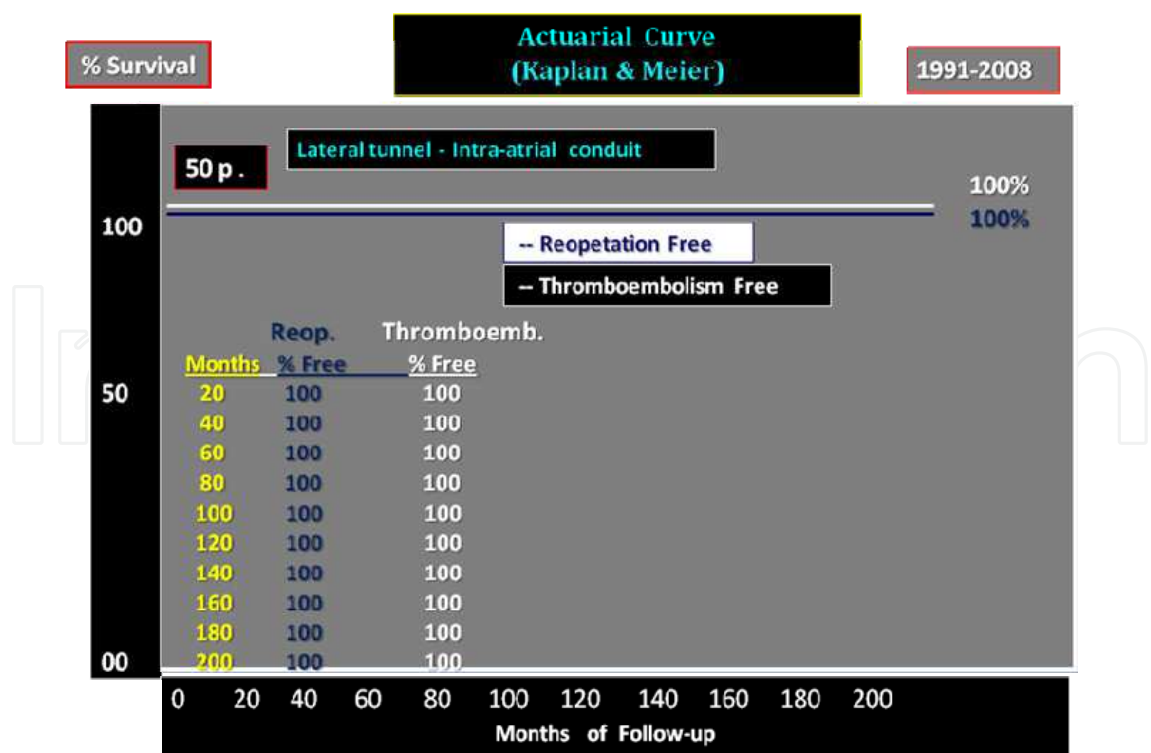


Fig. 9. Probability of overall reoperation and thromboembolism incidence in the last 9 years, after performing the lateral tunnel – Intracardiac conduit surgery.

3.11 Discussion

Throughout the years, the experience with Fontan operation has been increasing and has opened the way to a much wider application of this principle. The subsequent evolution of the cavopulmonary connection, thus avoiding stasis of the blood in the right atrium as seen in the atrial-pulmonary anastomosis or the turbulence seen in cases of atrial-ventricular-arterial connections. The hemodynamic concept of Jonas & Castaneda demonstrated the advantages of laminar flows, with less outflow and lower incidence of arrhythmias and thrombosis, introducing new surgical techniques. A number of major risk factors have been identified and managed by several modifications of the original Fontan procedure and late outcome of the Fontan circulation is encouraging. Ventricular morphology, surgical techniques and fenestration do not appear to influence early or late outcome. In the preoperative preparation of the patient is important to detect the impaired ventricular function and elevated pulmonary artery pressure because it has an adverse influence on both early and late outcome.

Reoperations are common with small preoperative pulmonary artery size being an additional risk factor.

This report focused its attention on the only two different variant options of intracardiac connection of the superior vena cava and inferior vena cava with the right pulmonary artery: intra-atrial lateral tunnel and intra-atrial conduit implantation, in order to reduce the cardiac arrhythmias and tunnel thrombosis.

In our Institution, the total cavopulmonary connection is performed in a staged strategy. An alternative approach is to make connections between both ends of the divided superior vena cava and the pulmonary artery and to place a patch within the right atrium at the entrance site of the superior vena cava. This procedure was performed at the São Paulo Federal University, being the first institution in the country to adopt this procedure, and then rapidly expand to other pediatric cardiac surgery centers in the country, looking for successful results. To complete the Fontan operation, the removal of this patch facilitates the connection between the IVC to RPA, with the construction of an intra-atrial tunnel or implantation of intra-atrial corrugated conduit of bovine pericardium, sutured to IVC and SVC ostium, facilitated by the proximal stump of the SVC with the RPA. This technique is an original contribution of our group.

In this series, 40 surviving patients with lateral tunnel Fontan presented 13 (30.9%) cases with cardiac arrhythmias. To prevent frequent cardiac arrhythmias we changed the lateral tunnel technique to the intra-atrial conduit implantation. A corrugated bovine pericardium tube is sutured around the ostium of the inferior vena cava and superior vena cava avoiding the right atrium wall stitched line. None of the last 10 patients, with intra-atrial conduit, submitted to Holter study during the follow-up, presented cardiac arrhythmias in 3 different moments: at rest, during exercise or sleeping. No patient was referred to pacemaker implant.

The postoperative period, early and late arrhythmias after a Fontan operation seem to be a consequence of adverse hemodynamic function. In the early follow-up is, therefore, poor even when the patient is restored to the sinus rhythm. Medical and surgical modifications in order to improve the hemodynamic disturbances associated with arrhythmias are therefore indicated.

Other authors described that Fontan conversion with concomitant arrhythmia surgery and permanent pacemaker placement are safe and improve the New York Heart Association functional class, and has a low incidence of recurrent arrhythmias. In most patients, concomitant permanent pacemakers are needed. The intra-atrial lateral tunnel (ILT) operation results in excellent midterm outcome even when used in patients with complex anatomy.

The incidence of postoperative atrial tachyarrhythmias is low and depends largely on the underlying cardiac morphology and incidence of preoperative arrhythmia. The good midterm outcome after an ILT operation should serve as a basis for comparison with other surgical alternatives to complete the Fontan circulation. Outcome after staged ILT operations is good, with comparable freedom from late re-operations and freedom from Fontan failure at 6-year follow-up. Right ventricular morphology was identified as a risk factor for arrhythmias.

The staged strategy is considered to be one of the most important factors for obtaining excellent clinical results in the treatment of high-risk Fontan candidates, with low mortality. The volume load reduction of bidirectional Glenn preceding intracardiac cavopulmonary connection allowed for any afterload mismatch to be corrected, thereby improving ventricular efficiency after staged intracardiac cavopulmonary connection in clinical patients.

The most significant findings in patients submitted to Fontan procedure who underwent a staged operation are: 1- The volume-load reduction of the systemic ventricle, resulted in an improvement of the contractility in both: after bidirectional Glenn and after staged intracardiac cavopulmonary connection; 2- Afterload increased both: after bidirectional Glenn and after staged intracardiac cavopulmonary connection and 3- These changes resulted in an improvement of ventricular efficiency during the interval period between bidirectional Glenn and intracardiac cavopulmonary connection.

Improved early morbidity and mortality after Fontan operation was presented in clinical experience of the Mayo Clinic, from 1987 to 1992.

In our Institution the study of the first 18 surviving patients submitted to bidirectional Glenn were available with cineangiographic exam showed a significant reduction in the total index of the left pulmonary artery after mean follow-up of 23.6 months.

An alternative approach to homogeneous distribution of SVC blood flow into RPA and LPA was performing of the hemi-Fontan operation that includes atriopulmonary anastomosis employing an atriopulmonary patch directs superior vena cava flow into both pulmonary arteries and inferior vena cava flow into the ventricle, thus maintaining cardiac output (modified Glenn physiology).

The extracardiac cavopulmonary connection is other alternative to cavopulmonary connection, utilizing a non-valved conduit is gradually becoming accepted as a new alternative for the surgical treatment of certain complex congenital heart diseases. Among the advantages of the use of an extracardiac conduit is the possibility of employing it under normothermic cardiopulmonary bypass with a beating heart, which is important for the preservation of the left ventricular function.

The extracardiac cavopulmonary connection, however, it is not always beneficial and among the complications that may arise are: thromboembolism, cellular hyperplasia, fibrosis and calcification and the absence of growth. All are severe complications, which can occur in the early follow-up or even months or years after the intervention and shadow the late evolution.

Another recent national experience shows: 18 consecutive patients with univentricular heart submitted to total cavopulmonary connection. These patients were operated using the extracardiac conduit procedure to make the connection between the inferior vena cava and the pulmonary circulation. Three patients died in the immediate post-operative period (hospital mortality rate: 16.6%). There were four cases of thrombosis with one case evolving to death. All the four cases were submitted to re-intervention. Apart from the case described above, a fifth case suffered from thrombosis and progressive calcification, which led to total occlusion of the conduit.

Due to this fact, the patients in this study were routinely prescribed warfarin sodium, using salicylic acetyl acid only when the use of the former was impossible or after the 12 post-operative month for the rest of their lives. This, however, did not prevent the occurrence of thrombosis in the conduit, initiating within 24 hours in one of the patients and with total occlusion of the tube, which forced replacement but this did not impede a lethal result of the complication.

The Fontan operation in its variant ways of performance was always associated with approximately 20% of thromboembolism in the post-operative period. The Kaplan & Meier actuarial curve in our series of 50 survival patients operated with the intra-atrial connection technique, followed-up by 12 to 204 months by Doppler-echocardiogram, MNR and CT reported survival of 96,1%, free of reoperations and we have not reported thromboembolism events in this period. Figure 6, 7, 8. All of our patients received anti-platelet drugs (salicylic acetyl acid), only.

3.12 Conclusion

The Bidirectional cavopulmonary anastomosis with intracardiac repair is a viable alternative for patients with RV hypoplasia. Early unloading of the functional univentricular heart by means of BDG allowed a good condition for completing the intra-atrial cavopulmonary connection.

Technical modifications of the intra-atrial operation (intra-atrial conduit implanted) have reported no cardiac arrhythmias and no prosthesis thrombosis during the follow-up. The modified surgical procedure can be a good alternative to the Fontan procedure in suitable patients.

4. Modified senning operation for surgical correction of simple transposition of the great arteries

Survival functional status and quality of life of patients with transposition of the great arteries (TGA), after an atrial switch operation (Senning or Mustard procedure) are reported to be reasonably good within the first two decades of life. However, in some cases the function of the systemic right ventricle deteriorates, severe tricuspid regurgitation develops or the patients suffer from arrhythmias.

Several strategies are proposed to handle those patients with failing right ventricle, such as: tricuspid valve repair, conversion to arterial switch or heart transplantation. In most of the cases, these procedures are performed after the right ventricular function has already deteriorated, as a consequence of high operative mortality. In the present study we focused on the analysis of the long-term results of atrial switch procedure (Senning operation), to identify risk factors for long-term outcome and quality of life, in a group of patients with simple TGA.

4.1 Patient information

From July 1990 to December 2000, 40 consecutive patients with TGA were submitted to palliative atrial switch (Senning operation); 37 cases had atrial septal defect (ASD) and 3 cases had ASD associated to small muscular ventricular septal defect (VSD). These patients were operated the cardiovascular Division of São Paulo Federal University (UNIFESP).

Out of 39 (97.5%) surviving patients, thirty six (94.8%) cases were included in a retrospective follow-up study. Three patients, living overseas were excluded from this study.

The patients age at the moment of surgical correction was 1 to 11 months (mean 5.3 months); male 21 (52.4%). The clinic diagnostic was confirmed by Doppler-echocardiogram: d-TGA with ASD, in 37 (92.5%) cases, and ASD associated to small muscular VSD (size: 3 to 4 mm of diameter), in three (7,5%) cases, were present. All patients were submitted to Rashkind procedure prior to surgery. Table 3.

Characteristics	Patients(%)	Mean	(range)
Age (months)	-----	5.3	(1-11)
Male	21 (52.4)	----	-----
TGA + ASD	37 (92.5)	----	-----
TGA + ASD + VSD *	03 (7.5)	----	-----
Rashkind procedure	40 (100)	----	-----

TGA: Transposition of the great arteries; ASD: Atrial septal defect; VSD: Ventricular septal defect. * Small muscular ventricular septal defect.

Table 3. Preoperative characteristics of patients

4.2 Operative technique

The surgical approach was performed by median sternotomy, employing hypothermic cardiopulmonary bypass (CPB), after vena cava and aortic cannulation; anterograde cold blood cardioplegia was used for myocardial protection, administrated every 20 minutes. During bypass assistance it was employed the conventional ultrafiltration (CUF) and after July 1996, it was associated with modified ultrafiltration (MUF), after the bypass was discontinued. In all patients it was used the Subramanian’s technique modification using left atrial appendix flap, for reconstruction of the new atrial septum and dispense the use of any prosthetic tissue. Figure 10. In order to avoid tunnel stenosis, the Hegar dilator was used to measure the diameter of the vena cava ostium Figure 11. No patient required a more extensive enlargement of the right or left atrium Figure 12,13 and interrupted suture was applied, around the superior and inferior vena cava to avoid external restriction. Figure 4.

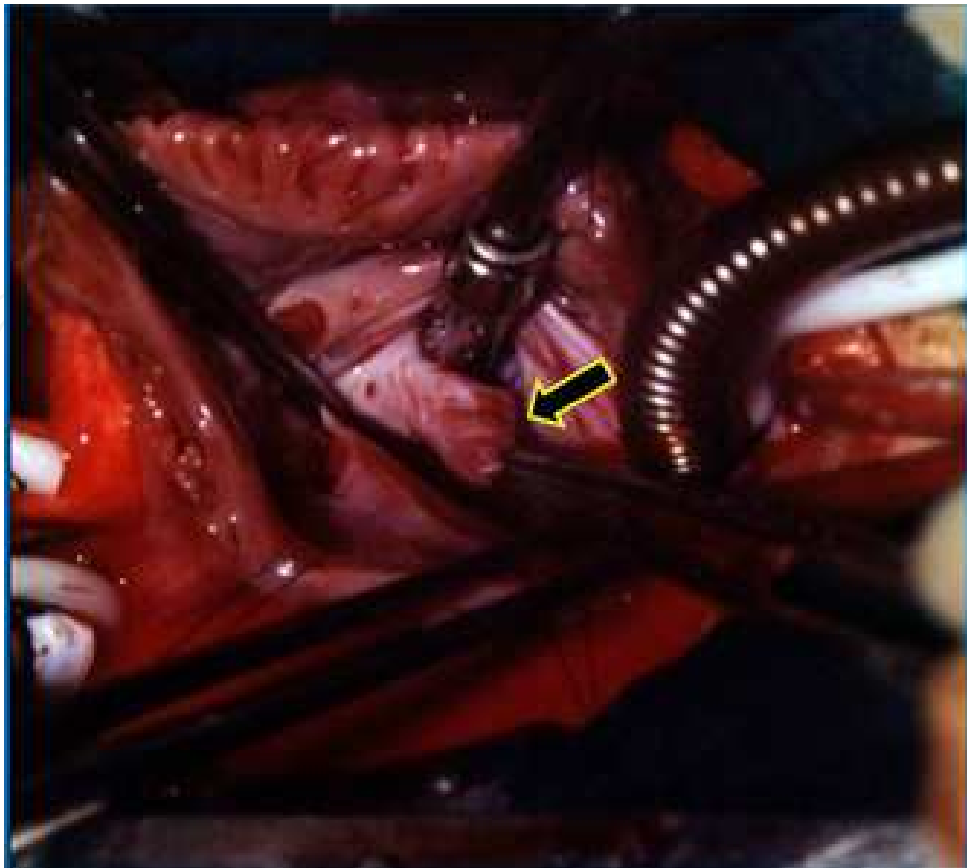

Fig. 10. Operative photography. Right atriotomy exposure of the left atrial appendix (arrow) used for the closure of the atrial septal defect and construction of the roof of the left atrial tunnel.

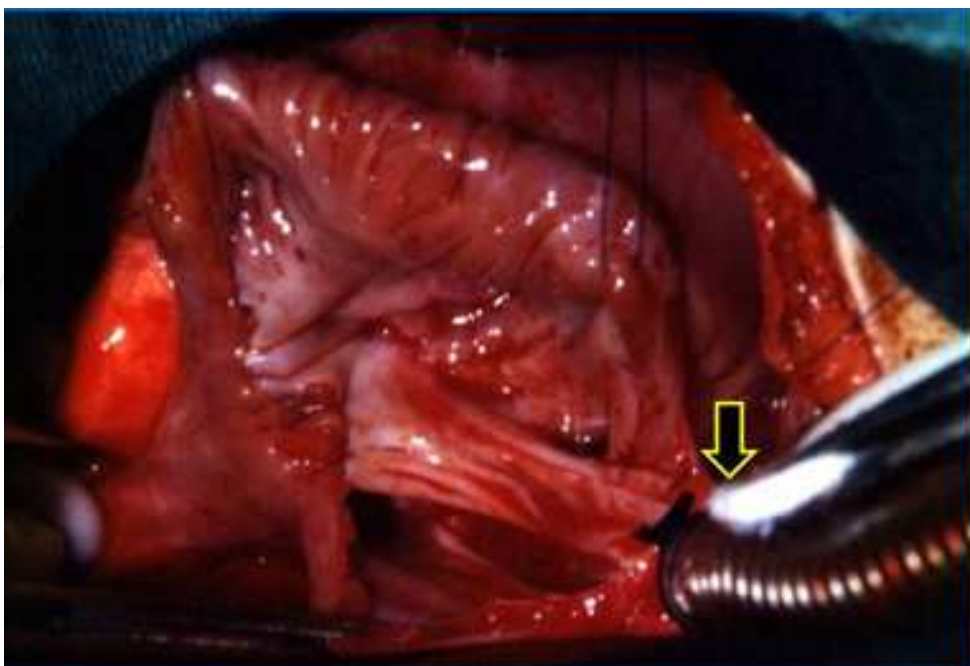


Fig. 11. Operative photography. Right atriotomy exposure of the vena cava tunnel. The Hegar dilator (arrow), was employed to measure the inferior vena cava ostium.

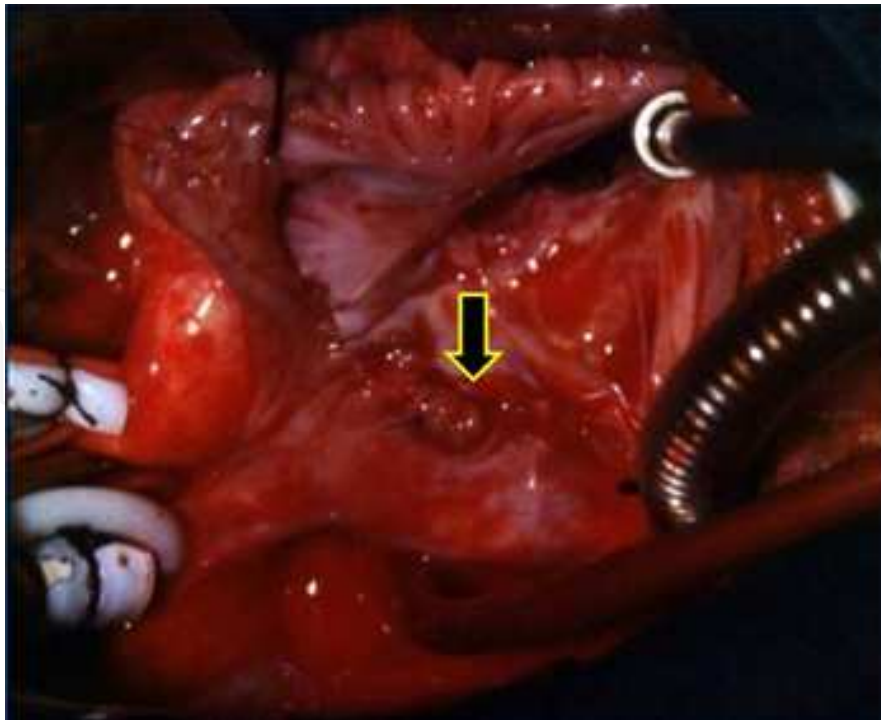


Fig. 12. Operative photography. Right atriotomy exposure of the vena cava tunnel finished. (arrow)

Small muscular VSD was kept open in three patients. The CPB was discontinued and whenever necessary administered inotropic drugs and temporary atrio-ventricular pacemaker stimulation in order to support the hemodynamic performance.

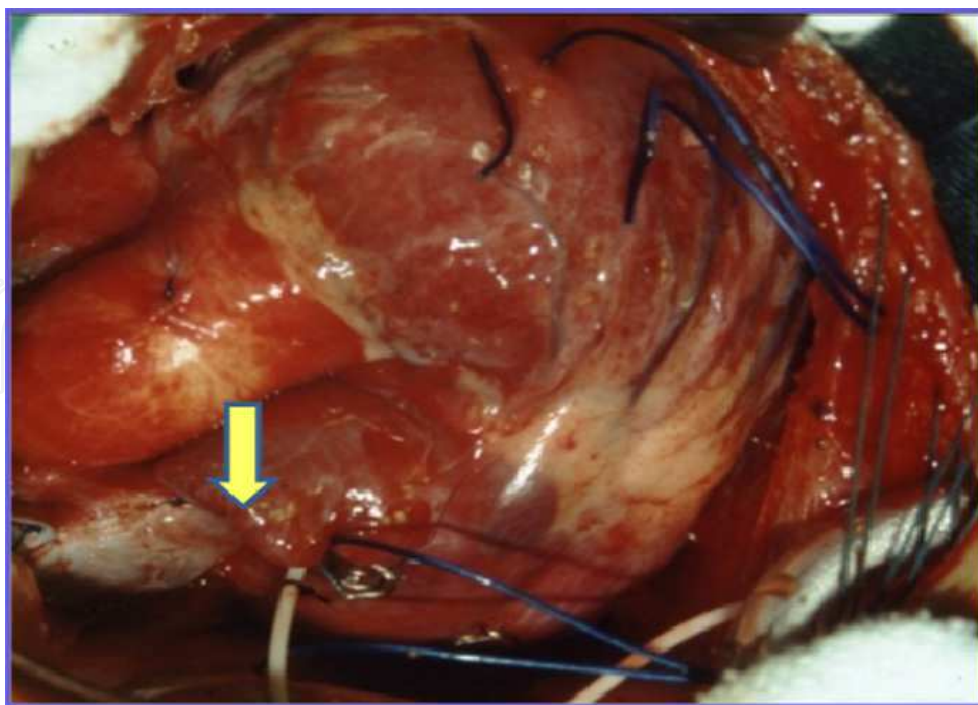


Fig. 13. Operative photography. Surgery conclusion; we can observe the Interrupted suture over the superior vena cava (arrow).

4.3 Statistical analysis

The surviving patients curve and relevant events, during the follow-up were performed according to the Kaplan-Meier’s method, comparing 2or more functions by the long-rank test. For all tests, a *p* value of less than 0.05 was considered significant.

4.4 Results

There was only one death (1/39) (mortality=2.5%), during the follow-up time (mean: 14.7 +/- 3.1 years), a 16 year-old patient with bipolar disease that due to his disease committed suicide. The actuarial survival was 97.5% (simple or with little VSD, TGA). The probability of staying in sinus rhythm, in 38 surviving patients was 71.1% (11 cases lost sinus rhythm).Eight (21.0%) patients presented moderate dysfunction of RV; three cases have mild RV dysfunction in the pre-operative period.

Preserved RV function was observed in 30 (78.9%) cases, 10 to 20 years after operation. The incidence of lost sinus rhythm and right ventricular dysfunction, increased gradually over time. Right ventricular dysfunction and active arrhythmias were not risk factors for late death.

All patients are free of reoperations and definitive pacemaker implantation. Table 4.

Procedure	Patients	
	N°	(%)
Senning operation	40	(100)
Small muscular VSD (maintained open)	03	(7.5)
Moderated dysfunction of RV	03	(7.5)

VSD: Ventricular septal defect. RV: right ventricle

Table 4. Operative procedure: Senning operation

4.5 Late follow-up

Thirty eight (97.5%) surviving patients had mean follow-up of 177months. Three patients were lost during the follow-up (living overseas). Thirty five surviving patients (92.1%) were submitted to Doppler –echocardiogram study Figure 14, and Holter study, during 3 periods of follow-up: 0 to 60 months; 60 to 120 months and > 120 months and the results of exams were:

Tricuspid valve dysfunction in 7 (20.0%), 8 (22.8%) and 10 (28.5%) cases, respectively. Mean tricuspid insufficiency in 7 (70.0%) cases and moderate insufficiency in 3 (30.0%) cases.

Right ventricular dysfunction in 3 (8.5%), 6 (17.1%), 8 (22.8%) cases, in the respective period.

Cardiac arrhythmias in 5 (14.2%), 7 (20.0%) and 8 (22.8%)cases, of each respective period. Junction rhythm, in 5 (62.5%) cases, Atrial fibrillation in 2 (25.0%) cases and Atrial flutter in 1 (12.5%) case.

Functional status: 28 (80%) patients were in functional class I and 7 (20%) cases, in functional class II (NYHA).Table 5.

The Kaplan – Meier survival curve (Fig. 15) shows: late survival rate was 97.4 % in the mean period of 14.7 years of follow-up. All patients are free of definitive pacemaker implantation and free of reoperation by right or left atrial tunnel stenosis repair, tricuspid valve plastic repair or right ventricle dysfunction.

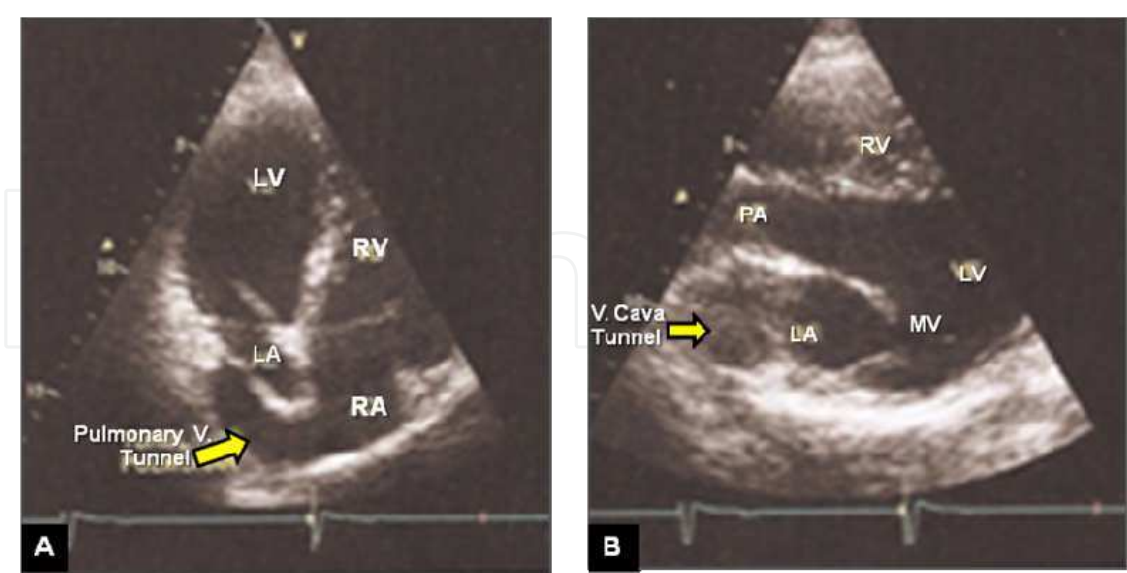


Fig. 14. Post-operative Doppler-echocardiogram study. Patient: male, 16 years-old, in late follow-up of Senning operation. A- Pulmonary vein tunnel draining into right atrium (arrow). B- Vena cava tunnel draining into the left atrium. RA: right atrium; LA: left atrium; RV: right ventricle; LV: left ventricle; V: vena .

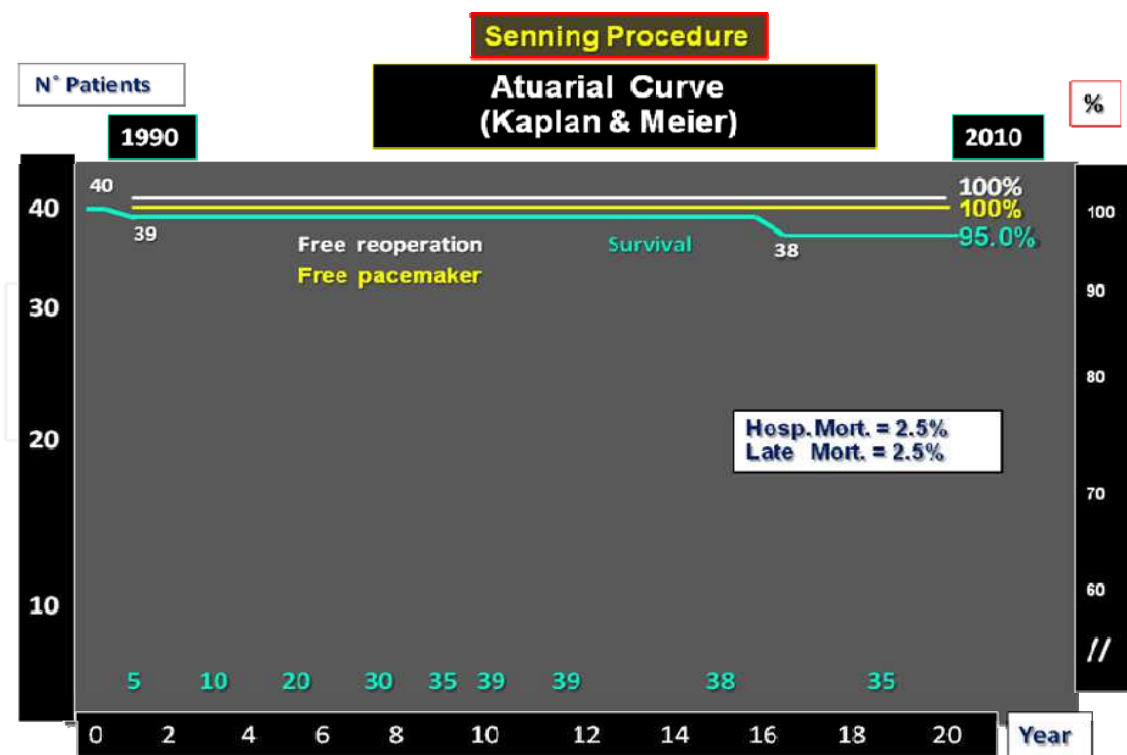


Fig. 15. Actuarial Kaplan & Meier curve. Late follow-up of patients submitted to Senning operation. Hosp. Mort.: hospital mortality

Time of Follow-up (months)	Tricuspid V. Function		RV function		Cardiac Arrhythmias	
	Normal	Insufficiency	Normal	Dysfunction	Sinusal R	Arrhythmias
	N° (%)	N° (%)	N° (%)	N° (%)	N° (%)	N° (%)
0- 60	28 (80.0)	7 (20.0)	32 (91.4)	3 (8.6)	30 (85.7)	5 (14.3)
60 – 120	27 (77.1)	8 (22.8)	29 (82.8)	6 (17.2)	28 (80.0)	7 (20.0)
120	25 (71.4)	10 (28.5)	27 (77.1)	8 (22.9)	27 (77.1)	8 (22.9)

* Total 38 patients; follow-up: 35 patients (three patients were excluded). V: valve; RV: right ventricle; R: rhythm

Table 5. Late follow-up patients with Senning operation (35 patients)*

4.6 Discussion

In the 1970s and 1980s, the atrial switch procedure was the treatment of choice for patients with TGA. After Quaegebeur et al reported favorable results with the Senning operation in 1977, many groups with arterial switch results not satisfactory, started a new surgical experience with Senning’s operation, in infants.

In our Institution, from 1990 until the 2000’s, the Senning’s procedure was indicated for infant patients with TGA + ASD, using in all cases, the Subramanian’s maneuver, with very satisfactory results.Baffle-related complications were the most frequent causes and accounted for 5.4% in the Senning a group. The curves for freedom of baffle re-intervention, were only slightly different within the first 15 years but began to diverge clearly after that time span. The study published by the Congenital Heart Surgeons Society in 2000 found the incidence of baffle-related complications in 173 Senning patients. All our patients were operated using the modified technique (Subramanian procedure) and no prosthetic material was used. Only two patients (2/40; 5.0%) presented stenosis of the IVC, during the early post-operative period; these patients were submitted to balloon angioplasty, with success. No patient of these series was re-operated during the late follow-up (mean 14.7 years).

In a recent publication, the inversion of the left atrial appendix, associated to autologous pericardium for venous pathway enlargement, presented retraction and calcification of the venous baffle with obstruction of the venous tunnel.

Surgery for RV dysfunction is the second most frequent indication for reoperation. Mortality associated with reoperations in general has been described to be as high as 36% in a previously published series, mainly because of conversion to the arterial switch operation.

Three (7.5%) patients in our series presented moderate RV dysfunction in the pre-operative period, but maintained the same RV dysfunction after Senning’s operation, during the early and late follow- up; this patients are in functional class II (NYHA).

Loss of sinus rhythm at long term has been described in patients after atrial baffle procedures, with the incidence being the same after the Senning or the Mustard procedure. However, reports present series of patients with sinus rhythm in 80.8% of the cases, 17.4 years after the Senning’s procedure.

In these published articles, patients free from pacemaker implantation, in the Senning group, were 98.7%, at 10 years and, thus, it was comparable to the findings by others series: 91% to 92% at 10 years.

Patients freedom from pacemaker insertion, at 20 years, was still > 90%. This might be related to the fact that in these patients the coronary sinus was not incised as originally described by Senning, and the atrial suture line was placed posterior to the coronary sinus.

Our surgical technique to perform the Senning's operation included: 1- ASD closure using left atrial appendix and 2- The atrial suture line was placed posterior to the coronary sinus.

In 40 patients operated, the cardiac rhythm in the early post-operative period showed: sinus rhythm in 30 (85.7%) cases and cardiac arrhythmias in 5 (14.3%) cases.

In 40 consecutive operations, we had one death (hospital mortality = 2.5%); these results are possible to compare to others reported series, with mortality ranging from 2% to 5.4%. Whereas, patients with simple TGA submitted to Senning's operation, resulted in a significant difference in the relative number of complex TGA. In addition, the surgical learning curve may have been a reason for the differences in mortality between the different published reports in international issues.

Thirty five (92.1%) surviving patients had mean follow-up of 177 months (other 3 surviving patients living overseas). During late follow-up, other 3 patients presented cardiac arrhythmias. Actually, 27 (77.1%) cases maintain sinus rhythm and 8 (22.9%) cases presented cardiac arrhythmias. No pacemaker was implanted in this group of patients.

Other series presented 90.9 ± 2.3 % of surviving patients in 25 years of follow-up, after the Senning procedure and 75.9 ± 4.8 %, after the Mustard procedure and thus, it was significantly different in univariate analysis. The Mustard procedure remained a significant risk factor for late death in multivariate analysis fully adjusted for all variables that were statistically significant between the 2 groups. This difference in late survival between the 2 operative procedures is not confirmed in all investigations.

Whereas, authors have observed a significantly better survival rate of patients after the Senning's operation (94% versus 77% at 15 years).

The Senning's operation is a risk factor for late death. In contrast, authors reported a similar long-term outcome for the Toronto Mustard group and the Zurich Senning group, with 75% survival after 25 years. However, they found a difference in the mode of death between the Mustard group and the Senning group. Similar to the results of the present study, relatively more Mustard patients died of sudden death compared with the Senning patients, who died preferentially of progressive congestive heart failure.

We had a previous published report, including only the first 17 patients, submitted to Senning's operation, for correction of the simple TGA, in our Institution. In this series we have one hospital death, (early mortality 2.5%).

In thirty nine surviving patients, no cardiac cause of death was observed (only one accidental death was observed). There was no sudden death in this group; the survival rate in our Institution was 95%, with mean follow-up of 14.7% years.

Regarding the type of atrial baffle procedure, patients with previous VSD carry a higher risk of late death than patients with intact ventricular septum. Reports show that: 90% of the patients with simple TGA but only 78% of the patients with complex TGA were alive 15 years after the Senning procedure. These data confirm the finding that the presence of a VSD is a significant risk factor for late death because VSD closure emerged as an dependent risk factor for late death in multivariate analysis.

From 1986, in our Institution, neonates with simple TGA, infants with TGA plus VSD or Taussig-Bing anomaly were referred to arterial switch operation (ASO) and VSD closure, but infants patients with diagnosis of simple TGA and simple TGA with small muscular VSD were referred to Senning's operation.

The question remains of whether the surgical procedure of VSD closure or rather the hemodynamic consequences of a previous VSD account for the intrinsic risk of late mortality. Potential complications of VSD closure that may also lead to late RV dysfunction and consecutively to late death such as iatrogenic postoperative AV block or tricuspid insufficiency were no more frequent in patients after VSD closure.

However, freedom from pacemaker implantation was lower in patients who received VSD closure at the time of the atrial switch operation. The incidence of right bundle branch block (RBBB), which has been associated with late development of RV dysfunction, was increased. Hence, the surgical procedure of VSD closure may have an influence on mortality in the long term.

Deterioration of the function of the systemic ventricle (RV) is a major concern in patients after atrial switch procedures. The incidence of moderate or severe RV dysfunction shows a wide variation in the literature from 8% at 12 to 18 years and 20% at 20 to 28 years, respectively. Authors found a rapid increase of RV dysfunction, after 10 years, and described the probability of normal right ventricular function to be only 52% and 39%, 10 to 15 years after the Senning's procedure in patients with simple and complex TGA, respectively. In the Lange et al study, the incidence of RV dysfunction was 16.1% at 25 years. However, in our experience with 40 consecutive cases of Senning's operation, three patients presented mild RV dysfunction, before operation and maintaining after 15 years of follow-up, in functional class II. The RV variability in assessing right ventricular function and the lack of a uniform definition restrict comparison. The incidence of RV dysfunction in the long term has been shown to be associated with the complexity of the heart defect, which we confirmed that this dysfunction progressed to moderate dysfunction, but maintaining the functional class II.

In our series, actually, 8 (22.8%) patients presented mild or moderate RV dysfunction and tricuspid insufficiency; these patients are medicated with β blocking drugs and patients with tachyarrhythmias are using anti-arrhythmic drugs.

4.7 Conclusions

Our results confirm that the patients with simple TGA submitted to the Senning's procedure in the late follow-up, presented a good quality of life functional class I-II, satisfactory results (low incidence of arrhythmias, free of pacemaker implantation or reoperation) and no risk of late sudden cardiac death.

5. Anomalous left coronary artery from the pulmonary artery. Autogenous arterial conduit technique

Anomalous left coronary artery from pulmonary artery (ALCAPA) is a rare cardiac malformation; whose clinical symptoms are expressed in the first months of life, by congestive heart failure (CHF) of difficult clinical improvement, followed by significant mortality. The symptoms of CHF associated with functional mitral insufficiency due to papillary muscle dysfunction and ischemic changes observed in the ECG are guidelines for the diagnosis of ALCAPA.

Doppler echocardiography diagnosis, depending on the operator may have difficulty in submitting images for reliable indication for surgery. Noninvasive diagnostic methods such as computerized tomography angiography (CT Angio) and magnetic resonance imaging (MRI) have enabled it to provide relevant information for a planned and safer surgical approach. These patients represent a model of our experience started in 1993 at the Department of Cardiovascular Surgery at São Paulo Federal University (UNIFESP), a group of 19 consecutive patients, all operated with the technique of direct re-implantation of left coronary artery from the ascending aorta and in the last three cases using the technique of autogenous arterial conduit.

5.1 Case report

Child, 9 years-old, male, with ALCAPA, who underwent corrective surgery in December 2001 with follow-up period of 9 years. The clinical examination, conducted in March 2010, showed an asymptomatic patient, without limitation during exercise, without medication in the last seven years in functional class I (NYHA). At 2 months of age, the patient was admitted to the Cardiology Department, of UNIFESP. On clinical examination the patient presented respiratory distress, tachycardia, thin wrists and pale complexion. He also presented enlarged liver and mitral systolic murmur. The ECG showed subendocardial injury current in precordial derivations, and the Doppler echocardiography showed lowered left ventricular function and moderate mitral insufficiency.

5.2 Surgical correction

After diagnosis of ALCAPA and moderate mitral insufficiency, the patient was submitted to surgical correction in December 2001 at two months of age, on cardiopulmonary bypass (CPB). During surgery it was confirmed cardiac malformation: the left coronary artery originated from the left posterior sinus of the pulmonary valve. The heart chambers were found dilated and presented left ventricular dyskinesia, and it was observed in the epicardial surface, an exuberant intercoronary shunt between the right and left coronary system. Figure 16.

During CPB, clinical diagnostic was confirmed and was observed hypokinetic apical area of the left ventricle (LV). The patient was kept in moderate hypothermia at 28°C and the right and left pulmonary arteries were occluded. After aortic clamping was initiated the infusion of blood cardioplegic solution, injected into both vessels ascending aorta and pulmonary trunk. (Figure 17 a, b).

After dissecting the pulmonary trunk, the latter was cross-sectioned near the origin of the pulmonary arteries. We observed the ostium of the left coronary artery emerging from the left posterior sinus of the pulmonary valve, distant 25 to 30 mm from the ascending aorta.

The coronary ostium was removed from the posterior sinus of the left pulmonary sinus, along with a long flap, taken from the anterior wall of the proximal stump of the pulmonary trunk, while other similar flap was built on the side wall of the aorta below the aortic clamps, pedicle on the posterior wall of the aorta. (Figure 17 c)

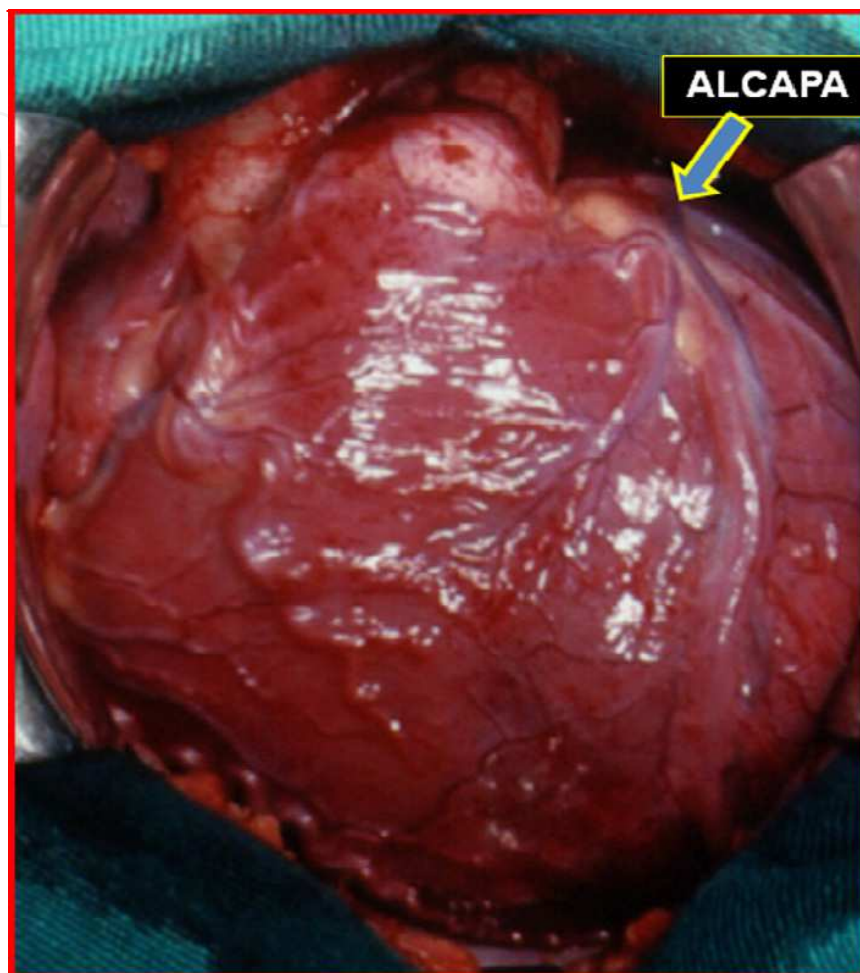


Fig. 16. Surgical image. External appearance of the heart, we observed the anomalous origin of left coronary artery from the pulmonary artery (ALCAPA) and significant intercoronary shunt.

The aortic and pulmonary flaps were sutured by their edges, using a 7-0 polypropylene thread, building an autogenous arterial conduit, anastomosed to the ascending aorta, about 2-3 cm above the left aortic sinus. (Figure 17 d).

No wire was needed for dissection or manipulation of the left coronary artery to approximate it to the aorta. The anterior wall of the pulmonary trunk was reconstructed with preserved bovine pericardium and there was no intervention on the mitral valve.

At the end of CPB, the patient underwent modified ultrafiltration (MUF) and administration of Dobutamine and Milrinone, with improvement of hemodynamic parameters.

The pediatric ICU stay was 96 hours and he had discharged on the 10th day after surgery, receiving medicated for CHF

This procedure was performed at the São Paulo Federal University, being the first Institution in the country to adopt this procedure, and then rapidly expand to other pediatric cardiac surgery centers in the country, looking for successful results and decide to abandon the intrapulmonary tunnel (Takeushi technique)

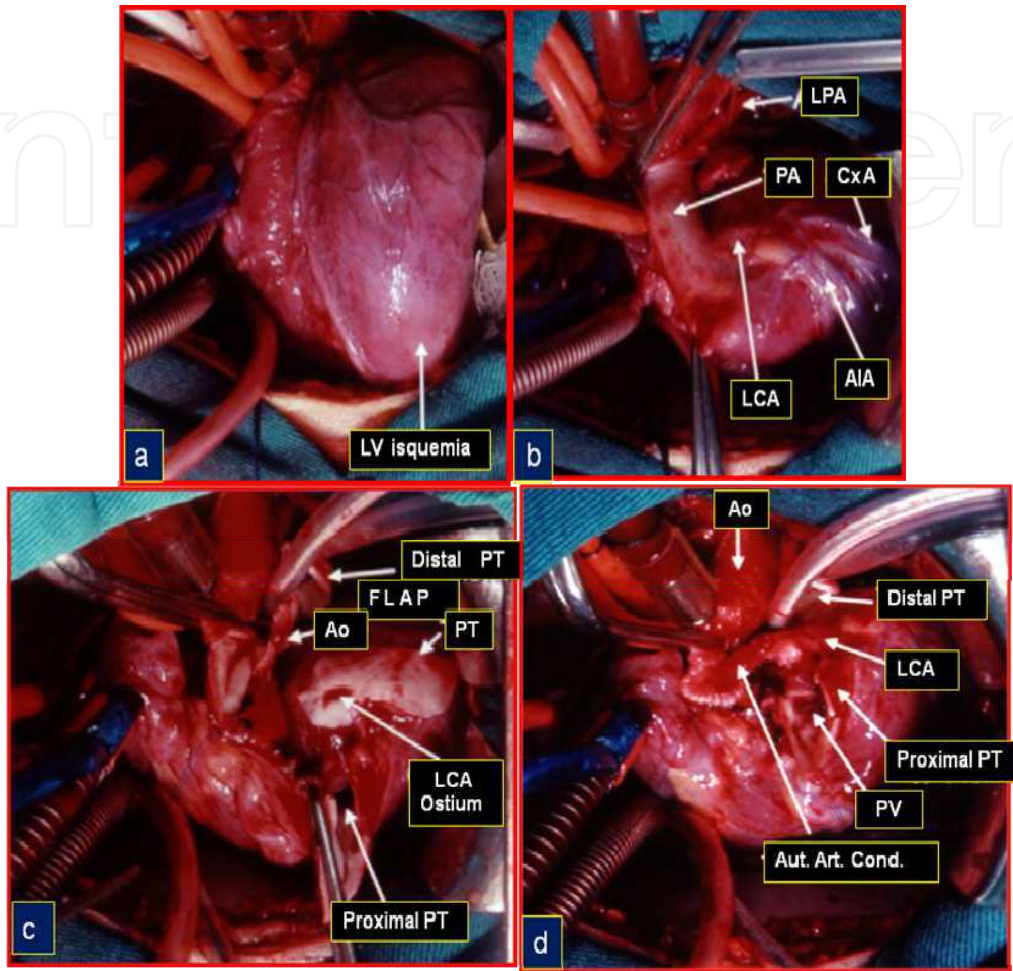


Fig. 17. Surgical image. Patient on cardiopulmonary bypass. a- Aspect of the ischemic anterior and apical region of the left ventricle b- Origin of the left coronary artery from the left posterior sinus of the pulmonary valve. Not was detected in previous pre- and postoperative tests. . c-: After section of the pulmonary trunk (PT) and resection of the *ostium* of the left coronary artery (LCA) along with flap from the wall of the PT; another pedicle was built on the lateral wall of the aorta (Ao). d- Implantation technique of the LCA in the ascending Ao. Manufacture of *autologous* arterial conduit (*Aut. Art. Cond.*) with flaps of pulmonary artery and aorta, sutured by their edges and side extremity anastomosed to the ascending aorta. . LV: left ventricle, PA: pulmonary artery, LPA: left pulmonary artery; Cx: circumflex artery; AIA: anterior interventricular artery PV: pulmonary valve.

5.3 Late postoperative follow-up

The patient had good postoperative evolution, returning for regular medical control. In October 2009, at eight years of age, the patient returned for clinical assessment: remained asymptomatic in Functional Class I (NYHA), without restriction to perform physical activities and without cardiac medication.

The clinical examination showed: regular heart rhythm without murmur; ECG: normal for the age; Doppler echocardiography: preserved left ventricular function, mitral valve competence and the presence of autogenous arterial conduit and patent left coronary artery.

Computerized Tomography Angiography showed images of implantation of autogenous arterial conduit in the ascending aorta above the aortic sinus (Figure 18 a), autogenous arterial conduit patency, with uniform diameter (Figure 18 b), reconstruction of the pulmonary artery (Figure 18 c) and the presence of a significant stenosis on the left pulmonary artery not detected in previous pre-and postoperative tests. (Figure 18 d).

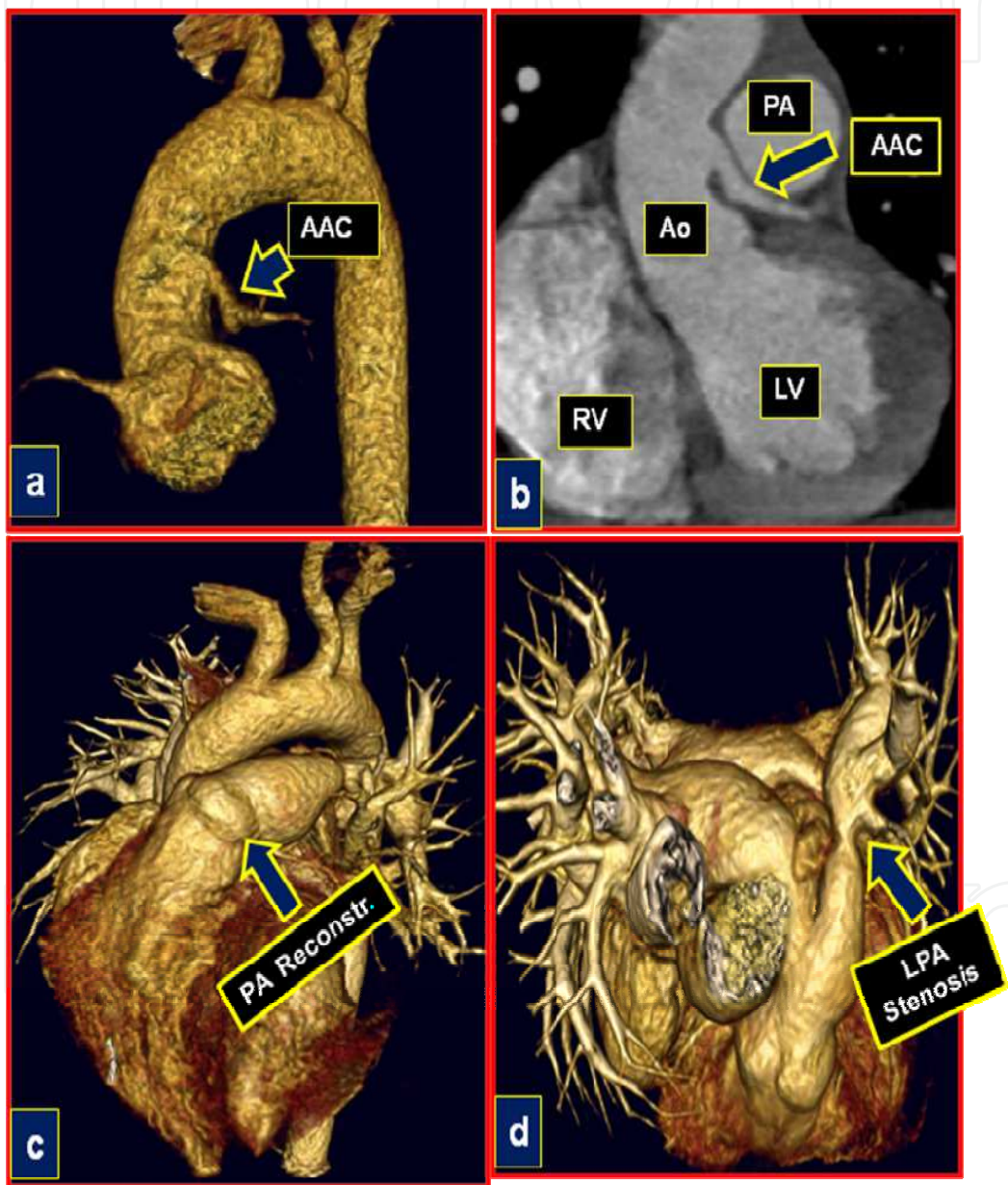


Fig. 18. Late follow-up of the 8th year. Postoperative image of CT angiography- a- Implantation of *Autologous* arterial conduit (ACC) in the ascending aorta above the aortic sinus. b- Autogenous arterial conduit patency, with uniform diameter. c- Reconstruction of the pulmonary artery . -d- Image of stenosis located in the distal left pulmonary artery. (LPA); RV: right ventricle; LV: left ventricle; PA: pulmonary artery; Ao; aorta

In February 2010 the patient was submitted to pulmonary angioplasty with balloon catheter (Figure 19 a), followed by stent implantation in the left pulmonary artery (Figure 19 b) with balloon expansion of the stent, successfully. (Figure 19 c).

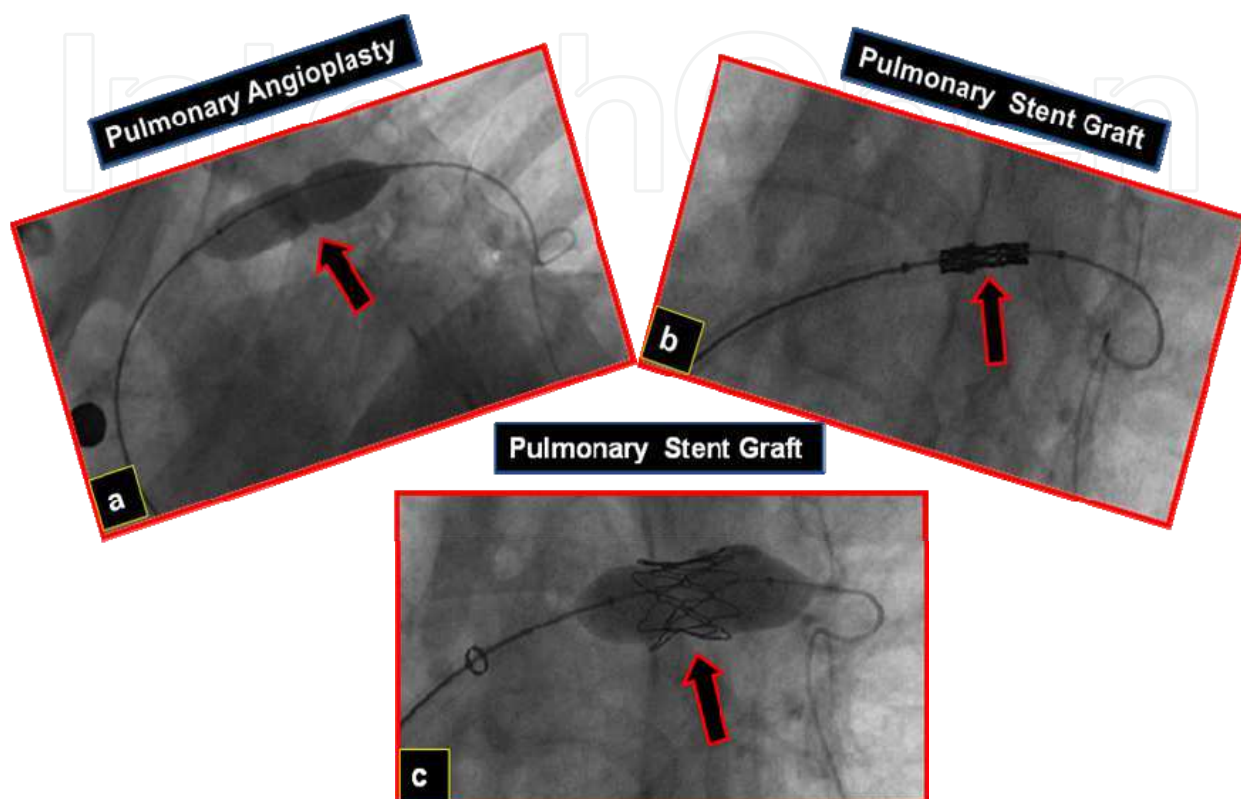


Fig. 19. Late follow-up of 8 years. Postoperative cardiac catheterization. Cineangiographic image a- Pulmonary angioplasty with balloon. b-Pulmonary stent implanted. c-Pulmonary stent dilatation, with balloon.

5.4 Comments

ALCAPA is a rare cardiac malformation described by Bland - White - Garland in 1933 and accompanied by high mortality in infants; Vouhe et al consider the mortality of about 90% in the first year of life.

This is a congenital defect where the myocardial function was deeply compromised due to myocardial ischemia, and as it occurred in our patient, it began at 2 months of life, immediately after the closure of the patent ductus arteriosus.

The most common local of origin of the left coronary artery ostium, as in our patient, occurred in the left posterior sinus of the pulmonary valve, standing away from the ascending aorta in any attempt for direct reimplantation into the aorta. During the external examination of the heart, we observed the presence of the main coronary arteries and their branches dilated and tortuous, the result of right to left coronary shunt.

The purpose of correction of ALCAPA is to create two separate coronary systems. However, the location of the left coronary ostium near or distant from the aorta, has raised interest and stimulated the creativity of the cardiac surgeon to develop new techniques and improve outcomes in the middle and long terms.

The direct re-implantation of the left coronary artery on the ascending aorta involves the dissection and movement of the coronary artery trunk and its main branches, but tension on the sutures compromise coronary flow and result in high mortality. In our series of patients we had two deaths due to ischemic dysfunction of the LV, probably due to tension in the anastomosis after aortic implantation of the left coronary artery, which originated within the left posterior sinus of the pulmonary valve.

Aiming to avoid such incidents and to improve the operative late outcome, this technique has been modified and now employs procedures to lengthen the proximal coronary artery and permit implantation in the aorta without tension.

Thus, Sese et al in 1992 described a new technique of stretching of the coronary artery, using a flap of the pulmonary artery wall and a pedicled flap of the aortic wall; this technique was called "trap-door." The criticism of this procedure is still the need for dissection of the main branches of the coronary artery, for its approach to the ascending aorta.

Similar procedures have been published by Tashiro et al in 1992 and Von Son et al in 1997. Katsumata et al in 1999 and Murthy et al in 2001, based on initial experience stretching the left coronary artery, now with aortic and pulmonary flaps, larger in width and length, built autogenous arterial conduits or tubs, to re-implant the left coronary artery originating from the left posterior sinus of the pulmonary valve, without tension and without dissection of the main coronary branches.

The experience of our group of congenital heart diseases at Unifesp started successfully in December 2001 and it was published six years later.

Nine years after the surgical correction, our patient presents good evolution and remains asymptomatic during physical activity and without medication (Functional Class I). The examinations of CT angiography, performed in December 2009, certifies the successful outcome of this technique, showing the autologous arterial graft patency and uniform diameter throughout its length.

Mitral regurgitation is a common finding in patients with ALCAPA, caused by ischemic papillary muscles and LV dilation. No case in our series had mitral valve surgery approach, being aware that after improvement of the ventricular function there would be regression of mitral valve dysfunction as documented in our patient. This conservative approach has been adopted by Vohue et al, with improvement of mitral dysfunction. This author reports that mitral valve repair is a procedure not very favorable in infants.

A recent report shows that a patient submitted to anomalous left coronary artery implanted in the aorta, followed by mitral valve repair by annuloplasty presented in the postoperative period, important mechanical hemolysis. This patient required a second intervention to remove a piece of bovine pericardium, .

Finally, the endothelialized tube construction, performed in our patient, had the advantage of avoiding the use of bovine pericardial patch, employed by other authors or using the intrapulmonary tunnel technique, maintaining the patency during the late follow-up.

5.5 Conclusion

1. The coronary artery transference was technically safe and feasible. The endothelialized inner conduit remains pervious during the late follow-up.
2. Long - term clinical outcome and left ventricular function are good despite severe left ventricular dysfunction at presentation.
3. Mitral valve repair was not necessary. Competent mitral valve was observed after the return of the normal left ventricle function.

6. Hypoplastic left heart syndrome. Hybrid procedure

Despite undeniable recent improvement in survival rates, the Norwood Stage I operation for hypoplastic left heart syndrome (HLHS) and related anomalies remains a high-risk endeavor. Neonates undergoing a stage I Norwood operation face a mortality of 10-20%, depending on the risk factors and the experience of the cardiac team. Current significant risk factors include birth weight < 2.5 kg, prematurity < 34 weeks gestational age, intact or restrictive atrial septum, additional cardiac anomalies and non-cardiac genetic malformations.

Lessons learned during the development of a novel hybrid approach have resulted in a reliable, reproducible alternative treatment for hypoplastic left heart syndrome (HLHS). Herein we report our results using this hybrid approach in a uniform risk cohort.

6.1 Methods

This is a review of prospectively collected data on patients treated for HLHS using a hybrid approach (n = 10) between July 1995 and June 2002. The hybrid approach includes pulmonary artery bands, a ductal stent, and atrial septostomy as a neonate, without cardiopulmonary bypass. (Figure 20,21)

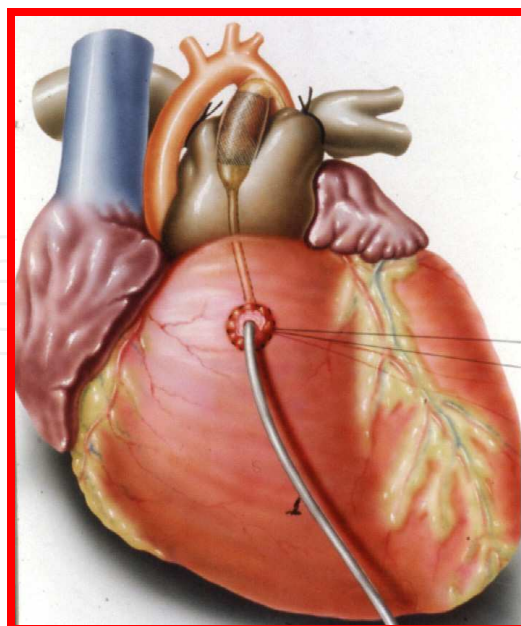


Fig. 20. Schematic drawing of surgical technique of hybrid procedure: stent implantation in the *ductus arteriosus* through the right ventricular infundibulum, associated with right and left pulmonary banding.

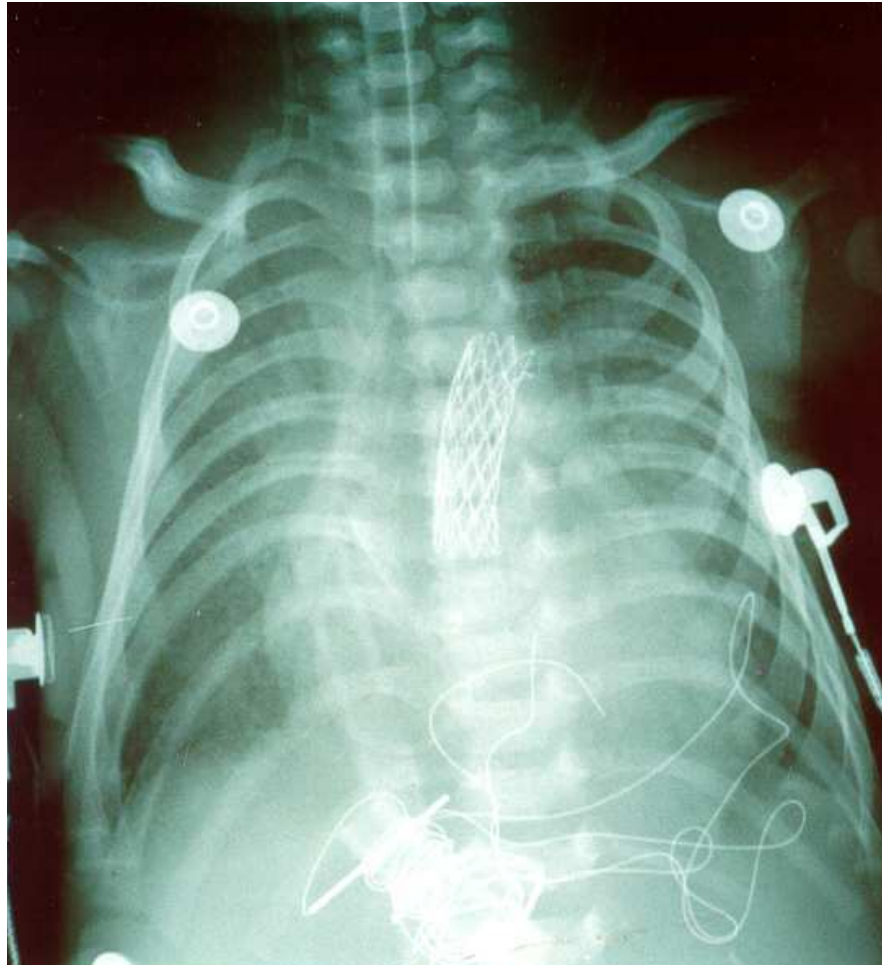


Fig. 21. Postoperative chest X-ray after hybrid procedure, showing stent implanted into the ductus arteriosus

This patient is getting prepared for stage 2 procedure resulting in Glenn shunt physiology at six months and stage 3, Fontan completion at two years.

6.2 Results

Ten patients had a hybrid stage 1 with survival rate between 1 day and 120 days. Unfortunately, no patient completed the stage 2 and 3.

This procedure was performed by the São Paulo Federal University, being the first institution in the country to adopt this procedure, and then rapidly expanding to other pediatric cardiac surgery centers in the country, seeking successful results.

Conclusion: The hybrid approach is still acceptable due to its intermediate results, but it is not comparable to a traditional Norwood strategy. Potential advantages of the hybrid approach include the avoidance of circulatory arrest and shifting the major surgical stage to a later time. These data provide the platform for a prospective trial comparing these two surgical options to assess whether there is less cumulative impact with the hybrid approach, thereby improving end organ function, quality, and quantity of life.

7. Hypoplastic left heart syndrome. Palliative surgical correction with beating heart

Hypoplastic left heart syndrome is a uniformly lethal cardiac abnormality if not surgically addressed. Since the description of surgical palliation by Norwood in the early 1980s and the description of allograft cardiac transplantation by Bailey in the mid 1980s, the interest in this lesion has remarkably increased. Currently, the Norwood surgical approach consists of a series of 3 operations: the Norwood procedure (stage I), the hemi-Fontan or bidirectional Glenn procedure (stage II), and the Fontan procedure (stage III). Orthotopic heart transplantation provides an alternative therapy, with results similar to those of the staged surgical palliation. Currently, the survival rate of infants treated with these surgical approaches is similar to that of infants with other complex forms of congenital heart disease in which a 2-ventricle repair is not possible.

7.1 Norwood operation

This surgery is complex and may vary slightly depending on the diagnosis and overall condition of the heart. The main pulmonary artery is separated from the left and right portions of the pulmonary artery and joined with the upper portion of the aorta. Widening of the pulmonary artery is often necessary, and may be accomplished by using the patient's existing biological tissue or appropriate animal tissue. This allows blood, a mixture of oxygenated and deoxygenated blood to be pumped to the body via the pulmonary valve. Since the remainder of the pulmonary artery is now disconnected from the heart, one of a few techniques must be used to supply blood to the lungs: With a modified Blalock-Taussig Shunt, a Gore-Tex conduit (a kind of plastic tubing) is used to connect the subclavian artery to the pulmonary artery. In this case, blood comes from the single ventricle, through the pulmonary valve, the reconstructed aorta, the subclavian artery, and the conduit, to the lungs. There are variations on this procedure where the origin of the shunt is elsewhere in the systemic circulation (e.g. from the aorta itself) rather than the subclavian artery.

7.2 Sano modification procedure

The Sano Modification of the Norwood involves the placement of a conduit (light blue tube below) between the pulmonary artery and the right ventricle instead of the Modified Blalock-Taussig Shunt.

7.3 Sano procedure

The first operation serves to make the right ventricle the main pumping chamber for blood flow to the body. The aorta is made larger to increase blood flow to the body. A connection is made to enable the blood traveling through the aorta towards the body to "shunt" through this connection and flow into the pulmonary artery to receive oxygen. This may be accomplished with a modified Blalock-Taussig shunt, which is a small tube placed between the aorta and the pulmonary arteries or by using the Sano modification procedure, in which a homograft (tissue) conduit is placed between the right ventricle and the pulmonary arteries. The choice of which procedure is best for your child can be discussed with your cardiologist and/or cardiovascular surgeon. However, even after the stage I procedure, the

infant will still have some degree of cyanosis since oxygen-poor (blue) blood from the right atrium and oxygen-rich (red) blood from the left side of the heart mixes and flows through the aorta to the body.

7.4 The Sano shunt

Over the last few years, a number of centers around the world have begun to adopt a modification of the Norwood procedure that involves a different type of shunt. Introduced by Shunji Sano, MD, who was trained in congenital cardiac surgery in Melbourne, Australia, and is now working in his home country of Japan, this new modification indicates further improvement in the survival of newborn babies with hypoplastic left heart syndrome.

The Sano shunt modification avoids the problem of competitive flow between the lungs and coronary arteries. The shunt is constructed from a slightly larger gore-tex tube graft than that used for the modified Blalock shunt. Generally a 5 mm tube graft is selected in contrast to the 3.5 mm graft used for average size babies for a Blalock shunt. Distally, the graft is connected to the main pulmonary artery between the right and left pulmonary artery takeoffs. The proximal end of the shunt is connected to a limited infundibular incision in the right ventricle.

7.5 Norwood – Sano operation at São Paulo Federal University

The Norwood procedure has been replaced by the Norwood procedure-Sano in our institution since 2004. The surgical technique consists in the careful dissection of the ascending aorta (Hypoplasia), vessels, pulmonary trunk, pulmonary branches and ductus arteriosus. (Figure 22)

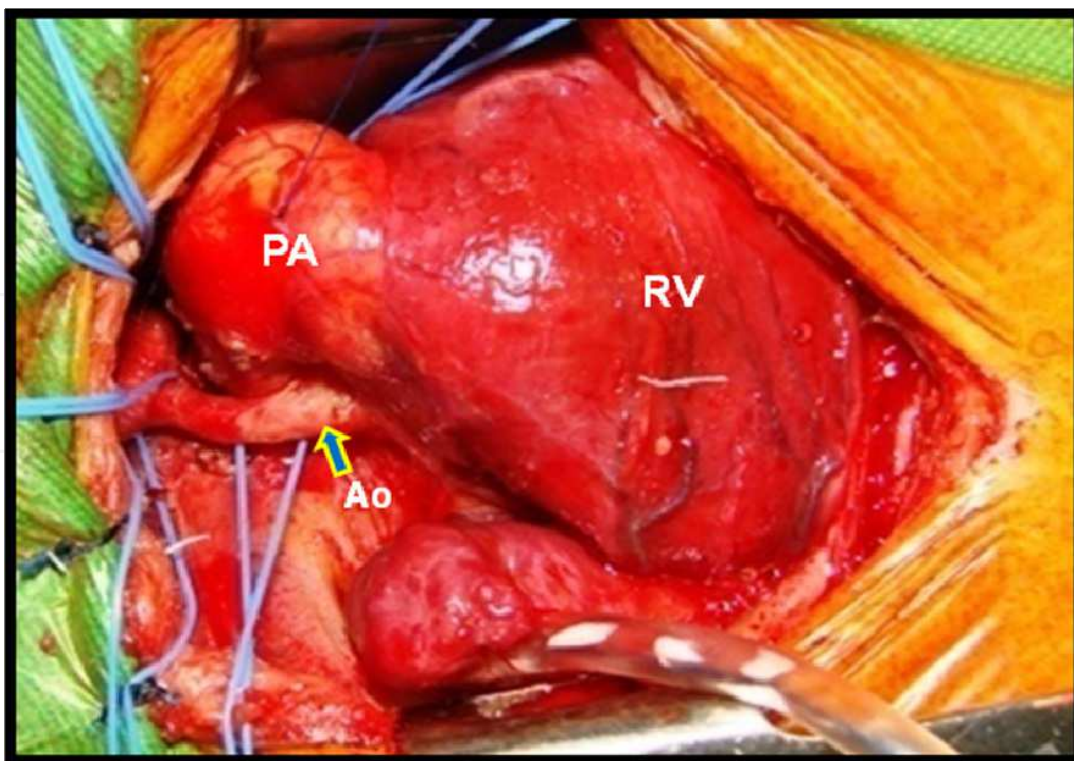


Fig. 22. Surgical image. Hypoplastic ascending aorta and dilated right ventricle (RV) and pulmonary artery (PA). Ao: aorta.

The establishment of cardiopulmonary bypass was performed by anastomosis of a gore-tex tube of 4.0mm in the brachiocephalic trunk where it will be held on cerebral and coronary arteries perfusion (fig. 23). The operation is performed with the aid of bypass and normothermic beating heart (without aortic clamping and without circulatory arrest). The perfusion of the descending aorta is performed by cannulation of the descending aorta using a Y-junction of the arterial line.

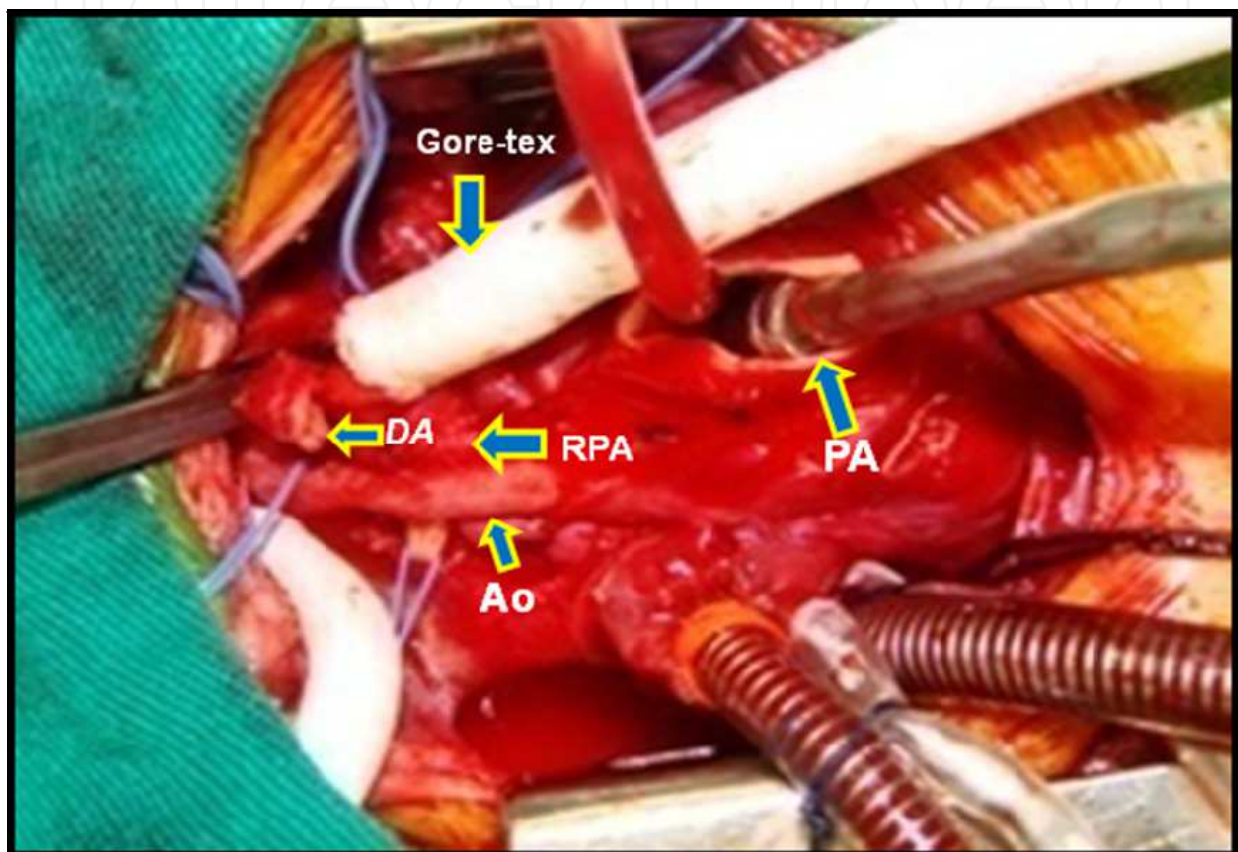


Fig. 23. Surgical image. Cardiopulmonary bypass installed: arterial perfusion by gore-tex prostheses anastomosed to braquiocephalic trunk. After ductus arteriosus and pulmonary artery (PA) sectioned, the pulmonary flow reconstructed with gore-tex tub (5.0mm), anastomosed to pulmonary arteries. Ao: aorta, RPA: right pulmonary artery, DA: ductus arteriosus.

With the clamping of the aortic arch near the innominate artery, and without interfering with the coronary and cerebral blood flow, and reconstruction of the neo-aorta by interposition of segment of porcine pulmonary trunk gauge similar to the pulmonary ring, interposed between the arch and isthmus and the pulmonary trunk in the region above the valve (modified Norwood Op.) figure 24.

Finally, the pulmonary blood flow is restored through the interposition of gore-tex prosthesis of 5.0 mm or 6.0 mm, between the infundibulum of the right ventricle and the pulmonary arteries (Sano modification) Figure 25.

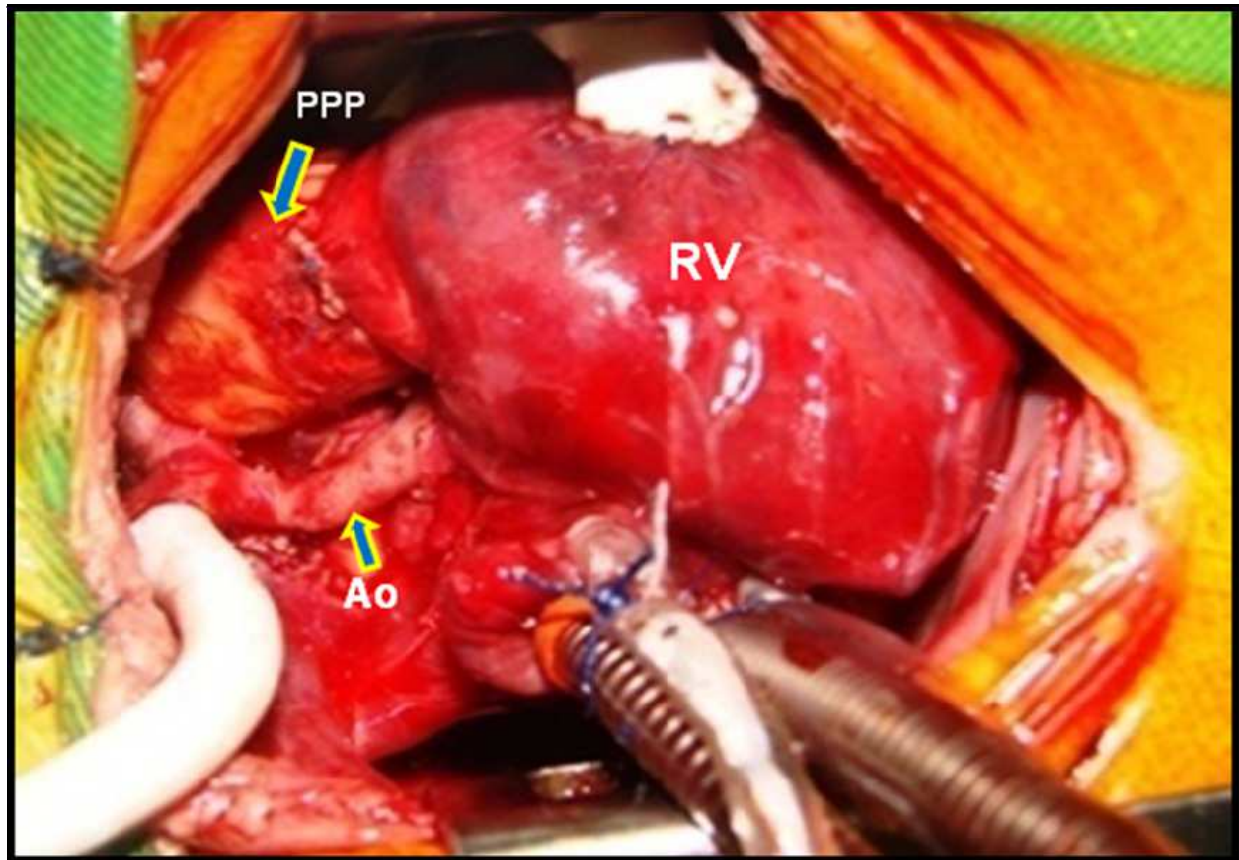


Fig. 24. Surgical image. Neoaorta reconstruction using a segment of porcine pulmonary prosthesis (PPP), implanted between pulmonary trunk and aortic arch. Ao: aorta, RV: right ventricle.

This kind of approach to HLHS is a unique technique developed at our institution, highlighting several advantages:

- Preservation of cerebral and myocardial function during the procedure, while maintaining continuous flow during CPB.- Minor metabolic disorders while maintaining normothermic CPB - Adequate flow without restriction and less chance of bleeding by using the neo-aortic porcine pulmonary prosthesis, anastomosed only their proximal and distal stumps.
- Preservation of cerebral and myocardial function during the procedure, while maintain continuous flow during CPB.
- Minor metabolic disorders while maintain CPB at normothermia.
- Adequate flow without restriction and less chance of bleeding by using the neo-aortic porcine pulmonary prosthesis, anastomosed only their proximal and distal stumps.

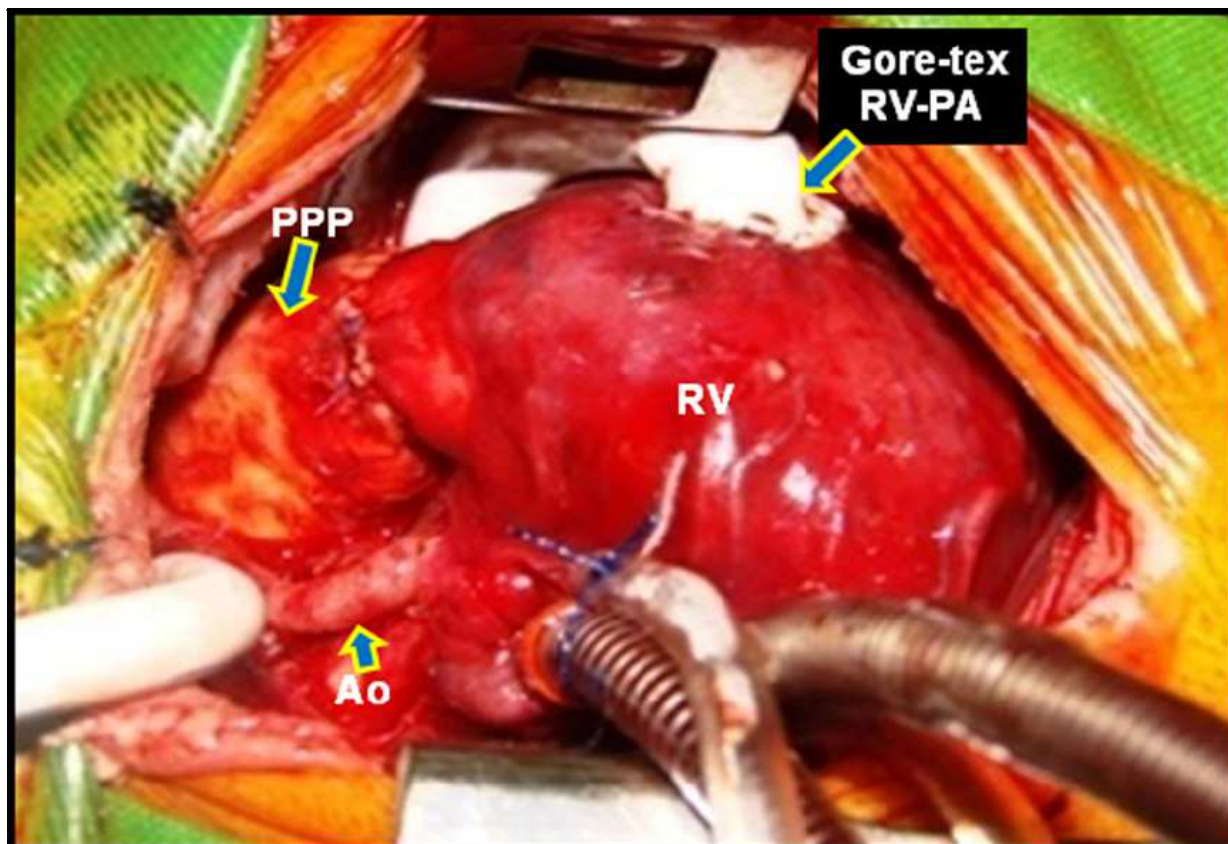


Fig. 25. Surgical image. Implant of a gore-tex prosthesis (5.0mm) between right ventricle (RV) and pulmonary artery (PA). Ao: aorta, PPP: porcine pulmonary prosthesis

8. New models of cardiac valves

8.1 Right ventricle remodeling surgery using porcine pulmonary prosthesis

The results of biventricular surgical repair of congenital heart disease with obstruction of the pulmonary ventricle are satisfactory. A surgical technique started over five decades ago is closely related to adequate pulmonary valve (PV) repair and right ventricular outflow tract (RVOT) reconstruction.

The use of prostheses with no valves induced the development of valvar pulmonary insufficiency (VPI), which for many years it was considered a benign residual lesion that patients tolerated reasonably well, but this selected technique and other causes that were responsible for ventricular dysfunction are now questioned.

With the increasing duration of follow-up, however, significant late morbidity and mortality have been observed in a portion of patients

More recently, the clinical relevance of VPI after enlargement of the hypoplastic pulmonary ring and trunk was confirmed once the medium and long-term results of the surgery were better known. Studies on the issue have established the need to repair the PV using valved prosthesis, minimizing or preventing VPI, which is considered to be the cause of late RV dysfunction.

Therefore, RV diastolic function should be carefully monitored in the long-term follow-up of patients undergoing correction of: tetralogy of Fallot (TOF) with trans-annular enlargement; *truncus arteriosus* (TA); pulmonary atresia (PA) with ventricular septal defect (VSD); PA with intact ventricular septum (IVS) and transposition of the great arteries (TGA) + VSD + left ventricle outflow tract obstruction (LVOTO).

The Doppler-echocardiography has shown the presence of diastolic flow in the pulmonary artery, synchronized with atrial systole and the respiratory cycle. The RV diastolic volume in the postoperative recovery, determines a diastolic compliance decrease and may be detected by a continuous laminar flow in the pulmonary artery.

The VPI is known as one of the most important factors that cause RV dilation due to volume increase and ejection fraction decrease after surgical correction.

There is a spectrum of VPI quantified with more refined method of evaluation, utilizing magnetic resonance imaging (MRI) as well as exercise testing in the follow-up of patients submitted to operations to alleviate the pulmonary obstruction, associated with RV dilation and hypertrophy.

The development of akinetic regions and aneurysmatic dilation of the RVOT, related only in part to the trans-annular patching, is common and contributes to increase RV diastolic volumes (RVDV) and decrease RV ejection fraction (RVEF), related to the degree of VPI.

Left ventricular systolic dysfunction, aortic regurgitation and RV dilation and dysfunction exist in adults with TOF, TA, PA / VSD, TGA / VSD / LVOTO, PA / IVS etc. related to the length of palliation with arterial shunts.

Measures to maintain or restore pulmonary valve function and to avoid VPI, RVOT aneurysm or akinesia are mandatory for preserving RV and LV function late, after pulmonary ventricle repair.

This manuscript reviews our experience in 203 consecutive patients treated with RVOT remodeling utilizing a preserved porcine pulmonary prosthesis (bicuspid and trileaflet).

8.2 Patients and methods

8.2.1 Study group

This study reports the surgical technique and late follow-up of the pulmonary ventricle performance and preserved porcine pulmonary prosthesis, used to PV repair and RVOT reconstruction, in patients with pulmonary ventricle obstruction.

This clinical study was performed at the Cardiovascular Division of the São Paulo Federal University, between June 1991 and December 2008.

This prosthesis was initially tested in experimental model in March 1990 and after good performance, it was approved for clinical use by the Medical Ethical Committee of this Institution in June 1991.

In 2006, the Medical Ethical Committee at the São Paulo Federal University approved the Magnetic Resonance Images and Computerized Tomography study, in patients with follow-up over 10 years.

Two hundred and three consecutive patients, aged 4 months to 35 years (mean=3.0) were operated. The patients were classified in 5 groups according to the diagnosis of the cardiac malformation.

G1- TOF with pulmonary hypoplasia, 144 (70.9%) cases; G2- PA + VSD, 32 (15.7%) cases; G 3 - TA, 12 (5.9%) cases; G 4 - TGA + VSD + LVOTO, 8 (3.9%) cases and G 5 - PA + IVS, 7 (3.4%) cases. (Figure 26).

Preoperative pulmonary hypertension, defined as pulmonary artery pressure greater than 50% of the systemic pressure was noted in 12 (5.9%) patients with TA. Cardiac catheterization was performed in 80% of the patients; more recently, MRI and computerized tomography (CT) have been used for definition of the branch pulmonary anatomy, especially in patients with PA/VSD.

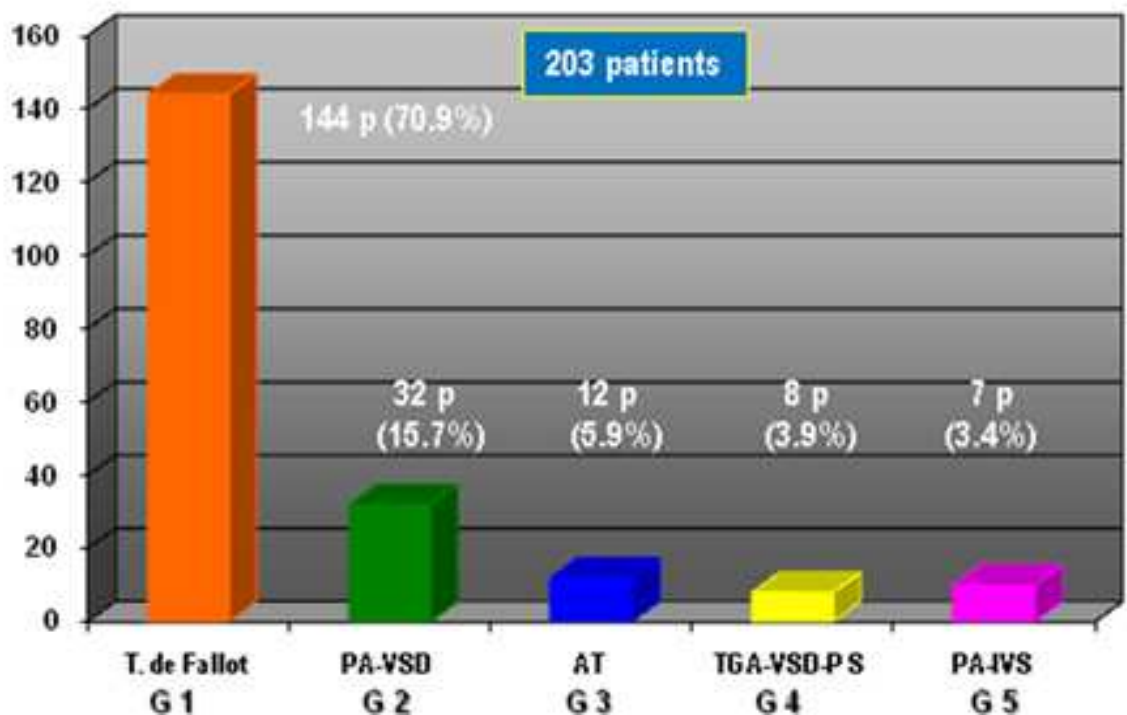


Fig. 26. Patients characteristic. T. Fallot: tetralogy of Fallot; PA/VSD: pulmonary atresia / ventricular septal defect; AT: arterial trunk; TGA / VSD / PS: transposition of the great arteries / ventricular septal defect / pulmonary stenosis; PA / IVS: pulmonary atresia / intact ventricular septum.

8.3 Prosthesis construction

The preparation of the biological material underwent several phases for the manufacture of the prosthesis: the valve and pulmonary trunk were isolated from the swine’s heart, followed by cleaning, tanning and tissue conservation.

Four different models of prosthesis were manufactured, according to the anatomical type of RV reconstruction that was programmed. These prostheses were prepared in series according to Braile-Biomédica specifications with strict Medical Quality Control. These prostheses are available commercially at Braile Biomédica and were employed for RVOT reconstruction by Pediatric Cardiovascular Surgery groups, in Brazil. (Figure 27).

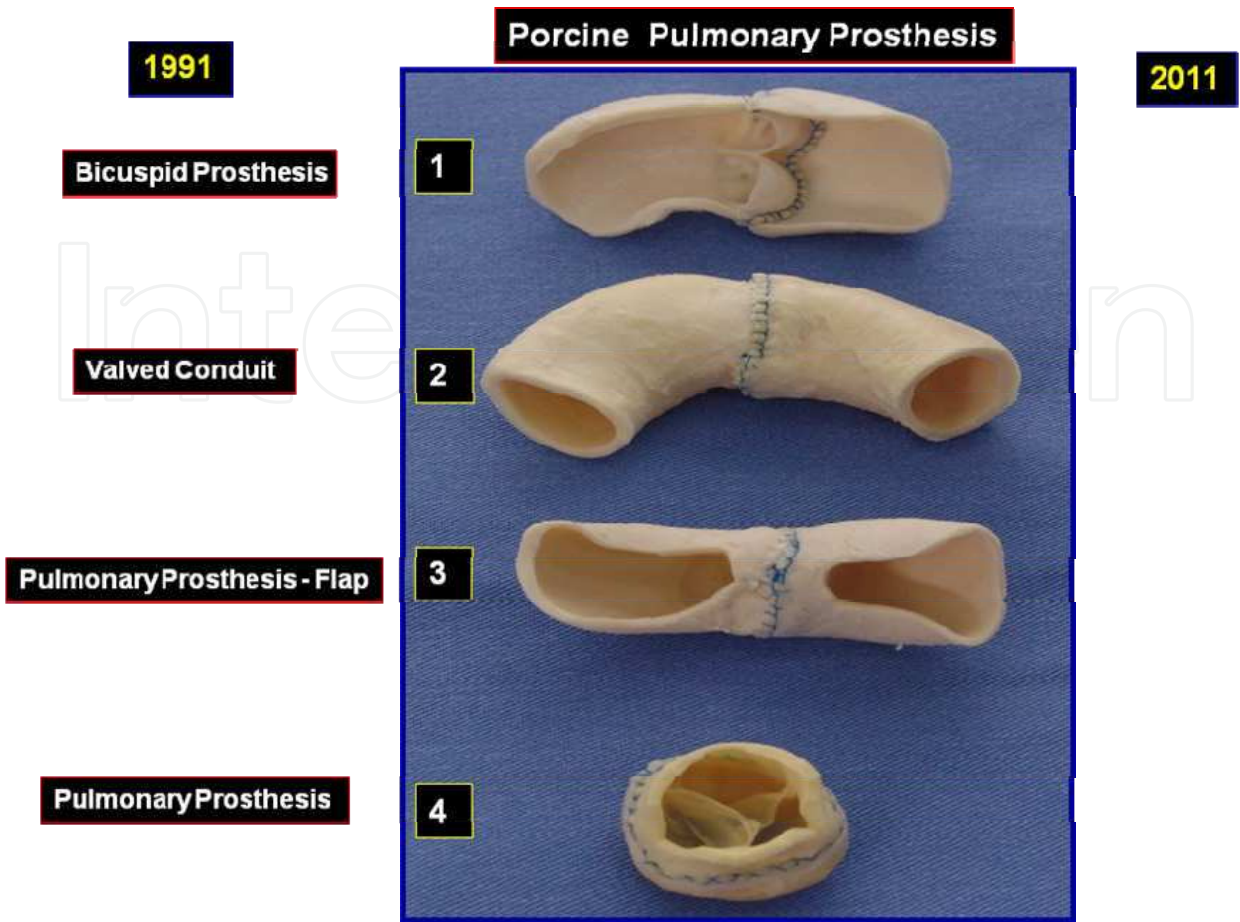


Fig. 27. Four different types of porcine pulmonary prosthesis

The pulmonary bicuspid prosthesis (PBP) was manufactured using two segments of the pulmonary artery, one including the trunk, ring and pulmonary valve and the other, only the pulmonary trunk (supravalvar area). The diameter of the pulmonary ring was measured using Hegar’s dilator and the grafts were classified according to the size in millimeters. One longitudinal incision was made in the concave part, removing a slice of the wall with one of the pulmonary valve cusps. A proportional wall segment was removed from the non-valved portion.

Finally, the two structures were ligated by their proximal tips and were superposed in a 3 to 5 mm extension, with continuous anchored polypropylene 5-0 suture. The suture was started at the graft’s concave face and followed the insertion of the fibromuscular ring cusp. A similar suture was performed in the convex side.

The pulmonary valved conduit (PVC) was manufactured using two entire segments of pulmonary trunk (one of these with trileaflet pulmonary valve); the tips of these segments were ligated with a running suture.

The pulmonary prosthesis with flap (PPF), was manufactured similarly to the CPP and two large flaps were performed at the pulmonary and ventricular tips.

The pulmonary prosthesis (PP) is performed by a short segment of the pulmonary artery, including the pulmonary valve

8.4 Surgical procedure

Our current strategy for RVOT remodeling utilized 4 types of preserved porcine pulmonary prosthesis: 1- Pulmonary bicuspid prosthesis (PBP) to repair the PV and RVOT reconstruction in patients under 1 year old (patients with narrow pulmonary ring and estimated pulmonary ring under 15 mm and 2- Pulmonary valved conduit (PVC): trileaflet prosthesis used in patients over 1 year old with pulmonary atresia. 3- Pulmonary prosthesis with flap (PPF) used in patients over 1 year old and hypoplastic pulmonary ring and pulmonary trunk. 4- Pulmonary Prosthesis (PP) used in patients with regular pulmonary ring or absent pulmonary valve (estimated pulmonary ring over 15 mm).

Other associated procedures for remodeling of the RV included: ventricular septal defect repair or LV to Aorta tunnel, tricuspid repair, pulmonary artery branch plastic procedure.

8.5 Group 1: Tetralogy of fallot

This group had 144 (70.9%) patients aging 5 months to 35 years (mean= 3.2): 30 cases (20.8%) had systemic pulmonary shunt as a palliative procedure before the operation; 4 cases (2.7%) had absent PV and 15 cases (10.4%) had pulmonary atresia. (Table 6)

Characteristic	Data
N° Patients	144 p
Age (year)	5 m to 35 y (mean: 3.2)
Blalock -Taussig Shunt	30 p (20.8%)
Absent pulmonary valve	4 p (2.7%)
Pulmonary atresia	15 p (10.4%)

Table 6. Tetralogy of Fallot – Preoperative Patients data

The surgery was carried out using cardiopulmonary bypass, established with bicaval cannulation and mild hypothermia. Aortic cross-clamping with intermittent potassium cold blood cardioplegia employed for the intracardiac repair. Vacuum-assisted venous drainage routinely utilized.

The VSD was closed by right atriotomy or right ventriculotomy approach, using treated bovine pericardium patch and running suture. Relief of the RVOT obstruction was obtained by wide resection of all septum-parietal and parietal-parietal muscle bundles of the pulmonary infundibulum. In all cases where the pulmonary annulus itself seemed narrowed; the incision extended through the pulmonary annulus up to the main pulmonary artery and the whole area was primary or reoperation; were performed with the heart beating.

For the reconstruction of the pulmonary ventricle in patients under 1 year old, a PBP was implanted and adjusted to the rudimentary pulmonary valve of the patient. (Figure 28).

In patients over 1 year old, a PPF (trileaflet pulmonary valve) was implanted in the native pulmonary annulus with running suture. For the reconstruction of the pulmonary trunk and RV outlet tract, two flaps (pulmonary and ventricular flap) of this prosthesis were used.

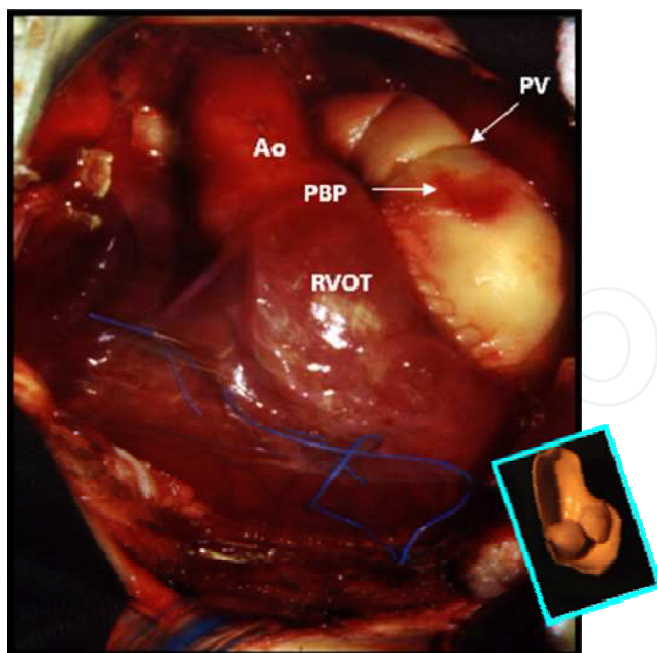


Fig. 28. Surgical photography. Patient with tetralogy of Fallot, submitted to remodeling of the right ventricle outlet tract (RVOT), using pulmonary bicuspid prosthesis (PBP) (in detail). Ao: aorta, PV: pulmonary valve.

Measurements were obtained by visualizing the heart images (including the prosthesis for the insertion of valves) and comparing them with the catheter's diameter in a superposed graded film with the identical magnification.

During the operation, the diameter of the pulmonary annulus was determined by classic normogram. The size graft was chosen according to the patient's weight: less than 10 kg, it was used 8 to 10 mm; and over 10 kg, it was used 12 to 20 mm.

In the cases with pulmonary atresia or absent pulmonary valve and under 1 year of age, a new cuspid was constructed using tissue from the pulmonary artery posterior wall, providing support for the PBP.

In patients over 2 years of age, the pulmonary valve and RVOT was reconstructed with porcine pulmonary prosthesis (Figure 29 a,b)

In cases with anomalous origin of coronary artery, crossing the infundibulum, the remodeling right ventricle surgery was performed with porcine pulmonary valved conduit. (Figure 30)

8.6 Group 2: Pulmonary atresia with ventricular septal defect

In this group, all thirty two (15.7%) patients were over 14 month of age. There were 3 cases with aortic-pulmonary collateral arteries submitted to previous unifocalization surgery plus Blalock-Taussig shunt. (Figure 31 a,b)

The surgical approach was performed by right ventriculotomy, after resection of the infundibulum muscle and closure of the VSD and finally was performed the right ventricle

remodeling surgery, implanting a porcine pulmonary valved conduit, between right ventricle infundibulum and pulmonary artery

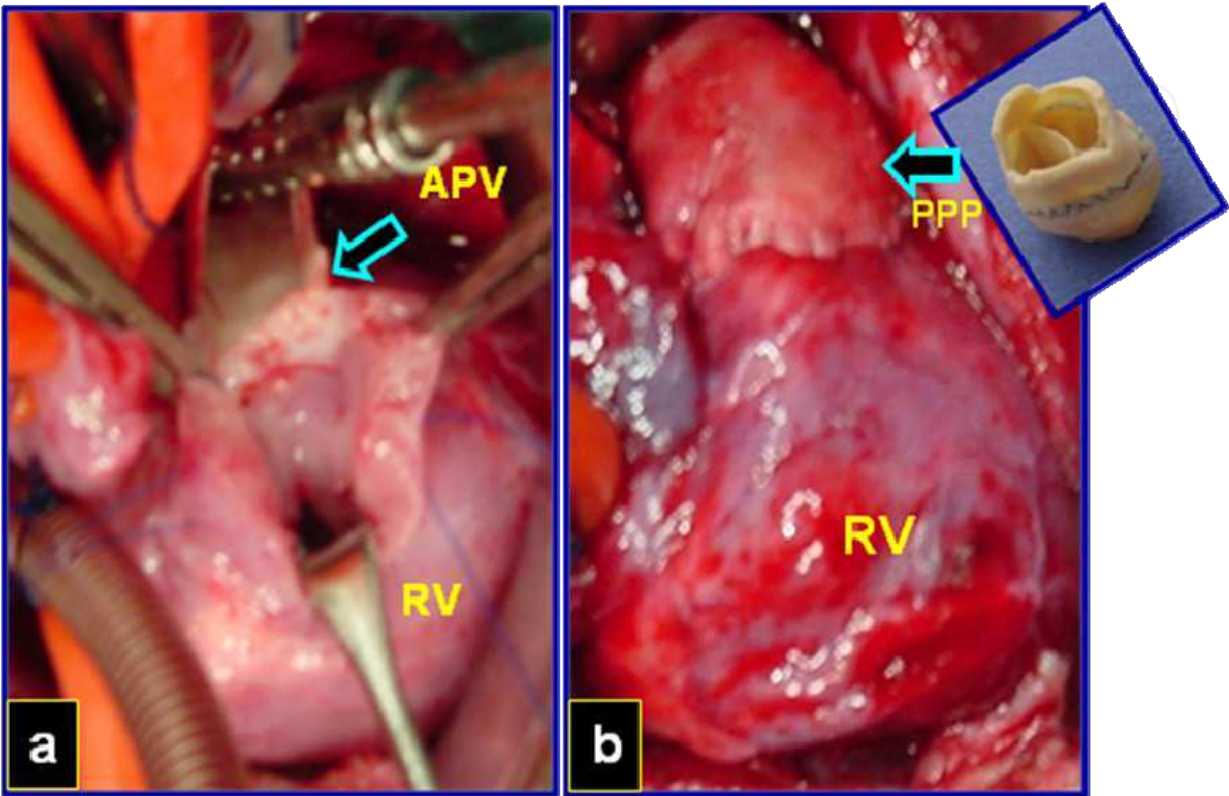


Fig. 29. Surgical photography. a- Patients with tetralogy of Fallot and absent pulmonary valve (arrow). b-Right ventricle (RV) remodeling with porcine pulmonary prosthesis (PPP) (arrow) (in detail)

8.7 Group 3: Truncus arteriosus

In this group, 12 (5.9%) patients under 6 months with TA type I, II were operated.

During the surgical approach, the pulmonary artery was disconnected from the ascending aorta and the left aortic sinus was reconstructed using a bovine pericardium patch; by the right ventricle approach, the VSD was closed, connecting the LV to the Aortic rout.

In ten patients, the posterior wall of RVOT was constructed with a pulmonary flap of the left pulmonary artery, but we did not use a monocuspid patch, according to the author`s technical specifications.

For the reconstruction of the pulmonary ventricle, we adjusted to the neo pulmonary annulus a PBP. In the remaining 2 patients, PVC was used for the reconstruction of the RVOT. PBP implantation was a surgical alternative for correcting TA type I and type II at early age (<6 months) using the technique without conduit.

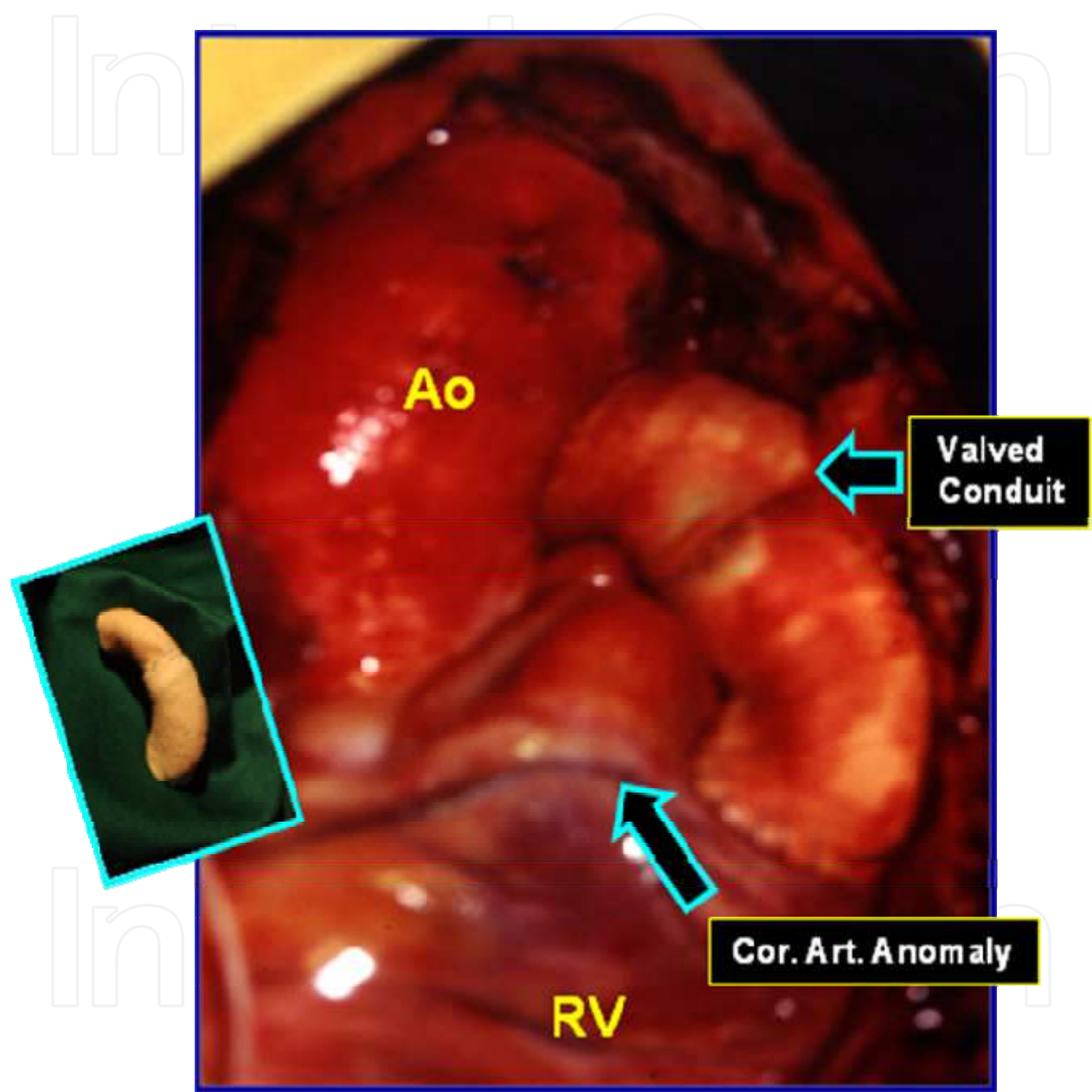


Fig. 30. Surgical photography. Patients with tetralogy of Fallot and anomalous origin of the coronary artery, crossing the Pulmonary infundibulum. The right ventricle remodeling surgery was performed with porcine pulmonary valved conduit (in detail). Ao: aorta, RV: right ventricle, Cor. Art.: coronary artery

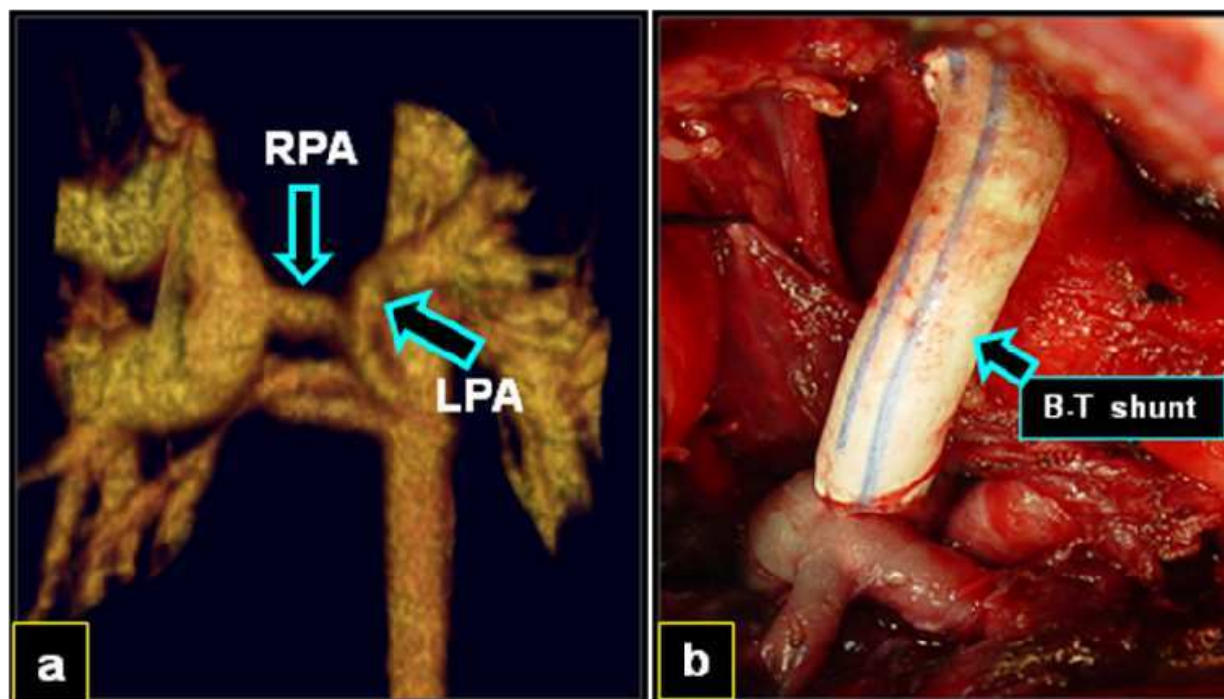


Fig. 31. a Computerized tomography showing pulmonary artery hypoplasia and aortic-pulmonary collaterals. b- Surgical photograph : Unifocalization plus Blalok-Taussig (B-T) shunt.

8.8 Group 4: Transposition of the great arteries with pulmonary stenosis

Eight (3.9%) patients of this group, age ranging from 2 to 8 years old (mean= 3.0), had TGA, VSD and left ventricle outflow tract obstruction (LVOTO) (Fig 32 a).

The Lecompte technique, introduced for the treatment of TGA / VSD / LVOTO is called: REV (Réparation à l'Etage Ventriculaire) procedure.

The Lecompte technique was performed in all our cases, and consists in approaching the upper right ventriculotomy, extensive resection of the conal septum and enlargement of the VSD. Afterwards, with a pericardium or Polytetrafluoroethylene (PTFE) patch and running suture, a tunnel was performed connecting the left ventricle to the aortic route (LV-Ao). (Figure 32 b)

Later, the aorta and the pulmonary artery were sectioned, the pulmonary valve was closed, the Lecompte maneuver was performed and finally the aortic and pulmonary outflow tracts were reconstructed.

In 6 cases a porcine pulmonary prosthesis with flap was used for the RVOT reconstruction (Figure 32 c) and porcine pulmonary conduit , in 2 remaining cases. One patient who had been submitted to Rastelli procedure 3 years earlier, presented RV-PA prosthesis obstruction and severe RV failure. This case was operated in emergency state and converted to Lecompte operation: After aortic section, the Lecompte's maneuver was performed and the pulmonary artery was positioned in front of the aorta. A PBP was used for RVOT reconstruction.

8.9 Group 5: Pulmonary atresia with intact ventricular septum

Seven (3.4%) patients of this group, with ages between 1 and 12 years old (mean= 4.0), had pulmonary atresia with intact ventricular septum (PA/IVS). Three patients had the first stage of the operation (Blalock-Taussig shunt plus pulmonary valvotomy) performed in neonatal period and second stage (Glenn operation) at 1 year old .

In these patients a “normal” tricuspid valve (Z score more than - 4.0) and hypoplastic but potentially usable right ventricle was observed. The repair consisted in patch closure of the atrial septal defect, tricuspid valve plastic repair and reconstruction of the RVOT was performed with PBP (One and a half ventricle repair with pulsate bidirectional Glenn) (Figure 33)

The remaining 4 patients had pulmonary valvotomy in neonatal period. The tricuspid valve and RV had morphology, size and function near normality. In these patients it was implanted a PPF to reconstruct the RVOT.

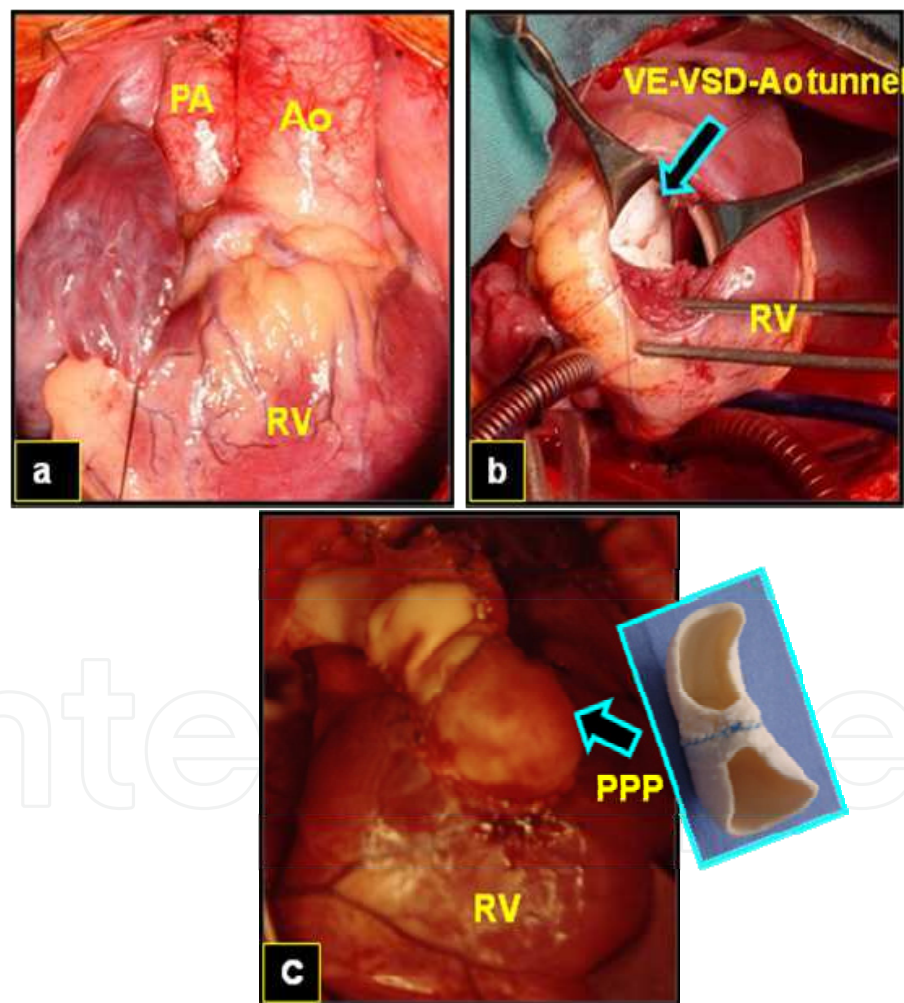


Fig. 32. Surgical photography. a- Transposition of the great arteries with ventricular septal defect (VSD) and left ventricle outlet tract obstruction. b- Lecompte operation : Left ventricle (LV) - ventricular septal defect (VSD) – aorta (Ao) tunnel is performed with polytetrafluoroethylene (PTFE) (in detail), and c- Right ventricle outlet tract reconstruction with porcine pulmonary prosthesis (PPP) with flap .

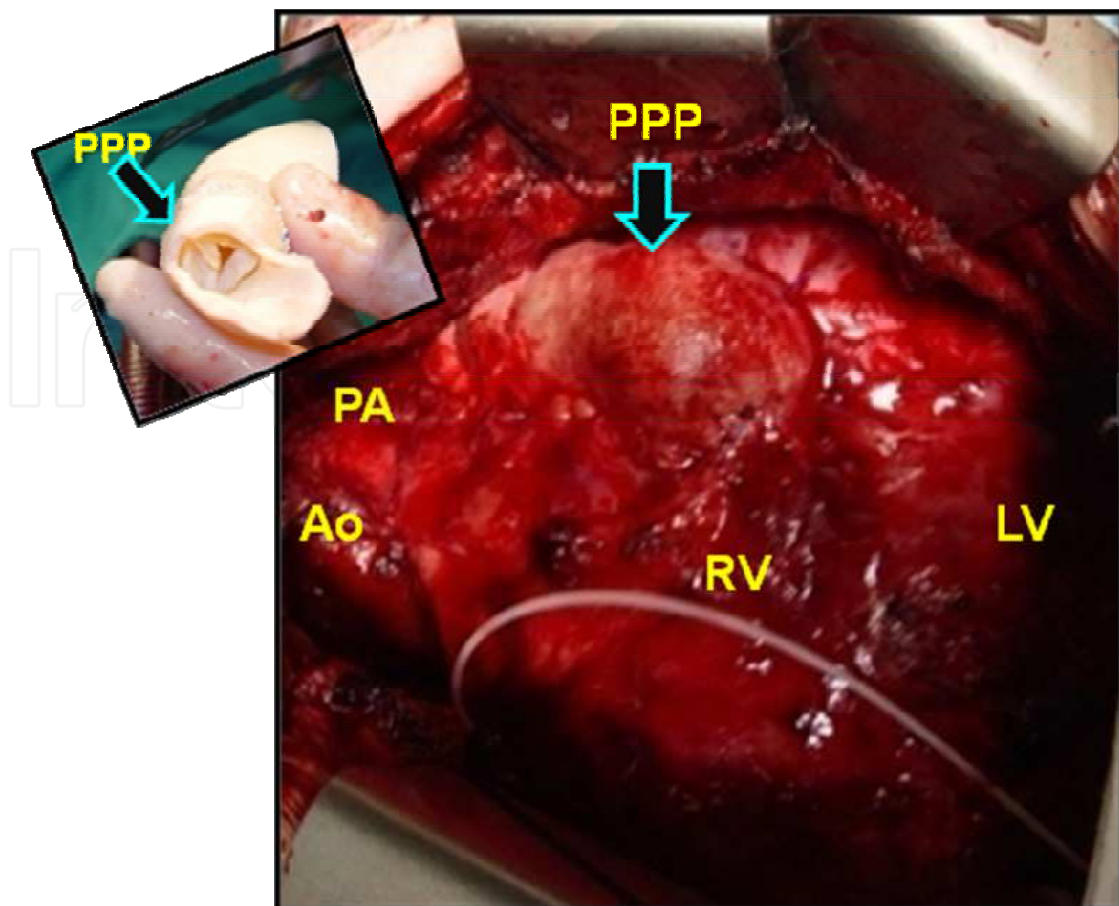


Fig. 33. Surgical photography. Pulmonary Atresia with Intact Ventricular Septum, submitted to surgical correction with: 1 ½ Ventricular Repair: Remodeling of the right ventricle (RV) outlet tract using valved porcine pulmonary prosthesis (PPP) (in detail); LV: left ventricle; Ao: aorta; PA: pulmonary artery.

8.10 Surgical recuperation

In all patients it was employed conventional ultrafiltration (CUF) during cardiopulmonary bypass (CPB) and in the last 12 years, modified ultrafiltration (MUF), after CPB was associated.

It was possible to discontinue CPB, in all cases and no patient had delayed sternum closure.

Sinus rhythm was maintained in all patients, before discharge from hospital. Temporary cardiac arrhythmias were detected, in 10 % of the cases, during hospital stay. No pacemaker was indicated or implanted in this group.

The most frequent cardiopulmonary support was performed with Dobutamine and Milrinone drugs.

8.11 Early and late mortality

There were 21 hospital deaths (10.3%); the mortality in different groups was: Group 1: TOF, 15 (10.4%) cases; Group 2: PA / VSD, 3 (9.3%) cases; Group 3: TA, 2 (16.6%) case; Group 4: TGA / VSD / LVOTO, 1 (12.5%) case. Group 5: PA / IVS, 0 (0.0%) cases.

There were 4 late deaths (2.1%): Two patients with TOF, caused by cardiac arrhythmia and bacterial endocarditis. Other two patients, with TA and PA/VSD, caused by ventricular dysfunction.

8.12 Morbidity

Forty (21.9%) nonfatal complications occurred in 182 early surviving patients.

In three patients it was detected residual pulmonary branch stenosis.

There were 159 (78.3%) patients free of reoperation.

8.13 Reintervention

Seventeen (9.6%) cases were submitted to reoperation due to residual defects or prosthesis dysfunction in an interval of 24 to 120 months after operation. Two patients developed aneurysmatic dilatation of the pulmonary prosthesis: after TOF correction and after "One and half ventricle" correction. Both patients died after reoperation due to ventricle dysfunction and surgical bleeding.

The pathologic study of the prosthesis removed shows: calcification islands compromising the external wall but preserving the integrity of its leaflet; nevertheless, two cases with aneurysmatic dilatation show sling wall and no presence of calcification. (Imperfection tissue fixation?).

Two patients presented residual pulmonary stenosis, located at the right and left branch origin. Both cases required placement of pulmonary stent implant.

8.14 Follow-up

Reconstruction of the PV and remodeling of the RV was an essential component in the treatment of many patients with congenital heart disease.

Fourteen patients (7.9%) were lost during the follow-up. One hundred and sixty two (79.8%) surviving patients were followed from 4 to 204 months (mean= 108). Actuarial survival curve at 204 month was estimated in 86.6%. (Figure 34)

The follow-up of these patients included: Clinical exam, exercise stress test, metabolic stress test, Doppler echocardiography study, Hemodynamic study, MRI and CT study.

We do not have all the complete data set on all of the above variables for the entire cohort of patients in this manuscript.

8.15 Doppler echocardiography study

This was the most frequent auxiliary study employed to analyze the results of cardiac surgery and prosthesis performance. This study was performed twice a year, during the follow-up. With the echocardiogram many parameters of the RV function were studied: RV performance, RV dimensions; and with the Doppler index: if tricuspid regurgitation (TR) is present an estimate of RV pressures, RV-PA gradients and pulmonary and tricuspid valves function.

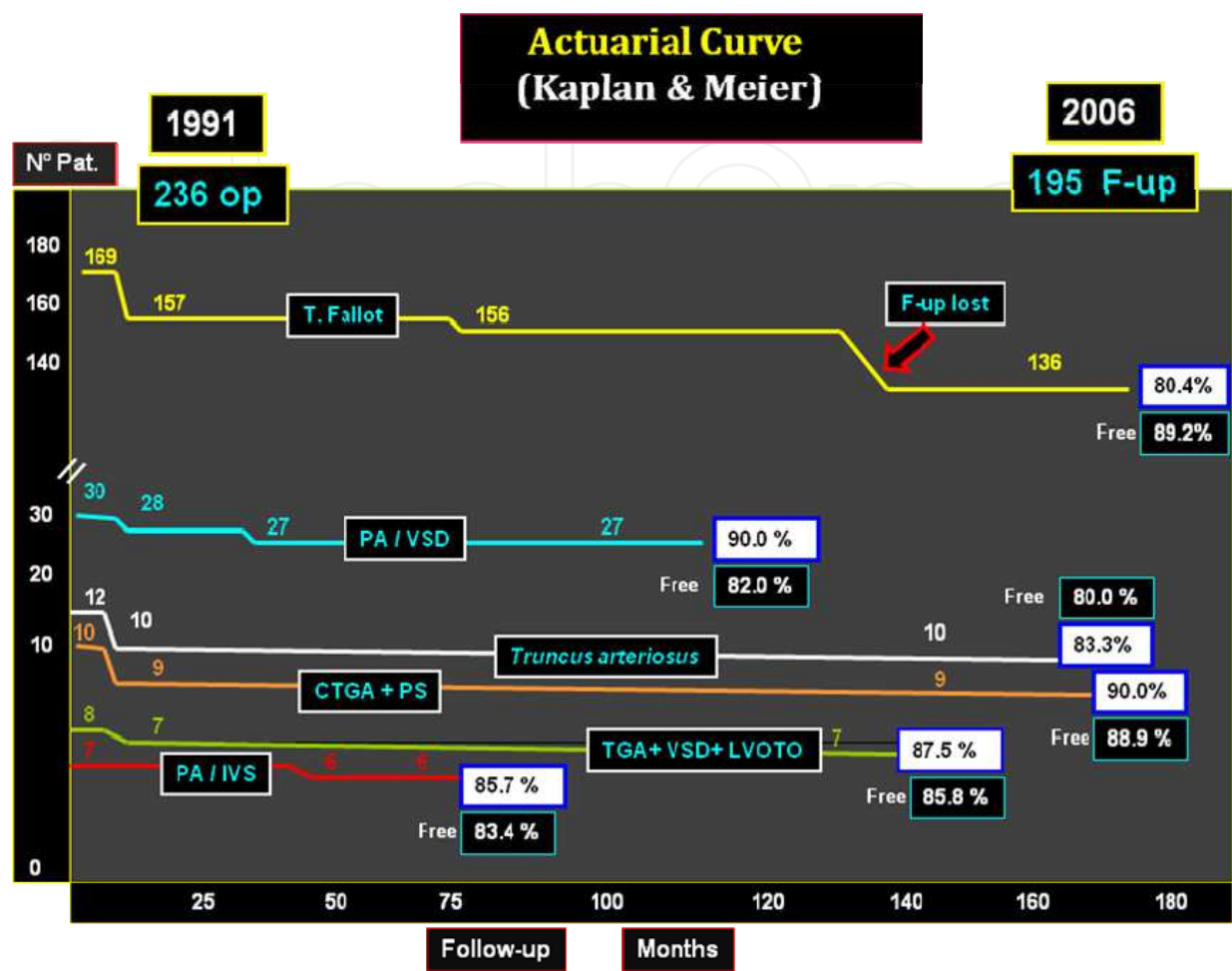


Fig. 34. Actuarial survival curve of patients undergoing right ventricle remodeling

One hundred and forty three surviving patients were discharged from hospital with RV-PA gradient less than 30.0 mmHg and trivial to moderated VPI. During the follow-up, in ten patients the Doppler-echocardiogram was decisive for reoperation and in other two patients, for the indication of hemodynamic procedure.

Among the 162 (79.8%) regular late follow-up patients, the degree of VPI that increased slightly was detected in 20 patients (12.3%), but only one patient had important pulmonary regurgitation

8.16 Hemodynamic evaluation

Hemodynamic studies were carried out in the first 15 (9.2%) cases of 162 survival patients with regular follow-up. All 15 patients had TOF and follow-up between 48 and 87 months (mean= 65.1). The patients age ranged from 5 to 16 years (mean= 8.2 years). Table 7.

Characteristic	Data
Age (years)	5 to 16 (mean=8.2)
Gender	F=6 (40.0%)
Weight (Kg)	16 to 49 (mean=23,6)
High (cm)	107 to 167 (mean=125.6)
Body surface (cm ²)	0.75 to 1.55 (mean=0.98.6)
PO Follow-up (month)	72 to 108 (mean=84)
Absent pulmonary valve	3 p (20.0%)
Pulmonary atresia	2 p (13.3%)

Table 7. Tetralogy of Fallot – Postoperative Hemodynamic study in 15 patients.

Right ventriculography in right anterior oblique (RAO) position and left anterior oblique (LAO) position and pulmonary arteriography in anterior posterior projection were carried out in all of the cases. The dimensions of the RV were established during cardiac cycle.

The measurements were obtained by visualization of the heart images (including the prosthesis for the insertion of valves) and superposed in a graded film with identical magnification which was compared to the catheter’s diameter.

In some cases it was difficult to establish the position of the pulmonary ring due to the presence of RVOT prosthesis. The degree of VPI was evaluated by the quantitative method after injection of contrast solution in the pulmonary artery, and the VPI was classified as mild when regurgitation was lower than 50% (group A) and moderate when greater than 50% (group B).

8.17 Hemodynamic dates

Out of fifteen patients undergoing hemodynamic and angiocardiographyc evaluation, no residual blood flow from left to right ventricular camera or significant gradient between the RV and PA was observed.¹⁴

8.18 Magnetic Resonance Imaging and Computerized Tomography study of the heart

Cardiac MRI and CT study has become an available method of diagnostic and postoperative follow-up. (Fig 35, 36)

In order to assess the responses of PV reconstruction and remodeling of the RV with PBP or PPF, it was used CT imaging and PVI evaluation and biventricular function using a MRI in patients who underwent TOF, PA / VSD, AT, TGA / VSD / LVOTO and PA/IVS repair.

In 2006, 10 patients were submitted to MRI and CT study with follow-up over 10 years. The parameter of cardiac function was obtained at rest: RV ejection fraction was normal (>45%) in 8 (80%) patients, the MRI was well suited to assess cardiac response and findings revealed a discrete VPI in PBP and a trivial VPI in PPF.

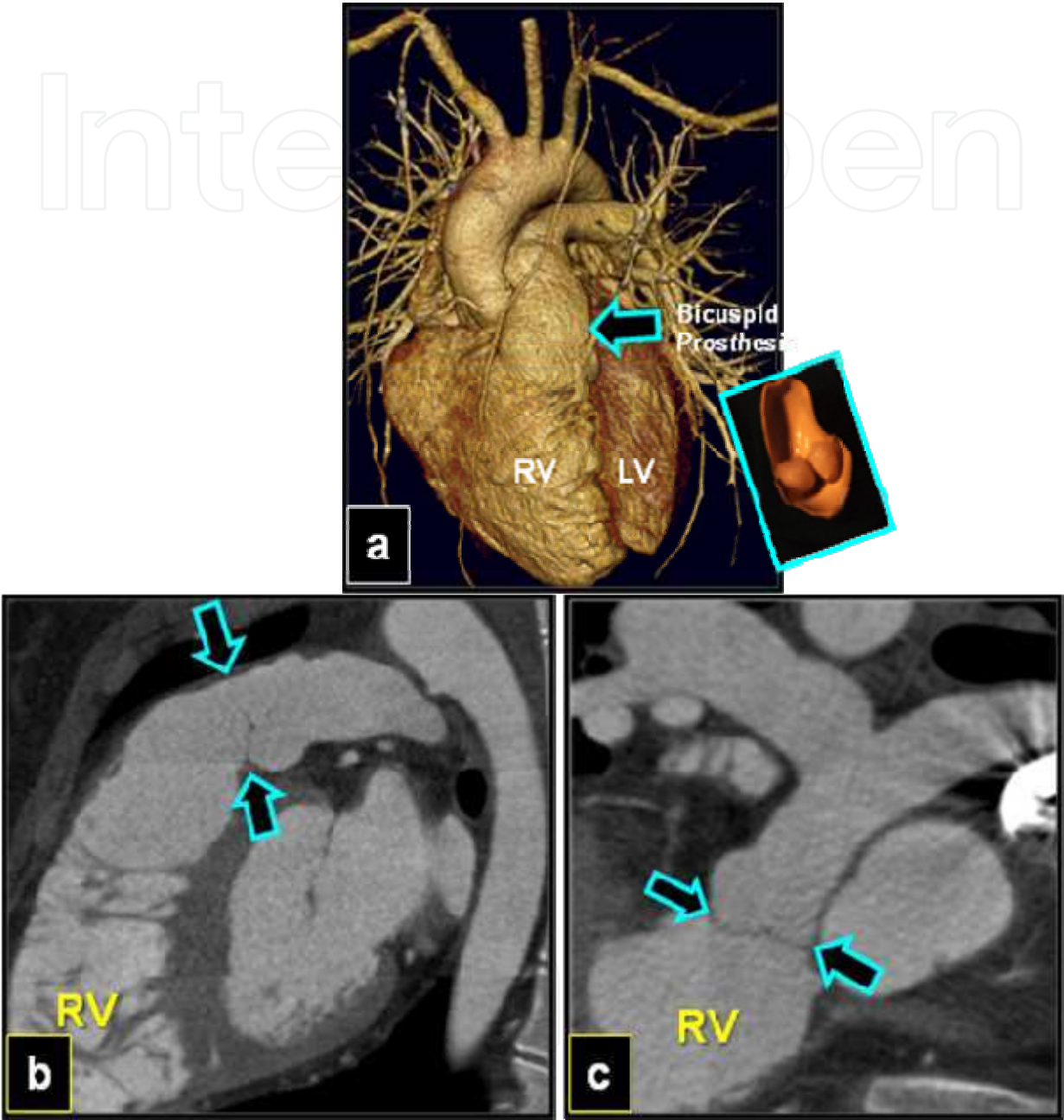


Fig. 35. Computerized tomography in a patient with tetralogy of Fallot submitted to surgical remodeling of the right ventricle (RV) outlet tract with an implant of a preserved porcine pulmonary bicuspid prosthesis (in detail), with 16 years of follow-up (arrows). LV: left ventricle

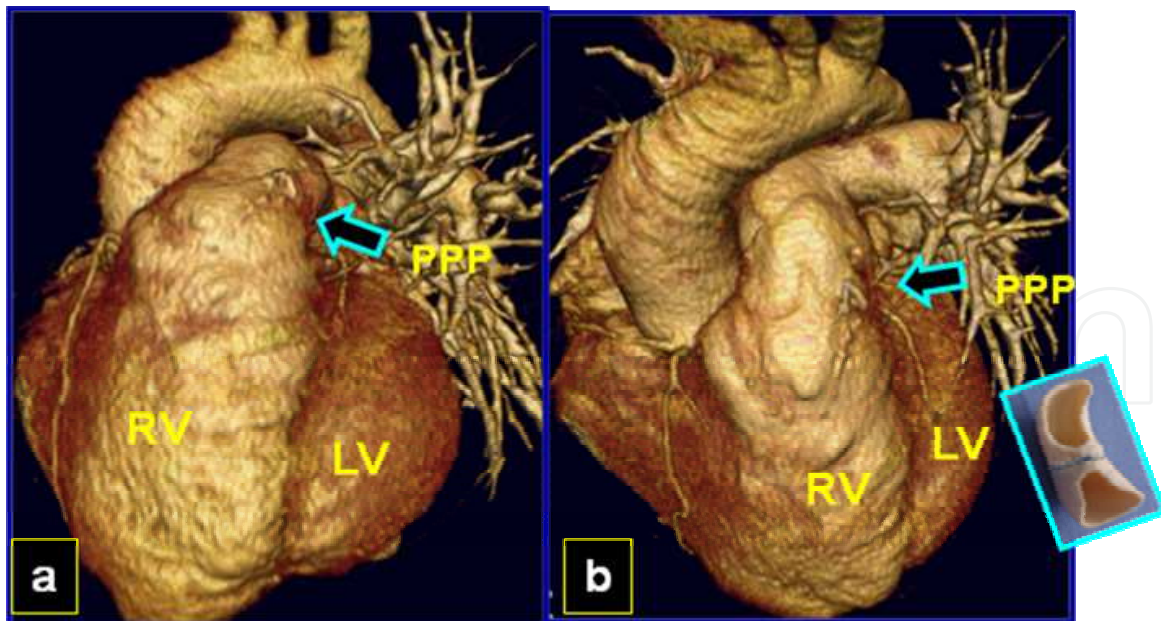


Fig. 36. Computerized tomography: a, b: Patient with tetralogy of Fallot and severe pulmonary insufficiency, after twenty years of follow-up., submitted to surgical remodeling of the right ventricle (RV) outlet tract with an implant of a preserved porcine pulmonary prosthesis (PPP) (in detail), with 7 years of follow-up (arrows). LV: left ventricle.

8.19 Statistical analysis

Statistical analyses of continuous variables were performed with both methods: by paired t test and the analysis of categorical variables performed by the Student's t test and $p < 0.05$ was considered statistically significant. The surviving patients curve was prepared according to the Kaplan-Meier's method, comparing 2 or more functions by the long-rank test. For all tests, a p value of less than 0.05 was considered significant.

8.20 Comments

The patients undergoing TOF repair surgery have an excellent prognosis and good late survival in about 90% of the cases, ten years after the surgery. In 95% of the cases it is possible the patient's social reintegration and good physical ability during exercise and 79.3% practice sports.²⁰

Reconstruction of the PV and remodeling of the RV using valved prostheses is an essential component in the treatment of patients with TOF and others congenital heart diseases with pulmonary ventricle obstruction.

It is difficult to establish the number of patients who had surgical correction of TOF and required reoperation. In general, it depends on the anatomical lesion of each patient and the kind of surgical approach used, as well as the kind of surgical reconstruction employed.

Multiple surgical options for PV reconstruction are available for these patients: mechanical valves, mechanical conduits, monocuspid homograft or patch, pulmonary and aortic homograft, stented and stentless heterograft, heterograft conduits, bovine jugular vein conduits and autologous pericardial valves.

The use of a mechanical valve in the pulmonary position has been reported in a few patients and had fallen out, due to frequent occurrence of thromboembolic phenomena and valve failure

In 1967, Marchand introduced a monocuspid homograft with excellent results. This type of RVOT repair was very well accepted and routinely adopted in several services, however, the presence of diastolic murmur and the early postoperative evaluation found out that different degrees of pulmonary insufficiency were interpreted as an inadequate alignment of the leaflet graft with the pulmonary valve native leaflets in the early postoperative follow-up. In 1968 Asano & Eguchi published their clinical experience with the use of a bicuspid pulmonary homograft and bicuspid pulmonary heterograft. An autologous pericardial segment sutured to pulmonary ring was used for the reconstruction of the RVOT. A posterior author's (publication 28) performed, described aneurismal dilatation of autologous pericardial segment at late follow-up.

Therefore, when the enlargement of the pulmonary ring is strictly necessary, the use of open tile-shaped prosthesis, in patients under one year old, allowed the ring to grow at the expense of the posterior wall. On the other hand, once this is a valved prosthesis adjusted for the right closure at the time of the operation, the growth of the pulmonary ring might make the prosthesis less contingent. On the other hand, the growth of the native valve might also be expected, although it can hardly be clinically proven.

A larger experience with PTFE monocuspid for RVOT reconstruction in 115 patients with follow-up of 6 months to 8 years (mean=2.6), demonstrated significant development of VPI graded as moderate to severe after 35 months in this monocuspid study.

Homograft valves have become widely used for reconstruction of the right ventricular outflow tract in congenital heart disease. However, mid-term and long-term follow-up studies have clearly demonstrated conduit obstruction and early valve insufficiency, degeneration and progressive calcification, more frequent in aortic homograft.

Some authors suggest that possibly the durability of cryopreserved pulmonary homograft is similar to pulmonary homograft used for the Ross procedure. When the trileaflet prosthesis is implanted in the orthotopic position, as in the Ross aortic valve replacement patient, can be easily accommodated, maintaining valvar competence.

The limited durability of homograft conduits, especially in small sizes, supported the search for an alternative conduit as the PBP, bicuspid homograft and PTFE bicuspid valve, that allowed the growth of the posterior face of the pulmonary ring and posterior wall of the pulmonary trunk. The superiority of the bicuspid prostheses has been demonstrated in experimental studies for reconstruction of a hypoplastic pulmonary root, and this experience was confirmed in clinical experience.

Pulmonary valve insufficiency may have a negative impact on RV function leading to the need for reoperation for the insertion of a competent valve at the RVOT.

There are no ideal options for restoring the VPI. Studies including adult patients with TOF after pulmonary valve replacement with various prostheses, generally reported good long-term results with both porcine xenograft and homograft.

VSD or PS might impair the long-term results and significantly change the patient's prognosis. Beginning in 1991, we started to use a preserved PBP in infants and PPF in children for the reconstruction of PV and RVOT in patients with TOF aiming to decrease residual VPI.

This series of patients undergoing TOF repair surgery presented an excellent prognosis and good late survival rate in about 80% of the cases, seventeen years after the surgery. 78% of the surviving patients, with late follow-up, are free of reoperation and show good physical ability during exercise and practice of sports. The hemodynamic evaluation of these patients shows that average individual RV/LV length ratios did not increase over time.

Although the preliminary studies of a valved bovine jugular vein conduits had reported short to intermediate term durability, Boudjemline et al and Zavanella et al, reported similar findings of extensive fibrosis at the conduit pulmonary anastomosis by developing intimal proliferation.

In these patients, submitted to PPF implantation, a technical modification was introduced to reduce PS development by intimal proliferation at the conduit: It was performed an enlarged pulmonary anastomosis, after constructing a flap at the distal graft's tip.

This procedure was also used for the reconstruction of pulmonary ventricular outflow tract in another group of patients: PA / VSD, AT, PA / IVS, TGA / VSD / LVOTO.

In the PA/VSD group, all patients were over 14 months of age and only 18 cases had palliative procedure, type: Blalock-Taussig shunt and unifocalization procedure.

All patients were submitted to pulmonary arteriography; in order to study the diameter of the PA (trunk, right and left branches) it was determined the McGoon index. Although, other quantitative methods were employed to study the degree of pulmonary development, in order to measure the pulmonary area, it was determined the Nakata index or PA index (PAI). All patients of our series had PAI higher than 150 mm/m².

During the operation, it was possible to close the VSD in all patients and after cardiopulmonary bypass, the RV/LV ratio pressure was measured; in all cases this relationship was below 0.58%. Total deaths: one patient died after refractory low cardiac output and another by generalized infection.

In the AT group, two types of prostheses were used for the reconstruction of the PV and remodeling of the RVOT:

The implant of the PBP was a surgical alternative for the correction of the AT type I, II, at early age (under 6 months), using the technique without conduit. In 8 patients of our series, it was possible to use the RVOT reconstruction using a bicuspid prosthesis: Using a flap of the left pulmonary it was constructed the posterior wall of the RVOT and using one PBP and running suture this prosthesis was adjusted

There were two hospital deaths by pulmonary hypertension crises.

The PVI was trivial in all cases, at the immediate postoperative period, in 7 surviving patients. At this moment, no patient was submitted to re-intervention, but actually 3 patients are in functional class II (NYHA) and presented moderate VPI.

2 - In the second type of prosthesis, the PP was implanted in patients older than 6 months. Two patients underwent operation with this technique: One patient, who underwent operation with a valveless woven Dacron conduit 5 years earlier in another center for RV dysfunction with significant PVI, received a PP implant.

The pulmonary ventricle may be compromised by either morphologic or functional problems, or by both. The morphologic defect may be defined by tricuspid valve Z value. In general, this value also reflects the corresponding ventricle volume.

Right ventricle outflow tract is alleviated by a variety of techniques, including muscle resection, valvotomy with division of the pulmonary annulus along with the commissure and reconstruction of the RVOT with a trans-annular pericardial patch or biological valved prosthesis.

In our series, seven patients with PA /IVS were submitted to correction with "one and half ventricle" technique, with success. All cases had Glenn procedure previous and were performed with the same procedure: atrial septal defect (ASD) closure and reconstruction of the RVOT with PPF. One patient was submitted to trans-catheter closure of the residual Blalock-Taussig shunt. The right ventricle performance and RV - PA junction were evaluated with MRI and the RVOT reconstruction with CT study. (Fig 8 A,B) The gradient RV - PA in all three patients was lower than 30 mmHg.

The Lecompte⁵¹ procedure introduced for the treatment of TGA / VSD / LVOTO, consisted in the construction of a LV to Ao tunnel, after conal septum resection, by ventricle approach. The RVOT reconstruction is performed after the pulmonary artery is transferred in front of aorta (Lecompte maneuver). A valved prosthesis is employed for the pulmonary valve reconstruction. This technique is called the REV procedure.

For the reconstruction of the pulmonary outflow tract there are two techniques:

When the aorta and the pulmonary artery are in anteroposterior position, the reconstruction of the RVOT is possible, after transversal aorta and pulmonary artery section and pulmonary valve reconstruction in front of the aorta.

When the aorta and the pulmonary artery are in side by side position, the Lecompte maneuver is dispensed and a valved conduit is necessary to reconstruct the pulmonary outflow tract.

In our series, when the great arteries had an anteroposterior relationship, it was not difficult to pull the pulmonary artery down to the right ventriculotomy site without tension in order to reconstruct the pulmonary outflow with a PBP. However, when the pulmonary artery and the aorta were in side by side position, the Lecompte maneuver was also employed and the pulmonary outflow tract was reconstructed with PPP.

8.21 Conclusion

The clinical follow-up of 176 (86.6%) patients from 4 to 204 months (mean=108) allowed the following conclusions:

Right ventricle remodeling constitutes a safe and standardized technique.

The early reconstruction of the pulmonary valve and right ventricle outlet tract could be able to preserve ventricular performance for a long period.

The prosthesis function could be analyzed during the follow-up.

The porcine pulmonary prosthesis has shown satisfactory results for a long time.

9. New technique in Cardiopulmonary bypass

9.1 Conventional and Modified Ultrafiltration during cardiac surgery in high-risk congenital heart disease.

The use of cardiopulmonary bypass (CPB), with hypothermia and hemodilution, in the pediatric age group is associated with the accumulation of an excessive amount of water. The ratio of prime volume to patient blood volume may be twice as high in smaller patients. However the inflammatory capillary leak is probably responsible for tissue edema and malfunction of several organs. Dilution of plasma proteins increases water transfer to the extravascular compartment and postoperative blood loss as a result of clotting disturbances.

Several methods are in use in order to reduce this water accumulation such as reduction of circuit diameter and prime volume, anti-inflammatory therapy, continuous diuretic and peritoneal dialysis. In 1991, Elliott's group from The Hospital for Sick Children at Great Ormond Street (London), reports an alternative technique of modified ultrafiltration (MUF) after CPB, through a filter with semi-permeable membrane, to remove water, electrolytes and other low molecular weight substances.

Conventional ultrafiltration (CUF), performed during CPB is associated with a statistically significant prime ultrafiltration but with clinically poor results.

Early studies with CPB in children demonstrated clinical improvement due to inflammatory agent removal, including endothelin-1 (a potent pulmonary vasoconstrictor) and other cytokines released during the warming period of CPB.

Efforts to reduce the detrimental effects of the capillary leak syndrome after CPB include ultrafiltration during CPB.

This prospective study was therefore undertaken to compare the effects of CUF + MUF with those of CUF during surgery for congenital heart disease.

9.2 Patients and methods

Forty-one children with complex congenital heart disease who underwent operations using CPB at Cardiovascular Division of the São Paulo Federal University .

Our service is the first service in the country in implementing this technique. To day, the MUF is used routinely in all patients submitted to surgery with CPB

Patients operated between January 1996 and March 1998 were included in this study. The Ethics Committee of the Institution approved the study protocol and informed consent was obtained from the parents of each child.

9.3 Patient group

This was a prospective, consecutive and nonrandomized study. We assigned 41 patients to one of two groups as follows: control group (n = 21) in which CUF during CPB was used.

Pediatric cardiac surgeries were performed between January 1996 and April 1997 (CUF group); and the experimental group (n = 20) in which CUF was associated with MUF after CPB, with surgeries performed between May 1997 and March 1998 (CUF + MUF group)

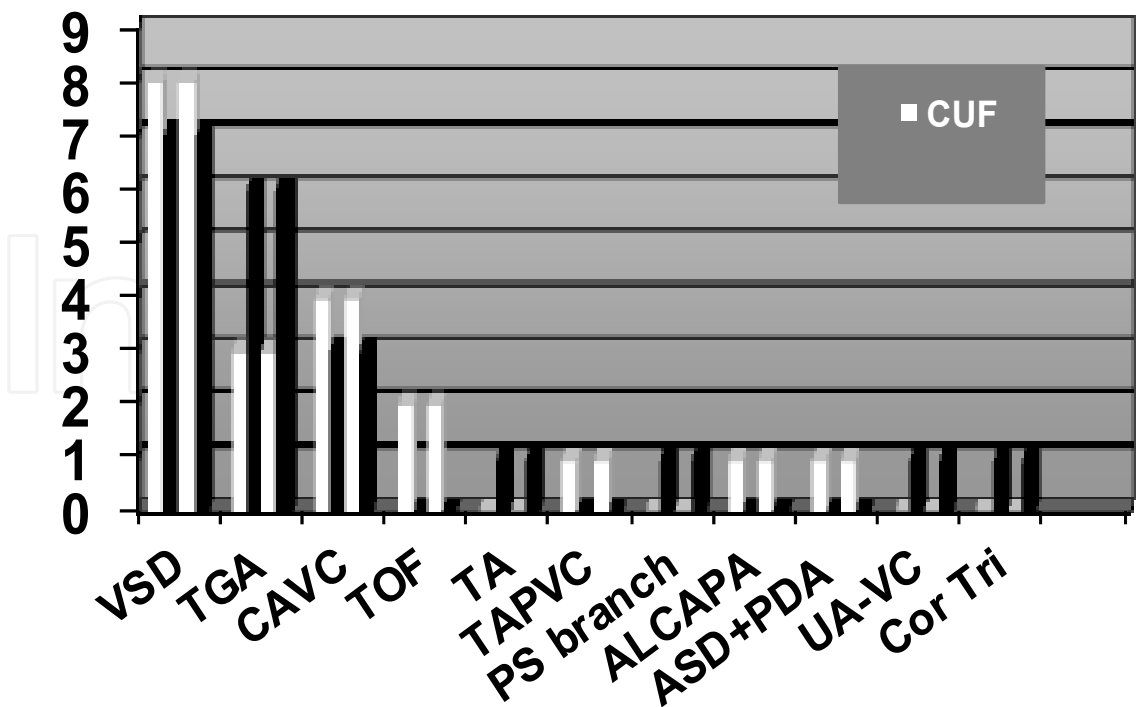
The patient characteristics are shown in Table 8. Both groups included patients with ages between 9 and 36 months. These groups were homogeneous and no significant differences were observed between them.

1996 - 1997			1997 - 1998		
CUF			CUF+MUF		
21 patients			20 patients	p	
10/11	—	Sex (M/F)	10/10	----	
15.0 ± 11.8	—	Mean age (mo)	9.2 ± 8.5	0.08	
1 (4.7%)	—	Neonates	3 (15.0%)	----	
7.2 ± 3.0	—	Mean weight (kg)	5.7 ± 2.5	0.09	

CUF: conventional ultrafiltration; CUF+MUF: modified ultrafiltration; mo.: months

Table 8. Patients characteristics

The preoperative diagnoses for each group were classified into 4 different degrees according to the operative complexity (Jenkins et al), as shown in Figure 37.



*Jenkins et al. (1995)

Fig. 37. 4 Operative Complexity

Figure 1: VSD: ventricular septal defect; TGA: transposition of great arteries; CAVC: complete atrioventricular canal; TOF: tetralogy of Fallot; TAPVC: total anomalous pulmonary vein connection; ASD: atrial septal defect; PDA: patent ductus arteriosus; TA: truncus arteriosus; ALCAPA: anomalous left coronary artery from pulmonary artery; PS: pulmonary stenosis; UA-VC: univentricular atrioventricular connection; Cor Tri: Cor triatriatum.

9.4 Preoperative evaluation

Preoperative evaluation was performed by cardiac catheterization in all patients with moderate and severe pulmonary hypertension (PH), using a 40-biplane angioscope (Siemens). Preoperative PH was defined as a systolic pulmonary pressure/systolic systemic pressure > 60. PH was present in 15 patients (71.4%) of the CUF group and in 14 patients (70.0%) of the CUF + MUF group.

Transthoracic Doppler echocardiography was performed in the patients using ATL Ultramark 9 with a 3-5 MHz transducer.

9.5 Surgical technique

Surgical management was standardized by cannulation of the ascending aorta for inflow, separate caval cannulae being inserted through the right atrium. CPB was instituted after 400 U/kg heparin infusion. A flow rate of 2.4 l/min/m² at normothermia was reduced to 1.8 l/min/m² during moderate hypothermia (25°C to 28°C).

Deep hypothermia (< 24°C) and circulatory arrest were not required. The left side of the heart was vented with a catheter inserted in the apex through the right upper pulmonary vein.

The pump prime was composed of 500 to 900 ml electrolyte solution with 5% glucose (Darrow Imagem S/A, Brazil), sodium bicarbonate 10 to 30 mEq/l, 25% albumin (12.4 g/250 ml of prime), 2% mannitol 2.0 ml/kg and washed packed red blood cells to maintain a hematocrit value of 25%. Partial arterial pressure of carbon dioxide was recorded. The infusion of blood cardioplegic solution was repeated at 20-minute intervals.

9.6 Technique of conventional ultrafiltration

In the CUF group, patients were treated with ultrafiltration during CPB, at the warming stage, which removed excess fluid and hemoconcentrated the patient's blood. A hemoconcentrator (model HPH 400, Minntech, Minneapolis, MN) was also inserted in parallel in the cardioplegic line (connected to the recirculation line).

The total amount of fluid filtered by CUF was 19.7 ml/kg. After CPB, blood from the extracorporeal circuit was centrifuged for red cell salvage.

9.7 Modified ultrafiltration technique

The MUF group was submitted to the CUF procedure during CPB and then an arteriovenous ultrafiltration via the cardioplegia circuit was used according to Groom's technique, with some adjustments introduced in the system (Fig. 38).

Following the last dose of cardioplegia, the hemofilter is placed in the cardioplegia circuit after the cardioplegia (sucker) roller pump but before the heat exchanger. The cardioplegia line is clamped and CPB is discontinued but the heparin is not reverted.

The venous cannulae are removed from the right atrium and the blood within the venous line is siphoned into the venous reservoir. The clamp on the arterial filter bypass line is removed and placed just prior to the filter. A 10 F to 12 F cannula is attached to the cardioplegia line and placed in the atrium. The cardioplegia pump is turned on and the flow is slowly increased.

Modified ultrafiltration circuit connected to cardioplegia line and heat exchange

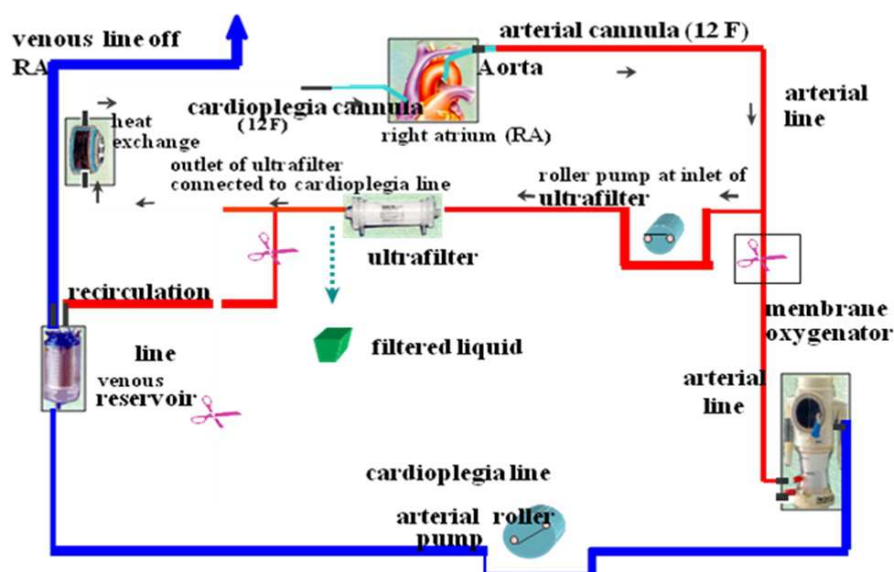


Fig. 38. Modified Ultrafiltration Circuit

This maneuver pumps blood from the aorta through the hemofilter and cardioplegia system and then Returns, the warm blood, to the RA after passing through the heat exchange of the cardioplegia line.

When the target flow of 100 to 200 ml/min is reached, the clamp of the filtrate line is removed, allowing the ultrafiltration process to begin. No suction was applied to the filtrate line. As plasma water is removed, it is necessary to maintain the patient's volemic status by transfusing the content of the pump circuit at a rate equal to the filtration rate.

After this process continues for approximately ten minutes, the cannulae are removed and protamine is administered. The total amount of fluid filtered by conventional and modified ultrafiltration in this group was 39.3 ml/kg.

Intraoperative monitoring

Left atrial catheter was used in all patients and pulmonary arterial catheter was used in patients with preoperative PH. When the systolic pulmonary artery pressure was higher than 40 mmHg, nitroprusside at a dose of 0.5 to 1.5 $\mu\text{g/kg/min}$, or nitroglycerin at a dose of 1 to 10 $\mu\text{g/kg/min}$ was used.

If dobutamine or dopamine was required, a dose of 5 to 10 $\mu\text{g}/\text{kg}/\text{min}$ was used; or in the case of epinephrine, a dose of 1 $\mu\text{g}/\text{kg}/\text{min}$.

9.8 Postoperative pulmonary hypertension control

Patients with preoperative PH were curarized and moderate hyperventilation was used. These patients also received nitroprusside, nitroglycerin and nitric oxide.

9.9 Postoperative management

All patients were followed-up in the Pediatric Intensive Care Unit (PICU).

9.9.1 Strategy for extubation

The respiratory management consisted of mechanical ventilation support to maintain the arterial oxygen tension at > 100 mmHg, the arterial carbon dioxide tension at 30 to 35 mmHg and the pH at 7.45 to 7.50. Once the children exhibited hemodynamic stability, they were weaned from mechanical ventilatory support and sedation.

Once the children demonstrated the ability to sustain adequate spontaneous respiration effort and required minimal supplemental oxygen as reflected by normal arterial blood gases, they were extubated. Neonatal patients at high-risk for post-operative PH required longer ventilatory support. Strategy for blood or hemoderivate replacement

No patient in this study received aprotinin. Washed packed cells were transfused to maintain hematocrit at 40% for patients with cyanotic congenital heart disease and 35% for those without cyanotic heart disease. Platelets, fresh frozen plasma, cryoprecipitate and albumin were transfused as required postoperatively.

9.10 Statistical analysis

Comparison between the two groups regarding duration of ventilator support, PICU stay and hospital stay data was performed by means of Student's t test.

Repeated measures analysis of variance was employed to evaluate the two groups during pre- and perioperative periods regarding hematocrit and platelet counts.

The hospital discharge probability was estimated using the Kaplan-Meier method. The log-rank test was employed to compare the two groups.

9.11 Results

9.11.1 Operative outcome

There were no MUF related complications. In all the patients it was possible to close the chest. No patient required reexploration for bleeding.

There were four postoperative deaths in the CUF + MUF group. All patients had PH and the main causes were cardiac arrhythmia, low cardiac output, ventilation problems, vasoactive agent handling and pulmonary infection.

There were six postoperative deaths in the CUF group. Five patients had PH and the main cause were coagulopathy, low cardiac output, ventilation problems, vasoactive agent handling and pulmonary infection.

9.11.2 Duration of ventilator support

Mean and standard deviation of duration of ventilator support in surviving patients of the CUF group were 94.8± 66.20 h for the CUF group and 95.67 ± 90.29 h, and for the CUF+MUF group. No significant difference was observed between the two groups (p= 0.976) Table 9.

9.11.3 PICU stay

Mean and standard deviation of the time of PICU stay in surviving patients of the CUF group were 169.60 ± 90.61 h and 157.81 ± 150.80 h for the CUF+MUF group. No significant difference was observed between PH groups (p= 0.795) Table II.

9.11.4 Hospital stay

The time of hospital stay in surviving patients of the CUF group were 14.87 ± 5.57 days and in surviving patients of the CUF+MUF group it was 14.69 ± 9.67 days. No significant difference was observed between PH groups (p= 0.950) (Table II). The estimated probability discharge from hospital after the 15th postoperative (PO) day was approximately 85% for both groups (Fig. 39)

Variables (Group)	N°	Minimu m	Maximu m	Mean	Standard deviation	P*
Ventilation support (hours)						
- CUF	15	24.00	192.00	94.80	66.20	0.976
- CUF+MUF	16	12.00	288.00	95.67	90.90	
PICU stay** (hours):						
- CUF	15	66.00	312.00	169.60	90.61	0.795
- CUF+MUF	16	24.00	576.00	157.81	150.80	
Hospital stay** (days)						
- CUF	15	5.00	28.00	14.87	5.57	0.950
- CUF+MUF	16	4.00	43.00	14.69	9.67	

*Student’s “t” test.
** Only alive patients were included In this Analysis

Table 9. Comparative results regarding studies variables of the CUF and CUF+MUF groups.

9.11.5 Blood transfusion

The CUF group presented significantly higher values of hematocrit than the CUF+MUF groups at the different times during the perioperative periods (p= 0.032). A significant decrease was observed after the surgery (p= 0.037), mainly in the CUF+MUF group.

The analysis of platelet counts at the different times during the perioperative period. There were no significant differences between groups ($p= 0.673$). A significant decrease was observed in platelet counts after the surgery ($p< 0.001$).

Requirements for red blood cell and coagulation factors (platelet, fresh frozen plasma and cryoprecipitate) were similar in both groups.

Only 15.8% of the CUF group (3 of 21) did not require red blood cell transfusion, whereas 16.7% patients (3 of 20) in the CUF+MUF group were free of red blood cell transfusion.

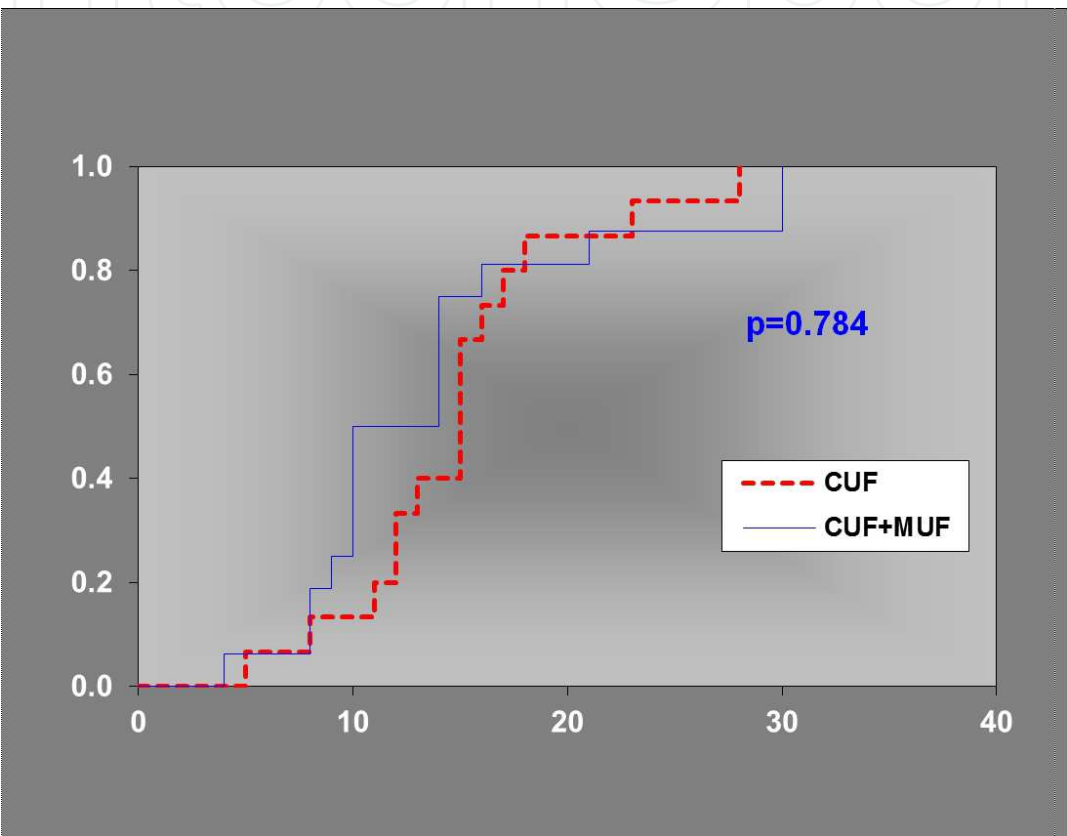


Fig. 39. Effective Hospital Stay or calculated probability

9.12 Discussion

Surgical correction of complex congenital heart disease in children requires long times of CPB and moderate or deep hypothermia inducing water retention, hypervolemia and distribution of liquid in the extravascular compartment. On the other hand, the generalized inflammatory reaction due to protein mediator release contributes to increase in capillary permeability and tissular edema, impairing organs such as the heart, lung and brain.

Accumulation of body water occurs due to intravenous administration of solutions and the contact of the prime with the patient's blood. On the other hand, CPB induces a generalized inflammatory reaction with unbalance of the patient's internal environment, increasing body water retention. These effects have a greater impact in low weight children who require correction of complex heart defects.

Based on studies of ultrafiltration in adult's, in 1990 we started to use CUF in children during the warming stage of CPB with satisfactory results. The purpose of CUF was: removal of excess water from the priming of the CPB and hemoconcentration of erythrocytes and coagulation factors increasing hematocrit, decreasing bleeding in the postoperative period, thus reducing the need for transfusions of the patient.

Introduction of MUF, after CPB, has avoided excessive accumulation of body water and improving the patient's clinical conditions, allowed decrease in bleeding and reduction of blood replacement and ultrafiltration of protein mediators responsible for the inflammatory response, aiming at PH control, reduction in time of use of vasoactive drugs, of pulmonary ventilation and of hospitalization.

In this study, 20 patients below the age of 36 months, who on surgical correction were submitted to the association of ultrafiltration methods (CUF + MUF) with follow-up until discharge from hospital, were compared to a similarly operated group previously and submitted to CUF. Therefore this is a comparative, prospective and consecutive, nonrandomized study like others in the literature.

Randomization of patients undoubtedly represents an ideal situation because it allows an accurate evaluation of the results, as shown by other studies on this subject. However, other comparative studies present restrictions to the evaluation of the benefits of MUF use.

Studies, equal to the present, one comparing CUF + MUF with CUF in two similar groups of pediatric patients, have been carried out by other authors.

The design of our research offered equal ultrafiltration opportunity to both groups, whose age, weight surgical complexity profile characterized them as being at high risk. All patients received CUF, thus allowing ultrafiltration of inflammatory reaction mediators primarily released during the warming stage of CPB.

Initially the MUF technique we used was similar to that presented by Elliott. However, due to the need to keep the ultrafiltered blood returning to the right atrium warm, as in Groom's study, we introduced changes in the outlet of the hemoconcentrator, substituting it for the cardioplegia line and thus allowing passage of ultrafiltered blood through the heat exchange.

Use of MUF after CPB, allows improvement in the systolic function of the left ventricle (LV) in children submitted to correction of congenital defects. There is an increase in the final diastolic diameter and fall in final diastolic pressure of the LV after MUF due to improvement in ventricular compliance, as a result of the reduction of myocardial edema. The hemodynamic improvement could be related to this reduction and the neutralization of the inflammatory response because of ultrafiltration of protein mediators.

Interest in the use of the MUF technique, benefits to the patients and possible intercurrents are increasing and justifying further studies by multiple centers. Despite the acquired experience, technical complications, which should not be discarded, have been detected.

The need for the evaluation of results in children at high surgical risk has led us to define our research in children aged 0 to 36 months, as has been done by other studies.

Patients submitted to prolonged CPB, hemodilution and hypothermia might develop a substantial myocardial edema, making chest closing difficult if they are not adequately ultrafiltered. In our study all patients were led to the PICU with a closed chest.

Association of CUF + MUF was efficient, significantly increasing the total volume of ultrafiltration ($227 + 71.4$ ml) when compared with CUF alone ($143.3 + 54.3$ ml) ($p < 0.001$).

In spite of the significant hemodynamic improvement through the use of CUF + MUF in our study, as well as in others, no significant differences were found regarding number and time of use of inotropic drugs when compared with the control group.

Reduction in pulmonary ventilation time and time of stay in the PICU is evident with use of MUF, although in our study no significant difference has been found.

There was a proportional fall in the Ht of both groups during the postoperative period and, according to the established criteria to maintain the Ht at 35% in acyanotic children and at 40% in cyanotic children, 84.2% of the patients of the CUF group and 83.3% of the patients of the CUF + MUF group, received blood, but there was no statistically significant difference between the groups.

Classification of the patients according to the degree of surgical complexity allowed the analysis of impact of hospital mortality in relation to the different variables. Despite the fact that there was no statistically significant difference regarding degree of complexity of the CUF and CUF + MUF groups, there were 50% of the CUF + MUF patients in category 3 and 4 (more severe) while in the CUF group, 76.2% of the cases belonged to category 2 (less severe).

Regarding duration of hospital stay, there was no significant difference between the groups, analyzed at 5 different times, 90% of the patients of both groups being discharged from hospital on the 20th day of postoperative period. Duration of hospital stay of patients submitted to surgical correction of complex congenital heart disease is usually prolonged, significantly increasing hospital costs. A detailed analysis of treatment time in this group of patients submitted to ultrafiltration will allow the assessment of reduction in hospital costs.

Association of congenital cardiopathies with severe PH (ratio pulmonary pressure/systemic pressure $> 60\%$) represents a group at higher surgical risk requiring effective treatment for PH control. The PH associated with high pulmonary vascular resistance is responsible for the long periods of mechanical ventilation, stay in PICU and high morbidity and mortality, after correction of cardiac defects using CPB.

Endothelin-1 produced by the cells of the vascular endothelium is a vasoactive agent, which participates, in the pathophysiological mechanism of PH. Studies have shown that the use of total hemodilution during CPB, associated with MUF, in children submitted to correction of cardiac malformations and PH, allow the elimination of excess body water and ultrafiltration of endothelin-1.

In our study, in the CUF + MUF group, consisting of 20 patients, 14 (70%) presented PH and in the CUF group, consisting of 21 patients, 15 (71.4%) had PH.

Despite the tendency to improvement of the results in the CUF + MUF group, there were 4/20 deaths (20%) as compared to the CUF group with 6/21 (28.5%) deaths.

9.13 Conclusion

We obtained those of Groom's group, a circuit design using cardioplegia line, have shown to be safe and equally efficient, with a significant filtered volume in the CUF + MUF group. Probably the efficacy of the CUF used in all patients and the lack of adjustment of the preoperative care protocol did not allow establishing more consistent results in the studied groups. These results should be examined with caution because they refer to a nonrandomized group with a small number of patients with high-risk congenital heart disease.

Currently we routinely use CUF + MUF in all pediatric patients undergoing heart surgery in our Institution. With ultrafiltration methods, in the future, pediatric patients should equally benefit from controlling their water balance, neutralizing the inflammatory response and reducing transfusion volumes.

10. Philanthropic activities

10.1 Pediatric cardiac surgery as a philanthropic activity in the country and foreign humanitarian mission

In Brazil each year are born 30,000 new patients with congenital heart disease, 50% of which need surgical correction in the first year of life. The statistics show data that are published yearly by Associação Nacional de Saúde (ANS) of Brazil, that only 6,000 - 7,000 patients undergo cardiac corrective or palliative surgery each year. These figures do not include the patients holding health insurance operated in hospitals associated to the medical insurance network; although it is a small contingent.

This reality shows that due to the fast technological development process in Medicine, the particularity of each patient was completely disregarded and his illness became an object of scientific study. The medical procedures, therefore, became inhuman.

In the same process, some changes have occurred in medicine graduation and in the work conditions, increasingly specialized, restricting the availability of physicians either for contact with the patient or for the search of a more specialized formation.

The actual conditions of medicine practice have not contributed to the betterment in the relationship between physicians and patients, and for a humanized assistance with good quality (this applies for both professionals in the area and health care institutions).

Nowadays, several actions have been proposed aiming the implementation of humanizing programs in health institutions, especially in pediatric assistance in hospitals; several projects and actions develop activities associated with plastic arts, music, theater, leisure and entertainment.

There are some Institutions that claim to be already humanized, but in some cases, this humanization applies only to architectural improvements and medical assistance aiming fiscal benefits. Undoubtedly, these are relevant measures in an Institution; however, they can be merely superficial factors unless they are inserted in a vast process of Humanizing Institutional Relationships.

When pondering about the Assistance Duties it can also lead us to Ethics. The ethic matters appear when one worries about the consequences of his actions upon others.

The work of a professional, whatever his activity might be, depends on both technical quality and interaction quality. In medicine, quality is a must that makes each specialty aim to develop its technical capacity that is part of what it is called relative abilities and knowledge of the technical area. In order to internationally capacitate the physician, of any specialty, it becomes necessary the instrumentalization to recognize and deal with the emotional aspects of assistance, that is, developing attitude.

Humanization is a vast, slow and complex process to which many definitely offer some resistance, because it involves changes of behavior that often promote insecurity. The already established standards seem rather safer, in addition, the new ones are not currently legal and do not have general characteristics, because each professional, each institution has its own particular humanization process. In this process many instances must be involved: Professionals of all areas, Institution Directory Board, politicians and public attorneys, a Professional Counsel and Philanthropic Entities.

There are a few public and private hospitals, in the country, that offer conditions for a complete assistance to children, in order to perform high complexity procedures.

Therefore, the pediatric assistance fails to meet the special needs of patients due to the long lines in ERs, shortage of vacancies in nurseries, ICU, etc; on the other hand, children that need to be transferred to more complex hospitals end up missing the opportunity due to the unavailability of rooms, which in its turn leads to a natural selection of patients.

These examples allow us to see the complexity in health management in the pediatric department.

In 1994, our pediatric cardiac surgery group, working at the Hospital Israelita Albert Einstein (HIAE), was invited by the Assistance Pediatric Directory to perform, in a philanthropic way, surgical corrections in children presenting cardiac defects, being followed up at the institution.

A similar experience with fewer patients was performed through the project Multi Assistance Association (AMA) at the Hospital Samaritano (HS).

Due to the success of this experience and sympathetic to the technical difficulties of colleagues in the same specialty belonging to the "Instituto para la Salud del Niño (ISN)" of Lima, Peru and also the social and economical difficulties of the country (Peru), we decided to accept this new challenge by initiating Humanitarian Missions to the ISN where professionals from the institution would perform operations for the surgical correction of complex cardiac defects. In this mission some theoretical and practical courses have been scheduled aiming a multidisciplinary training.

The recent meeting of pediatric cardiac surgeons in the World Summit on Pediatric and Congenital Heart Surgery held in Montreal (Canada) in June 2008, made possible some Cardiac Surgery Groups and Multidisciplinary Groups of wealthy countries to plan and perform humanitarian missions in third world countries.

More and more often a Health Institution is becoming an integrated system, consisting of a number of organizations, in search of a more harmonious joint action: Community / Physician / Hospital; more adequate to the current reality and without frontiers.

In the period between July 1994 and December 2008, 204 patients presenting congenital heart diseases were submitted to corrective or palliative surgery of cardiac defects.

Among these, 153 (75.0%) patients were operated in the philanthropic category, at the HIAE 20 p. (9,9%) at the HS, and the remaining 51 (25.0%) under humanitarian mission at the ISN (Table 10)

Data	Participating Institutions	Country	N °patients	(%)
1994 - 1999	HIAE	Brasil	133	(65.1)
2000 - 2003	H S	Brasil	20	(09.9)
2004 - 2008	ISN	Peru	51	(25.0)
Total			204	(100)

Table 10. Participating Institutions and patients enrolled in the Philanthropic and Humanitarian Project.

The characteristics of the patients were the following: Age: 1 day-old - 18 years-old (M=2.5); Gender: Female 52.6% of the cases; Operation: first operation in 163 (80%) cases and reoperation in 41(20%) cases.

All the patients were evaluated by the pediatric cardiologist that requested the complementary examinations and performed all the pre-operative procedures, post-operative follow-up and intensive care of the patients.

In the 3 institutions that participated in the study, the intensive care structure was held in Pediatric ICU and the intensive physicians were pediatricians. All the patients with surgical recommendation were presented in the specialty meeting.

The patients were rated according severity of their cardiac defects and surgical risk, according to international rules: Risk Adjustment Congenital Heart Surgery (RACHS) (Table 11)

Risk I (Mortality accepted: 0 - 3%)
ASD: Atrial Septal Defect; PDA: Patent Ductus Arteriosus (> 30d); CO-Ao: Coarctation of Aorta (> 30d); PAPVC: Partial Anomalous Pulmonary Venous Connection.
Risk II (Mortality accepted: 3 - 9%)
VSD: Ventricular Septal Defect; Sub Ao S: Sub aortic Stenosis; Tetralogy of Fallot; BDG: Bidirectional Glenn; AVC: Atrio-Ventricular Channel; Aortic Valvar Stenosis.
Risk III (Mortality accepted: 9 - 20%)
Ross Op.; Mitral Valve Op.; Co-Ao + VSD; Anomalous Coronary Artery Origin; Fontan Op.; PCA (<30d).
Risk IV (Mortality accepted: 20 - 25%)
Kono Op; Rastelli Op; Jatene Op; Unifocalization Pulmonary Artery Op.; TAPVD: Total Anomalous Pulmonary Veins Drain.
Risk V (Mortality accepted: 25 - 35%)
Ebstein Anomaly (<30d); Truncus Arteriosus;Aortic Arch Interruption.

Table 11. Risk Adjustment Congenital Heart Surgery (RACHS)

10.2 Statistical analysis

The relationships between hospital mortality and these risk factors were examined with Q2 (Siegel-2006). A p value of less than 0.05 or 5% was considered to be significant.

In the total analysis of result, there were 28 (13.7%) deaths in the immediate post-operative period. (Fig. 40) When we analyzed the results of each institution separately, it was observed: HIAE: 20 (15.0%) deaths; HS: 1 (5.0%) deaths and ISN: 7 (13.7%) deaths.(Table 12). (Fig. 41,42,43,44)

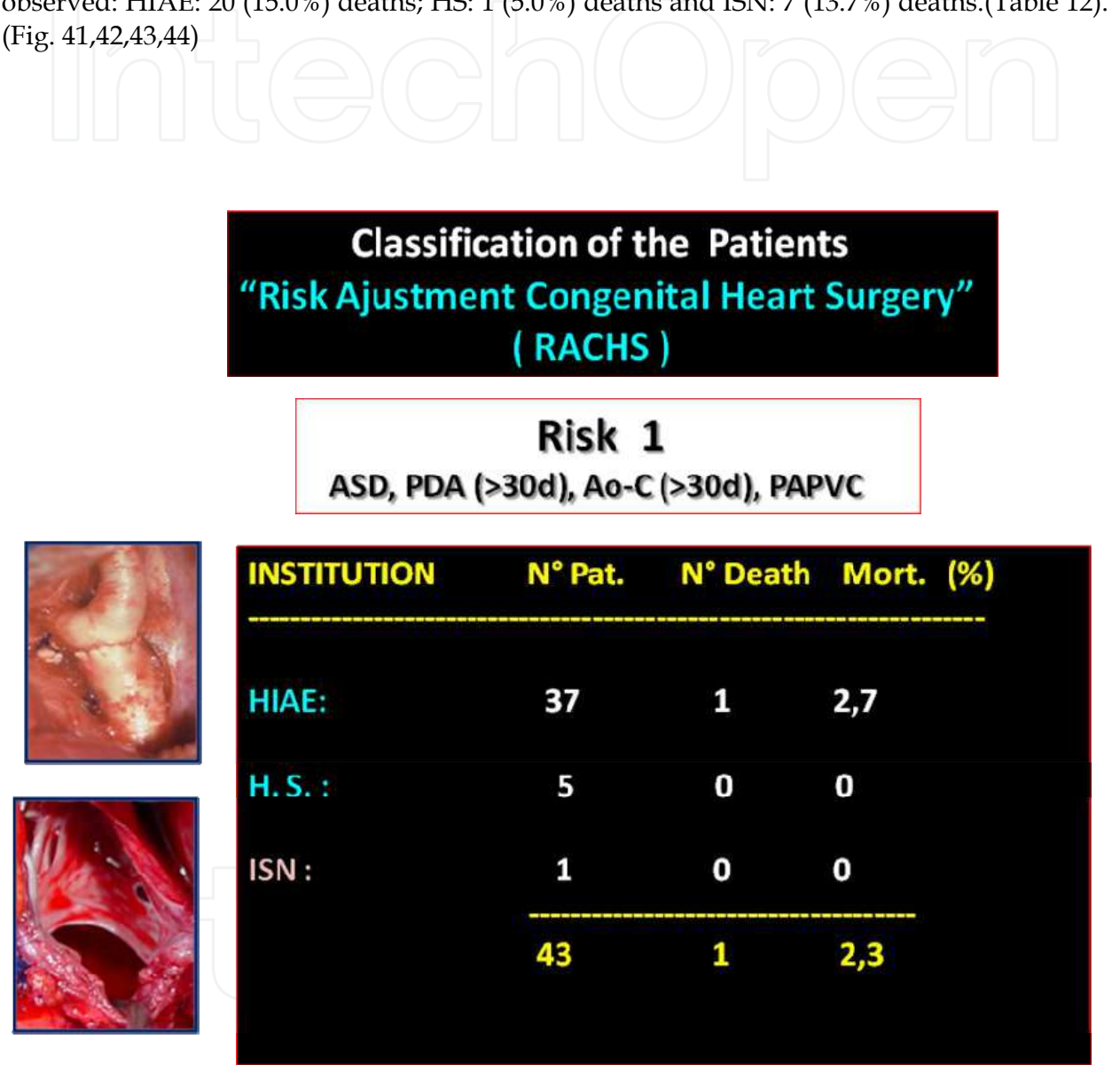


Fig. 40. Surgical results in patients operated in Risk Group 1, at 3 referred Institutions . PAPVC: Partial Anomalous Pulmonary Vein Connection; PDA: *Patent Ductus Arteriosus*; Ao C: Aortic Coarctation; ASD: Atrial Septal Defect.

There aren't statistic significance in this group.(p=0.147)

Institution	Patients	(%)	Deaths	Mortality (%)	p
HIAE	133	(65.2)	20	(15.0)	ns
HS	20	(09.8)	01	(5.0)	ns
ISN	51	(25.0)	07	(13.7)	ns
Total	204	(100)	28	(13.7)	0.147

Table 12. Immediate post-operative results.

When we analyzed the results according to the severity of cardiac malformation and the complexity of the surgical correction, we observed that the Risk Group I, consisting of 43 patients, there was only 1 death (Mortality 2.3%) at the Institution HIAE. (Table 13). There aren't statistic significance in this group.(p=0.748).

Institution	Patients	Deaths	Mortality	p
	N° (%)	N°	(%)	
HIAE	37 (27.8)	1	(2.7)	ns
HS	05 (25.0)	0	(0.0)	ns
ISN	01 (01.9)	0	(0.0)	ns
Total	43 (21.0)	1	(2.3)	0.748

Table 13. Immediate Post-operative Results – Risk I

The Risk Group II consisted of 68 patients and there were 5 deaths (Mortality 7.3%). All this 5 deaths occurred in the HIAE Institution (Table 14) (Fig 41). There was no statistical significance in this group. (p=0.202)

Institution	Patients	Deaths	Mortality	p
	N° (%)	N°	(%)	
HIAE	44 (33.0)	5	(11.3)	ns
HS	10 (50.0)	0	(0.0)	ns
ISN	14 (27.5)	0	(0.0)	ns
Total	68 (33.3)	5	(7.3)	0.202

Table 14. Immediate Post-operative Results – Risk II

The Risk Group III was the most numerous, consisting of 74 patients, there were15 deaths (Mortality20.2%). The deaths occurred at the HIAE: 12 cases; HS: 1 case and at the ISN: 2 cases (Table 16) Figure 42. There was no statistical significance in this group. (p= 0.06)

nstitution	Patients	Deaths	Mortality	p
	N° (%)	N°	(%)	
HIAE	43 (32.3)	12	(27.9)	ns
HS	05 (25.0)	01	(20.0)	ns
ISN	26 (19.5)	02	(7.6)	ns
Total	74 (36.2)	15	(20.2)	0.060

Table 15. Immediate Post-operative Results – Risk III

The Risk Group IV consisted of 13 patients; there were 3 deaths (Mortality 23.0%). The deaths occurred at the HIAE: 1 case and at the ISN: 2 cases (Table 16) Figure 43. There was no statistical significance in this group. ($p = 0.600$).

Institution	Patients	Deaths	Mortality	p
	N° (%)	N°	(%)	
HIAE	7 (3.4)	1	(14.2)	ns
HS	0 (0.0)	0	(0.0)	ns
ISN	6 (2.9)	2	(33.3)	ns
Total	13 (6.3)	3	(23.0)	0.600

Table 16. Immediate Post-operative Results – Risk IV

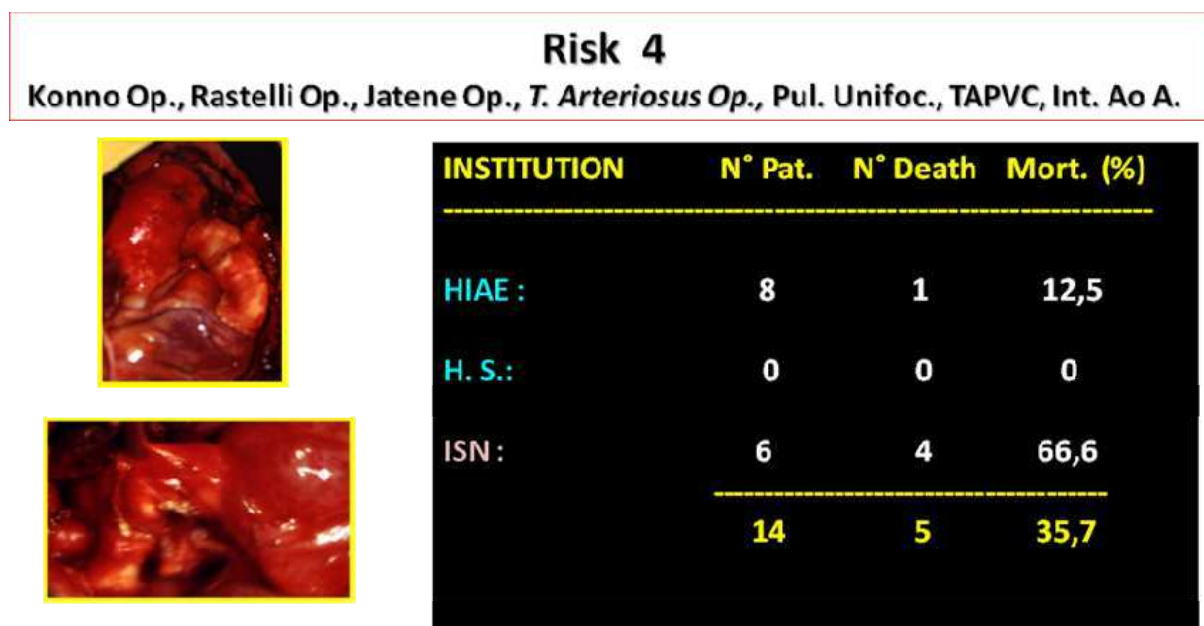


Fig. 43. Surgical outcome of patients operated in Risk Group 4, the three participating institutions. Op: operation; T: truncus; Pul. Unifocal.: pulmonary unifocalization; TAPVC: total anomalous pulmonary venous connection ; Int. A. Ao: Interrupted aortic arch

The Risk Group V consisted of 6 patients, there were 3 deaths (Mortality 50.0%). These deaths occurred: HIAE: 1 case and at the ISN: 2 cases (Table 17) (Fig.44). There was no statistical significance in this group. ($p=0,187$).

Institution	Patients	Deaths	Mortality	p
	N° (%)	N°	(%)	
HIAE	2 (0.9)	1	(50.0)	ns
HS	0 (0.0)	0	(0.0)	---
ISN	4 (1.9)	2	(50.0)	ns
Total	6 (2.9)	3	(50.0)	0.187

Table 17. Immediate Post-operative Results – Risk V

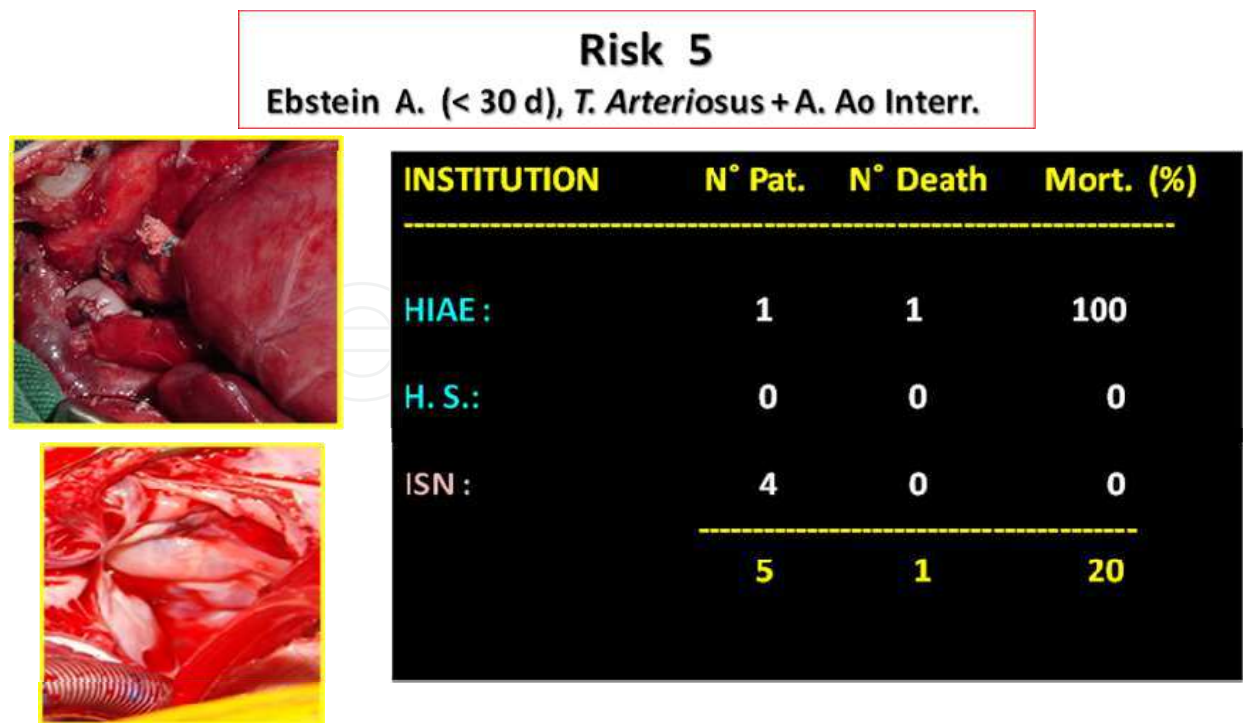


Fig. 44. Surgical outcome of patients operated in Risk Group 5, the three participating institutions: A: Anomaly, T.: truncus; Ao A Inter: : aortic arch interruption

10.3 Discussion

Even though the incidence of congenital heart disease not being significantly high, the restrict number of specialized centers, as well as the number of professionals and the high costs of procedures, make the surgical referrals increase proportionally with the population growth, though the amount of surgeries does not increase in the same proportion and many patients miss the opportunity to have surgical correction or simply end up dying.

Although the number of pediatric cardiac surgeries performed in public Institutions is noticeably increasing, unfortunately it is still not sufficient in order to put an end to the prolonged lines awaiting an opportunity for treatment.

In our field, many private hospitals well structured, sympathizing with this situation and motivated by the exemption of income tax, perform an important Welfare Work in the pediatric area. Undoubtedly, multiplying these services throughout the country is necessary, and by doing so, it would definitely have an immediate impact on the quality of assistance, the training of professionals and the surgical results.

Our group initiated its Philanthropic Activities in 1994 at the HIAE, supported by the Directory in effect, aiming the implementation of a Pediatric Cardiac Surgery Program, followed by the philanthropic assistance of children with cardiac malformation referred by the Pediatric Assistance Service originating from the poorest areas of the city and state of São Paulo. The immediate results of this philanthropic program for the treatment of more complex cardiac malformations allowed the access of patients from other states in the country.

Alongside with the theoretical and practical training of professionals in the area enabled the establishment of work regulations and protocols of conduct in the specialty.

Pediatric Cardiac Surgery Services are frequently in deficit or poorly developed in many countries around the world and currently there are several active foundations with services of cardiovascular support, specialized in the pediatric area, in business for 15 years, aiming to give humanitarian assistance, in the 4 continents, to a very restricted number of excluded patients.

The experience acquired with philanthropic assistance activities enabled the attainment of some experience which constituted an essential tool in order to embrace programs of humanitarian assistance. Between June, 2004 and December, 2007; 7 missions to Lima-Peru were realized, supported by the Ministério de La Salud of that country and we operated an average of 8 patients per mission.

Despite the well structured institutions assisting patients of the specialty, the technical resources for diagnosis and therapy, as well as the human resources ones were somewhat different for the philanthropic patients operated in the country, taking advantage of a more advanced technology, when compared to the one present in the humanitarian missions. As expected, the majority of the operated patients belong to the philanthropic group (75%) (HIAE= 65.1% and HS= 9.9 %), when compared to the humanitarian mission group (25%) (ISN= 25.0%).

When the operated patients were classified considering the surgical risk, according RACHS, we observed that the majority is in the Risk Group II and III (69.6%) and that none of the patients in Risk Group VII was operated.

10.4 Conclusions

Patients operated belonged to the 5 categories of Rachs risk, being that the Risk Group III was the most numerous (36.2%) - The results obtained at the HIAE and at the ISN, are justified by the number of patients, complexity of cardiac defects operated and structural difficulties in the implementation stage of the Pediatric Cardiac Surgery Service. The mortality in the Risk Group V, was higher than estimated by the Rachs study. On the other hand, in this study, neither did we consider the social-economical conditions of the patient nor the clinical ones, such as: malnutrition, pulmonary infection, type of clinical treatment that largely interfere in the final results in our experience.

11. References

- Ad N, Snir E, Katk J, Birk E, Vidne BA. Use of the modified technique of ultrafiltration in pediatric open-heart Surgery: a prospective study *Isr J Med Sci* 1996;32;1326-31.
- Agnetti A, Carano N, Cavalli C, Tchana B, Bini M, Squarcia U, Frigiola A. Long-term outcome after Senning operation for transposition of the great arteries. *Clin Cardiol.* 2004; 27: 611-614.
- Albert JD, Bishop DA, Fullerton DA, Campbell DN, Clarck DR. Conduit reconstruction of the right ventricle outflow tract. Lessons learned in a twenty-year experience. *J Thorac Cardiovasc Surg* 1993;106:228-35.

- Andreasson S, Gothberg S, Berggren H, Bengtsson A, Erikson E, Risberg B. Hemofiltration modifies complement activation after extracorporeal circulation in infants. *Ann Thorac Surg* 1993;56:1515-7.
- Ballard G, Tibby S, Miller O, Krasemann T, Rosenthal E, Anderson D, Austin C, Qureshi S, Simpson J. Growth of left heart structures following the hybrid procedure for borderline hypoplastic left heart. *Eur J Echocardiogr*, 2010; 11(10): 870 - 874.
- Bando K, Danielson GK, Schaff HV, Mair DD, Julsreed PR, Puga FJ. Outcome pulmonary and aortic homograft for right ventricular outflow tract reconstruction. *J Thorac Cardiovasc Surg* 1995;109:509-17.
- Bando K, Turrentine MW, Vijay P, Sharp TG, Sekine Y, Lalone BJ, et al. Effect of modified ultrafiltration in high risk patients undergoing operation for congenital heart disease. *Ann Thorac Surg* 1998;66(3): 821-8.
- Barbero-Marcial ML, Riso A, Verginelli G et al. Técnica para correção do truncus arteriosus I, II sem conduto extracardíaco.
- Bender HW Jr, Stewart JR, Merrill WH, Hammon JW Jr, Graham TP Jr. Ten years' experience with the Senning operation for transposition of the great arteries: physiological results and late follow-up. *Ann Thorac Surg*. 1989; 47: 218-223.
- Birnie D, Tometzki A, Curzio J, Houston A, Hood S, Swan L, Doig W, Wilson N, Jamieson M, Pollock J, Hillis WS. Outcomes of transposition of the great arteries in the era of atrial inflow correction. *Heart*. 1998; 80: 170-173.
- Blalock A, Taussig H- Surgical treatment of malformations of the heart in which there is stenosis or pulmonary atresia. *JAMA*, 1945; 128: 189-202
- Bockeria L, Alekian B, Berishvili D, Pursanov M, Krupianko SM, Zarginava G, Grigoryanz A. A modified hybrid stage I procedure for treatment of hypoplastic left heart syndrome: an original surgical approach. *Interactive CardioVascular and Thoracic Surgery*, 2010; 11(2): 142 - 145.
- Boudjemline Y, Bonnet D, Agnoletti G, Vouhe P. Aneurysm of the right ventricular outflow following bovine valved venous conduit insertion. *Eur J Cardiovasc Surg* 2003;23:122-124.
- Bove T, Demanet H, Wauthy P, et al. Early results of valved bovine jugular vein conduit versus bicuspid homograft for right ventricular outflow tract reconstruction. *Ann Thorac Surg* 2002; 74:536-541.
- Bricker JT. Sudden death and tetralogy of Fallot: risks, markers and causes. *Circulation* 1995;92:158-159 .
- Brown JW, Ruzmetov M, Rodefeld MD, Vijay P, Darragh RK. Valved bovine jugular vein conduit for right ventricular outflow tract reconstruction in children: An attractive alternative to pulmonary homograft. *Ann Thorac Surg* 2006;82:909-916.
- Bull C, McCartney FJ, and Horvath P et al. Evolution of long-term results of homograft and heterograft valves in extracardiac conduits . *J Thorac Cardiovasc Surg* 1987;94:12-9
- Caliani J; Machado A; Marinho J; Simões L; Barbosa O. Correção da origem anômala de artéria coronária esquerda com insuficiência mitral e hemólise mecânica. *Rev Bras Cir Cardiovasc* 2004; 19 (4): 405-408.
- Canêo L, Lourenço D, Silva R, Franchi S, Afiune J, Afiune C, Mocelin A, Barbero-Marcial M, Jatene F. Senning operation with autologous tissue for atrial septum augmentation or pulmonary venous pathway enlargement. *Bras J Cardiovasc Surg* 1999; 14 (4):298-302.

- Carvalho JS, Shinebourne EA, Busst C, Rigby ML, Redington AN. Exercise capacity after complete repair of tetralogy of Fallot: deleterious effects of residual pulmonary regurgitation. *Br Heart J* 1992;67:470-473
- Carvalho MV, Maluf MA, Catani R, La Rotta CA, Gomes WJ, Salomon R, Silva C, Carvalho AC, Branco JN, Buffolo E. Cytokines and pediatric open heart surgery with cardiopulmonary bypass. *Cardiol Young* 2001; 11: 36-43
- Chen Q, Parry. The current role of hybrid procedures in the stage 1 palliation of patients with hypoplastic left heart syndrome. *Eur. J. Cardiothorac. Surg.*, 2009; 36(1): 77 - 83.
- Cochrane AD, Karl TR, Mee RB. Staged conversion to arterial switch for late failure of the systemic right ventricle. *Ann Thorac Surg.* 1993; 56: 854-861.
- Croti U; Braile D; Resende C; Beani L. Origem anômala de artéria coronária da artéria pulmonar: operação de Takeuchi. *Rev Bras Cir Cardiovasc* 2006; 21 (4): 305-306.
- Davies MJ, Nguyen K, Gaynor JW, Elliott MJ. Modified ultrafiltration improves left ventricular systolic function in infants after cardiopulmonary bypass. *J Thorac Cardiovasc Surg* 1988; 115: 361-70
- Davlouros PA, Kilner PJ, Hornung TS, Li W, Francis JM, Moon JCC, Smith GC, Tat T, Pennell DJ, Gatzoulis MA. Right ventricular function in adults with repaired tetralogy of Fallot assessed with cardiovascular magnetic resonance imaging: detrimental role of right ventricular outflow aneurisms or akinesia and adverse right-to-left ventricular interaction. *J Am Coll Cardiol* 2002;40(11):2044-52.
- De Leval MR, Mc Kay R, Jones M, Stark J, Macartney FJ - Modified Blalock-Taussig shunt *J thorac Cardiovasc Surg*, 1981;81:112-9
- De Leval MR.. Evolution of the Fontan-Kreutzer procedure. *Semin Thorac Cardiovasc Surg Pediatr* 2010;13(1):91-
- De Leval, MR, Kilner P, Gewillig M, Bull C, Total cavopulmonary connection: a logical alternative to atriopulmonary connection for complex Fontan operation: Experimental studies and early clinical. *J Thorac Cardiovasc Surg.* 1988; 96(5):682-95.
- Eguchi S & Asano K. Homograft of pulmonary artery or ascending aorta with valve as a right ventricular outflow. *J Thorac Cardiovasc Surg* 1968;56:413-20
- Eguchi S, Irisawa T, Asano K. Use of valve-retaining homograft and heterograft patch for reconstruction of right ventricular outflow tract. *Ann Thorac Surg* 1972;14:615-25
- Elliott MJ. Ultrafiltration and modified ultrafiltration in pediatric open heart operations, *Ann Thorac Surgery* 1993; 56: 1518-22.
- Finn A, Naik S, Klein N, Levinsky RJ, Strobel S, Elliott MJ. Interleukin release and neutrophil degranulation after pediatric cardiopulmonary bypass *Thorac Cardiovasc Surg* 1993; 105:234-41.
- Fontan F, Baudet E. Surgical repair of tricuspid atresia. *Thorax* 1971;26:240-8.
- Friesen RH, Campbell DN, Clarke DR, Tornabene MA. Modified ultrafiltration attempted dilutional coagulopathy in pediatric open heart operations. *Ann Thoracic Surg* 1997;64:1787-9.
- Gelatt M, Hamilton RM, McCrindle BW, Connelly M, Davis A, Harris L, Gow RM, Williams WG, Trusler GA, Freedom RM. Arrhythmia and mortality after the Mustard procedure: a 30-year single-center experience. *J Am Coll Cardiol.* 1997; 29: 194-201.

- Gewilling M, Wyse RK, de Leval MR, Deanfield JE. Early and late arrhythmias after the Fontan operation: predisposing factors and clinical consequences. *Br Heart J* 1992; 67(1):72-9
- Graham TP, Cordell D, Atward GF, Boucek RJ, Boerth RC, Bender HW, Nelson JA, Vaughn WR. Right ventricle volume characteristics before and after palliative and reparative operation in tetralogy of Fallot. *Circulation* 1976;54:417-423
- Groom RC, Akl B, Albus RA, Hill A, Munoz R, Lefrak EA. Alternative method of ultrafiltration after cardiopulmonary bypass. *Ann Thorac Surg*; 58:573-576.
- Gurbuz AT, Novick WM, Pierce CA, Watson DC. Impact of ultrafiltration or blood use for atrial septal defect closure in infants and children. *Ann Thorac Surg* 1998; 65: 1105-9.
- Harrison DA, Harris L, Isu SC, Mc Laughlin CJ, Connelly MS, Wehog D, Downar E, Mc Laughlin PR, Williams WG. Sustained ventricular tachycardia in adult patients late after repair of tetralogy of Fallot. *Am J Coll Cardiol* 1997;30:1368-1373
- Hazekamp MG, Kurvers MM, Schoof PH, et al. Pulmonary Valve insertion late after repair of Fallot's tetralogy. *Eur J Cardiothorac Surg* 2001;19:667-70
- Helbing WA, Hansen B, Ottenkamp J, Rohmer J, Chin JG, Brom AG, Quaegebeur JM. Long-term results of atrial correction for transposition of the great arteries: comparison of Mustard and Senning operations. *J Thorac Cardiovasc Surg.* 1994; 108: 363-372.
- Howkins JA, Bailey WW, Dillon T, Schwartz DC. Midterm results with cryopreserved allograft valved conduits from the right ventricle to the pulmonary arteries. *J Thorac Cardiovasc Surg* 1992;104:910-6.
- Ilbawi MW, Idriss FS, Deleon SY, Muster AJ, Gidding SS, Berry TE, Paul MH: Factors that exaggerate the deleterious effects of pulmonary insufficiency on the deleterious effects of pulmonary insufficiency on the right ventricle after tetralogy repair. Surgical implications. *J Thorac Cardiovasc Surg* 1987;93:36-44.
- Jenkins KJ - Risk adjustment for congenital heart surgery: 1 method *Semin Thorac Cardiovasc Surg Pediatr Card Surg Annu* 2004;7:180-4
- Jenkins KJ. Newburger JW, Lock JE, Davis RB, Coffman A, Lezzoni LI. The hospital mortality of variation by care load. *Pediatrics*,1995,95:323-30.
- Jonas RA, Castaneda AR. Modified Fontan procedure: atrial baffle and systemic venous to pulmonary artery anastomotic techniques. *J Card Surg* 1988;3: 91-6.
- Journois D, Pouard P, Greeley WJ, Mauriat P, Vouhe P, Safran D. Hemofiltration during cardiopulmonary bypass in pediatric cardiac surgery. Effects on homeostasis, cytokines, and complement components *Anesthesiology* 1994; 81:1181-9.
- Katsumata T, Westaby S. Anomalous left coronary artery from the pulmonary artery: A simple method for aortic implantation with autogenous arterial tissue. *Ann Thorac Surg* 1999; 68:1090-1.
- Keenan HT, Thiagarajan R, Stephens KE, Williams G, Romamoorthy C, Lupinetti FM. Pulmonary function after modified venous-venous ultrafiltration in infants: a prospective randomized trial *J Thorac Cardiovasc Surg* 2000; 119: 501-7.
- Kirjavainen M, Happonen JM, Louhimo I. Late results of Senning operation. *J Thorac Cardiovasc Surg.* 1999; 117: 488-495.
- Kirklin JW, Barrat-Boyes BG. Anatomy, dimensions and terminology: *Cardiac Surgery*, 2nd ed. New York: Churchill Livingstone, 1993.

- Kitahori K, Murakami A, Takaoka T, Takamoto S, Ono M. Precise evaluation of bilateral pulmonary artery banding for initial palliation in high-risk hypoplastic left heart syndrome. *J. Thorac. Cardiovasc. Surg.*, 2010; 140(5): 1084 - 1091.
- Kiyota Y, Shiroyama T, Akamatsu T, Yokota Y, Ban T. In Vitro closing behavior of the St Jude Medical Herat valve in the pulmonary position. Valve incompetence originating in the prosthesis itself. *J Thorac Cardiovasc Surg* 1992; 104:779-85.
- Kocica MJ, Corno AF, Carreras-Costa F, Ballester-Rodes M, Moghbel MC, Cueva CNC, Lackovic V, Kanjuh V I, Torrent-Guasp F. The helical ventricular myocardial band: global, three-dimensional, functional architecture of the ventricular myocardium. *Eur J Cardiothorac Surg* 2006; 295:S21-40.
- Koutlas TC, Gaynor JW, Nicolson SC, Steven JM, Wernovsky G, Spray TL. Modified ultrafiltration reduces postoperative morbidity after cavopulmonary connection. *Ann Thorac Surg* 1997; 64 ;37-43.
- Kreutzer GO, Schlichter AJ, Kreutzer C. The Fontan/Kreutzer procedure at 40: an operation for the correction of tricuspid atresia. *Semin Thorac Cardiovasc Surg Pediatr Card Surg Annu.* 2010;13(1):84-90.
- Lange R, Hörer J, Kostolny M, Cleuziou J, Vogt M, Busch R, Holper K, Meisner H, Hess J, Schreiber C. Presence of a Ventricular Septal Defect and the Mustard Operation Are Risk Factors for Late Mortality After the *Atrial Switch Operation*. *Circulation.* 2006;114:1905-1913.
- Lecompte Y. Réparation à l'étage ventriculaire – The REV procedure: technique and clinical results. *Cardiol Young* 1991 ;1:63-70.
- Levinsky L, Srinivasan V, Alvarez-Diaz F, Subramanian S - Reconstruction of the new atrial septum in the Senning operation. New technique. *J Thorac Cardiovasc Surg*, 1981;81(1):131-4.
- Lillehei, CW; Cohen, M; Warden, HE; Warco, RL: Complete anatomical correction of the tetralogy of Fallot defects. Report of successful surgical case. *Arch Surg* 1956;73:526-31.
- Lillehei, CW; Levy, M; Adams, P; Anderson, RL: Corrective surgery for tetralogy of Fallot. Long term follow-up by postoperative recatheterization in 69 cases and certain surgical considerations. *J Thorac Cardiovasc Surg* 1964; 48:556-76..
- Lima LC. Resultados tardios da correção da transposição das grandes artérias com comunicação interatrial com a técnica de Senning. Tese Mestrado, *UNIFESP*, 2001.
- Maluf MA, Mangia CM, Diogenes MS, Carvalho AC, Buffolo E. Anomalous coronary artery from pulmonary artery: Autogenous arterial tube for aortic implantation. *J Cardiovasc Surg* 2004;45:577-9.
- Maluf M, Andrade JC, Catani R, Carvalho A C, Andrade JL, Silva C, Carvalho WB, Negrini N, Buffolo E. Avaliação dos Resultados Tardios da Operação de Derivação Cavo-Pulmonar Bidirecional no Tratamento Paliativo de Cardiopatias Congênitas com Câmara Ventricular Única Funcionante. *Rev Bras Cir Cardiovasc* 1994;9:95-103.
- Maluf M, Mangia C, Bertuccez J, Silva C, Catani R, Carvalho W, Carvalho A, Buffolo E. Estudo comparativo de associação de ultrafiltração convencional e modificada na correção de cardiopatias congênitas de alto risco. *Rev Bras Cir Cardiovasc* 1999;14(3):221-36.

- Maluf M; Franzoni M; Melgar E; Hernandez A; Perez R -. The Pediatric Cardiac Surgery as a Phylantropic Activities in the Country and Foreign Humanitarian Mission. Rev Bras Cir Cardiovasc, 2009; 24(3): VII – IX.
- Maluf M; Andrade J C; Catani R; Carvalho AC; Lima W; Andrade JL; Leão LEV; Buffolo E. Derivação Sistêmico-Pulmonar em Cardiopatias Congênitas com Hipofluxo Pulmonar: Análise Crítica da Técnica Cirúrgica e resultados Imediatos. Arq. Bras. Cardiol. 1991;56(4): 281-286.
- Maluf MA, Braile DM, Silva C, Catani R, Carvalho AC, Buffolo E: Reconstruction of the pulmonary valve and right ventricular outflow tract with bicuspid prosthesis in tetralogy of Fallot. Ann Thorac Surg 2000;70:1911-1917
- Maluf MA, Carvalho AC, Carvalho WB -Use of right ventricular remodeling surgery with a porcine pulmonary prosthesis for congenital heart disease. Heart Surg Forum, 2011;14:E40.
- Maluf MA, Mangia C, Silva C, Carvalho WB, Carvalho AC, Buffolo E. Conventional and conventional plus modified ultrafiltration during cardiac surgery in high-risk congenital heart disease. J Cardiovasc Surg 2001; 42:465-73.
- Maluf MA. Comparative study between conventional and association of the conventional and modified ultrafiltration, during cardiac surgery in high-risk congenital heart disease. Tese Livre Docencia. São Paulo: UNIFESP, 1998;10:120.
- Maluf MA: Reconstruction of the pulmonary valve and right ventricular outflow tract with porcine pulmonary bicuspid and tricuspid prosthesis. Experimental study in sheeps. PhD tesis – São Paulo - UNIFESP 1991.
- Maluf MA; Cal RG- *Tratamento Paliativo das Cardiopatias Congênitas - Conduas em Cirurgia do Departamento de Cirurgia da UNIFESP-EPM - 2001: cap.27, pg. 479-490. Ed. Atheneu*
- Maluf MA; Carvalho AC; Carvalho WB.- Intracardiac Cavopulmonary Connection in patients with Univentricular Heart using Intra-atrial lateral Tunnel and Intra-atrial conduit technique. The Heart Surgery Forum 2010; 13(6): 362-369.
- Maluf MA; Carvalho AC; Carvalho WB.- One and a half ventricular repair as na alternative for hypoplastic right ventricle. Rev Bras Cir Cardiovasc 2010; 25(4): 466-473
- Maluf, MA *Tratamento Cirúrgico das Cardiopatias Congênitas - Guia de Medicina Ambulatorial e Hospitalar da UNIFESP – EPM - 2ª Ed.2009, pg. 491-503. Ed. Manole*
- Maluf, MA; Andrade, JC; Catani, R; Carvalho, AC; Lima, W; Andrade, JL; Leão, LV; Buffolo, E - *Derivação sistêmico – pulmonar em cardiopatias congênitas com hipofluxo pulmonar: Análise crítica da técnica cirúrgica e resultados imediatos. Arq Bras Cardiol 56(4):281-286,1991.*
- Marcelletti C, Corno A, Giannico S, Marino B. Inferior vena cava-pulmonary artery extracardiac conduit: a new form of right heart bypass. J Thorac Cardiovasc Surg 1990; 100:228-32.
- Marchand P: The use of a cusp-bearing homograft patch the outflow tract and pulmonary artery in Fallot's Tetralogy and pulmonary valvular stenosis. Thorax 1967;22:497-509.
- Marie PY, Marcon F, Brunorte F, Briancon S, Dauchin N, Worms AM, Robert J, Pernot C. Right ventricular overload and induced sustained ventricular tachycardia in operatively "repaired" tetralogy of Fallot. Am J Coll Cardiol 1994;69:785-789.

- Mc Elhinney DB, Reddy VM, Moore P, Hanley FL. Revision of previous Fontan connections to extracardiac or intraatrial conduit cavopulmonary anastomosis. *Ann Thorac Surg.* 1996, 62(5):1276-82.
- McGoon DC, Baird DK, Davis GD. Surgical management of large bronchial collateral arteries with pulmonary stenosis or atresia *Circulation* 1975;52:109-18.
- McKay R, De Leval MR, Rees P - Post -operative angiographic assessment of modified Blalock-Taussig shunts using expanded polytetrafluoroethylene (Gore - tex). *Ann thorac Surg*, 1980;30:137-45
- Messmer K; Sunder-Plassman L; Klovekorn WP; Holper K. Circulatory significance of hemodilution: rheological changes and limitations. *Adv. Microcirc* 1972; 4: 1-77.
- Miyamura H, Kanazawa H, Hayashi J, Eguchi S. Thrombosed St Jude Medical valve prosthesis in the right side of the heart in patents with tetralogy of Fallot. *J Thorac Cardiovasc Surg* 1987;94:148-50.
- Moons P, Gewillig M, Sluysmans T, Verhaaren H, Viart P, Massin M, Suys B, Budts W, Pasquet A, De Wolf D, Vliers A. Long term outcome up to 30 years after the Mustard or Senning operation: a nationwide multicentre study in Belgium. *Heart.* 2004; 90: 307-313.
- Murphy JG, Gersh BJ, Mair DD, Fuster V, Mc Goon MD, Ilstrup DM, Mc Goon DC, Kirklin JW, Danielson GK. Long-term outcome in patients under-going surgical repair of tetralogy of Fallot. *N Engl J Med* 1993;329:593-599.
- Murthy KS, Krishnanaik S, Mohanty SR, Varghese R, Cherian KM. A new repair for anomalous left coronary artery. *Ann Thorac Surg* 2001; 71:1384-6.
- Naik SK, Knight A, Elliott MJ. A prospective randomized study of a modified technique of ultrafiltration during pediatric open-heart surgery. *Circulation* 1991;84 (Suppl 3): 422-31.
- Nakata S, Imai Y, Takanashi Y, Kurosawa H, Tezuka K, Nakazawa M, Ando M, Takao A- A new method for the quantitative standardization of cross-sectional areas of the pulmonary arteries in congenital heart diseases with decreased pulmonary blood flow. *J Thorac Cardiovasc Surg* 1984; 88:610-9.
- Nakata S, Imai Y, Takanashi Y, Kurosawa H, Tezuka K, Nakazawa N, Ando M, Takao A. A new method for the quantitative standardization of cross-sectional areas of the pulmonary arteries in congenital heart disease with decreased pulmonary blood flow. *J Thorac Cardiovasc Surg* 1984;88:610-19.
- Niwaya K, Knott-Graig CJ, Lane MM, Chandrasekaren K, Overholt ED, Elkins RC. Cryopreserved homograft valves in the pulmonary position: risk analysis for intermediate-term failure. *J Thorac Cardiovasc Surg* 1999; 117:141-6.
- Nollet G, Fischlein T, Bouterwek S, Bohmer C, Klinner W, Reichart B. Long-term survival in patients with repair of tetralogy of Fallot: 36-year after surgical repair. *J Am Coll Cardiol* 1997;30:1374-1383.
- Norvick WM, Stidham GL, Guillory KL, Ivancan V, Malicic I, Sandoval N, Reid RW, Lazorishisnets VV, Davis MG, Baum VC, Di Sessa TG. Are we improving after 10 years of humanitarian paediatric cardiac assistance?- *Cardiology in the Young* 2005;15:379-384.
- Norwood WI, Lang P, Castaneda AR, Campbell DN. Experience with operations for hypoplastic left heart syndrome. *J Thorac Cardiovasc Surg*, 1981;82(4):511-9.

- Norwood WI, Lang P, Hansen DD. Physiologic repair of aortic atresia-hypoplastic left heart syndrome. *N Engl J Med*, 1983;308(1):23-6.
- Oechslin E, Jenni R. 40 years after the first atrial switch procedure in patients with transposition of the great arteries: long-term results in Toronto and Zurich. *Thorac Cardiovasc Surg*. 2000; 48: 233-237.
- Oku, H; Shirotani, H; Sunakawa, A; Yokoyama, T: Postoperative long-term results in total correction of tetralogy of Fallot: hemodynamics and cardiac function. *Ann Thorac Surg* 1986;41:413-18.
- Oury JH, Hiro SP, Maxwell JM, Lamberti JS, Duran CM. The Ross procedure: current registry results. *Ann Thorac Surg* 1998; 66: S162-5.
- Owen AR, Gatzoulis AM. Tetralogy of Fallot: late outcome after repair and surgical implications. *Semin Thorac Cardiovasc Surg* 2000;3:216-26.
- Pacifico, AD; Kirklin, JW; Blackstone, EH: Surgical management of pulmonary stenosis in tetralogy of Fallot. *J Thorac Cardiovasc Surg* 1977;74:382-95.
- Pearl JM, Mannig PB, ME Namara JL, Sancier MM, Thomas DW. Effect of modified ultrafiltration on plasma thromboxane B₂, Leukotriene B₄, and eudothelin-1 in infants undergoing cardiopulmonary bypass. *Ann Thorac Surg* 1999, 68: 1369-75.
- Quintessenza JA, Jacobs JP, Morell VO, Giroud JM, Boucek RJ. Initial experience with a bicuspid polytetrafluoroethylene pulmonary valve in children and adults: A new option for right ventricular outflow tract reconstruction. *Ann Thorac Surg* 2005;79:924-931.
- Rastelli GC, McGoon DC, Wallace RB. Anatomic correction of transposition of great arteries with ventricular septal defect and subpulmonary stenosis. *J Thorac Cardiovasc Surg* 1969; 58:545-52.
- Rastelli or Lecompte procedure? *J Thorac Cardiovasc Surg* 1992; 103:428-36.
- Reich O, Voriskova M, Ruth C, Krejcir M, Marek J, Skovranek J, Hucin B, Samanek M. Long-term ventricular performance after intra-atrial correction of transposition: left ventricular filling is the major limitation. *Heart*. 1997; 78: 376-381.
- Rost L, Murz B, Colle AM, Festa P, Rodaelli S, Frigiola A. Pulmonary valve replacement: a role for mechanical prostheses? *Ann Thorac Surg* 1998; 65:889-90.
- Sakurai T, Kado H, Nakano T, Hinokiyama H, Shiose, M. Kajimoto, K. Joo, and Y. Ueda. Early results of bilateral pulmonary artery banding for hypoplastic left heart syndrome. *Eur. J. Cardiothorac. Surg.*, December 1, 2009; 36(6): 973 - 979.
- Sano S, Kawada M, Yoshida H, Kino K, Irie H, Aoki A, et al. Norwood procedure to hypoplastic left heart syndrome. *Jpn J Thorac Cardiovasc Surg*. 1998;46(12):1311-6.
- Sarkar D, Bull C, Yates R, Wright D, Cullen S, Gewillig M, Clayton R, Tunstill A, Deanfield J. Comparison of long-term outcomes of atrial repair of simple transposition with implications for a late arterial switch strategy. *Circulation*. 1999; 100: II-176-II-181.
- Senning A- Surgical correction of transposition of the great vessels. *Surgery*, 1959;45: 966-999.
- Sese A, Omoto Y. New technique in the transfer of an anomalously originated left coronary artery to the aorta. *Ann Thorac Surg* 1992; 53:527-9.
- Sievens HH, Storde U, Rohwedder EB, et al. Superior function of a bicuspid over a monocuspid patch for reconstruction of a bicuspid over a monocuspid patch for reconstruction of a hypoplastic pulmonary root in pigs. *J Thorac Cardiovasc Surg* 1993;105:580-90.


- Stark J, Bull C, Stajevic M, Jothi M, Elliott M, de Leval M. Fate of subpulmonary homograft conduits: determinants of late homograft failure. *J Thorac Cardiovasc Surg* 1998;115:506-14.
- Stoica SC, Philips AB, Egan M, Rodeman R, Chisolm J, Hill S, Cheatham JP, E. Galantowicz ME. The retrograde aortic arch in the hybrid approach to hypoplastic left heart syndrome. *Ann. Thorac. Surg.*, 2009; 88(6): 1939 - 1947.
- Tashiro T, Todo K, Hamta Y, Yasunaga H, Nagata M, Nakamura M. Anomalous origin of the left coronary artery from the pulmonary artery: new operative technique. *J Thorac Cardiovasc Surg* 1993; 106:718-22.
- Therrien J, Marx GR, Gatzoulis AM. Late problems in tetralogy of Fallot-recognition, management and prevention. *Cardiol Clin* 2002, 20:395-404.
- Thompson LD, Mc Elhinney DB, Findlay P, Miller- Hance W, Chen MJ; Minami M; Petrossian E , Parry AJ; Reddy VM, Hanley FL. A prospective randomized study comparing volume-standardized modified and conventional ultrafiltration in pediatric cardiac surgery. *Thorac Cardiovasc Surg* 2001; 122 (2): 220-28.
- Turina M, Siebenmann R, Nussbaumer P, Senning A. Long-term outlook after atrial correction of transposition of great arteries. *J Thorac Cardiovasc Surg.* 1988; 95: 828–835.
- Turrentine MW, McCarthy RP, Vijay P, McConnell KW, Brown JW. Polytetrafluoroethylene monocusp valve reconstruction of the right ventricular outflow tract. *Ann Thorac Surg* 2002;73:871-9.
- Vliegen HW, van Straten A, de Roos A, et al. Magnetic resonance imaging to assess the hemodynamic effects of pulmonary valve replacement in adults late after repair of tetralogy of Fallot. *Circulation* 2002; 106:1703-7.
- Vohue PR, Tamisier D, Sidi D, Vernant F, Mauriat P, Pouard P. Leca F. Anomalous left coronary artery from the pulmonary artery: Results of isolated aortic reimplantation. *Ann Thorac Surg* 1992; 54: 621-7.
- Von Son JA, Mohr FW. Repair of anomalous connection of the left coronary artery to the pulmonary artery using native aorta and pulmonary tissue flaps. *Eur J Cardiothorac surg* 1997; 12:322-9.
- Vouglpatanasin W, Hillis LD, Lange RA. Prosthetic heart valves. *N Engl J Med* 1996;335:407-16.
- Wells WJ, Arroyo Jr H, Bremner RM, Woog J, Starnes VA. Homograft conduit failure in infants is not due to somatic out growth. *J Thorac Cardiovasc Surg* 2002;124:88-96.
- Wells WJ, Blackstone E. Intermediate outcome after Mustard and Senning procedures: a study by the Congenital Heart Surgeons Society. *Semin Thorac Cardiovasc Surg Pediatr Card Surg Annu.* 2000; 3: 186–197.
- Westphal FL, Maluf MA, Silva CM, Carvalho ACC, Buffolo E. Estudo angiográfico comparativo da artéria pulmonar no pré e pós-operatório de pacientes submetidos a operação de derivação cavopulmonar bidirecional. *Rev Bras Cir Cardiovasc* 2001; 16 (4): 305-20.
- Williams WG, Mc Crindle BW, Ashburn DA, Jonas RA, Mavroudis C, Blackstone EH. Outcomes of 829 neonates with complete transposition of the great arteries 12–17 years after repair. *Eur J Cardiothorac Surg.* 2003; 24: 1–9.
- World Summit on Pediatric and Congenital Heart Surgery . Services, Education and Cardiac Care in Children and Adults with Congenital Heart Disease. Global Coalition to Improve Cardiac Care for Children and Adults with Pediatric and Congenital Heart Disease across the World. Montreal – Canada; June, 2008.

Yamagishi M, Kurosawa H. Outflow reconstruction of tetralogy of Fallot using a Gore-Tex valve. *Ann Thorac Surg* 1993;56:1414-6.

Zavanella C, Portela F. Early failure of bovine jugular vein conduit. *J Thorac Cardiovasc Surg* 2004; 127:610.

IntechOpen

IntechOpen



Contemporary Pediatrics

Edited by Dr. Öner Özdemir

ISBN 978-953-51-0154-3

Hard cover, 434 pages

Publisher InTech

Published online 21, March, 2012

Published in print edition March, 2012

Book Contemporary Pediatrics with its 17 chapters will help get us and patients enlightened with the new developments on the contemporary pediatric issues. In this book volume, beyond classical themes, a different approach was made to current pediatric issues and topics. This volume, as understood from its title, describes nutritional infant health and some interesting topics from pediatric subspecialties such as cardiology, hematology and infectious diseases.

How to reference

In order to correctly reference this scholarly work, feel free to copy and paste the following:

Miguel Angel Maluf (2012). Pediatric Cardiac Surgery: A Challenge of Skill and Creativity in Constant Search Results, Contemporary Pediatrics, Dr. Öner Özdemir (Ed.), ISBN: 978-953-51-0154-3, InTech, Available from: <http://www.intechopen.com/books/contemporary-pediatrics/pediatric-cardiac-surgery-a-challenge-of-skill-and-creativity-in-constant-search-results>

INTech
open science | open minds

InTech Europe

University Campus STeP Ri
Slavka Krautzeka 83/A
51000 Rijeka, Croatia
Phone: +385 (51) 770 447
Fax: +385 (51) 686 166
www.intechopen.com

InTech China

Unit 405, Office Block, Hotel Equatorial Shanghai
No.65, Yan An Road (West), Shanghai, 200040, China
中国上海市延安西路65号上海国际贵都大饭店办公楼405单元
Phone: +86-21-62489820
Fax: +86-21-62489821

© 2012 The Author(s). Licensee IntechOpen. This is an open access article distributed under the terms of the [Creative Commons Attribution 3.0 License](https://creativecommons.org/licenses/by/3.0/), which permits unrestricted use, distribution, and reproduction in any medium, provided the original work is properly cited.

IntechOpen

IntechOpen