

# We are IntechOpen, the world's leading publisher of Open Access books Built by scientists, for scientists

6,900

Open access books available

185,000

International authors and editors

200M

Downloads

Our authors are among the

154

Countries delivered to

TOP 1%

most cited scientists

12.2%

Contributors from top 500 universities



WEB OF SCIENCE™

Selection of our books indexed in the Book Citation Index  
in Web of Science™ Core Collection (BKCI)

Interested in publishing with us?  
Contact [book.department@intechopen.com](mailto:book.department@intechopen.com)

Numbers displayed above are based on latest data collected.  
For more information visit [www.intechopen.com](http://www.intechopen.com)



## Neuroimaging in Fragile X-Associated Tremor/Ataxia Syndrome (FXTAS)

Laia Rodriguez-Revenge<sup>1,2</sup>, Beatriz Gómez-Ansón<sup>3,4</sup>,  
 Esther Granell Moreno<sup>3</sup>, Javier Pagonabarraga<sup>4,5</sup> and Montserrat Mila<sup>1,2</sup>  
<sup>1</sup>Biochemistry and Molecular Genetics Department, Hospital Clínic, IDIBAPS Barcelona  
<sup>2</sup>CIBER de Enfermedades Raras (CIBERER), Barcelona  
<sup>3</sup>Neuroradiology Unit, Radiology Department, Hospital Sant Pau, Barcelona  
<sup>4</sup>CIBER de Enfermedades Neurodegenerativas (CIBERNED), Barcelona  
<sup>5</sup>Neurology Service, Hospital Sant Pau, Barcelona  
 Spain

### 1. Introduction

Fragile X syndrome (FXS, OMIM #300624) is the most common form of inherited mental retardation. The real incidence of the syndrome is not known, but epidemiological studies indicate that it is responsible for mental retardation in 1 in 4,000-6,000 males and in 1 in 7,000-10,000 females of European descent (for review Hagerman, 2002). In a study performed in Catalonia it gave an incidence of 1:2,466 male and 1:8,333 females (Rife *et al.*, 2003). It is also important to highlight the high incidence of premutation carriers, 1 in 1,233 males and 1 in 411 females (Rife *et al.*, 2003). FXS is inherited as X-linked dominant trait, with a reduced penetrance (80% for males and 30% for females).

In 1991 the responsible gene was identified by positional cloning and named the fragile X mental retardation-1 gene (*FMR1*) (Oberle *et al.*, 1991; Verkerk *et al.*, 1991; Yu *et al.*, 1991). The *FMR1* gene is located in the long arm of the X chromosome at Xq27.3, it expands 17 exons, and 40 kb of genomic DNA. It transcribes an mRNA of 3.9 kb, and the translated protein is called fragile X mental retardation protein (FMRP). The lack of this protein, which plays an important role in synaptogenesis and synaptic plasticity (Basell & Warren, 2008), is the cause of the FXS.

FXS is almost exclusively caused by a dynamic mutation, a CGG repeat expansion in the 5' untranslated region of the *FMR1* gene (Oberle *et al.*, 1991; Verkerk *et al.*, 1991; Yu *et al.*, 1991). In a normal situation the number of CGG repeats is polymorphic with alleles between 6 to about 54, with the most common allele presenting 30 CGG repeats. In this situation the CpG island, which is located in the promoter of the gene acting as a switch depending on its methylation status, is unmethylated. Thus the gene is active, *FMR1* is transcribed and translated. Repeats at this size remain stable upon transmission. A second class of alleles that overlaps with the upper range of the wild-type is those with ~40-55 CGGs. This range, known as the gray zone, no expands to full mutation but it is transmitted slightly unstable to subsequent generations with the possibility of creating a premutated allele. In the premutation, alleles range from 55 to about 200 CGG repeats. At this situation, the *FMR1*

gene is also transcribed as the CpG island is unmethylated. Therefore, premutated carriers have normal or lightly reduced synthesis of FMRP and they are asymptomatic for FXS. However, they have risk of having affected descendance since the number of CGG is unstable, and in each cellular division it can increase, and can be transmitted with a higher number of repeats to the next generation. Finally, when the CGG number is beyond 200 repeats (known as full mutation), the CpG island is methylated, and as consequence, the gene is transcriptionally silenced, and no protein is translated. These individuals are always affected if they are males and in about 30% of females.

In this chapter we review the clinical, molecular and neuroradiological aspects of FXTAS syndrome, a late-onset neuropsychiatric degenerative disorder that occurs predominantly in male carriers of the *FMR1* premutation. Based on our experience we describe in detail the different aspects that characterize the syndrome as well as the new findings.

## 2. Fragile X syndrome premutation and FXTAS identification

The possibility of clinical involvement in carriers of premutation expansions (55 to 200 CGG repeats) of *FMR1* gene was initially discounted, since carrier mothers of FXS children have a normal cognitive functioning (Bennetto *et al.*, 2001; Reiss *et al.*, 1993). Even though, and contrary to expectation, there are reported several subgroups of male and female premutation carriers displaying features consistent with the typical clinical spectrum of FXS. For instance, Riddle and co-workers (1998) and Hagerman (2002) described a group of premutation carriers with prominent ears and joint laxity; or with learning disabilities, attention deficit/hyperactivity disorder (ADHD), or difficulty with math (Riddle *et al.*, 1998, reviewed in Hagerman & Hagerman 2004). In addition, some carriers have emotional problems, including anxiety, obsessional thinking, schizotypy, and/or depression (Hagerman *et al.*, 2002; Rodriguez-Revengea *et al.*, 2008a). Such findings were observed to be more likely to occur in carriers with a lowered FMRP levels and particularly in those carrier females with larger CGG expansions (>100 repeats) (Johnston *et al.*, 2001).

There are, however, two forms of clinical involvement among carriers of premutation alleles that are not consistent with the clinical spectrum of the FXS. These two disorders are the primary ovarian insufficiency (FXPOI) and the fragile X-associated tremor/ataxia syndrome (FXTAS). FXPOI, which refers to the cessation of menses before age 40, is seen in ~20% of female who carry permutation alleles. Therefore, the genetic counseling for premutated women has to include a fertility advice since delaying the reproduction may not be a good option.

FXTAS, the second form of clinical involvement described among permutation carriers, was identified in 2001 by Hagerman and co-workers as a late-onset neurodegenerative disorder (Hagerman *et al.*, 2001). It took more than 10 years after the *FMR1* gene identification to recognize FXTAS as a *FMR1* permutation associated phenotype. One explanation for this is that the movement disorder experienced by older carriers, who were thought to be clinically normal, was not associated with the FXS (a childhood disorder) affecting children. Mothers of FXS children, being seen in clinics, were often expressing concerns about their fathers (*FMR1* premutation carriers) who were experiencing problems with hand tremor and unsteady gait. When Hagerman and co-workers evaluated these male carriers they found that they all have a common neurological profile, consisting of intention tremor and gait ataxia (reviewed in Hagerman & Hagerman 2004). Therefore, FXTAS was firstly identified among older male carriers of premutation alleles, including progressive action tremor and

ataxia with associated radiological findings (Hagerman & Hagerman 2004). However, to date FXTAS has also been described among premutated women although it has been suggested that it occurs less frequently and that the phenotype is milder with older age at onset (Hagerman *et al.*, 2001; Jacquemont *et al.*, 2004a). An explanation for this difference is the presence of a second normal allele and a random X-inactivation of the premutated one; however, there may be additional sex-specific effects that reduce penetrance among females (Hagerman & Hagerman, 2004).

Not all *FMR1* premutation carriers develop FXTAS and it remains unknown which carriers will do so and when. It has been estimated that at least one-third of all male carriers will develop a FXTAS syndrome, although the penetrance increases with age, exceeding 50% for men aged 70-90 years. Moreover, there is significant variability in the progression of neurological dysfunction (Hagerman & Hagerman 2004; Jacquemont *et al.*, 2004a, 2004b). In an attempt to provide an estimation of FXTAS penetrance among premutation carriers in Spanish FXS families, we evaluated 398 families among which 151 were composed of at least three generations. Our results showed that signs of FXTAS were detected in 16.5% of female premutation carriers and in 45.5% of premutated males older than 50 years. Overall, the mean age and the mean of CGG repeat number for the FXTAS men group was of  $72.05 \pm 6.85$  and  $85 \pm 21.5$  (mean  $\pm$  SD), respectively. Similarly it was of 75.8 years old  $\pm 10.2$  and 82 CGG repeats  $\pm 18$  (mean  $\pm$  SD) for the FXTAS women group (Rodriguez-Revengea *et al.*, 2009).

The description and characterization of FXTAS syndrome is of great interest to the population, because the prevalence of *FMR1* premutation in the general population is relatively high. Several studies have been performed in order to determine the real role of FXTAS in undiagnosed adult patients with movement disorders. The results obtained in European populations ranges from 0% to 4% (Brussino *et al.*, 2005; Macpherson *et al.*, 2003; Van Esch *et al.*, 2005; Zuhlke *et al.*, 2004). Our studies show an estimated FXTAS prevalence of 2% among patients presenting with ataxia or movement disorders of unknown etiology (Rodriguez-Revengea *et al.*, 2007, 2008b). Although large studies are necessary to better define FXTAS prevalence in this kind of population, on the basis of premutation male frequency in general population, the prevalence of FXTAS has been estimated in  $\sim 1/3,000$  males aged over 50 years of age ( $\sim 1/10,000$  males of all ages) (Hagerman & Hagerman, 2004).

### 3. Clinical and cognitive overview

FXTAS syndrome is a neurodegenerative disease that eventually appears in adult subjects who carry a CGG repeat length between 55 and 200 trinucleotides in the *FMR1* gene of chromosome X (Jacquemont *et al.*, 2007). These subjects are categorized as *FMR1* premutation carriers. As stated above, it was originally described in grandparents of children with FXS. Different specialized centres in diagnosing and attending children with FXS observed that their grandparents and uncles were more likely to develop, from 50 years onwards, a stereotyped clinical picture characterized by unsteadiness while walking and action tremor in both hands (Hagerman *et al.*, 2001).

Neurological examination of children's relatives disclosed the presence of predominant intention tremor in hands and wide-base cerebellar ataxia. Both symptoms used to follow a progressive course, and were often accompanied by progressive cognitive and behavioral disturbances (Hagerman *et al.*, 2001).

Clinical descriptions published in the past 10 years have demonstrated that *FMR1* premutation carriers are very prone to develop cerebellar dysfunction from the age of 50 years. Severity of symptoms usually impairs gait and associates mild to moderate dysmetria, repeated falls, intention tremor, and speech difficulties. The combination of cerebellar dysfunction, cognitive impairment and the appearance of characteristic radiologic features in the brain MRI has been claimed to constitute a nosological entity that has been named Fragile X-associated Tremor/Ataxia syndrome (FXTAS).

In the only study about the natural history of patients with FXTAS, this syndrome has been observed to represent a disabling condition impacting on motor daily activities, thinking, and social skills after 15 years of evolution (Jacquemont *et al.*, 2003).

Mean age of onset of FXTAS is 60 years. Mild intention tremor, affecting both hands, symmetrically, is usually the first symptom. Within the first 5 years, tremor becomes more apparent and some balance and speech problems develop. At this stage, balance problems are mild and are only noticed by patients as a feeling of unsteadiness while walking for long periods of time or when turning. Between 5 and 15 years from disease onset balance problems progress in severity and are usually the main complaint, provoking repeated falling and limiting the ability to drive, walking autonomously in the streets, or using public transportation. At this stage, moreover, is when the first cognitive and behavioural disturbances appear. After 15 years, autonomous walk is greatly impaired, and patients need the help of a walker or the supervision of another person. Finally, dysphagia and severe ataxia are associated with immobility and recurrent urinary and respiratory infections (Leehey *et al.*, 2007).

The penetrance of FXTAS is not well established. Penetrance increases with age, and it has been reported to range from 15% at 50 years of age to 75% at age 80 (Jacquemont *et al.*, 2004b).

Being a relatively newly described condition, the clinical spectrum of the disease has expanded in the past years. As in other diseases, such as Parkinson's disease, FXTAS was initially conceived as a predominant motor disease. New data have evidenced that many clinically relevant cognitive and behavioural disturbances may also develop in FXTAS patients. Also, while FXTAS was originally described in males, the number of women developing FXTAS symptoms has increased exponentially in the past five years. Women have been reported to develop the same motor, cognitive and behavioural problems than males, although women are more likely to develop a milder form of the disease (Coffey *et al.*, 2008). Nevertheless, cognitive dysfunction severe enough to accomplish criteria for dementia has been reported in FXTAS women with inactivation of the healthy X-chromosome (Rodriguez-Revilla *et al.*, 2010).

Cognitive impairment in FXTAS is characterized by recent episodic memory problems, difficulties in sustained attention, and other executive problems such as organizing new material and inhibiting automatic responses. In males, initially mild cognitive problems can accomplish criteria for dementia after 5 to 10 years of evolution (Grisby *et al.*, 2007). Extension of the neurodegenerative process to prefrontal and temporal structures seems to account for the progression of cognitive defects in FXTAS patients (Seritan *et al.*, 2008). While balance problems and tremor seem to be the consequence of the progressive degeneration of middle cerebellar peduncles and associated cerebellar structures, both cognitive and behavioural problems in FXTAS are associated with diffuse cortical and white-matter subcortical degeneration (Hashimoto *et al.*, 2011).



The dysexecutive problems of FXTAS patients affect different prefrontal dominions. Cognitive tasks dependent on the dorsolateral prefrontal cortex are affected since the early stages of the disease. Problems in working memory, set-shifting and mental flexibility have been described in patients with mild ataxia and tremor (Grisby *et al.*, 2007). Later in the disease, cognitive alterations more dependent on the medial prefrontal cortex, such as difficulties in inhibiting automatic responses, arise. Response inhibition in go-no go tasks, inability to perform Luria's promotor series, and signs of environmental dependency were seen not only to limit the ability of FXTAS' patients to cope with cognitive strategies in the daily life, but also accounted for the behavioral disorders of the disease (Moore *et al.*, 2004a). Memory problems develop due to both prefrontal and medial temporal dysfunction. Numerous eosinophilic inclusions have been observed bilaterally in the hippocampus and the entorhinal cortex. Progressive deterioration and atrophy of medial temporal lobe structures explains the progressive nature of temporal disorientation and both verbal and visual recent episodic memory. (Grisby *et al.*, 2008). In comparison with Alzheimer's disease, FXTAS patients show a higher impairment in dysexecutive tasks and less memory impairment, and in comparison with Parkinson's disease, visuospatial skills seem to be more preserved. In addition, compared to both Parkinson's disease and dementia with Lewy bodies, FXTAS patients are less likely to manifest visual hallucinations and psychosis (Grisby *et al.*, 2008).

Neuropsychiatric disturbances in FXTAS are characterized by a change in premorbid personality. Patients with FXTAS, as in frontotemporal dementia, may develop irritability, psychomotor agitation, a tendency to selfishness, blunted emotions, apathy, and sometimes even social and personal disinhibition. Similarities with frontotemporal dementia correlate with the evidence of predominant medial prefrontal and anteromedial temporal atrophy in neuroimaging studies (Bacalman *et al.*, 2006).

In summary, fronto-temporal cognitive and behavioral disturbances seem to characterize FXTAS patients. Frontal cognitive symptoms are present in early stages and progress through disease evolution, medial prefrontal behavioral disturbances appear in the middle stages and progress also in severity, and finally, from medium to late FXTAS stages, temporal cognitive symptoms impair even more global cognitive function and lead to dementia. A better delineation of each one of these components would help to refine the progression of cognitive and behavioural symptoms in different FXTAS subgroups (age, gender, etc...).

Other neurological disturbances described in FXTAS patients are the development of rigid-akinetic parkinsonism with predominant axial involvement (35%), unilateral resting tremor (10%), peripheral neuropathy (30%), dysautonomia (40-50%; urinary urgency, erectile dysfunction, orthostatic hypotension), nistagmus (10%), and hyporreflexia (10%).

In some patients, postural and intention tremor may present in isolation, making the diagnosis of essential tremor very likely. Reported cases stress the importance of considering the diagnosis of FXTAS in patients diagnosed of essential tremor who develop ataxia or with a family history of mental retardation (Leehey *et al.*, 2003). Other patients present with isolated and progressive adult-onset ataxia. Currently, genetic testing for FXTAS must be considered in any patient with ataxia developing after the age of 50. The screening of FXTAS in a prospective series of patients with multiple system atrophy showed that 4% of patients with an initial diagnosis of multiple system atrophy of the cerebellar type were actually *FMR1* premutation carriers (Kamm *et al.*, 2005). Taking into account the

consequences of a diagnosis of FXTAS on genetic counselling, FXTAS should be categorized as a new kind of spinocerebellar ataxia (Milà *et al.*, 2009).

4. Molecular genetics overview

FXTAS is an allelic disorder to the FXS, and therefore should be considered as a distinct neurodegenerative disorder. In fact, the molecular mechanism leading to FXTAS is distinct from the *FMR1* silencing mechanism and/or a deficit in FMRP operating in FXS. In premutated patients the *FMR1* gene is rarely silenced and FMRP levels are generally normal or only slightly lowered (Hagerman & Hagerman, 2004) (Fig.1a). The only known molecular abnormality among premutation carriers is the presence of markedly elevated levels (~2-8 fold) of *FMR1* mRNA (Fig.1b).

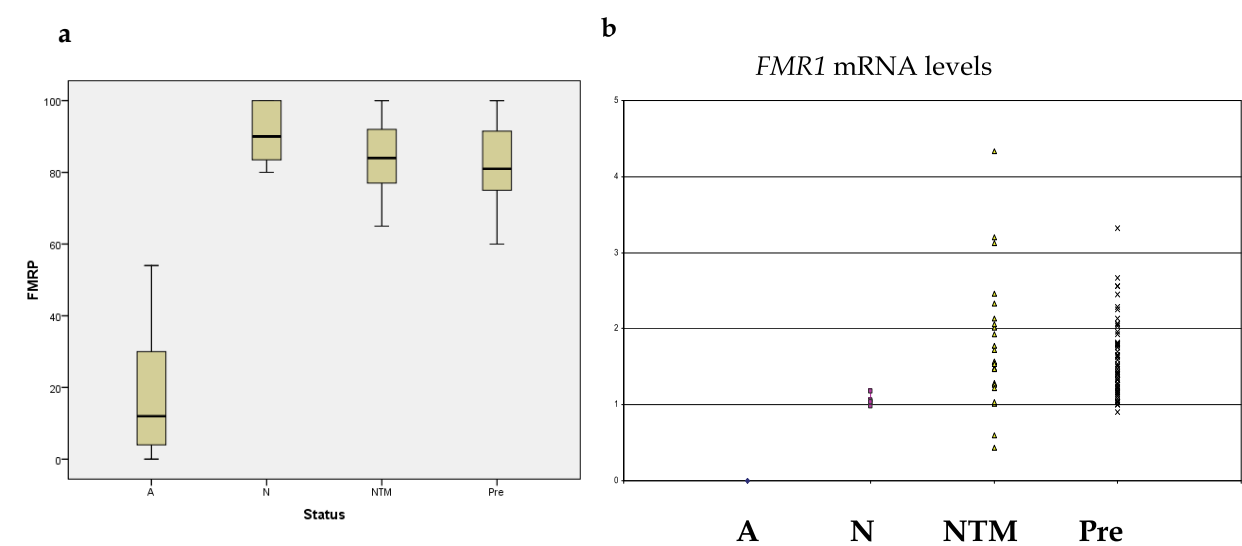


Fig. 1. a) Schematic representation of FMRP levels detected in A: FXS affected individuals, N: individuals with a normal CGG repeat number; NTM: *FMR1* premutation male carriers and Pre: *FMR1* premutation female carriers. B) Schematic representation of *FMR1* mRNA levels detected in A: FXS affected individuals, N: individuals with a normal CGG repeat number; NTM: *FMR1* premutation male carriers and Pre: *FMR1* premutation female carriers.

The increased transcriptional activity of the *FMR1* gene seems to be positively correlated with the size of the CGG repeat. That is, CGG repeats in the upper range (100-200 CGG) result in average 5-8 fold elevation, whereas CGGs in the lower range (50-100 CGG) result in an average 2-fold elevation (Kenson *et al.*, 2001; Oostra & Willemsen, 2003; Tassone *et al.*, 2000a, 2000b). Although the precise mechanism for this overexpression is unknown, several possible mechanisms have been postulated. A feedback mechanism suggests that the cell attempts to compensate for reduced levels of FMRP by increasing the amount of available *FMR1* transcript (reviewed in Galloway & Nelson, 2009; Tassone & Hagerman, 2003). Alternatively, it is likely that the increasing length of the CGG repeat near the *FMR1* promoter proportionally opens the chromatin, allowing more ready access to transcription factors (Tan *et al.*, 2009). The presence of these elevated levels of abnormal (expanded CGG repeat) *FMR1* mRNA led to propose an RNA “toxic gain-of-function” model for FXTAS, in which the mRNA itself, with the abnormal CGG repeat tract, is causative of the neurological

disorder (Greco *et al.*, 2002; Hagerman & Hagerman, 2004; Hagerman *et al.*, 2001; Jacquemont *et al.*, 2003). Although several evidences support the RNA-based mechanism, the precise form of how the CGG-repeat RNA is responsible for FXTAS pathogenesis is not yet resolved (Garcia-Arocena & Hagerman, 2010). The same RNA “toxic gain-of-function” mechanism has been proposed for myotonic dystrophy (DM1 and DM2), in which either the expanded repeat tract of CUG in DM1 or CCUG in DM2 sequestered CUG-binding proteins that disrupts mRNA processing of other genes or transport of other mRNAs (Mankodi & Thornton, 2002). In fact, this model has been demonstrated for DM1 by placing an expanded CTG tract in 3′ UTR region of the *DMPK* mRNA in a transgenic mouse (Mankodi *et al.*, 2000). Apart from this finding, FXTAS and myotonic dystrophy have another important similarity that supports the RNA gain-of-function mechanism. Both disorders show nuclear inclusions produced as a result of the binding proteins sequestered by the respective mRNA, with a cytotoxic effect that leads to cell death. In a study performed by Greco and co-worker (2002) eosinophilic intranuclear inclusions in neurons and astrocytes throughout the cortex and in deep cerebellar nuclei of FXTAS post-mortem samples were reported. Furthermore, in a subsequent study, there is described a highly significant association between CGG length and both the number of inclusions and the age of death, which correlates with the progressive character of the disease (Greco *et al.*, 2006). The intranuclear inclusions associated with FXTAS have characteristic features different than those found in tauopathies (e.g., Pick disease), synucleinopathies (e.g., Lewy body dementias and Parkinson disease) or polyglutamine disorders (SCAs). It is important to note that, unlike the polyglutamine disorders, there is no known structurally abnormal protein with FXTAS (reviewed in Galloway & Nelson, 2009; Iwahashi *et al.*, 2006). Taken together, these facts define FXTAS as a new class of inclusion disorder.

In order to test the RNA gain-of-function hypothesis for FXTAS, a “knock-in” mouse model has been generated in which the endogenous mouse CGG repeat was replaced by a human CGG tract carrying 98 CGGs (Bontekoe *et al.*, 2001; reviewed in Oostra & Willemsen, 2009). Further studies of the brain of these expanded-repeat mice (at 20–72 weeks) evidenced elevated *Fmr1* mRNA levels and ubiquitin-positive intranuclear inclusions (Willemsen *et al.*, 2003). An increase was also observed in both the number and the size of the inclusions in specific brain region during the course of life (Oostra & Willemsen, 2003). The presence of inclusions in this mouse, that has normal levels of FMRP, provides evidence against a protein-deficiency model for FXTAS, and supports a direct role of the *Fmr1* gene, by either CGG expansion *per se* or by elevated *Fmr1* mRNA levels, in the pathology.

There are several other animal and cell-based studies that provide evidence of direct RNA toxicity (Galloway & Nelson, 2010; reviewed in Garcia-Arocena & Hagerman, 2010). Most of these studies have demonstrated a sequestration of several candidate CGG-repeat binding proteins from their normal function. Remarkably, they have also demonstrated at least partial rescue of the wild-type phenotype by overexpressing the sequestered protein. The number of candidate proteins for sequestration has been lately increased and surprisingly, it has also been shown that inclusions are dynamic structures that expand over time, resulting in giant inclusions (Sellier *et al.*, 2010). Continuous enlargements of CGG RNA aggregates suggest that these repeats may constantly recruit proteins, implying a founding RNA-protein interaction event that would subsequently trap other proteins through indirect RNA-protein or protein-protein interactions (Sellier *et al.*, 2010). The protein components of FXTAS inclusions fell into eight major functional categories, including: histone family; intermediate filament; microtubule; myelin-associated proteins; RNA-binding proteins;



stress-related proteins; chaperones and ubiquitin-proteasome-related proteins (reviewed Galloway & Nelson, 2010). Interestingly, an antisense transcript, *ASFMR1*, has recently been identified to overlap the CGG repeat region of the *FMR1* gene (Ladd *et al.*, 2007). Similar to *FMR1*, the *ASFMR1* transcript is silenced in full mutation individuals and overexpressed in permutation carriers. However, whether *ASFMR1* contributes to the pathogenesis of either FXTAS or FXS remains to be determined (Tan *et al.*, 2009).

**5. Neuroimaging findings – Conventional MRI strenghts and limitations**

FXTAS was originally described in men, older than 50 years of age, having a typical clinical picture of progressive intention tremor, and cerebellar ataxia (Hagerman *et al* 2001). Magnetic resonance imaging (MRI) of the brain was obtained in these patients searching for specific features, and the finding of hyperintensities in the cerebellar white matter and middle cerebellar peduncles on T2-weighted images was reported as a characteristic feature and called the “MCP sign” (Fig. 2a), as it was seen in nearly all FXTAS-premutated carriers, and not in controls (Brunberg *et al.*, 2002). Other typical MR features described originally in patients with FXTAS included cerebellar, pontine, and cerebral atrophy, as well as white matter hyperintensities (Fig. 2 b-d) (Brunberg *et al.*, 2002).

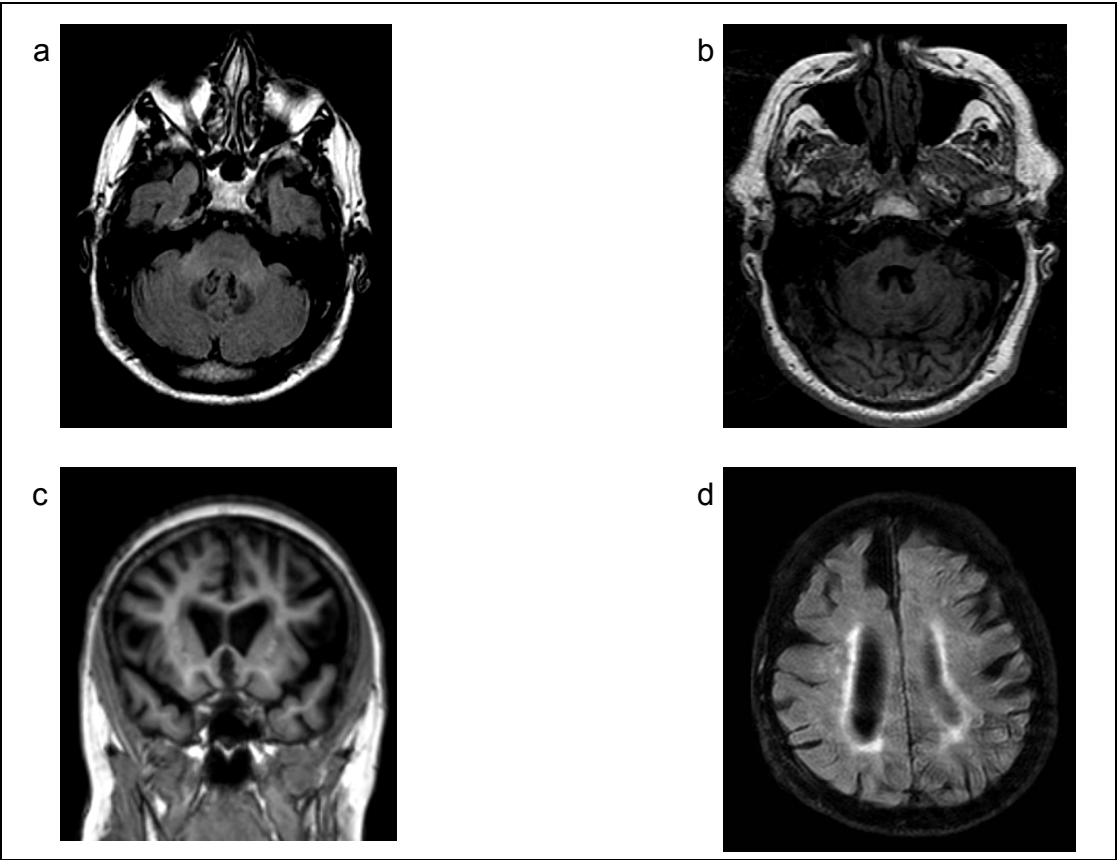


Fig. 2. MR images showing characteristic findings in FXTAS. 1a. Axial FLAIR- MCP sign (middle cerebellar peduncle hyperintensities); 1b. Axial T1- Cerebellar and pontine atrophy; 1c. Coronal T1- Cerebral atrophy; 1d. Axial FLAIR- Hyperintensities in the cerebral white matter.

Thus, characteristic findings described on conventional MRI in patients with FXTAS, were classified into two categories -major and minor criteria-, and proposed, together with clinical findings, as diagnostic criteria for FXTAS (Jacquemont *et al.*, 2003). Major criteria included the MCP sign, as well as white matter and brainstem hyperintensities. Cerebellar and brain atrophy were proposed as minor criteria (Jacquemont *et al.*, 2003) (Table 1).

Examination and Degree	Observation
<b>Radiological:</b>	
Major	MRI white matter lesions in MCPs and or brain stem
Minor	MRI white matter lesions in cerebral white matter
Minor	Moderate-to-severe generalized atrophy
<b>Clinical:</b>	
Major	Intention tremor
Major	Gait ataxia
Minor	Parkinsonism
Minor	Moderate-to-severe short-term memory deficiency
Minor	Executive function deficit

Inclusion criterion: CGG repeat number between 55 and 200.

*Note.* Data described by Jacquemont *et al.* 2003.

Table 1. Clinical Criteria for FXTAS. The diagnostic categories described by Jaquemont et al. 2003 are as follows:

- Definite (1 major radiological sign plus 1 major clinical symptom)
- Probable (1 major radiological sign plus 1 minor clinical symptom or two major clinical symptoms)
- Possible (1 minor radiological sign plus 1 major clinical symptom)

Early neuropathological, postmortem studies of the brain of patients with FXTAS revealed intranuclear inclusions in neurons and astrocytes throughout the cortex and in deep cerebellar nuclei, but not in Purkinje cells of the cerebellum (Greco *et al.*, 2002). Further evidence has shown that there is significant cerebral and cerebellar white matter disease, associated astrocytic pathology in the cerebral white matter, and intranuclear inclusions in both brain and spinal cord (Greco *et al.*, 2006). Additionally, there seems to be an association between the number of CGG repeats and the number of intranuclear inclusions in neurons and astrocytes, so that CGG repeat has been suggested as a predictor for clinical and neuropathological involvement (Greco *et al.*, 2006). Unfortunately, there is no histopathological evidence from brains of premutated, non-FXTAS subjects, who died because of an unrelated condition, being either asymptomatic neurologically, or little symptomatic. This evidence would certainly add in the understanding of the pathogenetic processes underlying glial and neuronal damage, and eventual neurological dysfunction. Brain banks and collaborative actions may represent a good opportunity in this regard. Penetrance of FXTAS among premutation carriers has been studied, and reported to be relevant, mainly in men (Jacquemont *et al.*, 2004). As premutation carriers are relatively common in the general population, it has been proposed that older men with ataxia and intention tremor should be screened for the *FMR1* mutation (Jacquemont 2004). Using the previously described criteria for FXTAS (Jacquemont *et al.*, 2003), a study among adult Spanish patients with ataxia, revealed an estimated FXTAS prevalence varying between

1.15% for males, and 3% for females (Rodriguez-Revena *et al.*, 2007). Similarly, a frequency of 1.6% of patients with FXTAS has been reported among adult patients with movement disorders who tested negative for the Huntington gene (Rodriguez-Revena *et al.*, 2008b). The importance of neuroradiological findings that could be used as an additional screening tool for FXTAS is demonstrated by these studies.

In this regard, the MCP sign, which was originally proposed to be a characteristic and specific feature for FXTAS, that could be used for screening purposes, has been also reported in patients with other forms of adult-onset cerebellar ataxia, thus lacking specificity for FXTAS (Okamoto *et al.*, 2003). Patients with atypical parkinsonism, and particularly those having a clinical picture including dysautonomia, and ataxia -a condition currently known as the cerebellar form of Multiple System Atrophy (MSA)-, may show the MCP sign on MRI, so that middle cerebellar peduncles hyperintensities in a patient with parkinsonism should be regarded as a non-specific finding, which can be seen in FXTAS, but also in MSA (Kamm *et al.*, 2005). Additionally, the sensitivity of the MCP sign may be less than previously thought, as the frequency of the MCP sign among women with FXTAS seems to be less (Hagerman *et al.*, 2004), and its presence among premutated men with subtle neurological, psychiatric, or cognitive dysfunction remains unknown.

As more evidence among *FMR1* premutation carriers developing neurological features, and particularly parkinsonism, is being gained, the spectrum and variability of MRI features becomes broader. Also, the severity of disease, which may relate to CGG repeat number, or other unknown factors, may influence the presence and magnitude of MRI findings. In this context, a correlation between CGG repeat length and reductions in IQ and cerebellar volume, and increased ventricular volume and whole-brain white matter hyperintensities, have been reported in *FMR1* premutation carriers (Cohen *et al.*, 2006). It may well then be the case, that patients with a longer duration of neurological disturbances, or a greater severity, are those showing the so-known “typical MRI findings” of FXTAS. In this regard, more evidence is needed among younger premutated patients. Additionally, premutated women and women with FXTAS seem to have a different phenotype (Berry *et al.*, 2004; Hagerman *et al.*, 2004; Hessler *et al.*, 2005), so that the frequency and relevance of MRI findings in women may be different from that in men. In this regard, less pronounced reductions in cerebellar volume and a lower incidence of the MCP sign has been reported in women with FXTAS compared to men (Adams *et al.*, 2007). Also, an absence of significant associations between reduced cerebellar volumes and increased FXTAS severity, and increased length of the CGG repeat expansion was reported in women, differently from men having FXTAS (Adams *et al.*, 2007).

Conventional MRI, as including T1- and T2- weighted MR images, suffers from several limitations as a tool to investigate patients with a neurodevelopmental disorder that develop a neurodegenerative process later in life, as happens in the *FMR1* premutation/FXTAS condition. Today, with the advent of high field strength MRI, and stronger gradients, there are more specific sequences such as susceptibility- or gradient-echo-weighted MR-images, which can provide more specific assessment of mechanisms underlying neuronal degeneration, such as iron deposition. Iron deposition is seen with normal aging in specific brain structures. Up to date, increased and/or iron deposition in certain brain structures has not been demonstrated among FXTAS patients, to the best of our knowledge, but this may only be a question of time or of the cohorts being studied.

Also, recently FLAIR imaging has somehow substituted T2-weighted imaging for the assessment of white matter and brainstem T2- signal changes. Findings on FLAIR images

may not be exactly the same as seen on T2-weighted images, and thus, more evidence is needed with these more recent techniques. Finally, Arterial Spin Labeling, a non-invasive MRI method that allows detection of specific perfusion patterns of involvement linked to brain metabolism, is currently being applied to several neurodegenerative brain conditions, and may also be useful in the context of *FMR1* premutation/FXTAS.

## 6. Advances in neuroimaging in FXTAS and future needs

The advancing field of Neuroradiology, and particularly of MRI, has provided insight in neurodegenerative conditions. Typical MRI findings have been described, that allow prompt and more precise characterization of many conditions, such as FXTAS. Additionally, MRI has provided non-invasive markers of disease, which may be potentially useful in early and differential diagnosis, in prognosis, and eventually in therapeutic response. This is the case for triplet expansion, genetic conditions, such as Huntington's disease (HD), which offers some similarities to FXTAS. Originally, conventional MRI was used and typical MRI findings were described in HD, but recently, more sophisticated imaging methods, such as MR-Spectroscopy, have been applied not only to patients with HD, but also to asymptomatic carriers, searching for markers for early diagnosis and conversion to disease. In this regard, metabolic (Gomez-Anson *et al.*, 2007) and structural (Gomez-Anson *et al.*, 2009) MR-alterations in the prefrontal regions of asymptomatic HD carriers have been recently described, linked to neuropsychological dysfunction, and proposed as early markers for disease, related to underlying pathology. Knowledge in field of *FMR1* premutation carriers, who will eventually develop FXTAS, may follow a similar course. Although until now, mainly conventional MRI features have been described, there is growing evidence from more sophisticated MR techniques, which has and will continue adding knowledge in the field.

Advances in Neuroimaging in *FMR1* premutation/FXTAS may, perhaps, come from two distinct contributions. Firstly, more recent developments in MR are being applied to these patients. This is particularly the case of functional MR techniques, which not only provide information about structural brain changes in these patients, but also of brain functioning. As an example, MR-Spectroscopy (MRS) is a technique which allows studying non-invasively brain metabolism in vivo. Metabolic information can be linked to cellular pools, thus to histopathological changes, and to neuropsychological and clinical features. There is very little evidence about MRS in FXTAS. However, MRS changes indicating neuronal loss/dysfunction have been described in the pons of patients with FXTAS having the typical MCP sign on conventional imaging (Ginestroni *et al.*, 2007). More recent evidence has shown altered metabolism on MRS in the middle cerebellar peduncles of patients with *FMR1* premutation, which may be more marked in FXTAS (Gomez-Anson *et al.*, abstract 2007). These findings indicate a potential usefulness of MRS, adding in differential diagnosis of patients with ataxias, and being able, perhaps, to identify those patients that will develop FXTAS. However, more longitudinal evidence and larger cohorts of carriers and patients from multicentric studies are needed in this regard. Functional MRI may also prove to be useful in the field of, as it has been recently demonstrated that there is altered prefrontal cortex activity underlying executive and memory deficits in permuted carriers and patients (Hashimoto *et al.*, 2011).

Secondly, contributions from more sophisticated postprocessing tools will certainly add during the near future in the field. In this context, assessment and quantification of volume changes in the brain is now feasible non-invasively using MRI and volumetric techniques. One of these techniques, the Voxel Based Morphometry method (VBM) allows



determination of focal changes of grey and white matter density in the brain on MRI (Ashburner *et al.*, 2000). However, the evidence of volumetric studies in FXTAS and premutation carriers is scarce (Gomez-Anson *et al.*, 2007; Hashimoto *et al.*, 2011; Moore *et al.*, 2004b). Automated postprocessing tools are also being currently applied to study regional changes of volume in the brain, which may be specific to a condition, and related to certain cognitive tasks. This is the case of the hippocampus and memory impairment, which are relevant in Alzheimer’s disease, for example (Sanchez-Benavides *et al.*, 2010). Evidence of the application of these tools to research in the FXTAS condition is still lacking. The potential usefulness of neuroimaging in providing insight in FXTAS becomes more evident as cognitive decline in FXTAS is resulting in an important field of research. As the phenotypic spectrum has expanded among *FMR1* premutated carriers, and FXTAS patients, psychiatric and cognitive disturbances are increasingly being recognized as relevant features

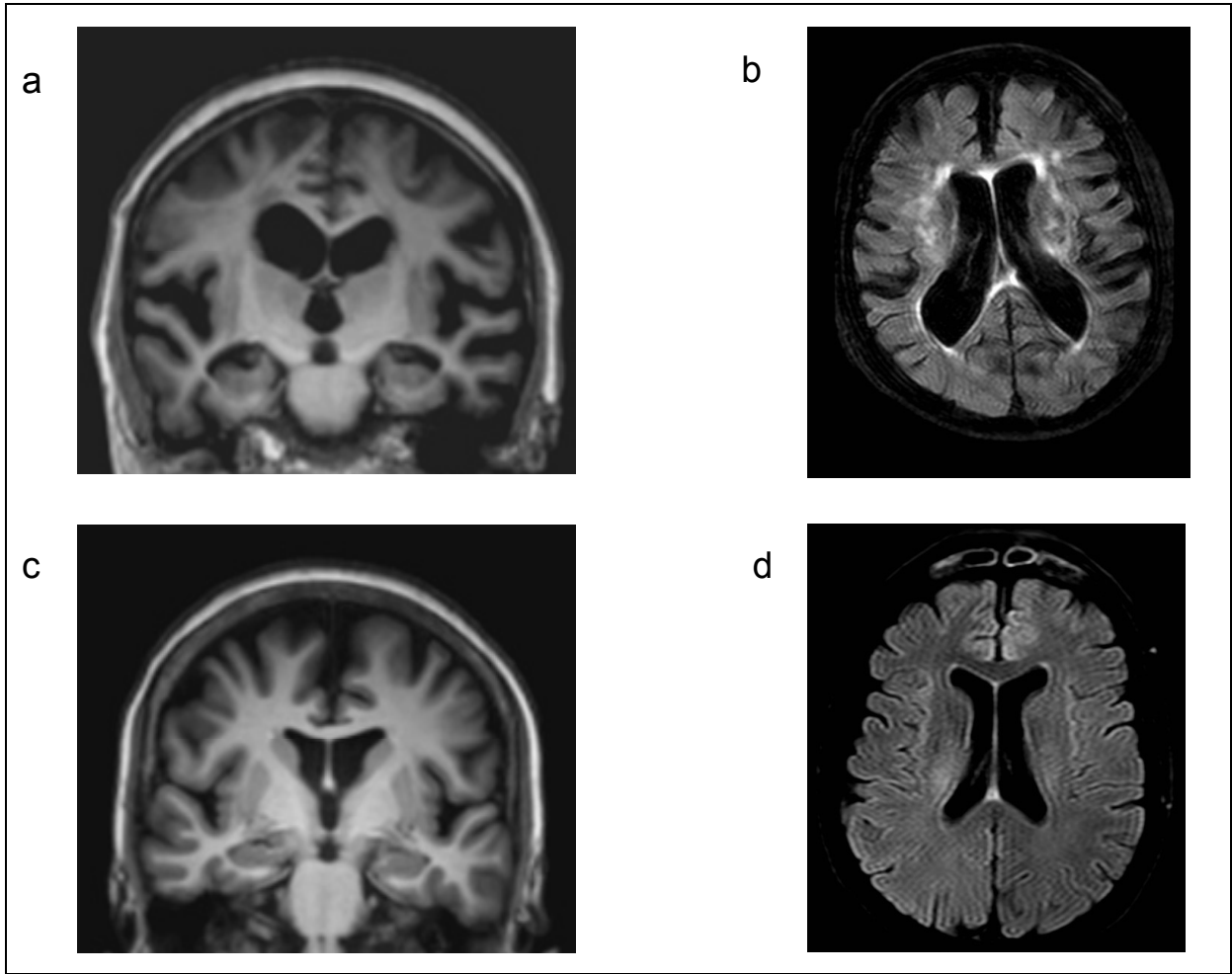


Fig. 3. Magnetic resonance imaging findings of two female patients with dementia and FXTAS. A) Coronal T1-weighted, 3D MPRAGE MR image of patient 1 shows asymmetrical frontal, and bilateral, symmetrical, medial temporal atrophy. B) Axial 3D FLAIR of patient 1 shows marked hyperintensities in the cerebral white matter. C) Coronal T1-weighted, 3D MPRAGE MR image of patient 2 shows moderate cerebral atrophy involving the frontal lobes, while the medial temporal lobes appeared normal.; K) Axial 3D FLAIR of patient 2 shows no marked HI in the white matter.



(Sevin *et al.*, 2009). Cognitive decline in FXTAS usually occurs in men, after a long duration of extrapyramidal disturbances, but it may also occur in women. Typically in men, a clinical picture similar distinct from Alzheimer's disease (Seritan *et al.*, 2008), and more similar to patients with fronto-temporal lobar degeneration occurs (FTLD) (Burgeois *et al.*, 2009).

Although there is little evidence from MRI in these patients, particularly in women (Al Hinti *et al.*, 2007; Karmon *et al.*, 2008), more recently, two cases of mother-to-daughter transmission were reported (Rodriguez-Revenge *et al.*, 2010). In these two female patients with FXTAS and dementia, a radiological pattern of brain atrophy resembling that of patients with FTLD, was described. However, radiological heterogeneity may be large in this condition, as shown by the fact that prominent white matter hyperintensities were only seen in one case, as had been previously described (Al Hinti *et al.*, 2007; Karmon *et al.*, 2008), the second case lacking these, as well as hippocampal atrophy (Fig. 3).

There is very recent evidence about the use of VBM for studying the brain changes of *FMR1* premutated carriers, with and without FXTAS, and their correlation to neuropsychology (Hashimoto *et al.*, 2011). In this study, patients with FXTAS demonstrated a distinct pattern of grey matter volume loss, involving multiple cortical and subcortical regions. This included different parts of the cerebellum, as well as of the medial surface of the brain, including the dorsomedial prefrontal cortex, anterior cingulate and precuneus. Additional volume loss was seen in the lateral prefrontal cortex, orbitofrontal cortex, amygdala, and insula. More interestingly, there were significant correlations between grey matter loss in different brain regions, behavioral scales, and CGG repeats (Hashimoto *et al.*, 2011).

## 7. Conclusion

FXTAS is a relatively new disorders that is currently regarded as a late-onset neurodegenerative disorder; however, the underlying pathogenic process may begin very early in life. It is essential to fathom the molecular mechanism of FXTAS and to increase our knowledge of disease pathology in order to understand of FXTAS disease progression. Although the RNA gain-of-function hypothesis for FXTAS is well accepted, further analysis of the pathogenic effect of the expanded CGG-repeat *FMR1* mRNA are still required. A better understanding of the molecular basis of FXTAS should shed light on therapeutic approaches that will combat neurodegeneration and improve cognitive and motor performance. Furthermore, it can also help unraveling common mechanisms in other neurodegenerative diseaser which will bring hope to treatments more effective and specific to the underlying dysfunction.

MRI findings in FXTAS patients classically include middle cerebellar and white matter hyperintensities, as well as cerebellar, pontine and brain atrophy. Neuroimaging, and particularly MR techniques, offer an excellent opportunity to gain insight into the FXTAS condition. In vivo biomarkers may be identified non-invasively, which may be potentially useful in improving recognition, and early characterization of patients with FXTAS, so that treatment strategies can be developed and applied.

As the prevalence of premutated alleles is relatively high in general population, FXTAS may represent one of the more common monogenic causes of tremor, ataxia, and dementia. For this reason, it is probably that many carriers with FXTAS are being seen by a clinical

specialist without awareness of the underlying genetic basis for the symptoms. The early diagnosis of those patients not only benefits themselves but also the rest of the family that should be advised for the FXS.

## 8. Acknowledgments

This work has received financial support from grant PI09/0413 and FISS PI/770 both financed by “Instituto Carlos III”. We would like to acknowledge GIRMOGEN and the Catalan Association of Fragile X syndrome as well as all FXS families that collaborate with us. The CIBER de Enfermedades Raras is an initiative of the ISCIII

## 9. References

- Adams, JS., Adams, PE., Nguyen, D., Brunberg, JA., Tassone, F., Zhang, W., Koldewyn, K., Rivera, SM., Grigsby, J., Zhang, L., DeCarli, C., Hagerman, PJ., & Hagerman, RJ. (2007). *Neurology* 28,69 ,851-859.
- Al-Hinti, JT., Nagan, N., & Harik, SI. (2007). *Alzheimer Disease & Associated Disorders* 21,262-264.
- Ashburner, J., & Friston, KJ. (2000). *Neuroimage* 11,805-821.
- Bacalman, S., Farzin, F., Bourgeois, JA., Cogswell, J., Goodlin-Jones, BL., Gane, LW., Grigsby, J., Leehey, MA., Tassone, F., & Hagerman, RJ. (2006). *Journal of Clinical Psychiatry* 67,87-94.
- Bassell, GJ., & Warren, ST. (2008). *Neuron* 60,201-214.
- Bennetto, L; Pennington, BF; Porter, D; Taylor, AK; Hagerman, RJ. (2001). *Neuropsychology* 15,290-299.
- Berry-Kravis, E., Potanos, K., Weinberg, D., Zhou, L., & Goetz, CG. (2004). *Annals of Neurology* 57,144-147.
- Bontekoe, CJ; Bakker, CE; Nieuwenhuizen, IM; van der Linde, H; Lans, H; de Lange, D; Hirst, MC; & Oostra, BA. (2001). *Human Molecular Genetics* 10,1693-1639.
- Bourgeois, JA., Coffey, SM., Rivera, SM., Hessler, D., Gane, LW., Tassone, F., Greco, C., Finucane, B., Nelson, L., Berry-Kravis, E., Grigsby, J., Hagerman, PJ., & Hagerman, RJ. (2009). *Journal of Clinical Psychiatry* 70,852-862.
- Brunberg J., Jacquemont S., Hagerman RJ., Berry-Kravis, E., Grigsby, J., Leehey, M., Tassone, F., Brown, T., Greco, C., & Hagerman. PJ. (2002). *American Journal of Neuroradiology*.23,1757-1766.
- Brussino, A., Gellera, C., Saluto, A., Mariotti, C., Arduino, C., Castellotti, B., Camerlingo, M., de Angelis, V., Orsi, L., Tosca, P., Migone, N., Taroni, F., & Brusco, A. (2005) *Neurology* 64,145-147.
- Coffey, SM., Cook, K., Tartaglia, N., Tassone, F., Nguyen, DV., Pan, R., Bronsky, HE., Yuhas, J., Borodyanskaya, M., Grigsby, J., Doerflinger, M., Hagerman, PJ., & Hagerman, RJ. (2008) *American Journal of Medical Genetics Part A* 146,1009-1016.
- Cohen, S., Masyn, K., Adams, J., Hessler, D., Rivera, S., Tassone, F., Brunberg, J., DeCarli, C., Zhang, L., Cogswell, J., Loesch, D., Leehey, M., Grigsby, J., Hagerman, PJ., & Hagerman, R. (2006). *Neurology* 67,1426-1431.
- Galloway, JN., & Nelson, DL. (2009) *Future Neurology* 4,785.

- Garcia-Arocena, D., & Hagerman PJ. (2010). *Human Molecular Genetics* 19,R83-R89.
- Ginestroni, A., Guerrini, L., Della Nave, R., Tessa, C., Cellini, E., Dotti, MT., Brunori, P., De Stefano, N., Piacentini, S., & Mascalchi, M. (2007). *AJNR - American Journal of Neuroradiology*. 28,486-488.
- Gómez-Ansón, B., Alegret, M., Muñoz, E., Sainz, A., Monte, GC., & Tolosa, E. (2007). *Neurology* 68,906-910.
- Gómez Ansón, B., Monte, GC., Rotger, R., Rodriguez-Revenge, L., Mila, M., & Capurro, S. (2007). MR characterization of premutated carriers of the fragile X syndrome: a VBM and 1H-MRS study. *Proceedings of Congress of European Society of Neuroradiology (ESNR)*, Genova, September 2007.
- Gómez-Ansón, B., Alegret, M., Munoz, E., Monte, GC., Alayrach, E., Sanchez, A., Boada, M., & Tolosa, E. (2009). *Parkinsonism & Related Disorders* 15,213-219.
- Greco, CM., Hagerman, RJ., Tassone, F., Chudley, AE., Del Bigio, MR., Jacquemont, S., Leehey, M., & Hagerman, PJ. (2002). *Brain* 125,1760-1771.
- Greco, CM., Berman, RF., Martin, RM., Tassone, F., Schwartz, PH., Chang, A., Trapp, BD., Iwahashi, C., Brunberg, J., Grigsby, J., Hessel, D., Becker, EJ., Papazian, J., Leehey, MA., Hagerman, RJ., & Hagerman, PJ. (2006). *Brain* 129:243-255.
- Grigsby, J., Brega, AG., Leehey, MA., Goodrich, GK., Jacquemont, S., Loesch, DZ., Cogswell, JB., Epstein, J., Wilson, R., Jardini, T., Gould, E., Bennett, RE., Hessel, D., Cohen, S., Cook, K., Tassone, F., Hagerman, PJ., & Hagerman, RJ. (2007). *Movement Disorders* 22,645-650.
- Grigsby, J., Brega, AG., Engle, K., Leehey, MA., Hagerman, RJ., Tassone, F., Hessel, D., Hagerman, PJ., Cogswell, JB., Bennett, RE., Cook, K., Hall, DA., Bounds, LS., Paulich, MJ., & Reynolds, A. (2008). *Neuropsychology* 22,48-60.
- Hagerman, RJ., Leehey, M., Heinrichs, W., Tassone, F., Wilson, R., Hills, J., Grigsby, J., Gage, B., & Hagerman, PJ. (2001). *Neurology* 57,127-130.
- Hagerman, RJ. (2002). Physical and behavioral phenotype, In: *Fragile X Syndrome: Diagnosis, treatment and research* Hagerman RJ & Hagerman PJ (3rd edition). The Johns Hopkins University Press, Baltimore, MD.
- Hagerman, PJ., & Hagerman, RJ. (2004). *The American Journal of Human Genetics* 74,805-816.
- Hashimoto, RI., Backer, KC., Tassone, F., Hagerman, RJ., & Rivera, SM. (2011). *Movement Disorder* 11.
- Hessel, D., Tassone, F., Loesch, DZ., Berry-Kravis, E., Leehey, MA., Gane, LW., Barbato, I., Rice, C., Gould, E., Hall, DA., Grigsby, J., Wegelin, JA., Harris, S., Lewin, F., Weinberg, D., Hagerman, PJ., & Hagerman, RJ. (2005). *American Journal of Medical Genetics Part A* 139,115-121.
- Iwahashi, CK., Yasui, DH., An, HJ., Greco, CM., Tassone, F., Nannen, K., Babineau, B., Lebrilla, CB., Hagerman, RJ., & Hagerman, PJ. (2006). *Brain* 129,256-271.
- Jacquemont, S., Hagerman, RJ., Leehey, M., Grigsby, J., Zhang, L., Brunberg, JA., Greco, C., Des Portes, V., Jardini, T., Levine, R., Berry-Kravis, E., Brown, WT., Schaeffer, S., Kissel J., Tassone, F., & Hagerman, PJ. (2003). *The American Journal of Human Genetics* 72,869-878.


- Jacquemont, S., Hagerman, RJ., Leehey, MA., Hall, DA., Levine, RA., Brunberg, JA., Zhang, L., Jardini, T., Gane, LW., Harris, SW., Herman, K., Grigsby, J., Greco, CM., Berry-Kravis, E., Tassone, F., & Hagerman, PJ. (2004a). *JAMA, the Journal of the American Medical Association* 291,460-469.
- Jacquemont, S., Farzin, F., Hall, D., Leehey, M., Tassone, F., Gane, L., Zhang, L., Grigsby, J., Jardini, T., Lewin, F., Berry-Kravis, E., Hagerman, PJ., & Hagerman, RJ. (2004b). *American Journal Of Mental Retardation* 109,154-164.
- Jacquemont, S., Hagerman, R., Hagerman, PJ., Leehey, MA. (2007). *The Lancet Neurology* 6,45-55.
- Johnston, C., Eliez, S., Dyer-Friedman, J., Hessel, D., Glaser, B., Blasey, C., Taylor, A., & Reiss, A. (2001). *American Journal of Medical Genetics* 103,314-319.
- Kamm, C., Healy, DG., Quinn, NP., Wüllner, U., Moller, JC., Schols, L., Geser, F., Burk, K., Børglum, AD., Pellecchia, MT., Tolosa, E., del Sorbo, F., Nilsson, C., Bandmann, O., Sharma, M., Mayer, P., Gasteiger, M., Haworth, A., Ozawa, T., Lees, AJ., Short, J., Giunti, P., Holinski-Feder, E., Illig, T., Wichmann, HE., Wenning, GK., Wood, NW., Gasser, T., & European Multiple System Atrophy Study Group. (2005). *Brain* 128,1855-1860.
- Karmon, Y., & Gadoth, N. (2008). *Journal of Neurology, Neurosurgery & Psychiatry* 79,738-739.
- Kenneson, A., Zhang, F., Hagedorn, CH., & Warren, ST. (2001). *Human Molecular Genetics* 10,1449-1454.
- Ladd, PD., Smith, LE., Rabaia, NA., Moore, JM., Georges, SA., Hansen, RS., Hagerman, RJ., Tassone, F., Tapscott, SJ., & Filippova, GN. (2007). *Human Molecular Genetics* 16,3174-3187.
- Leehey, MA., Munhoz, RP., Lang, AE., Brunberg, JA., Grigsby, J., Greco, C., Jacquemont, S., Tassone, F., Lozano, AM., Hagerman, PJ., & Hagerman, RJ. (2003). *Archives of Neurology* 60,117-121.
- Leehey, MA., Berry-Kravis, E., Min, SJ., Hall, DA., Rice, CD., Zhang, L., Grigsby, J., Greco, CM., Reynolds, A., Lara, R., Cogswell, J., Jacquemont, S., Hessel, DR., Tassone, F., Hagerman, R., & Hagerman PJ. (2007). *Movement Disorders* 22,203-206.
- Macpherson, J., Waghorn, A., Hammans, S., & Jacobs, P. (2003). *Human Genetics* 112,619-620.
- Mankodi, A., Logigian, E., Callahan, L., McClain, C., White, R., Henderson, D., Krym, M., & Thornton, CA. (2000). *Science* 289,1769-1773.
- Mankodi, A., & Thornton, CA. (2002). *Current Opinion in Neurology* 15,545-552.
- Milà, M., Madrigal, I., Kulisevsky, J., Pagonabarraga, J., Gómez, B., Sánchez, A., & Rodríguez-Revilla, L. (2009). *Medicina Clínica* 133, 252-4.
- Moore, CJ., Daly, EM., Schmitz, N., Tassone, F., Tysoe, C., Hagerman, RJ., Hagerman, PJ., Morris, RG., Murphy, KC., & Murphy, DG. (2004a). *Neuropsychologia* 42,1934-1947.
- Moore, CJ., Daly, EM., Tassone, F., Tysoe, C., Schmitz, N., Ng, V., Chitnis, X., McGuire, P., Suckling, J., Davies, KE., Hagerman, RJ., Hagerman, PJ., Murphy, KC., & Murphy, DG. (2004b). *Brain* 127,2672-2681.



- Oberle, I., Rousseau, F., Heitz, D., Kretz, C., Devys, D., Hanauer, A., Boue, J., Bertheas, MF., & Mandel, JL. (1991). *Science* 252,1097-1102.
- Okamoto, J., Tokiguchi, S., Furusawa, T., Ishikawa, K., Quardery, AF., Shinbo, S., & Sasai S. (2003). *AJNR Am American Journal of Neuroradiology* 24,1946-1954.
- Oostra, BA., & Willemsen, R. (2003). *Human Molecular Genetics* 12,R249-R257.
- Oostra BA., & Willemsen R. (2009). *Biochimica et Biophysica Acta* 1790,467-477.
- Reiss, AL., Freund, L., Abrams, MT., Boehm, C., & Kazazian, H. (1993). *The American Journal of Human Genetics* 52,884-894.
- Riddle, JE., Cheema, A., Sobesky, WE., Gardner, SC., Taylor, AK., Pennington, BF., & Hagerman, RJ. (1998). *American Journal Of Mental Retardation* 102,590-601.
- Rife, M., Badenas, C., Mallolas, J., Jimenez, L., Cervera, R., Maya, A., Glover, G., Rivera, F., & Mila, M. (2003). *Genetic Testing* 7,339-343.
- Rodriguez-Revenge, L., Gómez-Anson, B., Muñoz, E., Jiménez, D., Santos, M., Tintoré, M., Martín, G., Brieva, L., & Milà, M. (2007). *Molecular Neurobiology* 35,324-328.
- Rodriguez-Revenge, L., Madrigal, I., Alegret, M., Santos, M., & Milà, M. (2008a). *Psychiatric Genetics* 18,153-155.
- Rodriguez-Revenge, L., Santos, MM., Sánchez, A., Pujol, M., Gómez-Anson, B., Badenas, C., Jiménez, D., Madrigal, I., & Milà, M. (2008b). *Genetic Testing* 12,135-138.
- Rodriguez-Revenge, L., Madrigal, I., Pagonabarraga, J., Xunclà, M., Badenas, C., Kulisevsky, J., Gomez, B., & Milà, M. (2009). *European Journal of Human Genetics* 17,1359-1362.
- Rodriguez-Revenge, L., Pagonabarraga, J., Gómez-Anson, B., López-Mourelo, O., Xunclà, M., & Milà, M. (2010). *Neurology* 75,1370-1376.
- Sánchez-Benavides, G., Gómez-Ansón, B., Sainz, A., Vives, Y., Delfino, M., & Peña-Casanova, J. (2010). *Psychiatry Research* 181,219-225.
- Sellier, C., Rau, F., Liu, Y., Tassone, F., Hukema, RK., Gattoni, R., Schneider, A., Richard, S., Willemsen, R., Elliott, DJ., Hagerman, PJ., & Charlet-Berguerand, N. (2010). *The EMBO Journal* 29,1248-1261.
- Seritan, AL., Nguyen, DV., Farias, ST., Hinton, L., Grigsby, J., Bourgeois, JA., & Hagerman, RJ. (2008). *American Journal of Medical Genetics Part B: Neuropsychiatric Genetics* 147,1138-1144.
- Sevin, M., Kutalik, Z., Bergman, S, Vercelletto, M., Renou, P., Lamy, E., Vingerhoets, FJ., Di Virgilio, G., Boisseau, P., Bezieau, S., Pasquier, L., Rival, JM., Beckmann, JS., Damier, P., & Jacquemont, S. (2009). *Journal of Medical Genetics* 46,818-824.
- Tan, H., Li, H., & Jin, P. (2009). *Neuroscience Letters* 466,103-108.
- Tassone, F., Hagerman, RJ., Taylor, AK., Gane, LW., Godfrey, TE., & Hagerman, PJ. (2000a). *The American Journal of Human Genetics* 66,6-15.
- Tassone, F., Hagerman, RJ., Taylor, AK., Mills, JB., Harris, SW., Gane, LW., & Hagerman, PJ. (2000b). *American Journal of Medical Genetics* 91,144-1152.
- Tassone, F., & Hagerman, PJ. (2003). *Cytogenetic and Genome Research* 100,124-128.
- Van Esch, H., Matthijs, G., & Fryns, JP. (2005). *Annals of Neurology* 57,932-933.
- Verkerk, AJ., Pieretti, M., Sutcliffe, JS., Fu, YH., Kuhl, DP., Pizzuti, A., Reiner, O., Richards, S., Victoria, MF., Zhang, FP., et al. (1991). *Cell* 65,905-914.



- Willemsen, R., Hoogeveen-Westerveld, M., Reis, S., Holstege, J., Severijnen, LA., Nieuwenhuizen, IM., Schrier, M., van Unen, L., Tassone, F., Hoogeveen, AT., Hagerman, PJ., Mientjes, EJ., & Oostra, BA. (2003). *Human Molecular Genetics* 12,949-959.
- Yu, S., Pritchard, M., Kremer, E., Lynch, M., Nancarrow, J., Baker, E., Holman, K., Mulley, JC., Warren, ST., Schlessinger, D; *et al.* (1991). *Science* 252,1179-1181.
- Zuhlke, Ch., Budnik, A., Gehlken, U., Dalski, A., Purmann, S., Naumann, M., Schmidt, M., Burk, K., & Schwinger, E. (2004). *Journal of Neurology* 251:1418-1419.



## **Neuroimaging - Clinical Applications**

Edited by Prof. Peter Bright

ISBN 978-953-51-0200-7

Hard cover, 576 pages

**Publisher** InTech

**Published online** 09, March, 2012

**Published in print edition** March, 2012

Modern neuroimaging tools allow unprecedented opportunities for understanding brain neuroanatomy and function in health and disease. Each available technique carries with it a particular balance of strengths and limitations, such that converging evidence based on multiple methods provides the most powerful approach for advancing our knowledge in the fields of clinical and cognitive neuroscience. The scope of this book is not to provide a comprehensive overview of methods and their clinical applications but to provide a "snapshot" of current approaches using well established and newly emerging techniques.

### **How to reference**

In order to correctly reference this scholarly work, feel free to copy and paste the following:

Laia Rodriguez-Revenga, Beatriz Gómez-Ansón, Esther Granell Moreno, Javier Pagonabarraga and Montserrat Mila (2012). Neuroimaging in Fragile X-Associated, Neuroimaging - Clinical Applications, Prof. Peter Bright (Ed.), ISBN: 978-953-51-0200-7, InTech, Available from:  
<http://www.intechopen.com/books/neuroimaging-clinical-applications/neuroimaging-in-fragile-x-associated-tremor-ataxia-syndrome-fxtas->

**INTECH**  
open science | open minds

### **InTech Europe**

University Campus STeP Ri  
Slavka Krautzeka 83/A  
51000 Rijeka, Croatia  
Phone: +385 (51) 770 447  
Fax: +385 (51) 686 166  
[www.intechopen.com](http://www.intechopen.com)

### **InTech China**

Unit 405, Office Block, Hotel Equatorial Shanghai  
No.65, Yan An Road (West), Shanghai, 200040, China  
中国上海市延安西路65号上海国际贵都大饭店办公楼405单元  
Phone: +86-21-62489820  
Fax: +86-21-62489821

© 2012 The Author(s). Licensee IntechOpen. This is an open access article distributed under the terms of the [Creative Commons Attribution 3.0 License](https://creativecommons.org/licenses/by/3.0/), which permits unrestricted use, distribution, and reproduction in any medium, provided the original work is properly cited.

IntechOpen

IntechOpen