

We are IntechOpen, the world's leading publisher of Open Access books Built by scientists, for scientists

6,900

Open access books available

186,000

International authors and editors

200M

Downloads

Our authors are among the

154

Countries delivered to

TOP 1%

most cited scientists

12.2%

Contributors from top 500 universities



WEB OF SCIENCE™

Selection of our books indexed in the Book Citation Index
in Web of Science™ Core Collection (BKCI)

Interested in publishing with us?
Contact book.department@intechopen.com

Numbers displayed above are based on latest data collected.
For more information visit www.intechopen.com



The Role of Magnetic Resonance Spectroscopy in the Diagnosis of Ring Enhancing Lesions

Eftychia Kapsalaki¹, Efstathios D. Gotsis⁴,
Ioannis Tsougos² and Konstantinos N. Fountas³

¹*Department of Radiology,*

²*Department of Medical Physics,*

³*Department of Neurosurgery,*

University Hospital of Larisa, School of Medicine, University of Thessaly, Larissa,

⁴*Diagnostic Center Euromedica, Athens,*
Greece

1. Introduction

Ring-enhancing intracranial lesions constitute a common and quite puzzling diagnostic dilemma. These lesions may present as solitary or multiple on a routine brain MRI, and are characterized by a contrast enhancing halo and a non enhancing center. The central part may present with low signal intensity on T1, and high signal intensity on T2 weighted images. They are usually surrounded by a variable amount of edema. They may be located anywhere in the brain, although the junctional zone of gray-white matter is their most common location [Omuroet al., 2006; Smirniotopoulos et al., 2007]. Their size may vary from a few millimetres to several centimetres.

The differential diagnosis of ring enhancing lesions is quite large. It may include neoplasms, infections, inflammatory processes, or vascular pathologies. The incidence of each pathological entity depends highly on the geographical region and the study population. It is well documented that infections and inflammatory processes are more common in developing countries, while neoplasms and demyelinating lesions are more frequent in developed countries. Clinical history is not always helpful in their differential diagnosis, since more than 50% of CNS infections may present without fever and no obvious inflicting incident. Moreover, other laboratory tests may not be able to help in their differential diagnosis. In addition, the presenting symptomatology and the clinical examination of these patients are non-specific and frequently overlapping, making thus the establishment of an accurate diagnosis quite difficult.

Routine brain MR imaging is very sensitive in the identification of ring enhancing lesions but it cannot distinguish between neoplastic and non neoplastic lesions, in a large percentage of these cases. Frequently, the differentiation of a tumor from an infection is quite difficult, based solely on conventional MRI. Therefore, advanced MR imaging

techniques as Diffusion Weighted Imaging (DWI), Perfusion Weighted Imaging (PWI), and proton Magnetic Resonance Spectroscopy ($^1\text{HMRS}$) have been employed in the differential diagnosis of these lesions, with variable success rates. These studies are employed in combination with conventional MRI as complimentary imaging tests, and may significantly increase its specificity.

In this chapter, the role of $^1\text{HMRS}$ in the differential diagnosis of ring enhancing lesions is going to be discussed. The basic principles of $^1\text{HMRS}$, as well as, the typical spectroscopic profiles of the most commonly encountered ring enhancing lesions, are also presented. Furthermore, the implementation of other MR advanced techniques as DWI and PWI along with $^1\text{HMRS}$ in the evaluation of patients harbouring ring enhancing lesions, are analyzed.

2. Basic principles of $^1\text{HMRS}$

Proton MR Spectroscopy ($^1\text{HMRS}$) is a noninvasive imaging technique that may contribute in the preoperative diagnosis of patients with MR ring enhancing lesions. $^1\text{HMRS}$ depends on a change in the resonance frequency of the nuclei within the molecules, regarding their chemical bonds, which is based on the chemical shift theory. The resonance frequency difference (chemical shift) is expressed as parts per million or ppm, a value that is independent of the amplitude of the external magnetic field. The value of the chemical shift provides information about the molecular group carrying the hydrogen nuclei, and thus it provides differentiation among several metabolites. Water peak is located at 4.7 ppm, and is much greater than the obtained signal from other hydrogen containing compounds typically identified in the brain parenchyma. Therefore, water signal needs to be suppressed for identifying any other metabolites. The reference frequency used, set at zero ppm, is that of tetra-methyl silane molecule $\text{Si}(\text{CH}_3)_4$, which is symmetrical and has a single proton resonance.

In order to perform in vivo $^1\text{HMRS}$, a strong magnetic field of at least 1.5T is required. It is generally accepted that, the higher the magnetic field strength, the more metabolites can be identified. Specific sequences for spectroscopic signal acquisition are either Single Voxel Spectroscopy (SVS), which receives the spectrum from a single voxel only, or Chemical Shift Imaging (CSI), which measures spectra in projection, on a slice (2D CSI), or a volume (3D CSI).

3. Normal brain metabolites

Proton MRS obtains information about brain tissue metabolism, which cannot be performed by conventional MRI scans [Wilson et al., 2009]. The principal metabolites, which are most commonly identified and evaluated in brain $^1\text{HMRS}$, and their characteristic frequencies and concentrations, are summarised in **table 1**.

At a first glance, a normal brain spectrum contains five to ten resonance peaks (**figure 1**). *N-Acetyl-Aspartate* (NAA) is considered to be a unique neuronal marker, reflecting the number of intact neurons in the gray matter, and the density of intact axons in the white matter [Majos et al., 2004]. In general, reduction of NAA is produced by benign and malignant lesions in various proportions, and is indicative of normal neuronal tissue destruction. More specifically, NAA concentration decreases may occur with neuronal dysfunction caused by ischemia, trauma, inflammation, infection, tumor, neurodegenerative processes or reactive gliosis. Therefore, NAA is considered to be a highly sensitive but not specific marker.

Choline (Cho) constitutes an essential compound of cellular membranes, and is considered to be a sensitive marker of cellular membrane metabolism [Miller et al., 1996]. Hence, variation in choline represents a wide range of abnormalities reflecting cell membrane destruction. Characteristically, tumors, inflammatory processes, demyelinating processes, and hypoxia show increased concentrations of Cho. Contrariwise, the concentration of Cho is decreased in cerebral abscesses.

Metabolite	Frequency (ppm) / Cerebral Concentration (mmol/kg)	Physiological Role
<i>N-Acetyl-Aspartate(NAA)</i>	2.02 ppm / 7.9-16.6 mmol/kg	Neuronal cell marker.
<i>Choline (Cho)</i>	3.2 ppm / 0.9-2.5 mmol/kg	Marker of cell membrane metabolism.
<i>Creatine / Phosphocreatine (Cr)</i>	3.0 ppm / 5.1-10.6 mmol/kg	Compounds related to energy metabolism.
<i>Alanine(Ala)</i>	1.5 ppm / 0.2-1.4 mmol/kg	Is characteristic of meningeal tumors
<i>Lipids (Lip)</i>	0.9, 1.4 ppm / >1.0 mmol/kg	Membrane breakdown product.
<i>Lactate (Lac)</i>	1.33 ppm / 0.4 mmol/kg	A product of anaerobic glycolysis.
<i>Myo-inositol (mI)</i>	3.6 ppm / 3.8-8.1 mmol/kg	Glial Marker
<i>Glutamate-Glutamine ("Glx")</i>	2.1-2.4 ppm /	Intracellular Neurotransmitter Markers
<i>γ-amino-butyric acid ("GABA")</i>	1.3-12.6 mmol/kg	
<i>Acetate</i>	1.9 ppm	Characteristic in abscess
<i>Succinate / Pyruvate</i>	2.4 ppm	Characteristic in abscess

Table 1. Summary of the principal metabolites that are most commonly evaluated in Magnetic Resonance Spectroscopy (MRS)

Total Creatine (Cr) is a composite peak from the methyl and methylene protons of Cr and phosphorylated creatine, (PCr). The concentration of total creatine was thought to be relatively constant in the brain. However, with the development of quantitative MRS analysis techniques, it has been demonstrated that the concentration of total Cr is not constant. It has been shown that Cr concentrations may vary among different brain regions and among various pathological entities, thus, the usage of Cr as a reference signal should be applied with extreme caution [Howe et al., 2003]. The concentration of Cr is reduced in tumors and hypoxia, while Cr is totally absent in cerebral abscesses.

Lipids are normally absent from a normal brain MR spectrum, and their appearance represents necrosis. Increased concentrations of lipids may be observed in high grade primary and metastatic tumors, but also in abscesses and all necrotic lesions [Gotsis et al., 1996].

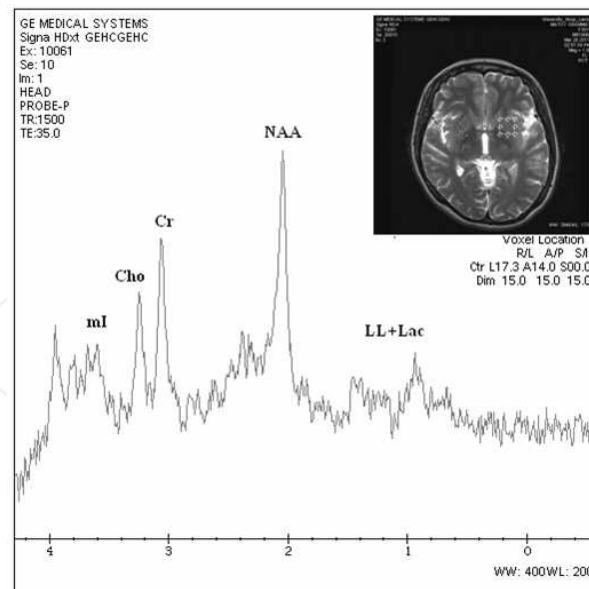


Fig. 1. Typical normal brain MR Spectrum showing the concentrations of Myoinositol (mI), Choline (Cho), Creatines (Cr), N-Acetyl-Aspartate (NAA), lipids (lip) and lactate (Lac)

Lactate signal appears in the same region of proton MR spectrum as lipids, therefore, it may be difficult to be distinguished. Lactate represents a product of anaerobic glycolysis [Barker et al., 1994; Negendank et al., 1996]. Its concentration is increased in ischemia, but also in high grade gliomas, as well as in pyogenic abscesses.

Myoinositol is a rather complex sugar alcohol, which gives rise to four groups of resonances. Its exact function is not completely known, although it has been proposed as a glial marker [Kallenberg et al., 2009]. Its concentration is reduced in high grade gliomas, but is also identified in meningiomas and demyelinating lesions.

Alanine peak appears near, and is often overlapped, by the lipids peak. It represents a discriminating metabolite of tumors of meningeal origin [Shino et al., 1999], but it is also identified in pyogenic anaerobic abscesses and cysticercosis [Kapsalaki et al., 2008]. Aminoacids (acetate and succinate) are not identified in a normal brain spectrum. Their presence is characteristic of brain abscesses.

In a routine clinical spectroscopic study, analysis of the obtained spectrum consists of measurement of the absolute concentrations of the identified metabolites, and calculation of the concentration ratios of the abovementioned metabolites. The most commonly used ratios include NAA/Cr, Cho/Cr, and NAA/Cho. Analysis of the accumulated data provides a characteristic metabolic profile, assigned to specific pathological entities.

4. Technical limitations of ^1H MRS

The clinical use of proton MR spectroscopy presents several technical limitations and pitfalls [Castillo et al., 1996; Fountas et al., 2000; Preul et al., 1996; Rand et al., 1999; Shukla-Dave et al., 2001]. Proton MRS lasts approximately 15 min and requires the patient's cooperation for avoiding motion artifacts. In single voxel MRS, the obtained region of interest should be appropriately placed at the center of the studied lesion, to avoid signal contamination from the surrounding tissues [Kimura et al., 2001]. It has been reported that even the slightest malpositioning of the voxel may result in up to 50% signal contamination of the obtained

spectrum, which may result in misinterpretation of the obtained spectroscopic study and subsequent imaging misdiagnosis. Moreover, calcifications, necrotic areas, and adjacent bony structures should be meticulously excluded from the obtained spectrum. Despite the recent advances in commercially available MRS software packages, the method remains operator dependent, and its accuracy is associated with the experience of the performing spectroscopist and the involved neuroradiologist.

5. Characteristic MR Spectroscopic profiles of the most common ring enhancing lesions

5.1 High grade astrocytomas

Proton MRS provides information regarding the metabolic profile of a glioma indicating the concentrations of various metabolites in the lesion. The commonly identified spectrum of a high grade glioma in proton MRS presents reduced concentration of NAA, because of destruction of normal neurons, markedly elevated concentrations of Cho due to exponentially increasing cellular populations and increased cell membrane turnover, and decreased Cr due to a major shift in the utilized cellular metabolic pathways. In regard to the commonly calculated metabolic ratios, the higher the Cho/NAA ratio is, the higher the astrocytoma grade. Therefore, ¹HMRS may suggest the area of highest malignancy within a non-homogenous glioma and accurately guide an open or stereotactic surgical biopsy. Lac appears infrequently in all grades of astrocytomas. Lipids are detected in high quantity in necrotic gliomas, in the area of the necrosis (figure 2).

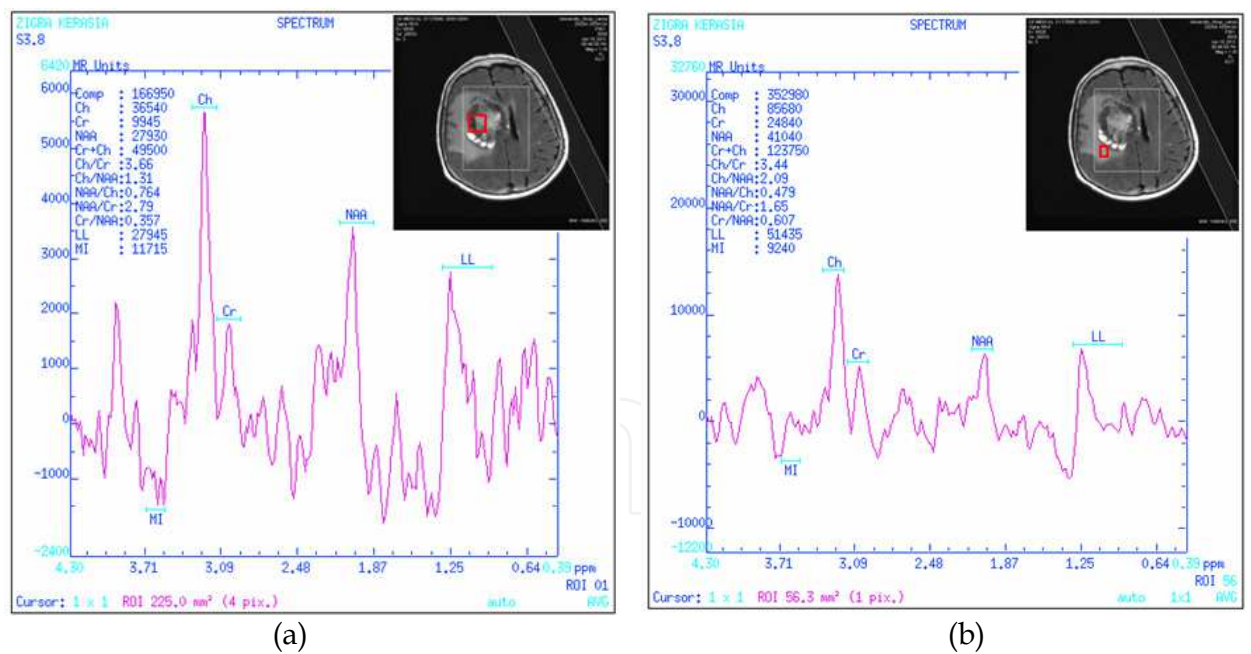


Fig. 2. a: Proton MR Spectrum of a high grade tumor. DD includes glioblastoma and metastatic lesion. 2b: The presence of increased concentration of Cho in the surrounding brain edema is suggestive of an infiltrative lesion, as a glioma versus a metastatic lesion.

It is well known that gliomas are highly infiltrating brain tumors, and their borders are typically ill-defined and cannot be accurately identified during their surgical removal [Croteau et al., 2001; Fountas et al., 2004; Mikkelsen & Edvardsen, 1995]. Performing MRS in

the surrounding edema may facilitate the identification of the glioma borders, and detect the presence and the extent of infiltration of a glioma. The identification of increased Cho and decreased NAA in the surrounding edema is indicative of infiltration, and is not characteristic of other ring enhancing lesions.

5.2 Metastatic lesions

The spectra of a ring enhancing metastatic tumor characteristically present very high concentrations of lipids, which are most probably associated with the presence of necrotic areas. Choline levels may also be elevated due to increased cell membrane destruction and turnover. However, the spectra of high grade gliomas and metastatic ring enhancing lesions are not easily distinguished [Burtscher et al., 2000; Opstad et al., 2004]. In such cases, spectra from the surrounding edema may provide additional important information. If normal concentrations of Cho and NAA are measured in a ring-enhancing lesion, this is more likely to be a metastatic lesion. Moreover, in metastatic lesions there is almost no Cr peak identified, which is not the case in high grade gliomas. (figure 3)

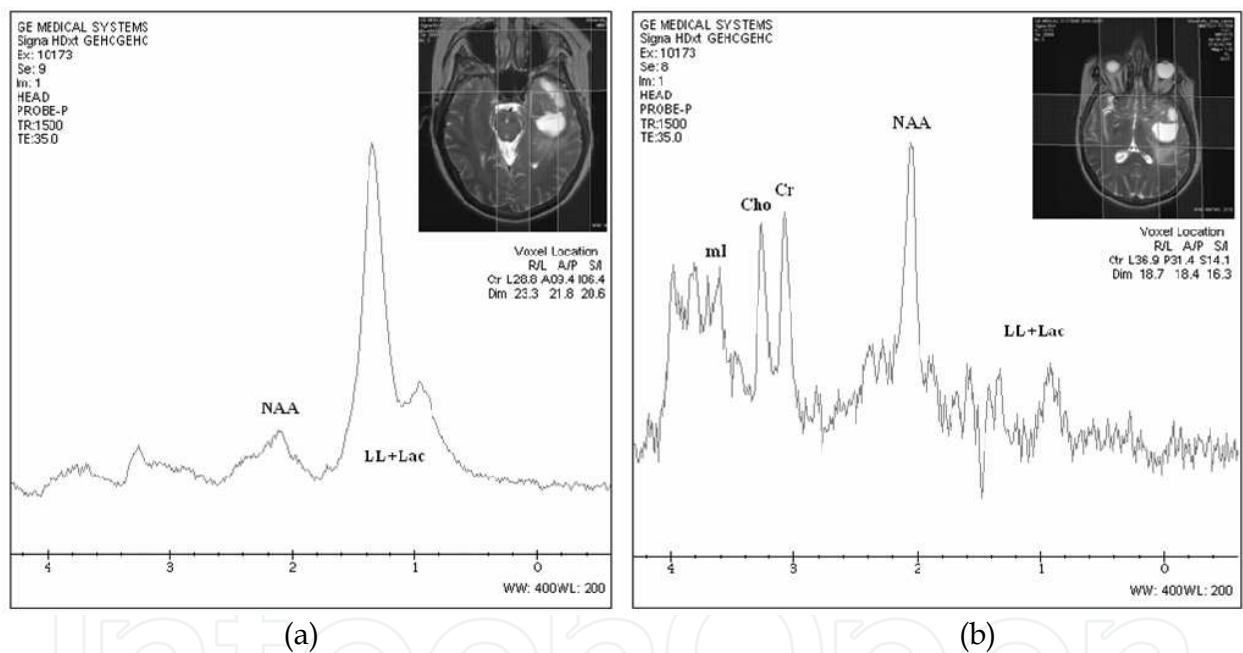


Fig. 3. a: The obtained spectrum demonstrates a very high peak representing severely increased concentration of lipids, which compresses all other metabolites, and suggests a highly necrotic lesion. Differential diagnosis between metastasis and glioma in this case is not possible. 3b: A normal spectrum of the surrounding brain edema suggests that the lesion is more compatible with a metastatic rather than an infiltrative tumor (glioma).

5.3 Recurrent astrocytomas versus post-radiation necrosis

Tumor recurrence and radiation-induced necrosis have similar MRI characteristics, and their distinction is usually difficult based solely on conventional MRI. Positron Emission Tomography (PET) has been suggested for differentiating between tumor recurrence and post-radiation necrosis [Kim et al., 2010; Tsuyuguchi et al., 2003] However, PET is a quite expensive imaging modality, with very limited distribution in clinical centers. Nevertheless,

¹HMRS has a significant role in their differentiation, considering that in a recurrent glioma the presence of Cho with increased concentration is identified, and the Cho/Cr and Cho/NAA ratios are significantly increased, with absolute values higher than 1.76 [Weybright et al., 2005; Schlemmer et al., 2002]. On the contrary, in cases of post-radiation necrosis, there is a marked reduction in the concentrations of all normally detected metabolites, along with a marked increase of lipids concentration. A study by Tarnawski and coworkers [Tarnawski et al., 2002] indicates that ¹H-MRS has a clear prognostic value for predicting survival in gliomas, and provides a clear diagnosis of recurrence following radiation therapy. In the presence of inflammation, increased levels of Cho may be detected. In such cases, differentiation between radiation necrosis and tumor recurrence with ¹HMRS alone is almost impossible. Other imaging modalities need to be combined, as perfusion MRI.

5.4 Abscesses

Cerebral abscesses contain no normal neurons and no membranous structures in their necrotic lesional center (Fountas et al., 2000; Lai et al., 2005). Therefore, no peaks of NAA, Cr, or Cho should be detected. A typical abscess spectrum shows the presence of cytosolic amino acids (leucine, isoleucine, and valine) [Garg et al, 2004; Kadota et al., 2001; Lai et al., 2002; Remy et al.,1995; Tsui et al., 2002], which are the products of proteolysis caused by enzymes released from neutrophil cells. Because these metabolites have never been detected in neoplasms, their detection is strongly indicative of a cerebral abscess [Kapsalaki et al., 2008]. Lactate is also detected in a large number of cerebral abscesses (figure 4).

Proton MR spectroscopy may also contribute in the identification of the causative organism of an abscess [Lai et al. 2002]. *Anaerobic microbial agents* are characterized by the presence of lactate, cytosolic amino acids, alanine, acetate, succinate, and lipids. *Aerobes and facultative anaerobes* are characterized by the presence of lactate, cytosolic amino acids, and the occasional presence of lipids. *Streptococcal abscesses* are characterized by the presence of lactate, while *Staphylococcal* infections are associated with the presence of lipids and lactate

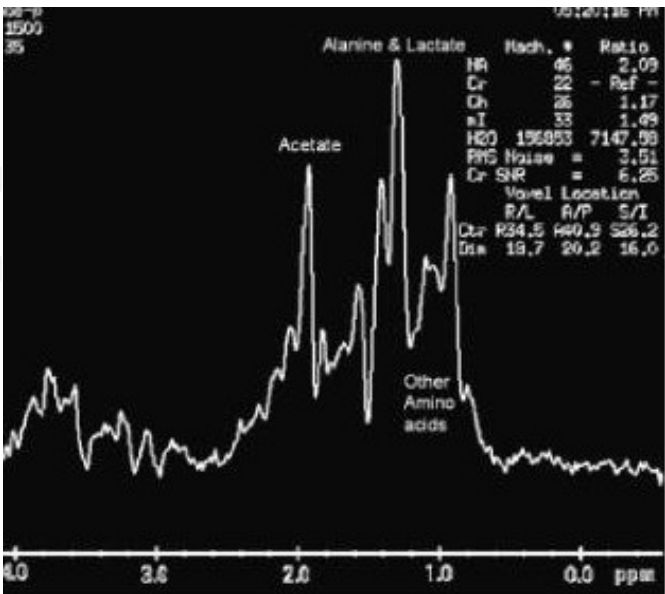


Fig. 4. Characteristic MR spectrum of an abscess. Note the absence of Cho, Cr, and NAA and also the increased concentrations of various aminoacids (acetate, alanine, lactate).

[Himmelreich et al., 2005]. It is apparent that identification of the etiologic factor of an abscess contributes significantly in its prompt and timely treatment. Moreover, ¹HMRS may contribute in the evaluation of the evolution and treatment response of a cerebral abscess. Sequential spectroscopic analysis of a brain abscesses may detect changes in the concentrations of the initially detected metabolites, providing thus a non-invasive methodology for evaluating the evolution of a cerebral abscess, and also its response to the administered antibiotic treatment.

5.5 Subacute infarct

Markedly elevated lactate is the key spectroscopic feature of cerebral hypoxia and ischemia, because of a major metabolic shift to anaerobic glycolysis. Choline is also elevated, with variable concentrations, while NAA and Cr concentrations are reduced. If cerebral infarction ensues, concentration of lipids will also increase. Furthermore, additional MR based advanced imaging modalities, such as Diffusion and Perfusion Weighted Imaging, may significantly contribute in the differential diagnosis in these cases [Parsons et al., 2000]

5.6 Demyelination

Proton MRS is a very useful tool in evaluating solitary tumefactive multiple sclerosis (MS) lesions. In acute MS lesions inflammation is the initial pathological change, while in more chronic lesions demyelination occurs. Proton MRS may be a quite sensitive imaging modality for evaluating axonal damage. At the initial presentation of MS, a typical spectrum shows decreased concentration of NAA, increased Choline and myo-inositol (MI) concentrations, and elevated concentration of Lactate, due to inflammation. With progression of an MS plaque, ¹HMRS shows normalization of MI and Lac levels, while Cho and NAA may remain unchanged. Thus, an MS spectrum may not be always diagnostic of a demyelinating lesion (figure 5). Taking into account the increased concentration of lactate at

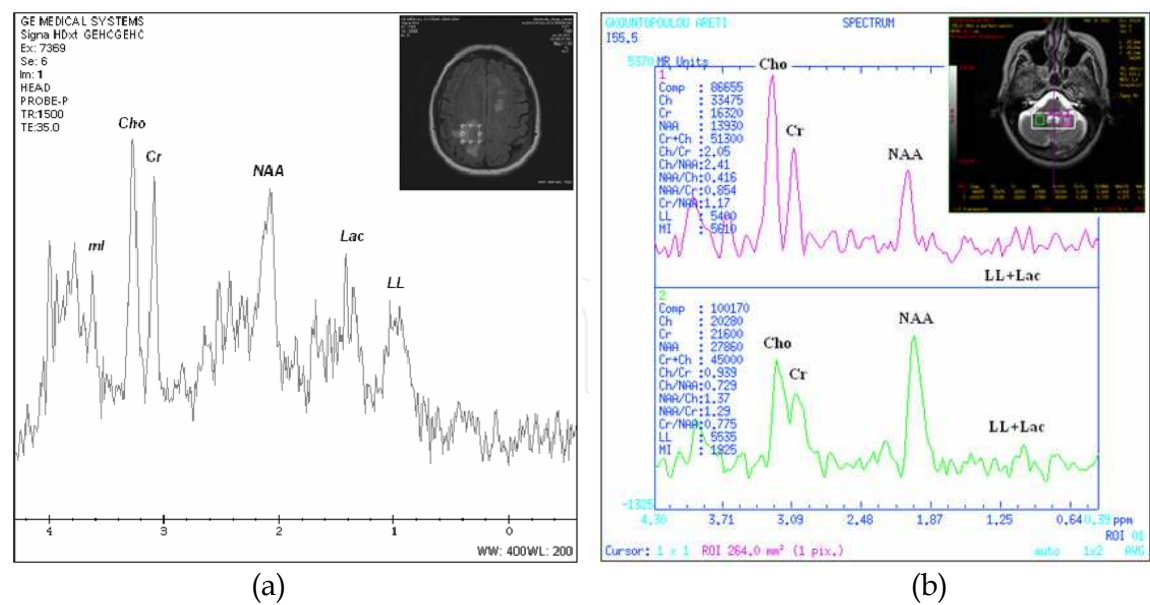


Fig. 5. (a) Characteristic proton MR spectrum of an acute MS plaque. Note the presence of slightly increased Cho, decreased concentration of NAA, and slightly increased concentration of Lactate (b) Spectrum obtained from a cerebellar demyelinating lesion. This spectrum is not suggestive of demyelination and may be erroneously diagnosed as a spectrum suggestive of a low grade glioma.

the initial phase, this finding may contribute to the establishment of an accurate diagnosis. However, it has to be emphasized that in cases that a demyelinating process is suspected, completion of the diagnostic investigation with other imaging and laboratory studies is often necessary [De Stefano & Filippi, 2007; Rovira & Leon, 2008; Takenaka et al., 2011].

6. Contribution of Diffusion Weighted Imaging (DWI) and Perfusion Weighted Imaging (PWI) in the distinction of ring enhancing lesions

6.1 Diffusion Weighted Imaging

Diffusion-weighted imaging (DWI) is an MRI technique, which is based on the Brownian motion of molecules. Diffusion-weighted imaging detects the tracing of the microscopic motion of water molecules, thus reflecting the microstructure of local tissue. Free motion of water molecules in all directions is called isotropic diffusion, while motion of water molecules in a specific direction, like a myelinated axon, is called anisotropic diffusion. The diffusion data can be presented as signal intensity, or as an image map of the apparent diffusion coefficient (ADC). Calculation of the ADC requires two or more acquisitions with different diffusion weightings. Increased signal intensity on DWI corresponds to restricted diffusion and low ADC, while low signal intensity on diffusion-weighted images corresponds to normal diffusion and a high ADC.

DWI is a method detecting the diffusion properties of water molecules, and is restricted in subacute ischemia, brain abscesses, and lymphomas. It is usually not restricted in cystic lesions. Application of DWI has been extensively described in the literature [Bükte et al., 2005; Chang et al., 2002]. Cystic lesions and necrotic brain tumors, primary or metastatic, that have a “cystic” central area, show normal diffusion, since the cystic area is caused by liquefaction (necrosis) of the tumor, that permits free motion of the molecules. However, several studies report the presence of restricted diffusion in necrotic brain gliomas, making the use of other imaging modalities mandatory [Chang et al., 2002; Holtas et al., 2000; Lai et al., 2007]. On the contrary, in brain abscesses the cystic part reflects the presence of inflammatory cells, debris and possibly bacteria, that restrict the free motion of the molecules, and thus cause restricted diffusion, which appears with increased signal intensity. However, diffusion may also be restricted in several cases of malignant brain tumors, in acute demyelinating lesions, and in acute encephalitis. In such cases, the employment of ^1H MRS, along with DWI may contribute in the differentiation of these lesions.

6.2 Perfusion Weighted Imaging

Perfusion Weighted Imaging (PWI), is the dynamic contrast imaging of the passage of intravenously injected paramagnetic contrast agent. Perfusion Weighted Imaging requires the acquisition of fast T2* images. After bolus intravenous contrast administration, the T2* images show drop of signal intensity, and as time passes, data are obtained in the form of cerebral blood flow (CBF), cerebral blood volume (CBV), and mean transit time (MTT). A time-intensity curve is generated for each voxel in each MR slice. The time-to-peak (TTP) is the time from the start of the scan until the maximum contrast attenuation occurs. The mean transit time (MTT) is the time it takes the contrast bolus to pass from the arterial to the venous side of the cerebral circulation. The entire area under the curve is a measure of relative cerebral blood volume (rCBV). Moreover, a measure of relative cerebral blood flow (rCBF) is calculated by dividing the rCBV by the MTT.

Perfusion Weighted Imaging is important in the diagnosis of brain tumors and the differentiation of recurrent gliomas from post-radiation necrosis. Malignant high grade gliomas demonstrate neovascularization that is detected by PWI, showing a correlation between microvessel density and histological tumor grade. The higher the tumor grade is, the higher the rCBV will be (Sugahara et al., 1998; Provenzale et al., 2006). Perfusion weighted imaging is of particular importance in the distinction of post-radiation necrosis from glioma recurrence. Especially, when PWI is employed in association with ^1H MRS, the sensitivity and specificity of both methods increase significantly. When PWI shows a low Cerebral Blood Volume through the area of contrast enhancement, this usually suggests post-radiation necrosis, while high rCBV along with increased levels of Cho, and markedly increased Cho/Cr, Cho/NAA ratios are more suggestive of glioma recurrence. It has to be pointed out, however, that despite all these recent imaging advances, differentiation of post-radiation necrosis from glioma recurrence may not be possible, and the employment of PET scan may be required in these cases.

7. Conclusions

The presence of ring enhancing lesions on brain MRI studies constitutes a frequent and quite challenging diagnostic dilemma. The differential diagnosis of lesions presenting as ring enhancing is quite extensive, and varies significantly with patient's age and the geographical region. Unfortunately, clinical history and symptomatology along with conventional MRI cannot accurately differentiate and establish a diagnosis of these lesions. Proton MRS may contribute in their differential diagnosis and may enhance, alone or in combination with other advanced MR Imaging modalities, the specificity and the diagnostic accuracy of conventional MRI. Proton MRS is a non invasive MR based diagnostic modality, which provides a direct spectroscopic signature of the examined brain parenchymal area and its underlying pathology, and an indirect evaluation of the lesion's metabolism. Detection of certain brain metabolites and calculation of their absolute and relative concentrations, are utilized in spectroscopic analysis. N-acetyl-aspartate, Cho, Cr, Lac, Lipids, MI, cytosolic aminoacids, and metabolic ratios of NAA/Cho, NAA/Cr, and Cho/Cr are the most commonly calculated metabolites. Changes in their concentrations may contribute in the differential diagnosis of ring enhancing lesions, since specific spectroscopic profiles exist for most of these lesions. High grade gliomas, metastatic tumors, abscesses, evolving infarcts, and demyelinating lesions demonstrate a specific and characteristic spectrum. In addition, employment of DWI and PWI, may further increase the diagnostic accuracy of ^1H MRS and conventional MRI in all these cases. Differentiation of post-radiation necrosis from tumor recurrence remains puzzling, despite all these advanced MR modalities and may require the employment of other imaging methodologies, such as PET. It has to be emphasized that ^1H MRS carries significant technical limitations, and requires an experienced spectroscopist and neuroradiologist in order to avoid misinterpretation of the obtained data, and subsequently misdiagnosis of the studied lesion.

8. Acknowledgements

The authors want to thank Mrs Evdokia Kokoti for her valuable help and support in organizing and submitting this chapter


9. References

- Barker, PB., Gillard, JH., van Zijl, PCM., Soher, BJ., Hanley, DF., Agildere, AM., Oppenheimer, SM., & Bryan, RN. (1994). Acute stroke: evaluation with serial proton MR spectroscopic imaging, *Radiology* Vol. 192, No. 3 (September 1994), pp. 723-732, ISSN 0033-8419
- Bükte, Y., Paksoy, Y., Genç, E., & Uca, AU. (2005) Role of diffusion-weighted MR in differential diagnosis of intracranial cystic lesions, *Clin Radiol* Vol. 60, No. 3, (March 2005), pp. 375-83, ISSN 0009-9260
- Burtscher, IM., & Holtas, S. (2001). Proton magnetic resonance spectroscopy in brain tumours: clinical applications, *Neuroradiology* Vol. 43, pp. 345-352, ISSN 0028-3940
- Castillo, M., Kwock, L., & Mukherji, SK. (1996). Clinical applications of proton MR spectroscopy, *AJNR Am J Neuroradiol* Vol.17, No.1, (January 1996), pp. 1-15, ISSN 0195-6108
- Castillo, M., Smith, JK. & Kwock, L. (2000). Correlation of myo-inositol levels and grading of cerebral astrocytomas, *AJNR Am J Neuroradiol* Vol. 21, No. 9 (October 2000), pp. 1645-1649, ISSN 0195-6108
- Chang, SC., Lai, PH., Chen, WL., Weng, HH., Ho, JT., Wang, JS., Chang, CY., Pan, HB., & Yang, CF. (2002). Diffusion-weighted MRI features of brain abscess and cystic or necrotic brain tumors: comparison with conventional MRI, *Clin Imaging* Vol. 26, No. 4 (July-August 2002), pp. 227-36, ISSN 0899-7071
- Croteau, D., Scarpace, L., Hearshen, D., Gutiérrez, J., Rock, J., Rosenblum, M., Fisher, J., & Mikkelsen, T.(2001). Correlation between magnetic resonance spectroscopy imaging and image-guided biopsies: semi-quantitative and qualitative histopathologic analysis of patients with untreated glioma, *Neurosurgery* Vol. 49, No. 4 (October 2001), pp. 823-829, ISSN 1528-8285
- De Stefano, N. & Filippi, M. (2007). "MR spectroscopy in multiple sclerosis." *J Neuroimaging* 17 Suppl 1, (April 2007), pp. 31S-35S, ISSN 1051-2284
- Fountas, KN., Kapsalaki, EZ., Gotsis, SD., Kapsalakis, JZ., Smisson, HF 3rd., Johnston, KW., Robinson, JS Jr., & Papadakis, N. (2000). In vivo proton magnetic resonance spectroscopy of brain tumors, *Stereotact Funct Neurosurg* Vol. 74, No. 2, pp. 83-94, ISSN 1011-6125
- Fountas, KN., Kapsalaki, E., Vogel, R., Fezoulidis, I., Robinson, JS., & Gotsis, ED. (2004). Noninvasive histologic grading of solid astrocytomas using proton magnetic resonance spectroscopy, *Stereotact Funct Neurosurg* Vol. 82, No. 2-3, pp. 90-97, ISSN1011-6125,
- Garg, M., Gupta, RK., Husain, M., Chawla, S., Chawla, J., Kumar, R., Rao, SB., Misr, MK., & Prasad, KN. (2004). Brain abscesses: etiologic categorization with in vivo proton MR spectroscopy, *Radiology* Vol. 230, No. 2, (February 2004), pp. 519-527, ISSN 0033-8419
- Gotsis, ED., Fountas, K., Kapsalaki, E., Toulas, P., Peristeris, G., & Papadakis, N. (1996). In vivo proton MR spectroscopy: the diagnostic possibilities of lipid resonances in brain tumors, *Anticancer Res* Vol. 16, No. 3B, (May- June 1996), pp. 1565-7, ISSN 0250-7005
- Himmelreich, U., Accurso, R., Malik, R., Dolenko, B., Somorjai, RL., Gupta, RK., Gomes, L., Mountford, CE., & Sorrell, TC. (2005). Identification of Staphylococcus aureus brain

- abscesses: rat and human studies with ¹H MR spectroscopy, *Radiology* Vol. 236, No. 1, (July 2005), pp. 261–270, ISSN 0033-8419
- Holtås, S., Geijer, B., Strömblad, LG., Maly-Sundgren, P., Burtscher, IM. (2000). A ring-enhancing metastasis with central high signal on diffusion-weighted imaging and low apparent diffusion coefficients, *Neuroradiology* Vol.24, No. 11, (November 2000), pp. 824-7, ISSN 0195-6108
- Howe, FA., Barton, SJ., Cudlip, SA., Stubbs, M., Saunders, DE., Murphy, M., Wilkins, P., Opstad, KS., Doyle, VL., McLean, MA., Bell, BA., & Griffiths, JR. (2003). Metabolic profiles of human brain tumors using quantitative in vivo ¹H magnetic resonance spectroscopy, *Magn Reson Med* Vol. 49, No. 2, (February 2003), pp. 223-32, ISSN 1522-2594
- Kadota, O., Kohno, K., Ohue, S., Kumon, Y., Sakaki, S., Kikuchi, K., & Miki, H. (2001). Discrimination of brain abscess and cystic tumor by in vivo proton magnetic resonance spectroscopy, *Neuro Med Chir (Tokyo)* Vol. 41, No. 3, (March 2001), pp. 121-126, ISSN 0470-8105
- Kallenberg, K., Bock, HC., Helms, G., Jung, K., Wrede, A., Buhk, JH., Giese, A., Frahm, J., Strik, H., Dechent, P., & Knauth, M. (2009). Untreated glioblastoma multiforme: increased myo-inositol and glutamine levels in the contralateral cerebral hemisphere at proton MR spectroscopy, *Radiology* Vol. 253, No. 3, (December 2009), pp. 805-12, ISSN 0033-8419
- Kapsalaki, E., Gotsis, ED., & Fountas, KN. (2008). The role of proton magnetic resonance spectroscopy in the diagnosis and categorization of cerebral abscesses, *Neurosurg Focus* Vol. 24, No. 6, pp. E7
- Kimura, T., Sako, K., Gotoh, T., Tanaka, K., & Tanaka, T. (2001). In vivo single-voxel proton MR spectroscopy in brain lesions with ring-like enhancement, *NMR Biomed* Vol. 14, No. 6 (October 2001), pp. 339–349, ISSN 0952-3480
- Kim, YH., Oh, SW., Lim, YJ., Park, CK., Lee, SH., Kang, KW., Jung, HW., & Chang, KH. (2010). Differentiating radiation necrosis from tumor recurrence in high-grade gliomas: assessing the efficacy of ¹⁸F-FDG PET, ¹¹C-methionine PET and perfusion MRI, *Clin Neurol Neurosurg* Vol. 112, No. 9, (November 2010), pp. 758-65, ISSN 0303-8467
- Lai, PH., Ho, JT., Chen, WL., Hsu, SS., Wang, JS., Pan, HB., & Yang, CF. (2002) Brain abscess and necrotic brain tumor: discrimination with proton MR spectroscopy and diffusion-weighted imaging, *AJNR Am J Neuroradiol* Vol. 23, No. 8, (September 2002), pp. 1369–1377, ISSN 0195-6108
- Lai PH, Li KT, Hsu SS, et al. (2005). Pyogenic brain abscess: findings from in vivo 1.5-T and 11.7-T in vitro proton MR spectroscopy. *AJNR Am J Neuroradiol* No. 26, pp. 279–288, ISSN 0195-6108
- Lai, PH., Hsu, SS., Ding, SW., Ko, CW., Fu, JH., Weng, MJ., Yeh, LR., Wu, MT., Liang, HL., Chen, CK., & Pan, HB. (2007). Proton magnetic resonance spectroscopy and diffusion-weighted imaging in intracranial cystic mass lesions, *Surg Neurol* Vol. 68, Suppl 1, pp. S25-36, ISSN 0090-3019
- Majos, C., Julia-Sape, M., Alonso, J., Serrallonga, M., Aguilera, C., Acebes, JJ., Arus, C., & Gili, J. (2004). Brain tumor classification by proton MR spectroscopy: comparison of diagnostic accuracy at short and long TE, *Am J Neuroradiol* Vol. 25, No. 10, (November-December 2004), pp. 1696–1704, ISSN 0195-6108

- Mikkelsen, T., & Edvardsen, K. (1995). Invasiveness in nervous system tumors. In: *Cancer of the Nervous System* (Eds, Black P, Loeffler JS), Blackwell Scientific Publications, ISBN 0781737311, Cambridge, MA
- Miller, BL., Chang, L., Booth, R., Ernst, T., Cornford, M., Nikas, D., McBride, D., & Jenden, DJ. (1996). In vivo ¹H MRS choline: correlation with in vitro chemistry/histology, *Life Sci* Vol. No. 22, pp. 1929-1935, ISSN 0024-3205
- Negendank, WG., Sauter, R., Brown, TR., Evelhoch, JL., Falini, A., Gotsis, ED., Heerschap, A., Kamada, K., Lee, BC., Mengeot, MM., Moser, E., Padavic-Shaller, KA., Sanders, JA., Spraggins, TA., Stillman, AE., Terwey, B., Vogl, TJ., Wicklow, K., & Zimmerman, RA. (1996). Proton magnetic resonance spectroscopy in patients with glial tumors, *J Neurosurg* Vol. 84, No. 3, (March 1996), pp. 449-58, ISSN 0022-3085
- Omuro, AM., Leite, CC., Mokhtari, K., & Delattre, JY. (2006). Pitfalls in the diagnosis of brain tumours, *Lancet Neurol* Vol. 5, No. 11, (November 2006), pp. 937-48, ISSN 1474-4422
- Opstad, KS., Murphy, MM., Wilkins, PR., Bell, BA., Griffiths, JR., & Howe, FA..(2004). Differentiation of metastases from high-grade gliomas using short echo time ¹H spectroscopy, *J Magn Reson Imaging* Vol. 20, No. 2, (August 2004), pp. 187-192, ISSN 1522-2594
- Parsons, MW., Li, T., Barber, PA., Yang, Q., Darby, DG., Desmond, PM., Gerraty, RP., Tress, BM., & Davis, SM. (2000). Combined (1)H MR spectroscopy and diffusion-weighted MRI improves the prediction of stroke outcome, *Neurology*, Vol. 55, No. 4, (August 22, 2000), pp. 498-505, ISSN 10158618
- Preul, MC., Caramanos, Z., Collins, DL., Villemure, JG., Leblanc, R., Olivier, A., Pokrupa, R., & Arnold, DL. (1996). Accurate, noninvasive diagnosis of human brain tumors by using proton magnetic resonance spectroscopy, *Nat Med* Vol. 2, No. 3, (March 2003), pp. 323-325, ISSN 1078-8956
- Provenzale, JM., Mukundan, S., & Barboriak, DP. (2006). Diffusion-weighted and perfusion MR imaging for brain tumor characterization and assessment of treatment response, *Radiology* Vol. 239, No. 3, (June 2006), pp. 632-49, ISSN 0033-8419
- Rand, SD., Prost, R., & Li, SJ.(1999). Proton MR spectroscopy of the brain, *Neuroimaging Clin N Am* Vol. 9, No. 2, (May 1999), pp. 379-395, ISSN 1052-5149
- Remy, M., Grand, S., Lai, ES., Belle, V., Hoffmann, D., Berger, F., Estève, F., Ziegler, A., Le Bas, JF., Benabid, AL., et al. (1995). ¹H RMS of human brain abscesses in vivo and in vitro, *Magn Reson Med* Vol. 34, No. 4, (October 1995), pp. 508-514, ISSN 1522-2594
- Rovira, A. & Leon, A. (2008). MR in the diagnosis and monitoring of multiple sclerosis: an overview, *Eur J Radiol* Vol. 67, No. 3, (September 2008), pp. 409-14, ISSN 0720-048X
- Schlemmer, JP., Bachert, P., Henze, M., Buslei, R., Herfarth, KK., Debus, J., & van Kaick, G. (2002). Differentiation of radiation necrosis from tumor progression using proton magnetic resonance spectroscopy, *Neuroradiology* Vol. 44, No. 3, (March 2002), pp. 216-222, ISSN 0028-3940
- Shino, A., Nakasu, S., Matsuda, M., Handa, J., Morikawa, S., & Inubushi, T. (1999). Noninvasive evaluation of the malignant potential of intracranial meningiomas performed using proton magnetic resonance spectroscopy, *J Neurosurg* Vol. 91, No. 6, (December 1999), pp. 928-934, ISSN 0022-3085
- Shukla-Dave, A., Gupta, RK., Roy, R., Husain, N., Paul, L., Venkatesh, SK., Rashid, MR., Chhabra, DK., & Husain, M. (2001). Prospective evaluation of in vivo proton MR

- spectroscopy in differentiation of similar appearing intracranial cystic lesions, *Magn Reson Imaging* Vol. 19, No. 1, (January 2001), pp. 103–110, ISSN 0730-725X
- Smirniotopoulos, JG., Murphy, FM., Rushing, EJ., Rees, JH., & Schroeder, JW. (2007). Patterns of contrast enhancement in the brain and meninges, *Radiographics* Vol. 27, No. 2, (March –April 2007), pp. 525-51, ISSN 0271-5333
- Sugahara, T., Korogi, Y., Kochi, M., Ikushima, I., Hirai, T., Okuda, T., Shigematsu, Y., Liang, L., Ge, Y., Ushio, Y., & Takahashi, M. (1998). Correlation of MR imaging blood volume maps with histologic and angiographic determination of vascularity of gliomas, *AJR Am J Roentgenol* Vol. 171, No. 6, (December 1998), pp. 1479–1486, ISSN 1546-3141
- Takenaka, S., Shinoda, J., Asano, Y., Aki, T., Miwa, K., Ito, T., Yokoyama, K., & Iwama, T. (2011). Metabolic assessment of monofocal acute inflammatory demyelination using MR spectroscopy and (11) C-methionine-, (11)C-choline-, and (18)F-fluorodeoxyglucose-PET, *Brain Tumor Pathol* (2011 Mar 26), Epub ahead of print, ISSN 1433-7398
- Tarnawski, R., Sokol, M., Pieniazek, P., Maciejewski, B., Walecki, J., Miszczyk, L., & Krupska, T. (2002). 1H-MRS in vivo predicts the early treatment outcome of postoperative radiotherapy for malignant gliomas, *Int J Radiat Oncol Biol Phys* Vol. 52, No. 5, (April 1, 2002), pp. 1271–1276, ISSN 0360-3016
- Tsui, EYK., Chan, JH., Cheung, YK., Lai, KF., Fong, D., & Ng, SH. (2002). Evaluation of cerebral abscesses by diffusion-weighted MR imaging and MR spectroscopy, *Comput Med Imaging Graph* Vol. 26, No. 5, (September- October 2002), pp. 347–351, ISSN 0895-6111
- Tsuyuguchi, N., Sunada, I., Iwai, Y., Yamanaka, K., Tanaka, K., Takami, T., Otsuka, Y., Sakamoto, S., Ohata, K., Goto, T., & Hara, M. (2003). Methionine positron emission tomography of recurrent metastatic brain tumor and radiation necrosis after stereotactic radiosurgery: is a differential diagnosis possible? *J Neurosurg*, Vol. 98, No. 5, (May 2003), pp., ISSN 0022-3085
- Weybright, P., Sundgren, P., Maly, P., Hassan, DG., Nan, B., Rohrer, S., & Junck, L. (2005). Differentiation between brain tumor recurrence and radiation injury using MR spectroscopy, *AJR Am J Roentgenol*, Vol. 185, No. 6, (December 2005), pp. 1471–1476, ISSN 1546-3141
- Wilson, M., Davies, NP., Grundy, RG., & Peet, AC. (2009). A quantitative comparison of metabolite signals as detected by in vivo MRS with ex vivo 1H HR-MAS for childhood brain tumours, *NMR Biomed* Vol. 22, No. 2, (February 2009), pp. 213–9, ISSN 0952-3480
- Xu, V., Chan, H., Lin, AP., Sailasuta, N., Valencerina, S., Tran, T., Hovener, J. & Ross, BD. (2008). MR spectroscopy in diagnosis and neurological decision-making, *Semin Neurol* Vol. 28, No. 4, (September 2008), pp. 407–422, ISSN: 0271-8235



Neuroimaging - Clinical Applications

Edited by Prof. Peter Bright

ISBN 978-953-51-0200-7

Hard cover, 576 pages

Publisher InTech

Published online 09, March, 2012

Published in print edition March, 2012

Modern neuroimaging tools allow unprecedented opportunities for understanding brain neuroanatomy and function in health and disease. Each available technique carries with it a particular balance of strengths and limitations, such that converging evidence based on multiple methods provides the most powerful approach for advancing our knowledge in the fields of clinical and cognitive neuroscience. The scope of this book is not to provide a comprehensive overview of methods and their clinical applications but to provide a "snapshot" of current approaches using well established and newly emerging techniques.

How to reference

In order to correctly reference this scholarly work, feel free to copy and paste the following:

Eftychia Kapsalaki, Efstathios D. Gotsis, Ioannis Tsougos and Konstantinos N. Fountas (2012). The Role of Magnetic Resonance Spectroscopy in the Diagnosis of Ring Enhancing Lesions, Neuroimaging - Clinical Applications, Prof. Peter Bright (Ed.), ISBN: 978-953-51-0200-7, InTech, Available from: <http://www.intechopen.com/books/neuroimaging-clinical-applications/the-role-of-magnetic-resonance-spectroscopy-in-the-diagnosis-of-ring-enhancing-lesions->

INTECH
open science | open minds

InTech Europe

University Campus STeP Ri
Slavka Krautzeka 83/A
51000 Rijeka, Croatia
Phone: +385 (51) 770 447
Fax: +385 (51) 686 166
www.intechopen.com

InTech China

Unit 405, Office Block, Hotel Equatorial Shanghai
No.65, Yan An Road (West), Shanghai, 200040, China
中国上海市延安西路65号上海国际贵都大饭店办公楼405单元
Phone: +86-21-62489820
Fax: +86-21-62489821

© 2012 The Author(s). Licensee IntechOpen. This is an open access article distributed under the terms of the [Creative Commons Attribution 3.0 License](https://creativecommons.org/licenses/by/3.0/), which permits unrestricted use, distribution, and reproduction in any medium, provided the original work is properly cited.

IntechOpen

IntechOpen