

# We are IntechOpen, the world's leading publisher of Open Access books Built by scientists, for scientists

6,900

Open access books available

186,000

International authors and editors

200M

Downloads

Our authors are among the

154

Countries delivered to

TOP 1%

most cited scientists

12.2%

Contributors from top 500 universities



WEB OF SCIENCE™

Selection of our books indexed in the Book Citation Index  
in Web of Science™ Core Collection (BKCI)

Interested in publishing with us?  
Contact [book.department@intechopen.com](mailto:book.department@intechopen.com)

Numbers displayed above are based on latest data collected.  
For more information visit [www.intechopen.com](http://www.intechopen.com)



# Dentofacial Aspects of the Changes in Body Posture, Investigation Procedures

Emil Segatto and Angyalka Segatto  
*University of Szeged, Department of Orthodontics  
 and Pediatric Dentistry  
 Hungary*

## 1. Introduction

The literature exploring the reasons and the development of the orofacial-orthopaedic anomalies and orthodontic deviations deals measurably with the correlation of these deviations and postural disorders. The development of certain pathological curvatures different from the physiological curvatures of the spine is mainly responsible for the majority of the postural deviations present during the pre-puberty. No spinal curvatures are found in the frontal plane at healthy people. In a normal spine there are four types of spinal curvatures (thoracic and sacral kyphosis, and cervical and lumbar lordosis) in the sagittal plane responsible for the upstanding posture. These curvatures become the characteristic attributes of an individual at the age of six-seven (Bellyei, 1995).

During growth the functional disorders at the spinal and body muscles are manifested in poor postures of different severity and directions. These can result in considerable spinal and therefore trunk inclinations in the frontal, the sagittal or both planes. If observed in time the poor or abnormal posture can be corrected with effective muscle strengthening exercises. The failure of the early discovery and of the early started corrective muscle exercises result in the consolidation of the pathological posture and in the development of the spinal deformities. The development of these skeletal problems is associated in many instances by other primary factors of which entire scale has not been disclosed so far. Without reference to the several different causative factors the general characteristic of all spinal deformities is that the active muscle strengthening exercises are not suitable for the fully management though the progression rate can be positively influenced.

The pathological curvature found on any segment of the spine playing a primary role in establishing the static balance induces the apparition of compensating curvatures that many times due to their positional attributes result in abnormal head posture. This way the spinal curvatures found in the frontal plane result in laterally tilted head posture, while the pathological spinal curvatures in the sagittal plane result in forward, respectively backward tilted head posture. In case of compensating spinal deformities the head posture is normal and compensating spinal malformations evolved in lower position level.

The literature studying the deformation of the facial skeletal structures deals with the cause and effect correlations regarding the head posture disorders in several publications (Solow

& Tallgren, 1976; Marcotte, 1981; Solow & Siersbaek-Nielsen, 1986). According to the authors discovering positive relations, the head posture altered in the growth period - through the gravitational effects - induces pathological soft tissue load (Solow & Kreiborg, 1977), that on the basis of the functional matrix theory results in an abnormal development of the cartilage and bone structures concerning the direction and size (Proffit & Fields, 2000).

The literature has disclosed the examination of those subjects suffering from spinal deformities who have scoliosis characterized with curvatures in the frontal plane. There are no detailed data on a comprehensive dentofacial screening at patients with Scheuermann's disease with increased thoracic kyphosis inducing forward tilted head posture. The available researches deal with the dentofacial deviations that can be connected with the examined spinal deformities or with the patients with abnormal head postures. No one research has attempted to specifically examine the previously mentioned two subject groups with congenial methods and in the same time as regards the earlier determined dentofacial deviations, having separated the correlation with the functional and/or structural etiological problems.

The literature presenting the dentofacial aspects of the spinal deformities versus the orofacial orthopaedic examinations at patients with postural disorders does not have a long history. The difficulty of the accurate determination of the postural features was the main reason. The modernization of the posture examining radiation free methods has brought a break-through in this matter, rasterstereography being the most outstanding technology. This examination method enables the calibrated determination of such numerical parameters helping to indirectly describe the spinal curvatures responsible for poor body posture and it can be used for comparison at examinations performed on a large sample. The examination of the dentofacial deviation associated to the postural deformities comprised beside routine orthodontic examination methods functional and radiologic procedures as well. The latter mainly includes the evaluation of the lateral cephalogram, P-A cephalogram and Orthopantomograms (OPG). The P-A cephalogram unlikely the lateral cephalogram and the OPG is not a routine radiologic procedure in orthodontics. As a result of our researches made to decrease the radiation load, the self-developed OPG analysing software is suitable for the expansive topographic asymmetry examinations of the mandible. This way the P-A cephalograms becomes unnecessary.

During our research activity we could amend for the first time the results of the dentofacial examinations of the samples screened by the rasterstereographic method with the results of such a comprehensive examination where the evaluations of the lateral cephalograms were unified with the very detailed data of the mandibular asymmetry examinations. The asymmetry examinations have pointed out results showing close correlation with certain elements of the lateral cephalogram analyses that can substitute during the determination of the dentofacial sample. These findings defines further examination directions for the radiation load reduction with determining such measurements elaborated on OPG's that can replace the performance of the lateral cephalograms in cases that were considered positive during an orthopaedic screening.

The purpose of the chapter is to give a comprehensive vision about the correlation between the dentofacial problems and the changes in body posture which play an etiologic role in

their development, with detailed presentation of the specific malformations of both fields, completed with the presentation of the up to date methods of investigation.

## **2. Factors causing changes in body posture**

Among the factors influencing the static body posture - beside the lower limbs structural asymmetries - the structural deviations of the pelvis as well as the malformations of the direction of the spine and the supporting body muscles are present. The structural malformations of the pelvis are relatively rare, and nowadays the disadvantageous effects of the limb asymmetries influencing the body posture are more easily treated with the modern orthopaedic appliances. Due to the earlier mentioned cause and effect correlation among the body posture deviations playing a significant role in the alteration of the head posture, the alterations in the spine and supporting body muscle position deserve more attention because of the frequency indices and the difficult therapeutic treatment. The more severe part of the latter deviation-group is formed by the spinal deformities while the more frequent part by the body muscle morphofunctional deviations.

### **2.1 Spinal disorders**

The common feature of the spinal deformities is the steady, structural deviation of the spine vertebrae which manifests in the pathological curvatures found on the affected spine segment due to the cumulated effects. Based on the frequency indices the two most prevailing spinal deformities are the scoliosis and the Scheuermann's disease, or Scheuermann's kyphosis. While the scoliotic curvature is a lateral curvature in the frontal plane, at Scheuermann's disease the hyperkyphosis developed due to the increase of the physiological thoracic kyphotic curvature. The appearance time and the progression of these deviations can be very diverse. We have to take into consideration that the quick condition decline most frequently is at the beginning of puberty, which - based on the earlier literature - significantly influences the development of the dentofacial deviations (Huggare et al., 1991).

#### **2.1.1 Scoliosis**

Scoliosis - its first written records are connected to Hippocrates - is a pathological entity with unknown aetiology. Its characteristic feature is the lateral spinal curvature developed as a result of the asymmetric growth of the vertebrae (Lowe et al., 2000). No spinal deviations are found in the frontal plane at healthy people. With the development of the structural deviations the pathological spinal curvatures become steady later, so the spinal deformity developed this way is called scoliosis. The curvatures found in the frontal plane are accompanied by the rotations measurable at horizontal plane as well as the altered curvatures in the sagittal plane. These deformities most often affect the thoracic and the lumbar segment segregated or entirely affecting such compensating curvatures that are entitled to ease the load and to balance the compression areas.

Scoliosis can be divided upon several aspects. Basically we can talk about primary and secondary scoliosis. The asymmetric growth developed on the spinal vertebral level is the reason of the primary deviation. This can be congenital or acquired. The acquired primary scoliosis can be further divided into idiopathic, traumatic, infectious, neuromuscular,

tumorous and degenerative. Scoliosis according to the direction of the curvature can be classified as follows: convex to the right or left, or of double direction. Scoliosis can further be classified by the localization of the curvatures. The curvatures can be structural or functional, as well as compensated or non-compensated. The most frequently examined type is the primary idiopathic scoliosis due to its incidence, its particular clinical feature and its progression. According to when onset occurs scoliosis can be: juvenile and adolescent. While at the juvenile scoliosis 90% of the cases show spontaneous improvement, the adolescent scoliosis is a progressive type deviation and till the age of 25 is constantly worsening in different phases (Herman et al., 1985).

During the examination of the affected spinal segment the morphological features detected on both side of the spinal curvature show correlation with the severity of the curvature. The vertebral bodies broaden on the convex side, the ribs are deforming and lifting towards the dorsal while the radius of their curvature is decreasing. On the concave side the vertebral bodies are narrower; the ribs are deformed while losing their normal curvatures they are curving straightforward (Bellyei, 1995). When scoliosis is present, the thoracic kyphosis decreases, straightens or could become lordotic. On the convex side at the apex of the curvature the ribs are heightened because of the spinal torsion, while on the concave side the ribs are sinking. The direction of the ribs deformation on the foreside of the thorax is opposed. The childhood clinical symptoms become localized on the spinal deformity, pains and other complaints are missing. Larger curvatures can be seen due to the postural and the caused structural asymmetries.

The basic conclusions of the researches related to the aetiology of the idiopathic structural scoliosis as regards the development of the scoliosis are the following: correlates to the adolescent growth-spurt; in girls the development of the curvature tends to be of a greater severity; presence of different deformities and genetically inherited (Hadley, 2000). Among the several aetiological factors the most often mentioned are the defect on level of CNS, the failure in the control of the melatonin production, the effect of calmodulin, the collagen abnormality, the altered platelets, as well as several hypothetical genetic inheritance – autosomal dominant inheritance, multi gene inheritance, multi-factorial inheritance and the X-linked dominant inheritance (Wise et al., 2000; Inoue et al., 2002; Parent et al., 2005).

Because of the diversity of world-wide applied early screening protocols, different occurrence data are available. The screenings at school showed such visually detectable body asymmetry at 15% of girls and boys at age 10 and 14, which were later proved by radiological examinations. The international literature data reports a ratio of 10 girls for every one boy (Morissy & Weinstein, 2006). On the basis of the earlier mentioned the classic idiopathic structural scoliosis is a right-curved, dorsal, lateral spinal curvature found at girls between age 10 and 12. The rotation evolved among the affected vertebrae and the presence of the torsion - a shift between certain elements within the vertebrae - is also characteristic features of the disease (Bagnall, 2008). The natural process of scoliosis is basically determined by the etiology and the outline of the curvature. The most frequent symptoms of the untreated scoliosis: the progression of the curvature, back pains, cardiopulmonary complaints and psychosocial problems. Though the mentioned symptoms are present in most of the cases, the effects on the entire organism are various. One single constant adjunct element to the untreated scoliosis, which shows a close correlation with the degree of the curvature, is the decrease of the pulmonary function. This is ascribable to the lateral



curvature, the high degree thoracic lordosis, the rotation of the vertebrae and the decreased dynamism of the respiratory muscles. As regards the psychosocial problems, the findings are particularly different. One third of the untreated patients with scoliosis reported that the disease curbed their every day activities (Lin et al., 2001).

### 2.1.2 Scheuermann's disease

The disease developed with the enlargement of the thoracic kyphosis of the spine and as a result of the structural deviation of the involved spinal segment was named and described as „kyphosis dorsalis juvenilis” by Scheuermann, a Danish radiologist (Ali, 1999). There are several names for the disorder in the literature: M.Scheuermann, osteochondrosis juvenilis dorsi, kyphosis dorsalis juvenilis, Scheuermann's kyphosis, juvenile kyphosis, Calvé's disease (Lowe, 1999). Actually the deformity is considered to be a form of juvenile osteochondrosis of the spine.

The degree of the thoracic kyphosis varies at healthy individuals; the normal curvature of the thoracic spine is between 20 and 40 degrees. The kyphotic curvature of more than 40-45 degrees gives the impression of a humpback, which is sometimes accompanied by the forward tilted head posture. Under the most frequently affected thoracic segment the increased compensatory lordosis of the lumbar part appears. In 25-30 % of the cases a moderate, generally functional dorso-lumbar scoliosis associates the previously mentioned deviations (Lemirre et al., 1996).

According to the localization the Scheuermann's disease can be classified in three main types. The type localized on the thoracic part is the most frequent, it extends on more vertebrae and usually painless. The dorso-lumbar interim type is rare, it covers several vertebrae and pain can be observed. The rarest type is the lumbar localized, it affects only one vertebrae and it is usually accompanied by pain (Bellyei, 1995). The children suffering from Scheuermann's disease are thin, have weak body muscles manifested in poor body posture and in abnormal head posture. In the majority of the cases the increased thoracic kyphosis causes only interim disturbance of growth and lasts till the end of growth with no progression. In a minor number severe progression can be observed, these can hardly be cured with conservative treatments. In these cases the thoracic kyphosis is very increased and the deformity is accompanied by complaints. In general there is no correlation between the onset of the complaints and the severity of the kyphosis - even a severe kyphosis can be painless, and in fact with a mild kyphotic curvature severe pains can be detected.

Similarly as in the case of scoliosis the earlier age the symptoms are present, the more favourable the prognosis is. Progression speeds up at the puberty phase. In this development period the growth of muscles cannot follow the fast grow of the bones. As a result of the endocrine harmonization and the increased stress the severity of deformity develops together with the complaints (Deacon et al., 1985).

The accurate etiology of the disease is still unknown. Some researchers consider the disease as deviations present at the level of the intervertebral discs among the vertebrae; others think that the endochondral ossification disorder of end plates is the causative factor. The notion „insufficiencia vertebrae” introduced by Schanz originates the development of the deviation to the balance disorder of the active (muscular) and passive (skeletal) system. Today it is a well-known fact that beside the mechanical factors, weight and height also play

an important role. Some researchers proved the presence of the autosomal dominant inheritance – the expected incidence for the repetition of the disorder in the family of the child with Scheuermann's disease is 50 %. Literature sources reports on very diverse incidence values. These vary between 0.4% - 8%, with similar ratio in the two genders (Tribus, 1998).

The most characteristic symptom of the disorder is the increased thoracic kyphosis indicating forward tilted hunchback posture. The compensatory lordosis of the spine segment found caudally from the deformity is less visible similarly to the functional scoliosis present as an accompanying symptom in some of the cases. It is more common the forward tilted head posture as well as the pendulous upper limbs attributable to the myasthenia. The characteristic of the disease is the presence of the “wedging” shape vertebrae developed on the involved spine segment, which makes the kyphotic curvature more increased. The Schmorl's nodes developed as a result of the forces acting through the anterior flattened vertebral discs and the presence of the uneven, attenuated endplate surfaces are very important in the distinctive diagnosis (Bradford, 1981). In case of untreated kyphotic curvature with less than 100 degrees the decrease of the pulmonary function is not common. In case of a kyphotic curvature with more than 100 degrees, with apex of the curve located between 1 and 8 thoracic vertebrae always can be seen restrictive pulmonary disorder (Murray et al., 1993).

## 2.2 Postural problems

The harmonic spinal curvature system proper to the individual in case of normal static development appears by the age of 6-7. The abnormal or poor body posture develops most frequently due to the spinal deformities in the sagittal plane. When developing beside the lowered load capacity of the spinal and body muscles the lack of will-powers needed for normal body posture as well as psychic factors play a significant role. Postural problems can be divided into three main groups: *dorsum rotundum* – thoracic kyphosis larger than the normal; *dorsum kypholordoticum* – increased thoracic kyphosis accompanied by compensatory increased lumbar lordosis and *dorsum planum* – thoracic kyphosis smaller than the normal. The common feature of postural problems is that they can be corrected by active muscle power. Accompanying symptoms are: loose joints, *pes planovagus* and vaulted abdomen, procident shoulders and frequent abdominal breathing (Bellyei, 1995).

## 2.3 Methods of investigation

The examination of the presented postural problems is partly done by physical and partly by instrumental diagnostic examination methods. The use of the clinical examination methods besides the orthopedic consulting-hours is standing orders at school and paediatrician consultation hours. The completion of the instrumental examinations and the result evaluations require specialist background and consulting-room environment.

The observation being used as a first step in the physical examination methods trends to body postures and respectively to the possible asymmetries. The higher-degree pathological spinal curvatures become visible by influencing the body posture. The lateral curvatures higher than 5 degree are responsible for the asymmetric appearance. The increased curvature can be observed laterally on the thoracic segment of the vertebrae with palpation.

The examination of the child's back in forward bend position (Adam's test) follows. At children with scoliosis a rib hump can be seen on the convex side of the curvature, which can be measure by the help of a scoliometer. At children with Scheuermann's disease during the test while the apex of the curvature is pushed down the patient is asked to chase by lifting their arms and head. As opposed to healthy as well as children with postural problems the kyphosis in case of Scheuermann's disease hardly decrease or not at all. As a last step during the examination of the locomotion range of the spine the aim of the trunk bending forward and back and laterally is to detect the restrain, which can be cause by the fixation of the involved spine deformity. At the potential pathological cases screened during testing the performance of an instrumental examination is suggested to confirm the diagnosis (Tribus, 1998).

The most frequent instrumental diagnostic examination methods are the radiological procedures. The methods developed to evaluate the radiograms taken from different sides are of high accuracy, due to their widespread use their evaluations are permeable, they are easily understood both in therapy and researches and can be used by all.

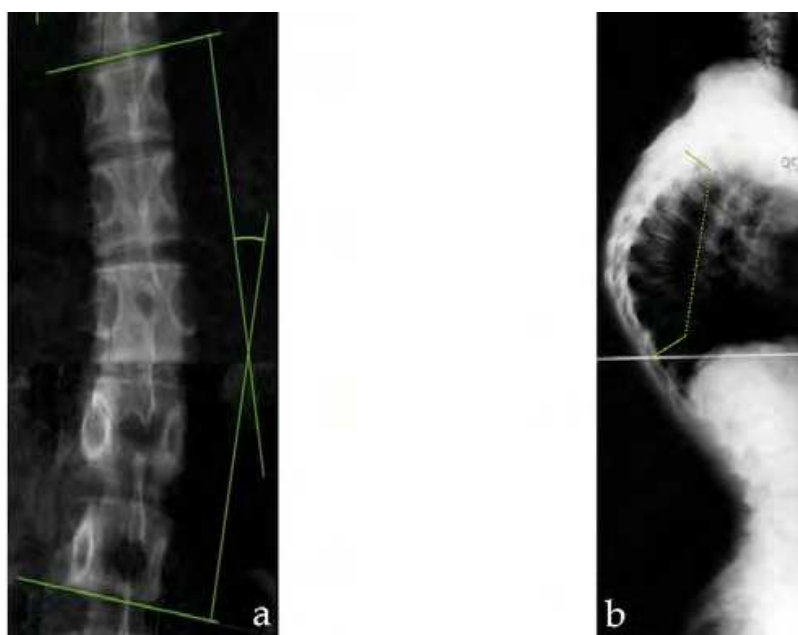


Fig. 1. Measurement of the: scoliotic curvature according to Cobb (a) and kyphotic angle (b).

The most prevailing measure for determining the scoliotic curvatures is the determination of the Cobb angle. These are defined by the adjacent angle of the angle between the lines drawn perpendicular along the superior and inferior end plates of the vertebrae bordering the curvature (Fig.1.a.). Since there is not physiological spinal curvature in the frontal plane the measurable Cobb values unequivocally show the presence of scoliosis. The determination of the kyphotic curvature in degrees in case of Scheuermann's disease happens in the same way using the end plates of the superior and inferior vertebrae of the pathological curvature for the measurements (Fig.1.b.). For a Scheuermann's disease diagnosis the presence of the following x-ray symptoms is essential: kyphotic curvature greater than 45°; presence of three or more adjacent "wedging" shape vertebrae; presence of Schmorl's nodes (Ali et al., 1999).



Because of the expansion of the spine the amount of the radiation dosage as well as the more frequent x-ray picture taking explained by the disease process have increasingly highlighted the importance of those attempts, which focused on developing diagnostic examination methods with reduced exposure to radiation. These methods deduce the spinal structural deformities from the morphological features of the surface back contour. During their development period in order to increase the accuracy the most important aspect was the comparability with the reliable radiological parameters. At the beginning the radiation free moiré-topography was the greatest break-through, but because of its efficiency indicator did not work out as a routine application (Kim et al., 2001).

The appearance of the rasterstereography providing more accurate values than the moiré-topography was a milestone (Frobin & Hierholzer, 1981). In the course of the rasterstereography procedure the testing device (Formetric 2, Diers International GmbH, Schlangenbad, Germany) elaborates a 3-D photographic mapping of the patient's back in upright position. For this purpose the device projects a sensitive gridded picture onto the back of the patient positioned at the suitable distance and way.

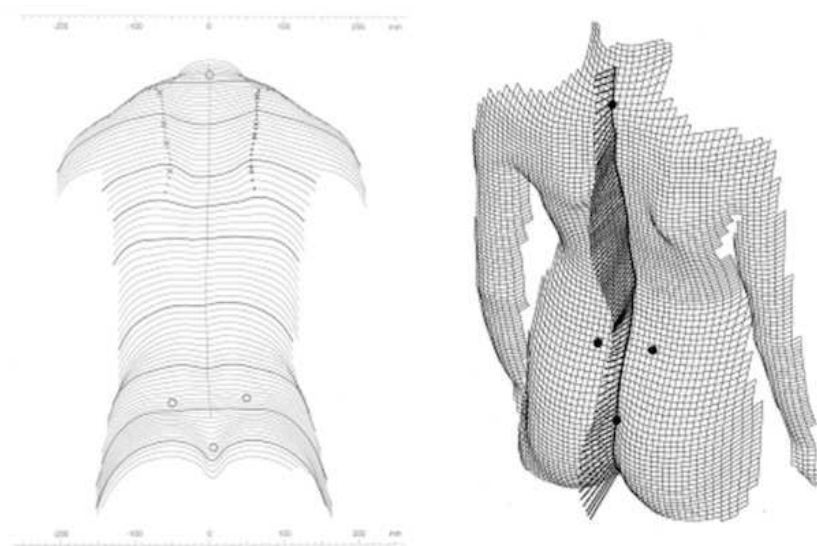


Fig. 2. Rasterstereography – reconstruction of the back surface.

The grid transmits accurate data about the back into the video-optical unit. Mapping the entire back takes 0.04 seconds and it is of high accuracy (methodological error < 0.1 mm) (Drerup & Hierholzer, 1987). The associated software units reconstruct the sagittal and frontal intercept of the surface back contour on the basis of certain anatomical structures (vertebra prominens and spinae iliacae) (Drerup & Hierholzer, 1994) (Fig. 2.).

With the usage of mathematical algorithms the visualization of the surface back contour is available from both sagittal and frontal side. The shift of the spine from the real perpendicular can be shown with a mathematical modelling. The curvatures in the sagittal plane can be reproduced with a 2.8° accuracy, those in the frontal plane with a 2° accuracy.

The sagittal curvatures can be characterized with the following measurement from lateral aspect: flèche cervicale and flèche lombaire. Both measurements show the distance of the furthest point of a given area calculated from the tangent lined along the hams and blades,

enabling the very accurate approach of the thoracic kyphosis degree (Lippold et al., 2006a)(Fig.3.a.).

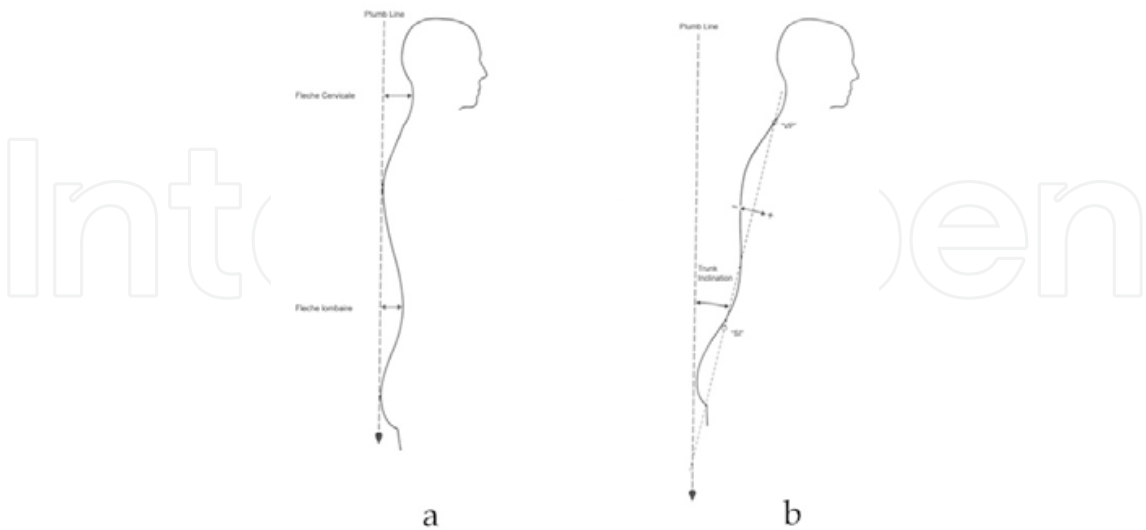


Fig. 3. Rasterstereography: flèche cervicale and flèche lombaire (a) and trunk inclination (b).

The most important measurement related to the body posture from lateral aspect is the trunk inclination, which is described by the angle between the vertical based on the vertebra prominens and the straight line between vertebra prominens and the center point of the straight line between the right and left crista iliaca posterior superior (VPDM line) (Fig.3.b.). Three variables are characteristic for the lateral curvatures from frontal aspect (Fig.4.).

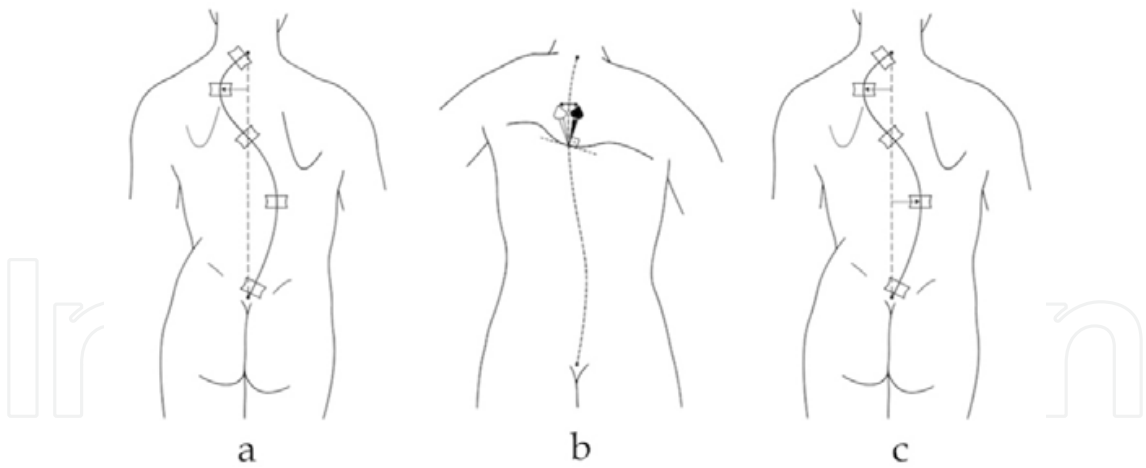


Fig. 4. Rasterstereography: maximal lateral deviation (a), surface rotational amplitude (b) and lateral amplitude (c).

The maximal lateral deviation shows the distance of the vertebra found at the apex of the greatest curvature in the spinal frontal plane from the VPDM line (Drerup et al., 1997) (Fig.4.a.). The surface rotational amplitude is the angle between the perpendiculars drawn on the vertebrae showing the greatest rotation on the lateral curvature (Fig.4.b.). The lateral amplitude is the sum of the distances measured from the VPDM line of the opposite side curvatures of the apex vertebra found in the frontal plane (Fig.4.c.).

Beside its outstanding reliability the radiation-free aspect of the method makes it favourable for screening the large patient groups for research purposes. Though when developing several instrumental examination methods the main purpose is the accurate, quick and radiation-free diagnostic, these facts are suitable only for determination of the degree of the body posture disorder without x-ray pictures. The rasterstereography procedure is feasible to define the degree of different spinal disorders (Schulte et al., 2008). When compared to some x-ray measurement we obtain results that are closer to the kyphotic curvature values than in the case of the scoliotic curvatures (Weiss & ElObeidi, 2009). To support the diagnosis of the spinal disorders – structural deformed vertebrae – the evaluation of the spine x-rays are still necessary. In diagnosing the postural problems the rasterstereography is suitable for separating three main types, also for accurate localizing and measuring the curves deviated from the normal but not being steady yet. In order to acknowledge these results taking x-ray pictures of differential diagnosis importance is essential, these being suitable for revealing the lack of “wedging” shape vertebrae and Schmorl’s nodes.

### **3. Dentofacial features associated to changes in body posture**

#### **3.1 Literature review**

In the course of the interdisciplinary researches the investigation of the orthopaedic and orthodontic correlations has an important academic and practical significance concerning the separation of the preventive diagnostic and therapeutic areas within the two specialities. The literature sources reports on several researches that were examining the correlation between certain orthopaedic parameters and certain Angle classes. The results presume possible correlations between the scoliosis and the Angle Class II malocclusion (Huggare et al., 1991) as well as between the poor body posture and Class II malocclusions (Lippold et al., 2003). Similarly the close correlation between the lateral spinal deformity and the unilateral crossbite, as well as the lower midline deviation has been proved in some researches (Huggare, 1998; Ben-Bassat et al., 2006). The cause of the presented malocclusions in majority of the cases is the presence of the skeletal asymmetries. (Sabah, 2002). This is also confirmed by the subgroup of the Angle Class II malocclusion frequently associated with the jaw asymmetry (Ben-Bassat et al., 1993). The registration of the jaw asymmetries related to the scoliosis is due to the tight relation with the adjacent soft tissues and it can be even demonstrated through a simple observation (Korbmacher et al., 2004). The typical deviation of the facial midline and the presence of spinal deformity as a causative agent introduced the naming of facial scoliosis accepted and used in the literature. The findings show a close correlation between the patients with severe scoliosis and the presence of the convergence angle describing the facial scoliosis (U. Hirschfelder & H. Hirschfelder, 1983). The laterally tilted head posture can likely be a cause for the correlation between the facial soft tissue as well as the skeletal asymmetries and the lateral deviation of the spine (Pirttiniemi et al., 1989; Huggare et al., 1991; Huggare, 1998). The pathological symptoms present on the temporomandibular joints level loaded asymmetrical by the abnormal head posture also show a close correlation with the spinal deformities determining the head posture (Kondo & Aoba, 1999). Finally, it is worth mentioning the problems of the dental deformities appearing during the treatment of the scoliosis and as a result of it. This has mainly historic importance since the Milwaukee-brace - which has totally lost ground in the therapeutic practice - played a principal role in the existence of the mentioned dental deformities (Bögi & Nagy, 1970, Paphalmy et al., 1975).

The literature examining the orofacial-orthopaedic deviations beside the orthopaedic disorders deals in details with the deviations observed in the sagittal plane and with the analysis of the pathological spinal deformities possibly allocable to them. Among the orthodontic diagnostic radiologic methods the spread of the lateral cephalograms has launched an extensive research activity aiming at investigation the etiology of the dental and skeletal deviation being measurable this way. These researches enlisted the interest to the correlation between the deviations found in the vertical and sagittal plane and the forward, respectively backward tilted head posture (Yamaguchi & Sueishi, 2003). Various researches revealed close relation between the cervical hyperlordosis and the cl. II malocclusions (Solow & Tallgren, 1976; Huggare, 1998). In average a 2 mm lack of space associates the increased cranio cervical angle in the upper or lower frontal regions of the dental arch (Solow & Sonnesen, 1998). Different intra-articular distances were recorded on x-ray pictures taken in with the head in various postures, which is probably a manifestation of differences in mandibular loading in the different head postures (Visscher et al., 2000). In order to explain the precise correlations the demand is to take cephalograms in natural head position (Leitao & Nanda, 2000). The basic criteria of taking cephalograms - the head position which is essential for evaluation - contradict the notion of natural head position, therefore this issue is still unsolved (Raju et al., 2001; Halazonetis, 2002). Contradictory to this the investigations searched the cephalograms taken in the positioned posture related to the true vertical and the true horizontal reference, not taking into account the relationship between natural head position and craniofacial morphology. The cephalograms examined this way enabled accurate measurements, hereby appraisable correlations related to maxilla were possible, while the inaccuracy of the mandibular measurement excluded the use of these methods for scientific purposes. Close correlation with the natural head position is shown only by the following measurement: facial axis, lower facial height and the facial ratios (Leitao & Nanda, 2000). The rasterstereographic procedures - used with research purpose recently - have a great importance in the head posture determination, but findings related to the connection between the body posture affected by the spine morphology and the head posture are still humble in number. The examination of the orthodontic deviations at children with Scheuermann's disease cannot be found in the qualified literature apart from the publications presenting some partial findings of our researches (Segatto et al., 2006, 2008).

There is a relatively great number of findings in the literature dealing with the relationship between the characteristics of the body posture determined by rasterstereographic procedures and certain orofacial-orthopaedic parameters. During the examination of the dental features the investigation did not show any close correlation between the characteristics of the spine morphology and the overjet (Lippold et al., 2006b). Similarly no close correlation was revealed between the mandibular position and the variables of the kyphotic and the lordotic angle or the pelvic inclination (Lippold et al., 2005). Among the craniofacial skeletal parameters the facial axis, the mandibular plane and the facial depth showed a significant correlation with the degree of the cervical curvature (Murray et al., 1993). Similarly, the facial axis together with the lordotic angle and the pelvic inclination, the inner gonial angle and the mandibular plane with the lordotic angle and the pelvic inclination, as well as the facial depth with the pelvic inclination showed a significant correlation (Lippold et al., 2006b). Finally the examination of the correlation between the pelvic torsion, the facial axis and the facial depth whereby the vertical and the sagittal mandibular parameters are in close correlation with the body posture needs to be mentioned (Lippold et al., 2007).



### 3.2 Methods of investigation

The examination of the dentofacial feature follows the standard orthodontic intra- and extra-oral examination protocol. Beside the physical functional and morphological examinations the evaluation of the x-ray pictures are paid great attention. The physical tests focused on the measurement of the TMJ condition and the activity of the adjacent muscles. The applied procedures comprise of the determination of the movement ranges and the detection of the differences between the sides. The extra-oral part of the morphological tests focused on the observation of the abnormal facial ration and the registration of the facial asymmetries. During the intraoral test the dental and occlusion features were examined. Vertical features: the frontal open bite and the deep bite as well as the lateral deep bite; sagittal features: the frontal overjet, crossbite, as well as the molar relationship ranged in Angle classes.

For analysing the skeletal features, for mapping the dentoskeletal conditions and for determining the position of the two jaws to each other and to the base of the skull the evaluation of different radiograms are available. During several researches the evaluation of the lateral cephalogram, the postero-anterior cephalogram as well as the orthopantomogram pictures provided the data. The standardized conditions provide the adaptability of the radiograms for researches. The determination of the skeletal features on the lateral and the postero-anterior cephalograms is done with one of the known evaluation methods. The most frequently measured parameters on the postero-anterior cephalogram by Ricketts are as follows: the inclination of the occlusal plane, postural symmetry, maxillary ratio, mandibular ratio, maxillary-mandibular midline; while on the lateral cephalogram: the maxillary depth, the ramus position, the facial axis, the lower facial height and the mandibular plane angle. Beside the determination of the asymmetry of the cranial structures on the postero-anterior cephalogram we used the parameters obtained during the definition of the mandibular asymmetries for our researches. Contrary to the cephalometric measurement when measuring the mandibular asymmetry no evaluation software was available. To overcome the compilation difficulties of the digital x-ray pictures and to evaluate quickly and accurately a large number of radiograms we developed the first mandibular asymmetry evaluating software. The measurements done by AsymmetrixX were based on previously accepted methods, which were modified taking into account the compilation characteristics. The asymmetry index calculation is used for the comparison of the distances of the two mandibular-halves (d) on the basis of the following formula:  $d \text{ asymmetry-index (AI)} = \left| \frac{(d_{\text{right}} - d_{\text{left}})}{(d_{\text{right}} + d_{\text{left}})} \right| \times 100$ . The importance of the mandibular asymmetry examination is provided by those findings that confirm that two-third of the asymmetries originates from the lower third of the face, and the size or the positional disorders of the mandible are responsible for their development (Vig & Hewitt, 1975; Farkas & Cheung, 1981).

The application of the Orthopantomogram being part of the orthodontic routine radiograms to the examination of mandibular asymmetries has a long history. In the early period of the application the problem of the reproducibility had to be solved; the solution was the creation of the head position standards (Larheim & Svanaes, 1986). After this, in order to eliminate the distortions emerging as the attribute of taking radiograms those recommendations were created that aimed to exclude certain measurement direction from the calculations (Habets et al., 1987). It proved to be similarly useful the application of the threshold value of 6% in the course of introducing the asymmetry index for substituting the head position deviations (Habets et al., 1988). On the basis of the asymmetry index formula



the difference of 6% between the two sides equals to an asymmetry index of 3%. The results vary between 0% (full symmetry) and 100% (full asymmetry), and results below 3% conventionally counts as symmetric.

Several papers dealt with the control of the genuineness of the early protocols and of the reliability of the method (Schulze et al., 2000; Stramotas et al., 2002; Saglam, 2003). A couple of them provide newer measurement and structural methods, too. There were some attempts to determine the mandibular asymmetries on the basis of the soft tissues contour with the help of graphical applications, however, the variedly implemented analysis of the OPG's remained the gold standard (Edler et al., 2003; Good et al., 2006).

In the period of the spread of the mandibular asymmetry measurements the distances to be compared became measurable by re-tracing the OPG's and by compiling the reference points and lines. With the spread of the digital x-rays the compilation of the distances required the use of graphical design programs, which meant a great difficulty for a medical research expert. The awkward compilation procedure assumed a deep knowledge of the design program and the long evaluation procedure suitable for limited data collection did not enable the examination of large patient group. The modern cephalometric procedure in the case of the digital lateral and PA cephalograms enabled the combination of the latter ones and the graphical applications used at the mandibular asymmetry measurements. As a result of this the number of the measurements increased and more accurate analysis are possible.

The analysing program AsymmetrixX developed to satisfy the provided claims were made in Delphi 7 development environment (Fig.5.). The principal accuracy of the measurements is determined by the size of the reference point and the thickness of the compiled added lines, whose size is: 1 pixel = 0.26 mm. Because of the measurement accuracy and the comparability it is important to unify the size of the OPG's to be analysed, which complies with the calibration requirement as well. After setting the adequate sharpness and contrast rates the selection of the OPG can be done by browsing from any paths. Before this the data required by the program for identifying the examined person (name, date of birth, date of taking the OPG) are recorded.

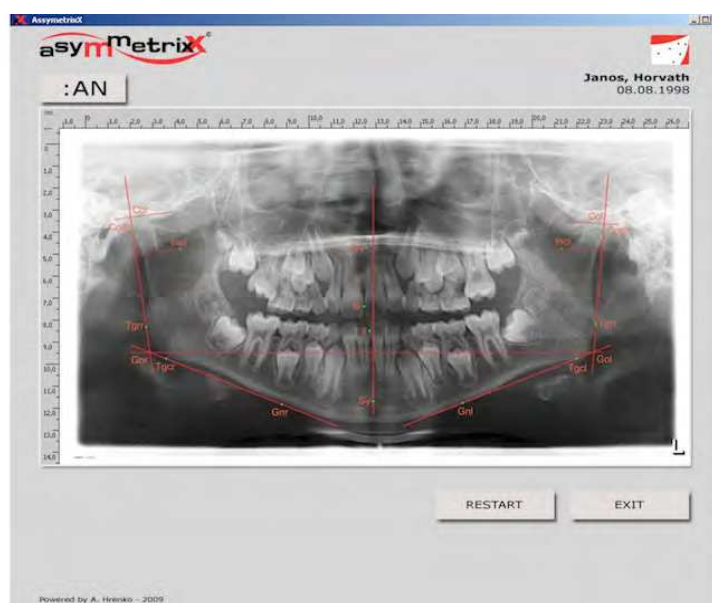


Fig. 5. Drawings performed with AsymmetrixX.

In the first step of the analysis by superposing the moveable Codr – Tgrr line appearing next to the right mandibular ramus to the Codr (Condylion dorsale right) and the Tgrr (Tangent ramus right) points we receive the right ramus tangent. By confirming the movement we determine the Codr point at the meeting of the tangent and the condylion, then the Tgrr point as a next step. After this the moveable Gnr – Tgcr line appears under the mandibular corpus, which we superpose on the Gnr (Gnathion right) and the Tgcr (Tangent corpus right) points, and we receive the right corpus tangent. After the fixation, next to the mentum we determine the Gnr point at the meeting of the tangent and the corpus, then the Tgcr point before the mandibular corner, at the meeting of the tangent and the corpus. Simultaneously with this, on the ramus tangent a slidable added perpendicular line appears; we fix it by moving it up to the top point of the processus condylaris. The next required point is the Cor (Condylion right) determined at the meeting of the fixed added line and the top point of the processus condylaris. By fixing it, the next slidable added line perpendicular to the ramus tangent appears, which we set to the bottom point of the Incisura mandibulae, and the meeting point determines the point Incr (Incisura mandibulae right).

The determination of the aforementioned reference points and lines should be followed by the left counterparts: left ramus tangent, Codl (Condylion dorsale left), Tgrl (Tangent ramus left), left corpus tangent, Gnl (Gnathion left), Tgcl (Tangent corpus left), Col (Condylion left), then Incl (Incisura mandibulae left). After the compilation of the paired measurement points come the unpaired points, which are requested in the following order by the program: the ANS (Anterior nasal spine), the is (incision superior), the ii (incision inferior), then finally the Sy (Symphysis mandibulae). After the fixation of this latter a line compiled from this point appears automatically, which will be perpendicular to the added line linking the meeting points of the bilateral ramus and corpus tangents (Gor – Gonion right and Gol – Gonion left). The program measures the distance of the other three odd points from this line. This way the ANS distance indicates the mentum deviation from the mid-facial reference structures, and the distance of the two dental midlines indicates the deviation thereof from the mandibular midline.

In the course of the compilation we received two important reference lines: the GoL (Gonion line) links the two compiled mandibular angles, and the ML (Midline) perpendicular to this indicates the mandibular midline. The two lines develop such a coordinate system, where the coordinates of the determined measurement points indicate the distance thereof from the adequate lines, in absolute values. Besides the distances measured from the two lines the program determines the distance of the projections of the given measurement points (Cor and Incr as well as Col and Incl) falling to the two ramus tangents. The so received RH (ramus height) = Go-Inc section and CH (condylar height) = Inc-Co section are suitable for the formerly applied mandibular asymmetry measurements. Each of the distances measured on the two halves of the mandible are suitable to be applied in the formerly explained asymmetry index formula.

Besides the indication of the length values the program automatically performs the asymmetry index calculations, and it represents the received 67 variables (51 distance measurements, 16 indices) in a csv file suitable for Excel statistical applications, so the possible errors of the manual data recording are eliminated. The graphic presentation of the

major results provides useful help for the fellow professions during the quick orientation among the analysis results. At the same time, the storage of all formats of the results is easily solved; they can be used for comparison with further analyses.

Our attempts get deeper connotations by the principles of the human face asymmetry examinations. In case of apparently symmetric, harmonic faces there are often skeletal asymmetries found which seems to confirm the camouflage ability of the soft tissues (Shah & Joshi, 1978). Due to the lack of the criteria system related to the determination of the asymmetry there is no precise threshold value above which the given measurement is asymmetric. At the same time the more visible an asymmetry is, the more attention deserves since the closer it gets to the pathological condition (Rossi et al., 2003). The asymmetries of the craniofacial area are observed as the size disorders of the two face-halves. The amplitude of the real disorders is often decreased by the well functioning adjacent soft tissues through the camouflage effect (Bishara et al., 1994). The most common method to reveal the skeletal asymmetries being present behind the soft tissues is taking frontal cephalograms (P-A). Taking these postero-anterior cephalograms – due to the unnecessary radiation loading – is needed in the case of one-third of those asymmetries where not the mandibular region is responsible for the deformations. At the examination of the mandibular asymmetries, a further disadvantage is the occlusal position that could result in inaccurate measurements in the case of possible functional deviations.

By developing the AsymmetrixX we aimed at working out such analysing software that is suitable for a simple, quick and very accurate asymmetry analysis of the most widespread - and suitable for large utilization - panoramic radiograms (OPG). Its usage enables the omission of the indication of the postero-anterior cephalograms related to the asymmetry examination, thus decreasing the patients' radiation load.

#### **4. The use of AsymmetrixX to examine the mandibular asymmetries associated with postural deformities**

##### **4.1 Aim**

The aim of the study is the mandibular asymmetry analysis of the children's orthopantomogram participating in the rasterstereographic surface back contour examination with AsymmetrixX in order to detect the correlations between the surface back contour characteristics and the elements of the topographic patterns of an accurate mandibular asymmetry.

##### **4.2 Subjects and methods**

The members of the examination group were selected from 320 children registered at the orthodontic consultations. We used the data of 271 children complied with the selection criteria - spinal deformities neither diagnosed nor treated earlier; dental and orofacial-orthopaedic deviations neither diagnosed nor orthodontically treated earlier; had rasterstereographic back contour analysis, and orthopantomogram done during the consultation – for the examinations. Average age of the group: 11Y8M; min.: 7Y2M; max.: 16Y12M; SD: 2Y0M; distribution of the genders: 42.4% boys, 57.6% girls (Fig.6.).

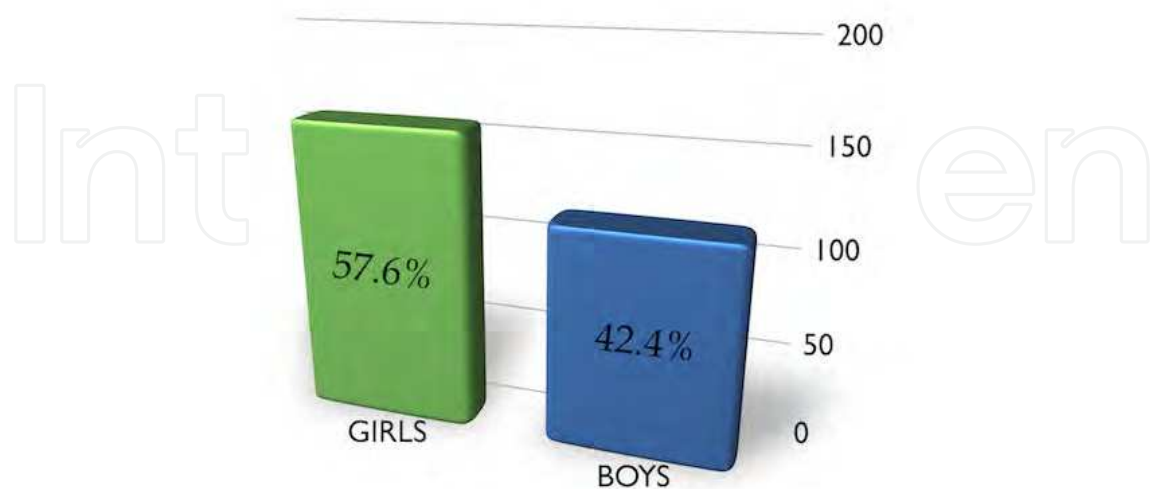


Fig. 6. The distribution of the children participating in the examination by gender.

#### 4.3 Results

After the descriptive statistical analysis of the orthopaedic and dentofacial instrumental testing data, the detailed comparison of these data served the findings of our researches.

##### 4.3.1 The descriptive statistics of the results obtained by the rasterstereographic surface back contour analysis

12 variables are determined during the rasterstereographic procedure, some of them related to the characteristics observed on the sagittal, the other on the frontal plane of the surface back contour. With the help of a multidimensional scaling we place the main components of the 12 variables in 2 dimension so that the heavily correlating ones to be close to each other (distance formula:  $-\ln(\text{abs}(\text{Pearson } r))$ ). This way the variables are separated into 5 groups, which were reduced to three by the importance concerning the view of the examination. The components being in heavy correlation with each other enabled further reduction, finally this decreased the applied indices to three sagittal and three frontal variables. They are the following:

- flèche cervicale – kyphosis index
- flèche lombaire – lordosis index
- trunk inclination – entire kypholordotic index
- maximal lateral deviation – lateral scoliosis index
- surface rotational amplitude – rotational scoliosis index
- lateral amplitude – entire scoliosis index.

The descriptive statistics of the orthopaedic variables are presented in (Table 1.).

Results of the rasterstereographic analyses		N	Min.	Max.	Mean	SD
	Flèche cervicale	271	0.00mm	138.95mm	53.89	21.28
	Flèche lombaire	271	1.70mm	72.20mm	30.65	13.12
	Trunk inclination	271	-5.65°	11.56°	2.90	3.07
	Maximal lateral deviation	271	-27.92mm	21.53mm	-5.95	8.60
	Surface rotational amplitude	271	1.72°	19.14°	6.79	3.22
	Lateral amplitude	271	3.44mm	34.56mm	11.65	5.19

Table 1. The descriptive statistics of the parameters determined by rasterstereography.

4.3.2 The descriptive statistics of the mandibular asymmetry examination results

The asymmetry examinations of the OPG’s of the patient groups were done by the AsymmetrixX analysing software. The program after determining the required tangents and measuring points calculates 67 variables. To reduce these variables we used the 2 dimension projection of the multidimensional scaling of the main components and correlations. This way the variables were classified into three groups, though these groups do not demarcate from each other therefore by further reduction of the heavily correlation variables we did not manage to narrow the number of the measurement suitable for further comparative examination.

Those horizontal linear measurements which due to the inaccuracy of the horizontal lenght measurements characteristics of OPG are omitted from the comparison are not among the applied variables. The remaining 36 variables consist of 6 horizontal and 9 vertical asymmetry indices and 21 vertically oriented distance measurements. The descriptive statistics of the most important vertical mandibular asymmetry variables are presented in (Table 2.).



Results of the analyses performed with AsymmetrixX		N	Min.	Max.	Mean	SD
	Cod-ML index	271	-9.50	29.47	1.78	4.75
	Go-ML index	271	-11.09	30.70	1.05	4.39
	Co-GoL index	271	-11.16	91.69	3.26	15.81
	Tgr-GoL index	271	-80.56	21.42	-4.06	18.21
	CH index	271	-21.07	14.99	-0.29	5.57
	RH index	271	-8.65	11.31	0.48	3.24
	CH+RH index	271	-3.90	7.02	0.29	1.70
	CHr	271	12.74mm	30.29mm	20.67	3.12
	CHl	271	13.72mm	29.66mm	20.74	2.79

Table 2. The descriptive statistics of the main vertical parameters determined by AsymmetrixX.

4.3.3 Comparative examination results

Due to the large number of the comparable variables the examination of correlation between the orthopaedic and dentofacial parameters was done by the stepwise linear regression. In case of the flèche cervicale orthopaedic variable the (CH + RH) mean ( $p<0.0005$ , coefficient: 1.258), the Tgc-GoL mean ( $p=0.024$ , coefficient: 0.685), the Gn-GoL mean ( $p=0.016$ , coefficient: 0.671) and the Tgc-GoL index ( $p=0.002$ , coefficient: -0.196) seemed to be the significant, absolute linear predictor. The flèche lombaire variable in the linear regression shows correlation only with RH mean ( $p=0.011$ , coefficient: 0.382). In case of the trunk inclination orthopaedic variable the CH mean ( $p=0.034$ , coefficient: 0.141) seemed to be the significant, absolute linear predictor.

The maximal lateral deviation, the surface rotational amplitude and the lateral amplitude do not show linear regression correlation with any mandibular asymmetry variables (Table 3.).

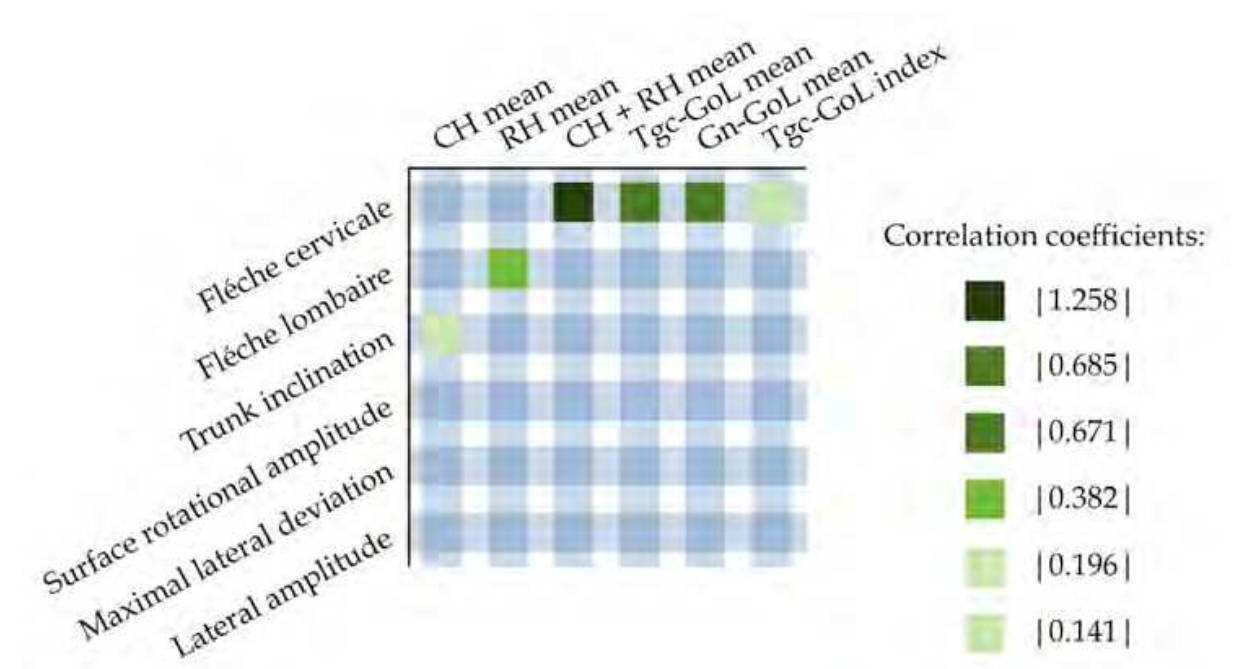


Table 3. The rate of the correlation between the orthopaedic and dentofacial parameters.

4.4 Discussion

The orthopaedic parameters of the examination group were provided by the rasterstereographic analysis. It means that the back contour morphology was mapped through a simultaneous registration of the deviation of different planes, without taking into account the threshold limit values separating the healthy and unhealthy categories. With the help of the statistical methods, out of the 12 measurements we selected 3 determining the sagittal and 3 determining the frontal curvatures and the positional deviations of the spine in the most precise way. For the comparative examinations 36 asymmetry variables measured on OPG's were used.

The flèche cervicale shows close correlation with the entire ramus height as well as the steepness of the inclination of the mandibular corpus out of the asymmetry variables determined on the mandible so the increased ramus height and mandibular base plane accompany the hyperkyphotic back. The flèche lombaire shows a moderately close correlation with the average of the ramus height, thus accentuation of the lumbar lordosis is associated with an increased ramus height. The trunk inclination shows similar correlation with the degree of the condylar height, therefore the forward inclined body posture presumes increase condylar height.

Based on the result of the comparative examination of the maximal lateral deviation, the surface rotational amplitude and the lateral amplitude the distance between the degree of the lateral deviation of the spine, the degree of vertebral rotation being present at the level of scoliotic curvature and the bilateral spinal curvatures is not associated with any of the mandibular asymmetry variables.

The comparative evaluation of the mandibular asymmetry variables obtained at the large number of patient group screened by the rasterstereographic procedure having used the

AsymmetrixX analysing software on examinations brought new results. The asymmetry variables determined with the help of the analysing software show close correlation with the rasterstereographic variables modelling the curvatures on the sagittal plane. The simple, non-invasive examination methods of certain features make possible to explore the given deviations at an early stage and in an interdisciplinary way. The skeletal basis of the postural disorders developing at the same age as well as the early recognition of the mandibular asymmetries showing close correlation therewith should mean the necessity of examining the potentially present joint deviations for the specialists of both fields. The new analysing methods waiting to be introduced are certainly suitable for recognising the features of the asymmetric dentofacial character.

## 5. Conclusions

The importance of the findings establishing a close correlation between the orthopaedic and orofacial-orthopaedic specialities is described below. The postural problems diagnosed during the pre-puberty as well as the dentofacial problems observed with the spinal deformities adverted to the necessity of the careful and accurate screening in both speciality fields. The prompt orthodontic screening in an early stage of the children diagnosed with spinal deformities can reveal those deviations which can be managed with conservative methods. Similarly to this the joint presence of the dentofacial pattern elements can be a disease-marker from the point of view of revealing a possible orthopaedic background disease.

Our research work focused on the confirmation of the previously listed results and to complement the experienced deficiency accentuating the importance of the identification of such early diseases-markers that can contribute to the formation of already proved associated deformities or to their progression. The early observation methods related to these deformities have to be known by the specialists working in the paediatric field. We have developed the computerized analysing software which significantly simplifies by its accuracy and quickness the early observation of the dentofacial deviations at the mentioned patient groups to help their and the specialists' preventive activity.

The synchronization of the result obtained with the applied examination methods as well as their harmonization with the modern radiologic procedures is a new challenge for the researchers. According to the reviewed detailed information the direction of the researches of this specialty considered to be of high importance has to be determined by the attempts that focus on the elaboration of an automatic classifying system based on the 3D topographic examination of the cranium also contributing to the early orthopaedic diagnosis. On the other hand the work out of those mandibular asymmetry measurements that substitute the disease-marker measurements obtained during the evaluation of the lateral cephalograms and similarly to the rasterstereography further reduce the radiation load of the involved orthopaedic subject is very important.

## 6. Acknowledgment

I would like to express my gratitude to my colleague Dr. Carsten Lippold for the patients' database provided and to my friend Éva Szász for her help with the translations.

## 7. References

- Ali, RM., Green, DW. & Patel, TC. (1999). Scheuermann's kyphosis. *Curr Opin Pediat.*, 11: 70-75
- Bagnall, KM. (2008). Using a synthesis of the research literature related to the aethiology of adolescent idiopathic scoliosis to provide ideas on future directions for success. *Scoliosis*, 3:5
- Bellyei, Á. (1995). The diseases of the spine, spinal deformities. In: *The book of othopaedics*, Vízkelety, T. (1st ed.), 112-159, Semmelweis Publisher, ISBN 963-8154-60-8, Budapest
- Ben-Bassat, Y., Yaffe, A., Brin, I., Freeman, J. & Ehrlich, Y. (1993). Functional and morphological-occlusal aspects in children treated for unilateral posterior cross-bite. *Eur J Orthod*, 15: 57-63
- Ben-Bassat, Y., Yitschaky, M., Kaplan, L. & Brin, I. (2006). Occlusal patterns in patients with idiopathic scoliosis. *Am J Orthod Dentofacial Orthop*, 130: 629-633
- Bishara, SE., Burkey, PS. & Kharouf, JG. (1994). Dental and facial asymmetries: a review. *Angle Orthod*, 64: 89-98
- Bradford, DS. (1981). Vertebral osteochondrosis (Scheuermann's kyphosis). *Clin Orthop*, 158: 83-90
- Bögi, I. & Nagy, L. (1970). The prevention and management of the denal deformities present as a result of the scoliosis treatment. *Fogorv Sz*, 63: 238-244
- Deacon, P., Berkin, CR. & Dickson, RA. (1985). Combined idiopathic kyphosis and scoliosis. *J Bone Joint Surg Br*, 67: 189-192
- Drerup, B. & Hierholzer, E. (1987). Automatic localization of anatomical landmarks on the back surface and construction of a body-fixed coordinate system. *J Biomech*, 20: 961-970
- Drerup, B. & Hierholzer, E. (1994). Back shape measurement using video rasterstereography and three-dimensional reconstruction of spinal shape. *Clinical Biomechanics*, 9: 28-36
- Drerup, B., Hierholzer, E. & Ellger, B. (1997). Shape analysis of the lateral and frontal projection of spine curves assessed from rasterstereographs. In: *Research into Spinal Deformities*, J.A. Sevastik & K.M. Diab, (1st ed.), 271-275, IOS Press, Amsterdam
- Edler, R., Wertheim, D., & Greenhill, D. (2003). Comparison of radiographic and photographic measurement of mandibular asymmetry. *Am J Orthod Dentofacial Orthop*, 123: 167-174
- Farkas, LG. & Cheung, G. (1981). Facial asymmetry in healthy North American caucasians. *Angle Orthod*, 51: 70-77
- Frobin, W. & Hierholzer, E. (1981). Rasterstereography: a photogrammetric method for measurement of body surfaces. *Photogrammetric Engineering and Remote Sensing*, 47: 1717-1724
- Good, S., Edler, R., Wertheim, D. & Greenhill, D. (2006). A computerized photographic assessment of the relationship between skeletal discrepancy and mandibular outline asymmetry. *Eur J Orthod*, 28: 97-102
- Habets, LLMH., Bezuur, JN., Van Ooij, CP. & Hansson, TL. (1987). The orthopantomogram, an aid in diagnosis of temporomandibular joint problems. I. The factor of vertical magnification. *J Oral Rehabil*, 14: 475-480



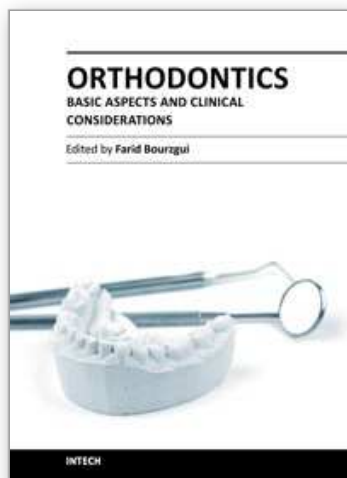
- Habets, LLMH., Bezuur, JN., Naeiji, M. & Hansson, TL. (1988). The Orthopantomogram®, an aid in diagnosis of temporomandibular joint problems. II. The vertical symmetry. *J Oral Rehabil*, 15: 465-471
- Hadley, MN. (2000). Spine update: genetics of familial idiopathic scoliosis. *Spine*, 25: 2416-2418
- Halazonetis, DJ. (2002). Estimated natural head position and facial morphology. *Am J Orthod Dentofacial Orthop*, 121: 364-368
- Herman, R., Mixon, J., Fischer, A., Maulucci, R. & Stuyck, J. (1985). Idiopathic scoliosis and the central nervous system: a motor control problem. *Spine*, 10: 1-14
- Hirschfelder, U. & Hirschfelder, H. (1983). Auswirkungen der Skoliose auf den Gesichtsschädel. *Fortschr Kieferorthop*, 44: 457-467
- Huggare, J., Pirttiniemi, P. & Serlo, W. (1991). Head posture and dentofacial morphology in subjects treated for scoliosis. *Proc Finn Dent Soc*, 87: 151-158
- Huggare, J. (1998). Postural disorders and dentofacial morphology. *Acta Odontol Scand*, 56: 383-386
- Inoue, M., Minami, S., Nakata, Y., Takaso, M., Otsuka, Y., Kitahara, H., Isobe, K., Kotani, T., Maruta, T. & Moriya, H. (2002). Prediction of curve progression in idiopathic scoliosis from gene polymorphic analysis. *Stud Health Technol Inform*, 91: 90-96
- Kim, HS., Ishikawa, S., Ohtsuka, Y., Shimizu, H., Shinomiya, T. & Viergever, MA. (2001). Automatic scoliosis detection based on local centroids evaluation on moiré topographic images of human backs. *IEEE Trans Med Imaging*, 20: 1314-1320
- Kondo, E. & Aoba, TJ. (1999). Case report of malocclusion with abnormal head posture and TMJ symptoms. *Am J Orthod Dentofacial Orthop*, 116: 481-493
- Korbmacher, H., Eggers-Stroeder, G., Koch, L. & Kahl-Nieke, B. (2004). Correlations between anomalies of the dentition and pathologies of the locomotor system – a literature review. *J Orofac Orthop*, 65: 190-203
- Larheim, TA. & Svanaes, DB. (1986). Reproducibility of rotational panoramic radiography: Mandibular linear dimensions and angles. *Am J Orthod Dentofacial Orthop*, 90: 45-51
- Leitao, P. & Nanda, RS. (2000). Relationship of natural head position to craniofacial morphology. *Am J Orthod Dentofacial Orthop*, 117: 406-417
- Lemirre, JJ., Mierau, DR., Crawford, CM. & Dzus, AK. (1996). Scheuermann's juvenile kyphosis. *J Manipulative Physiol Ther*, 19: 195-201
- Lin, MC., Liaw, MY., Chen, WJ., Cheng, PT., Wong, AM. & Chiou, WK. (2001). Pulmonary function and spinal characteristics: their relationships in persons with idiopathic and postpoliomyelitic scoliosis. *Arch Phys Med Rehabil*, 82: 335-341
- Lippold, C., van den Bos, L., Hohoff, A., Danesh, G. & Ehmer, U. (2003). Interdisciplinary study of orthopedic and orthodontic findings in pre-school infants. *J Orofac Orthop*, 64: 330-340
- Lippold, C., Danesh, G., Schilgen, M., Drerup, B. & Hackenberg, L. (2005). Sagittal jaw position in relation to body posture in adult humans – a rasterstereographic study. *BMC Musculoskeletal Disorders*, 7:8
- Lippold, C., Danesh, G., Hoppe, G., Drerup, B. & Hackenberg, L. (2006). Sagittal spinal posture in relation to craniofacial morphology. *Angle Orthod*, 76: 625-631
- Lippold, C., Danesh, G., Schilgen, M., Drerup, B. & Hackenberg, L. (2006). Relationship between thoracic, lordotic, and pelvic inclination and craniofacial morphology in adults. *Angle Orthod*, 76: 779-785



- Lippold, C., Danesh, G., Hoppe, G., Drerup, B. & Hackenberg, L. (2007). Trunk inclination, pelvic tilt and pelvic rotation in relation to the craniofacial morphology in adults. *Angle Orthod*, 77: 29-35
- Lowe, TG. (1999). Scheuermann's disease. *Orthop Clin North Am*, 30: 475-487
- Lowe, TG., Edgar, M., Margulies, JY., Miller, NH., Raso, J., Reinker, KA. & Rivard, CH. (2000). Etiology of idiopathic scoliosis: current trends in research. *J Bone and Joint Surg*, 82-A: 1157-1168
- Marcotte, MR. (1981). Head posture and dentofacial proportions. *Angle Orthod*, 51: 208-213
- Morissy, RT. & Weinstein, SL. (2006). *Lovell and Winter's Pediatric Orthopedics* (6<sup>th</sup> ed.), Lippincott-Raven, ISBN 0-7817-5358-9, New York
- Murray, PM., Weinstein, SL. & Spratt, KF. (1993). The natural history and long-term follow-up of Scheuermann kyphosis. *J Bone Joint Surg Am*, 75: 236-248
- Paphalmy, Zs., Kállay, M. & Tomory, I. (1975). Prevention of the dental deformities appearing during the treatment of children with scoliosis. *Fogorv Sz*, 68: 374-376
- Parent, S., Newton, PO. & Wenger, DR. (2005). Adolescent idiopathic scoliosis: etiology, anatomy, natural history, and bracing. *Instr Course Lect*, 54: 529-536
- Pirttiniemi, P., Lahtela, P., Huggare, J. & Serlo, W. (1989). Head posture and dentofacial asymmetries in surgically treated muscular torticollis patients. *Acta Odontol Scand*, 47: 193-197
- Proffit, WR. & Fields, HW Jr. (2000). *Contemporary orthodontics* (3<sup>rd</sup> ed.), Mosby, ISBN 1-55664-553-8, St.Luis
- Raju, NS., Prasad, KG., Jayade, VP. (2001). A modified approach for obtaining cephalograms in the natural head position. *J Orthod*, 28: 25-28
- Rossi, M., Ribeiro, E. & Smith, R. (2003). Craniofacial asymmetry in development: An anatomical study. *Angle Orthod*, 73: 381-385
- Sabah, ME. (2002). Submentovertex cephalometric analysis of Class II subdivision malocclusion. *Oral Sci*, 44: 125-127
- Saglam, AMS. (2003). The condylar asymmetry measurements in different skeletal patterns. *J Oral Rehabil*, 30: 738-742
- Schulte, TL., Hierholzer, E., Boerke, A., Lerner, T., Liljenqvist, U., Bullmann, V. & Hackenberg, L. (2008). Raster stereography versus radiography in the long-term follow-up of idiopathic scoliosis. *Journal of spinal disorders & techniques*, 21(1):23-8
- Schulze, R., Krummenauer, F., Schalldach, F. & d'Hoedt, B. (2000). Precision and accuracy of measurements in digital panoramic radiography. *Dentomaxillofac Radiol*, 29: 52-56
- Segatto, E., Jianu, R., Marschalkó, P. & Végh, A. (2006). Dentofacial features of children diagnosed with scoliosis and Scheuermann's disease. *TMJ*, 56: 259-264
- Segatto, E., Lippold, C. & Végh, A. (2008). Craniofacial features of children with spinal deformities. *BMC Musculoskelet Disord*, 9: 169
- Shah, SM. & Joshi, MR. (1978). An assessment of asymmetry in the normal craniofacial complex. *Angle Orthod*, 48: 141-148
- Solow, B. & Tallgren, A. (1976) Head posture and craniofacial morphology. *Am J Phys Anthropol*, 44: 417-435
- Solow, B. & Kreiborg, S. (1977). Soft tissue stretching: a possible control factor in craniofacial morphogenesis. *Scand J Dent Res*, 85: 505-507
- Solow, B. & Siersbaek-Nielsen, S. (1986). Growth changes in head posture related to craniofacial development. *Am J Orthod*, 89: 132-140

- Solow, B. & Sonnesen, L. (1998). Head posture and malocclusions. *Eur J Orthod*, 20: 685-693
- Stramotas, S., Geenty, JP., Petocz, P. & Darendeliler, MA. (2002). Accuracy of linear and angular measurements on panoramic radiographs taken at various positions in vitro. *Eur J Orthod*, 24: 43-52
- Tribus, CB. (1998). Scheuermann's kyphosis in adolescents and adults: diagnosis and management. *J Am Acad Orthop Surg*, 6:36-43
- Vig, PS. & Hewitt, AB. (1975). Asymmetry of the human facial skeleton. *Angle Orthod*, 45: 125-129
- Vissche, CM., Huddleston, S. Jr, Lobbezoo, F. & Naeije, M. (2000), Kinematics of the human mandible for different head postures. *J Oral Rehabil*, 27: 299-305
- Weiss, HR. & ElObeidi, N. (2009). Kyphosis angle evaluated by video rasterstereography - relation to X-ray measurements. *Scoliosis*, 4(Suppl 1):O49
- Wise, CA., Barnes, R., Gillum, J., Herring, JA., Bowcock, AM. & Lovett, M. (2000). Localization of susceptibility to familial idiopathic scoliosis. *Spine*, 25: 2372-2380
- Yamaguchi, H. & Sueishi, K. (2003). Malocclusion associated with abnormal posture. *Bull Tokyo Dent Coll*, 44: 43-54

IntechOpen



## **Orthodontics - Basic Aspects and Clinical Considerations**

Edited by Prof. Farid Bourzgui

ISBN 978-953-51-0143-7

Hard cover, 446 pages

**Publisher** InTech

**Published online** 09, March, 2012

**Published in print edition** March, 2012

The book reflects the ideas of nineteen academic and research experts from different countries. The different sections of this book deal with epidemiological and preventive concepts, a demystification of cranio-mandibular dysfunction, clinical considerations and risk assessment of orthodontic treatment. It provides an overview of the state-of-the-art, outlines the experts' knowledge and their efforts to provide readers with quality content explaining new directions and emerging trends in Orthodontics. The book should be of great value to both orthodontic practitioners and to students in orthodontics, who will find learning resources in connection with their fields of study. This will help them acquire valid knowledge and excellent clinical skills.

### **How to reference**

In order to correctly reference this scholarly work, feel free to copy and paste the following:

Emil Segatto and Angyalka Segatto (2012). Dentofacial Aspects of the Changes in Body Posture, Investigation Procedures, Orthodontics - Basic Aspects and Clinical Considerations, Prof. Farid Bourzgui (Ed.), ISBN: 978-953-51-0143-7, InTech, Available from: <http://www.intechopen.com/books/orthodontics-basic-aspects-and-clinical-considerations/dentofacial-aspects-of-the-changes-in-body-posture-investigation-procedures>

**INTECH**  
open science | open minds

### **InTech Europe**

University Campus STeP Ri  
Slavka Krautzeka 83/A  
51000 Rijeka, Croatia  
Phone: +385 (51) 770 447  
Fax: +385 (51) 686 166  
[www.intechopen.com](http://www.intechopen.com)

### **InTech China**

Unit 405, Office Block, Hotel Equatorial Shanghai  
No.65, Yan An Road (West), Shanghai, 200040, China  
中国上海市延安西路65号上海国际贵都大饭店办公楼405单元  
Phone: +86-21-62489820  
Fax: +86-21-62489821

© 2012 The Author(s). Licensee IntechOpen. This is an open access article distributed under the terms of the [Creative Commons Attribution 3.0 License](https://creativecommons.org/licenses/by/3.0/), which permits unrestricted use, distribution, and reproduction in any medium, provided the original work is properly cited.

IntechOpen

IntechOpen