

# We are IntechOpen, the world's leading publisher of Open Access books Built by scientists, for scientists

6,900

Open access books available

186,000

International authors and editors

200M

Downloads

Our authors are among the

154

Countries delivered to

TOP 1%

most cited scientists

12.2%

Contributors from top 500 universities



WEB OF SCIENCE™

Selection of our books indexed in the Book Citation Index  
in Web of Science™ Core Collection (BKCI)

Interested in publishing with us?  
Contact [book.department@intechopen.com](mailto:book.department@intechopen.com)

Numbers displayed above are based on latest data collected.  
For more information visit [www.intechopen.com](http://www.intechopen.com)



## Three-Dimensional Imaging and Software Advances in Orthodontics

Ahmed Ghoneima<sup>1,2</sup>, Eman Allam<sup>1</sup>, Katherine Kula<sup>1</sup> and L. Jack Windsor<sup>1</sup>

<sup>1</sup>*Indiana University School of Dentistry, Indianapolis,*

<sup>2</sup>*Faculty of Dental Medicine, Al-Azhar University, Cairo*

<sup>1</sup>*USA*

<sup>2</sup>*Egypt*

### 1. Introduction

The technological advances and innovations of imaging systems for orthodontic practice require a continuous update of their applications and assessments of their strength and weakness, as well as guidelines for utilization. Orthodontists are challenged by the increasing number and complexity of these systems and softwares. Accurate diagnostic imaging is an essential requirement for the optimal diagnosis and treatment planning of orthodontic patients. In addition, it is a critical tool that allows the clinician to monitor and document the treatment progress and outcome. The purpose of this chapter is to update orthodontists about the current options and applications of the latest imaging techniques in orthodontic practice and to review the existing software advances.

### 2. Cone beam technology in orthodontics

The cone-beam computed tomography (CBCT) scanners were introduced in the late 1990s. Shortly after, the US Food and Drug Administration (FDA) approved the first CBCT unit in 2001. Since then, there has been an enormous interest in this new technology for its clinical and research applications. The CBCT is an imaging acquisition technique that utilizes a volumetric scanning machine. This technology is based on a cone-shaped X-ray beam directed at a flat two-dimensional (2D) detector. As both rotate around the patient's head, a series of 2D images are generated. The software then reconstructs the images into three-dimensional (3D) data set using a specialized algorithm (De Vos et al., 2009; Molen, 2011).

Currently, there are more than 43 CBCT systems from 20 different companies available commercially. The most commonly used of these CBCT imaging acquisition systems are the 3D Accuitomo (J. Morita, Kyoto, Japan), CB MercuRay (Hitachi Medical Corporation, Osaka, Japan), iCAT (Imaging Sciences International, Hatfield, PA), Galileos (Sirona Dental Systems LLC, Charlotte, NC), New-Tom 3G (QR srl, Verona, Italy), Scanora 3D (SOREDEX, Milwaukee, WI), and Kodak 9500 (Kodak Dental Systems, Rochester, NY). There are big variations in the quality and characteristics of the images or the reconstructed volumes and the radiation doses between most of these CBCT systems. Machines with reduced radiation doses and less powerful tubes are often associated with poor image quality, low contrast

resolution and increased noise. The exposure parameters, the source-detector distance, the field of view (FOV), the data reconstruction algorithm, and the software used are among the major factors responsible for those variations. The currently available CBCT units utilize radiation doses ranging from 87 to 206  $\mu\text{Sv}$  for a full craniofacial scan. These radiation doses are slightly higher than the conventional radiographic techniques such as the lateral cephalograms or the panoramic radiographs and markedly lower than that of multi-slice CT. The scan time varies between 10 to 75 seconds, depending on the FOV and the CBCT unit used (Molen, 2011; Kapila et al., 2011).

Craniofacial imaging is a crucial component of an orthodontic patient's record. The gold standard for orthodontic records is the attempt to achieve an accurate replication of the real anatomical structures or the "anatomic truth". Although the use of the traditional imaging views in orthodontics has been adequate, the achievement of the ideal imaging goal of replicating the anatomic truth has been limited by the available technology such as the 2D frontal and lateral cephalograms, panoramic radiographs, and intraoral/extraoral photographs. Recently, more emphasis has been placed on the CBCT technology, the 3D images, and virtual models. The main advantage for the use of CBCT is that the clinician can get more accurate data from one scan than from the many 2D radiographs traditionally used with less radiation exposure (Mah & Hatcher, 2005) (Figure 1).

The 3D CBCT data can greatly expand the orthodontist's diagnostic capabilities. It offers a comprehensive evaluation of the dentition and is very useful for identifying abnormalities such as missing teeth, supernumerary teeth, eruption disturbances, teeth malpositions, and/or root irregularities that could delay or prevent tooth movement. CBCT can be considered the technique of choice for examining and localizing impacted teeth. The exact position of impacted tooth and its relations to the adjacent roots or important anatomical structures such as the maxillary sinus or the mandibular canal when planning surgical exposure and subsequently orthodontic management can be precisely assessed by 3D CBCT (Mah et al., 2011) (Figures 2 and 3).

Using CBCT scans, alveolar bone can be assessed from all aspects not only on the mesial and distal surfaces of the tooth. This allows for the assessment of the width of available bone for buccolingual movement of teeth during orthodontic management especially in cases requiring arch expansion or labial movement of incisors. Fenestrations, dehiscence, and/or external apical root resorption can be precisely visualized on the 3D images. Evaluation of alveolar bone volume, which is especially important in periodontally compromised adult orthodontic patients, is one of the beneficial uses of CBCT in orthodontics. The width of alveolar ridges for placement of implants is another variable that can be investigated (Halazonetis, 2005; Valiathan et al., 2008).

Preoperative implant site assessment is probably one of the most useful applications of CBCT in orthodontics. In the orthodontic field, osseo-integrated implants are either used for anchorage or as a prosthetic replacement of missing teeth. The accurate determination of root angulations and the available space are essential for successful placement of the implant. CBCT can be used to accurately assess the space availability and root angulation, as well as the 3D quantification of the alveolar bone at the implant site (Mah & Hatcher, 2005) (Figure 4).

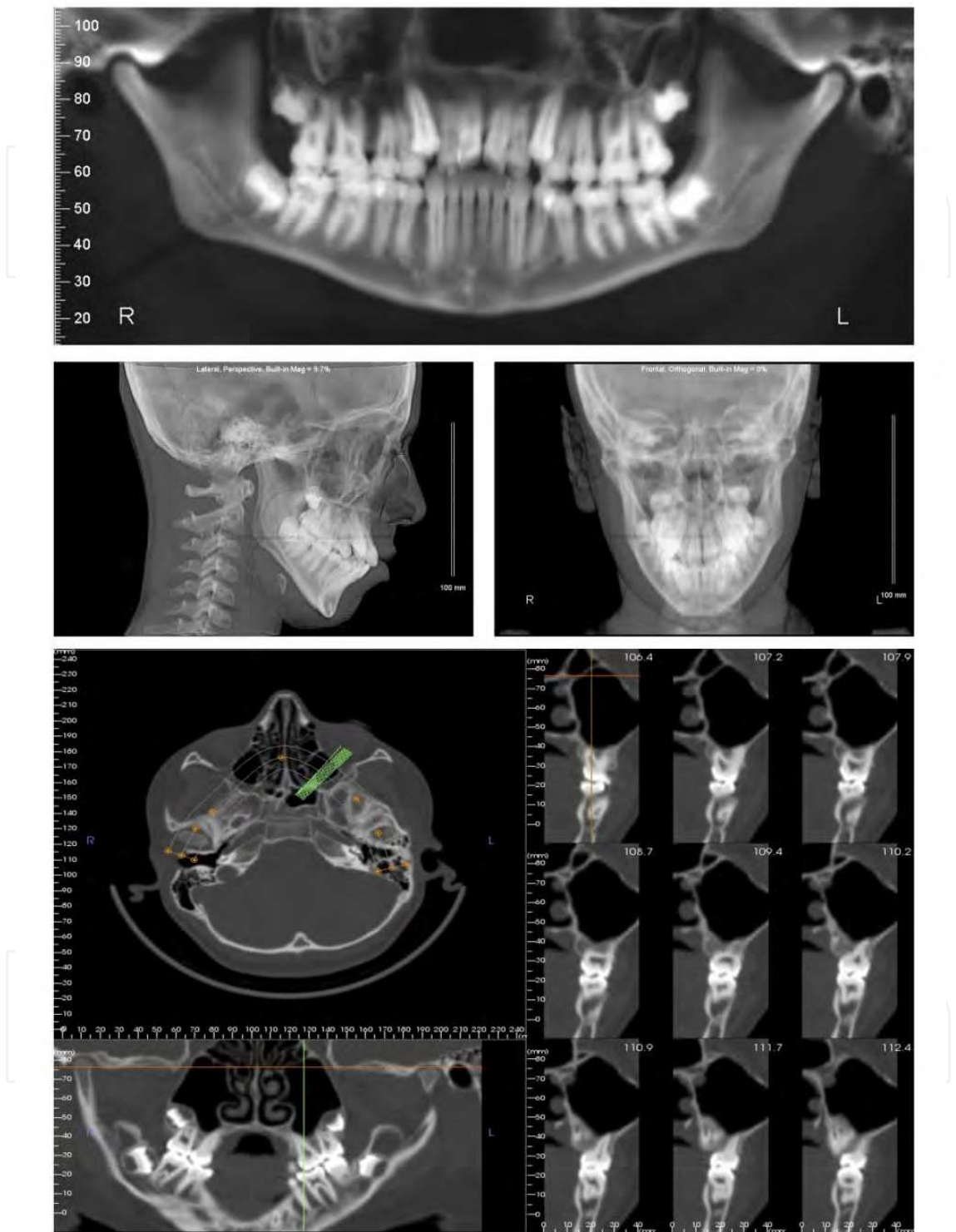


Fig. 1. CBCT data can be easily reconstructed into traditional panoramic, lateral, or postero-anterior cephalometric images, as well as cross section views. In this way, the clinician can get more information from the scan than from multiple 2D radiographs with less radiation exposure. Images created by the Dolphin and InVivoDental softwares from a single CBCT scan.



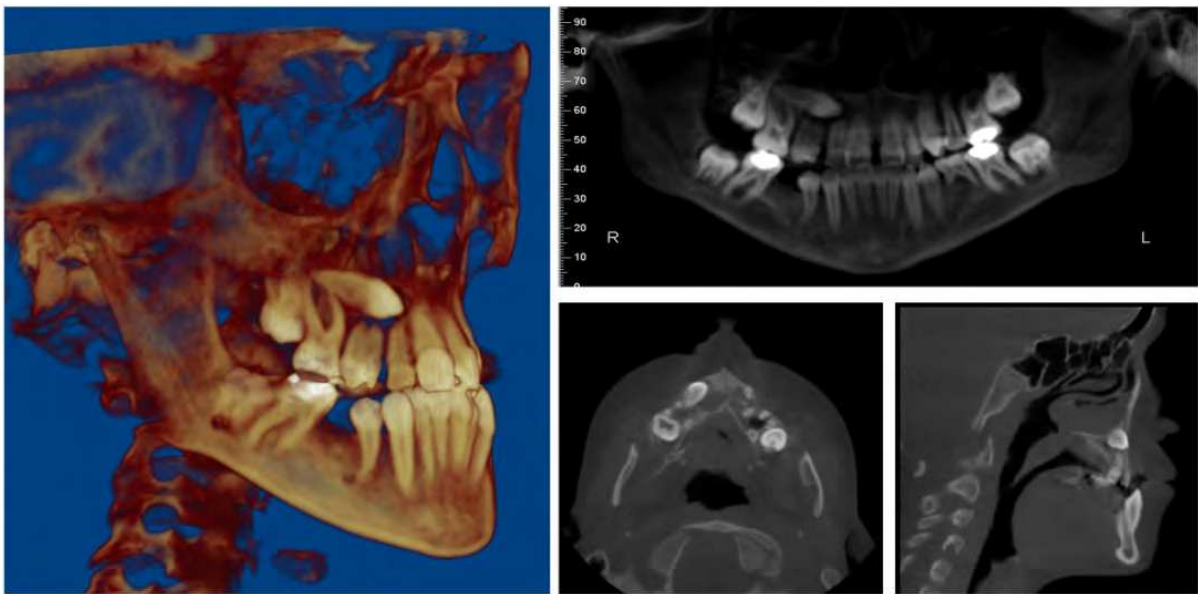


Fig. 2. A 15 years old female with impacted canine that was initially diagnosed on the panoramic radiograph, but could not be precisely located in relationship to the present teeth. Using the axial and sagittal sections of the CBCT data, the labial location could be confirmed. In addition, the 3D volume allowed for viewing the impacted canine from any angle.

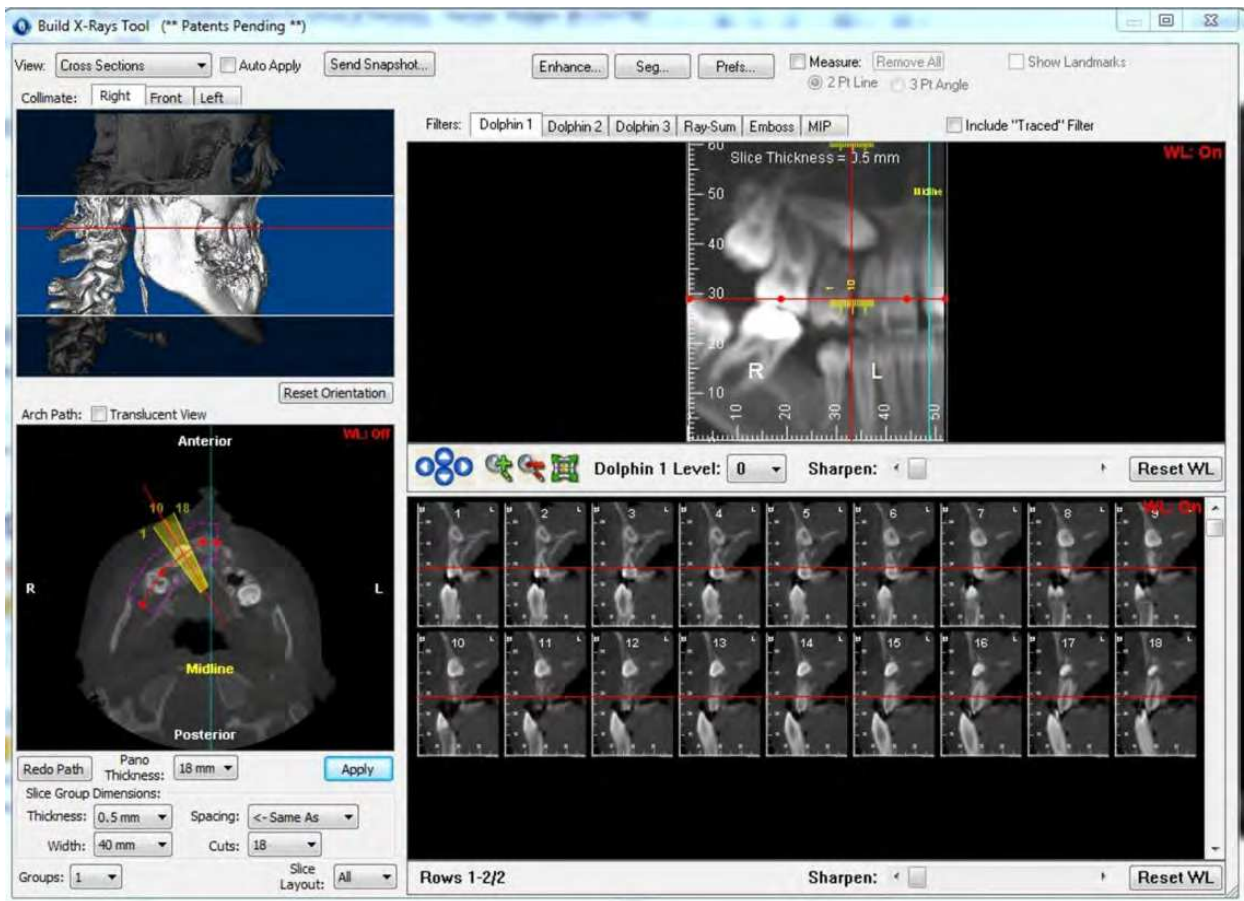


Fig. 3. Cross section view for the impacted canine allowed for the evaluation of its location and relationship to other structures slice by slice in 1 view (slice thickness 0.5 mm).

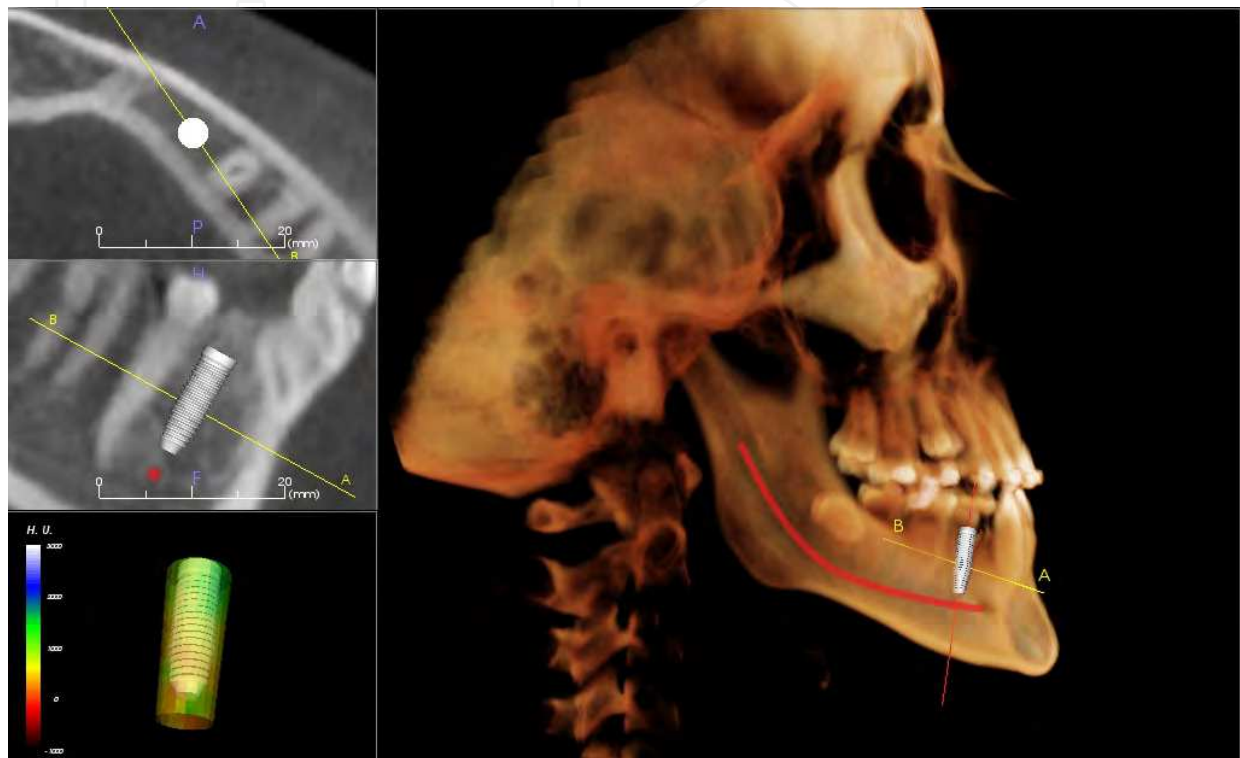


Fig. 4. Axial and sagittal sections showing the buccal and lingual bone thickness, as well as the relationship between the implant and the inferior alveolar nerve (labeled in red color). The 3D view is important in the evaluation of space availability.

Orthodontic patients with temporomandibular joint (TMJ) disorders are common. When these disorders occur during development, they may alter the facial growth pattern and may also affect the growth of the ipsilateral part of the mandible with compensations in the maxilla, tooth position, occlusion, and cranial base. CBCT allows the clinicians to assess and quantify these changes associated with TMJ disorders more accurately than the 2D images as these changes occur in the vertical, horizontal, and transverse directions. CBCT is especially indicated when more information about the morphology and internal structure of the osseous components of the TMJ is required. Studies have shown that CBCT images provide higher reliability and accuracy than CT and panoramic radiographs in the detection of condylar cortical erosion. CBCT images also allow for the visualization of the TMJs from different views and efficient evaluation of its relationship to the dentition and occlusion (Huang, et al., 2005; Hilgers et al., 2005; Honey et al., 2007) (Figure 5).





The digital models allow the clinician to obtain additional diagnostic information that are not available with the use of the plaster models such as root shape, position, and angulations. The relationship of the roots to anatomic structures such as the mandibular nerve, as well as quantitative bone density information, can also be evaluated. Crown to root ratios can be estimated and other different dental measurements can be performed easily. Several studies have proved that the digital models created from CBCT scans or obtained from laser scanning of a dental impression or study model are as accurate and as reliable as plasters models (Dalstra & Melsen, 2009; Hernandez-Soler et al., 2011). Perhaps a major advantage of the digital models is the virtual setup capability with complete 3D anatomy by including the roots and the alveolar bone. The virtual setup provides superior case presentation, treatment simulation, aesthetic predictions, and results visualization. It also allows for including the torque and labiolingual inclination calculations in the dental setup (Hernandez-Soler et al., 2011) (Figures 6 and 7).

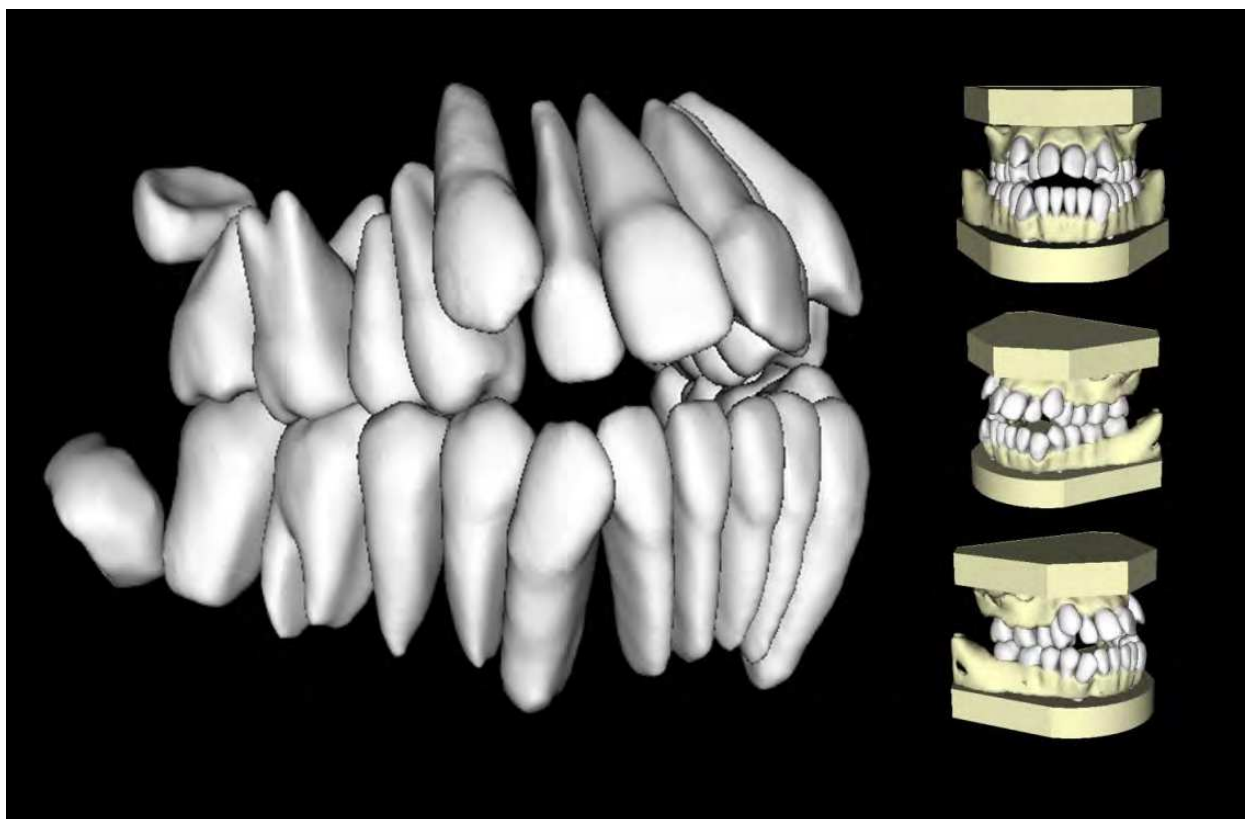


Fig. 6. Computer-generated models reconstructed from the digital imaging and communications in medicine (DICOM) data using the InVivoDental software showing not only the crowns of the teeth but also the roots.



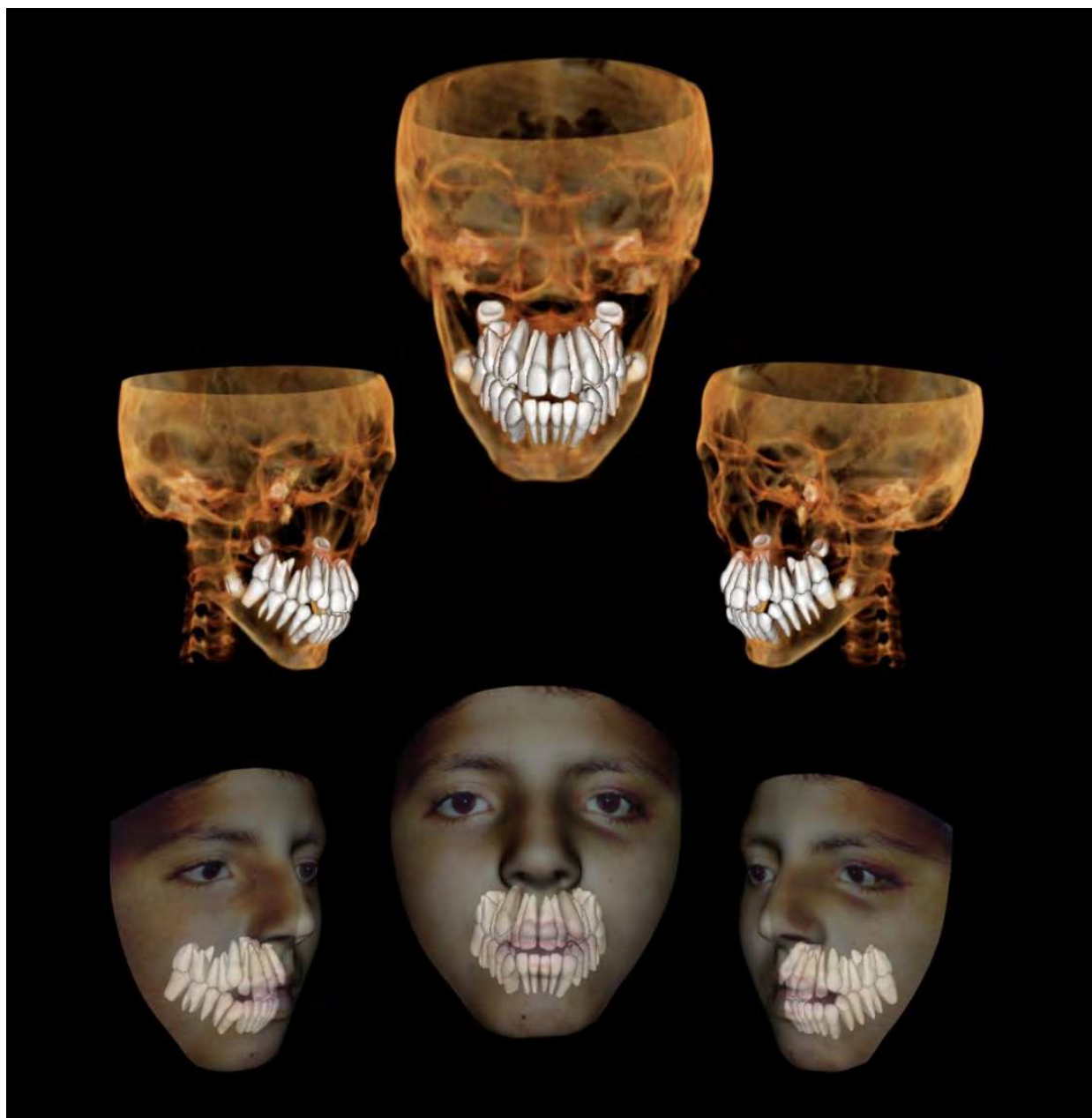


Fig. 7. Dual volume superimposition: the digital model superimposed on a 3D skull volume and a 3D facial photograph provides an excellent tool for treatment simulation and for the evaluation of the anatomical relationships between the teeth, the skeletal, and the soft tissues.

### 3. Cone beam computed tomography and airway analysis

Airway disorders are a common cause of malocclusions and might result in the classical appearance of adenoid facies. The results of a retrospective review of 500 orthodontic patients showed that 18.2 percent of the patients had airway-related problems. Variations in airway morphology and dimensions are commonly related to hereditary or functional disorders. Despite the cause or the effect, any airway problem has to be properly diagnosed and treated as soon as it is identified. Methods that are traditionally used to assess the

airway include cephalometry, rhinoendoscopy, and tomography (Subtenley & Baker, 1965; Fujiki & Rossato, 1999; Filho et al., 2001; Abramson et al., 2010).

Mandibular advancement device, tongue retraining device, and a continuous positive airflow pressure appliance are the most common orthodontic therapeutic options for patients with breathing disorders. The assessment of the patient's airway plays a primary role in planning the management strategy, especially in patients suffering from mouth breathing, adenoid hypertrophy, or sleep apnea. The 2D lateral cephalograms offer limited information due to the difficulty in identifying the soft tissue contour in the third dimension thus restricting evaluation of areas and volumes. Currently, there appears to be no better way to assess the airway than by using CBCT imaging (Halazonetis, 2005; Aboudara et al., 2009).

3D CBCT images offer accurate representation of the airway. The CBCT data with the use of different software systems allows better visualization, volumetric measurements, and patency assessment of the airway, as well as the precise distinction between the soft tissues and the airway space. Several studies questioned the reliability of the 3D methods and indicated high reliability and accuracy of area and volume measurements using this technique. Clinicians can more easily perform the volumetric measurements and also calculate the cross-sectional areas of the airway in 3 planes of space: coronal, sagittal, and axial. In addition, the option provided by some softwares for detecting and measuring the most constricted area in the airway provides essential diagnostic clinical information especially in obstructive sleep apnea patients (Ogawa et al., 2007; Aboudara et al., 2009; Abramson et al., 2010) (Figures 8 and 9).

#### 4. 3D cephalometry

Cephalometric analysis in orthodontics is an important diagnostic tool for the assessment of craniofacial morphology. The lateral cephalograms enable orthodontists to determine the size and shape of the jaws, their position in sagittal and vertical relation to the anterior base of the skull, and their position in relation to each other. An analytical method is used to identify and analyze the necessary parameters. It involves determining hard tissue and soft tissue landmarks, and making angular and linear measurements. The information provided by the lateral cephalogram about the vertical and sagittal structure of the facial skull cannot be obtained by any other diagnostic measure. However, cephalometric measurements on the 2D images suffer from several limitations such as the difficulty in locating some reference points and landmarks, image distortion, differences in magnifications, superimposition of the bilateral craniofacial structures, and measurement errors. Another important drawback of lateral and frontal cephalograms is the lack of information about cross-sectional area and volume (Adams et al., 2004; Lenza et al., 2010).

CBCT provide a 3D method for cephalometric analysis (Figure 10). Compared with the traditional cephalometric radiographs, the CBCT produces images that are anatomically true (real-size 1:1 scale) with accurate volumetric 3D depiction of hard and soft tissues of the skull and lack of superimposition of the anatomical structures. Other advantages of this method over the 2D cephalometric analysis include the reduced radiation exposure (as the 3D visualization software generates a 2D lateral image from the 3D data set) and the high precision of the linear and angular measurements obtained. Reliability studies demonstrated that cephalograms reconstructed from CBCT data have no statistically significant differences

in linear and angular measurements relative to traditional cephalograms, whereas measurement error from CBCT images are lower than those from cephalograms (Kumar et al., 2007; Moshiri et al., 2007; Kumar et al., 2008).

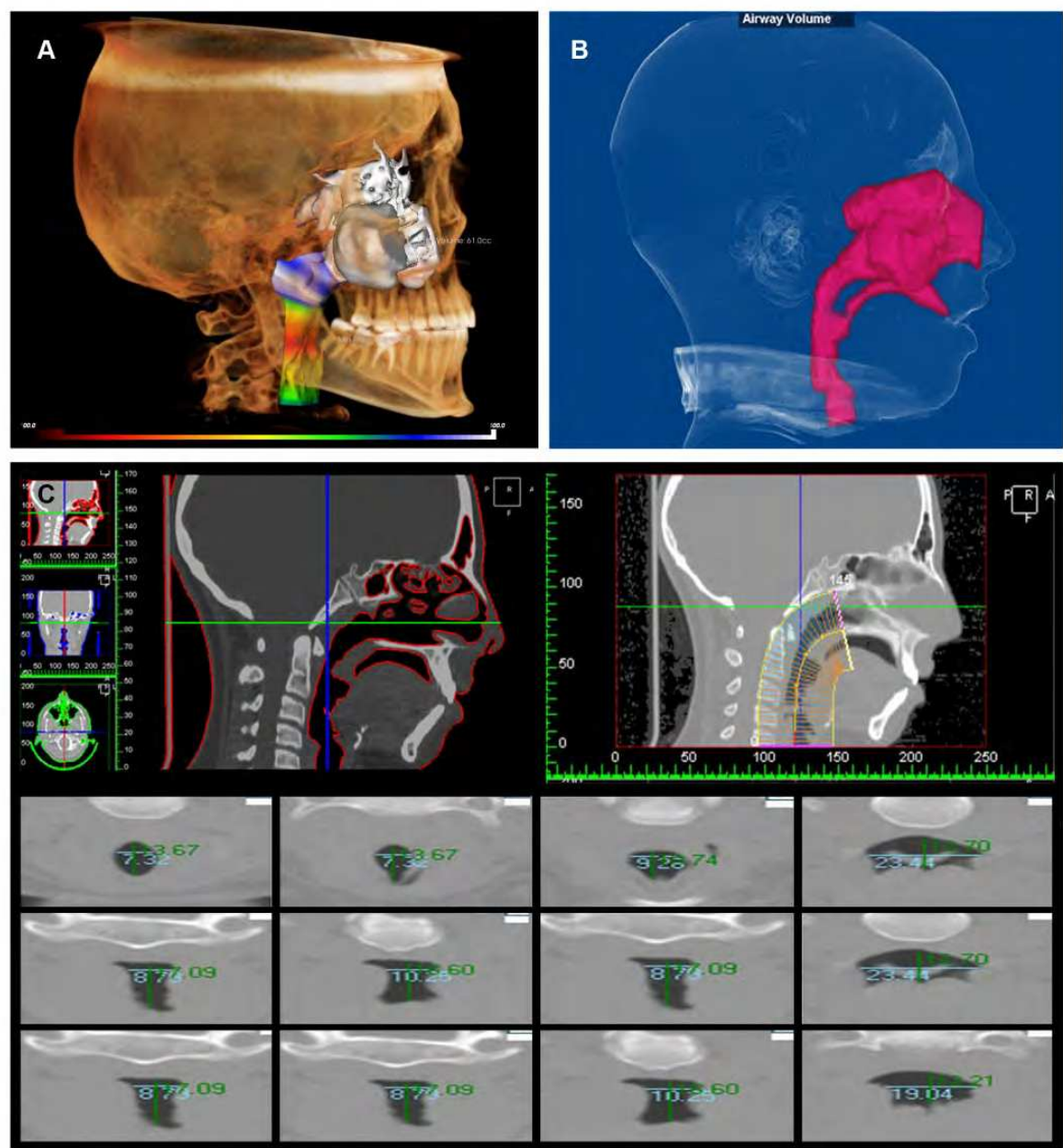


Fig. 8. Volumetric measurements of the airway can be done using different softwares each with a different way of performing the calculations. A) using the InVivoDental software (Anatomage Inc, San Jose, CA), the operator first manually trace the airway passage and then the software will calculate it selectively, B) total airway volume can be calculated by filling in the airway space automatically using the Dolphin software (Dolphin Imaging & Management solutions, Chatsworth, CA), and C) using 3dMD software (3dMD LLC, Atlanta, GA), segmentation for the airway is done first and then the selected areas to be measured will be automatically turned up to a multiple axial slices and the software will calculate the height and width of each slice and give the total airway volume.



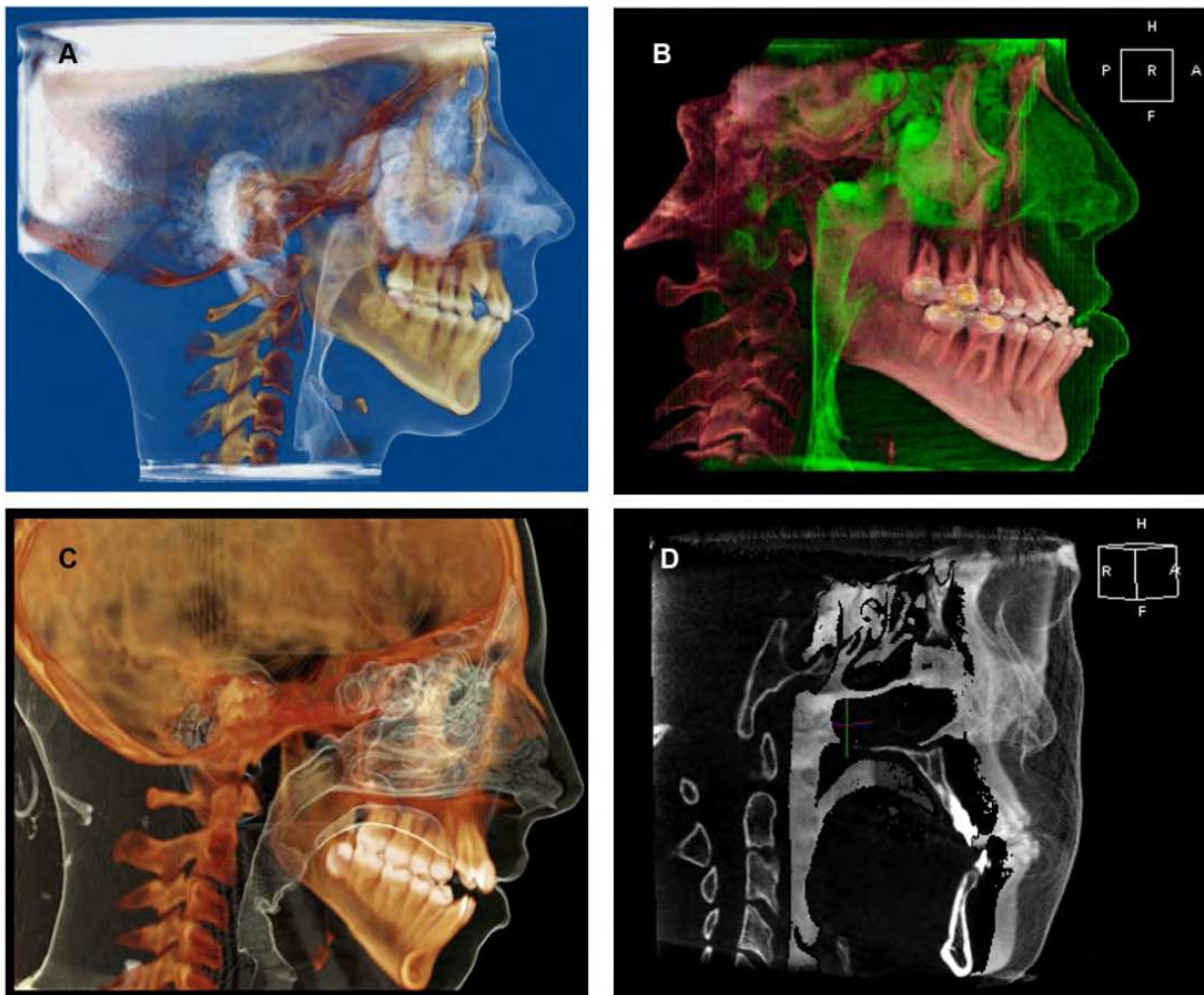


Fig. 9. Volume-rendered CBCT images for the airway in either color enhanced form (A, B, and C) or shaded form (D) where the colors or the shadow are used to aid better visualization and assessment of the airway, as well as correlations with the surrounding head and neck structures. Images generated using the Dolphin software (A), 3dMD (B and D), and InVivoDental (C).

For 3D cephalometry, the anatomical landmarks are identified on 3D surface-rendered volumes or models obtained from CBCT data. In the tracing step, cephalometric planes are defined using either three or four landmarks instead of the two landmarks traditionally used in 2D cephalometry. Beside the elimination of the superimposition of bilateral structures and unequal enlargement artifacts, this also allows for the evaluation of the right and the left sides of the skull independently. The quality and the visibility of the 3D cephalometric landmarks and parameters vary among the different scanners and depend mainly on the scan field of view (FOV) selection, the 3D model segmentation threshold, and image artifacts (Swennen & Schutyser, 2006; Halazonetis, 2005).



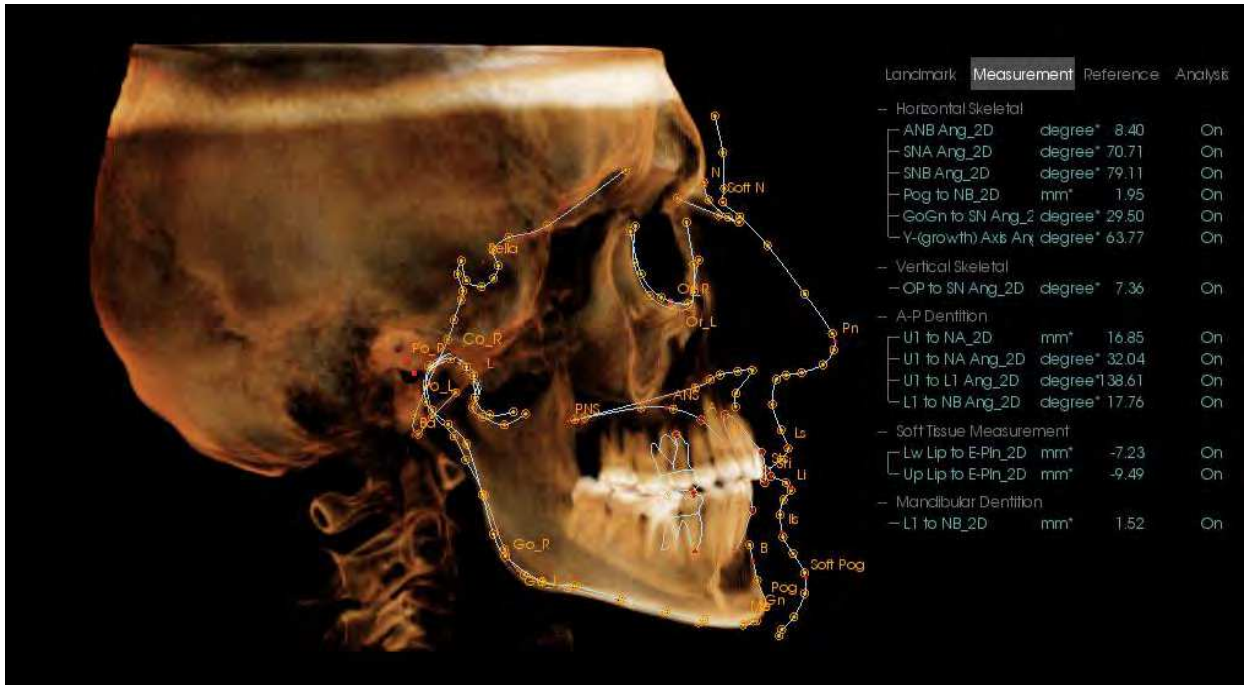


Fig. 10. Linear and angular parameters used for 3D cephalometric analysis (InVivoDental software).

5. 3D superimposition

One of the main advantages of the CBCT is that it allows superimposition of serial images to evaluate the growth and treatment changes. This is an efficient way for showing areas of bone displacement and remodeling, as well as demonstrating the changes in size, shape, and shift in positions of skeletal and soft tissues as a result of either orthodontic or surgical treatments. The 2D cephalograms have been traditionally used to evaluate these growth or treatment changes based on stable reference structures or anatomical landmarks. The traditional approach to lateral cephalometric superimposition is based on using the most stable anatomical landmarks. For example, the sella turcica for the cranial base registration, the lingual curvature of the palate for the maxillary bony structures, the internal cortical outline of the symphysis, and the mandibular canal for the mandible. However, a major limitation of the 2D representation of a 3D structure with the difficulty in identification of the landmarks is due to the superimposition of multiple structures. In contrast, 3D images provided easier and more accurate anatomical landmark registration (Cevitanes et al., 2005; Lagravere et al., 2006).

The available software tools and options allow optimal alignment of the 3D CBCT datasets at different time points with high precision and accuracy after identification of specific anatomical landmarks and structures. The computed registration is then applied to the segmented structures to measure changes due to orthodontic treatment or surgery. Surface distance calculations are then used for the purpose of accurate quantification of the changes or displacement due to either growth or treatment. Color mapping can show surface area distance differences between two 3D objects or 3D facial photographs (Cevitanes et al., 2005) (Figures 11, 12, and 13).

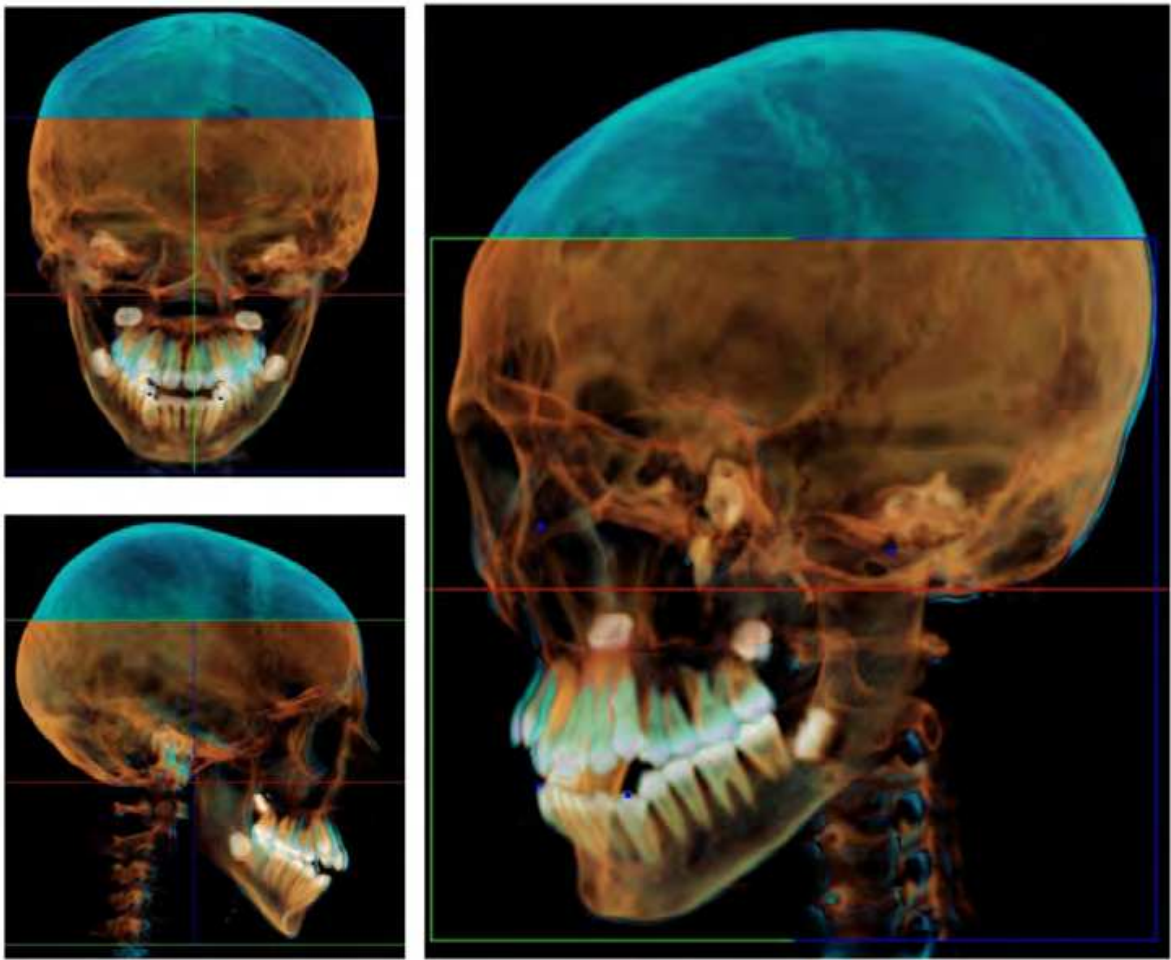


Fig. 11. Demonstration of superimposition of the pre- (brown) and post - (blue) treatment skull models of a 12 years old patient treated with rapid maxillary expansion for a constricted maxillary arch. The use of different colors highlights the changes between the two scans.

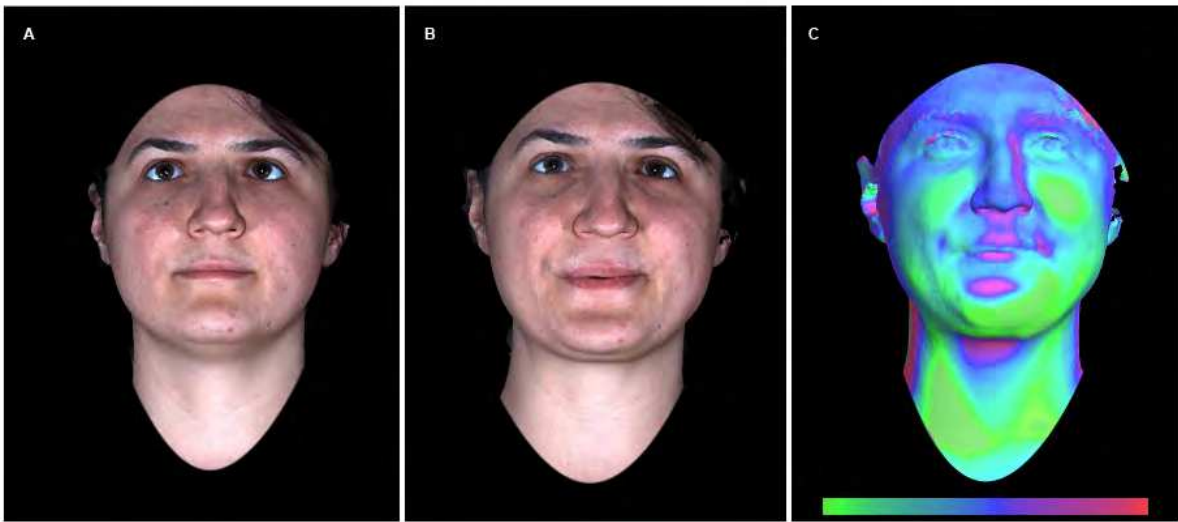


Fig. 12. Three-dimensional facial photograph of a trumpet player: in the rest position (A), during blowing (B), and color mapping (C) used to demonstrate the differences between the two positions.

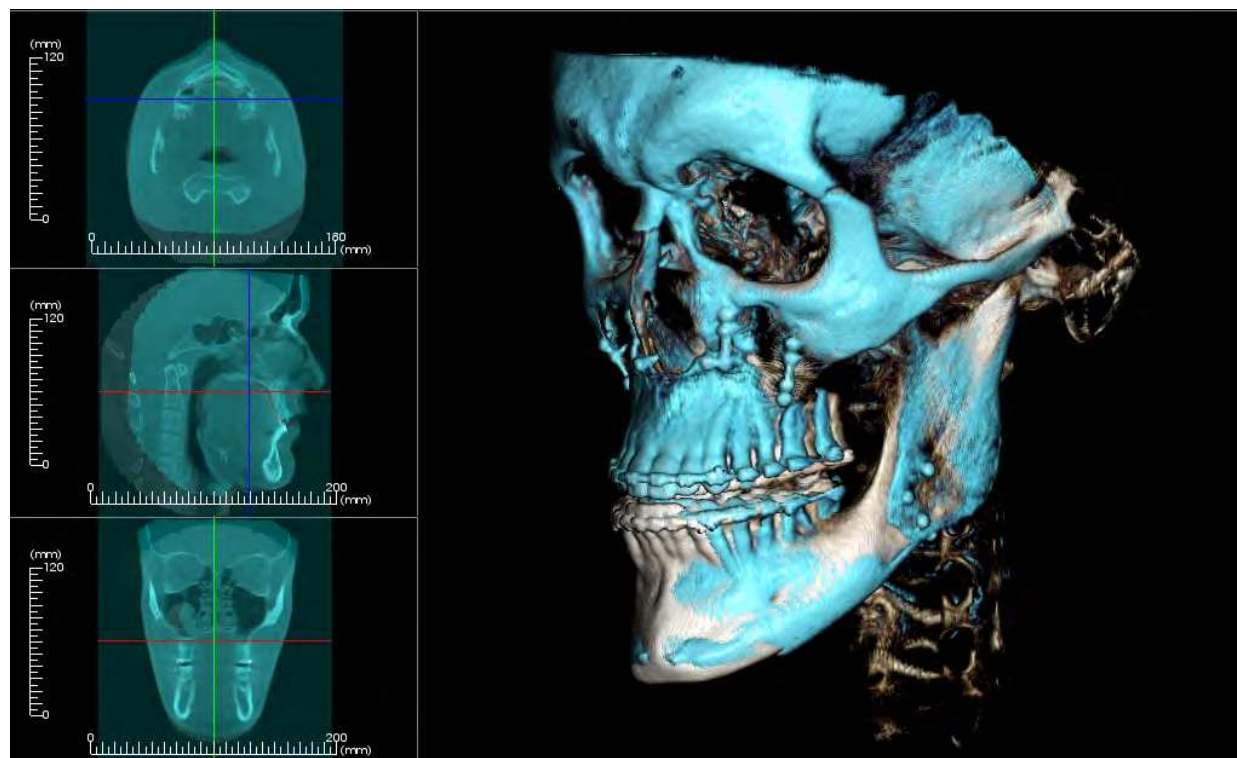


Fig. 13. The changes and shift in position of skeletal structures resulting from orthognathic surgery for correction of mandibular prognathism in 23 years old female patient demonstrated by superimposition of serial 3D images of skull volumes using 2 different color codes.

## 6. 3D facial photographs

With the introduction of a new system and software, the applicability of 3D photographs in daily orthodontic practice became possible. Photographic soft tissue profile analysis, evaluation of the craniofacial growth and development, orthodontic diagnosis, and measurements of the aesthetic facial parameters can all be professionally performed on these photographs.

One of the gold standard diagnostic tools in orthognathic surgery and preoperative orthodontic treatment is the 2-D facial photographs that consequently reveal limitations in describing the 3D structures of a patient's face. CBCT and the newly introduced imaging techniques such as the 3D stereophotogrammetry (3D photographs) allows exploring the human face 3-dimensionally with multiple useful applications that ranges from using the facial scans to measure all the aesthetic facial parameters to orthodontic diagnosis and evaluation of the craniofacial growth and development (Lane & Harrell, 2008).

Stereophotogrammetry is a method of obtaining an image by means of one or more stereo pairs of photographs being taken simultaneously. The 3D photo camera is used to capture the soft tissue surface of the face with correct geometry and texture information. The technique is based on the triangulation and fringe projection method. Image fusion (i.e., registration of a 3D photograph upon a CBCT) results in an accurate and photorealistic digital 3D data set of a patient's face (Maal et al., 2008).



The registration of pre- and post-operative 3D photographs has many important applications, which mainly include the evaluation of treatment outcomes in orthognathic surgery or orthodontic treatment. After registration or matching of the 3D photographs, the differences between the pre- and post-photographs can be visualized by a color scale or map. In this way, results of the treatment can be evaluated quantitatively and objectively. Other useful applications of comparing different 3D photographs are the evaluation of pathological lesions or swelling such as abscess or tumors over time, cross-sectional growth changes, and the establishment of databases for normative populations. For clinical use, the registration process of pre- and post-treatment 3D photographs has to be very accurate (Metzger et al., 2007; Maal et al., 2010).

One of the recently introduced software features allow the facial photograph to be morphed onto a digital imaging and communications in medicine (DICOM) dataset where the 3D volume can generate a simulated 3D projection of the face in any frontal, lateral, or user-defined view of the face. By changing the translucency of the image, the correlation between the facial soft tissues to the skeleton can be determined. This has great implications in planning orthognathic surgery, orthodontic treatment, or other craniofacial therapies that could affect the facial appearance (Harrell, 2009; Schendel & Lane, 2009) (Figure 14).

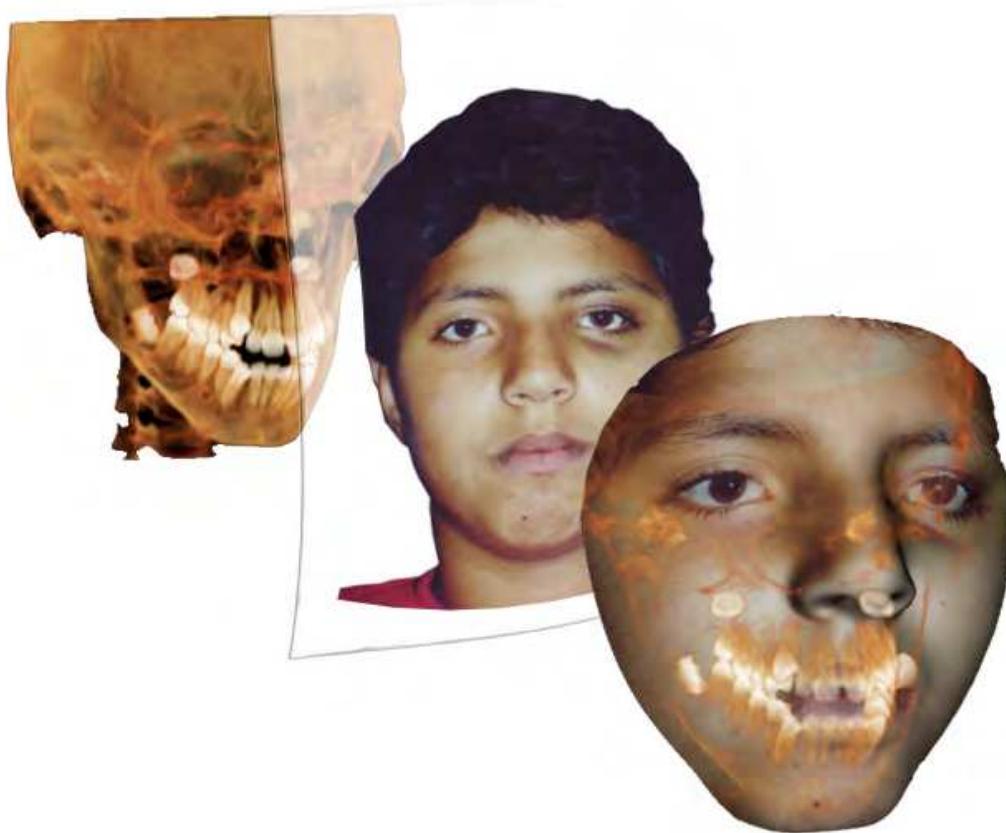

Fig. 14. Facial photographs morphed onto 3D skeletal volume can be used for measurements of the aesthetic facial parameters and soft tissue profile analysis, as well as treatment simulation.



## 7. Conclusion

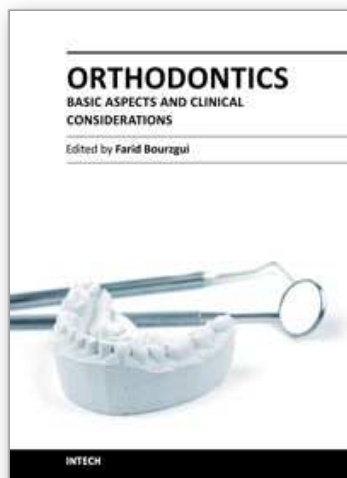
CBCT has become widely available and acceptable by the orthodontic community especially as the radiation exposure and cost decreases. The continuous advancements in the imaging machines, techniques, and softwares have added valuable improvement in its diagnostic capabilities. In addition, the ease of image manipulation and its relevancy to the clinical setting offers orthodontists and clinicians the chance for improved diagnosis. Craniofacial imaging is expected to become totally digital in the near future. The orthodontic community needs to increase their knowledge, and evaluate its clinical relevancy and reliability, as well as consider its other applications.

## 8. References

- Aboudara, C., Nielsen, I. & Huang, J. (2009). Comparison of human airway space using conventional lateral headfilms and three-dimensional reconstruction from cone-beam computed tomography. *Am J Orthod Dentofac Orthop* 135:468-479.
- Abramson, Z., Susarla, S., August, M., Troulis, M. & Kaban, L. (2010). Three-dimensional computed tomographic analysis of airway anatomy in patients with obstructive sleep apnea. *J Oral Maxillofac Surg* 68:354-362.
- Adams, G., Gansky, S., Miller, A., Harell, W. & Hatcher D. (2004). Comparison between traditional 2-dimensional cephalometry and a 3-dimensional approach on human dry skull. *Am J Orthod Dentofac Orthop* 126:397-409.
- Cevidanes, L., Bailey, L. & Tucker, GR.(2005). Superimposition of 3D cone-beam CT models of orthognathic surgery patients. *Dentomaxillofac Radiol* 34:369-375.
- Cevidanes, L., Oliveira, A., Grauer, D., Styner, M. & Proffit, W. (2011). Clinical application of 3D imaging for assessment of treatment outcomes. *Semin Orthod* 17:72-80.
- Dalstra, M. & Melsen, B. (2009). From alginate impressions to virtual digital models. *J Orthod* 36:36-41.
- De Vos, W., Casselman, J. & Swennen, G. (2009). Cone-beam computerized tomography (CBCT) imaging of the oral and maxillofacial region: A systemic review of the literature. *Int J Oral Maxillofac Surg* 38(6):609-25.
- Enciso, R., Memon, A. & Fidaleo, D. (2003). The virtual craniofacial patient: 3D jaw modeling and animation. *Stud Health Technol Inform* 94:65-71.
- Filho, D., Raveli, D., Raveli, R., De Castro, L. & Gandin, L. (2001). A comparison of nasopharyngeal endoscopy and lateral cephalometric radiography in the diagnosis of nasopharyngeal airway obstruction. *Am J Orthod Dentofac Orthop* 120:348-352.
- Fujiki, P. & Rossato, C. (1999). Influencia da hipertrofia adenoideana no crescimento e desenvolvimento craniodentofacial. *Ortodontia* 32:70-79.
- Halazonetis, D. (2005). From 2-dimensional cephalograms to 3-dimensional computed tomography scans. *Am J Orthod Dentofac Orthop* 127: 627-637
- Harrell, W. (2009). 3D diagnosis and treatment planning in orthodontics. *Semin Orthod* 15:35-41.
- Hernandez-Soler, V., Enciso, R. & Cisneros, G. (2011). The virtual patient specific-model and the virtual dental model. *Semin Orthod* 17:46-48.
- Hilgers, M., Scarfe, S. & Scheetz, J. (2005). Accuracy of linear temporomandibular joint measurements with cone beam computed tomography and digital cephalometric radiography. *Am J Orthod Dentofacial Orthop* 128:803-811.

- Honey, O., Scarfe, W. & Hilgers, M. (2007). Accuracy of cone-beam computed tomography imaging of the temporomandibular joint: Comparisons with panoramic radiology and linear tomography. *Am J Orthod Dentofacial Orthop* 132:429-438.
- Huang, J., Bumann, A. & Mah, J. (2005). Three dimensional radiographic analysis in orthodontics. *JCO* 7:421-428.
- Kapila, S., Conley RS. & Harrell, Jr. (2011). The current status of cone beam computed tomography imaging in orthodontics. *Dentomaxillofacial Radiology* 40:24-34.
- Kumar, V., Ludlow, J., Mol, A. & Cevdanes, L. (2007). Comparison of conventional and cone beam CT synthesized cephalograms. *Dentomaxillofacial Radiology* 36: 263-269
- Kumar, V., Ludlow, J., Cevdanes, L. & Mol, A. (2008). In vivo comparison of conventional and cone beam CT synthesized cephalograms. *Angle Orthodontist* 78: 873-879
- Lagravere, M., Hansen, L., Harzer, W. & Major, P. (2006). Plane orientation for standardization in 3-dimensional cephalometric analysis with computerized tomography imaging. *Am J Orthod Dentofac Orthop* 129:601-4.
- Lane, C. & Harrell, W. (2008). Completing the 3-dimensional picture. *Am J Orthod Dentofac Orthop* 133:612-20.
- Lenza, M., Lenza, MM., Dalstra, M., Melsen, B. & Cattaneo, PM. (2010). An analysis of different approaches to the assessment of upper airway morphology: a CBCT study. *Orthod Craniofac Res* 13:96-105.
- Maal, T., Plooi, J., Rangel, F., Mollemans, W., Schutyser, F. & Berge, S. (2008). The accuracy of matching three-dimensional photographs with skin surfaces derived from cone-beam computed tomography. *J Oral Maxillofac Surg* 37:641-646.
- Maal, T., Loon, B., Plooi, J., Rangel, F., Ettema, A., Borstlap, W. & Berge, S. (2010). Registration of 3-dimensional facial photographs for clinical use. *J Oral Maxillofac Surg* 68:2391-2401.
- Mah, J. & Hatcher, D. (2005) Craniofacial imaging in orthodontics. In: Graber, TM., Vanarsdall, RL. & Vig, KWL., editors. *Orthodontics, current principles and techniques*. 4th ed. St Louis: Mosby.
- Mah, J., Yi, L., Huang, R. & Choo, H. (2011). Advanced applications of cone beam computed tomography in orthodontics. *Semin Orthod* 17:57-71.
- Metzger, MC., Hohlweg-Majert, B. & Schon, R. (2007). Verification of clinical precision after computer-aided reconstruction in craniomaxillofacial surgery. *Oral Surg Oral Med Oral Pathol Oral Radiol Endod* 104:e1.
- Molen, A. (2011). Comparing cone beam computed tomography systems from an orthodontic perspective. *Semin Orthod* 17:34-38.
- Moshiri, M., Scarfe, W., Hilgers, M., Scheetz, J., Silveira, A. & Farman, A. (2007). Accuracy of linear measurements from imaging plate and lateral cephalometric images derived from cone-beam computed tomography. *Am J Orthod Dentofac Orthop* 132: 550-560
- Ogawa, T., Enciso, R., Shintaku, W. & Clark, G. (2007). Evaluation of cross-section airway configuration of obstructive sleep apnea. *Oral Surg Oral Med Oral Pathol Oral Radiol Endod* 103:102-8.
- Schendel, S. & Lane, C. (2009). 3D orthognathic surgery simulation using image fusion. *Semin Orthod* 15:48-56.

- Subtelney, J. & Baker, H. (1956). The significance of adenoid tissue in velopharyngeal function. *Plastic and Reconstructive Surgery* 17:235-250.
- Swennen, G. & Schutyser, F. (2006). Three-dimensional cephalometry: spiral multi-slice vs cone-beam computed tomography. *Am J Orthod Dentofac Orthop* 130: 410–416
- Valiathan, A., Dhar, S. & Verma, N. (2008). 3D CT imaging in orthodontics: Adding a new dimension to diagnosis and treatment planning. *Trends Biomater Artif Organs* 21(2):116-120.



## **Orthodontics - Basic Aspects and Clinical Considerations**

Edited by Prof. Farid Bourzgui

ISBN 978-953-51-0143-7

Hard cover, 446 pages

**Publisher** InTech

**Published online** 09, March, 2012

**Published in print edition** March, 2012

The book reflects the ideas of nineteen academic and research experts from different countries. The different sections of this book deal with epidemiological and preventive concepts, a demystification of cranio-mandibular dysfunction, clinical considerations and risk assessment of orthodontic treatment. It provides an overview of the state-of-the-art, outlines the experts' knowledge and their efforts to provide readers with quality content explaining new directions and emerging trends in Orthodontics. The book should be of great value to both orthodontic practitioners and to students in orthodontics, who will find learning resources in connection with their fields of study. This will help them acquire valid knowledge and excellent clinical skills.

### **How to reference**

In order to correctly reference this scholarly work, feel free to copy and paste the following:

Ahmed Ghoneima, Eman Allam, Katherine Kula and L. Jack Windsor (2012). Three-Dimensional Imaging and Software Advances in Orthodontics, Orthodontics - Basic Aspects and Clinical Considerations, Prof. Farid Bourzgui (Ed.), ISBN: 978-953-51-0143-7, InTech, Available from:  
<http://www.intechopen.com/books/orthodontics-basic-aspects-and-clinical-considerations/three-dimensional-3d-imaging-and-software-advances-in-orthodontics>

**INTECH**  
open science | open minds

### **InTech Europe**

University Campus STeP Ri  
Slavka Krautzeka 83/A  
51000 Rijeka, Croatia  
Phone: +385 (51) 770 447  
Fax: +385 (51) 686 166  
[www.intechopen.com](http://www.intechopen.com)

### **InTech China**

Unit 405, Office Block, Hotel Equatorial Shanghai  
No.65, Yan An Road (West), Shanghai, 200040, China  
中国上海市延安西路65号上海国际贵都大饭店办公楼405单元  
Phone: +86-21-62489820  
Fax: +86-21-62489821



© 2012 The Author(s). Licensee IntechOpen. This is an open access article distributed under the terms of the [Creative Commons Attribution 3.0 License](https://creativecommons.org/licenses/by/3.0/), which permits unrestricted use, distribution, and reproduction in any medium, provided the original work is properly cited.

IntechOpen

IntechOpen