

We are IntechOpen, the world's leading publisher of Open Access books Built by scientists, for scientists

6,900

Open access books available

185,000

International authors and editors

200M

Downloads

Our authors are among the

154

Countries delivered to

TOP 1%

most cited scientists

12.2%

Contributors from top 500 universities



WEB OF SCIENCE™

Selection of our books indexed in the Book Citation Index
in Web of Science™ Core Collection (BKCI)

Interested in publishing with us?
Contact book.department@intechopen.com

Numbers displayed above are based on latest data collected.
For more information visit www.intechopen.com



Arterial Angioplasty in Congenital Heart Disease

Thomas J. Forbes, Srinath Gowda and Daniel R. Turner
*Wayne State University/Children's Hospital of Michigan, Detroit, MI
 USA*

1. Introduction

This chapter will describe the historical background, technical issues, outcomes, and future considerations of angioplasty to treat various congenital heart lesions in both the systemic and pulmonary arteries. Intravascular stent placement will be mentioned briefly, but the primary focus will be balloon angioplasty of arterial stenosis. Peripheral stenoses secondary to acquired arterial lesions will not be discussed.

2. Coarctation of the aorta

2.1 Historical background

Coarctation of the aorta is a condition where the aorta is narrowed in the area where the ductus arteriosus inserts (Figure 1). Coarctation represents 5-10% of all congenital heart disease. Coarctation is more common in Caucasian than Asian individuals and is less common among Native Americans. Males are affected 1.6-1.8 times as often as females. The overall incidence of coarctation in the United States is 64 per 100,000. The presentation can range from shock in infancy after closure of the ductus arteriosus to systemic hypertension in early childhood to adulthood.

The three treatment modalities for coarctation of the aorta are surgery, stent placement, and balloon angioplasty (BA). Candidates for BA will be discussed in detail below. In native coarctation of the aorta, the anatomy most suitable for BA is discrete, rather than diffuse, stenosis (Figures 2a and 2b). This is not necessarily the case in recurrent coarctation, where discrete or diffuse lesions secondary to surgical scarring are each amenable to BA.¹⁻³

2.2 Neonates/infants

Balloon angioplasty of coarctation of the aorta in neonates/infants can typically be performed with low-profile balloon angioplasty catheters due to the smaller final inflation diameter required in this age group. The most common diameter used in this age group is 6-8 mm, although as the patient approaches 12 months of age, the diameter shifts to the 8-10 mm range. The most commonly used balloons are the TyShak II balloons (NuMed Corp, Hopkington, New York). Up to 8 mm diameter balloons take an 0.021" wire, can be introduced through 4-Fr sheaths, and have a rated burst pressure (RBP) of at least 4 atmospheres (ATMs). The 9-12 mm diameter balloons take an 0.025" (9-10 mm) or 0.035" (12 mm) wire, can be introduced through 5-Fr sheaths, and have a RBP of 3.5 ATMs. TyShak Mini balloons (NuMed), with diameters from 4-10 mm, are even lower profile, using 3-Fr

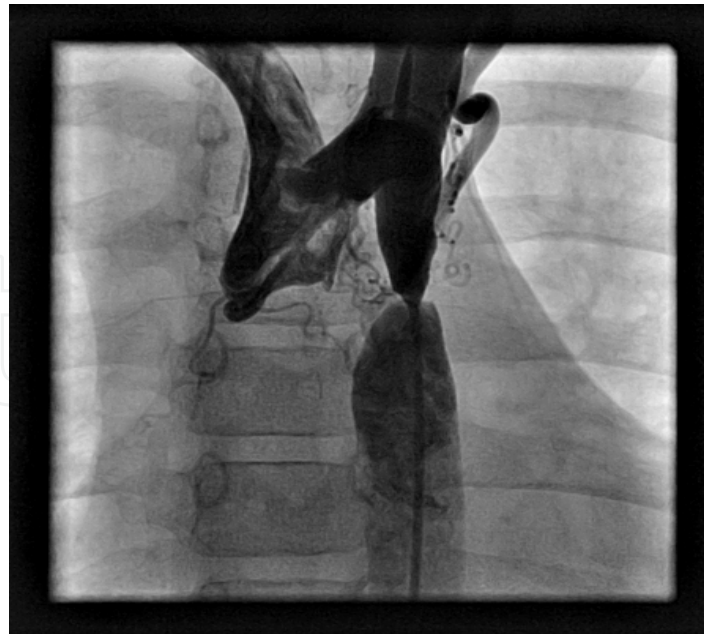

Fig. 1. Coarctation

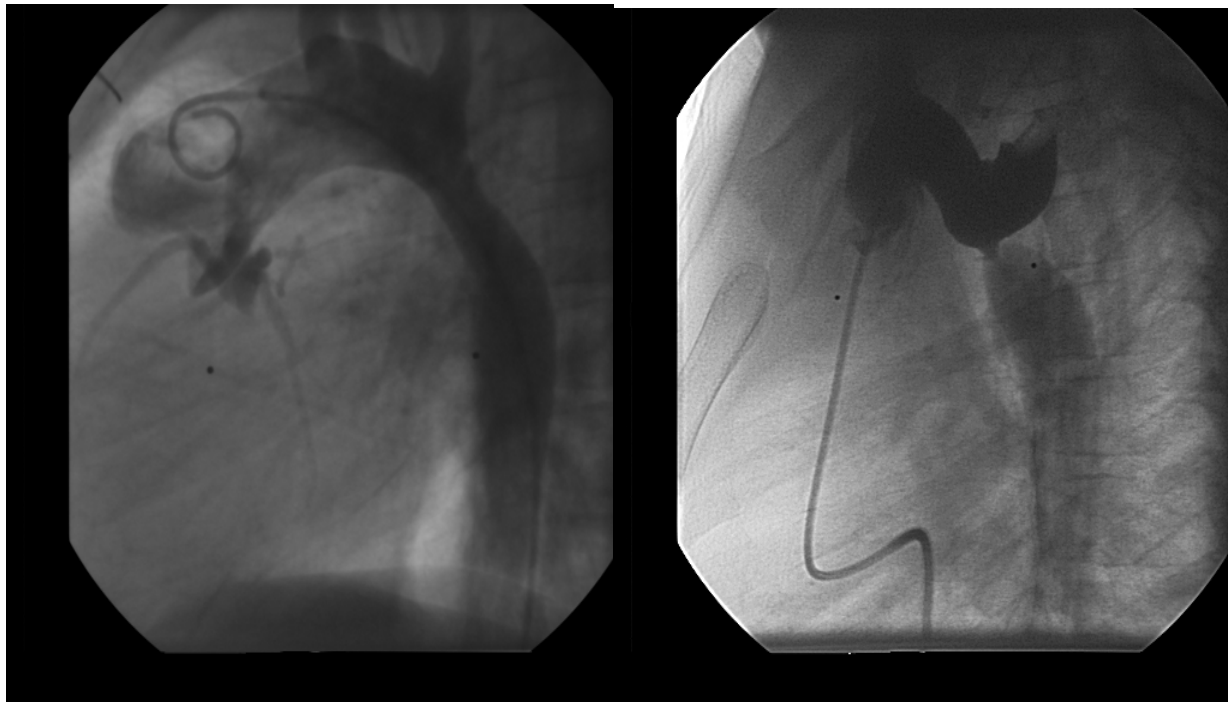


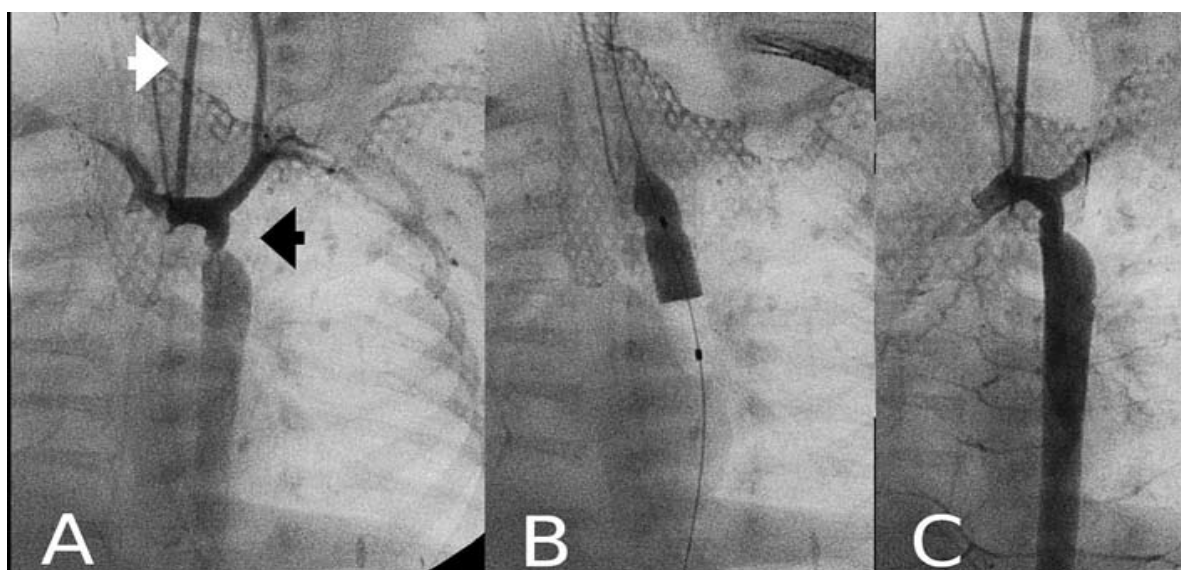
Fig. 2. a-b.

sheaths up to 8 mm diameter and 4-Fr sheaths for the 9-10 mm sizes. They take an 0.014" wire and can reach RBP of at least 3.5 ATMs. Most coarctations require 3 ATMs to obtain adequate dilation of the narrowed segment.

On occasion, high-profile, non-compliant balloon angioplasty catheters may be required to adequately dilate the coarctation segment. There are numerous balloon angioplasty catheters available: PowerFlex series (4-12 mm diameter, Cordis Corp, Warren, New Jersey), Z-Med II balloons (4-30 mm diameter, NuMed), and Cook ATB (4-10 mm diameter, Cook

Corp, Bloomington, IN). Each are similar, although certain sizes of PowerFlex and ATB balloons can be advanced through sheaths that are 1-Fr size smaller than Z-Med II. Rarely, cutting balloons (CB) may be required for coarctation angioplasty.⁴ More specific information on CB will be given in the pulmonary angioplasty section.

The standard approach for native or recurrent coarctation of the aorta is retrograde via femoral- or umbilical-arterial access. This approach offers the most direct route to treat the coarctation site. In very small infants (< 1.5 kg), alternative approaches have been reported (Figures 3a, 3b, and 3c).⁵ Angiograms of the coarctation and transverse aortic arch are performed prior to balloon angioplasty. In over 20% of patients, most commonly in cases of symptomatic neonatal/infant coarctation of the aorta, transverse aortic arch hypoplasia may be present. The definition of transverse aortic arch hypoplasia is a transverse arch-to-descending aortic ratio of < 0.60.⁶⁻⁸ Measurements at the transverse aortic arch and descending aorta at the level of the diaphragm are made. The smaller of these diameters determines the size of the balloon catheter used to perform coarctation angioplasty. It is particularly important that the balloon be de-aired prior to inflation, as balloon rupture may cause air emboli into the brachiocephalic vessels. On initial inflation, one tries not to exceed a balloon-to-coarctation ratio of > 4:1.⁷ Pre- and immediately post-pressure measurements are obtained. After the angioplasty, it is extremely important to obtain standard and orthogonal angiographic views of the coarctation area to exclude a small dissection or aneurysm. If high pressure or cutting balloon catheters are required for adequate dilation of the coarctation segment, a covered stent should be available in the catheterization lab in case one encounters aneurysm formation, an acute dissection, or vessel tear.



Courtesy of Prada F, et al. Rev Esp Cardiol. 2010 Jun;63(6):741-3.

Fig. 3. a-c. Balloon angioplasty of a critical coarctation in a 1200 gram premature infant per the left carotid artery via a 3 Fr sheath using the Seldinger technique. A 4 mm TyShak Mini balloon was used with the coarctation segment increasing from 1.5 to 3.2 mm and a decrease in the systolic gradient from 35 to 7 mmHg. The infant developed recoarctation 2 months later and at 2200 grams underwent repeat balloon angioplasty from the femoral arterial system. At 6 months out from the procedure (5600 grams) the infant continues to do well with no evidence of recoarctation.

2.3 Outcomes

Infantile coarctation of the aorta typically occurs in conjunction with severe heart failure or shock. In this setting, coarctation is frequently associated with other congenital heart lesions (bicuspid aortic valve in 60-70%, ventricular septal defect in 40%, and other left-sided lesions, i.e. mitral valve stenosis, subaortic valve stenosis, and hypoplastic left ventricle 3% of the time). Performance of coarctation angioplasty is not recommended in patients with associated congenital lesions requiring surgery. The predominant treatment for isolated native coarctation of the aorta presenting in infancy is surgical repair with extended end-to-end anastomoses. Although many believe that surgical repair is the standard of care, some have advocated that BA in high-risk patients is a reasonable initial procedure to improve their surgical candidacy.⁹ The overall outcome of BA is poor in infants presenting in heart failure or shock. Liang et al. performed a recent study where they evaluated 18 infants with native coarctation of the aorta and congestive heart failure who underwent balloon angioplasty. The mean age was just less than three months and the mean body weight was 4 kg. Congestive heart failure symptoms improved markedly in all patients immediately after BA. The incidence of re-coarctation was high in infants, requiring surgery if the systolic pressure gradient > 10 mmHg from ascending to descending aorta or if the coarctation diameter measured < 3 mm. The recurrent coarctation rate was 44% (8/18 patients) and the conclusion was that balloon angioplasty, in this setting, was ineffective and not recommended as a primary treatment alternative.⁹

In another recent study by Rau, et al., 51 infants less than 3 months of age who presented with heart failure underwent balloon coarctation angioplasty from the umbilical artery (16/51), femoral artery (26/51) and femoral venous antegrade across the inter-atrial communication (9/51). Findings included acute reduction in the peak gradient across the coarctation segment, increase in the diameter of the coarctation segment, and improved symptomatology following BA. Effective palliation was achieved in 47/51 infants (92%). At intermediate follow-up, 22/51 (43%) developed re-coarctation within three months after balloon angioplasty, requiring either repeat BA (14/22) or surgical (8/22) intervention. Using avoidance of surgery for four weeks as the definition of success, the authors concluded that BA is an excellent alternative to surgical intervention for the management of native coarctation in the neonatal period. With > 50% of patients requiring reintervention within 10 months of initial BA, we believe that surgical treatment of this condition remains the standard of care in this subgroup of patients.¹⁰

2.4 Challenges for the future

The development of bioabsorbable stents could potentially change this treatment paradigm. There are two current challenges with bioabsorbable stent technology: (1) to reliably make a stent that can reach 6-7 mm diameter with adequate radial strength to overcome the coarctation; and (2) to be able to deliver the stent through a low profile sheath (4-5-Fr if performed retrograde and up to 7-Fr if performed antegrade from the venous route). There are currently two bioabsorbable stents being evaluated with the potential to enter clinical use in Europe within the next several years.

3. Aortic coarctation in children and adults

3.1 Historical overview

Balloon angioplasty for the treatment of native or recurrent coarctation of the aorta has been performed since the mid 1980s.¹¹ There is excellent data to support BA to treat recurrent

coarctation of the aorta in this age group. Although BA is considered the treatment of choice for this lesion in children and adults,¹² controversy surrounds the use of BA for native coarctation of the aorta in these patients presenting with hypertension.

3.2 Technique

BA is performed from the retrograde femoral arterial route in the majority of children and adults undergoing BA for either recurrent or native coarctation. Recently, there have been reports of using radial access for recognition and treatment of potential complications, some advocating for BA though we, and others, feel radial access is more appropriate for stent treatment of coarctation of the aorta.¹³ After a complete right and left heart catheterization is performed, the coarctation segment is approached retrograde from the descending to ascending aorta. It is important to rule out any potential left-sided lesions, including mitral valve stenosis, subaortic valve stenosis, or aortic valve stenosis, as these lesions can be also associated with coarctation of the aorta. Furthermore, significant diastolic dysfunction and increased diastolic pressures can be encountered in this patient group. For severe or nearly atretic coarctation of the aorta, crossing the narrowed segment retrograde may be quite difficult. Under those circumstances, transseptal technique is used to enter the left heart antegrade and the coarctation can then be crossed more easily from the ascending to descending aorta. Typically, either an angled 0.035" glide wire (Cook Corp, Bloomington, Indiana) or Wholey wire (Covidian Inc. Mansfield, MA) are used. The wire is then snared retrograde from the distal descending aorta and an arterial-venous loop is created, then allowing retrograde delivery of the balloon to the coarctation segment.



Fig. 4. a-b. Comparison between the Atlas and Z Med II balloon catheters. The tapered shoulder on the Atlas balloon significantly increases the actual balloon length as well as inflation/deflation time in comparison to the shorter Z Med II balloon.

Higher RBP for coarctation BA is more important as patients age. Although lower profile (TyShak II) balloons may be used, less compliant, higher profile balloon angioplasty catheters are usually required. PowerFlex, Maxi-Plus (Cordis corp, Warren, NJ), Z-Med II, Mullins (NuMed corp., Hopkington, NY), and Atlas (Bard Medical, Tempe, AZ) balloon angioplasty catheters have all been used. The Atlas balloon catheter has enhanced low profile (2-3 Fr sizes less than the others) and high RBP. The tapered shoulders of the Atlas balloon makes the balloon quite long and longer inflation/deflation times are required, making it more difficult to adequately position this balloon catheter across the coarctation segment (Figures 4a-b).

As one exceeds 5-6 atmospheres of pressure to achieve successful dilation of the coarctation segment, there is an increased likelihood of creating an acute dissection, aneurysm, or in rare cases, rupture of the aorta.⁷ It has been recommended that one not exceed four times the narrowest coarctation segment during dilation in the initial setting. Patients with extremely tight coarctation segments therefore require a staged approach.

3.3 Outcomes

Balloon angioplasty of native coarctation of the aorta is part of the treatment paradigm in children and adults. In the Congenital Cardiovascular Interventional Study Consortium (CCISC) registry comparing surgical vs. stent vs. balloon angioplasty treatment of native coarctation of the aorta in children and adults, BA appeared to have an increased risk of aneurysm formation and dissection at short-term and intermediate follow-up (Tables 1 and 2) (Journal American College of Cardiology, *in press*). The overall hemodynamic outcome related to blood pressure management and upper to lower extremity blood pressure gradient appear to be equal between the three groups at short-term and intermediate follow-up. In the subgroup of patients undergoing balloon angioplasty, the incidence of aneurysm formation was as high as 43% at intermediate follow-up, some patients requiring placement of a covered stent (Figures 5a-b). Cowley et al., in comparing surgery with balloon angioplasty for native coarctation of the aorta, showed that aneurysm formation and the need for re-intervention was significantly higher in the balloon angioplasty group compared to the surgical group.¹⁴ Hassan, et.al., looked at balloon angioplasty in the older adolescent and young adult populations only, age range from 14-54 years. In this age group, the aneurysm rate was much lower (7%) at intermediate follow-up.^{15, 16} The difference between these studies may be related to the age group of patients treated with balloon angioplasty. In the Forbes study, the mean age was 6.8 years vs. 22 years in Hassan's study. Perhaps older patients are more likely to have successful outcomes and less likely to have aneurysm formation following BA.

The most severe complication, aortic rupture or large dissection, is rare, but occurs with increased incidence in older patients. As expected, it is the non compliant, adult aorta where this is more likely to occur. Aortic rupture or large aneurysm formation does not appear to be related to exceeding the balloon:coarctation ratios of 4:1, but may be related to exceeding 6 ATMs during initial balloon inflation. In one case, a 43 yo lady with moderate hypertension and coarctation of the aorta presented for transcatheter treatment of the coarctation segment. BA was unsuccessful in relieving the gradient. Stent placement was performed using a high pressure balloon angioplasty catheter. At the end of the procedure, a small amount of contrast was observed outside of the stent posteriorly. CT scan revealed near complete transection of the aorta. One month and one year follow-up CT imaging

noted complete resolution of the peri-aortic hematoma with no evidence of dissection or aneurysm formation (Figures 6a-d).

Outcomes	Surgery (n = 26)	Balloon (n = 28)	Stent (n = 97)	p-value (2-sided)
Any Complications ¹	23.1%	32.1%	8.3%	0.003*
Aortic Wall Injury (%)	11.5%	21.4%	3.1%	0.004*
Dissection / Intimal Tear (%)	0.0%	7.1%	0.0%	0.062
Aneurysm (%)	11.5%	14.3%	3.1%	0.040*
Coarct / Dao ratio (mean)	0.91	0.73	0.82	0.003*
Coarct / Dao ≥ 0.6	87%	79%	90%	0.247
Any Re-obstruction	19.2%	32.1%	15.4%	0.057
Mild ²	7.7%	17.9%	11.3%	
Moderate	7.7%	3.6%	4.1%	
Severe	3.9%	10.7%	0%	

¹Defined as any moderate to severe reobstruction, aortic wall injury (aneurysm, dissection, intimal tear) or stent fracture.

²Mild reobstruction was not considered as a complication in our analysis.

* P- value < 0.05

Table 1. Short-Term Follow-up Outcomes by Integrated Imaging

Outcomes	Surgery (n = 16)	Balloon (n = 16)	Stent (n = 56)	p-value (2-sided)
Any Complications ¹	25.0%	43.8%	12.5%	0.020*
Aortic Wall Injury (%)	12.5%	43.8%	7.1%	0.003*
Dissection / Intimal Tear (%)	0.0%	6.3%	1.8%	0.598
Aneurysm (%)	12.5%	43.8%	5.4%	<0.001
Coarct / Dao ratio (mean)	0.98	0.79	0.80	0.011*
Coarct / Dao ≥ 0.6	88%	93%	89%	1.000
Any Re-obstruction	18.8%	18.8%	14.3%	0.923
Mild ²	6.3%	18.8%	12.5%	
Moderate	6.3%	0%	1.8%	
Severe	6.3%	0%	0%	

¹Defined as any moderate to severe reobstruction, aortic wall injury (aneurysm, dissection, intimal tear) or stent fracture.

²Mild reobstruction was not considered as a complication in our analysis.

* P- value < 0.05

Table 2. Intermediate Follow-up Outcomes by Integrated Imaging

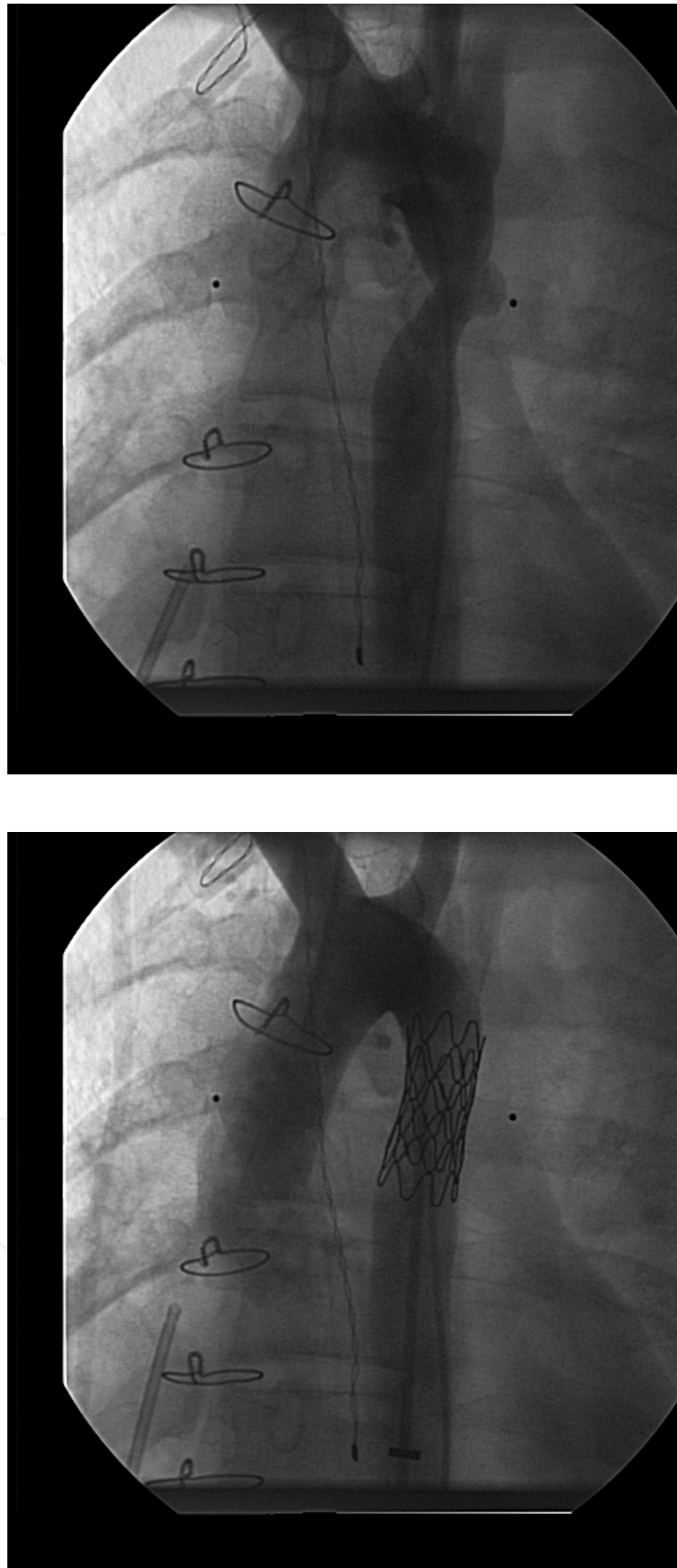


Fig. 5. a-b.

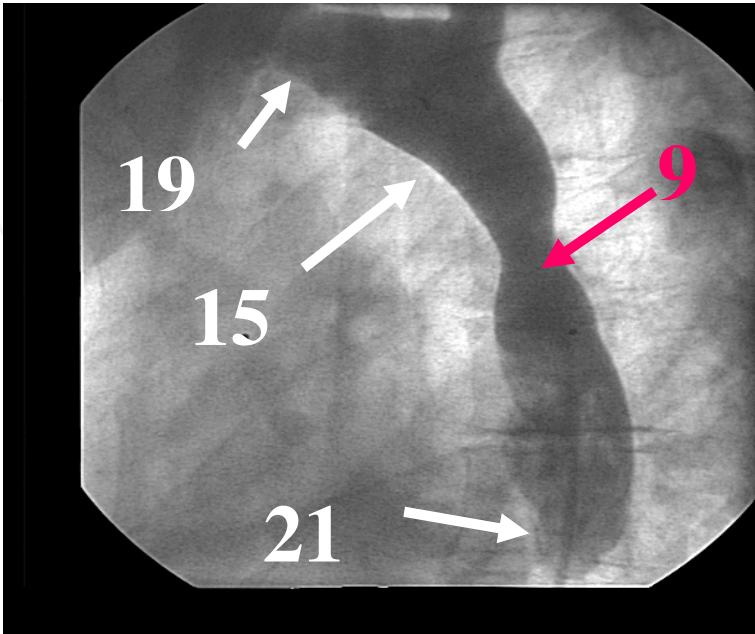


Fig. 6. a.

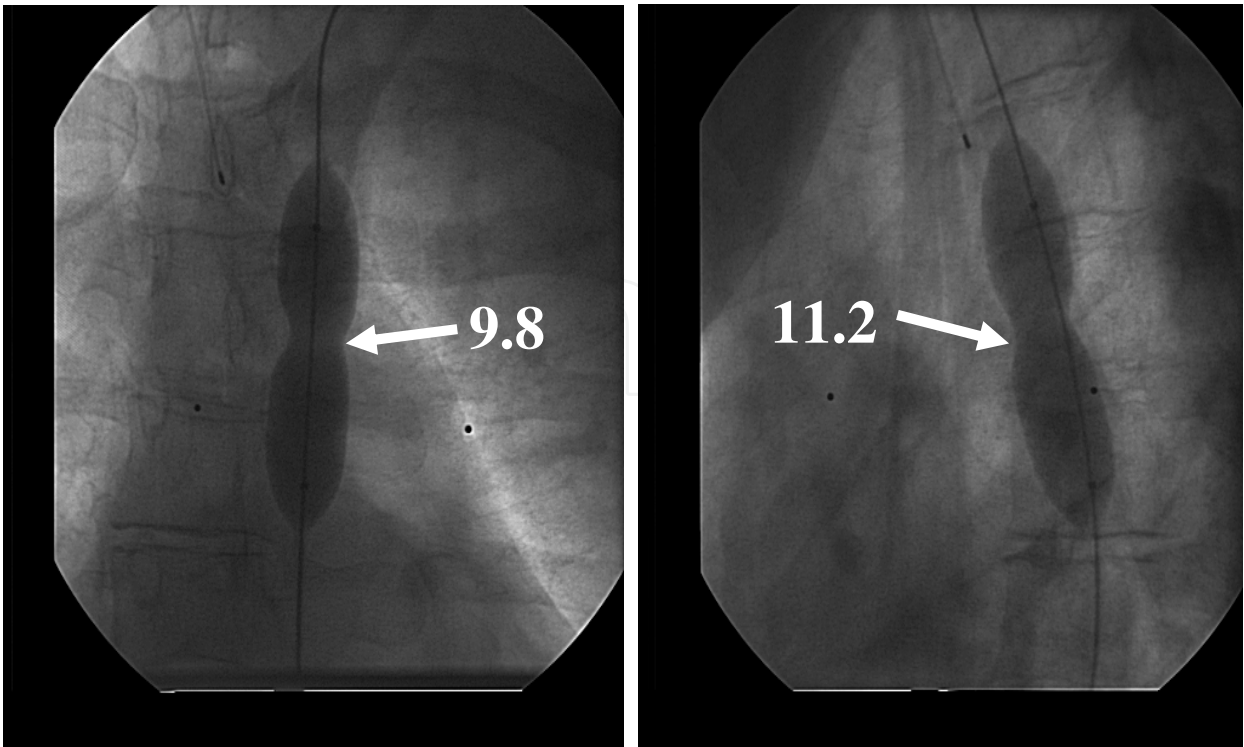


Fig. 6. b-c.

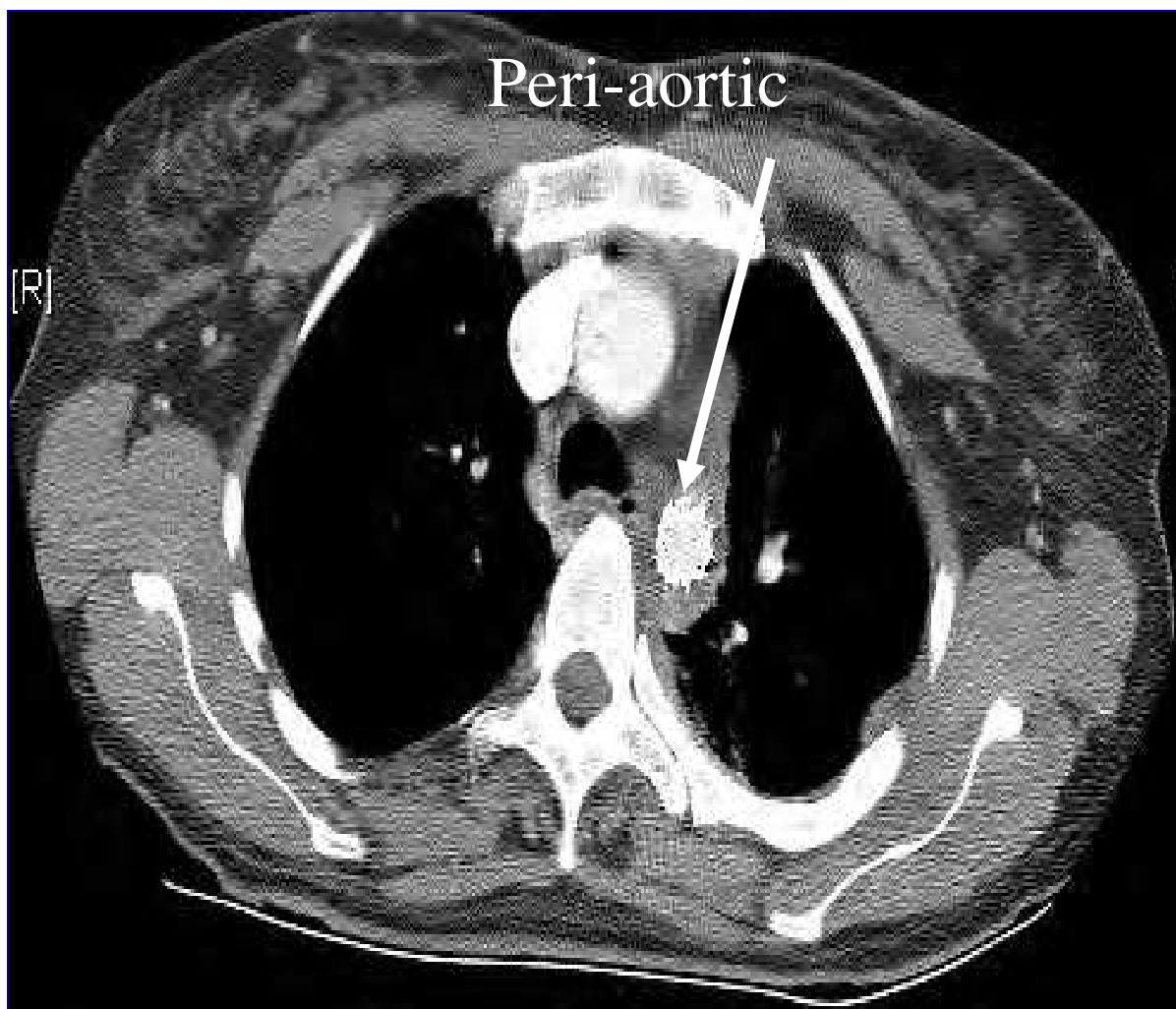


Fig. 6. d.

Re-obstruction, as defined as an upper to lower blood pressure gradient > 20 mmHg or narrowed segment $> 50\%$ of the native vessel diameter, appears to be less common as the age at the time of initial treatment increases. Re-obstruction frequency ranges from 3-20% in older children/adults undergoing primary BA of native coarctation compared to the nearly 50% re-obstruction rate seen in infant balloon angioplasty of their native coarctation.^{9,10,15}

3.4 Challenges for the future

Stent treatment, particularly in older children and adults, appears to be the treatment of choice in treatment of native and recurrent coarctation of the aorta.^{7, 8, 13, 17} Permeating balloons, where a drug is injected into the vessel wall during angioplasty to prevent the development of re-stenosis, have not been successful for adequate drug delivery in animal studies. The primary challenge involves unintentional delivery of the drug directly into the blood stream, and not into the vessel wall. Placement of markers 5 mm apart, marking the permeating holes within the balloon catheter may assist us in delivering the treatment drug directly into the vessel wall, though this remains to be seen. The length of time for inflation required to deliver the medication (1-3 minutes) would require adequate collateralization around the coarctation lesion to decrease the likelihood of encountering lower

extremity/bowel ischemia. The current medications that may have a role in this are similar to the current medications being placed on drug eluting stents. These can be broken down into cytotoxic/cytostatic drugs, which have recently been undergoing head-to-head trials in applications to coronary stenting^{18, 19 20} or “pro-healing” drugs such as endogenous growth factors or endothelial progenitor cells.²¹ What role, if any, in this approach to coarctation of the aorta, remains to be seen.

4. Pulmonary artery stenosis

4.1 Historical background

Balloon angioplasty, first described for use in pulmonary valve stenosis in 1983,²² has become the treatment of choice for balloon angioplasty of branch pulmonary artery stenosis in most pediatric cardiology centers.^{23, 24} Surgical repair of branch pulmonary artery stenosis has been sub-optimal, associated with increased morbidity, especially in young infants and children.

4.2 Technique

As with any interventional procedure, the first step in evaluating a pulmonary artery for BA is to understand the anatomy and pathophysiology of the stenotic lesion to be addressed. Generally, as in coarctation of the aorta, discrete lesions tend to be more amenable to BA compared to long segmental lesions. In Figures 7a-c, a patient with Tetralogy of Fallot with pulmonary valve atresia has multiple discrete and long segment stenosis of the right upper lobe segment. BA is performed both in the distal discrete stenosis and the more proximal long segment stenosis. Follow up imaging noted resolution of the distal discrete stenosis with persistence of the proximal stenosis, which required stent placement. In another patient with RPA stenosis following the arterial switch procedure (Figure 8), MRI imaging shows the RPA stenosis to be secondary to posterior compression from the aorta. Therefore stent placement, not BA, was necessary to treat this mechanical RPA stenosis.

Performance of branch pulmonary artery BA is relatively straightforward and can be through a short sheath. The most difficult part of the procedure is usually crossing the stenotic segment. Accurate angiographic imaging is essential. For proximal stenosis (prior to the takeoff of the upper lobe branch), the lesion is crossed with either a 0.025 or 0.035” wire where, depending on patient size, a 4-5 Fr pigtail or multipurpose catheter is advanced over the wire into the stenosed pulmonary artery. Hand or power angiography is performed. For distal branch stenosis, the stenotic lesion is usually crossed with a glide wire and then a 4-Fr JB-1 or similar glide catheter (Cook Corp, Bloomington, IN) is advanced over the wire distal to the lesion. Hand injections can be performed through the catheter with the wire remaining in place. BA is usually carried out over that same wire. If multiple lobar segments are involved, the BA catheter is pulled back into the proximal pulmonary arterial segment and the soft tipped 0.018” wire is used to cross other stenoses. Stent treatment of multiple branch PA stenosis is usually not recommended, as many of the affected branch vessels would be “jailed off” by the stent (Figure 9a-b).

The balloons typically required for branch pulmonary artery BA are the higher-pressure, non-compliant balloon catheters. Typically, the more distal or peripheral the stenosis, the greater the need for higher atmosphere balloons or cutting balloons (or both) to achieve adequate BA of the stenotic segment.

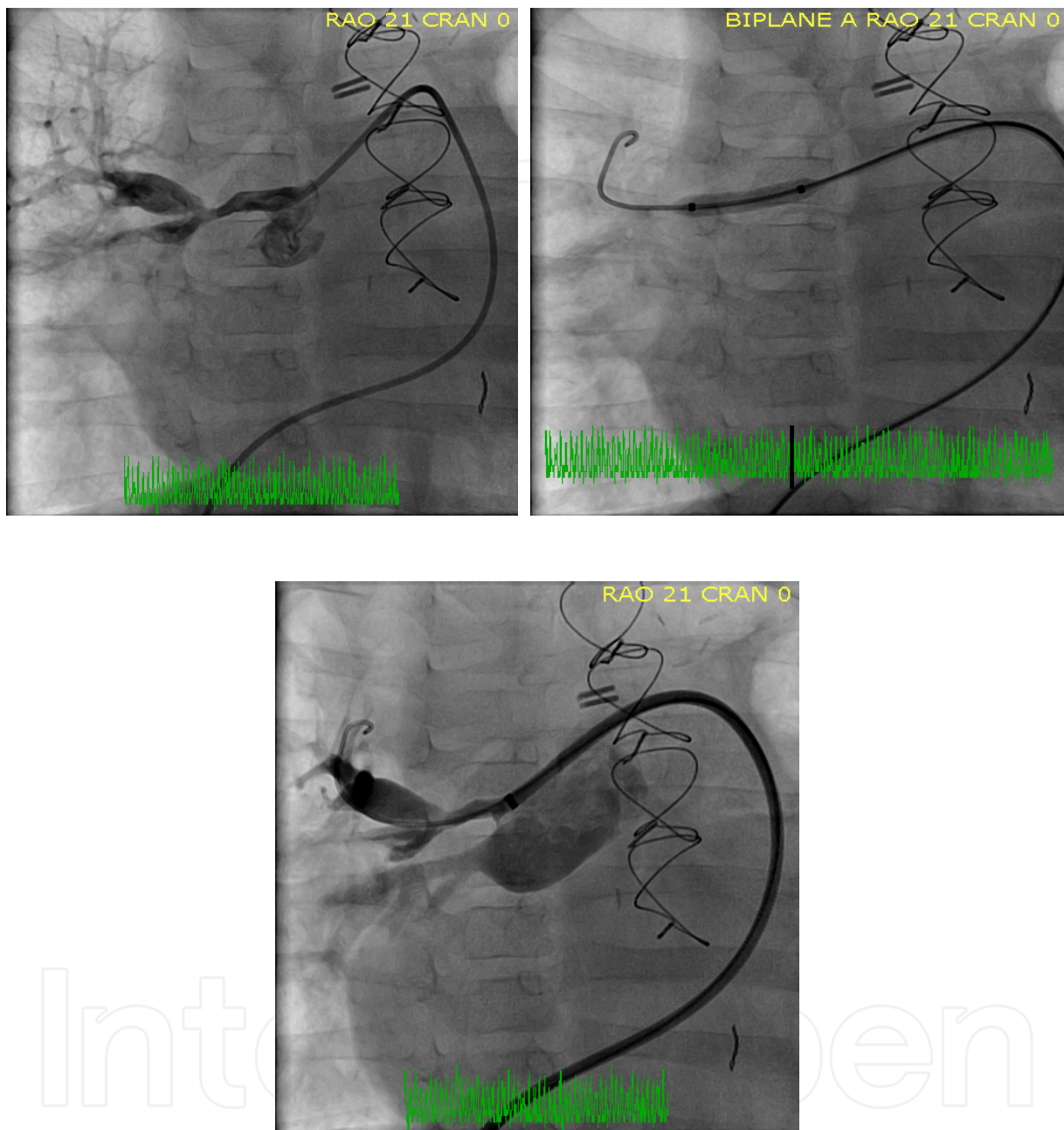


Fig. 7. a-c. Patient with Pulmonary Atresia and Ventricular Septal Defect with multiple distal stenosis of the RPA segment. BA is performed up to 19 ATMs with a 4 mm balloon angioplasty catheter. Left lower panel notes resolution of the distal discrete stenosis, though persistence of the proximal stenosis.

The cutting balloon (CB) is a dilation balloon made of noncompliant modified polyethylene terephthalate with available balloon diameters from 2-8 mm and lengths 10, 15, and 20 mm (Boston Scientific Corp., Natick, Massachusetts, Figure 10 a-b). The incremental increase in balloon size is 0.25 mm from 2-4 mm and 1 mm from 5-8 mm. Depending on the balloon diameter, 3 or 4 microsurgical blades are attached every 90 or 120 degrees, each blade with a

working height of 0.11-0.18 mm. Prior to dilation, the folds of the balloon cover the microsurgical blades and following dilation, the blades wrap into the folds of the balloon with deflation. Use of the CB requires a long sheath, 4-Fr for a 4 mm CB, 6-Fr for a 5 mm CB, and 7-Fr for a 6-8 mm CB. Wires are 0.014" up to 4 mm diameter and 0.018" from 5-8 mm diameter. These balloons reach full inflation at 6 ATMs with burst pressure at 10 ATMs. Aggressive balloon angioplasty of the vessel (up to 22 ATM pressure) with a standard balloon angioplasty catheter is usually performed prior to performing CB. (Figure 11a-d). The CB is usually dilated 1-2 mm larger than the narrowest segment of the stenosis. Following this, standard BA is performed up to the native vessel size. The balloons may undergo repeat dilation, but it is recommended that no more than 10 inflation/deflation cycles be used for one balloon catheter. Rapid inflation and deflation of CB should not be performed; rather slowly inflating and deflating these balloons over a one minute period of time is recommended. Finally, exceeding the burst pressure of these balloons should never be undertaken. Balloon rupture, which typically is longitudinal, prevents the proper folding of the balloon and subsequent coverage of the microblades, thereby making it more likely to strip a blade off the balloon catheter during removal of the CB. CB angioplasty is performed via either long flexor sheaths (Cook Flexor, Cook corp, Bloomington, IN) or various guiding sheaths.

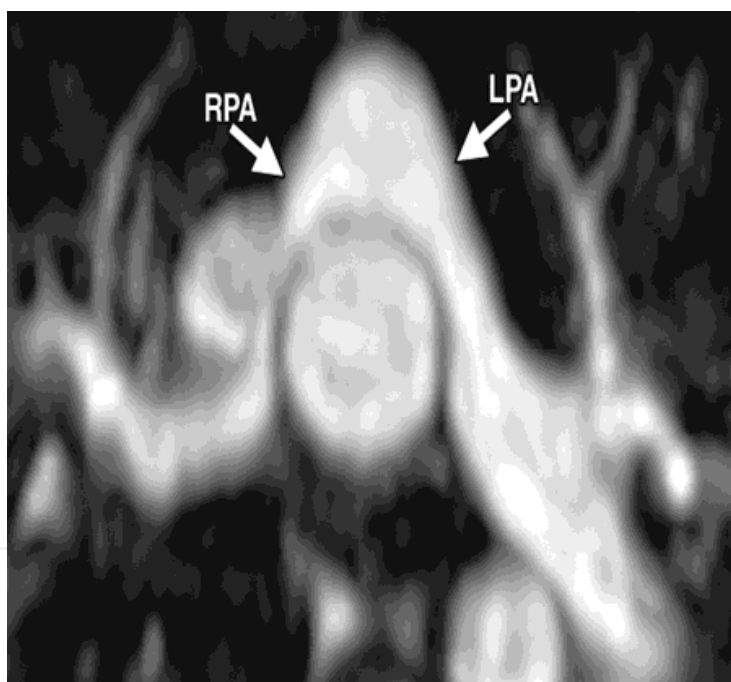
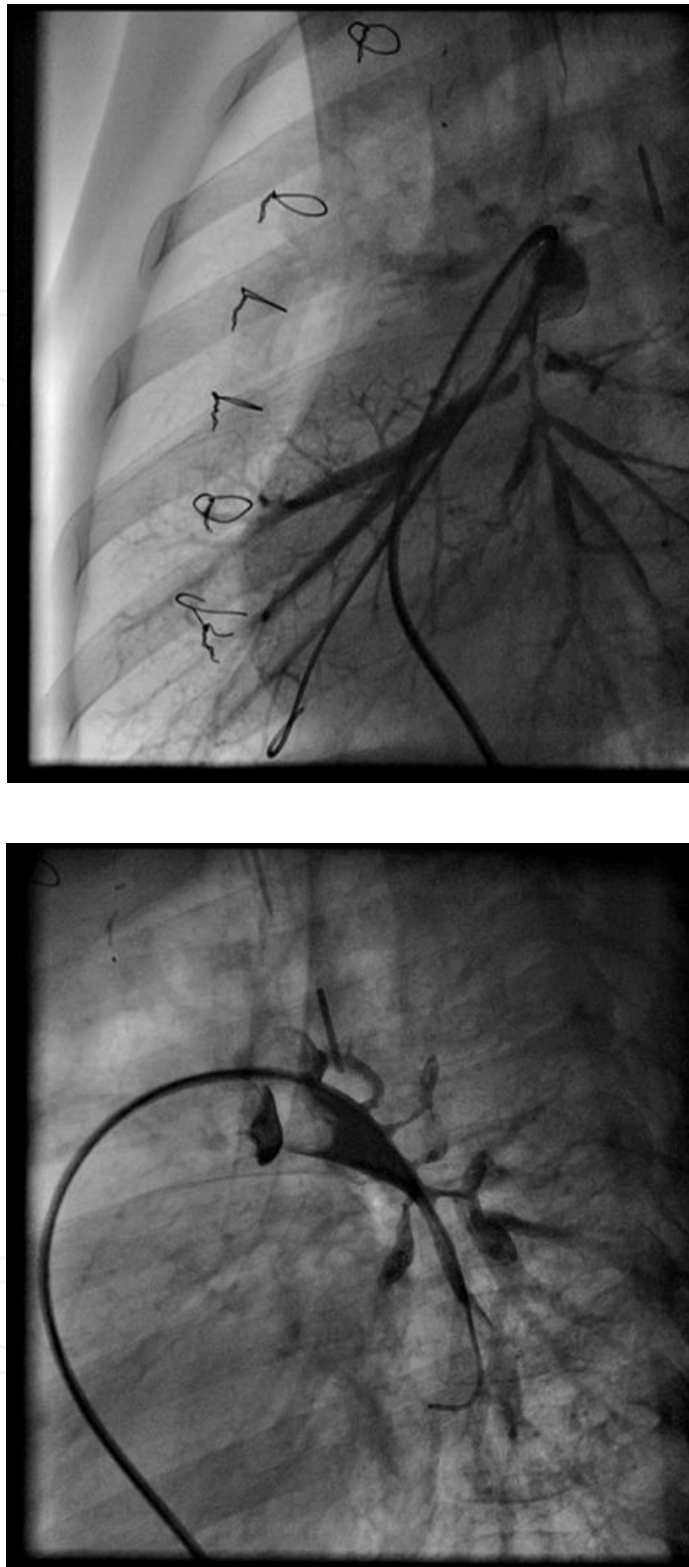


Fig. 8.

Patients with multiple bilateral peripheral pulmonary artery stenoses can suffer from re-perfusion injury following dilation of multiple affected lung segments. This situation can be life threatening in patients who are already compromised with severe elevation of the right ventricular pressure. Multiple techniques have been addressed in an attempt to avoid this circumstance. One is to dilate one segment or pulmonary arterial side with no treatment of the contralateral side at the same cath procedure. Another is selectively ventilating the contralateral lung segment during the BA procedure, thereby decreasing blood flow to the treated lung and theoretically decreasing the likelihood of encountering re-perfusion injury of those involved segments.²⁵



Courtesy Allison Cabalka, Mayo Clinic, Rochester, MN

Fig. 9. a-b. Multiple right and left pulmonary artery stenosis of the distal branches. Patient has systemic right sided pressures and is planning on undergoing multiple balloon angioplasty dilations. One can see discrete as well as diffuse stenosis of the distal branch vessels.


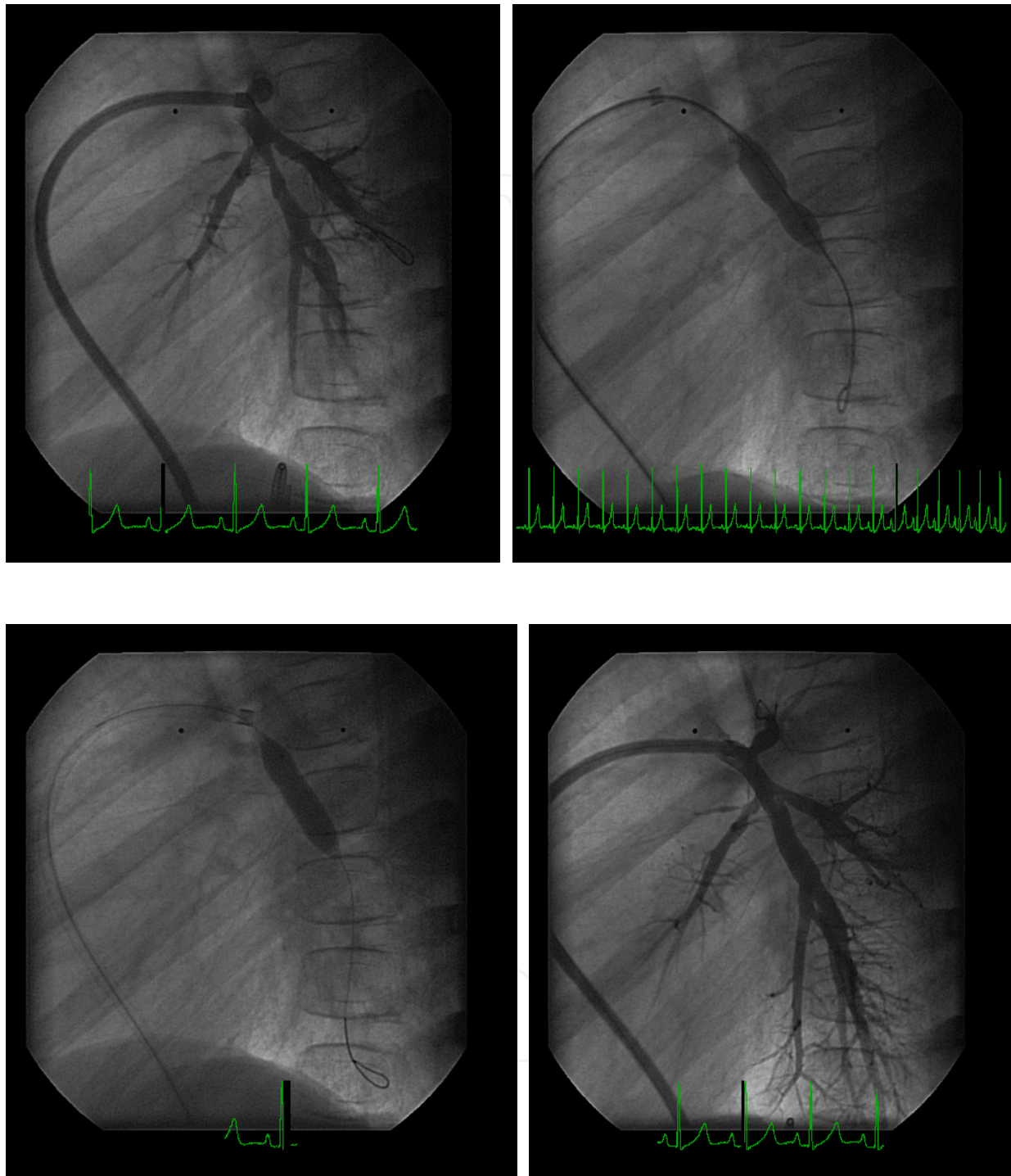


Fig. 10. a-b.

4.3 Outcomes

The performance of pulmonary balloon valvuloplasty to treat pulmonary valve stenosis has been an extremely effective procedure. Unfortunately, balloon dilation of stenoses of the pulmonary arteries distal to the pulmonary valve has not been as satisfactory.^{23, 26} Although the stenotic vessels often can be dilated with angioplasty balloons, even to three or four times the original size, the stenoses frequently recur immediately after balloon deflation. The recurrence of obstruction following dilation is thought to be due to the natural elastic recoil of the tissue in native pulmonary arterial stenosis or to resilience and resistance of scar tissue in postoperative cases. Rothman, et al. reported the only large series of balloon pulmonary artery dilations in 135 patients.²⁷ They noted that previous reports of surgery for the direct relief of pulmonary artery lesions was difficult and often ineffective.²⁸ The mean diameter of the lesion increased from 3.8 ± 1.7 to 5.5 ± 2.1 mm with dilation ($p = 0.001$). The overall success rate was 58% (127/218 dilations), assessed by the following criteria: an increase greater than or equal to 50% of predilation diameter, an increase greater than 20% in flow to the affected lung, or a decrease greater than 20% in systolic right ventricular to aortic pressure ratio. A pulmonary artery aneurysm occurred in 5% of the pulmonary arteries dilated. Two patients died at angioplasty. Restenosis occurred in 16% of the restudied patients with initial successful dilation. They concluded that balloon angioplasty was an established, highly useful procedure in the management of branch pulmonary artery stenosis.²⁷

The use of cutting balloons (CB) has increased the success rate of pulmonary artery BA from 50-60% to 80%, irrespective of whether CB were used de novo or following failure of standard balloon angioplasty.²⁶ One area where CB have been particularly effective is in severe, multiple discrete stenosis of the distal pulmonary arterial branches (Figure 9a-b).^{29, 30}



Courtesy Jaqueline Kreutzer, Children's Hospital of Pittsburgh, Pittsburgh, PA

Fig. 11. a-d. Cutting balloon angioplasty of distal branch left lower lobe pulmonary artery stenosis. Upper left panel notes the stenotic segments of the left lower lobe branches. Right upper panel notes failed aggressive balloon angioplasty at 18 ATMs. Left lower panel, successful cutting balloon dilation of the stenotic segment. Right lower panel, resolution of the left lower lobe stenosis following cutting balloon angioplasty.

This is a rare condition that can be idiopathic or associated with William's/Alagille syndrome.^{29, 31} Primary stenting is generally not recommended for these lesions due to the likelihood of jailing off adjacent pulmonary arterial branches. Balloon angioplasty of these lesions almost always requires high-pressure balloons and in many cases is resistant to standard BA.²³ Aneurysm, dissection, and vessel perforation have been associated with BA of pulmonary artery stenosis, with one patient having a late rupture of an aneurysm with subsequent death.³² These procedures can be tedious but the outcomes, over time, can be dramatic.

Surgical repair of pulmonary arterial stenosis has also been ineffective and carries considerably greater morbidity and probably greater mortality.²⁸ Surgical problems with these lesions relate to the location of the narrowings, often in the distal branch pulmonary arteries, an area difficult to reach from a standard midline sternotomy or lateral thoracotomy. Recurrent stenosis has been reported in up to 31% of patients who had surgical repair of the right pulmonary artery after Waterston shunt placement.²⁸

4.4 Challenges for the future

Although BA has its limitations, it remains a very important treatment modality for pulmonary and systemic arterial stenosis. CBs have improved the treatment of resistant lesions. The improvement of balloon technology has significantly decreased the number of vascular complications over the past 15 years. Drug delivery through permeable balloons (see section under Challenges for the Future in Coarctation) has significant potential application for the treatment of stenosis in the pulmonary arterial system. The tolerance of longer inflation times and smaller vessel size observed in the pulmonary arterial system makes this a technically easier undertaking in comparison to attempting drug delivery in the systemic arterial system.

5. Conclusion

Balloon angioplasty has proven to be successful in the treatment of pulmonary artery stenosis and coarctation of the aorta. Significant challenges remain, primarily in the prevention of recurrent stenosis. The development of biodegradable stents and permeable balloon catheters will undoubtedly improve outcomes for both pulmonary artery and aortic coarctation angioplasty, most importantly in the area of restenoses.

6. References

- Yetman AT, Nykanen D, McCrindle BW, Sunnegardh J, Adatia I, Freedom RM, Benson L. Balloon angioplasty of recurrent coarctation: a 12-year review. *J Am Coll Cardiol.* 1997;30(3):811-816.
- Li F, Zhou A, Gao W, Wang R, Yu Z, Huang M, Yang J. Percutaneous balloon angioplasty of coarctation of the aorta in children: 12-year follow-up results. *Chin Med J (Engl).* 2001;114(5):459-461.
- McCrindle BW, Jones TK, Morrow WR, Hagler DJ, Lloyd TR, Nouri S, Latson LA. Acute results of balloon angioplasty of native coarctation versus recurrent aortic obstruction are equivalent. Valvuloplasty and Angioplasty of Congenital Anomalies (VACA) Registry Investigators. *J Am Coll Cardiol.* 1996;28(7):1810-1817.

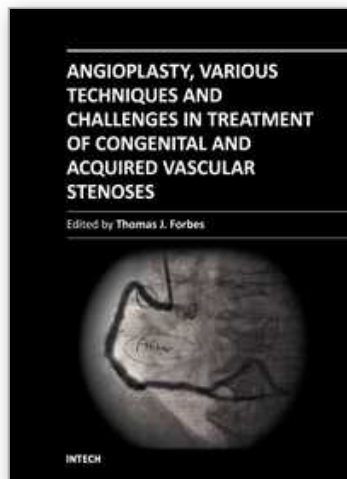
- Ozawa A, Predescu D, Chaturvedi R, Lee KJ, Benson LN. Cutting balloon angioplasty for aortic coarctation. *J Invasive Cardiol.* 2009;21(6):295-299.
- Prada F, Carretero J, Mortera C, Velasco D. Balloon angioplasty in a 1200-gram premature infant with critical aortic coarctation. *Rev Esp Cardiol.* 63(6):741-743.
- Hamdan MA, Maheshwari S, Fahey JT, Hellenbrand WE. Endovascular stents for coarctation of the aorta: initial results and intermediate-term follow-up. *J Am Coll Cardiol.* 2001;38(5):1518-1523.
- Forbes TJ, Garekar S, Amin Z, Zahn EM, Nykanen D, Moore P, Qureshi SA, Cheatham JP, Ebeid MR, Hijazi ZM, Sandhu S, Hagler DJ, Sievert H, Fagan TE, Ringewald J, Du W, Tang L, Wax DF, Rhodes J, Johnston TA, Jones TK, Turner DR, Pedra CA, Hellenbrand WE. Procedural results and acute complications in stenting native and recurrent coarctation of the aorta in patients over 4 years of age: a multi-institutional study. *Catheter Cardiovasc Interv.* 2007;70(2):276-285.
- Forbes TJ, Moore P, Pedra CA, Zahn EM, Nykanen D, Amin Z, Garekar S, Teitel D, Qureshi SA, Cheatham JP, Ebeid MR, Hijazi ZM, Sandhu S, Hagler DJ, Sievert H, Fagan TE, Ringwald J, Du W, Tang L, Wax DF, Rhodes J, Johnston TA, Jones TK, Turner DR, Pass R, Torres A, Hellenbrand WE. Intermediate follow-up following intravascular stenting for treatment of coarctation of the aorta. *Catheter Cardiovasc Interv.* 2007;70(4):569-577.
- Liang CD, Su WJ, Chung HT, Hwang MS, Huang CF, Lin YJ, Chien SJ, Lin IC, Ko SF. Balloon angioplasty for native coarctation of the aorta in neonates and infants with congestive heart failure. *Pediatr Neonatol.* 2009;50(4):152-157.
- Rao PS, Jureidini SB, Balfour IC, Singh GK, Chen SC. Severe aortic coarctation in infants less than 3 months: successful palliation by balloon angioplasty. *J Invasive Cardiol.* 2003;15(4):202-208.
- Lock JE, Bass JL, Amplatz K, Fuhrman BP, Castaneda-Zuniga W. Balloon dilation angioplasty of aortic coarctations in infants and children. *Circulation.* 1983;68(1):109-116.
- Reich O, Tax P, Bartakova H, Tomek V, Gilik J, Lisy J, Radvansky J, Matejka T, Tlaskal T, Svobodova I, Chaloupecky V, Skovranek J. Long-term (up to 20 years) results of percutaneous balloon angioplasty of recurrent aortic coarctation without use of stents. *Eur Heart J.* 2008;29(16):2042-2048.
- Dehghani P, Collins N, Benson L, Horlick E. Role of routine radial artery access during aortic coarctation interventions. *Catheter Cardiovasc Interv.* 2007;70(4):622-623.
- Cowley CG, Orsmond GS, Feola P, McQuillan L, Shaddy RE. Long-term, randomized comparison of balloon angioplasty and surgery for native coarctation of the aorta in childhood. *Circulation.* 2005;111(25):3453-3456.
- Hassan W, Awad M, Fawzy ME, Omrani AA, Malik S, Akhras N, Shoukri M. Long-term effects of balloon angioplasty on left ventricular hypertrophy in adolescent and adult patients with native coarctation of the aorta. Up to 18 years follow-up results. *Catheter Cardiovasc Interv.* 2007;70(6):881-886.
- Hassan W, Malik S, Akhras N, Amri MA, Shoukri M, Fawzy ME. Long-term results (up to 18 years) of balloon angioplasty on systemic hypertension in adolescent and adult patients with coarctation of the aorta. *Clin Cardiol.* 2007;30(2):75-80.
- Golden AB, Hellenbrand WE. Coarctation of the aorta: stenting in children and adults. *Catheter Cardiovasc Interv.* 2007;69(2):289-299.

- Kim JS, Shin DH, Kim BK, Ko YG, Choi D, Jang Y, Hong MK. Optical coherence tomographic comparison of neointimal coverage between sirolimus- and resolute zotarolimus-eluting stents at 9 months after stent implantation. *Int J Cardiovasc Imaging*.
- Klauss V, Serruys PW, Pilgrim T, Buszman P, Linke A, Ischinger T, Eberli F, Corti R, Wijns W, Morice MC, di Mario C, van Geuns RJ, van Es GA, Kalesan B, Wenaweser P, Juni P, Windecker S. 2-year clinical follow-up from the randomized comparison of biolimus-eluting stents with biodegradable polymer and sirolimus-eluting stents with durable polymer in routine clinical practice. *JACC Cardiovasc Interv*.4(8):887-895.
- Simsek C, Magro M, Boersma E, Onuma Y, Nauta S, Daemen J, Gaspersz M, van Geuns RJ, van der Giessen W, van Domburg R, Serruys P. Comparison of Six-Year Clinical Outcome of Sirolimus- and Paclitaxel-Eluting Stents to Bare-Metal Stents in Patients with ST-Segment Elevation Myocardial Infarction: An Analysis of the RESEARCH (Rapamycin-Eluting Stent Evaluated at Rotterdam Cardiology Hospital) and T-SEARCH (Taxus Stent Evaluated at Rotterdam Cardiology Hospital) Registries. *J Invasive Cardiol*.23(8):336-341.
- Klomp M, Beijk MA, Varma C, Koolen JJ, Teiger E, Richardt G, Bea F, van Geloven N, Verouden NJ, Chan YK, Woudstra P, Damman P, Tijssen JG, de Winter RJ. 1-Year Outcome of TRIAS HR (TRI-Stent Adjudication Study-High Risk of Restenosis) A Multicenter, Randomized Trial Comparing Genous Endothelial Progenitor Cell Capturing Stents With Drug-Eluting Stents. *JACC Cardiovasc Interv*.4(8):896-904.
- Lock JE, Castaneda-Zuniga WR, Fuhrman BP, Bass JL. Balloon dilation angioplasty of hypoplastic and stenotic pulmonary arteries. *Circulation*. 1983;67(5):962-967.
- Hosking MC, Thomaidis C, Hamilton R, Burrows PE, Freedom RM, Benson LN. Clinical impact of balloon angioplasty for branch pulmonary arterial stenosis. *Am J Cardiol*. 1992;69(17):1467-1470.
- Kan JS, Marvin WJ, Jr., Bass JL, Muster AJ, Murphy J. Balloon angioplasty--branch pulmonary artery stenosis: results from the Valvuloplasty and Angioplasty of Congenital Anomalies Registry. *Am J Cardiol*. 1990;65(11):798-801.
- De Giovanni JV. Balloon angioplasty for branch pulmonary artery stenosis--cutting balloons. *Catheter Cardiovasc Interv*. 2007;69(3):459-467.
- Gentles TL, Lock JE, Perry SB. High pressure balloon angioplasty for branch pulmonary artery stenosis: early experience. *J Am Coll Cardiol*. 1993;22(3):867-872.
- Rothman A, Levy DJ, Sklansky MS, Grossfeld PD, Auger WR, Ajami GH, Behling CA. Balloon angioplasty and stenting of multiple intralobar pulmonary arterial stenoses in adult patients. *Catheter Cardiovasc Interv*. 2003;58(2):252-260.
- Wilson JM, Mack JW, Turley K, Ebert PA. Persistent stenosis and deformity of the right pulmonary artery after correction of the Waterston anastomosis. *J Thorac Cardiovasc Surg*. 1981;82(2):169-175.
- Gandy KL, Tweddell JS, Pelech AN. How we approach peripheral pulmonary stenosis in Williams-Beuren syndrome. *Semin Thorac Cardiovasc Surg Pediatr Card Surg Annu*. 2009:118-121.
- Sugiyama H, Veldtman GR, Norgard G, Lee KJ, Chaturvedi R, Benson LN. Bladed balloon angioplasty for peripheral pulmonary artery stenosis. *Catheter Cardiovasc Interv*. 2004;62(1):71-77.

- Zalzstein E, Moes CA, Musewe NN, Freedom RM. Spectrum of cardiovascular anomalies in Williams-Beuren syndrome. *Pediatr Cardiol.* 1991;12(4):219-223.
- Zeevi B, Berant M, Blieden LC. Late death from aneurysm rupture following balloon angioplasty for branch pulmonary artery stenosis. *Cathet Cardiovasc Diagn.* 1996;39(3):284-286.

IntechOpen

IntechOpen



Angioplasty, Various Techniques and Challenges in Treatment of Congenital and Acquired Vascular Stenoses

Edited by Dr. Thomas Forbes

ISBN 978-953-51-0084-3

Hard cover, 236 pages

Publisher InTech

Published online 14, March, 2012

Published in print edition March, 2012

The field of performing transcatheter interventions to treat vascular lesions has exploded over the past 20 years. Not only has the technology changed, especially in the arena of balloon/stent devices, but the techniques of approaching complex lesions has evolved over the past decade. Lesions that no one would have imagined treating back in the 1990's are now being done routinely in the catheterization suite. This book provides an update on the current techniques and devices used to treat a wide variety of lesions. Though, at first, the outward appearance of the topics appears to be varied, they are all related by the common thread of treating vascular lesions. We hope, by publishing this book, to accomplish two things: First, to offer insight from experts in their field to treat, both medically and procedurally, complex vascular lesions that we frequently encounter. Secondly, we hope to promote increased communication between areas of medicine that frequently don't communicate, between adult interventional cardiologists, pediatric interventional cardiologists, interventional radiologists, and neurosurgeons. Much can be learned from our respective colleagues in these areas which can further our own world of interventions.

How to reference

In order to correctly reference this scholarly work, feel free to copy and paste the following:

Thomas J. Forbes, Srinath Gowda and Daniel R. Turner (2012). Arterial Angioplasty in Congenital Heart Disease, Angioplasty, Various Techniques and Challenges in Treatment of Congenital and Acquired Vascular Stenoses, Dr. Thomas Forbes (Ed.), ISBN: 978-953-51-0084-3, InTech, Available from:
<http://www.intechopen.com/books/angioplasty-various-techniques-and-challenges-in-treatment-of-congenital-and-acquired-vascular-stenoses/angioplasty-in-congenital-heart-disease>

INTECH
open science | open minds

InTech Europe

University Campus STeP Ri
Slavka Krautzeka 83/A
51000 Rijeka, Croatia
Phone: +385 (51) 770 447
Fax: +385 (51) 686 166
www.intechopen.com

InTech China

Unit 405, Office Block, Hotel Equatorial Shanghai
No.65, Yan An Road (West), Shanghai, 200040, China
中国上海市延安西路65号上海国际贵都大饭店办公楼405单元
Phone: +86-21-62489820
Fax: +86-21-62489821

© 2012 The Author(s). Licensee IntechOpen. This is an open access article distributed under the terms of the [Creative Commons Attribution 3.0 License](https://creativecommons.org/licenses/by/3.0/), which permits unrestricted use, distribution, and reproduction in any medium, provided the original work is properly cited.

IntechOpen

IntechOpen