

# We are IntechOpen, the world's leading publisher of Open Access books Built by scientists, for scientists

6,900

Open access books available

186,000

International authors and editors

200M

Downloads

Our authors are among the

154

Countries delivered to

TOP 1%

most cited scientists

12.2%

Contributors from top 500 universities



WEB OF SCIENCE™

Selection of our books indexed in the Book Citation Index  
in Web of Science™ Core Collection (BKCI)

Interested in publishing with us?  
Contact [book.department@intechopen.com](mailto:book.department@intechopen.com)

Numbers displayed above are based on latest data collected.  
For more information visit [www.intechopen.com](http://www.intechopen.com)



# Percutaneous Angioplasty and Stenting for Mesenteric Ischaemia

Emily He<sup>1</sup> and Stephen M. Riordan<sup>2</sup>

<sup>1</sup>*Gastroenterology Registrar, Gastrointestinal and Liver Unit  
Prince of Wales Hospital, Sydney*

<sup>2</sup>*Senior Staff Specialist, Gastrointestinal and Liver Unit, Prince of Wales Hospital  
Sydney, Australia and Professor of Medicine (Conjoint)  
University of New South Wales, Sydney  
Australia*

## 1. Introduction

Mesenteric ischaemia due to impaired arterial supply is an important cause of abdominal pain, especially in older patients with risk factors for vascular disease. Until recently, surgical revascularisation procedures such as endarterectomy and aorto-coeliac or aorto-mesenteric bypass grafting were the only available treatment options for patients with mesenteric ischaemia. However, reported rates of peri-operative major complications and mortality are high, influenced by a high prevalence of significant patient co-morbidities. Percutaneous angioplasty and stenting have been shown to be effective and safe alternatives to surgical revascularisation in high-risk patients with mesenteric ischaemia. Indeed, in high-surgical risk patients and in those with suitable lesions, such endovascular revascularisation has emerged as the primary treatment modality.

Here, we review current concepts in the diagnosis, treatment selection and outcomes for percutaneous angioplasty and stenting for patients with either chronic or acute mesenteric ischemia.

## 2. Chronic mesenteric ischaemia

Chronic mesenteric ischaemia (CMI) most commonly arises from atherosclerotic diseases of the mesenteric arteries. Other causes of CMI include aortic dissection, fibromuscular dysplasia, vasculitides and median arcuate ligament syndrome.

Atherosclerotic disease of the mesenteric arteries is estimated to occur in 17% of patients over the age 65 years (Hansen et al., 2004). Despite its prevalence, the majority of these patients are asymptomatic as a result of the extensive collateral circulation between the celiac trunk, superior mesenteric artery (SMA) and inferior mesenteric artery (IMA). Whether or not ischaemia ensues depends on the site of the stenosis or occlusion and the development or otherwise of collateral vessels (Loffroy et al., 2009). CMI typically occurs in patients who have SMA lesions in conjunction with lesions in either the celiac trunk or IMA. However, mesenteric ischaemia can also develop in patients with a single vessel lesion. Distal lesions are more likely to be symptomatic compared with more proximal arterial pathology due to the absence of an effective collateral circulation.

3. Clinical presentation

CMI commonly affects people over the age of 60 years, with women three times more likely to be affected than men (Hansen et al., 2004). Most patients have multiple cardiovascular risk factors and atherosclerotic complications in other vascular territories. Classic symptoms of CMI include postprandial abdominal pain, fear of eating and significant weight loss. Patients may also present with persistent nausea and diarrhoea. These symptoms are non-specific and extensive investigations are generally undertaken to exclude other pathologies such as gastrointestinal or pancreatic malignancy.

4. Diagnosis

Duplex ultrasound is a useful, non-invasive screening test for mesenteric ischaemia (Moneta et al., 1993) (Table 1). Its accuracy is affected by operator experience and patient factors such as fasting status, body habitus and presence of bowel gas. CT-angiography and MR-angiography are of value in cases where duplex ultrasound is inconclusive (Cademartiri et al., 2008; Horton et al., 2007; Laissy et al., 2002). CT-angiography also provides excellent 3-D anatomical reconstruction to facilitate planning for endovascular revascularisation. Nevertheless, digital subtraction angiography remains the gold standard in evaluating the degree of stenosis in mesenteric vessels.

Vessel	Duplex criteria	Sensitivity	Specificity	Accuracy
SMA	PSV > 275cm/s	92%	96%	96%
Coeliac trunk	PSV > 200cm/s	87%	82%	82%

PSV: peak systolic velocity

Table 1. Duplex ultrasound criteria for detecting >70% stenosis in mesenteric vessels (from Moneta et al., 1993).

5. Treatment options

Treatment of symptomatic CMI is aimed at relieving symptoms and preventing progression to acute mesenteric ischaemia (AMI) and intestinal infarction. Prophylactic treatment of asymptomatic patients is controversial. The risk of progressing to AMI is greatest in patients with three-vessel disease with an estimated one third of these patients progressing to intestinal infarction if left untreated (Kolkman et al., 2004). The prognosis is relatively benign in those with single-vessel disease. In participants of the Cardiovascular Health Study who were found to have isolated coeliac trunk or mesenteric artery disease on duplex ultrasound, there was no increased risk of mortality, intestinal infarction or development of symptoms consistent with CMI over a median follow up period of 6.5years (Wilson et al., 2006). The gold standard of treatment has traditionally been surgical revascularisation in the form of bypass, endarterectomy or embolectomy. Given that patients affected by CMI are generally malnourished, of advanced age and have multiple cardiovascular co-morbidities, there is considerable peri-operative mortality (0-17%) and morbidity (15-33%) associated with surgical revascularisation (Kougias et al., 2009). Endovascular revascularisation is increasingly being offered to patients affected by CMI. In a large US registry study comprising of 5583 patients treated for CMI during the years 1988

to 2006 (Schermerhorn et al., 2009), the number of endovascular procedures steadily increased, surpassing all surgery for CMI in 2002. Endovascular revascularisation is associated with a lower in-hospital mortality and morbidity rate as well as shorter length of stay. Significantly lower rates of bowel resection, as well as fewer renal, cardiac and respiratory complications have been reported in patients who received endovascular revascularisation compared to surgically-treated counterparts (Table 2). A later analysis of published data concerning procedures performed between 2000 and 2009 similarly demonstrated a significantly reduced peri-operative complication rate in patients managed by endovascular therapy compared to surgery (Gupta et al., 2010).

	Endovascular revascularisation	Surgical revascularisation	p- value
Mortality	3.7%	15.4%	<0.001
Overall morbidity	20%	38%	<0.05
Bowel resection	3%	8%	<0.001
Cardiac events	0.7%	5.9%	<0.001
Respiratory events	0.3%	5.7%	<0.001
Acute renal failure	6.0%	10.5%	<0.05
LOS median (range), days	5 (0-94)	11 (1-135)	<0.001

Table 2. Mortality, morbidity, peri-operative complications and length of stay (LOS): endovascular revascularisation vs. surgical revascularisation. (adapted from Schermerhorn et al., 2009)

A serious potential complication of endovascular treatment is the precipitation of acute intestinal ischemia by plaque embolization or dissection of the artery. Standard catheter based salvage techniques such as stent deployment, embolectomy or thrombolysis are usually successful in treating these complications. Emergency laparotomy with mesenteric bypass and bowel resection is also used as salvage treatment. We recently reported the occurrence of splenic infarction complicating otherwise successful celiac artery stenting, presumably as a consequence of distal embolization of disrupted calcific plaque, with this complication representing a novel cause of abdominal pain post-procedure (Almeida & Riordan, 2008).

The most common procedural complication of endovascular therapy relates to the puncture site, manifesting as either haemorrhage or thrombosis. Haemorrhage is generally controlled with local pressure and/or injection of thrombin. Insertion of interventional sheaths in small arteries is associated with an increased risk of thrombosis. Rapid heparinization after sheath insertion is usually an adequate preventative measure.

Another important issue is the longer-term arterial patency rate in patients treated by endovascular means compared to those managed surgically. In a recent review of 328 patients undergoing endovascular treatment for chronic mesenteric ischaemia, the overall technical success rate was 91% and immediate symptomatic relief was achieved in 82% of patients (Kougias et al., 2007). Despite the initial success rate, approximately one third of patients (84/292) available for follow up developed restenosis over a mean follow up period of 26 months. The 30-day mortality rate was 3-5%. Clinical series comparing endovascular and surgical revascularisation have shown that long term patency rates and freedom from

symptoms may be inferior in patients who have had endovascular revascularisation (Kougias et al., 2009; Atkins et al., 2007; Kasiragjan et al., 2001). Indeed, an analysis of all published literature comparing surgical and endovascular treatment options for CMI performed between 2000 and 2009 concluded that 5-year primary patency rates were 3.8 times greater in the surgical group ( $P < 0.001$ ), while freedom from symptoms at 5 years was 4.4 times greater in patients managed surgically compared to those treated with endovascular techniques ( $p < 0.001$ ) (Gupta et al., 2010).

## 6. Angioplasty vs stenting

There is general agreement that stenting is indicated for residual stenosis following primary angioplasty (defined as residual stenosis of 30% or more, or pressure gradient higher than 15mmHg), for ostial or eccentric lesions, or as a salvage procedure for acute dissection after angioplasty (Kougias et al., 2007). Balloon-expandable stents are preferred because of their accuracy and ability to generate considerable radial force. More distal or long lesions may be better suited to self-expandable stents given their flexibility (Loffroy et al., 2009).

Kougias et al (2007) reported that technical success was significantly higher with stenting compared with angioplasty alone (95% vs 83%,  $p = 0.007$ ), although the rate of restenosis was also higher in the stented subgroup, a finding that may have been biased by the inclusion of earlier studies where more primitive stents were used and peri-procedural anticoagulant and antiplatelet treatment regimens were not standardized. A recent case series demonstrated that long-term patency rate was higher in patients managed with primary stenting compared to angioplasty alone (Daliri et al., 2010).

## 7. Which vessel to treat

Literature from the surgical revascularisation setting has shown that complete revascularisation of the coeliac trunk and SMA is associated with improved long-term outcomes (Mateo et al., 1999; McAfee et al., 1992; Foley et al., 2000). The simultaneous treatment of two vessels prevents symptom recurrence in the event of restenosis in either artery. Improved graft patency and survival with complete reconstruction (McAfee et al., 1992), and a higher incidence of symptoms and graft failure with single vessel therapy (Foley et al., 2000) have each been demonstrated.

There is a tendency to treat fewer vessels when choosing endovascular revascularisation compared with surgical revascularisation (Kougias et al., 2009). The conventional approach to endovascular intervention is to treat SMA lesions in preference to celiac trunk or IMA lesions. There is conflicting evidence as to whether treatment of both SMA and celiac arteries will produce better long-term patency. A recent series by Peck et al indicated that two-vessel treatment resulted in lower symptomatic recurrences, improved patency and fewer re-interventions (Peck et al., 2010). On the other hand, Sarac et al. (2008) did not report any difference in 1 year patency between single-vessel and two-vessel treatment, while Malgor et al. (2010) similarly found in a study of longer follow-up of 3 years that two-vessel celiac artery and SMA stenting did not result in improved outcomes when compared with single-vessel SMA stent placement for CMI.

Traditionally, there has been a preference for treating stenotic rather than occlusive lesions by endovascular means. Although the presence of an occluded vessel is not an absolute contraindication to endovascular intervention, the practice in many centres is to convert



from endovascular to open surgical revascularisation when an occlusion is found (Kasiragjan et al., 2001). Endovascular passage of guide wires and stents through totally occluded lesions is a technically challenging procedure and not without significant risks of vessel perforation or dissection. Although not statistically validated, the degree of difficulty is likely to increase with the length of occlusion. A theoretical concern also exists for plaque fragmentation and distal embolization, which also increases with the length of occlusion.

Although the efficacy of endovascular intervention in treating occluded mesenteric vessels is not well established, evolving endovascular technology with low-profile systems has now made recanalization of occluded vessels feasible. Landis et al. (2005) reported technical success and 1-year patency rates of 100% in 9 patients with mesenteric occlusion. A case series by Peck et al. also indicated that patients with occluded SMA who underwent revascularisation had lower 3-year symptom recurrence rates, with three year patency rates of 90% for treated SMA occlusions versus 40% for untreated SMA occlusions (Peck et al., 2010). This difference however was not statistically significant, possibly due to the small numbers of patients studied.

## 8. Surveillance of vessel patency

There is a lack of uniformity in the follow up of patients who have received endovascular therapy for CMI. Although recurrence of symptoms is correlated with restenosis, this alone is not a reliable predictor of vessel patency, with sensitivity as low as 33% for detection of restenosis (McMillan et al., 1995). Failure to diagnose progressive disease in asymptomatic patients may result in the subsequent development of acute mesenteric thrombosis. This is a potentially fatal vascular emergency with overall mortality rate ranging from 32% to 65% (Park et al., 2002).

Abdominal duplex ultrasonography is the most commonly used method of surveillance due to its non-invasive nature. Although duplex ultrasonography has been validated in the diagnosis of mesenteric arterial stenosis (Zwolak et al., 1998), there is no current consensus on which velocity criteria should be used to define high-grade recurrent disease (Kasirajan et al., 2001; Armstrong et al., 2007; Fenwick et al., 2007). CT-angiography and MR-angiography are alternative modalities of imaging, although digital subtraction angiography is generally considered the gold standard. There is a potential role for functional studies such as gastrointestinal tonometry to detect mesenteric ischemia and guide treatment (Otte et al., 2008).

## 9. Acute mesenteric ischemia

Acute mesenteric ischemia is associated with a daunting mortality rate of greater than 50% (Schermerhorn et al., 2009). Prompt diagnosis and institution of revascularisation therapy are crucial for a successful outcome.

Endovascular treatment for AMI was traditionally reserved for selected patients who have prohibitive operative risk, no clinical signs of peritoneal inflammation, or those with a contaminated peritoneal cavity and no autogenous vessel available for grafting (Loffroy et al., 2009). With evolving expertise and technological advancements in endovascular therapy, there has been an increase in the use of endovascular revascularisation for treatment of AMI. In the US registry study of 5237 patients treated for AMI, the outcomes of patients who were treated with endovascular intervention were compared to those who were treated with

surgery (Schermerhorn et al., 2009). Patients who were treated with endovascular measures tended to have higher rates of cardiovascular comorbidities than those undergoing open surgical repair, including hypertension, peripheral vascular disease, coronary artery disease and chronic renal failure. Despite these unfavourable patient characteristics, mortality was significantly lower in the endovascular group compared with the surgical group (16% vs 39%,  $p < 0.001$ ).

In a recent retrospective, single centre case series of 70 patients with AMI, the largest such case series to date, Arthurs et al. (2011) demonstrated that the use of endovascular therapy as primary treatment for AMI produced lower complication rates and better outcomes (Arthurs et al., 2011). During a 9-year study period, endovascular therapy was initiated in 56 patients while surgical therapy was used in 24 patients. Overall, technical success for endovascular therapy was 87%. Failures in endovascular therapy were treated with embolectomy in 78% and revascularisation in 22%. Successful endovascular treatment resulted in a mortality rate of 36%, which was significantly lower compared with a rate of 50% in those treated surgically ( $p < 0.05$ ). Patients who failed endovascular treatment had a mortality rate of 50%, an outcome which was equivalent to that of traditional surgical therapy. Block et al. (2010) have also recently reported improved 30 day and long-term survival with endovascular revascularisation of the SMA compared to surgery in patients identified through the Swedish Vascular Registry from 1999 to 2006, although the need for prospective randomised data to confirm group differences was highlighted.

The general view that laparotomy is crucial for all patients with AMI to assess intestinal viability and perform resection as required has also recently been questioned. Arthurs et al. (2011) challenged this philosophy by performing laparotomy only on patients who had signs of peritoneal inflammation or deteriorated clinically following initial revascularisation. Over 30% of patients in the endovascular therapy group did not ultimately require laparotomy, thereby avoiding further physiologic insult to patients who are already critically ill.

Another important issue is to what extent ischaemia-reperfusion injury of the intestine, leading to microvascular injury and cellular necrosis and apoptosis, contributes to morbidity and mortality in patients in whom arterial revascularisation is attained and whether various recent advances in preventing or limiting this phenomenon described in the experimental situation can be translated clinically (Santora et al., 2011; Petrat & de Groot, 2011; Flessas et al., 2011).

## 10. Conclusions

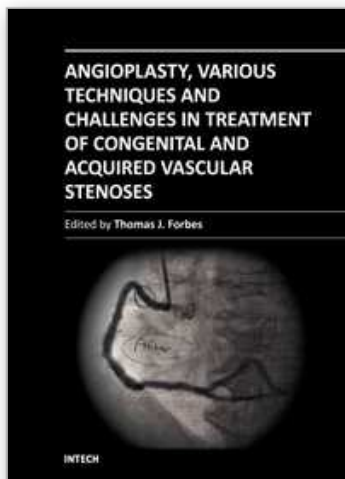
There has been a recent paradigm shift in the treatment of mesenteric ischaemia. Whereas endovascular therapy was once reserved for the few patients who had prohibitive operative risks, it is now increasingly used for revascularisation of both chronic and acute mesenteric ischemia. Endovascular therapy is less invasive than open surgery, and is associated with lower peri-procedural morbidity and mortality. There is growing evidence that stenting may achieve better technical success and patency rates compared with angioplasty alone. The timing and choice of imaging modality for surveillance of vessel patency remains an important question for clinicians. Effective approaches to improving longer-term vessel patency rates following endovascular therapy are required, along with strategies to prevent ischaemia-reperfusion injury in those patients with acute mesenteric ischaemia in whom revascularisation is achieved.

## 11. References

- Almeida JA, Riordan SM. Splenic infarction complicating percutaneous transluminal coeliac artery stenting for chronic mesenteric ischaemia. *Journal of Medical Case Reports* 2008; 2: 261.
- Armstrong PA. Visceral duplex scanning: evaluation before and after artery intervention for chronic mesenteric ischemia. *Perspect Vasc Surg Endovasc Ther* 2007; 19: 386-92.
- Arthurs ZM, Titus J, Bannazadeh M, et al. A comparison of endovascular revascularisation with traditional therapy for the treatment of acute mesenteric ischemia. *J Vasc Surg* 2011; 53:698-704.
- Atkins MD, Kwolek CJ, LaMuraglia GM. Surgical revascularisation versus endovascular therapy for chronic mesenteric ischemia: a comparative experience. *J Vasc Surg* 2007; 45:1162-1171.
- Block TA, Acosta S, Bjorck M. Endovascular and open surgery for acute occlusion of the superior mesenteric artery. *Journal of Vascular Surgery* 2010; 52 (4): 959-966.
- Cademartiri F, Palumbo A, Maffei E, et al. Noninvasive evaluation of the celiac trunk and superior mesenteric artery with multislice CT in patients with chronic mesenteric ischemia. *Radiol Med* 2008; 113:1135-1142.
- Daliri A, Grunwald C, Jobst B, et al. Endovascular treatment for chronic atherosclerotic occlusive mesenteric disease: is stenting superior to balloon angioplasty? *Vasa* 2010; 39: 319-24
- Fenwick JL, Wright. Endovascular repair of chronic mesenteric occlusive disease: the role of duplex surveillance. *Aust N Z J Surg* 2007; 77:60-63
- Flessas IL, Papalois AE, Toutouzas K, Zagouri F, Zografos GC. Effects of lazaroids on intestinal ischemia and reperfusion injury in experimental models. *Journal of Surgical Research* 2011; 166: 265-274.
- Foley MI, Moneta GL, Abou-Zamzam AM Jr, et al. Revascularisation of the superior mesenteric artery alone for treatment of intestinal ischemia. *J Vasc Surg* 2000;32:37-47
- Gupta PK, Horan SM, Turaga KK, Miller WJ, Pipinos II. Chronic mesenteric ischemia: endovascular versus open revascularisation. *Journal of Endovascular Therapy* 2010; 17 (4): 540-549.
- Hansen KJ, Wilson DB, Craven TE, et al. Mesenteric artery disease in the elderly. *J Vasc Surg* 2004;40:45-52
- Horton KM, Fishman EK. Multidetector CT angiography in the diagnosis of mesenteric ischemia. *Radiol Clin North Am* 2007; 45:275-288
- Kasirajan K, O'Hara PJ, Gray BH, et al. Chronic mesenteric ischemia: Open surgery versus percutaneous angioplasty and stenting. *J Vasc Surg* 2001;33:63-71
- Kolkman JJ, Mensink PB, van Petersen AS, et al. Clinical approach to chronic gastrointestinal ischemia from "intestinal angina" to the spectrum of chronic splanchnic disease. *Scand J Gastroenterol Suppl* 2004; 241: 9-16.
- Kougias P, El Sayed H, Zhou W, et al. Management of chronic mesenteric ischemia. The Role of Endovascular Therapy. *J Endovasc Ther* 2007; 14:395-405
- Kougias P, Huyng TT, Lin PH. Clinical outcomes of mesenteric artery stenting versus surgical revascularisation in chronic mesenteric ischemia. *Int Angio*. 2009; 28(2):132-137.



- Laissy JP, Trillaud H, Douek P. MR angiography: noninvasive vascular imaging of the abdomen. *Abdom Imaging* 2002; 27:488-506
- Landis MS, Rajan DK, Simons ME, et al. Percutaneous management of chronic mesenteric ischemia: outcomes after intervention. *J Vasc Inter Radiol* 2005; 16:1319-1325
- Loffroy R, Steinmetz E, Guiu B, et al. Role for endovascular therapy in chronic mesenteric ischemia. *Can J Gastroenterol* 2009; 23:365-373
- Malgor RD, Oderich GS, McKusick MA, Misra S, Kalra M, Duncan AA, Bower TC, Glaviczk P. Results of single- and two-vessel mesenteric artery stents for chronic mesenteric ischemia. *Annals of Vascular Surgery* 2010; 24 (8): 1094-1101.
- Mateo RB, O'Hara PJ, Hertzner NR, et al. Elective surgical treatment of symptomatic chronic mesenteric occlusive disease: early results and late outcomes. *J Vasc Surg* 1999; 29:821-31
- McAfee MK, Cherry KJ Jr, Naessens JM, et al. Influence of complete revascularisation on chronic mesenteric ischemia. *Am J Surg* 1992; 164:220-4
- McMillan WD, McCarthy WJ, Bresticker MR, et al. Mesenteric artery bypass: objective patency determination. *J Vasc Surg* 1995; 21: 729-740
- Moneta GL, Lee RW, Yeager RA, et al. Mesenteric duplex scanning: a blinded prospective study. *J Vasc Surg* 1993; 17:79-84
- Otte JA, Huisman AB, Geelkerken Rh, et al. Jejunal tonometry for the diagnosis of gastrointestinal ischemia. Feasibility, normal values and comparison of jejunal with gastric tonometry exercise testing. *Eur J Gastroenterol Hepatol* 2008; 20:62-67
- Peck MC, Conrad MF, Kwolek CJ, et al. Intermediate-term outcomes of endovascular treatment for symptomatic chronic mesenteric ischemia. *J Vasc Surg* 2010; 51:140-7
- Petrat F, Ronn T, de Groot H. Protection by pyruvate infusion in a rat model of severe intestinal ischemia-reperfusion injury. *Journal of Surgical Research* 2011; 167 (2): e93-e101.
- Santora RJ, Lie ML, Grigorev DN, Nasir O, Moore FA, Hassoun HT. *Journal of Vascular Surgery* 2010; 52 (4): 1003-1014.
- Sarac TP, Altinel O, Kashyap V, et al. Endovascular treatment of stenotic and occluded visceral arteries for chronic mesenteric ischemia. *J Vasc Surg* 2008; 47:485-91
- Schermerhorn ML, Giles KA, Hamdan AD, et al. Mesenteric revascularisation: management and outcomes in the United States, 1988-2006. *J Vasc Surg* 2009; 50:341-348
- Wilson DB, Mostafavi K, Craven TE, et al. Clinical course of mesenteric artery stenosis in elderly Americans. *Arch Intern Med* 2006; 166:2095-100.
- Zwolak RM, Fillinger MF, Walsh DB, et al. Mesenteric and celiac duplex scanning: a validation study. *J Vasc Surg* 1998; 27:1078-87.



## **Angioplasty, Various Techniques and Challenges in Treatment of Congenital and Acquired Vascular Stenoses**

Edited by Dr. Thomas Forbes

ISBN 978-953-51-0084-3

Hard cover, 236 pages

**Publisher** InTech

**Published online** 14, March, 2012

**Published in print edition** March, 2012

The field of performing transcatheter interventions to treat vascular lesions has exploded over the past 20 years. Not only has the technology changed, especially in the arena of balloon/stent devices, but the techniques of approaching complex lesions has evolved over the past decade. Lesions that no one would have imagined treating back in the 1990's are now being done routinely in the catheterization suite. This book provides an update on the current techniques and devices used to treat a wide variety of lesions. Though, at first, the outward appearance of the topics appears to be varied, they are all related by the common thread of treating vascular lesions. We hope, by publishing this book, to accomplish two things: First, to offer insight from experts in their field to treat, both medically and procedurally, complex vascular lesions that we frequently encounter. Secondly, we hope to promote increased communication between areas of medicine that frequently don't communicate, between adult interventional cardiologists, pediatric interventional cardiologists, interventional radiologists, and neurosurgeons. Much can be learned from our respective colleagues in these areas which can further our own world of interventions.

### **How to reference**

In order to correctly reference this scholarly work, feel free to copy and paste the following:

Emily He and Stephen M. Riordan (2012). Percutaneous Angioplasty and Stenting for Mesenteric Ischaemia, Angioplasty, Various Techniques and Challenges in Treatment of Congenital and Acquired Vascular Stenoses, Dr. Thomas Forbes (Ed.), ISBN: 978-953-51-0084-3, InTech, Available from:  
<http://www.intechopen.com/books/angioplasty-various-techniques-and-challenges-in-treatment-of-congenital-and-acquired-vascular-stenoses/angioplasty-and-stenting-for-mesenteric-ischaemia>

**INTECH**  
open science | open minds

### **InTech Europe**

University Campus STeP Ri  
Slavka Krautzeka 83/A  
51000 Rijeka, Croatia  
Phone: +385 (51) 770 447  
Fax: +385 (51) 686 166  
[www.intechopen.com](http://www.intechopen.com)

### **InTech China**

Unit 405, Office Block, Hotel Equatorial Shanghai  
No.65, Yan An Road (West), Shanghai, 200040, China  
中国上海市延安西路65号上海国际贵都大饭店办公楼405单元  
Phone: +86-21-62489820  
Fax: +86-21-62489821

© 2012 The Author(s). Licensee IntechOpen. This is an open access article distributed under the terms of the [Creative Commons Attribution 3.0 License](https://creativecommons.org/licenses/by/3.0/), which permits unrestricted use, distribution, and reproduction in any medium, provided the original work is properly cited.

IntechOpen

IntechOpen