

We are IntechOpen, the world's leading publisher of Open Access books Built by scientists, for scientists

6,900

Open access books available

186,000

International authors and editors

200M

Downloads

Our authors are among the

154

Countries delivered to

TOP 1%

most cited scientists

12.2%

Contributors from top 500 universities



WEB OF SCIENCE™

Selection of our books indexed in the Book Citation Index
in Web of Science™ Core Collection (BKCI)

Interested in publishing with us?
Contact book.department@intechopen.com

Numbers displayed above are based on latest data collected.
For more information visit www.intechopen.com



Retinal Vascular Occlusions

Mario Bradvica, Tvrtka Benašić and Maja Vinković
*University of Josip Juraj Strossmayer, Medical School Osijek, University Hospital Osijek
 Croatia*

1. Introduction

Retinal vascular occlusions are serious diseases and significant causes of blindness that include arterial and venous obstructions. The causes, pathogenesis, clinical characteristics, prognosis, and response to therapy are influenced by the location of the occlusion in the retinal vasculature and by the extent of retinal nonperfusion.

The hallmark of clinical presentation in the retinal occlusive disease is painless loss of vision, which can be asymptomatic, gradual with only mildly reduced visual acuity, or sudden and reduced to counting fingers depending on the extent of the irrigation area of the affected vessel. The clinical presentation aids in distinguishing the type of the occlusion, which may be classified according to the anatomical site of the occlusion.

2. Retinal Artery Occlusion

Retinal artery occlusion (RAO) represents an ophthalmologic emergency. In 1859, von Graefe first described central retinal artery occlusion (von Graefe, 1859). Retinal artery obstruction may be classified as follows: central (CRAO), affecting the retinal vessel at the optic nerve, hemicentral (occasional, only when one of the two trunks of the CRA is occluded) (Akkoyun et al., 2006; Karagoz et al., 2009; Schmidt & Kramer-Zucker, 2011), branch (BRAO), obstruction distally to the lamina cribrosa of the optic nerve, cilioretinal (CLRAO) and central sparing cilioretinal artery (Hayreh, 2011). Obstructions more proximal to the central retinal artery, in the ophthalmic artery, or even in the internal carotid artery, may produce visual loss as well. More proximal obstructions usually cause a more chronic form of visual problem—the ocular ischemic syndrome often associated with occlusive carotid disease (Kearns & Hollenhorst, 1963).

Central retinal artery occlusion results in sudden visual loss and is therefore one of the most important topics in ophthalmology. Branch retinal artery occlusion causes sudden segmental visual loss and may recur to involve other branch retinal arterioles. Amaurosis fugax is a common transient acute retinal ischemic condition. Acute retinal arterial occlusive disorders together comprise one of the major causes of acute visual loss (Hayreh, 2011). Only anecdotal reports have described spontaneous recovery of vision, and case series have shown only up to 14% of spontaneous recovery (Atebara et al., 1995).

The majority of retinal arterial obstructions are either thrombotic or embolic in nature (an embolus is visible only in 20% of the patients with branch or central retinal artery occlusion)

(Rumelt & Brown, 2003). Arterial occlusions in the eye are almost always due to microembolism and the major source of microemboli is the plaque(s), which may be present with or without any significant carotid artery stenosis. Thus, absence of significant stenosis of the carotid artery does not necessarily rule out the carotid artery as the source of microembolism (Hayreh et al., 2009).

Immediate intervention improves chances of visual recovery, but even then, the prognosis is rather poor, with only 21-35% of eyes retaining useful vision (Jain & Juang, 2009), because it dominantly depends on the type of the occlusion (Hayreh & Zimmerman, 2005). Although restoration of vision is of immediate concern, retinal artery occlusion is a forerunner for other systemic diseases that must be evaluated promptly. Establishing of the cause of obstruction is essential. In case of giant cell arteritis causing occlusion immediate treatment is urgent.

2.1 Epidemiology

Central retinal artery obstruction (CRAO) is a rare event – it has been estimated to account for about 0.85 in 100,000 per year (Jain & Juang, 2009). The mean age at onset is about 60 years, with a range from the first to the ninth decade of life (Duker, 2003). Bilateral obstruction occurs in 1-2% of cases (Brown, 1994). CRAOs account for 58% of acute RAOs, BRAOs for 38%, and cilioretinal artery occlusions (CLRAOs) (Jain & Juang, 2009). There are discrepancies among authors regarding the prevalence of men over women. Some advocate the ratio 2:1 (Duker, 2003) whereas the others found slightly more frequent occurrence in men (Hayreh et al., 2009). A large case series documented that approximately one fourth of patients with CRAO had a form with the cilioretinal sparing (Brown & Shields, 1979). The incidence of CLRA occlusion (CLRAO) varies in different studies from none to 32% (Justice & Lehmann 1976), which would be the most acceptable data, because the incidence was calculated by reviewing stereoscopic color fundus photographs as well as FA; the incidence of CLRAO is in direct proportion with the presence of cilioretinal artery in the population. FA is the most reliable way to ascertain the true incidence because the CLRA dyes concurrently with the filling of the choroid and usually before the start of filling of the CRA. The arteries occurred bilaterally in 14.6% (Justice & Lehmann, 1976).

Multiple studies have shown increased mortality in patients with retinal arterial emboli (Bruno et al., 1995; Ho et al., 2008; Lindley et al., 2009). The frequency of retinal emboli increases with age and are more common in men than in women. Bilateral are rare, although multiple emboli in a single eye may be seen in up to one third of cases. They are associated with the presence of carotid artery disease (CAD), hypertension, smoking, and possibly diabetes (Wong & Klein, 2002). The large Beaver Dam Eye Study calculated the prevalence of retinal arteriolar emboli of 1.3% in the population ranged from 43-86 years, and the 5-year incidence of 0.9%, the 10-year incidence of 1.5% for the same population, and also confirmed a significantly higher hazard of dying from a stroke in people with retinal emboli (Klein et al., 1999; Klein et al., 2003).

Debate exists in the literature on the prevalence and etiology of neovascularization (NV) following CRAO. The reported prevalence varies from 2.5% to 31.6%. Studies have reported prevalence of 18.2% of neovascularization and 15.2% of neovascular glaucoma (NVG) (Duker et al., 1991; Rudkin et al., 2010). In branch retinal artery occlusion, the incidence is

even rarer. Neovascularization is more likely to occur in persons with concurrent diseases and not CRAO per se, as with diabetes, severe carotid artery disease or generalized atherosclerosis (Hayreh & Podhajsky, 1982). Clinical cases have been reported in which neovascular glaucoma developed after branch retinal artery occlusion (Brown & Reber, 1986); most probably they are a result of later complete CRAO rather than pure BRAO.

2.2 Pathophysiology and histology

Visual loss from retinal arterial occlusion (RAO) occurs from the loss of blood supply to the inner layer of the retina. Blood supply to the retina originates from the central retinal (CRA) and the cilioretinal (CLRA) artery. The primary source of blood supply to both arteries - the ophthalmic artery (OA), usually the first intracranial branch of the internal carotid artery (ICA), does not always originate from the ICA; the most common abnormal origin is the middle meningeal artery (Hayreh, 2011; Morandi et al., 1998). The central retinal artery arises independently in 37.5% from the ophthalmic artery, in 59.5% by a common trunk with one or another posterior ciliary artery (PCA), and extremely rarely with other branches of the OA. Numerous anastomoses are established by the branches of the CRA with other branches of the OA, mostly pial. The study showed that these pial anastomoses were usually large enough to establish a variable amount of collateral circulation in the eye having an occlusion of the CRA. This was also demonstrated by fluorescein fundus angiography (FA) (Hayreh, 2011; Hayreh & Weingeist, 1980). The central retinal artery supplies the retina as it branches into smaller segments upon leaving the optic disc. The so-called "branch retinal arteries" are in fact arterioles after the first branching in the retina which don't have either an internal elastic lamina or a continuous muscular layer (Hayreh, 2011). A retinal vascular bed does not own any anastomoses; it is end-arterial system. The cilioretinal artery belongs to the PCA system; it usually originates from the peripapillary choroid or directly from one of the PCAs and supplies the part of the macular retina. The CLRA has a characteristic hook-like appearance at its site of entry into the retina at the optic disc margin, usually on the temporal side. Branch retinal artery occlusion (BRAO) occurs when the embolus lodges in a more distal branch of the retinal artery. BRAO typically involves the temporal retinal vessels and usually does not require treatment, unless perifoveolar vessels are threatened (Ho et al., 2008).

Acutely, obstruction of the central retinal artery results in inner retinal layer edema and pyknosis of the ganglion cell nuclei. Ischemic necrosis results and the retina become opacified and yellow-white in appearance. The opacity is most dense in the posterior pole as a result of the increased thickness of the nerve fiber layer and ganglion cells in this region. The opacification takes as little as 15 minutes to several hours before becoming evident and resolves in 4-6 weeks. Furthermore, the foveola assumes a cherry-red spot because of a combination of 3 factors: (i) the intact retinal pigment epithelium and choroid underlying the fovea, (ii) the foveolar retina is nourished by the choriocapillaris, and (iii) the thinnest NFL at this location. The late stage shows a homogenous scar replacing the inner layer of the retina. Pigmentary changes are typically absent since the retinal pigment epithelium remains unaffected (Kearns & Hollenhorst, 1963).

It has been shown experimentally on animal studies that the retinal damage is irreversible after 105 minutes of completely occluded circulation, but may recover at 97 minutes (Hayreh et al., 2004), and the treatment instituted at any time beyond 4h after the onset of

CRAO cannot have any scientific rationale for improvement of vision. However, complete occlusion or retinal artery circulation in humans is rare with retinal artery disease; thus, retinal recovery is possible even after days of ischemia (Brown & Magargal, 1988). Controversy exists regarding the optimal window of treatment in humans, but the conservative approach involves treatment up to 24 hours (Kearns & Hollenhorst, 1963).

The retinal artery could be occluded due to embolism, vasoobliteration (atherosclerotic plaques, giant-cell arteritis and other types of vasculitis) and vascular compression (a retrobulbar mass - hematoma, neoplasm, retrobulbar injections may lead to an optic nerve and central retinal artery compression) (Korner-Stiefbold, 2001), angiospasm, hemodynamic or hydrostatic arterial occlusion (Hayreh, 2011). By far the most common cause of nonarteritic RAO is the embolism. Emboli are usually of three types: cholesterol - Hollenhorst plaque, platelet-fibrin, calcified, and occasionally myxomatous, or bacterial. The incidence is 74%, 15.5% and 10.5% for the first 3 types, respectively (Arruga & Sanders, 1982). They are mostly of carotid and/or cardiac origin (Korner-Stiefbold, 2001). The major source of embolism in the carotid arteries is plaque (66%), whereas a significant carotid stenosis (>50%) accounts for only 30% of cases (Hayreh et al., 2009; Korner-Stiefbold, 2001; Younge, 1989). Statistically, Caucasians, when compared to African Americans, have significantly different incidence of ICA stenosis, which is 41% and 3.4% for the each group, respectively (Ahuja et al., 1999). A significant stenosis of the extracranial internal carotid artery is the most common identified condition associated with retinal and ocular ischemia (Biousse, 1997; Mizener et al., 1997; Sharma et al., 1998). It represents the hemodynamic cause, and, especially if associated with nocturnal arterial hypotension, can lead to transient CRAO (Hayreh & Zimmerman, 2005). The sources of emboli in heart are valvular lesions, patent foramen ovale, myxoma and endocarditis (Mangat, 1995; Reese & Shafer, 1978; Schmidt et al., 2005; Sharma et al., 1997). It must be remembered though, that the absence of any abnormality on color Doppler ultrasound or echocardiography does not exclude carotid artery or the heart as the source of microembolism, because of the test-resolution and location of the plaque/stenosis.

Animal studies have shown that, serotonin in atherosclerotic vessels produces vasospasm of the central retinal artery (CRA) and/or posterior ciliary artery (PCA) in various combinations (but not vasospasm of the arterioles in the retina). It is postulated that in some atherosclerotic individuals this mechanism may play an important role in the development of ischemic disorders of the retina and optic nerve head (ONH), including amaurosis fugax, CRA occlusion and anterior ischemic optic neuropathy, and possibly also glaucomatous optic neuropathy, particularly in normal tension glaucoma (Hayreh, 1999).

Central retinal arterial occlusions could be divided into permanent or transient; arteritic (usually gigantocellular arteritis) or nonarteritic occlusion. The transient is the nonarteritic and could occur due to (i) transient impaction of an embolus, (ii) fall of perfusion pressure in the retinal vascular bed below the critical level (night arterial hypotension, hypovolemic shock, hemodialysis, spasm of CRA, marked carotid artery disease, ocular ischemia, or a rise of intraocular pressure because of orbital swelling, acute angle-closure glaucoma, neovascular glaucoma (NVG) with ocular ischemia), and (iii) vasospasm of the atherosclerotic lesions (induced by the platelet-aggregation plaque secreting serotonin) (Hayreh, 2011).

Branch arterial occlusion is usually due to embolism and occasionally vasculitis. It could be recurrent (Barak et al., 1997; Beiran et al., 1995; Beversdorf et al., 1997; Johnson et al., 1994). Most of these cases probably have Susac's syndrome (autoimmune endotheliopathy leading to encephalopathy, BRAO and hearing loss) (Susac et al., 2007). The etiology of this syndrome is still unknown, but the prognosis is good in most cases. Spontaneous resolution usually occurs, but early treatment minimizes the risk of sequelae (Van Winden & Salu, 2010).

2.3 Causes

Embolism of the carotid artery and the heart are the most common causes of retinal artery obstruction. Carotid artery disease causes retinal arterial occlusion by three mechanisms: embolism, hemodynamic changes in significantly stenosed carotid artery, and arterial spasm. The major source of emboli is plaques in the carotid arteries, and much less frequently stenosis. According to some studies, hemodynamically significant carotid artery stenosis was found in about 18% of patients with acute RAO (Sharma et al., 1998) and as previously mentioned, Hayreh et al. suggest that the presence of plaques on Doppler color imaging is of more value in determining the cause of acute occlusive event rather than the embolus itself (Hayreh, 2005). The probable cause is the microembolism, which may not produce hemodynamically significant stenosis recordable on Doppler color imaging but may indeed account for the retinal artery occlusion. As shown in the study, carotid Doppler and/or angiography showed the presence of plaques in 71% in CRAO and 66% in BRAO (Hayreh et al., 2009). The fluctuation of hemodynamic factors, especially drops in blood pressure in nocturnal hypotension along with significant stenosis of the carotid artery may be responsible for transient retinal artery occlusion (Hayreh & Zimmerman, 2005; McCullough et al., 2004). Based on experimental studies on animals, the investigators have introduced the possible role of serotonin, released by platelet aggregation on atherosclerotic plaques in the carotid artery, causing transient vasospasm of the central retinal artery and thus potentially inducing retinal artery occlusion and retinal ischemic disorders.

Systemic cardiovascular diseases have a well known association with retinal arterial occlusive disease in elderly people (Sharma, 1998). Therefore, a careful history should include identifying the possible underlying causes such as arterial hypertension, diabetes mellitus, hyperlipidemia, carotid artery disease, coronary artery disease, cerebrovascular disease and symptoms suggestive of temporal arteritis. Cigarette smoking has been described significantly more common among these patients than in the general population. In patients with no obvious systemic risk factors and especially in subjects under the age of 40, the other causative options should be considered, which include systemic vasculitis, blood dyscrasias, drug abuse, hypercoagulable states, infective diseases, migraine and prolonged direct pressure to the globe in unconscious patients (Brown et al., 1981; Graham, 1990; Greven et al., 1995).

Coagulopathies from sickle cell anemia or antiphospholipid antibodies are more common etiologies for CRAO in patients younger than 30 years of age and the proposed mechanisms involve increase in coagulation factor or platelet activity, thrombocytosis, interaction of lupus anticoagulant and anticardiolipin antibodies with phospholipids as well as the deficiencies of protein C and S and resistance to activated protein C (Comp & Esmon, 1984; Love & Santoro, 1990; Palmowski-Wolfe et al., 2007; Vignes et al., 1996). Increased levels of homocysteine have been linked with higher incidence of occlusive vascular incidents damaging the vascular

endothelium and thus increasing atherosclerotic changes and the formation of blood clots. Therefore, in cases of suspected homocystinuria or heterozygosity for homocystinuria an oral methionine loading test may be performed since this state may be preventable by taking appropriate vitamin supplements (Boers et al., 1985; Weger et al., 2002; Wenzler et al., 1993). In cases of clinical suspicion, the HIV testing may be indicated since there have been case reports of CRAO or BRAO associated with HIV infection (Conway et al., 1995). A variety of other diseases, including systemic lupus erythematosus, polyarteritis nodosa, dengue fever, West Nile virus, sickle cell disease, Takayasu's arteritis, after smallpox vaccination, Churg-Strauss syndrome, ocular Behçet's disease, Fabry's disease, Susac's syndrome, and head injury may present with retinal occlusive disorders. It is necessary to exclude these states if there is a young person with sudden loss of vision, fundoscopic findings of arterial occlusion, central or branch, and no obvious identifiable systemic risk factors as above mentioned. In conclusion, arterial occlusive disease of the retina is the result of either arteriosclerotic thrombosis, embolic impaction (predominantly atheromatous plaques of carotid bifurcation, or the internal carotid artery, but also consisting of different material – fat, parasites, talc, air), vasculitis, vasospasm or systemic hypotension. These numerous potential causes mandate often time-consuming and expensive lab tests, and sometimes a causative management of the underlying disease. The possible causes and underlying states associated with retinal arterial occlusion are incorporated in Table 1.

2.4 Clinical presentation

2.4.1 Symptoms

The main presenting symptom of the arterial occlusive disease is loss of vision, usually monocular, which may be sudden (seconds to minutes) blurring, decrease or total loss of vision. The extent of visual loss depends on the type of the occlusion. In central artery occlusions, visual loss is central and dense. In branch artery occlusions, visual loss may go unnoticed if only a section of the peripheral visual field space is affected. Various types of the retinal artery occlusion have different degree of visual acuity (VA) drop; CRAO characterizes severely decreased VA (counting fingers to light perception); BRAO has VA 20/20 to counting fingers; VA in cilioretinal occlusion ranges from 20/30-20/60; CRAO with cilioretinal sparing has VA 20/30 to hand motion, depending on the amount of the papillomacular bundle supplied by the patent vessel; combined CRAO and CRVO have VA counting fingers to light perception (Rumelt S, Brown GC, 2004). The patients with CRAO without cilioretinal sparing rarely regained any useful vision (Brown & Shields, 1979).

Pain accompanying the visual loss is unusual and usually denotes associated ocular ischemic syndrome (Werner et al. 1994). Rarely, in cases associated with arterial spasm, a relapsing and remitting course of visual loss precedes central retinal artery obstruction. Amaurosis fugax precedes visual loss in about 10% of patients involving transient loss of vision lasting seconds to minutes, but which may last up to 2 hours (Brown, 1999). The vision usually returns to baseline after an episode of amaurosis fugax.

2.4.2 Signs

In CRAO, the first signs are afferent pupillary defect on the affected side and segmental arterial blood flow ("box-carring"), which appear immediately at the occlusion and are

accompanied by the various degree of diminished visual acuity. Later signs are retinal opacification and cherry-red spot and optic disc pallor, attenuation of the retinal arteries, arterio-arteriolar collaterals or neovascular glaucoma (as a complication). Von Graefe was the first one who described typical fundoscopic findings associated with occlusion of the central retinal artery: whitish, edematous retina attributable to infarction, especially at the posterior pole where the nerve fibre layer and ganglion cell layer are the thickest (Beatty & Au Eong, 2000). As these layers are absent in the fovea, the underlying choroidal vascular bed can be seen in this area, thus giving rise to the classic cherry-red spot (Fig. 1.). In the presence of a patent cilioretinal artery, the retinal region served by the unobstructed vessel is not involved (Fig. 2.). Disc pallor and retinal vascular narrowing are characteristic of the late stage of CRAO. The characteristic of BRAO is retinal edema in the distribution of the affected vessel only (Fig. 3.). Obstruction of a cilioretinal artery, or even a macular branch arteriole, gives cloudy, edematous appearance of the macula and affects central vision. In acute stage, the arteries appear thin and attenuated while cherry red spot and ground glass appearance may take hours to develop. In severe blockages, both veins and arteries may manifest “box-carring” or segmentation of the blood flow.

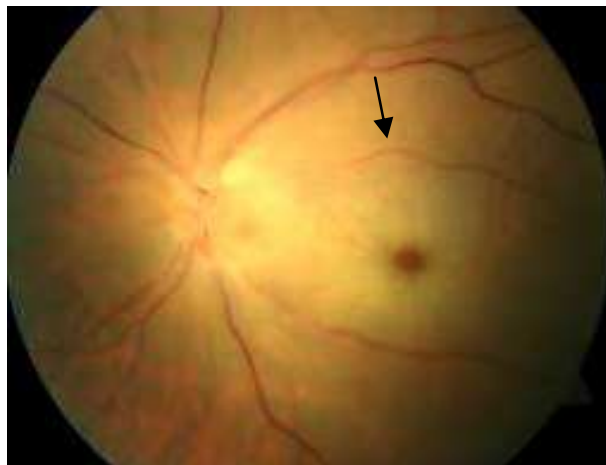


Fig. 1. Central retinal artery occlusion, note foveal cherry red spot and ground glass appearance of the macula (arrow)

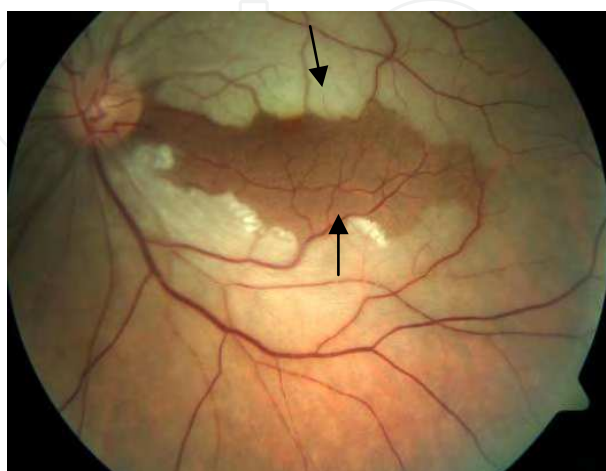


Fig. 2. Cilioretinal sparing central artery occlusion; sparing between the disc and fovea (arrows), representing irrigation area of the cilioretinal artery

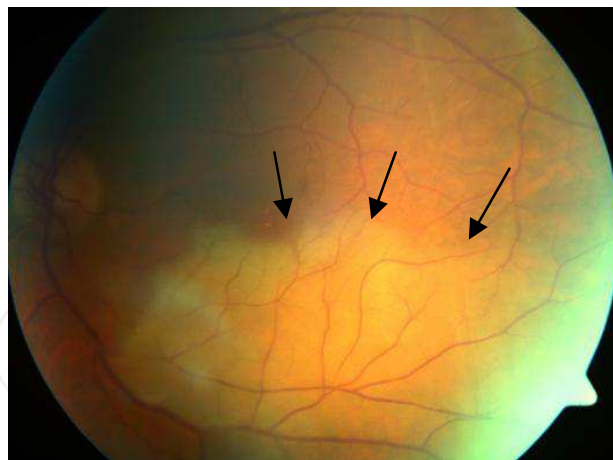


Fig. 3. Branch retinal artery occlusion; note pale, edematous retina in the area of affected vessel (arrows)

Late complication of CRAO is a neovascularization which indicates severe retinal ischemia and is more common at the far periphery and not at the optic disc or the posterior pole, and may complicate with vitreous or preretinal hemorrhage (Duker & Brown, 1989). This is why, in most cases, they are not observed clinically or angiographically with standard angle fundus camera. Only ischemia is usually seen by fluorescein angiography. The typical angiographic finding of neovascularization is the leakage of dye, whereas collateral shunting vessels do not present with such a feature. The fundoscopic findings typically resolve within days to weeks of the acute event, and residual optic atrophy may be the only physical finding. This feature also explains why it is crucial to treat the far periphery of the retina by cryo in addition to treatment by photocoagulation, in cases that the retinal periphery cannot be treated by photocoagulation.

Acute simultaneous obstruction of both the retinal and choroidal circulations is referred to as an ophthalmic artery obstruction. It can be differentiated clinically from central retinal artery obstruction by the following features: severe visual loss – bare or no light perception; intense ischemic retinal whitening that extends beyond the macular area; little to no cherry-red spot; pronounced choroidal perfusion defects on fluorescein angiography; nonrecordable electroretinogram; and late retinal pigment epithelium alterations (Brown et al., 1986). Cases of ophthalmic artery obstruction usually have associated local orbital or systemic diseases: orbital mucormycosis, orbital trauma, retrobulbar anesthesia, depot corticosteroid injection, atrial myxoma, or carotid artery disease (Sullivan et al., 1983). In conjunction with ipsilateral ischemic optic neuropathy, temporal arteritis may produce ophthalmic artery obstruction.

2.5 Evaluation and imaging

To summarize and to choose a rational approach in the workup, it is our opinion that the evaluation should be related to the age group. We recommend the following procedures to be undertaken in the persons over 50 years: the physical examination with complete cardiovascular assessment, ECG, the lab tests including full blood count, erythrocyte sedimentation rate, C reactive protein, fasting blood glucose, lipidogram, urine analysis, Doppler color imaging of the carotid arteries, and transthoracic echocardiography in patients with cardioembolic risk factors.

In the younger patients and those with unidentifiable systemic risk factors these are the proposed investigations: fluorescein angiography, vasculitis screen including anticardiolipin antibodies, antinuclear antibodies, anti-double stranded DNA antibodies, routine coagulation tests (prothrombin time, partial thromboplastin time), specialized clotting factor and platelet activity studies (levels of protein S, protein C, antithrombin III, plasminogen activator, plasminogen activator inhibitor, fibrinogen and resistance to activated protein C) and homocysteine.

Systemic cardiovascular disease
Hypertension, Diabetes mellitus, Atheromatous disease, Cardiac-valvular disease, bacterial endocarditis, myxoma, arrhythmias
Coagulopathies
Antiphospholipid antibodies, Protein C deficiency, Protein S deficiency, Antithrombin III deficiency, Elevation of platelet factor 4, Sickle cell anemia, Homocysteine
Systemic vasculitis
Polyarteritis nodosa, Temporal arteritis, Kawasaki's syndrome, Wegener's granulomatosis, Susac's disease, Systemic lupus erythematosus
Oncologic
Metastatic tumors, Leukemia, Lymphoma
Infective diseases
Syphilis, HIV
Trauma
Direct ocular compression, Penetrating injury, Retrobulbar injection, Orbital trauma, Purtscher's disease
Ocular conditions
Preretinal arterial loops, Optic nerve drusen, Necrotizing herpetic retinitis, Toxoplasmosis
Other causes
Oral contraceptives, Pregnancy, Drug abuse, Migraine

Table 1. Systemic and ocular conditions related to retinal arterial occlusion

It is important to exclude temporal arteritis in older patients, since it follows different clinical course and mandates the prompt administration of systemic corticosteroids. Giant cell arteritis is concerned as approved clinically if two of the three symptoms or signs exist: headache, tenderness over the temple and high sedimentation rate. Biopsy only approves it and treatment should not be deferred for biopsy result. It should be immediately initiated if two or more of the above are present. The purpose of the treatment is to prevent visual loss of the fellow eye, which usually occurs within 10 days of the event in one eye. Apart from the sudden, painless, nonprogressive vision loss in one eye, the patients may have headaches, jaw claudication, scalp tenderness, proximal muscle and joint aches, anorexia, weight loss, or fever.

All patients with acute retinal arterial occlusion must be evaluated for the source of embolism, which is the commonest cause for its development. The imaging techniques are used to confirm the diagnosis in uncertain cases and these are fluorescein angiography, visual field testing, optical coherence tomography and electroretinography.

2.5.1 Fluorescein angiography

Fluorescein angiography is not routinely indicated in the acute phase of arterial occlusive disease. The angiographic findings in both types, CRAO and BRAO (Fig. 4.), include delayed arm-to-retina time which is over 12 seconds (Richard G. et al., 1998), reduced arterial caliber and “cattle-trucking” of the blood column in the branch arteries. Sometimes, it may be minutes before the retinal arterial tree fills with fluorescein. Arteriovenous transit is also delayed, and late staining of the disc is common.

The CLRA dyes concurrently with the filling of the choroid and usually before the start of filling of the CRA (Justice & Lehmann, 1976).

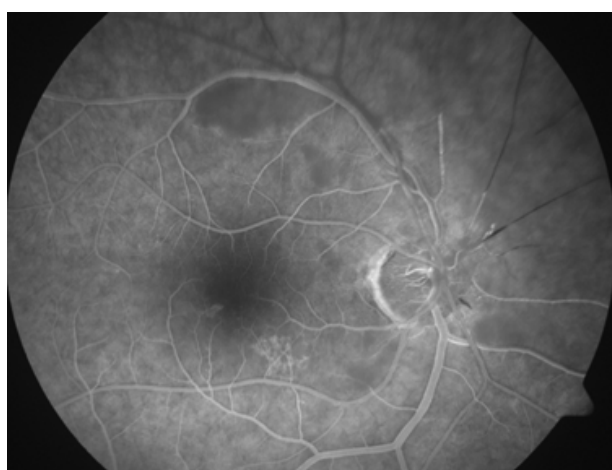


Fig. 4. Superior branch retinal artery occlusion of the right eye. Note the delayed filling of the dye in the superior quadrant of retina

2.5.2 Visual field testing

Visual fields show a remaining temporal island of peripheral vision. In cases of a patent cilioretinal artery, a small intact central island is found as well.

2.5.3 Electroretinography

Electroretinography characteristically shows a decreased to absent b-wave with intact a-wave.

2.5.4 Optical Coherence Tomography (OCT)

Optical coherence findings depend on the duration of the ischemia. Acute stages show increased reflectivity in the inner retinal layers and decreased reflectivity of the photoreceptor layer due to the shadowing effect (Fig. 4.). If involved, the macular region shows cystoid changes with loss of the foveolar contour. Old cases of arterial occlusion are presented with macular thinning with increased reflectivity of the retinal structure denoting ischemia.

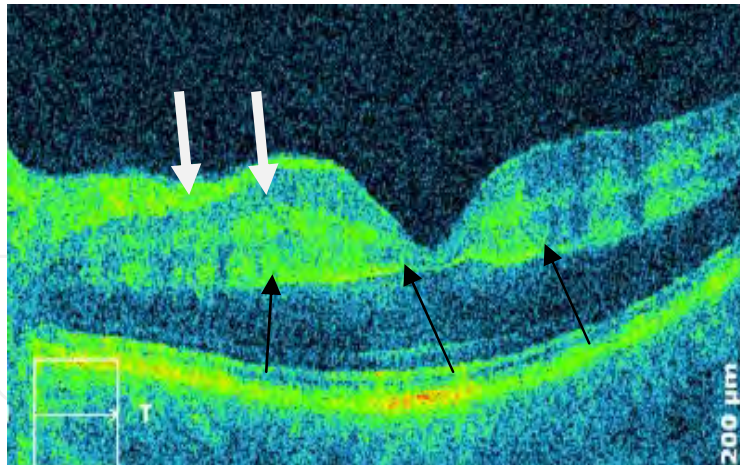


Fig. 5. CRAO – OCT changes, retinal edema in the inner layers (white arrows) denoting ischemia and the shadowing effect in the photoreceptor layer (black arrows)

2.5.5 Color Doppler imaging

Color Doppler imaging is an ultrasonographic evaluation of the blood flow characteristics of the retrobulbar circulation. Color Doppler studies of acute central retinal artery obstruction show diminished to absent blood flow velocity in the central retinal artery, generally with intact flow in the ophthalmic and choroidal branches (Sharma, 1998). Color Doppler imaging can be used to detect calcific emboli at the lamina cribrosa and also may be used to monitor blood flow changes induced by therapy. In addition, carotid artery studies may be carried out concurrently with ocular blood flow determinations to evaluate the possible causes of the central retinal artery obstruction. It is, however, important to determine the presence of plaques in the inspected vessels that are often the source of microemboli responsible for the occlusive event. In doubtful cases, the above-mentioned physical examination and laboratory testing should be carried out, especially in subjects younger than 40 years of age (Table 2).

2.6 Differential diagnosis

Ocular ischemic syndrome

Purtscher's retinopathy

Severe commotio retinae

Inflammatory or infectious retinitis

2.7 Management

Due to the poor prognosis of retinal artery occlusions, several treatment approaches have been attempted. These can be divided into two major categories: (1) conservative treatment, including mechanical (ocular massage and paracentesis), pharmacologic, and other means; and (2) invasive treatment, including catheterization of the proximal ophthalmic artery, usually through the femoral artery with infusion of thrombolytic agents. Any treatment that results in a statistically higher percentage of visual recovery compared with the spontaneous

recovery rate and has a low risk for morbidity and mortality could be considered the treatment of choice (Rumelt & Brown, 2003).

2.7.1 Management of central retinal artery occlusion

Conservative treatment

- First step is arterial vasodilatation using sublingval isosorbide dinitrate, or CO₂ rebreathing in the bag;
- Reduction of intraocular pressure (IOP) and improvement of perfusion by means of antiglaucomatous treatment topically (timolol, etc), systemically (mannitol), or surgically by paracentesis;
 - Ocular massage to move embolus further downstream through artery circulation in distant arterioles. Begin ocular massage with 3-mirror contact lens. Press the lens repeatedly for 10 seconds until the appearance of pulsation; or in the absence of pulsation, until collapse of the retinal blood flow. Observation for improvement of retinal blood flow is made through the lens during the ocular massage. If blood supply improves, ocular massage can be stopped and no further steps are required. If the blood flow does not improve, ocular massage should be continued meticulously for approximately 20 minutes. In addition, treatment prior to 24 hours is more highly to be successful and the success depends on the type of the embolus (calcified are the resistant ones). No light perception is also indication to start treatment. Our experience supports the statement of others that even patients with no light perception may recover (this was also seen in cases of orbital compartment syndrome) (Rumelt et al, 1999);
 - During the ocular massage, administer acetazolamide 500 mg IV;
 - During the ocular massage, administer mannitol 20% 1 mg/kg IV or glycerol 1ml/kg PO;
 - Scleral paracentesis or anterior chamber paracentesis – anesthetize the limbus with q-tip soaked with lidocaine 4%, and perform anterior chamber paracentesis with 25-G needle withdrawing 0.2 ml of aqueous humor;
- Antiplatelet therapy (streptokinase 750 000 I.U. IV, urokinase), heparin therapy, isovolemic haemodilution, which basically make no sense if there is no circulation in the occluded artery and agents cannot reach the embolus (Hayreh, 2011);
- Pentoxifylline injection intravenously to reduce red blood cell rigidity;
- Systemic steroids, in case where CRAO is caused by giant cell arteritis;
- Hyperbaric oxygenation is one of the promising ways of treatment (Weinberger et al., 2002; Bradvica et al., 2009), which can override the time to artery recanalization. However, there is still need for further evaluation because of the lack of greater randomized studies.

Invasive treatment

- Nd:Yag laser arteriotomy and embolectomy (Opremcak et al., 2008), although this rather invasive treatment frequently caused vitreous hemorrhage and need for vitrectomy, so it requires further evaluation;
- Local intraarterial thrombolysis, one of the very enthusiastically announced approaches in CRAO therapy, which is suspended due to a high adverse reactions incidence as

reported by the last European Assessment Group for Lysis in the Eye Study (EAGLE) (Schumacher et al., 2010). Probable reason for the high complication rate was the inexperience of some of the participating physicians. The results and complications were much lower when the procedure was performed by one group (Schmidt et al., 1992; Schumacher et al., 1993).

Since the outcome of invasive treatment depends on the experience of the physician and therefore is not applicable to most centers, the best treatment so far is the conservative multi-step treatment that requires the persistence of the physician (Rumelt et al, 1999).

2.7.2 Management of branch retinal artery occlusion

Management of BRAO depends on the type of occlusion; either it is permanent or transient. In permanent BRAO, like in CRAO there are a lot of advocated treatments but none of them has proven efficient. Transient BRAO does not require any treatment at all except a thorough diagnostics to establish the cause of the occlusion and possibly prevent permanent BRAO from occurring. Nonarteritic cilioretinal artery occlusion (CLRAO) can be treated with any of the procedures described in CRAO treatment. Only arteritic CLRAO associated with giant cell arteritis (GCA) has to be treated with a high dose of steroids, i.e. treat GCA to prevent affecting the other eye and total blindness.

It is important that CRAO and BRAO are both emergencies and any procedures leading to recanalization, or improving the outflow, have to be done urgently inside 97 min from the onset of occlusion (Hayreh et al., 2004), and certainly not after 240 min, because after that time the most part of the retinal tissue function is probably destroyed. It has to be emphasized though that these results are valid for experimental models in primates and for complete occlusion and not for humans that usually have partial obstruction. That is probably the reason why the treatment may be successful even more than 24 hours after the occlusion and the onset of symptoms. Therefore, prevention and education of patients to present immediately to an ophthalmologist or emergency care unit may be the one of the measures of improving the chances of treatment in such patients.

3. Retinal Vein Occlusion

Retinal vein occlusion (RVO) has been recognized as an entity since 1855 (Liebreich, 1855) and is one of the most common causes of acquired retinal vascular abnormality in adults as well as the frequent cause of visual loss. However, the pathogenesis and management of this disorder remains somewhat of an enigma. Current treatments for RVO and its sequelae are still evolving.

CRVO and HCRVO are commonly subdivided into nonischemic and ischemic (hemorrhagic) types according to the degree of obstruction. Ischemic type occurs in more severe (complete) obstruction. Such a distinction is relevant to the clinician, since these two types have very different clinical features, visual outcomes, complications, prognosis and management. Nonischemic RVO is a comparatively benign disease, with central scotoma, essentially due to macular edema, as its major complication, with no risk of ocular neovascularization. Ischemic RVO, by contrast, is a seriously blinding disease, since up to two thirds of patients develop the devastating complications of ischemia, and neovascularization that lead to neovascular glaucoma which causes blindness (Hayreh, 1994).

Retinal vein obstruction is divided into central (CRVO), an occlusion of the central retinal vein resulting in four quadrants of retinal involvement; hemi-central retinal vein occlusion (HCRVO) and branch (BRVO) which consists of major BRVO, an occlusion of either a major branch retinal vein draining one quadrant of the retina, macular BRVO (Hayreh, 1994), an occlusion of a macular branch vein draining a portion of the macula, and peripheral BRVO, an occlusion of a branch retinal vein draining a portion of the retinal periphery. According to the most study data, hemicentral (HCRVO) is an anatomic variant of central retinal vein occlusion (CRVO). Thus, HCRVO acts more like CRVO in terms of risk factors, visual outcome, risk of neovascularization, and response to laser treatment (Appiah & Trempe, 1989). CRVO and BRVO have both differences and similarities in pathophysiology, underlying systemic associations, average age of onset, clinical presentation, prognosis (natural history, complication rate) and treatment.

Furthermore, central and hemi-central occlusion are divided into ischemic and nonischemic subtypes each having different clinical implications and ischemic carrying the risk of developing macular edema and devastating consequences regarding the visual function.

3.1 Epidemiology

The worldwide RVO prevalence, according to the meta-analysis which used pooled data from 15 different international studies involving over than 50,000 participants, ranged from 30 to 101 years, has been calculated per 1000 as follows: 5.20 for any RVO, 4.42 for BRVO, and 0.80 for CRVO. On the basis of these rates, projected to the world population, 16.4 million adults are affected by RVO (Rogers et al., 2010). For comparison, more than 171 million adults with diabetes worldwide either have diabetic retinopathy or are at risk of developing this potentially blinding disease, according to a 2005 World Health Organization report (Wild et al., 2004). An estimated 13.9 million people globally are affected by BRVO and 2.5 million by CRVO. Prevalence varied by race/ethnicity and increased with age, but did not have a sex predilection. The age- and sex-standardized prevalence of any RVO was 3.7 per 1000 in whites, 3.9 per 1000 in blacks, 5.7 per 1000 in Asians, and 6.9 per 1000 in Hispanics. Prevalence of CRVO was lower than BRVO in all ethnic populations. Although BRVO prevalence appears to be highest in Asians and Hispanics and lowest in whites, the authors assume this may reflect differences in the prevalence of RVO risk factors, varying methodologies or definitions among reviewed studies (Rogers et al., 2010). Ischemic central retinal vein obstructions account for 20–25% of all central retinal vein obstructions (Klein et al., 2000).

3.2 Pathophysiology

All types of RVO are multifactorial in origin. A whole host of local and systemic factors acting in different combinations and to different extent may produce the vascular occlusion. The role of the various factors may vary, with some as predisposing factors and other as precipitating ones in one group and vice versa in another. Most investigators accept that BRVO and CRVO represent varying degrees of the same underlying disease process. Yet, other clinicians and researchers argue that ischemic and nonischemic types are distinct clinical entities. It is also essential to understand that CRVO and HCRVO are very different from BRVO pathogenetically. In conclusion, it is a mistake to try to explain all types of RVO by one common pathogenetic mechanism (Hayreh, 1994).

3.2.1 Central Retinal Vein Occlusion

The pathogenesis of CRVO is not fully understood and there are marked controversies on the pathogenesis of ischemic and especially nonischemic CRVO. A combination of vascular, anatomic, and inflammatory factors contributes to its pathophysiology.

The occlusive mechanisms in CRVO are mostly these: (i) external mechanical compression of the vein (i.e. by sclerotic adjacent central retinal artery and common adventitia, especially in elderly persons, structural changes in lamina cribrosa, e.g., glaucomatous cupping, inflammatory swelling in optic nerve and orbital disorders) followed by secondary endothelial proliferation; (ii) primary venous wall disease (degenerative or inflammatory); and (iii) hemodynamic disturbances produced by a variety of factors (e.g., hyperdynamic or sluggish circulation, blood dyscrasias, disturbances on the arterial side, etc.). Consequently, a stagnation of the vein flow occurs and a thrombus formation ensues (Hayreh, 1994; Williamson, 1997).

There are multiple anatomic variations of the branching pattern to the central retinal vein. In 20% of eyes there are, as a congenital abnormality, two trunks of the central retinal vein (CRV) in the optic nerve (instead of the usual one), and the merging of the trunks occurs posterior to the lamina cribrosa (Chopdar, 1984; S. S. Hayreh & M. S. Hayreh, 1980). If one of these trunks is occluded, the result is a nonperfusion to superior or inferior retina. Additionally, the venous outflow from the nasal retina may occur via a branch of one of the temporal branches, rather than an independent nasal vein. In an eye with such a branching pattern, an inferior or superior HCRVO may occur if one the venous branches that drain the nasal and temporal retina is occluded (Sanborn & Magargal, 1984). So, considering the various possible scenarios that can result in a HCRVO, a consensus as to whether HCRVO is a variant of BRVO or CRVO still has not been reached.

CRVO is significantly more common in patients with raised intraocular pressure (IOP) and glaucoma (up to 5- to 10-fold increased risk) (Risk factors for central retinal vein occlusion. The Eye Disease Case-Control Study Group, 1996). To maintain the blood flow, the pressure in the CRV at the optic disc has to be higher than the IOP, otherwise a retinal venous stasis and sluggish venous outflow occur (Hayreh, 2005).

There is much more congruence of the data on the pathogenesis of the ischemic CRVO. Most probably ischemic CRVO represents a more extensive (or complete) obstruction while non-ischemic CRVO represents a milder (partial) obstruction. A conception suggests that the vessels are in a tight compartment within limited space for displacement, because of a common adventitial sheath as CRA and CRV exit the optic nerve head and pass through a narrow opening in the lamina cribrosa. This anatomical position *per se* predisposes to thrombus formation in the central retinal vein. But, CRV has multiple tributaries during its course in the optic nerve, pial outside the optic nerve, none in the lamina cribrosa, and only a small one in the prelaminar region. These tributaries establish anastomoses with the surrounding veins. Since the severity of retinal venous stasis depends upon the site of occlusion in the CRV, and the number of available tributaries anterior to it, the site of the occlusion is likely to be much posteriorly to the lamina cribrosa in nonischemic CRVO than in ischemic CRVO (Hayreh, 2005). There is a possibility of changing nonischemic CRVO to ischemic in some patients, probably due to a further precipitous gradual or sudden fall of perfusion pressure (Hayreh, 1994).

Occlusion of the central retinal vein leads to the retention of the blood in the retinal venous system, and increased resistance to venous blood flow subsequently causes a stagnation of the blood and ischemic damage to the retina. It has been postulated that ischemic damage to the retina stimulates increased production of vascular endothelial growth factor (VEGF) in the vitreous cavity. Increased levels of VEGF stimulate neovascularization of the posterior and anterior segment (responsible for secondary complications due to CRVO). Also, it has been shown that VEGF causes capillary leakage leading to macular edema (which is the leading cause of visual loss in both ischemic CRVO and nonischemic CRVO) (Boyd et al., 2002; Noma et al., 2008; Pe'er et al., 1998).

The prognosis of CRVO depends upon the reestablishment of patency of the venous system by recanalization, dissolution of clot, or formation of optociliary shunt vessels.

3.2.2 Combined Retinal Vein and Artery Occlusion

A central retinal artery obstruction combined with central retinal vein obstruction can occur rarely (Richards, 1979), and the mechanism is probably increased pressure on both central retinal artery and vein. The most common cause for combined CRAO and CRVO is retrobulbar anesthetic injection, caused probably by inadvertent injection into the optic nerve sheath (Torres, 2005). If no CRV tributaries are available anterior to the site of occlusion in the CRVO, it converts the circulation into a closed loop and this results in complete hemodynamic block of the retinal circulation, and secondary CRAO. This condition is invariably diagnosed as simultaneous occlusion of CRA and CRV (Hayreh, 2005). Nonischemic CRVO associated with cilioretinal artery occlusion (CLRAO) is usually a result of transient rise i.e. a functional obstruction of the blood pressure in the entire retinal capillary bed due to a sudden blockage of blood flow by a thrombus in the CRV, which, in turn, results in a physiologic block in the CLRA circulation (Theoulakis et al., 2010). Within a day or two, with the development of venous collaterals by the CRV, the blood pressure in the retinal vascular bed falls, and normal cilioretinal filling occurs. However, the severity of retinal ischemia and associated visual loss depends upon the length of time elapsed before the circulation was re-established (Hayreh, 1994).

3.2.3 Branch Retinal Vein Occlusion

Branch retinal vein occlusion is defined as a focal occlusion of a retinal vein at an arterio-venous crossing site. In all but a few rare cases, the BRVO occurs at crossing sites where the artery is passing anteriorly (superficially) to the vein (Duker & Brown, 1989; Weinberg et al., 1990). The upper temporal vascular arcade is more often involved than the lower temporal vascular arcade. Most BRVOs involve the area inside the temporal vascular arcades (macular BRVO), whereas peripheral BRVOs are more rarely seen, partly because they tend to be asymptomatic (Christoffersen & Larsen, 1999).

The arterio-venous crossing plays an important role in the pathogenesis of BRVO, and the anterior position of the arteriole at the crossing somehow renders the underlying vein vulnerable to occlusion. It seems logical to assume that sclerotic retinal arteriole probably compresses the accompanying vein because of a common thickened, adventitial and glial sheath; however, histopathological studies failed to confirm this view. In addition, turbulent flow may injure the vessel wall exposing it for thrombus formation (Hayreh, 1994; Williamson, 1997).

3.3 Causes

Retinal vascular occlusions all have overlapping clinical presentation as well as the similar underlying causes. They are all multifactorial in origin and each patient may have a unique combination of systemic and local factors leading to the occlusive event (Hayreh, 1994). Since the systemic vascular disease is a possible underlying pathophysiological cause, it is important to ask about history of hypertension, diabetes mellitus, any condition predisposing embolic events (endocarditis, atrial fibrillation, atherosclerotic disease, drug and alcohol abuse, hypercoagulable states) (Klein et al., 2003; Schmidt et al., 2007). Also, the questions regarding possible trauma as well as the undertaken surgical procedures should not be omitted from the medical history since the prolonged pressure to the globe may lead to the ischemic event.

The well-known risk factors contributing to retinal vein occlusions are systemic vascular diseases. The most recognized risk factors for retinal vein occlusion are hypertension, diabetes mellitus, arteriosclerosis and hyperlipidemia. Also, cigarette smoking has been related to increased risk of RVO. They predominately affect the older age group of patients but the younger patients may also develop this type of retinal occlusive disorder and they account for 10-15% of patients with RVO. Mild central retinal vein obstructions in patients younger than 50 years have been referred to as papillophlebitis or optic disc vasculitis. An inflammatory optic neuritis or vasculitis is hypothesized as the cause (Fong, 1992).

According to the recent studies by Hayreh et al. there may be some difference in the risk factors between CRVO and BRVO, with higher prevalence of hypertension, venous disease, peripheral vascular disease and peptic ulcer in the latter (Hayreh et al., 2001). This suggests that it may not be correct to generalize about these underlying causes for the entire group of retinal vein occlusions.

In addition to well-recognized risk factors, new thrombophilic factors have been investigated in these patients. The role of thrombophilic risk factors in RVO is controversial and the studies are showing conflicting results. Hyperhomocysteinemia as well as low levels of vitamin B₆ and folic acid have been identified as independent risk factors (Sofi et al., 2008; Taubert, 2008). Other potential risk factors include elevated factor V Leiden, protein C or S deficiency, anti-cardiolipin antibodies or lupus anticoagulant. Blood dyscrasias and dysproteinemias result in hyperviscosity syndromes, which may appear similar to central retinal vein obstruction but possibly represent curable disease. Hyperviscosity syndromes may produce a bilateral retinopathy similar to central retinal vein obstruction and may, in fact, induce a true central retinal vein obstruction with thrombus formation (Bandello et al., 1994). Simultaneous bilateral disease is an unusual finding in central retinal vein obstructions but occurs more commonly in hypercoagulable and hyperviscous states. Diseases such as sickle cell disease, polycythemia vera, leukemia, and multiple myeloma are but a few of the possibilities. When there is a patient with bilateral central retinal vein obstructions, especially simultaneous, the medical and laboratory evaluation should include a search for evidence of hyperviscous and hypercoagulable syndromes (Marcucci et al., 2001). Severe anemia with thrombocytopenia can masquerade as a central retinal vein obstruction, and it is differentiated from a central retinal vein obstruction by a complete blood count with platelets.

In combined central retinal vein occlusion with branch retinal artery occlusion systemic associations other than hypertension and diabetes have not been confirmed. In combination

with central retinal artery occlusion associated systemic or local disease is the rule – collagen vascular disorders, leukemia, orbital trauma, retrobulbar injections, and mucormycosis have been implicated (Jorizzo, 1987).

Oral contraceptive use in women may be associated with both thromboembolic disease and central retinal vein obstruction (Stowe et al., 1978). In addition, acute hypertensive retinopathy with disc edema may resemble bilateral central retinal vein obstruction. Obstructive sleep apnea affects more patients with retinal vein obstruction than other disorders and treatment of the sleep apnea may help prevent central vein obstruction (Glacet-Bernard et al., 2010). Other rare associations include closed-head trauma, optic disc drusen, and arteriovenous malformations of retina.

The Eye Disease Case-Control Study Group reported that the risk of CRVO is decreased in men with increased levels of physical activity and increased alcohol consumption (Risk factors for central retinal vein occlusion. The Eye Disease Case-Control Study Group, 1996). The same study group reported a decreased risk of CRVO with the use of postmenopausal estrogens and an increased risk with higher erythrocyte sedimentation rates in women.

An ocular risk factor for the development of central retinal vein occlusion is raised intraocular pressure; the risk of central retinal vein occlusion in glaucoma patients is 5-fold to 10-fold increase (Risk factors for central retinal vein occlusion. The Eye Disease Case-Control Study Group, 1996). Unlike CRVO and HCRVO, glaucoma plays no role in the pathogenesis of BRVO (Hayreh, 1994).

In ischemic CRVO, for example, neovascular glaucoma develops in about 45%. The chronic hypoxia of the retinal tissue induces ocular neovascularization by producing the vasoproliferative factor, which is the proposed mechanism in CRVO whereas in CRAO, there is acute retinal ischemia and infarction responsible for the occlusive event. Also a surprisingly small proportion of patients (2.5%) have the course of illness complicated with neovascular glaucoma (Hayreh, 2011).

3.4 Clinical presentation

3.4.1 Symptoms

Retinal vein occlusion is characterized by painless unilateral loss of vision. It may be subtle in character, with intermittent episodes of blurred vision. In other cases, it may be sudden and dramatic. The nonischemic type is often the more subtle of the two, while the ischemic type is prone to the more acute clinical presentations and may be accompanied by pain.

Ischemic CRVO Acute, markedly decreased visual acuity ranged from 20/200 (6/60) to hand-motion is the usual initial complaint. A prominent afferent pupillary defect is typical. Pain at the time of evaluation may occur if neovascular glaucoma already had developed.

Nonischemic CRVO The majority of patients with central retinal vein obstruction (75–80%) fall into nonischemic form. Patients usually have mild to moderate decreased visual acuity, although this can vary from normal to as poor as the finger counting. Transient visual obscuration may also be a complaint.

Branch retinal vein occlusion is characterized by painless decrease in vision on the affected eye and some patients may have a scotoma.

Combined Retinal Vein and Artery Occlusion Such patients present with acute, severe loss of vision, usually to bare or no light perception. The visual prognosis is generally poor.

3.4.2 Signs

The distinction between the ischemic and nonischemic type is important, because they carry a totally different prognosis regarding visual recovery and potential complication, which may result in permanent visual deterioration.

Both types of central retinal vein obstruction, ischemic and nonischemic, have similar fundoscopic findings—dilated, tortuous retinal veins and retinal hemorrhages in all four quadrants, optic disc swelling, cotton wool spots and macular edema (Fig. 5). Hemorrhages can be superficial, dot and blot, and/or deep. They may vary in severity, covering the whole fundus and sometimes even obscuring retinal and choroidal details, or can be limited to the peripheral fundus only. Vitreous hemorrhage may ensue when bleeding breaks through the internal limiting membrane. The optic disc is usually edematous during the early-stage disease, but the edema may persist in chronic cases (Ehlers & Fekrat, 2011). Many or all of the pathological retinal findings may resolve over the 6–12 months following diagnosis. The resolution of retinal hemorrhages may be complete whereas the optic nerve may appear normal, but optociliary collateral vessels are common finding. In spite the resolution of macular edema, a persistent cystoid macular edema can linger and result in permanent visual loss, often leading to pigmentary changes, epiretinal membrane formation, or subretinal fibrosis.

Ischemic CRVO The presence of cotton-wool spots located around the posterior pole is characteristic of and more common with ischemic CRVO (Fig. 6.). In ischemic CRVO, the ganglion cells in the macular retina are irreversibly damaged by ischemia during the initial stages of the disease; therefore, there is little chance of improvement of visual acuity in such an eye. The distinction between the two types of vein obstructions remains somewhat arbitrary and is based on the total area of nonperfusion on fluorescein angiography. However, dense intraretinal hemorrhage in acute stages may block retinal fluorescence and renders it impossible to determine the extent of retinal nonperfusion. Therefore, it is important to take into account other clinical features such as poor initial visual acuity, the presence of an afferent pupillary defect, neovascularization as well as the functional tests – visual field testing (Goldmann) and electroretinography (ERG) to establish the perfusion status of the retina (Hayreh et al., 2011). In central retinal vein obstruction, perfusion of the inner retina is affected, so that the amplitude of the b-wave is decreased relative to the a-wave; the b-to-a ratio has been shown to be reduced. Some studies indicate that a b-to-a ratio of less than 1 suggests an ischemic central retinal vein obstruction (Matsui et al., 1994). It is only the ischemic CRVO eye which is at risk of developing ocular neovascularization (Hayreh et al., 1983; Natural history and clinical management of central retinal vein occlusion. The Central Vein Occlusion Study Group, 1997). The incidence of anterior segment neovascularization in ischemic central retinal vein obstruction is 60% or higher and has been documented as early as 9 weeks after onset of an occlusive event. The greatest risk of developing anterior segment neovascularization is during the first 7 months, after which the risk of dreaded complication of neovascular glaucoma falls dramatically to minimal. Neovascularization of the optic disc and retinal neovascularization may be seen as well, but they are less common. As with nonischemic central retinal vein obstruction, the findings may decrease or resolve 6–12 months after diagnosis. The anterior segment structures may

show signs of ischemia: congestion of the conjunctival and ciliary vessels, corneal edema, iris and anterior chamber angle neovascularization with development of synechial changes predisposing the development of secondary glaucoma.

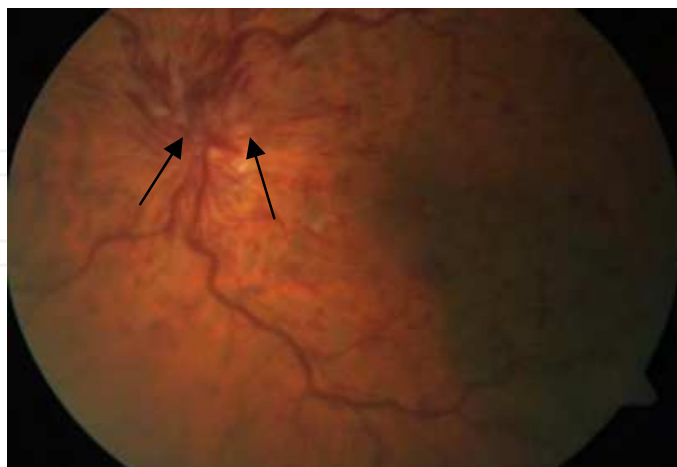

Fig. 6. Central retinal vein occlusion; dilated, tortuous retinal veins and retinal hemorrhages in all four quadrants, optic disc swelling (arrows), cotton wool spots and macular edema

Nonischemic CRVO Neovascularization of either the anterior or posterior segment is rare in a true nonischemic central retinal vein obstruction (less than 2% incidence), although conversion from an initially nonischemic vein obstruction to the ischemic variety is fairly common. The Central Vein Occlusion Study Group noted that 34% of nonischemic central retinal vein occlusions (CRVOs) progressed to become ischemic within 3 years and 15% of the study group converted within the first 4 months (Natural history and clinical management of central retinal vein occlusion. The Central Vein Occlusion Study Group, 1997).

Hemicentral RVO In hemicentral retinal vein obstruction venous outflow from the superior or inferior parts of retina is impaired. Although they involve half of the retina, in terms of visual outcome, the risk of neovascularization, and response to the laser treatment, they resemble the ischemic variant of the disease.

Branch retinal vein occlusion (Fig. 7.) Intraretinal hemorrhages (usually flame shaped), retinal edema, and cotton-wool spots are seen in the distribution of a retinal vessel.

Papillophlebitis The characteristic finding is optic disc edema out of proportion to the retinal findings, cotton-wool spots that ring the optic disc, and occasionally cilioretinal artery obstructions or even partial central retinal artery obstructions. Although spontaneous improvement occurs, the course is not always benign. Approximately 30% of these patients may develop the ischemic type of occlusion, a final visual acuity of 20/200 in nearly 40% of these subjects, and neovascular glaucoma has been reported (Fong, 1992).

Combined Retinal Vein and Artery Occlusion Examination shows a cherry-red spot combined with features of a central retinal vein obstruction, which include dilated, tortuous veins that have retinal hemorrhages in all four quadrants (Fig. 8.). The risk of neovascularization of the iris is about 75%. Exceptionally, a patient may manifest spontaneous improvement (Jorizzo, 1987). Branch retinal artery obstruction combined with simultaneous central retinal vein obstruction has also been reported. This rare entity behaves as a central retinal vein obstruction. Neovascularization of the iris is possible.

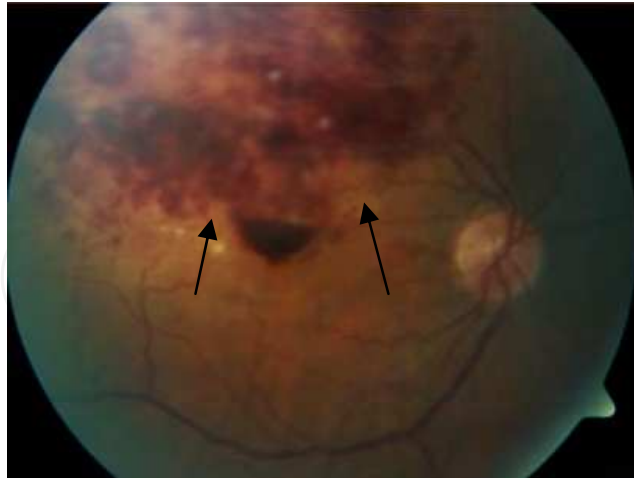


Fig. 7. Branch retinal vein occlusion; note hemorrhages and edema in superior temporal quadrant (arrows)

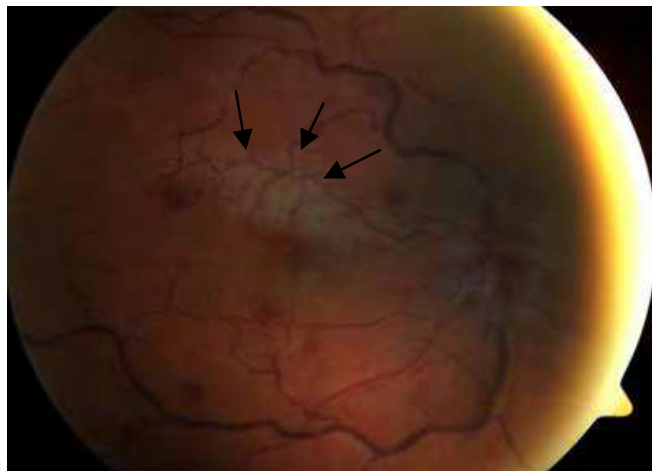


Fig. 8. Combined branch retinal artery occlusion (BRAO) and central retinal vein occlusion (CRVO) of the right eye, ischemia involving superior macular branches (arrows), optic disc swelling, tortuous veins and dot and blot hemorrhages

3.5 Evaluation and imaging

3.5.1 Systemic evaluation

Given the heterogeneity of risk factors and their possible interaction in these subjects, the following algorithm of patients with RVO is proposed in the Table 2. As for the arterial occlusive retinal disease, these tests should be performed in younger patients and in doubtful cases.

We feel that, as with the arterial occlusive disease, the stepwise approach to each patient should be tailored, taking into account the age of the patient. Therefore the investigations in the patients older than 50 years of age should consist of: cardiovascular risk assessment, ECG, carotid and vertebral artery Doppler color imaging, echocardiogram; the lab tests including full blood count, erythrocyte sedimentation rate, C reactive protein, fasting blood glucose, lipidogram. The younger patients should be evaluated for thrombophilia, hyperviscosity syndromes, screening for autoimmune diseases and women should be asked about the use of oral contraceptives. Of course, other possible causes of retinal vein occlusions should be considered in cases of normal findings and the investigations should be expanded in stepwise approach, since each case may have a unique combination of risk factors and underlying causes.

<div><div>Cardiovascular risk factors assessment (diabetes, hypertension, smoking habitus, dyslipidemia, BMI)</div><div>ECG</div><div>Carotid and vertebral artery Doppler color imaging</div><div>Echocardiogram (transthoracic, transesophageal in selected cases)</div><div>Lab tests (complete blood count, fasting glucose, lipidogram, autoimmune screen in selected cases: ANA, anti ENA, anti DNA; homocysteine level, folic acid, vitamin B12 and B6, antiphospholipid antibodies)</div><div>Thrombophilia assessment in subjects younger than 50 years (factor V Leiden, antithrombin, protein C, protein S)</div></div>

Table 2. Proposed systemic work-up in RVO patients

Although most cases are diagnosed straightforward from the fundus appearance, the following ancillary tests may be undertaken to distinguish between ischemic or milder, nonischemic form, which is very important in terms of the treatment options as well as the natural course and visual prognosis of the patients.

3.5.2 Fluorescein angiography

Arteriolar filling is usually normal, but venous filling in the affected vessel is usually delayed in the acute phase. Hypofluorescence caused by hemorrhage and capillary nonperfusion are common findings, and dilated, tortuous veins are seen (Fig. 9a.). The retinal vessels, particularly the vein walls, may stain with fluorescein, especially at the site of the occlusion (Fig.10.). The very important distinction should be made between neovascular fronds, which may show profuse leakage of dye, vs. collateral vessels, which do not leak fluorescein. Cystoid macular edema (Fig. 9b.) appears in the late stage of the angoigram shows typically petaloid pattern and may involve the entire fovea or just several clock hours, depending on the distribution of the obstruction. It is, however, important to emphasize that in early stages the retinal angiograms may be misleading because of the masking by abundant hemorrhages and the fact that retinal capillary obliteration is a progressive phenomenon which takes at least 3-4 weeks or even longer to develop after the occurrence of ischemic CRVO (Hayreh, 1994).

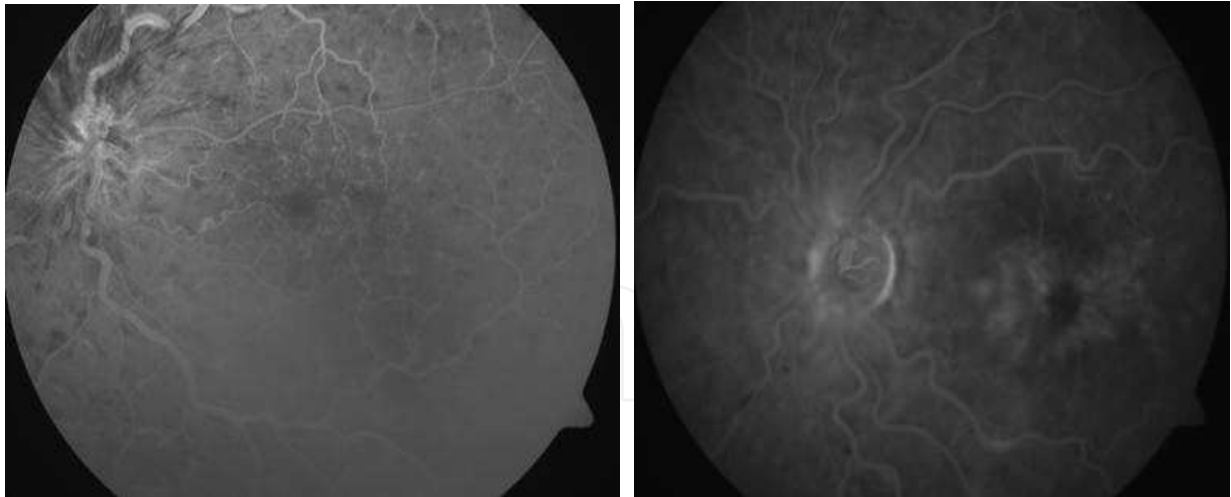


Fig. 9. Fluorescein angiogram of the left eye with central retinal vein occlusion a and b. a) staining of blood vessel walls, disc hyperfluorescence and blockage from intraretinal hemorrhage b) the late stages of angiogram shows leakage of dye in cystoid macular edema, with characteristic “petaloid” appearance.

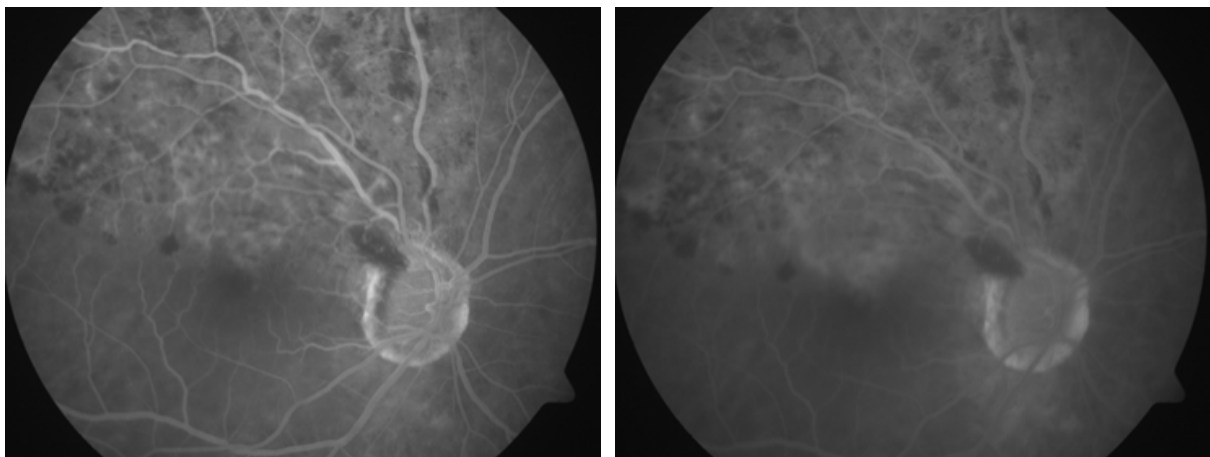


Fig. 10. Fluorescein angiogram of the right eye with superior branch retinal vein occlusion a and b. a) blockage of dye with hemorrhages, mottled areas of intraretinal leakage and microaneurysm formation with vascular teleangiectasia in the upper parts b) the late stages of angiogram shows further diffuse leakage of dye, through all layers of the retina, affecting the macular region as well.

3.5.3 Optical coherence tomography

The optical coherence tomograms show increase in the retinal thickness, which is seen as a loss of macular contour. In the area of edematous retina the presence of cystoids spaces denotes the existence of cystoid macular edema (Fig. 11.). The retinal hemorrhages, subretinal fluid accumulation, cotton wool spots and optic disc edema may also be visualized on OCT. OCT is useful in the management and treatment of the macular edema; it also offers certain advantages over angiograms because it quantifies the macular thickness useful in monitoring the response to treatment and gives valuable data on distribution of the fluid, is not invasive and has no potentially serious side effects. There have been some

disputes whether the macular thickness correlates significantly with visual acuity (Nussenblatt et al., 1987). What counts is the improvement in visual functions and not the anatomy. Several factors were predictive of better visual acuity outcomes and more favorable OCT outcomes, including younger age and shorter duration of macular edema, respectively. These factors may assist clinicians in predicting disease course for patients with CRVO and BRVO (Scott et al., 2011). Loss of foveal IS/OS junction line and absence of inner retinal layers in late stage significantly correlated with poorer visual outcome. Macular ischemia by fluorescein angiography shows significant correlation with thinner central subfield thickness, loss of inner retinal layers (Lima, 2011).

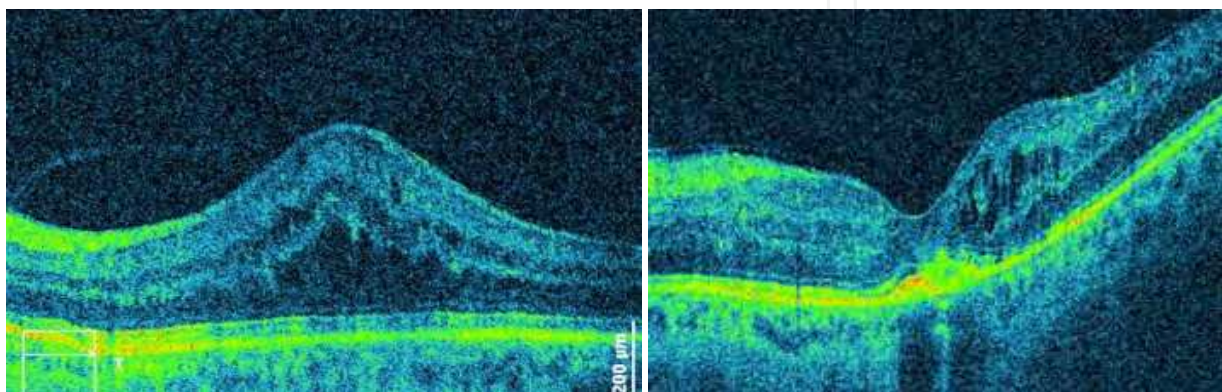


Fig. 11 a and b. Optical coherence tomography (OCT) changes of eye with central retinal vein occlusion a) Cystoid macular edema prior to anti-VEGF injection; b) Cystoid macular edema after anti-VEGF injection treatment Cross-section goes through inferior retina to superior retina, capturing the abnormally thickened retina associated with intracellular edema.

3.6 Differential diagnosis

Hypertensive retinopathy

Diabetic retinopathy

Ocular ischemic syndrome

Juxtafoveal retinal telangiectasia

Radiation retinopathy

Retinal artery occlusion

Retinal detachment

Vitreous hemorrhage

3.7 Management

Some treatments have addressed the venous outflow and the majority the sequelae of the venous occlusion (i.e. cystoid macular edema, neovascularization). In the following text the advocated treatment options are discussed.

3.7.1 Management of branch retinal vein occlusion

Etiology treatment

- Isovolemic hemodilution, used to lower plasma viscosity and to improve retinal perfusion. However, the true benefit of hemodilution has not been established because the published reports have used a combination therapy in the hemodilution groups ;
- Laser chorioretinal venous anastomosis, performed to bypass the occluded site by inducing a communication between the involved branch vein and the choroidal circulation by placing a laser burn directly on the vein and then on the adjacent Bruch's membrane. During the healing process, a chorioretinal anastomosis may form. The technique is studied on CRVO patient, but the small number of BRVO case series were reported (Bavbek et al., 2005; Fekrat et al., 1998);
- Pars plana vitrectomy and arteriovenous sheathotomy. Arteriovenous sheathotomy, in which the retinal vein and artery are surgically separated at the arteriovenous crossing by cutting the common adventitial sheath bare the same idea of improving perfusion. Several small, uncontrolled series have shown good results in improving macular edema and macular perfusion. However, others have reported a lack of efficacy of this procedure (Le Rouic et al., 2001; Cahill et al., 2003).

Sequelae treatment

- Grid laser photocoagulation. The Branch Vein Occlusion Study (BVOS) demonstrated the efficacy of grid laser photocoagulation in the treatment of BRVO-related macular edema. According to the study, grid photocoagulation performed in the first 12 months of onset of the occlusion can, compared to the natural course, improved the response almost twice (Argon laser photocoagulation for macular edema in branch vein occlusion. The Branch Vein Occlusion Study Group, 1984) Argon laser grid or sector treatment result in resolution of the edema but do not improve visual acuity;
- Sector Scatter Retinal Laser Photocoagulation. This treatment was also evaluated during the BVOS study in the ability of preventing the development of neovascularization and vitreous hemorrhage in the BRVO. It is recommended that scatter photocoagulation should be used in BRVO, if and when neovascularization occurs (Argon laser scatter photocoagulation for prevention of neovascularization and vitreous hemorrhage in branch vein occlusion. A randomized clinical trial. Branch Vein Occlusion Study Group, 1986);
- Intravitreal corticosteroids, using a long lasting corticosteroid such as triamcinolone (IVTA), or biodegradable carrier containing dexamethasone to manage macular edema. SCORE study was conducted to compare IVTA versus standard of care, i.e. grid-pattern macular photocoagulation (Scott et al., 2009). The results of this study suggest that both procedures have a similar effect on resolving macular edema and improving visual acuity, but IVTA has more side effects (increasing IOP, cataract progression). In a randomized pilot study of subjects with cystoid macular edema (CME) secondary to BRVO, the increase in visual acuity was significantly greater in those treated with combination of IVTA and grid-pattern laser photocoagulation than in the eyes treated with grid-pattern laser alone, suggesting that IVTA can be effective as an adjunctive treatment to laser (Parodi et al., 2008). Allergan conducted an international study at 167 centers in 24 countries on the effect of intravitreal dexamethasone sustained release delivery system (Ozurdex). The data for the first 6 months was released (Haller et al., 2010). It appears that visual acuity was significantly better in the group of patients who received 0.7 mg dexamethasone implant than in the control group after 60 and 90 days, but is similar 180 days after the treatment. Ozurdex received FDA approval for treatment of macular edema

secondary to BRVO in 2009. An implantable fluocinolone acetonide (Retisert, Bausch and Lomb, Rochester, NY), at present being registered for the intravitreal treatment of chronic non-infectious uveitis, is also being evaluated for the treatment of BRVO and CRVO. The beneficial effect of intravitreal corticosteroids is limited in time and repeated treatment is associated with the accumulation of the complications including steroid-induced glaucoma, cataract, endophthalmitis and retinal detachment. IOP sparing corticosteroids may only prevent glaucoma but not the other side-effects;

- Intravitreal Anti-Vascular Endothelial Growth Factor. It was noticed that VEGF plays a substantial role in the development of CME and neovascular complication in RVO patients. The first intravitreally used drug was bevacizumab, originally developed for the intravenous treatment of colorectal carcinoma metastases, but widely used for treating RVO complications and other retinal disorders (e.g. diabetic macular edema, age related macular degeneration). Several studies have reported a decrease in retinal thickness and improved visual acuity after receiving bevacizumab (Kreutzer et al., 2008; Kriechbaum et al., 2008; Pai et al., 2007). Visual acuity usually increased to maximum in 3-6 weeks after the injections (Stahl et al., 2007). A subsequent decrease in visual acuity appeared to be closely related to an increase in CME. Early recurrence of CME should prompt consideration for retreatment. The most appropriate timing interval between injections is still unclear. The other anti-VEGF agents on the market are pegaptanib, the first FDA approved intravitreal agent (for the treatment of neovascular age-related macular degeneration - ARMD) and ranibizumab, the first FDA approved agent for the treatment of not only ARMD but also macular edema caused by BRVO, based on the results of BRAVO study. Results of phase III BRAVO study show us that after six monthly intravitreal injections of ranibizumab 55% (0.3mg group), and 61% (0.5mg group) gain more than 15 letters, compared to 28.8% in the control group. Also a central foveal thickness decreased by 158 microns in the control group versus 337 microns in the 0.3 mg group and by 345 microns in the 0.5 mg group. Adverse events are rare - one retinal detachment in the 0.3 mg group, one endophthalmitis and one myocardial infarction in 0.5 mg group, and one stroke in the control group. According to our experience as well as numerous other authorities it is doubtful that myocardial infarction and stroke are caused by the local treatment with anti-VEGF, since they are most prominent in the older population which is prone to these conditions (Rosenfeld, 2006). After six months the control group received intravitreal ranibizumab on as needed basis; i.e. if macular edema occurs. Therefore, the long-term results remain unknown. We can say that, according to this data, the use of anti-VEGF agents become an important option in macular edema treatment secondary to BRVO;
- Pars plana vitrectomy with removal of the posterior hyaloid is effective in resolving CME (only if the traction is the cause of retinal edema and usually if the duration of the edema is less than 6 months) and improving visual acuity (Figueroa et al., 2004). Due to complications associated with these procedures, such as vitreous hemorrhage, intraoperative retinal tears, rhegmatogenous retinal detachment and cataract development, they are not often in use.

3.7.2 Management of central retinal vein occlusion

Etiology treatment

- Isovolemic hemodilution. Several studies have suggested the presence of abnormal blood viscosity in CRVO patients. Based on that assumption, some authors have

advocated the use of hemodilution in CRVO, but other (Hayreh, 2003) claim that there is little scientifically valid evidence of beneficial effects of this therapy;

- Anticoagulant and antiplatelet therapy. Although no clear ocular benefit of antithrombotic drugs has been demonstrated, antiplatelet drugs (e.g. aspirin) are prescribed for many patients, including CRVO patients. Hayreh (Hayreh, 2002) claims that this therapy as well as the anticoagulant therapy, such as recombinant tissue plasminogen activator (rt-PA), is contraindicated and even harmful for CRVO patients. Some authors have tried local application of rt-PA into retinal branch vein but the results are controversial and complication rate (haemophthalmus, neovascular glaucoma, retinal detachment, eye phthisis) is unacceptably high; rt-PA should penetrate the retina to exert its activity
- Chorioretinal venous anastomosis. The techniques explained earlier may create an anastomosis, but also carry significant risks. Given the variable success rate, these techniques are rarely employed;
- Surgical decompression of the retinal vein. Proposed procedures can be divided into two mayor types; the first is the vitrectomy with radial optic neurotomy, in which a surgeon's approach is from inside the globe, and the second is optic nerve sheet decompression using orbital "outer" approach. Because of the danger and invasiveness of the procedures and the lack of scientific explanation (Hayreh et al., 2002), there is a need for a larger study to eventually find a place for these procedures in the management of CRVO.

Treatment directed at sequelae

- When speaking of sequelae treatment, we have to add an antiglaucomatous treatment as needed if increase of IOP occurs. Local medical therapy such as, β -blocker (timolol 0,5%), α -2 agonists (brimonidine 0'1-0,2%), carbonic anhydrase inhibitor (acetazolamide, dorzolamide) and panretinal photocoagulation. If failed, the other method of treatment has to be applied such as (i) trabeculectomy with antimetabolites as a first step when there is potential to improve state, (ii) aqueous shunt implants as a second step, and (iii) diode laser cyclophotocoagulation or retinal cryoablation, and in the worst case, with no vision and the patient suffering from great pain, (iv) evisceration or enucleation should be considered (Sivak-Callcott et al., 2001);
- Grid-pattern laser photocoagulation. According to CVOS study, these procedures have no beneficial effect on the visual outcome in macular edema due to CRVO, either ischemic or non-ischemic;
- Scatter panretinal laser photocoagulation. It has been almost universally accepted that prophylactic panretinal photocoagulation (PRP) is the treatment of choice to prevent neovascular glaucoma or treat neovascular glaucoma itself in ischemic CRVO. CVOS study revealed that there is no benefit of the prophylactic PRP in the eyes with ischemic CRVO. These results have led to the recommendation that PRP should be applied promptly after the identification of intraocular neovascularization in eyes with ischemic CRVO to minimize the risk of the development of neovascular glaucoma;
- Corticosteroids. Steroids reduce vascular permeability and stabilize the blood-retina barrier. The mechanism for these effects involves inhibition of the production of inflammatory mediators and vascular permeability factors (e.g. VEGF) as well as the stabilization of the vascular endothelial cell tight junctions. The inhibition of VEGF production may further help prevent neovascular sequelae. Some authors have proposed for some patients the systemic use of corticosteroids (Hayreh, 2010) in high

oral doses of about 80 mg of prednisone to control macular edema, which is the main cause of visual loss. Most of the patients with CRVO according to the SCORE study respond to intravitreal triamcinolone application of either 1 or 4 mg doses compared to the standard care in terms of improving visual acuity of more than 15 letters. As far as the safety is concerned, there are more complications such as cataract formation and IOP elevation in the triamcinolone group. Complications rate is higher in the group with higher dose (4 mg) (Ip et al., 2009). Although triamcinolone is a long lasting corticosteroid, it appears that it is not enough and it leads to the development of sustained corticosteroid delivery devices, which release the drug longer. One of them is Retisert which has good results in chronic refractory CME (Ramchandran et al., 2008), with the best results 12 month after injection. However, the complication rates are very high - all phakic eyes developed visually significant cataracts, and 92% have had an elevation of IOP that needed intervention. Allergan conducted an international study on dexamethasone sustained delivery devices (Ozurdex) and the six month results have been published. In CRVO subgroup of patients a significantly better result in gaining visual acuity (more than 15 letters) has been recorded in the group which received 0.7 mg implant compared with control group at 30 and 60 days control point, and not significantly better at 90 and 180 days point. There were no significant differences in cataract formation between groups and ocular hypertension occurred in only 4% of patients receiving an implant. In 2009 FDA gave approval for the Ozurdex in the treatment of macular edema secondary to CRVO;

- Intravitreal anti vascular endothelial growth factor (anti-VEGF). As VEGF plays a key role in the pathophysiology of CRVO, several anti-VEGF treatments have been developed to decrease VEGF and block vascular permeability and angiogenic activity (bevacizumab, ranibizumab, pegaptanib). According to the results of CRUISE study, FDA released approval of intravitreal ranibizumab for the treatment of CRVO (Brown et al., 2010);
- In cases of refractory CME secondary to CRVO with no resolution after bevacizumab or IVTA individually, a combination treatment with both agents may result in resolution of CME and significant recovery of visual acuity (Ehlers & Fekrat, 2011; Ekdawi & Bakri, 2007). These results suggest that for some patients, the complementary actions of bevacizumab and IVTA on VEGF and inflammation may be more effective than either therapy used alone in the treatment of RVO. Further studies examining multi-modal therapy are needed to answer these questions regarding optimal therapy. Probably a combined treatment or new drugs will have a better efficacy.

4. Ocular Ischemic Syndrome

Obstructions more proximal to the central retinal artery usually cause a more chronic form of visual problem - the ocular ischemic syndrome. Ocular ischemic syndrome (OIS) is a condition that has a variable spectrum of signs and symptoms that result from chronic ocular insufficiency, usually secondary to severe carotid artery disease (CAD). Moreover, they may be the first manifestations of CAD (Dugan & Green, 1991). OIS was firstly described in 1963 and named *venous stasis retinopathy* (Hedges, 1963; Kearns & Hollenhorst, 1963).

4.1 Epidemiology

The OIS occurs at a mean age of 65 years and generally does not develop before 50 years of age. Men outnumber women by a ratio of 2:1, because of the higher incidence of

atherosclerosis in men (Brown & Magargal, 1988). No racial predilection exists. Bilaterally OIS occurs up to 22% of cases (Mendrinós et al., 2010). The incidence of OIS is not known precisely, but is estimated at 7.5 cases per million people annually (Sturrock & Mueller, 1984).

Different studies found various incidence of OIS development in patients with hemodynamically significant CAD, which is 4%, 18%, and 1.5% respectively (Kearns & Hollenhorst, 1963; Kearns et al., 1978; Klijn et al., 2002). Ipsilateral transient monocular visual loss is the hallmark of carotid insufficiency and occurs in 30-40% of patients with CAD. CAD on the one common (CCA) or internal carotid artery (ICA) is often accompanied by occlusion or stenosis of the opposite carotid artery (Mendrinós et al., 2010).

4.2 Pathophysiology and causes

Both stenosis and occlusion of the common or internal carotid arteries are responsible for ipsilateral ocular signs and symptoms that may herald a devastating cerebral infarction (Biousse, 1997). The decreased vascular perfusion results in tissue hypoxia and increased ocular ischemia, leading to neovascularization (Leibovitch et al., 2009; Kahn et al., 1986; Takaki et al., 2008).

Patients who develop OIS show decreased blood flow in the retrobulbar vessels and reversal of blood flow in the ophthalmic artery (OA) (Mendrinós et al., 2010). OA shunts blood flow away from the eye to the low-resistance intracranial circuit. This blood steal leads to further reduction of retrobulbar blood flow, hypoperfusion, and subsequently ocular ischemia.

OIS develops especially in patients with poor collateral circulation between the internal and external arterial systems or between the two ICAs. The occurrence of cerebral infarctions and poor neurologic prognosis could also be explained by the insufficient collateral circulation.

4.3 Clinical presentation

Ocular ischemic syndrome encompasses a spectrum of ocular signs and symptoms that are the result of ocular hypoperfusion caused by severe carotid artery obstruction.

4.3.1 Symptoms

The presenting symptom is a variable degree of visual loss often accompanied by pain caused either by ischemia of the globe or elevated intraocular pressure in neovascular glaucoma. The natural course of the ischemic syndrome is generally poor, although there is certain proportion of cases with milder clinical picture retaining the visual function.

4.3.2 Signs

The anterior segment signs are often present: neovascularization of the iris in approximately two thirds of eyes at the time of initial examination; corneal edema and striae usually concurrent with increased pressure from neovascular glaucoma. Although the iris neovascularization is the presenting sign in large percentage of patients with ischemic syndrome, only one third of cases develop secondary neovascular glaucoma. This may be due to a lower arterial supply of the ciliary body causing hypotony or normal pressure in

spite neovascular changes in the iridocorneal angle. There may be signs of mild anterior chamber reaction in 20% of these eyes with flare being a more prominent feature than the cellular response (Kahn et al., 1986). Advanced lens opacification may also be present in the late stages of this syndrome. The fundoscopic findings may mimic other vascular retinal disorders and involutive changes seen in elderly population: constriction, straightening and narrowing of the arteries, dilated retinal veins, but without accentuated tortuosity commonly seen in vein occlusions. Venous beading may resemble features of proliferative diabetic retinopathy. In the majority of cases there are dot and blot retinal hemorrhages distributed diffusely around the periphery, but they can spread onto the posterior pole. The other features of retinal ischemia may also be present: cherry red spot appearance, cotton wool exudates, optic atrophy and edema.

4.4 Evaluation and imaging

A careful clinical examination and lab tests (ESR, CRP) must be undertaken to exclude possible temporal arteritis, which may resemble this clinical entity and mandates different diagnostic and therapeutic approach, which may prevent further visual loss and potentially blindness.

4.4.1 Fluorescein and indocyanine green angiography

Besides clinical examination, fluorescein angiography (FA) can help to establish the diagnosis of ocular ischemic syndrome. Prolonged choroidal filling time is the most specific angiographic sign of ocular ischemic syndrome (Mendrinou et al., 2010). Patchy filling of the choroid that lasts more than 5 seconds is seen in about 60% of eyes affected by ocular ischemic syndrome (Brown & Margargal, 1998). Staining of the retinal vessels, both the major vessels and its branches, is another sign seen in 85% of eyes with ocular ischemic syndrome. Demonstration of a well-demarcated leading edge of fluorescein dye within a retinal artery is a typical sign of OIS. Other findings on fluorescein angiography include an increased arteriovenous transit time (over 11 seconds), macular edema, retinal capillary nonperfusion, and evidence of microaneurysms (especially in the periphery) (Richard et al., 1998).

Indocyanine green angiography (ICG) shows signs of choroidal hypoperfusion – occlusion of choriocapillaries with filling defects in the posterior pole or the mid-periphery. There is also prolonged arm to choroid (over 10 seconds) and intrachoroidal circulation time (over 5-6 seconds). Another characteristic finding is slow filling of the watershed zones of the choroids) (Richard et al., 1998).

4.4.2 Electroretinography

Electroretinography demonstrates a decrease in both a and b waves in these eyes, which is in contrast to the sparing of the a wave found in central retinal artery occlusions (Brown et al., 1982).

It is of paramount role to assess the carotid artery function since the endarterectomy procedure reduces the risk of stroke as life threatening consequence and there is some evidence of improvement in retinal function viewed through the improvement of a and b waves in electroretinography, as well as the normalization of preoperative retrograde ophthalmic artery flow shown on Doppler color imaging (Kawaguchi et al., 2001; Story et al., 1995).

4.4.3 Duplex carotid ultrasonography

Duplex carotid ultrasonography combines B-mode ultrasound and Doppler ultrasound providing the morphologic imaging and flow velocity data. It is the most commonly used noninvasive method in evaluation of carotid artery obstruction.

Color Doppler imaging is a noninvasive tool for assessing the velocity of blood flow in the retrobulbar circulation. Diminished velocities of the blood flow in the central retinal artery, choroidal vessels, and ophthalmic artery are typical. There may be a reversal of flow in the ophthalmic artery, as well. Color Doppler imaging may assess the carotid arteries simultaneously.

4.4.4 Invasive diagnostics

If noninvasive carotid artery evaluation is unremarkable in an eye that shows signs suggestive of ocular ischemia, conventional carotid arteriography or digital subtraction angiography may be required to detect possible chronic obstruction of the ophthalmic artery (Wardlaw et al., 2006).

The new minimally invasive methods, magnetic resonance angiography and computed tomographic angiography are evolving and improving as adjunctive diagnostic tests in evaluating the patients with carotid occlusive disease.

4.5 Differential diagnostic

Diabetic retinopathy

Nonischemic central retinal venous occlusions

Giant cell arteritis

Takayasu arteritis

Ischemic optic neuropathy

Retinal artery occlusion

Neovascular glaucoma

4.6 Management

Management of OIS is basically multidisciplinary and the task of the ophthalmologist is to treat ocular condition, recognize the possible cause of OIS and refer the patient to a cardiologist, neurologist or other specialists, where they can get proper treatment of the cause of OIS.

Ophthalmology treatment consists of increased IOP control, management of neovascularization and control of anterior segment inflammation.

- Anterior segment inflammation is usually treated with topical steroids and long acting cycloplegic agents;
- Increased IOP, usually controlled with topical β -adrenergics blockers, α -agonists and topical or oral carbonic anhydrase inhibitors to reduce aqueous production; prostaglandins (could increase ocular inflammation) and pilocarpin should be avoided;

- Ocular neovascularization following carotid occlusive disease is usually managed with panretinal photocoagulation and can prevent neovascular glaucoma (Carter, 1984; Chen et al., 2001). If PRP is not possible due to media opacities or refractory miosis, other modalities such as transconjunctival cryotherapy of peripheral retina or transscleral diode laser retinopexy should be considered to prevent neovascularization. In any case, PRP works effectively and reduces the iris neovascularization in only 36% of patients with OIS (Sivalingam et al., 1991). In other cases it can even get worse (Turut & Malthieu, 1986), which suggests that uveal ischemia can induce neovascularization, as it is shown on animal model (Hayreh & Baines, 1973). Therefore, in the cases where there is retinal ischemia, prophylactic PRP is advisable. Neovascularization and macular edema caused by OIS can be also treated with intravitreal bevacizumab (Amselem et al., 2007). In this case report neovascularization regressed, but there was no improvement in VA or IOP. Macular edema can also be treated with triamcinolone intravitreally, reducing macular edema and improving visual acuity (Klais & Spaide, 2004). Further investigation with a more reliable sample is needed to establish the role of this therapy in IOS patient. Additionally, we have to mention that when neovascular glaucoma occurs it is usually refractory to medical therapy and if panretinal photocoagulation failed the other method of treatment has to be applied, such as (i) trabeculectomy with antimetabolites as a first step when there is potential to improve state, (ii) aqueous shunt implants as a second step, and (iii) diode laser cyclophotocoagulation or retinal cryoablation, and in the worst case, with no vision and the patient suffering from great pain (iv) evisceration or enucleation should be considered (Sivak-Callcott et al., 2001).

Medical treatment includes conservative treatment by other specialists in order to manage associated systemic diseases or states such as coronary artery disease, hiperlipidemia, hypertension, diabetes mellitus etc.

Some of the surgical treatment is advocated to manage carotid stenosis and to improve ocular ischemia (Costa et al. 1999; Chaer & Makaroun, 2008; Sivalingam et al., 1991), such as carotid artery endarterectomy (CEA), carotid artery stenting (CAS) or extracranial-intracranial arterial bypass surgery (EC-IC), but without sufficient evidence to claim improvement of the ocular state with this treatment, except for CEA, where studies show some beneficial effect on the patient who has mild ocular ischemia and less effect on the patient with a greater degree of ocular ischemia, where retinal damage has probably become irreversible.

In conclusion, we can say that the ocular ischemic syndrome is a rare, vision-threatening condition and since the ophthalmologists may be the first to deal with such patients, they should be aware of the clinical presentation of OIS and recognize it early enough to start treating the condition when visual acuity is preserved enough and when prognosis is better. The continuing improvements in the diagnostic techniques, medical management and surgical treatment of carotid artery occlusive disease make the role of ophthalmologists increasingly important in the early detection and management of the OIS and its comorbidity.

5. Conclusion

Retinal vascular occlusions are an important cause of visual loss, particularly in elderly patients with multifactorial pathophysiological arms uniquely intertwined in each patient. They are often referred to as a „stroke“ in the eye due to symptoms and clinical picture, often dramatic in its presentation. It also emphasizes the tremendous influence on patient's quality of life.

Apart from the similar clinical symptoms of visual loss there are some distinctive features that direct the clinician towards the diagnosis of arterial or venous occlusion. A thorough examination should assess the degree of vision loss by testing visual acuity, the presence of afferent pupillary defect, visual field testing, slit lamp examination of both anterior and posterior segments of the eye as well as ERG, which along with afferent pupillary defect and visual field testing provides the most sensitive diagnostic test in distinguishing between ischemic and non ischemic types of the occlusive disease (Hayreh, 2005). Visual acuity alone is not sufficient to validate peripheral retinal function but solely central vision. Therefore, it has been advocated by some authors to combine morphologic and functional tests in order to establish the type of the occlusion which has tremendous impact on the clinical course, prognosis and management of each case. The oxymetry (Gehlert et al., 2010) offers new possible tool in evaluating the perfusion status of the retina as this is extremely important prognostic factor when deciding which diagnostic and therapeutic algorithm should be undertaken in patient with occlusive disorder.

In conclusion we can say that retinal vascular occlusions are very common ocular diseases and the causes of visual loss with poor perspectives in the past, but recent studies on various medications and treatment modalities raise hope between a patient and ophthalmologist for establishing the proper treatment. Although we still cannot foresee, prevent, or causatively and successfully treat occlusive diseases of the retina, there are promising, recently introduced novel options focused on the management of visually deteriorating complications. Intravitreal agents, especially anti-VEGF medications and intravitreal corticosteroid implants have drastically changed the visual outcome for the affected patients. The perspective looks brighter as the development of the most effective treatment regimens and their combinations is evolving. Probably a combined therapy will better act than a single one. Developing new drugs is warranted.

6. Acknowledgement

Authors would like to thank Zoran Pletikosa, MD on providing them with useful medical sources from some databases unavailable to them in a time of writing this chapter.

7. References

- Ahuja, R. M., Chaturvedi, S., Elliott, D., Joshi, N., Puklin, J. E., & Abrams, G. W. (1999). Mechanisms of retinal arterial occlusive disease in African American and Caucasian patients. *Stroke*, 30(8), 1506-1509.
- Akkoyun, I., Baskin, E., Caner, H., Agildere, M. A., Boyvat, F., & Akova, Y. A. (2006). [Hemicentral retinal artery occlusion associated with moyamoya syndrome]. *Ophthalmologie*, 103(10), 888-891.
- Amselem, L., Montero, J., Diaz-Llopis, M., Pulido, J. S., Bakri, S. J., Palomares, P., et al. (2007). Intravitreal bevacizumab (Avastin) injection in ocular ischemic syndrome. *Am J Ophthalmol*, 144(1), 122-124.
- Appiah, A. P., & Trempe, C. L. (1989). Differences in contributory factors among hemicentral, central, and branch retinal vein occlusions. *Ophthalmology*, 96(3), 364-366.

- Argon laser photocoagulation for macular edema in branch vein occlusion. The Branch Vein Occlusion Study Group. (1984). *Am J Ophthalmol*, 98(3), 271-282.
- Argon laser scatter photocoagulation for prevention of neovascularization and vitreous hemorrhage in branch vein occlusion. A randomized clinical trial. Branch Vein Occlusion Study Group. (1986). *Arch Ophthalmol*, 104(1), 34-41.
- Arruga, J., & Sanders, M. D. (1982). Ophthalmologic findings in 70 patients with evidence of retinal embolism. *Ophthalmology*, 89(12), 1336-1347.
- Atebara N. H., Brown, G. C., & Cater, J. (1995). Efficacy of anterior chamber paracentesis and Carbogen in treating acute nonarteritic central retinal artery occlusion. *Ophthalmology* 102:2029-2034.
- Bandello, F., Vigano D'Angelo, S., Parlavecchia, M., Tavola, A., Della Valle, P., Brancato, R., et al. (1994). Hypercoagulability and high lipoprotein(a) levels in patients with central retinal vein occlusion. *Thromb Haemost*, 72(1), 39-43.
- Barak, N., Ferencz, J. R., Freund, M., & Mekori, Y. (1997). Urticaria in idiopathic bilateral recurrent branch retinal arterial occlusion. *Acta Ophthalmol Scand*, 75(1), 107-108.
- Bavbek, T., Yenice, O., & Toygar, O. (2005). Problems with attempted chorioretinal venous anastomosis by laser for nonischemic CRVO and BRVO. *Ophthalmologica*, 219(5), 267-271.
- Beatty, S., & Au Eong, K. G. (2000). Acute occlusion of the retinal arteries: current concepts and recent advances in diagnosis and management. *J Accid Emerg Med*, 17(5), 324-329.
- Beiran, I., Dori, D., Pikkol, J., Goldsher, D., & Miller, B. (1995). Recurrent retinal artery obstruction as a presenting symptom of ophthalmic artery aneurysm: a case report. *Graefes Arch Clin Exp Ophthalmol*, 233(7), 444-447.
- Berversdorf, D., Stommel, E., Allen, C., Stevens, R., & Lessell, S. (1997). Recurrent branch retinal infarcts in association with migraine. *Headache*, 37(6), 396-399.
- Biousse, V. (1997). Carotid disease and the eye. *Curr Opin Ophthalmol*, 8(6), 16-26.
- Boers, G. H., Smals, A. G., Trijbels, F. J., Fowler, B., Bakkeren, J. A., Schoonderwaldt, H. C., et al. (1985). Heterozygosity for homocystinuria in premature peripheral and cerebral occlusive arterial disease. *N Engl J Med*, 313(12), 709-715.
- Boyd, S. R., Zachary, I., Chakravarthy, U., Allen, G. J., Wisdom, G. B., Cree, I. A., et al. (2002). Correlation of increased vascular endothelial growth factor with neovascularization and permeability in ischemic central vein occlusion. *Arch Ophthalmol*, 120(12), 1644-1650.
- Bradavica, M., Barać, J., Benašić, T., Kalajdžić Čandrlić, J., Štenc Bradavica, I., & Biuk, D. (2009). Treatment of occlusion of the central retinal artery with hyperbaric oxygenation - our experience on eight patients. *Medicinski Glasnik*, 6(1), 4.
- Brown, D. M., Campochiaro, P. A., Singh, R. P., Li, Z., Gray, S., Saroj, N., et al. (2010). Ranibizumab for macular edema following central retinal vein occlusion: six-month primary end point results of a phase III study. *Ophthalmology*, 117(6), 1124-1133 e1121.
- Brown, G. C. (1994). Retinal artery obstructive disease. In S. J. Ryan (Ed.), *Retina* (2 ed., Vol. 2, pp. 1361-1377). St. Louis: Mosby.
- Brown, G. (1999). Retinal arterial occlusive disease. In D. Guyer (Ed.), *Retina-Vitreous-Macula* (Vol. 1, pp. 271-285).

- Brown, G. C., Magargal, L. E., Shields, J. A., Goldberg, R. E., & Walsh, P. N. (1981). Retinal arterial obstruction in children and young adults. *Ophthalmology*, 88(1), 18-25.
- Brown, G. C., Magargal, L. E., & Sergott, R. (1986). Acute obstruction of the retinal and choroidal circulations. *Ophthalmology*, 93(11), 1373-1382.
- Brown, G. C., & Magargal, L. E. (1988). The ocular ischemic syndrome. Clinical, fluorescein angiographic and carotid angiographic features. *Int Ophthalmol*, 11(4), 239-251.
- Brown, G. C., & Reber, R. (1986). An unusual presentation of branch retinal artery obstruction in association with ocular neovascularization. *Can J Ophthalmol*, 21(3), 103-106.
- Brown, G. C., & Shields, J. A. (1979). Cilioretinal arteries and retinal arterial occlusion. *Arch Ophthalmol*, 97(1), 84-92.
- Bruno, A., Jones, W. L., Austin, J. K., Carter, S., & Qualls, C. (1995). Vascular outcome in men with asymptomatic retinal cholesterol emboli. A cohort study. *Ann Intern Med*, 122(4), 249-253.
- Cahill, M. T., Kaiser, P. K., Sears, J. E., & Fekrat, S. (2003). The effect of arteriovenous sheathotomy on cystoid macular oedema secondary to branch retinal vein occlusion. *Br J Ophthalmol*, 87(11), 1329-1332.
- Carter, J. E. (1984). Panretinal photocoagulation for progressive ocular neovascularization secondary to occlusion of the common carotid artery. *Ann Ophthalmol*, 16(6), 572-576.
- Chaer, R. A., & Makaroun, M. S. (2008). Evolution of carotid stenting: indications. *Semin Vasc Surg*, 21(2), 59-63.
- Chen, K. J., Chen, S. N., Kao, L. Y., Ho, C. L., Chen, T. L., Lai, C. C., et al. (2001). Ocular ischemic syndrome. *Chang Gung Med J*, 24(8), 483-491.
- Chopdar, A. (1984). Dual trunk central retinal vein incidence in clinical practice. *Arch Ophthalmol*, 102(1), 85-87.
- Christoffersen, N. L., & Larsen, M. (1999). Pathophysiology and hemodynamics of branch retinal vein occlusion. *Ophthalmology*, 106(11), 2054-2062.
- Comp, P. C., & Esmon, C. T. (1984). Recurrent venous thromboembolism in patients with a partial deficiency of protein S. *N Engl J Med*, 311(24), 1525-1528.
- Conway, M. D., Tong, P., & Olk, R. J. (1995). Branch retinal artery occlusion (BRAO) combined with branch retinal vein occlusion (BRVO) and optic disc neovascularization associated with HIV and CMV retinitis. *Int Ophthalmol*, 19(4), 249-252.
- Costa, V. P., Kuzniec, S., Molnar, L. J., Cerri, G. G., Puech-Leao, P., & Carvalho, C. A. (1999). The effects of carotid endarterectomy on the retrobulbar circulation of patients with severe occlusive carotid artery disease. An investigation by color Doppler imaging. *Ophthalmology*, 106(2), 306-310.
- Dugan, J. D., Jr., & Green, W. R. (1991). Ophthalmologic manifestations of carotid occlusive disease. *Eye (Lond)*, 5 (Pt 2), 226-238.
- Duker, J. S. (2003). Retinal Arterial Obstruction. In M. Yanoff, J. S. Duker & A. J. James (Eds.), *Ophthalmology* (2nd ed.). St. Louis: Mosby.
- Duker, J. S., & Brown, G. C. (1989a). Anterior location of the crossing artery in branch retinal vein obstruction. *Arch Ophthalmol*, 107(7), 998-1000.
- Duker, J. S., & Brown, G. C. (1989b). Neovascularization of the optic disc associated with obstruction of the central retinal artery. *Ophthalmology*, 96(1), 87-91.

- Duker, J. S., Sivalingam, A., Brown, G. C., & Reber, R. (1991). A prospective study of acute central retinal artery obstruction. The incidence of secondary ocular neovascularization. *Arch Ophthalmol*, 109(3), 339-342.
- Ehlers, J. P., & Fekrat, S. (2011). Retinal vein occlusion: beyond the acute event. *Surv Ophthalmol*, 56(4), 281-299.
- Ekdawi, N. S., & Bakri, S. J. (2007). Intravitreal triamcinolone and bevacizumab combination therapy for macular edema due to central retinal vein occlusion refractory to either treatment alone. *Eye (Lond)*, 21(8), 1128-1130.
- Fekrat, S., Goldberg, M. F., & Finkelstein, D. (1998). Laser-induced chorioretinal venous anastomosis for nonischemic central or branch retinal vein occlusion. *Arch Ophthalmol*, 116(1), 43-52.
- Figueroa, M. S., Torres, R., & Alvarez, M. T. (2004). Comparative study of vitrectomy with and without vein decompression for branch retinal vein occlusion: a pilot study. *Eur J Ophthalmol*, 14(1), 40-47.
- Fong, A. C., Schatz, H., McDonald, H. R., Burton, T. C., Maberley, A. L., Joffe, L., et al. (1992). Central retinal vein occlusion in young adults (papillophlebitis). *Retina*, 12(1), 3-11.
- Gehlert, S., Dawczynski, J., Hammer, M., & Strobel, J. (2010). Haemoglobin Oxygenation of Retinal Vessels in Branch Retinal Artery Occlusions over Time and Correlation with Clinical Outcome. *Klin Monbl Augenheilkd*, 227(12), 976-980.
- Glacet-Bernard, A., Leroux les Jardins, G., Lasry, S., Coscas, G., Soubrane, G., Souied, E., et al. (2010). Obstructive sleep apnea among patients with retinal vein occlusion. *Arch Ophthalmol*, 128(12), 1533-1538.
- Graham, E. M. (1990). The investigation of patients with retinal vascular occlusion. *Eye (Lond)*, 4 (Pt 3), 464-468.
- Greven, C. M., Slusher, M. M., & Weaver, R. G. (1995). Retinal arterial occlusions in young adults. *Am J Ophthalmol*, 120(6), 776-783.
- Haller, J. A., Bandello, F., Belfort, R., Jr., Blumenkranz, M. S., Gillies, M., Heier, J., et al. (2010). Randomized, sham-controlled trial of dexamethasone intravitreal implant in patients with macular edema due to retinal vein occlusion. *Ophthalmology*, 117(6), 1134-1146 e1133.
- Hayreh, S. S. (1994). Retinal vein occlusion. *Indian J Ophthalmol*, 42(3), 109-132.
- Hayreh, S. S. (1999). Retinal and optic nerve head ischemic disorders and atherosclerosis: role of serotonin. *Prog Retin Eye Res*, 18(2), 191-221.
- Hayreh, S. S. (2002). t-PA in CRVO. *Ophthalmology*, 109(10), 1758-1761; author reply 1761-1753.
- Hayreh, S. S. (2003). Management of central retinal vein occlusion. *Ophthalmologica*, 217(3), 167-188.
- Hayreh, S. S. (2005). Prevalent misconceptions about acute retinal vascular occlusive disorders. *Prog Retin Eye Res*, 24(4), 493-519.
- Hayreh, S. S. (2010). Central Retinal Vein Occlusion from webeye.ophth.uiowa.edu/dept/crvo/
- Hayreh, S. S. (2011). Acute retinal arterial occlusive disorders. *Prog Retin Eye Res*, 30(5), 359-394.
- Hayreh, S. S., & Baines, J. A. (1973). Occlusion of the vortex veins. An experimental study. *Br J Ophthalmol*, 57(4), 217-238.

- Hayreh, S. S., & Hayreh, M. S. (1980). Hemi-central retinal vein occlusion. Pathogenesis, clinical features, and natural history. *Arch Ophthalmol*, 98(9), 1600-1609.
- Hayreh, S. S., Opremcak, E. M., Bruce, R. A., Lomeo, M. D., Ridenour, C. D., Letson, A. D., et al. (2002). Radial optic neurotomy for central retinal vein obstruction. *Retina*, 22(3), 374-377; author reply 377-379.
- Hayreh, S. S., & Podhajsky, P. (1982). Ocular neovascularization with retinal vascular occlusion. II. Occurrence in central and branch retinal artery occlusion. *Arch Ophthalmol*, 100(10), 1585-1596.
- Hayreh, S. S., Podhajsky, P. A., & Zimmerman, M. B. (2009). Retinal artery occlusion: associated systemic and ophthalmic abnormalities. *Ophthalmology*, 116(10), 1928-1936.
- Hayreh, S. S., Podhajsky, P. A., & Zimmerman, M. B. (2011). Natural history of visual outcome in central retinal vein occlusion. *Ophthalmology*, 118(1), 119-133 e111-112.
- Hayreh, S. S., Rojas, P., Podhajsky, P., Montague, P., & Woolson, R. F. (1983). Ocular neovascularization with retinal vascular occlusion-III. Incidence of ocular neovascularization with retinal vein occlusion. *Ophthalmology*, 90(5), 488-506.
- Hayreh, S. S., & Weingeist, T. A. (1980). Experimental occlusion of the central artery of the retina. I. Ophthalmoscopic and fluorescein fundus angiographic studies. *Br J Ophthalmol*, 64(12), 896-912.
- Hayreh, S. S., Zimmerman, B., McCarthy, M. J., & Podhajsky, P. (2001). Systemic diseases associated with various types of retinal vein occlusion. *Am J Ophthalmol*, 131(1), 61-77.
- Hayreh, S. S., & Zimmerman, M. B. (2005). Central retinal artery occlusion: visual outcome. *Am J Ophthalmol*, 140(3), 376-391.
- Hayreh, S. S., Zimmerman, M. B., Kimura, A., & Sanon, A. (2004). Central retinal artery occlusion. Retinal survival time. *Exp Eye Res*, 78(3), 723-736.
- Hedges, T. R., Jr. (1963). Ophthalmoscopic findings in internal carotid artery occlusion. *Am J Ophthalmol*, 55, 1007-1012.
- Ho, T. Y., Lin, P. K., & Huang, C. H. (2008). White-centered retinal hemorrhage in ocular ischemic syndrome resolved after carotid artery stenting. *J Chin Med Assoc*, 71(5), 270-272.
- Ip, M. S., Scott, I. U., VanVeldhuisen, P. C., Oden, N. L., Blodi, B. A., Fisher, M., et al. (2009). A randomized trial comparing the efficacy and safety of intravitreal triamcinolone with observation to treat vision loss associated with macular edema secondary to central retinal vein occlusion: the Standard Care vs Corticosteroid for Retinal Vein Occlusion (SCORE) study report 5. *Arch Ophthalmol*, 127(9), 1101-1114.
- Jain, N., & Juang, P. S. C. (2009, Jun 30, 2009). Retinal Artery Occlusion. Retrieved Jun 12, 2011, from <http://emedicine.medscape.com/article/799119-overview>
- Johnson, M. W., Thomley, M. L., Huang, S. S., & Gass, J. D. (1994). Idiopathic recurrent branch retinal arterial occlusion. Natural history and laboratory evaluation. *Ophthalmology*, 101(3), 480-489.
- Jorizzo PA, K. M., Shults WT, Linn ML. (1987). Visual recovery in combined central retinal artery and central retinal vein occlusion. *Am J Ophthalmol*, 104, 358-363.
- Justice, J., Jr., & Lehmann, R. P. (1976). Cilioretinal arteries. A study based on review of stereo fundus photographs and fluorescein angiographic findings. *Arch Ophthalmol*, 94(8), 1355-1358.


- Kahn, M., Green, W. R., Knox, D. L., & Miller, N. R. (1986). Ocular features of carotid occlusive disease. *Retina*, 6(4), 239-252.
- Karagoz, B., Ayata, A., Bilgi, O., Uzun, G., Unal, M., Kandemir, E. G., et al. (2009). Hemicentral retinal artery occlusion in a breast cancer patient using anastrozole. *Onkologie*, 32(7), 421-423.
- Kawaguchi, S., Okuno, S., Sakaki, T., & Nishikawa, N. (2001). Effect of carotid endarterectomy on chronic ocular ischemic syndrome due to internal carotid artery stenosis. *Neurosurgery*, 48(2), 328-332; discussion 322-323.
- Kearns, T. P., & Hollenhorst, R. W. (1963). Venous-Stasis Retinopathy of Occlusive Disease of the Carotid Artery. *Proc Staff Meet Mayo Clin*, 38, 304-312.
- Kearns, T. P., Siekert, R. G., & Sundt, T. M. (1978). The ocular aspects of carotid artery bypass surgery. *Trans Am Ophthalmol Soc*, 76, 247-265.
- Klais, C. M., & Spaide, R. F. (2004). Intravitreal triamcinolone acetonide injection in ocular ischemic syndrome. *Retina*, 24(3), 459-461.
- Klein, R., Klein, B. E., Jensen, S. C., Moss, S. E., & Meuer, S. M. (1999). Retinal emboli and stroke: the Beaver Dam Eye Study. *Arch Ophthalmol*, 117(8), 1063-1068.
- Klein, R., Klein, B. E., Moss, S. E., & Meuer, S. M. (2000). The epidemiology of retinal vein occlusion: the Beaver Dam Eye Study. *Trans Am Ophthalmol Soc*, 98, 133-141; discussion 141-133.
- Klein, R., Klein, B. E., Moss, S. E., & Meuer, S. M. (2003). Retinal emboli and cardiovascular disease: the Beaver Dam Eye Study. *Arch Ophthalmol*, 121(10), 1446-1451.
- Klijn, C. J., Kappelle, L. J., van Schooneveld, M. J., Hoppenreijds, V. P., Algra, A., Tulleken, C. A., et al. (2002). Venous stasis retinopathy in symptomatic carotid artery occlusion: prevalence, cause, and outcome. *Stroke*, 33(3), 695-701.
- Korner-Stiefbold, U. (2001). [Central retinal artery occlusion--etiology, clinical picture, therapeutic possibilities]. *Ther Umsch*, 58(1), 36-40.
- Kreutzer, T. C., Alge, C. S., Wolf, A. H., Kook, D., Burger, J., Strauss, R., et al. (2008). Intravitreal bevacizumab for the treatment of macular oedema secondary to branch retinal vein occlusion. *Br J Ophthalmol*, 92(3), 351-355.
- Kriechbaum, K., Michels, S., Prager, F., Georgopoulos, M., Funk, M., Geitzenauer, W., et al. (2008). Intravitreal Avastin for macular oedema secondary to retinal vein occlusion: a prospective study. *Br J Ophthalmol*, 92(4), 518-522.
- Le Rouic, J. F., Bejjani, R. A., Rumen, F., Caudron, C., Bettembourg, O., Renard, G., et al. (2001). Adventitial sheathotomy for decompression of recent onset branch retinal vein occlusion. *Graefes Arch Clin Exp Ophthalmol*, 239(10), 747-751.
- Leibovitch, I., Calonje, D., & El-Harazi, S. M. (2009, May 13, 2009). Ocular Ischemic Syndrome *The Medscape from WebMD Journal of Medicine* Retrieved June 11, 2011, from <http://emedicine.medscape.com/article/1201678-overview>
- Liebreich, R. (1855). Ophthalmoskopische Notizen: Ueber die Farbe des Augengrundes. *Albrecht Von Graefes Arch Ophthalmol*, 1, 333-343.
- Lima, V. C., Yeung, L., Castro, L.C., Landa, G. & Rosen, R. B. (2011). Correlation between spectral domain optical coherence tomography findings and visual outcomes in central retinal vein occlusion. *Clin Ophthalmol*, 5:299-305.
- Lindley, R. I., Wang, J. J., Wong, M. C., Mitchell, P., Liew, G., Hand, P., et al. (2009). Retinal microvasculature in acute lacunar stroke: a cross-sectional study. *Lancet Neurol*, 8(7), 628-634.

- Love, P. E., & Santoro, S. A. (1990). Antiphospholipid antibodies: anticardiolipin and the lupus anticoagulant in systemic lupus erythematosus (SLE) and in non-SLE disorders. Prevalence and clinical significance. *Ann Intern Med*, 112(9), 682-698.
- Mangat, H. S. (1995). Retinal artery occlusion. *Surv Ophthalmol*, 40(2), 145-156.
- Marcucci, R., Bertini, L., Giusti, B., Brunelli, T., Fedi, S., Cellai, A. P., et al. (2001). Thrombophilic risk factors in patients with central retinal vein occlusion. *Thromb Haemost*, 86(3), 772-776.
- Matsui, Y., Katsumi, O., Sakaue, H., & Hirose, T. (1994). Electroretinogram b/a wave ratio improvement in central retinal vein obstruction. *Br J Ophthalmol*, 78(3), 191-198.
- McCullough, H. K., Reinert, C. G., Hynan, L. S., Albiston, C. L., Inman, M. H., Boyd, P. I., et al. (2004). Ocular findings as predictors of carotid artery occlusive disease: is carotid imaging justified? *J Vasc Surg*, 40(2), 279-286.
- Mendrinou, E., Machinis, T. G., & Pournaras, C. J. (2010). Ocular ischemic syndrome. *Surv Ophthalmol*, 55(1), 2-34.
- Mizener, J. B., Podhajsky, P., & Hayreh, S. S. (1997). Ocular ischemic syndrome. *Ophthalmology*, 104(5), 859-864.
- Morandi, X., Le Bourdon, E., Darnault, P., Brassier, G., & Duval, J. M. (1998). Unusual origin of the ophthalmic artery and occlusion of the central retinal artery. *Surg Radiol Anat*, 20(1), 69-71.
- Natural history and clinical management of central retinal vein occlusion. The Central Vein Occlusion Study Group. (1997). *Arch Ophthalmol*, 115(4), 486-491.
- Noma, H., Funatsu, H., Mimura, T., & Hori, S. (2008). Changes of vascular endothelial growth factor after vitrectomy for macular edema secondary to retinal vein occlusion. *Eur J Ophthalmol*, 18(6), 1017-1019.
- Nussenblatt, R. B., Kaufman, S. C., Palestine, A. G., Davis, M. D., & Ferris, F. L., 3rd. (1987). Macular thickening and visual acuity. Measurement in patients with cystoid macular edema. *Ophthalmology*, 94(9), 1134-1139.
- Opremcak, E., Rehmar, A. J., Ridenour, C. D., Borkowski, L. M., & Kelley, J. K. (2008). Restoration of retinal blood flow via transluminal Nd:YAG embolysis/embolectomy (TYL/E) for central and branch retinal artery occlusion. *Retina*, 28(2), 226-235.
- Pai, S. A., Shetty, R., Vijayan, P. B., Venkatasubramanian, G., Yadav, N. K., Shetty, B. K., et al. (2007). Clinical, anatomic, and electrophysiologic evaluation following intravitreal bevacizumab for macular edema in retinal vein occlusion. *Am J Ophthalmol*, 143(4), 601-606.
- Palmowski-Wolfe, A. M., Denninger, E., Geisel, J., Pindur, G., & Ruprecht, K. W. (2007). Antiphospholipid antibodies in ocular arterial and venous occlusive disease. *Ophthalmologica*, 221(1), 41-46.
- Parodi, M. B., Iacono, P., & Ravalico, G. (2008). Intravitreal triamcinolone acetonide combined with subthreshold grid laser treatment for macular oedema in branch retinal vein occlusion: a pilot study. *Br J Ophthalmol*, 92(8), 1046-1050.
- Pe'er, J., Folberg, R., Itin, A., Gnessin, H., Hemo, I., & Keshet, E. (1998). Vascular endothelial growth factor upregulation in human central retinal vein occlusion. *Ophthalmology*, 105(3), 412-416.

- Ramchandran, R. S., Fekrat, S., Stinnett, S. S., & Jaffe, G. J. (2008). Fluocinolone acetonide sustained drug delivery device for chronic central retinal vein occlusion: 12-month results. *Am J Ophthalmol*, 146(2), 285-291.
- Reese, L. T., & Shafer, D. (1978). Retinal embolization from endocarditis. *Ann Ophthalmol*, 10(12), 1655-1657.
- Richard, G., Saubrane, G., & Yanuzzi, L. A. (1998). *Fluorescein and ICG Angiography: Textbook and atlas*. (2 Rev Exp ed.). New York, N.Y. U.S.A. : Thieme.
- Richards, R. D. (1979). Simultaneous occlusion of the central retinal artery and vein. *Trans Am Ophthalmol Soc*, 77, 191-209.
- Risk factors for central retinal vein occlusion. The Eye Disease Case-Control Study Group. (1996). *Arch Ophthalmol*, 114(5), 545-554.
- Rogers, S., McIntosh, R. L., Cheung, N., Lim, L., Wang, J. J., Mitchell, P., et al. (2010). The prevalence of retinal vein occlusion: pooled data from population studies from the United States, Europe, Asia, and Australia. *Ophthalmology*, 117(2), 313-319 e311.
- Rudkin, A. K., Lee, A. W., & Chen, C. S. (2010). Ocular neovascularization following central retinal artery occlusion: prevalence and timing of onset. *Eur J Ophthalmol*, 20(6), 1042-1046.
- Rosenfeld, P. J., Rich, R. M., & Lalwani, G. A. (2006). Ranibizumab: Phase III clinical trial results. *Ophthalmol Clin North Am*, 19(3), 361-372.
- Rumelt, S., Dorenboim, Y., & Rehany, U. (1999). Aggressive systematic treatment for central retinal artery occlusion. *Am J Ophthalmol*, 128(6), 733-738.
- Rumelt, S., & Brown, G. C. (2003). Update on treatment of retinal arterial occlusions. *Curr Opin Ophthalmol* 14 - (3):139-141.
- Rumelt, S., & Brown, G. C. (2004). A systematic approach to evaluate and treat retinal arterial occlusions. Handouts for a course on retinal arterial occlusions for the American Academy of ophthalmology Meetings.
- Sanborn, G. E., & Magargal, L. E. (1984). Characteristics of the hemispheric retinal vein occlusion. *Ophthalmology*, 91(12), 1616-1626.
- Schmidt, D., Schumacher, M., & Wakhloo, A. K. (1992). Microcatheter urokinase infusion in central retinal artery occlusion. *Am J Ophthalmol*, 113(4), 429-434.
- Schmidt, D., Hetzel, A., & Geibel-Zehender, A. (2005). Retinal arterial occlusion due to embolism of suspected cardiac tumors -- report on two patients and review of the topic. *Eur J Med Res*, 10(7), 296-304.
- Schmidt, D., Hetzel, A., Geibel-Zehender, A., & Schulte-Monting, J. (2007). Systemic diseases in non-inflammatory branch and central retinal artery occlusion--an overview of 416 patients. *Eur J Med Res*, 12(12), 595-603.
- Schmidt, D., & Kramer-Zucker, A. (2011). [Hemicentral Retinal Artery Occlusion due to Oral Contraceptives.]. *Klin Monbl Augenheilkd*.
- Schumacher, M., Schmidt, D., & Wakhloo, A. K. (1993). Intra-arterial fibrinolytic therapy in central retinal artery occlusion. *Neuroradiology*, 35(8), 600-605.
- Schumacher, M., Schmidt, D., Jurklies, B., Gall, C., Wanke, I., Schmoor, C., et al. (2010). Central retinal artery occlusion: local intra-arterial fibrinolysis versus conservative treatment, a multicenter randomized trial. *Ophthalmology*, 117(7), 1367-1375 e1361.
- Scott, I. U., Ip, M. S., VanVeldhuisen, P. C., Oden, N. L., Blodi, B. A., Fisher, M., et al. (2009). A randomized trial comparing the efficacy and safety of intravitreal triamcinolone with standard care to treat vision loss associated with macular Edema secondary to

- branch retinal vein occlusion: the Standard Care vs Corticosteroid for Retinal Vein Occlusion (SCORE) study report 6. *Arch Ophthalmol*, 127(9), 1115-1128.
- Scott, I. U., VanVeldhuisen, P. C., Oden, N. L., Ip, M. S., Blodi, B. A., Hartnett, M. E., & Cohen, G. (2011). Baseline predictors of visual acuity and retinal thickness outcomes in patients with retinal vein occlusion: Standard Care Versus Corticosteroid for Retinal Vein Occlusion Study report 10. *Ophthalmology* 118(2):345-52.
- Sharma, S. (1998). The systemic evaluation of acute retinal artery occlusion. *Curr Opin Ophthalmol*, 9(3), 1-5.
- Sharma, S., Pater, J. L., Lam, M., & Cruess, A. F. (1998). Can different types of retinal emboli be reliably differentiated from one another? An inter- and intraobserver agreement study. *Can J Ophthalmol*, 33(3), 144-148.
- Sharma, S., Sharma, S. M., Cruess, A. F., & Brown, G. C. (1997). Transthoracic echocardiography in young patients with acute retinal arterial obstruction. RECO Study Group. Retinal Emboli of Cardiac Origin Group. *Can J Ophthalmol*, 32(1), 38-41.
- Sivak-Callcott, J. A., O'Day, D. M., Gass, J. D., & Tsai, J. C. (2001). Evidence-based recommendations for the diagnosis and treatment of neovascular glaucoma. *Ophthalmology*, 108(10), 1767-1776; quiz1777, 1800.
- Sivalingam, A., Brown, G. C., & Magargal, L. E. (1991). The ocular ischemic syndrome. III. Visual prognosis and the effect of treatment. *Int Ophthalmol*, 15(1), 15-20.
- Sofi, F., Marcucci, R., Bolli, P., Giambene, B., Sodi, A., Fedi, S., et al. (2008). Low vitamin B6 and folic acid levels are associated with retinal vein occlusion independently of homocysteine levels. *Atherosclerosis*, 198(1), 223-227.
- Stahl, A., Agostini, H., Hansen, L. L., & Feltgen, N. (2007). Bevacizumab in retinal vein occlusion-results of a prospective case series. *Graefes Arch Clin Exp Ophthalmol*, 245(10), 1429-1436.
- Story, J. L., Held, K. S., Harrison, J. M., Cleland, T. P., Eubanks, K. D., & Brown, W. E., Jr. (1995). The ocular ischemic syndrome in carotid artery occlusive disease: ophthalmic color Doppler flow velocity and electroretinographic changes following carotid artery reconstruction. *Surg Neurol*, 44(6), 534-535.
- Stowe, G. C., 3rd, Zakov, Z. N., & Albert, D. M. (1978). Central retinal vascular occlusion associated with oral contraceptives. *Am J Ophthalmol*, 86(6), 798-801.
- Sturrock, G. D., & Mueller, H. R. (1984). Chronic ocular ischaemia. *Br J Ophthalmol*, 68(10), 716-723.
- Sullivan, K. L., Brown, G. C., Forman, A. R., Sergott, R. C., & Flanagan, J. C. (1983). Retrobulbar anesthesia and retinal vascular obstruction. *Ophthalmology*, 90(4), 373-377.
- Susac, J. O., Egan, R. A., Rennebohm, R. M., & Lubow, M. (2007). Susac's syndrome: 1975-2005 microangiopathy/autoimmune endotheliopathy. *J Neurol Sci*, 257(1-2), 270-272.
- Takaki, Y., Nagata, M., Shinoda, K., Tatewaki, S., Yamada, K., Matsumoto, C. S., et al. (2008). Severe acute ocular ischemia associated with spontaneous internal carotid artery dissection. *Int Ophthalmol*, 28(6), 447-449.
- Taubert, M., Dowd, T. C., & Wood, A. (2008). Malnutrition and bilateral central retinal vein occlusion in a young woman: a case report. *J Med Case Reports*, 2, 77.

- Theoulakis, P. E., Livieratou, A., Petropoulos, I. K., Lepidas, J., Brinkmann, C. K., & Katsimpris, J. M. (2010). Cilioretinal artery occlusion combined with central retinal vein occlusion - a report of two cases and review of the literature. *Klin Monbl Augenheilkd*, 227(4), 302-305.
- Torres, R. J., Luchini, A., Weis, W., Frecceiro, P. R., & Casella, M. (2005). Combined central retinal vein and artery occlusion after retrobulbar anesthesia--report of two cases. *Arq Bras Oftalmol*, 68(2):257-61.
- Turut, P., & Malthieu, D. (1986). [Failure of laser photocoagulation in ischemic retinopathy associated with carotid occlusion]. *Bull Soc Ophthalmol Fr*, 86(11), 1297-1299.
- Van Winden, M., & Salu, P. (2010). Branch retinal artery occlusion with visual field and multifocal erg in Susac syndrome: a case report. *Doc Ophthalmol* 121(3):223-9.
- Vignes, S., Wechsler, B., Elmaleh, C., Cassoux, N., Horellou, M. H., & Godeau, P. (1996). Retinal arterial occlusion associated with resistance to activated protein C. *Br J Ophthalmol*, 80(12), 1111.
- von Graefe, A. (1859). Ueber Embolie der Arteria centralis retinae als Ursache plotzlicher Erblindung. *Albrecht Von Graefes Arch Ophthalmol*, 5, 136-157.
- Wardlaw, J. M., Chappell, F. M., Best, J. J., Wartolowska, K., & Berry, E. (2006). Non-invasive imaging compared with intra-arterial angiography in the diagnosis of symptomatic carotid stenosis: a meta-analysis. *Lancet*, 367(9521), 1503-1512.
- Weger, M., Stanger, O., Deutschmann, H., Leitner, F. J., Renner, W., Schmut, O., et al. (2002). The role of hyperhomocysteinemia and methylenetetrahydrofolate reductase (MTHFR) C677T mutation in patients with retinal artery occlusion. *Am J Ophthalmol*, 134(1), 57-61.
- Weinberg, D., Dodwell, D. G., & Fern, S. A. (1990). Anatomy of arteriovenous crossings in branch retinal vein occlusion. *Am J Ophthalmol*, 109(3), 298-302.
- Weinberger, A. W., Siekmann, U. P., Wolf, S., Rossaint, R., Kirchhof, B., & Schrage, N. F. (2002). [Treatment of Acute Central Retinal Artery Occlusion (CRAO) by Hyperbaric Oxygenation Therapy (HBO)--Pilot study with 21 patients]. *Klin Monbl Augenheilkd*, 219(10), 728-734.
- Wenzler, E. M., Rademakers, A. J., Boers, G. H., Cruysberg, J. R., Webers, C. A., & Deutman, A. F. (1993). Hyperhomocysteinemia in retinal artery and retinal vein occlusion. *Am J Ophthalmol*, 115(2), 162-167.
- Werner, M. S., Latchaw, R., Baker, L., & Wirtschafter, J. D. (1994). Relapsing and remitting central retinal artery occlusion. *Am J Ophthalmol*, 118(3), 393-395.
- Wild, S., Roglic, G., Green, A., Sicree, R., & King, H. (2004). Global prevalence of diabetes: estimates for the year 2000 and projections for 2030. *Diabetes Care*, 27(5), 1047-1053.
- Williamson, T. H. (1997). Central retinal vein occlusion: what's the story? *Br J Ophthalmol*, 81(8), 698-704.
- Wong, T. Y., & Klein, R. (2002). Retinal arteriolar emboli: epidemiology and risk of stroke. *Curr Opin Ophthalmol*, 13(3), 142-146.
- Younge, B. R. (1989). The significance of retinal emboli. *J Clin Neuroophthalmol*, 9(3), 190-194.



Advances in Ophthalmology

Edited by Dr Shimon Rumelt

ISBN 978-953-51-0248-9

Hard cover, 568 pages

Publisher InTech

Published online 07, March, 2012

Published in print edition March, 2012

This book focuses on the different aspects of ophthalmology - the medical science of diagnosis and treatment of eye disorders. Ophthalmology is divided into various clinical subspecialties, such as cornea, cataract, glaucoma, uveitis, retina, neuro-ophthalmology, pediatric ophthalmology, oncology, pathology, and oculoplastics. This book incorporates new developments as well as future perspectives in ophthalmology and is a balanced product between covering a wide range of diseases and expedited publication. It is intended to be the appetizer for other books to follow. Ophthalmologists, researchers, specialists, trainees, and general practitioners with an interest in ophthalmology will find this book interesting and useful.

How to reference

In order to correctly reference this scholarly work, feel free to copy and paste the following:

Mario Bradvica, Tvrtka Benašić and Maja Vinković (2012). Retinal Vascular Occlusions, *Advances in Ophthalmology*, Dr Shimon Rumelt (Ed.), ISBN: 978-953-51-0248-9, InTech, Available from: <http://www.intechopen.com/books/advances-in-ophthalmology/retinal-vascular-occlusions>

INTech
open science | open minds

InTech Europe

University Campus STeP Ri
Slavka Krautzeka 83/A
51000 Rijeka, Croatia
Phone: +385 (51) 770 447
Fax: +385 (51) 686 166
www.intechopen.com

InTech China

Unit 405, Office Block, Hotel Equatorial Shanghai
No.65, Yan An Road (West), Shanghai, 200040, China
中国上海市延安西路65号上海国际贵都大饭店办公楼405单元
Phone: +86-21-62489820
Fax: +86-21-62489821

© 2012 The Author(s). Licensee IntechOpen. This is an open access article distributed under the terms of the [Creative Commons Attribution 3.0 License](https://creativecommons.org/licenses/by/3.0/), which permits unrestricted use, distribution, and reproduction in any medium, provided the original work is properly cited.

IntechOpen

IntechOpen