

We are IntechOpen, the world's leading publisher of Open Access books Built by scientists, for scientists

6,900

Open access books available

185,000

International authors and editors

200M

Downloads

Our authors are among the

154

Countries delivered to

TOP 1%

most cited scientists

12.2%

Contributors from top 500 universities



WEB OF SCIENCE™

Selection of our books indexed in the Book Citation Index
in Web of Science™ Core Collection (BKCI)

Interested in publishing with us?
Contact book.department@intechopen.com

Numbers displayed above are based on latest data collected.
For more information visit www.intechopen.com



Mini Invasive Treatments in Acute Biliary Pancreatitis

Juan Carlos Barbella, Diego L. Dip,
Anzorena Francisco Suarez, Jorge Dodera and Emiliano Monti
*Buenos Aires University,
Argentina*

1. Introduction

Gallstone disease is one of the most common causes of acute pancreatitis. There are two accepted mechanisms regarding its pathogenesis: reflux of bile into the pancreatic duct and transient ampullary obstruction in the ampulla ¹.

Although most episodes are mild and resolve spontaneously, severe pancreatitis with local and systemic complications may lead to death ². It is uncertain whether gallstones initiate or also maintain biliary pancreatitis ³.

Since the advent of endoscopic retrograde cholangiopancreatography (ERCP) in 1974, it has replaced conventional surgery with the T-tube as the treatment of choice for common bile duct stones, reducing complications and shortening recovery time.

It is also used to treat a variety of pancreaticobiliary diseases such as biliary strictures, stone removal, and biliary leaks.

This chapter will review the role of endoscopy in acute gallstone pancreatitis and some of its complications.

2. The role of endoscopy in acute gallstone pancreatitis

2.1 Technique

ERCP is performed with a side-viewing duodenoscope, reaching the ampulla of Vater. The bile duct is cannulated selectively under fluoroscopic guidance. There are different cannulation techniques, such as the use of a standard catheter or sphincterotome (Cotton-Cannulatome II PC Double Lumen Sphincterotome Cook-Medical), guidewire assistance, or a needle knife.

2.2 ERCP in acute gallstone pancreatitis

The management of acute gallstone pancreatitis has been controversial and the major debate has been whether the endoscopic treatment of acute gallstone pancreatitis ameliorates or exacerbates the disease.⁴

One of the most discussed issues in the investigation of acute pancreatitis has been whether enrolled patients would benefit from ERCP, with or without sphincterotomy, and whether it is possible to determine in which cases it would be beneficial.

Increases in serum bilirubin, alkaline phosphatase and/or gamma-glutamyl transferase, and persistent dilatation of the common bile duct ⁵, suggest that gallstones are the cause of the pancreatic inflammation.

In the majority of patients with mild biliary pancreatitis, bile duct stones have already passed to the duodenum by the time cholangiography is considered, so routine ERCP would be unnecessary ⁶; the prevalence of residual choledocholithiasis is less than 30% ⁷.

Thus, patients with resolving mild acute pancreatitis can undergo laparoscopic cholecystectomy with intraoperative cholangiography, and any remaining bile duct stones can be dealt with by postoperative or intraoperative ERCP ⁸. During the last years, several studies have reported that the indication for ERCP has changed from being a diagnostic tool to a therapeutic procedure ^{9 10}, avoiding the risk of complications.

Abdominal ultrasound, magnetic resonance (MR) and endosonography are the imaging techniques of choice.

Although the value of ultrasound is limited due to its low sensitivity, its specificity is high. Dilation of the common bile duct alone is neither sensitive nor specific for the detection of common bile duct stones ⁸.

MR is known to miss small gallstones 6 mm ¹. The latter are the most frequent cause of acute pancreatitis. Limitations of magnetic resonance imaging include the difficulty in performing this procedure in critically ill or uncooperative patients, and its contraindications such as the presence of pacemakers ⁸. In these cases it is advisable to perform a biliary endosonography, with a positive predictive value of 91% to 100% in detecting bile duct stones ⁷.

EUS is generally considered to be the most accurate method.

Persistent biliary obstruction worsens the outcome and increases the severity of acute pancreatitis. When tests clearly show an alteration in liver function, with images compatible with common bile duct stones, it is undoubtedly advisable to perform endoscopic sphincterotomy and stone removal. Biliary drainage is necessary when bile drainage is incomplete because cholestasis predisposes the patient to cholangitis ^{9 11}.

Routine ERCP should be avoided in patients with low to intermediate suspicion of retained bile duct stones and who are planned to have cholecystectomy ⁸.

2.3 Acute gallstone pancreatitis at the time of admission

Wirsung duct hypertension and the migration gallstone theory

One of the most prominent theories on the pathophysiology of acute pancreatitis is the common pathway and gallstone migration ¹². In 1974 Acosta et al demonstrated the association between gallstone disease and acute pancreatitis. Gallstones were found in the feces of 34 out of 36 patients with pancreatitis ¹³. Transient obstruction of the ampulla of Vater increases pancreatic duct pressure and activates digestive enzymes ¹¹.

Currently, most authors agree that transient obstruction by a migrating gallstone initiates pancreatitis. There is no consensus on the effects that follow stone impaction and the development of pancreatic inflammation. Some studies have questioned the relationship between duration of obstruction and severity of pancreatitis. A randomized trial in 61 patients reported by Acosta et al in 2006 demonstrated that duration of ductal obstruction is a critical factor in determining severity.¹⁴

2.4 Early decompression of the wirsung duct – ERCP

As a result of the theories proposed for the onset of acute pancreatitis, different studies have questioned the benefit of early decompression of the ampulla of Vater.

There are several randomized studies that compare patients receiving either early endoscopic intervention (EEI) within 72 hours after admission or early conservative management (ECM)^{15 14}, and which show contradictory conclusions^{16 17 3}.

A study conducted in Hong Kong by Fan et al included 195 patients with acute pancreatitis: 97 patients underwent ERCP within 24 hours after admission, and 98 received initial conservative treatment. Complications occurred in 18% of patients receiving early ERCP and in 29% of those receiving conservative treatment. The authors concluded that early ERCP is safe and effective in reducing the incidence of biliary sepsis, but removal of stones from the ampulla or from the common bile duct does not completely reverse the damage already done to the pancreas during the first hours or days of the illness¹⁷. Fan et al and Neoptolemos et al demonstrated a significantly lower rate of complications in patients who had predicted severe pancreatitis and underwent early ERCP^{16 17}.

In a study performed in Germany in 1997, Folsch et al randomized 126 patients to early ERCP and 112 to conservative treatment. This was a 22-institution multicenter prospective trial, which excluded patients with jaundice or cholangitis. Complications were similar in the two compared groups, but patients in the ERCP group had more respiratory failure. Because the authors found no explanation for this difference, they concluded that early ERCP and papillotomy were not beneficial³.

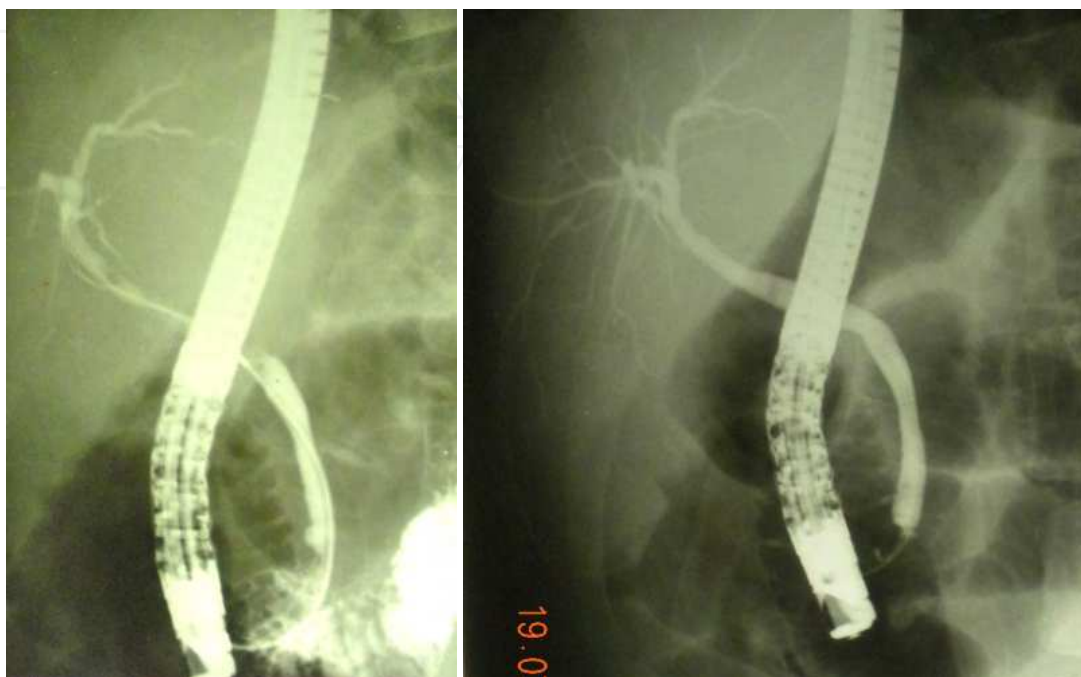
A meta-analysis carried out in the USA in 1999 by Sharman and Colin reported statistically significantly fewer overall complications and reduced mortality in patients with acute pancreatitis treated with ERCP + sphincterotomy compared with those treated conservatively. The role of ERCP + ES in patients with mild gallstone pancreatitis should be further evaluated in a large prospective RCT. ERCP + ES should be recommended for all patients with acute biliary pancreatitis and may be particularly beneficial in those with severe disease.

ERCP may not be necessary or beneficial in patients with low likelihood of biliary obstruction¹⁸.

In 2006, Oria et al randomized 103 patients to receive either EEI (n =51) or ECM (n = 52). Their study failed to provide evidence that EEI benefits patients with acute gallstone pancreatitis.

In 2008, Petrov et al conducted a meta-analysis in 450 patients. The results showed that early ERCP in patients with predicted mild and predicted severe ABP without acute cholangitis did not lead to a significant reduction in the risk of overall complications and mortality¹.

One of the most important points is proper patient selection. Larger prospective studies are needed to determine the correct value of ERCP in acute gallstone pancreatitis. Finally, there is no consensus as to which patients should be treated within 72 hours or later. In conclusion, ERCP in acute gallstone pancreatitis is still controversial, except when there is associated cholangitis.



Stone removal with a Dormia Basket.

Figs. 1 – 2. ERCP in acute gallstone pancreatitis

2.5 Cholangitis and acute gallstone pancreatitis

Biliary drainage is indicated within 24h of admission for patients with cholangitis (fever, abdominal pain and jaundice, the classic Charcot's triad) ⁸.

Clinical presentation ranges from a mild, self-limited process to a serious, life-threatening condition ¹⁹. The most frequent symptoms are fever in 90%, jaundice in 60% and abdominal pain in 70% of cases. It can be associated with hypotension and altered mental status, the so-called Reynold's Pentad Syndrome ²⁰.

Historically, surgery was the treatment of choice.

Currently, endoscopic retrograde cholangiopancreatography is the gold standard treatment.

There are several methods to perform ERCP endoscopy, sphincterotomy with or without stent placement, or nasobiliary drainage placement. The latter has advantages in that it can be washed and bile culture can be done, but has the disadvantage of patient discomfort ²¹.

Biliary obstruction promotes bacterial colonization and infection. The most common organisms are *E. coli*, *Enterococcus* and *Klebsiella*. Biliary obstruction is necessary but not sufficient to cause cholangitis. Partial obstruction is associated with a higher rate of infection than complete obstruction.

It is essential to perform early diagnosis and deliver prompt treatment ¹⁹, which should initially include medical therapy, antibiotics and supportive medical care, followed by biliary decompression. The delay or failure in early recognition of cholangitis may be fatal.

An endoscopic biliary stent should be placed if bile duct stones cannot be removed, so as to ensure proper drainage of the bile duct.

Twenty to 40 ml of bile should be aspirated to provide a sample of bile for microbiologic analysis, and adopt the most suitable antibiotic therapy. Endoscopic treatment can only involve stone removal with or without biliary stents, or with a nasobiliary catheter. Stents can be placed in different sizes, from 8.5 to 10 French, and their length shall depend on the length of the bile duct. Several studies have demonstrated no difference in treatment outcomes between biliary stenting and nasobiliary catheter drainage ^{22 23}.

Biliary stents are temporary and are removed after 30 days.

2.5.1 Post ERCP pancreatitis

ERCP complications are pancreatitis, hemorrhage, perforation, cholangitis and cholecystitis. The overall rate of complications is 9.8% ²⁴. The most frequent is pancreatitis. Young age, a history of pancreatitis, and sphincter of Oddi dysfunction, are risk factors. Thus, the technique and the experience of the endoscopist are important. The mechanisms underlying pancreatitis include intraductal pressure due to overinjection and papillary edema. ²⁵.

Criteria to define ERCP pancreatitis are: acute pain and tenderness in the upper abdomen, elevated pancreatic enzyme levels in blood, and radiologic abnormalities characteristic of acute pancreatitis.

Pancreatitis post ERCP should be classified according to Cotton's staging ⁶.

Although there has been controversy regarding the use of pre-cut sphincterotomy, a recent meta-analysis by Cennamo et al showed that pre-cut implementation reduces post-ERCP pancreatitis risk ²⁶.

3. Endoscopic treatment of pancreatic pseudocyst

3.1 Introduction

Pancreatic pseudocysts are organized collections of enzyme-rich fluid after an acute pancreatitis, an exacerbation of chronic pancreatitis, or pancreatic trauma ²⁷. They can be associated with necrotizing pancreatitis in between 2% and 50% of cases ²⁸.

Spontaneous resolution rate is 30% to 50% after a period of 6 weeks.

Pseudocysts larger than 6 cm and persistent more than 6 weeks should be drained.

Two thirds are located in the head of the pancreas ²⁸.

Infection of the pseudocyst results in a pancreatic abscess that can progress to sepsis, so early recognition and prompt intervention are necessary. ²⁷.

Surgical management is performed by internal drainage by cystenteric anastomosis, either in the form of a cystgastrostomy, cystduodenostomy, or cystjejunostomy ²⁹.

The major advantage of endoscopic drainage over surgical drainage is minimal invasiveness, which reduces the duration of hospital stay and improves patient tolerance ³⁰.

Endoscopic transmural drainage is a minimally invasive alternative to surgery ³¹. The approach is to create a fistula between the pancreatic collection and the digestive tract. It is a proven treatment and can be performed via a transpapillary and/or transmural approach. The transgastric route is the most preferred.

The risk of perforation is high when luminal compression is not visible at endoscopy ³¹.

The introduction of endoscopic ultrasonography has allowed a proper selection of the puncture sites, avoiding major gastric vessels and adjacent structures ³².

Morbidity mainly consists of bleeding, infection, and perforation.

Bleeding is the most frequent complication ²⁸

3.2 Technique

It is very important that the pseudocyst be in close approximation to the enteric wall (less than 1 cm).

The first step is to search for a luminal compression in the stomach or in the duodenum by using the duodenoscope.

When the cyst is not found to bulge, which occurs in almost 50% of cases, endoscopic ultrasound may be used for localization and evaluation of the distance between the two structures and identification of interposed vessels ²⁹.

When a luminal compression is identified, a needle-knife catheter is used to puncture and access the pseudocyst. After access, a 0.035-inch guidewire (Tracer Metro Direct Wilson-Cook Medical) is coiled within the pseudocyst and dilation of the fistula is performed using a 15 mm balloon dilator (CRE balloon; Microvasive) under fluoroscopic guidance.

There are several devices that are used to puncture the gastric or duodenal wall to enter into the cyst cavity³⁰. Once inside the pseudocyst, the pancreatic necrosis is removed with a Dormia Basket (Cook Medical WEB-2X4-2X6).

In a randomized trial, Varadarajulu et al demonstrated that success rate of transmural drainage of pancreatic pseudocysts was higher when performed under endosonography guidance. The authors concluded it should be considered as the first-line treatment.

4. Percutaneous approach in necrotizing biliary pancreatitis

4.1 Introduction

About 20% of patients with acute pancreatitis develop pancreatic necrosis associated or not with peri pancreatic necrosis ³³. This is one of the most feared complications of acute pancreatitis due to its high morbidity and mortality. Infection of pancreatic necrosis naturally develops during the second phase of the disease (most commonly in the 2nd and 3rd week after the onset of symptoms) and has been reported in as many as 40–70% of

patients with necrotizing pancreatitis. The risk of infection increases with the extent of intra- and extra-pancreatic necrosis ³⁴. It is crucial to know whether the necrosis is infected or not, since this will determine which treatment is to be performed.

When fever, leukocytosis, and unexpected deterioration appear, infection is suspected¹¹.

Infected pancreatic necrosis necessitates surgical debridement, while sterile necrosis is managed best non-operatively (Fig 3.) Infected necrosis constitutes an absolute indication for prompt intervention.

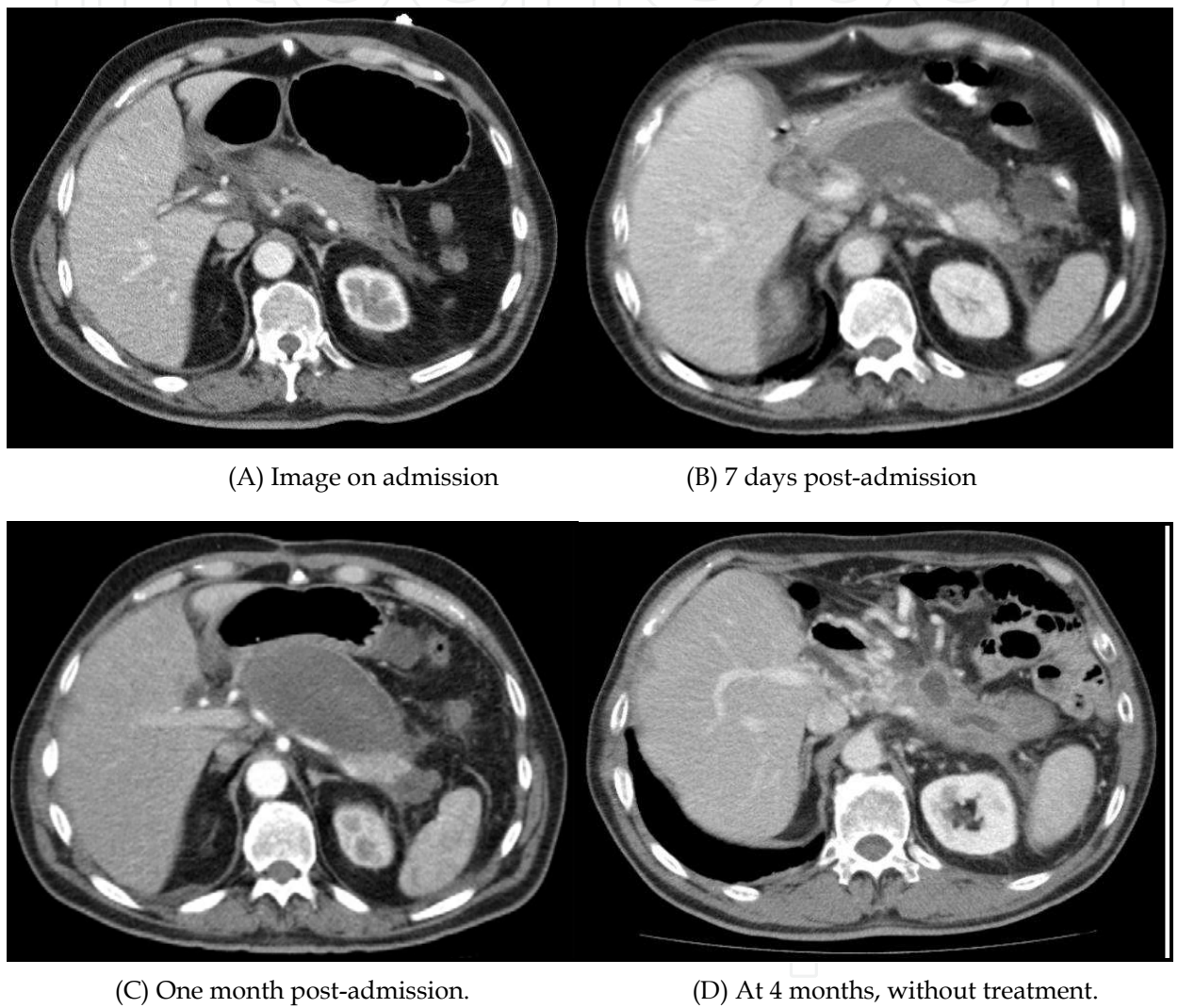


Fig. 3. Conservative treatment.

Until recently, the first-choice intervention in infected necrotizing pancreatitis was surgical necrosectomy by laparotomy. This approach is associated with considerable morbidity (34–95%) and mortality (11–39%) ³³.

In 1998, Freeny et al published a series of patients who were treated primarily with imaging-guided percutaneous catheter drainage.

Since Van Sonnenberg and D'agostino et al's first reports, intervention strategies in acute pancreatitis have been used for over fifteen years in patients not amenable to surgical treatment.

There are various techniques of necrosectomy: surgical, endoscopic and endoscopic necrosectomy. Treatments are multidisciplinary and tend to be conservative.

Retroperitoneoscopy, endoscopy and laparoscopy are minimally invasive techniques and have prompted the use of mini-invasive or step-up treatment strategies.

Both surgical and percutaneous drainage are associated with a significant risk of pancreatico-cutaneous fistula formation³⁵.

This chapter will address only percutaneous necrosectomy

Percutaneous treatments for resolution of the complications of acute pancreatitis

- Ultrasound-guided diagnostic puncture.
- CT-guided diagnostic puncture.
- Single or multiple percutaneous drainage under ultrasound guidance.
- Single or multiple percutaneous drainage with CT guidance.
- Replacement of catheters up to 30 Fr with fluoroscopic guidance.
- Retroperitoneal lavage under fluoroscopic guidance.
- Retroperitoneoscopy under fluoroscopic guidance.
- Catheter replacement under fluoroscopic guidance.

Infected pancreatic necrosis is uniformly fatal if untreated and even after aggressive surgical intervention ³⁶

The time point for surgical or interventional procedures has changed in the last years. Mortality rate of patients undergoing early surgical necrosectomy reached 65%. Ideally, necrosectomy should be performed on day 30 after onset of symptoms. Delayed necrosectomy allows demarcation of the necrotic tissue ³⁷. One of the most difficult tasks is choosing the right time for intervention.

The evolution and advances in radiologic imaging and new developments of interventional radiology have demonstrated the advantages of mini-invasive treatment.

Percutaneous treatment in severe acute pancreatitis is directed at addressing local complications, such as abscesses, peripancreatic collections and infected necrosis, to postpone surgical intervention or even to obviate the need for surgical necrosectomy³³.

Percutaneous endoscopic necrosectomy requires insertion of a catheter under CT guidance into the necrotic retroperitoneal collection. The drain tract is dilated to 28 to 30 F to allow piecemeal necrosectomy at multiple endoscopic sessions with acceptable success and mortality rates ³⁸.

The procedure is best suited for the stable patient but can be attempted in the critically ill patient as well ³⁹.

In addition to catheter debridement, these patients also require care from a multidisciplinary team involving collaboration by internists and surgeons, as well as interventional radiologists, to manage their complex clinical picture ³⁶.

4.2 Fine needle aspiration

Elevations in white blood count and temperature occur in both sterile and infected necrosis. Hence, it is not possible to distinguish these conditions clinically unless CT scan shows evidence of air in the retroperitoneum, but this is a rare findings^{40 41 42}.

The use of FNA is controversial. It has been the practice of some authors to advocate early FNA to identify infection and determine which patients will benefit from necrosectomy.

Treatment strategies based on the presence of infection have led to the widespread advocacy for early fine needle aspiration (FNA) of the necrotic pancreas^{37,41,43}.

FNA can be guided by either computed tomography or ultrasonography and should be performed in patients who develop significant pancreatic necrosis and clinical signs of sepsis.

Bacterial tests including gram staining and culture of the aspiration material have a diagnostic sensitivity and specificity of 88 and 90%, respectively.

It is important that only those patients who develop clinical signs of sepsis should undergo FNA, since the procedure bears a potential risk of secondary infection^{34,37,44}.

Haney, Pappas et al. consider that clinical presentation is sufficient to make an operative determination. They argue that to examine the appropriate role of FNA, one must consider the timing of surgical intervention. Although early necrosectomy was once advocated, numerous more recent studies have confirmed that delayed surgical intervention is associated with better outcomes. The current consensus is for delayed surgical intervention, even in the setting of infected necrosis^{37,41}.

The critical argument against routine FNA, then, is that during this delay, the clinical course of the patient will readily predict who will need debridement and who will not⁴¹.

4.3 Ultrasound – Guided puncture

This procedure is performed in patients in poor general condition in intensive care units with progressive deterioration of their general condition and suspected infected collection.

The puncture approach depends on the ultrasound, and should be performed using the best acoustic window possible. The needles used in the procedure are thin because they are only for diagnostic purposes.

When the puncture yields purulent fluid percutaneous drainage can be placed following the Seldinger technique.

4.4 CT guided puncture

It is performed in patients with progressive deterioration of general condition and suspected infected pancreatic fluid collection. An advantage of CT guided puncture is that it can be performed by different approaches: anterior, posterior, right or left lateral, or transgastric, according to the location of collections.

It is the method of choice in the presence of abdominal distention and deep fluid collection.

The aim of the procedure is to extract as much necrotic tissue as possible.

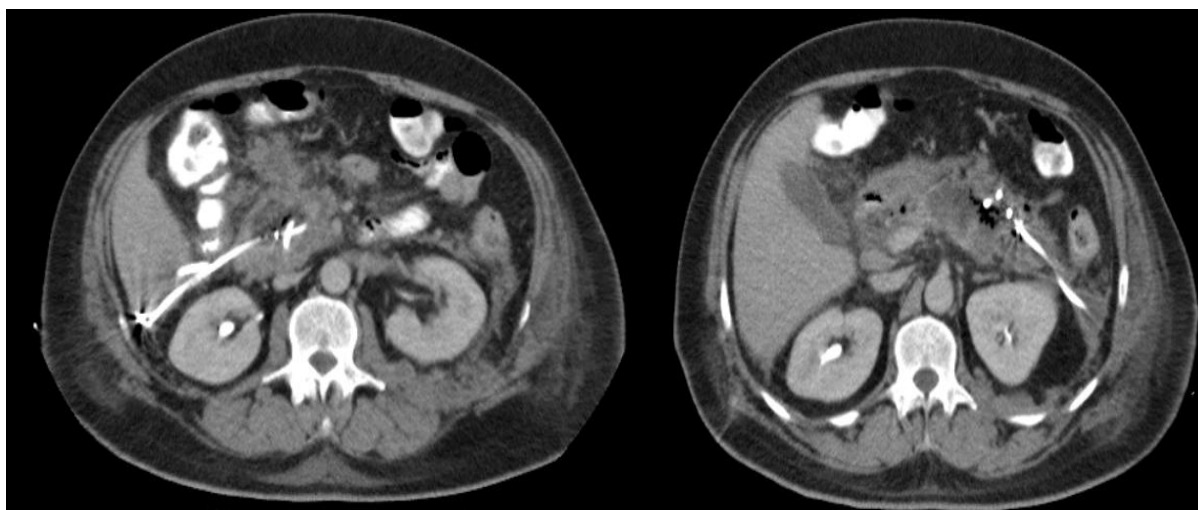Catheters are removed when cavity size is small at fluoroscopy, no collection is noted on scan tomography, and catheter output has decreased to 15-30 mL per day.

4.5 Placement of drains

The placement of drains with ultrasound or CT guidance depends on the usage and customs of each operator. Undoubtedly, in the presence of abdominal distention and deep fluid collection the method of choice is computer-tomography guided puncture.

Indication for the procedure is the presence of infection in the collection that has been confirmed either by the presence of pus or a positive culture from the puncture.

Drainage site selection depends on the location of the infected collections; this decision can be made at the time of drainage or during the course of treatment. The size and number of catheters depends on the consistency of content and its location. Eight Fr or 8.5 Fr catheters can be used initially and be replaced with catheters up to 30 Fr; this replacement can be performed with fluoroscopic guidance.



(A) Right lateral drainage

(B) Left lateral drainage

Fig. 4.

4.6 Replacement of catheters up to 30 Fr with fluoroscopic guidance

It is important to assess the effectiveness of drainage catheters. When there are poor drainage areas, larger caliber drainage catheters up to 30 Fr can be placed under fluoroscopic guidance. They should be examined constantly according to the patient's clinical course and washed with saline when necessary. Performing a sonogram is useful. Dye is injected through the catheter; drainage catheters are considered sufficiently effective if the dye is evacuated completely leaving no residue.

When debris or poor drainage persists, the procedure should be attempted using catheters of increasing caliber, to reach 30 Fr diameter. A rigid Amplatz-type guidewire is placed through the existing catheter using the set of Amplatz dilators up to 30 Fr. The catheters are then fixed following the regular technique and can be flushed with saline solution when necessary.

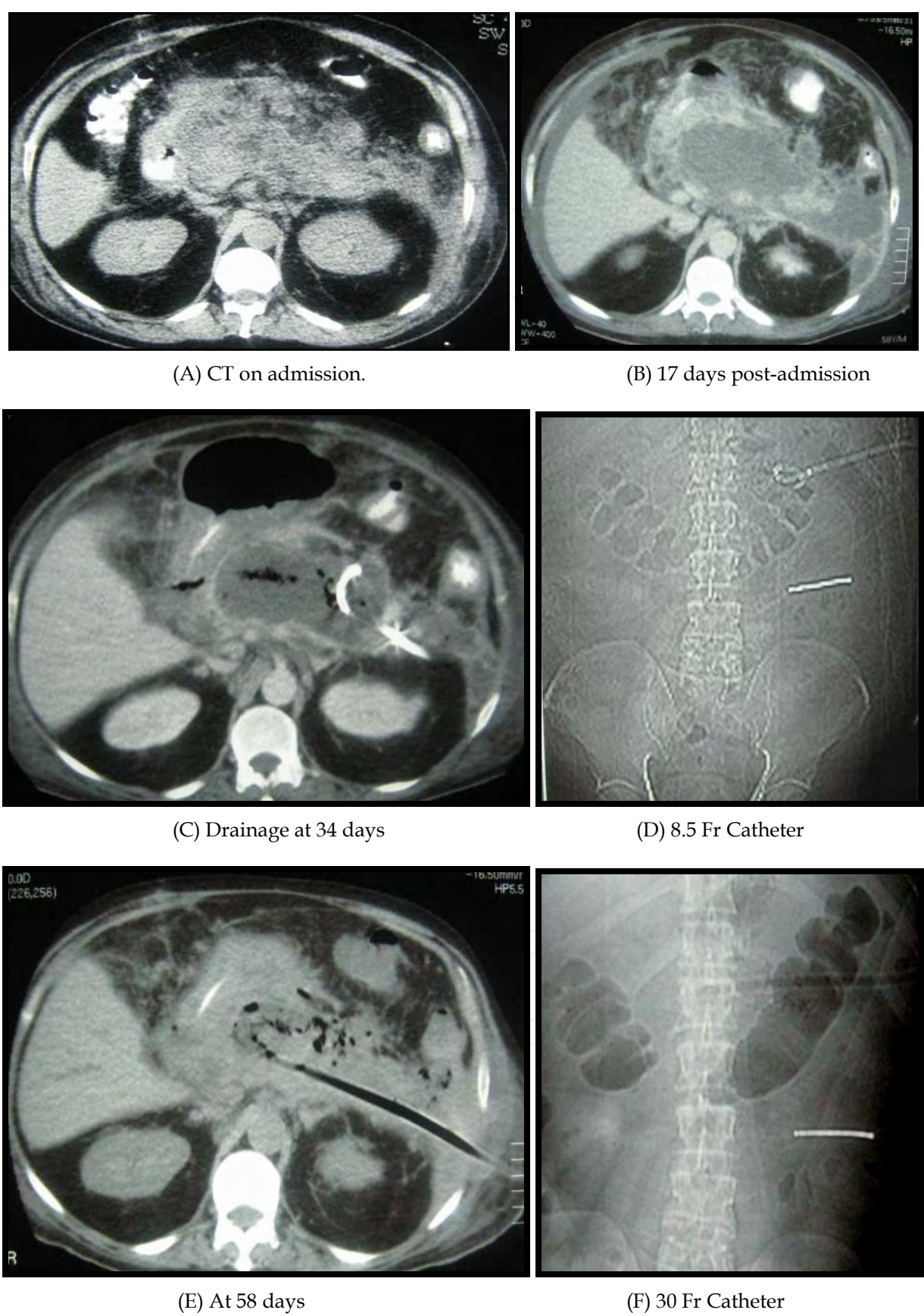


Fig. 5.

4.7 Multiple percutaneous Catheter Technique

Multiple catheters are often used simultaneously (Fig 5). One to five 10 to 16 Fr catheters are inserted under CT guidance into the pancreatic necrotic tissue. Aggressive irrigation is performed with saline when necessary, while the debris is removed by syringe suction. Lavage fluid is injected to fill the cavity and aspirated until all fluid is removed. When the catheter becomes occluded, it is removed under syringe suction ³⁶.

Stone baskets are used to remove large pieces of debris. This is repeated until the fluid becomes clear. Finally, a self-retaining catheter is left in the drainage cavity. The session is repeated 2 to 3 times per week ³⁹. The aim of the procedure is to extract as much necrotic tissue as possible.

All patients receive intravenous antibiotics appropriate to the organism grown in culture of the pancreatic fluid.

Catheters are removed when cavity size is small at fluoroscopy, no collection is noted on scan tomography, and catheter output has decreased to 15-30 mL per day.

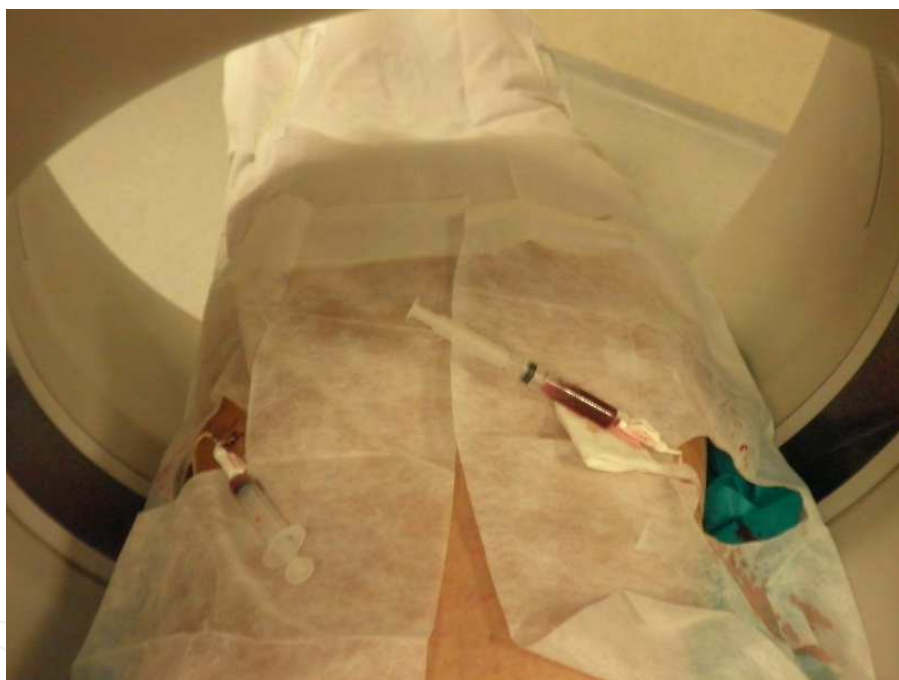

Fig. 6. Multiple drainage performed under CT scan guidance

4.8 Retroperitoneoscopy under fluoroscopic guidance

When collection persists after drainage, catheters can be replaced under fluoroscopic guidance. The procedure is performed under sedation following the Seldinger technique. A nephroscope equipped with two channels for viewing the inside the pancreatic collection is used. It is placed with a video camera connected to a monitor, and tweezers are inserted through the working-channel to remove necrotic and devitalized tissue. The major risk is hemorrhage. It is useful to perform the procedure under direct vision and fluoroscopic guidance, to view how far the ureteroscope has reached. On completion of the session, the necrotic cavity is flushed and a 30Fr catheter is inserted.

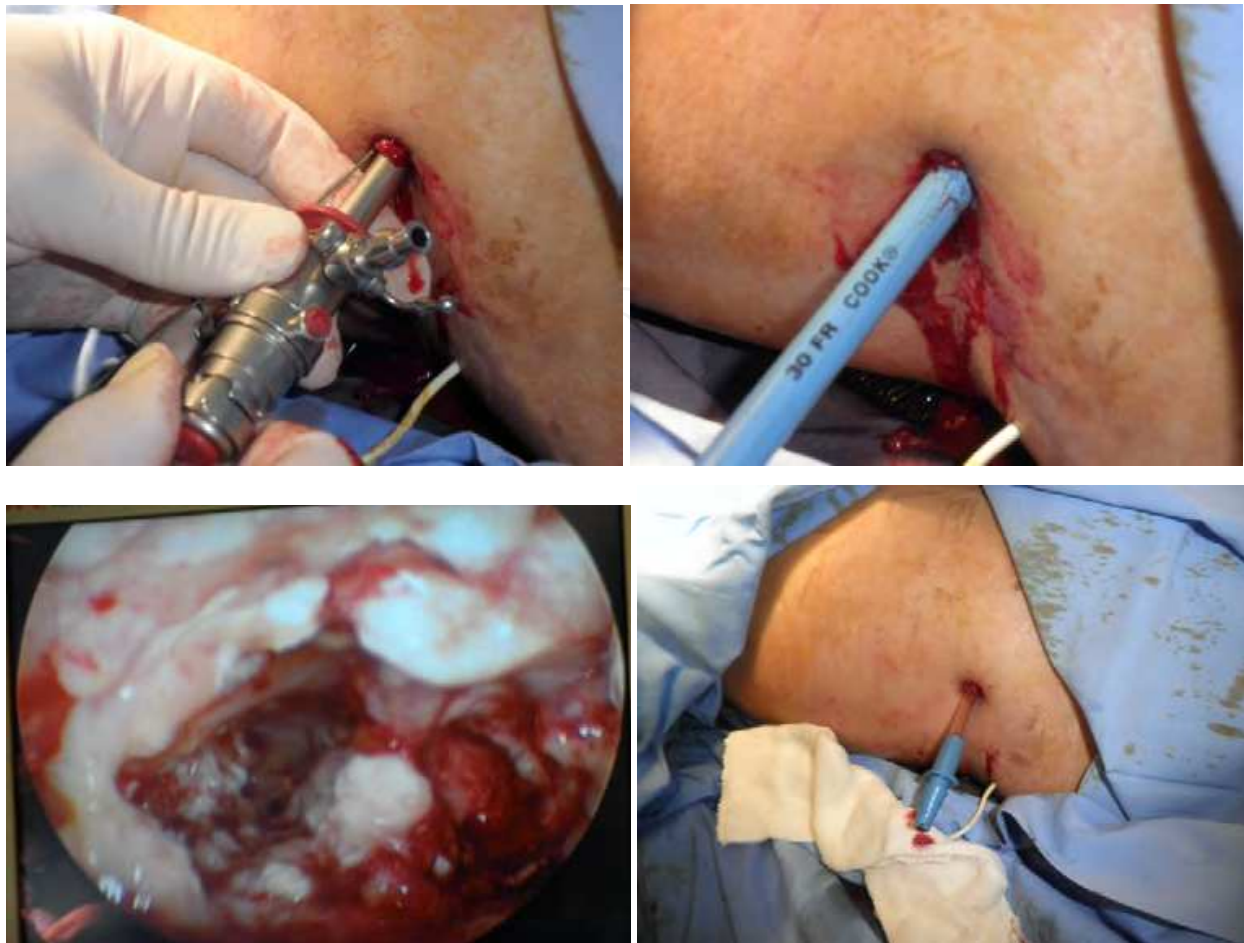

Fig. 7.

5. References

- [1] Petrov MS, van Santvoort HC, Besselink MG, van der Heijden GJ, van Erpecum KJ, Gooszen HG. Early endoscopic retrograde cholangiopancreatography versus conservative management in acute biliary pancreatitis without cholangitis: a meta-analysis of randomized trials. *Annals of surgery* 2008;247:250-7.
- [2] Cohen SA, Siegel JH. Endoscopic retrograde cholangiopancreatography and the pancreas: when and why? *Surg Clin North Am* 2001;81:321-8, x.
- [3] Folsch UR, Nitsche R, Ludtke R, Hilgers RA, Creutzfeldt W. Early ERCP and papillotomy compared with conservative treatment for acute biliary pancreatitis. The German Study Group on Acute Biliary Pancreatitis. *N Engl J Med* 1997;336:237-42.
- [4] Kozarek R. Role of ERCP in acute pancreatitis. *Gastrointest Endosc* 2002;56:S231-S6.
- [5] Roston AD, Jacobson IM. Evaluation of the pattern of liver tests and yield of cholangiography in symptomatic choledocholithiasis: a prospective study. *Gastrointest Endosc* 1997;45:394-9.
- [6] Cotton PB, Lehman G, Vennes J, et al. Endoscopic sphincterotomy complications and their management: an attempt at consensus. *YMGE* 1991;37:383-93.


- [7] Romagnuolo J, Currie G. Noninvasive vs. selective invasive biliary imaging for acute biliary pancreatitis: an economic evaluation by using decision tree analysis. *Gastrointest Endosc* 2005;61:86-97.
- [8] Banks PA, Freeman ML, Gastroenterology tPPCotACo. Practice Guidelines in Acute Pancreatitis. *Am J Gastroenterol* 2006;101:2379-400.
- [9] Canlas KR, Branch MS. Role of endoscopic retrograde cholangiopancreatography in acute pancreatitis. *World J Gastroenterol* 2007;13:6314-20.
- [10] Attasaranya S, Abdelaziz A, Lehman G. Endoscopic Management of Acute and Chronic Pancreatitis. *Surgical Clinics of North America* 2007;87:1379-402.
- [11] Whitcomb DC. Clinical practice. Acute pancreatitis. *N Engl J Med* 2006;354:2142-50.
- [12] Wang GJ, Gao CF, Wei D, Wang C, Ding SQ. Acute pancreatitis: etiology and common pathogenesis. *World J Gastroenterol* 2009;15:1427-30.
- [13] Acosta JM, Ledesma CL. Gallstone migration as a cause of acute pancreatitis. *N Engl J Med* 1974;290:484-7.
- [14] Acosta JM, Katkhouda N, Debian KA, Groshen SG, Tsao-Wei DD, Berne TV. Early Ductal Decompression Versus Conservative Management for Gallstone Pancreatitis With Ampullary Obstruction. *Annals of Surgery* 2006;243:33-40.
- [15] Oria A, Cimmino D, Ocampo C, et al. Early endoscopic intervention versus early conservative management in patients with acute gallstone pancreatitis and biliopancreatic obstruction: a randomized clinical trial. *Annals of surgery* 2007;245:10-7.
- [16] Neoptolemos JP, Carr-Locke DL, London NJ, Bailey IA, James D, Fossard DP. Controlled trial of urgent endoscopic retrograde cholangiopancreatography and endoscopic sphincterotomy versus conservative treatment for acute pancreatitis due to gallstones. *Lancet* 1988;2:979-83.
- [17] Fan ST, Lai EC, Mok FP, Lo CM, Zheng SS, Wong J. Early treatment of acute biliary pancreatitis by endoscopic papillotomy. *N Engl J Med* 1993;328:228-32.
- [18] Mark DH, Lefevre F, Flamm CR, Aronson N. Evidence-based assessment of ERCP in the treatment of pancreatitis. *Gastrointest Endosc* 2002;56:S249-S54.
- [19] Attasaranya S, Fogel EL, Lehman GA. Choledocholithiasis, Ascending Cholangitis, and Gallstone Pancreatitis. *Medical Clinics of North America* 2008;92:925-60.
- [20] Yusoff IF, Barkun JS, Barkun AN. Diagnosis and management of cholecystitis and cholangitis. *Gastroenterol Clin North Am* 2003;32:1145-68.
- [21] Park SY, Park CH, Cho SB, et al. The safety and effectiveness of endoscopic biliary decompression by plastic stent placement in acute suppurative cholangitis compared with nasobiliary drainage. *Gastrointest Endosc* 2008;68:1076-80.
- [22] Lee DW, Chan AC, Lam YH, et al. Biliary decompression by nasobiliary catheter or biliary stent in acute suppurative cholangitis: a prospective randomized trial. *Gastrointest Endosc* 2002;56:361-5.
- [23] Sharma BC, Kumar R, Agarwal N, Sarin SK. Endoscopic biliary drainage by nasobiliary drain or by stent placement in patients with acute cholangitis. *Endoscopy* 2005;37:439-43.
- [24] Freeman ML, Nelson DB, Sherman S, et al. Complications of endoscopic biliary sphincterotomy. *N Engl J Med* 1996;335:909-18.

- [25] Akashi R, Kiyozumi T, Tanaka T, Sakurai K, Oda Y, Sagara K. Mechanism of pancreatitis caused by ERCP. *Gastrointest Endosc* 2002;55:50-4.
- [26] Cennamo V, Fuccio L, Zagari RM, et al. Can early precut implementation reduce endoscopic retrograde cholangiopancreatography-related complication risk? Meta-analysis of randomized controlled trials. *Endoscopy* 2010;42:381-8.
- [27] Cannon JW, Callery MP, Vollmer CM, Jr. Diagnosis and management of pancreatic pseudocysts: what is the evidence? *J Am Coll Surg* 2009;209:385-93.
- [28] Barthet M, Lamblin G, Gasmi M, Vitton V, Desjeux A, Grimaud JC. Clinical usefulness of a treatment algorithm for pancreatic pseudocysts. *Gastrointest Endosc* 2008;67:245-52.
- [29] Bergman S, Melvin WS. Operative and nonoperative management of pancreatic pseudocysts. *Surg Clin North Am* 2007;87:1447-60, ix.
- [30] Reddy DN, Gupta R, Lakhtakia S, Jalal PK, Rao GV. Use of a novel transluminal balloon accessotome in transmural drainage of pancreatic pseudocyst (with video). *Gastrointest Endosc* 2008;68:362-5.
- [31] Varadarajulu S, Christein JD, Tamhane A, Drelichman ER, Wilcox CM. Prospective randomized trial comparing EUS and EGD for transmural drainage of pancreatic pseudocysts (with videos). *Gastrointest Endosc* 2008;68:1102-11.
- [32] Antillon MR, Shah RJ, Stiegmann G, Chen YK. Single-step EUS-guided transmural drainage of simple and complicated pancreatic pseudocysts. *Gastrointest Endosc* 2006;63:797-803.
- [33] Van Baal MC, van Santvoort HC, Bollen TL, Bakker OJ, Besselink MG, Gooszen HG. Systematic review of percutaneous catheter drainage as primary treatment for necrotizing pancreatitis. *The British journal of surgery* 2011;98:18-27.
- [34] Uhl W, Warshaw A, Imrie C, et al. IAP Guidelines for the Surgical Management of Acute Pancreatitis. *Pancreatology* 2002; 2:565-73.
- [35] Ross A, Gluck M, Irani S, et al. Combined endoscopic and percutaneous drainage of organized pancreatic necrosis. *Gastrointest Endosc* 2010;71:79-84.
- [36] Echenique AM, Sleeman D, Yrizarry J, et al. Percutaneous catheter-directed debridement of infected pancreatic necrosis: results in 20 patients. *J Vasc Interv Radiol* 1998;9:565-71.
- [37] Schneider L, Buchler MW, Werner J. Acute pancreatitis with an emphasis on infection. *Infect Dis Clin North Am* 2010;24:921-41, viii.
- [38] Fotoohi M, Traverso LW. Pancreatic necrosis: paradigm of a multidisciplinary team. *Adv Surg* 2006;40:107-18.
- [39] Sleeman D, Levi DM, Cheung MC, et al. Percutaneous lavage as primary treatment for infected pancreatic necrosis. *J Am Coll Surg* 2011;212:748-52; discussion 52-4.
- [40] Banks PA, Freeman ML. Practice guidelines in acute pancreatitis. *Am J Gastroenterol* 2006;101:2379-400.
- [41] Haney JC, Pappas TN. Necrotizing pancreatitis: diagnosis and management. *Surg Clin North Am* 2007;87:1431-46, ix.
- [42] Jury RP, Tariq N. Minimally invasive and standard surgical therapy for complications of pancreatitis and for benign tumors of the pancreas and duodenal papilla. *Med Clin North Am* 2008;92:961-82, x.

- [43] Wada K, Takada T, Hirata K, et al. Treatment strategy for acute pancreatitis. J Hepatobiliary Pancreat Sci 2010;17:79-86.
- [44] Cappell MS. Acute Pancreatitis: Etiology, Clinical Presentation, Diagnosis, and Therapy. Medical Clinics of North America 2008;92:889-923.

IntechOpen

IntechOpen



Pancreatitis - Treatment and Complications

Edited by Prof. Luis Rodrigo

ISBN 978-953-51-0109-3

Hard cover, 212 pages

Publisher InTech

Published online 02, March, 2012

Published in print edition March, 2012

Pancreatitis may be acute or chronic. Although they can be caused by similar aetiologies, they tend to follow distinct natural histories. Around 80% of acute pancreatitis (AP) diagnoses occur as secondary to gallstone disease and alcohol misuse. This disease is commonly associated with the sudden onset of upper abdominal that is usually severe enough to warrant the patient seeking urgent medical attention. Overall, 10 to 25% of AP episodes are classified as severe, leading to an associated mortality rate of 7 to 30%. Treatment is conservative and consists of general medical support performed by experienced teams, sometimes in ICUs. Although most cases of acute pancreatitis are uncomplicated and resolve spontaneously, the presence of complications has significant prognostic importance. Necrosis, hemorrhage, and infection convey rates of up to 25%, 50%, and 80% mortality, respectively. Other complications such as pseudocyst formation, pseudoaneurysm formation, or venous thrombosis increase morbidity and mortality to a lesser degree. The presence of pancreatic infection must be avoided.

How to reference

In order to correctly reference this scholarly work, feel free to copy and paste the following:

Juan Carlos Barbella, Diego L. Dip, Anzorena Francisco Suarez, Jorge Dodera and Emiliano Monti (2012). Mini Invasive Treatments in Acute Biliary Pancreatitis, *Pancreatitis - Treatment and Complications*, Prof. Luis Rodrigo (Ed.), ISBN: 978-953-51-0109-3, InTech, Available from: <http://www.intechopen.com/books/pancreatitis-treatment-and-complications/mini-invasive-treatments-in-acute-biliary-pancreatitis>

INTeCH
open science | open minds

InTech Europe

University Campus STeP Ri
Slavka Krautzeka 83/A
51000 Rijeka, Croatia
Phone: +385 (51) 770 447
Fax: +385 (51) 686 166
www.intechopen.com

InTech China

Unit 405, Office Block, Hotel Equatorial Shanghai
No.65, Yan An Road (West), Shanghai, 200040, China
中国上海市延安西路65号上海国际贵都大饭店办公楼405单元
Phone: +86-21-62489820
Fax: +86-21-62489821

© 2012 The Author(s). Licensee IntechOpen. This is an open access article distributed under the terms of the [Creative Commons Attribution 3.0 License](https://creativecommons.org/licenses/by/3.0/), which permits unrestricted use, distribution, and reproduction in any medium, provided the original work is properly cited.

IntechOpen

IntechOpen