

We are IntechOpen, the world's leading publisher of Open Access books Built by scientists, for scientists

6,900

Open access books available

186,000

International authors and editors

200M

Downloads

Our authors are among the

154

Countries delivered to

TOP 1%

most cited scientists

12.2%

Contributors from top 500 universities



WEB OF SCIENCE™

Selection of our books indexed in the Book Citation Index
in Web of Science™ Core Collection (BKCI)

Interested in publishing with us?
Contact book.department@intechopen.com

Numbers displayed above are based on latest data collected.
For more information visit www.intechopen.com



Corneal Surgical Techniques

Miroslav Vukosavljević, Milorad Milivojević and Mirko Resan
*Eye Clinic, Military Medical Academy, Belgrade,
 Serbia*

1. Introduction

1.1 History of corneal refractive surgery

There is a long history of corneal refractive surgery. Leonardo Da Vinci in 1508 said the theory of refractive errors. The first systematic analysis of the nature and results of refractive errors came from Francis Cornelius Donders. His classic treatise, "On the anomalies of accommodation and refraction of the eye", outlined the fundamental principles of physiological optics. Ironically, in this treatise, Donders railed against surgical attempts to correct refractive errors by altering the corneal shape. In 1885 Hjalmar Schiøtz performed corneal incision to correct astigmatism. Modern refractive surgery extended corneal reshaping to treat myopia and astigmatism. Throughout the 1930s and 1940s, Sato published several reports, describing his attempts to refine incisional refractive surgery with anterior and posterior corneal incisions. The Russian ophthalmologist, Fyodorov later developed a systematic process of anterior radial keratotomy and treated thousands of myopic patients with greater predictability. Lamellar surgery was first introduced by Jose Barraquer. He invented keratoplasty procedures that involved the transplantation of corneal tissue of a size different from the host size to alter the curvature of cornea. He also invented a series of lamellar procedures and developed a formula that represented the relationship between the added corneal thickness and the change in refractive power, later called Barraquer's law of thickness. The transition from incisional to ablative laser refractive surgery arose with the development of Excimer laser technology. Excimer lasers use argon fluoride gases to emit ultraviolet laser pulses. Taboda and Archibald reported the use of the Excimer laser to reshape the corneal epithelium in 1981. In 1983, Trokel and colleagues showed how the Excimer laser could be used to ablate bovine corneal stroma. In 1985, Seiler did the first Excimer laser treatment in a blind eye. He later did the first Excimer laser astigmatic keratotomy. In 1989, McDonald and colleagues did the first photorefractive keratectomy on a seeing eye with myopia. Jose Barraquer's pioneering work, including the use of lamellar procedures to subtract corneal stromal tissue and the development of the first microkerotomes, set the stage for laser in situ keratomileusis (LASIK) surgery. Ruiz and Rowsey modified Barraquer's technique to perform keratomileusis in situ with a geared automated microkeratome. In the early 1990s, Pallikaris and colleagues and Buratto and colleagues independently described a technique that combined two existing technologies: the microkeratome and the Excimer laser. Pallikaris coined the term LASIK for this new technique, which has become a widely used refractive technique worldwide (1).

1.2 Introduction

Astigmatism is a unique refractive error that causes reduced visual acuity and produces symptoms of glare, monocular diplopia, asthenopia, and distortion. The control and correction of astigmatism has been a topic of great interest to cataract, refractive and corneal surgeons.

Corneal refractive surgical techniques that can correct astigmatism are: incisional surgical techniques, such as arcuate keratotomy and limbal relaxing incisions; laser-assisted *in situ* keratomileusis (LASIK); and surface ablation techniques, such as photorefractive keratectomy (PRK), *trans*-epithelial PRK (tPRK), laser-assisted subepithelial keratomileusis (LASEK), epi-LASIK and Intralase.

Arcuate keratotomy is an incisional surgical technique in which arcuate incisions of approximately 95% depth are made in the corneal midperipheral 7,0 mm zone placed in the steep meridian(s). Arcuate keratotomy was used to correct naturally occurring astigmatism, but it is now used primarily to correct postkeratoplasty astigmatism. Limbal relaxing incisions are incisions set at approximately 600 μm depth, or 50 μm less than the thinnest pachymetry at the limbus, and placed just anterior to the limbus. Limbal relaxing incisions are used to manage astigmatism during or after phacoemulsification and intraocular lens (IOL) implantation (2).

LASIK is a lamellar laser refractive surgical technique in which the Excimer laser ablation is done under a partial-thickness lamellar corneal flap. The lamellar flap could be made with a microkeratome or with a femtosecond laser. The microkeratome uses an oscillating blade to cut the flap after immobilization of the cornea with a suction ring. Microkeratomes from several companies cut the lamellar flaps with either superior or nasal hinges, and can cut to depths of 100–200 μm . A femtosecond laser has been developed that can etch lamellar flaps within the cornea stroma at a desired corneal depth. The femtosecond laser provides more accuracy in flap thickness than previous methods; the microkeratome cuts can vary widely in depth. The ablation might either correct sphere and cylinder error, or is wavefront-guided. After the ablation has been completed, the stromal bed is irrigated and the corneal flap is repositioned (3).

Surface ablation is a generic term referring to the application of Excimer laser directly on the anterior stromal surface. The epithelium is removed in order for the Excimer laser to be applied to the stroma. There are several ways in which the epithelium can be separated from Bowmans layer. The epithelium can be fashioned as a flap and replaced (as in LASEK and epi-LASIK) or removed (as in PRK). Surface ablation techniques are continuously evolving in order to achieve better results with faster visual recovery and less pain (4).

LASIK and PRK are the most commonly used refractive surgical methods worldwide.

2. Laser in situ keratomileusis (LASIK)

Laser in situ keratomileusis (LASIK) is the most commonly used refractive surgical method worldwide. This method employs two technologies: Excimer laser and microkeratome. Excimer (acronym for excited dimer) laser is an ultraviolet gas laser (argon-fluoride, ArF) with wavelength of 193 nm, which achieves photoablative effect on tissue of corneal stroma.

First, microkeratome cuts through the cornea and make intrastromal flap on hinge. Flap has a diameter from 8 to 10 mm and its thickness can be 100-180 μm , but usually 100-130 μm (about 15-35% of total corneal thickness). Then the flap is lifted and the corneal stroma exposed to the Excimer laser, and stroma is remodeled according to the type of ametropia and its values. On the end of Excimer laser the flap is repositioned and for a short time have stable position without of need for sutures (5). Postoperative visual rehabilitation is rapid. Sixteen hours after LASIK the majority of patients are reaching 97% of the preoperative best corrected visual acuity (6).

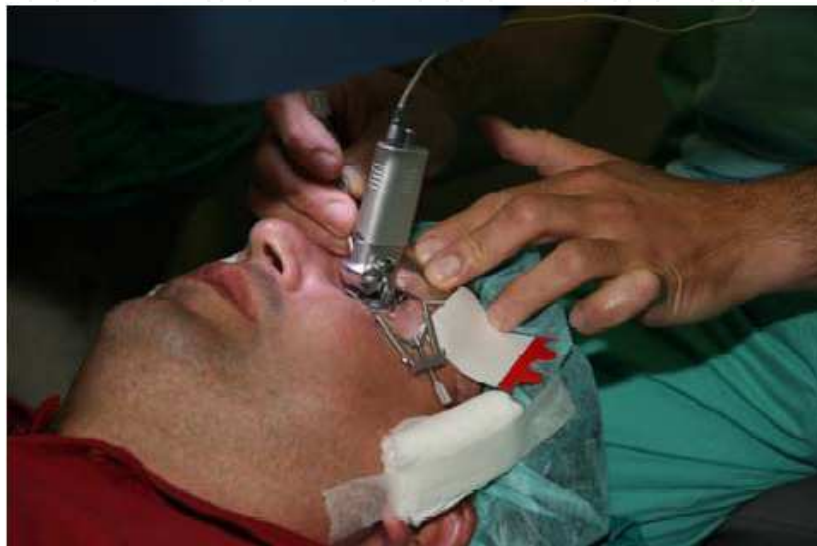

Fig. 1. Placing of suction ring and microkeratome on the eye (5).

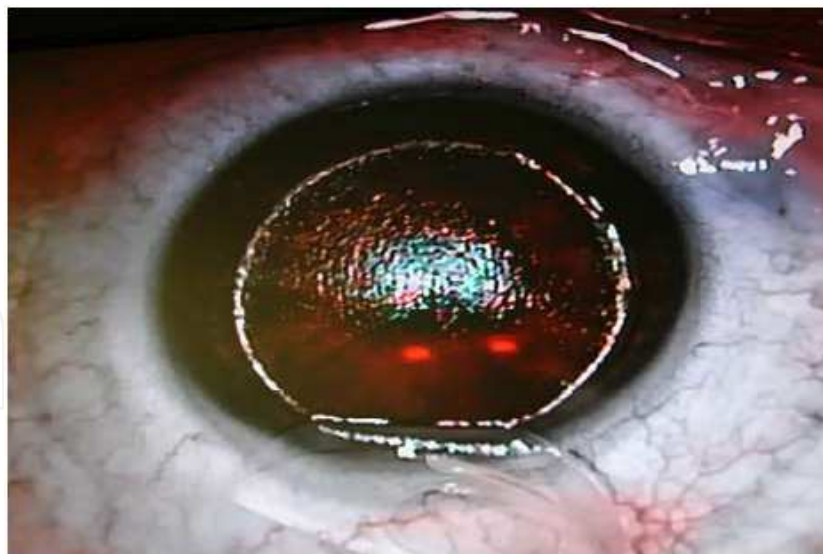


Fig. 2. Flap is created and corneal stroma prepared for Excimer laser ablation (5).

The American Academy of Ophthalmology (AAO) recommended the indications for LASIK: myopia up to - 10 Dsph, hyperopia up to + 4 Dsph, and astigmatism up to 4 Dcyl (7).

The contraindications for Excimer laser refractive surgery including LASIK and PRK are general and ophthalmic. General are: immunological diseases (autoimmune, collagen

vascular, immune deficiency); pregnancy or breast feeding; the tendency to form keloids; diabetes; and systemic administration of isotretinoin or amiodarone. Ophthalmic are: dry eye; neurotrophic keratitis; herpes zoster ophthalmicus / keratitis herpetica; glaucoma; ectatic corneal dystrophy (keratoconus, keratoglobus); highly irregular astigmatism; uveitis, diabetic retinopathy; progressive retinal disease and previously performed radial keratotomy (8).

The complications of LASIK include: intraoperative and postoperative complications. The intraoperative complications or flap related complications (9) are: wrong ablation, flap loss, buttonhole flap (hole in the flap), thin flap, brief flap, free cap (flap amputation), corneal bleeding, epithelial defects and corneal perforation (very rare). The postoperative complications (10) are: infections, dislocation of the flap, flap folding (striae), diffuse lamellar keratitis (sands of the Sahara), epithelial ingrowth, corneal ectasia, regression, intraflap fluid accumulation and paradoxical hypotony.

Each candidate for LASIK should be at least 21 years of age and must have a stable refractive error in the period of two years. Preoperative evaluation of each candidate includes: general and ophthalmic history; autorefractokeratometry; uncorrected visual acuity (UCVA) and best corrected visual acuity (BCVA); Schirmer test; review of the eye anterior segment on slit-lamp; applanation tonometry; review of the eye fundus in a wide pupil; imaging of corneal topography and aberrometry. The following formula to evaluate whether a candidate can safely perform LASIK is:

Central pachymetry - flap thickness - ablation depth = residual stromal thickness of the cornea

As a limit value for residual stromal thickness of the cornea (residual stromal bed) after cutting and effects of Excimer laser 300 μm are taken; as a critical value for steep corneal meridian (steep K) <39 or > 47 D are taken; as a limit value for elevation of the posterior corneal surface 50 μm are taken (5).

Numerous studies confirm the effectiveness of LASIK for the correction of astigmatism. Stojanovic and Nitter evaluated safety, efficacy, predictability, and stability in the treatment of myopic astigmatism with LASIK and PRK using the 200 Hz flying-spot technology of the Excimer laser. This retrospective study included 110 eyes treated with LASIK and 87 eyes treated with PRK that were available for evaluation at 6 and 12 months. The mean preoperative spherical equivalent (SE) was -5.35 diopters (D) ± 2.50 (SD) (range -1.13 to -11.88 D) in the LASIK eyes and -4.72 ± 2.82 D (range -1.00 to -15.50 D) in the PRK eyes. The treated astigmatism was 4.00 D in both groups. None of the eyes lost 2 or more lines of best spectacle-corrected visual acuity. Seventy-seven percent of the LASIK eyes and 78% of the PRK eyes achieved an uncorrected visual acuity of 20/20 or better; 98% in both groups achieved 20/40 or better. In conclusion, Excimer laser was safe, effective, and predictable and with LASIK and PRK the results are stable when treating low to moderate myopia and astigmatism up to 4.0 D (11). Ditzen et al evaluated safety, predictability, efficacy, and stability of LASIK for spherical hyperopia and hyperopia with astigmatism. This retrospective study analyzed the results of 23 eyes of 23 patients who had LASIK for spherical hyperopia (preoperative astigmatism ≤ 0.75 D) and 44 eyes of 44 patients who had LASIK for hyperopia with astigmatism. In group 1 (spherical hyperopia), mean preoperative spherical equivalent refraction was $+4.88 \pm 2.13$ D (range $+2.13$ to $+9.63$ D); in group 2

(hyperopic astigmatism), $+4.33 \pm 2.15$ D (range +0.50 to +9.50 D). One year after LASIK, mean spherical equivalent refraction was $+0.30 \pm 0.90$ D (range -0.75 to +2.50 D) in group 1 and $+0.29 \pm 1.27$ D (range -3.25 to +3.25 D) in group 2. In group 1, no eyes lost two or more lines, and one eye (6%) lost one line of best spectacle-corrected visual acuity at 1 year. In group 2, one eye (4%) lost one line and one eye (4%) lost more than two lines at 1 year. Uncorrected visual acuity of 20/40 or better was achieved in 83% (group 1) vs. 62% (group 2) at 1 year. In conclusion, LASIK seemed to be safe and effective for hyperopia and hyperopia with astigmatism for corrections up to +6.00 D (12). Albarran-Diego et al evaluated bitoric LASIK for the correction of mixed astigmatism. This prospective study included 28 eyes of 21 patients with mixed astigmatism who had bitoric LASIK. Six months after bitoric LASIK, the mean UCVA was 0.70 ± 0.23 (SD). The percentage of eyes with a UCVA of 20/40 or better was 78.6% and of 20/20, 21.4%. There was a statistically significant increase in the mean BCVA from 0.71 ± 0.19 before surgery to 0.83 ± 0.15 at 6 months. Three eyes (10.7%) lost 1 line of BCVA. The mean preoperative astigmatism of -4.04 ± 1.13 diopters (D) was reduced to -0.67 ± 0.79 D after surgery (13).

3. Photorefractive keratectomy (PRK)

Photorefractive keratectomy (PRK) is still a successful method in certain indications and now is used worldwide as PRK or as its modification - LASEK and EpiLASIK. All methods for its performance require use of Excimer laser (14).

PRK is superficial ablative method because the Excimer laser thinner and reshapes the anterior part of the corneal stroma just below Bowman's membrane. This provides greater residual stromal thickness, and thus strengthens the biomechanical strength of the cornea. But, ablation of front stroma, especially through a layer of Bowman's membrane, causing aggressive response in wound healing, which may result in frequent appearance of subepithelial clouding (haze) and scarring compared with LASIK. Recovery after PRK is slower and more painful compared with LASIK. One to four days after the intervention most of the patients have a transient low-intensity pain. Postoperative visual rehabilitation is a little longer and lasts several weeks (1,15).

Certain situations may favor PRK over LASIK in particular safety issues due to the absence of flap related complications in PRK. These situations include: predisposition for contact injury (e.g. those involved in martial arts or boxing); anterior basement membrane (BM) dystrophy; epithelial sloughing during LASIK in the fellow eye; thin corneas in which the residual stromal bed would be less than 250-300 μ m; deep set eyes or a small palpebral aperture (poor exposure for the microkeratome); previous surgery involving the conjunctiva (e.g. glaucoma drainage bleb, scleral buckle); and moderate dry eye before surgery. In addition, flat (< 41 D) or steep corneas (> 48 D), with the risk of free, thin, incomplete or buttonholed flaps, may be better suited to PRK. It is desirable to avoid suction and iatrogenically raising the IOP during LASIK, as in patients with glaucoma or a risk of poor optic nerve perfusion, PRK procedure would be preferred (15).

In PRK the first step is corneal epithelium removing (mechanically with knife-hockey or rotating brush; or by chemical abrasion with 20% ethanol), then the corneal stroma is exposed to the effects of Excimer laser which thins and reshapes it according to the type of ametropia and its values and after that therapeutic soft contact lens is applied for 5 days.

The American Academy of Ophthalmology (AAO) recommended the next indications for PRK: myopia up to - 8 Dsph, hyperopia up to + 4 Dsph, and astigmatism up to 4 Dcyl (7). Large corrections (ablation depth greater than 100 μm) are considered for adjunctive 0.02% mitomycin C (MMC) because of the increased risk of postoperative haze and regression (16).

Complications of PRK include: subepithelial haze, corneal scarring, ectasia and regression.

Each candidate for PRK should be at least 21 years of age and must have a stable refractive error in the period of two years. Preoperative evaluation of each candidate includes: general and ophthalmic history; autorefractokeratometry; uncorrected visual acuity (UCVA) and best corrected visual acuity (BCVA) in each eye; Schirmer test; examination of the eye anterior segment on slit-lamp; applanation tonometry; examination of the eye fundus in a wide pupil; imaging of corneal topography and aberrometry. As a limit value for residual stromal thickness of the cornea (residual stromal bed) is 300 μm . The critical value for steep corneal meridian (steep K) is <39 or >47 D and the limit value for elevation of the posterior corneal surface is 50 μm (5).

Numerous studies have investigated the effectiveness of PRK in the correction of astigmatism. Haw and Manche evaluated the safety and efficacy of PRK for the treatment of primary compound myopic astigmatism. Ninety three eyes from 56 patients with a mean spherical equivalent of -4.98 ± 1.80 diopters (range, -1.75 to -8.5) underwent photoastigmatic refractive keratectomy and were followed for 2 years. Fifty-six eyes (94.9%) had an uncorrected visual acuity of 20/40 or greater, whereas 34 eyes (57.6 %) demonstrated an uncorrected visual acuity of 20/20 or greater. One eye (1.7%) lost 2 or more lines of best spectacle-corrected visual acuity (17). Nagy et al evaluated the results of PRK using Gaussian flying spot technology in the treatment of hyperopia and hyperopic astigmatism. Two hundred eyes were evaluated with 12-month follow-up. Eyes were divided into four groups: group 1 (spherical hyperopia up to +3.50 D and astigmatism less than 1.00 D, n=62); group 2 (hyperopia up to +3.50 D and astigmatism of 1.00 D or more, n=44); group 3 (hyperopia greater than +3.50 D and astigmatism less than 1.00 D, n=56); and group 4 (hyperopia greater than +3.50 D and astigmatism of 1.00 D or more, n=38). In group 1, 82.2% (51/62 eyes) were within ± 0.50 D of target refraction; 88.7% (55/62 eyes) had 20/20 or better uncorrected visual acuity; 1.6% (1/62 eye) lost two or more lines. In group 2, 68.1% (30/44 eyes) were within ± 0.50 D; 77.2% (34/44 eyes) had 20/20 or better uncorrected visual acuity; 9.1% (4/44 eyes) lost two or more lines of spectacle-corrected visual acuity. In group 3, 76.8% (43/56 eyes) were within ± 0.50 D; 78.6% (44/56 eyes) had 20/20 or better uncorrected visual acuity; 5.4% (3/56 eyes) lost two or more lines of spectacle-corrected visual acuity. In group 4, 42% (16/38 eyes) were within ± 0.50 D; 60.5% (23/38 eyes) had 20/20 or better uncorrected visual acuity; 15.8% (6/38 eyes) lost two or more Snellen lines. In conclusion PRK was most safe and effective for low hyperopia (18).

4. Trans-epithelial photorefractive keratectomy (tPRK)

In this method, the Excimer laser is used to ablate the epithelium in addition to then ablating the underlying stroma. The cornea undergoes an epithelial ablation within a fixed diameter. The operating room lights are turned off as blue fluorescent light is emitted whereas epithelium is ablated. Once the blue fluorescence disappears, this indicates that the epithelium has been removed. Accuracy with this method is dependent upon regular

epithelial thickness across the diameter treatment zone and also similar epithelial thicknesses between different eyes. This technique can produce variable results when laser surface enhancement is proposed after previous refractive surgery due to areas of epithelial hyperplasia causing variable epithelial thickness (15).

5. Laser-assisted subepithelial keratomileusis (LASEK)

LASEK is a surgical procedure that combines certain elements of both LASIK and PRK to improve the risk/benefit ratio. Diluted alcohol is used to loosen the epithelial adhesion to the corneal stroma. The loosened epithelium is moved aside from the treatment zone as a hinged sheet. Laser ablation of the subepithelial stroma is performed before the epithelial sheet is returned to its original position. The main rationale for combining elements of LASIK and PRK to LASEK is to avoid the flap-related LASIK complications and the slow visual recovery and haze risk of PRK. LASEK may avoid several of the inherent complications, including free caps, incomplete pass of the microkeratome, flap wrinkles, epithelial ingrowth, flap melt, interface debris, corneal ectasia, and diffuse lamellar keratitis, after LASIK and postoperative pain, subepithelial haze, and slow visual rehabilitation after PRK. Current ophthalmic literature does not provide the specific indications, visual outcomes, complications, and limitations of LASEK (19). Bilgihan et al. evaluated the efficacy, predictability, and safety of LASEK for treatment of high myopia with astigmatism. LASEK was performed in 61 eyes of 36 consecutive patients with myopic spherical equivalent refraction of -6.00 to -10.00 D using the Aesculap-Meditec MEL60 Excimer laser. Ninety-six percent of eyes achieved 20/40 or better uncorrected visual acuity (UCVA) at 1 month. At 12 months, 64% of eyes achieved 20/20 and 92% achieved 20/40 or better UCVA. Two eyes lost 2 lines of best spectacle-corrected visual acuity (BSCVA) at 6 or 12 months. Accuracy of correction was ± 0.50 D from emmetropia in 82% of eyes, and ± 1.00 D in 90% at 12 months (20). Taneri et al evaluated the visual outcomes and complications in low to moderate levels of myopia and astigmatism treated with LASEK. One hundred seventy-one eyes of 105 patients were studied. Preoperatively, the mean spherical equivalent was -2.99 diopters (D) ± 1.43 (SD) and the mean cylinder -0.78 ± 0.73 D. One week postoperatively, 96% of eyes had a UCVA of 20/40 or better but definitive visual recovery took more than 4 weeks in some eyes. Approximately 95% of eyes were within ± 1.0 D of emmetropia after 4 to 52 weeks; the remaining 5% did not show major deviations. At 4 to 52 weeks, only 1 eye was overcorrected by more than 1.0 D of manifest refraction (21).

6. Epithelial laser in situ keratomileusis (Epi-LASIK)

Epi-LASIK has proved to be a suitable procedure, especially in patients with active lifestyles or occupations, eyes with thin corneas without ectatic disorders, and patients with moderate dry-eye syndrome. In epi-LASIK, an epithelial flap is created with the help of a special microkeratome. The epithelial flap is repositioned on the cornea after photoablation. It has been postulated that compared with conventional laser-assisted subepithelial keratectomy (LASEK), in which an epithelial flap is created after the epithelium is exposed to an alcohol solution, cell viability of the epithelial sheet is better in epi-LASIK surgery, in which mechanical separation is performed with a microkeratome. The quality of the epithelial separation is crucial for the success of the procedure because stromal lacerations or remaining islands of basal epithelial cells would reduce the optical quality of the cornea after photoablation (22).

Factor	PRK	LASEK	EPI-LASIK	LASIK
Range of correction	Low to moderately high			Low to moderately high
Postoperative pain	Mild to moderate 24–72 hours			Minimum 12 hours
Postoperative medications	1–3 months			1 week
Functional vision recovery	3 to 7 days			<24 hours
Refractive stability achieved	3 weeks to 3 months			1 week to 3 months
Specific complications	Haze formation, scarring	Haze formation, scarring	Haze formation, scarring, incomplete epithelial flap, stromal incursions	Free caps, incomplete pass of microkeratome, flap wrinkles, epithelial ingrowth, flap melt, interface debris, corneal ectasia, diffuse lamellar keratitis
Dry-eye sensitive	1 to 6 months			1 to 12 months
Thin corneas or wide pupils	Often not contraindicated			May be contraindicated depending on amount of intended correction
Special (relative) indications	Thin corneal pachymetry, wide scotopic pupil, LASIK complications in fellow eye, predisposition to trauma, keratoconus suspect (irregular astigmatism), glaucoma suspect, recurrent erosion syndrome, dry-eye syndrome, basement membrane disease			Concern about postoperative pain, requirement of rapid visual recovery
Special (relative) contraindications	Concern about postoperative pain, requirement of rapid visual recovery	Concern about postoperative pain, requirement of rapid visual recovery	Concern about postoperative pain, requirement of rapid visual recovery, glaucoma, scleral buckle, deep-set eyes, small palpebral fissure	Thin corneas, wide pupils, recurrent erosion syndrome, glaucoma, scleral buckle, deep-set eyes, small palpebral fissure

Fig. 3. Widely accepted relative differences between PRK, LASEK, epi-LASIK, and LASIK (23).

7. Femtosecond laser in laser in situ keratomileusis

In the early 1960s, Barraquer introduced the concept of lamellar refractive procedures. In the 1990s, Pallikaris et al. and Buratto et al. conceived of techniques combining lamellar procedures with Excimer laser ablation. These advances led to the development of modern laser in situ keratomileusis (LASIK) procedures. LASIK has several advantages over PRK when performed properly in appropriate eyes. These include faster visual recovery, less discomfort after surgery, and milder and more predictable wound healing with less risk for corneal stromal opacity (haze). Lamellar corneal flap formation is the critical step in successful LASIK surgery. Improper flap formation, including improper flap geometry, decentration, irregularity of the cut, and epithelial damage, can lead to myriad LASIK complications. Considerable progress has been made over the years in producing safer instruments for LASIK flap formation since the Automated Corneal Shaper was adapted to LASIK. Thus, more reliable and safer mechanical microkeratomes contributed to the explosive growth of refractive surgery over the past 15 years. Despite these advances, complications such as incomplete or partial flaps, free flaps, buttonholes, and small irregular flaps continue to plague refractive surgeons who perform LASIK with a microkeratome. There are also significant limitations to the eyes that can safely have lamellar flap formation

performed with a mechanical microkeratome, including corneas that are too steep (likely to have buttonhole flaps), too flat (likely to have small diameter flaps), or relatively thin (more likely to have low residual stromal bed) (Fig. 4).

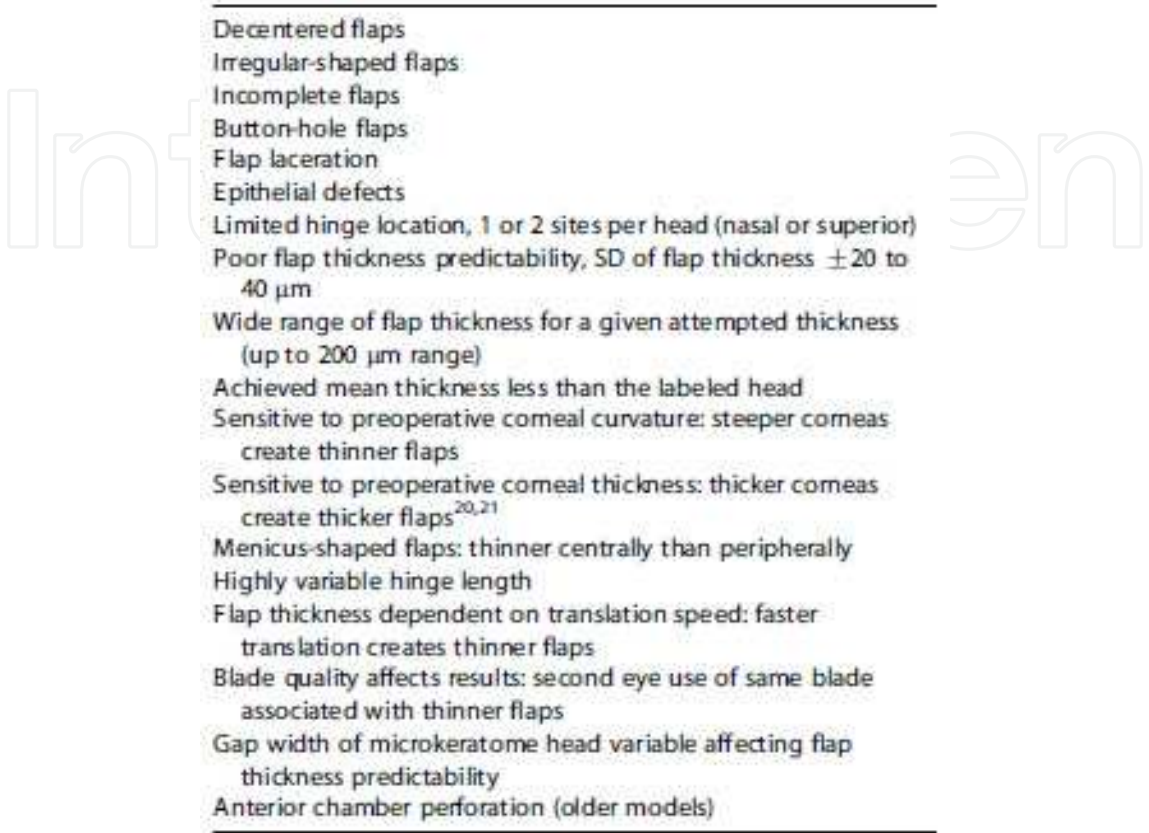


Fig. 4. Corneal complications reported with conventional microkeratomes (24).

The femtosecond laser became available for LASIK flap formation approximately 10 years ago. Since the early femtosecond laser models were introduced, considerable progress has been made in improving flap geometry and limiting complications of LASIK performed with the laser. This has led to increasing popularity of LASIK performed with the femtosecond laser, to the point that different sources estimate that 30% to 50% of LASIK procedures in the United States in 2008 were performed using a femtosecond laser. Recently, new femtosecond laser models were introduced. These include the Femtec (20/10 Perfect Vision AG), the Femto LDV (Zeimer Group), the Visu-Max (Carl Zeiss Meditec) and commonly used IntraLase 60 kHz femtosecond laser (Abbott Medical Optics, Inc.). All 4 commercially available femtosecond laser systems use ultrashort pulses of laser and produce corneal tissue cutting using a photodisruption process. To create the lamellar flap, the IntraLase laser generates pulses of femtosecond laser at a near-infrared (1053 nm) wavelength and delivers closely spaced 3 mm spots, which are focused at variable depths to photodisrupt stromal tissue. When a high peak power is reached, hot plasma is generated, initiating a process of tissue ionization that is commonly called laser-induced optical breakdown. The hot plasma expands in shock waves and creates an intrastromal cavitation bubble composed primarily of water and carbon dioxide. Multiple cavitation bubbles coalesce, and an intrastromal cleavage plane is created. The laser delivers a series of pulses

in a specified pattern to create the lamellar intrastromal cut and then extends the cleavage to the surface with a side cut to complete the flap (25). Stonecipher et al. reported the refractive results after LASIK for high myopia and cylinder at one center with one surgeon comparing two laser platforms. A total of 206 eyes of 121 patients were treated for -6.00 to -12.00 diopters (D) of spherical equivalent refractive error with up to 3.00 D of cylinder. All eyes underwent LASIK with the ALLEGRETTO WAVE 200-Hz (n=141) or 400-Hz (n=65) laser (Alcon Laboratories Inc). Corneal flaps were created with the IntraLase femtosecond laser (Abbott Medical Optics) at an intended thickness of 100 or 110 μm in all cases. At 3- and 6-month follow-up in the 200-Hz group, 77% (109/141) and 86% (121/141) of eyes, respectively, were within ± 0.50 D of intended correction. In the 400-Hz group, 98.5% (64/65) and 100% (65/65) of eyes were within ± 0.50 D of intended correction at 3 and 6 months postoperatively. At 3- and 6-month follow-up, 84% (119/141) and 77% (109/141) of eyes, respectively, in the 200-Hz group and 80% (52/65) and 92% (60/65) of eyes, respectively, in the 400-Hz group had 20/20 or better uncorrected distance visual acuity. At 6-month follow-up, refractive predictability and visual acuity were statistically superior in eyes in the 400-Hz group (chi square, $P < .01$). No eyes underwent retreatment as a secondary procedure during the time of analysis (26).

8. Refractive laser surgery in children

The use of Excimer laser vision correction in children is controversial because their eyes and refractive state continue to change. More studies on the growing eye and the effect of Excimer laser on the pediatric corneal endothelium are needed before the effect of refractive surgery in the pediatric age group can be fully understood (27).

Traditional methods of correcting and rehabilitating the refractive status of children with high myopia, myopic anisometropic amblyopia, hyperopia, hyperopic anisometropic amblyopia or significant astigmatism include glasses and contact lenses combined with some form of occlusion or optical penalization therapy. However, some children may not improve with these traditional forms of treatment because of aniseikonia, compliance issues, or both. This is especially true when children have concurrent medical diagnoses such as autism, cerebral palsy, developmental delay, Down syndrome, or other associated ocular disorders (eg, corneal, retinal, and optic nerve problems). So, in such children traditional optical refractive correction is often not successful (28, 29).

In the past ten years, refractive laser surgery techniques have been shown to be a good last-resort treatment in children who have failed with traditional treatment approaches. There are numerous reports of the successful performance of PRK, LASIK and LASEK in children when conventional therapy failed.

Autrata and Rehurek evaluated the visual and refractive results of multizonal PRK for high myopic anisometropia and contact-lens intolerance in children. Twenty-one patients aged 7 to 15 years with high myopic anisometropia had multizonal PRK in the more myopic eye and were retrospectively analyzed. The scanning-slit Nidek EC-5000 Excimer laser was used. The safety, efficacy, predictability, and stability of the procedure were evaluated. Long-term binocular vision outcome was analyzed. All patients completed a 4-year follow-up. The mean preoperative spherical equivalent (SE) refraction was -8.93 diopters (D) ± 1.39 (SD) (range - 6.75 to - 11.75 D) and the mean postoperative SE was -1.66 ± 0.68 D (range -

0.50 to - 2.75 D). The mean preoperative uncorrected visual acuity (UCVA) of 0.034 ± 0.016 increased to 0.35 ± 0.15 postoperatively. The mean preoperative best spectacle-corrected visual acuity (BSCVA) was 0.53 ± 0.19 and changed to 0.64 ± 0.16 postoperatively. No eye lost a line of BSCVA; 9 eyes gained 1 line, and 5 eyes gained 2 lines. No eye had + 3 haze. There were no significant complications. In conclusion, PRK was safe and effective in correcting high myopic anisometropia in children who were contact-lens intolerant (30).

Yin et al. assessed the efficacy of LASIK in facilitating amblyopia management of children from 6 to 14 years old, with high hyperopic and myopic anisometropia. Between 2000 and 2005, 42 children with high hyperopic anisometropic amblyopia and 32 children with high myopic anisometropic amblyopia underwent LASIK to reduce their anisometropia. LASIK was performed under topical or general anesthesia. Follow-up ranged from 6 months to 3 years, the averages of which were 17,45 months in the hyperopic group and 18,31 months in myopic group. Hyperopic anisometropia correction ranged from + 3.50 D to + 7.75 D, and the mean postoperative anisometropia was $+0.56 \pm 0.75$ D at 3 years. Myopic anisometropia correction ranged from -15.75 to - 5.00 D and the mean postoperative anisometropia at 3 years was $- 2.20 \pm 1.05$ D. The best-corrected visual acuity for distance and reading in the myopic group improved from 0.4 ± 0.25 and 0.58 ± 0.27 , respectively, before surgery to 0.59 ± 0.28 and 0.96 ± 0.35 , respectively, 3 years after surgery. In the hyperopic group, best-corrected visual acuity for distance and reading improved from 0.23 ± 0.21 and 0.34 ± 0.32 , respectively, before surgery to 0.53 ± 0.31 and 0.80 ± 0.33 , respectively, 3 years after surgery. Study shows that LASIK is an alternative method for correcting high hyperopic and myopic anisometropia. The proportion of patients who had stereopsis increased from 19.1% preoperatively to 46.7% postoperatively in the hyperopic group and from 19% to 89% in the myopic group. In conclusion, LASIK reduced high hyperopic and myopic anisometropia in children, thus facilitating amblyopia management and improving their visual acuity and stereopsis (31).

Astle et al. assessed the refractive, visual acuity, and binocular results of LASEK for anisomyopia, anisohyperopia, and anisoastigmatia in children with various levels of amblyopia secondary to the anisometropic causes. Retrospective review was of 53 children with anisometropia who had LASEK to correct the refractive difference between eyes. All LASEK procedures were performed using general anesthesia. Patients were divided into 3 groups according to their anisometropia as follows: myopic difference greater than 3.00 diopters (D), astigmatic difference greater than 1.50 D, and hyperopic difference greater than 3.50 D. The children were followed for at least 1 year. The mean age at treatment was 8.4 years (range 10 months to 16 years). The mean preoperative anisometropic difference was 6.98 D in the entire group, 9.48 D in the anisomyopic group, 3.13 D in the anisoastigmatic group, and 5.50 D in the anisohyperopic group. One year after LASEK, the mean anisometropic difference decreased to 1.81 D, 2.43 D, 0.74 D, and 2.33 D, respectively, and 54% of all eyes were within ± 1.00 D of the fellow eye, 68% were within ± 2.00 D, and 80% were within ± 3.00 D. Preoperative visual acuity and binocular vision could be measured in 33 children. Postoperatively, 63.6% of children had an improvement in best corrected visual acuity (BCVA) and the remainder had no noted change. No patient had a reduction in BCVA or a loss in fusional ability after LASEK. Of the 33 children, 39.4% had positive stereopsis preoperatively and 87.9% had positive stereopsis 1 year after LASEK. In conclusion, LASEK is an effective surgical alternative to improve visual acuity in

anisometropic children unable to tolerate conventional methods of treatment or in whom these methods fail (32).

9. References


- [1] Sakimoto T, Rosenblatt MI, Azar DT. Laser eye surgery for refractive errors. *The Lancet* 2006; 367 (9520): 1432-1447.
- [2] American Academy of Ophthalmology. Incisional Corneal Surgery. In: American Academy of Ophthalmology. *Refractive surgery, Section 13, 2010-2011*. Singapore: American Academy of Ophthalmology; 2010. p. 67-71.
- [3] American Academy of Ophthalmology. Photoablation. In: American Academy of Ophthalmology. *Refractive surgery, Section 13, 2010-2011*. Singapore: American Academy of Ophthalmology; 2010. p. 109-146.
- [4] American Academy of Ophthalmology. Photoablation. In: American Academy of Ophthalmology. *Refractive surgery, Section 13, 2010-2011*. Singapore: American Academy of Ophthalmology; 2010. p. 92-109.
- [5] Vukosavljević M, Milivojević M, Resan M, Cerović V. Laser in situ keratomileusis (LASIK) for correction of myopia and hypermetropia – our one year experience *Vojnosanitet Pregl* 2009; 66 (12): 979–984.
- [6] Giessler S, Duncker GIW. Short-term visual rehabilitation after LASIK. *Graefes Arch Clin Exp Ophthalmol* 2001; 239 (8): 603-608.
- [7] American Academy of Ophthalmology. Patient Evaluation. In: American Academy of Ophthalmology. *Refractive surgery, Section 13, 2010-2011*. Singapore: American Academy of Ophthalmology; 2010. p. 41-58.
- [8] Young JA, Kornmehl EW. Preoperative evaluation for refractive surgery. In: Yanoff M, Duker JS. *Ophthalmology*. St. Louis: Mosby; 2004. p. 133-136.
- [9] Probst LE. Intraoperative complications. In: Probst LE. *Lasik: a color atlas and surgical synopsis*. Thorofare, NJ: Slack Incorporated; 2001. p. 211-232.
- [10] Probst LE. Early and late postoperative complications. In: Probst LE. *Lasik: a color atlas and surgical synopsis*. Thorofare, NJ: Slack Incorporated; 2001. p. 257-297.
- [11] Stojanovic A, Nitter TA. 200 Hz flying-spot technology of the LaserSight LSX excimer laser in the treatment of myopic astigmatism: six and 12 month outcomes of laser in situ keratomileusis and photorefractive keratectomy. *J Cataract Refract Surg* 2001; 27 (8): 1263- 1277.
- [12] Ditzen K, Fiedler J, Pieger S. Laser in situ Keratomileusis for Hyperopia and Hyperopic Astigmatism Using the Meditec MEL 70 Spot Scanner. *J Refract Surg* 2002; 18: 430-434.
- [13] Albarran-Diego C, Munoz G, Montes-Mico R, Alio JL. Bitoric laser in situ keratomileusis for astigmatism. *J Cataract Refract Surg* 2004; 30 (7): 1471-1478.
- [14] Grabner G. Die entwicklung der refraktiven chirurgie. *Spektrum Augenheilkd* 2009; 23 (3): 187–192.
- [15] Reynolds A, Moore JE, Naroo SA, Moore CBT, Shah S. Excimer laser surface ablation – a review. *Clin Experiment Ophthalmol* 2010; 38 (2): 168-182.

- [16] Hashemi H, Taheri SM, Fotouhi A, Kheiltash A. Evaluation of the prophylactic use of mitomycin C to inhibit haze formation after photorefractive keratectomy in high myopia: a prospective clinical study. *BMC Ophthalmol* 2004; 4: 12.
- [17] Haw WW, Manche EE. Photorefractive keratectomy for compound myopic astigmatism. *Am J Ophthalmol* 2000; 130 (1): 12-19.
- [18] Nagy ZZ, Munkacsy G, Popper M. Photorefractive Keratectomy Using the Meditec MEL 70 G-scan Laser for Hyperopia and Hyperopic Astigmatism. *J Refract Surg* 2002; 18: 542-550.
- [19] Taneri S, Zieske JD, Azar DT. Evolution, techniques, clinical outcomes and pathophysiology of LASEK : review of the literature. *Surv Ophthalmol* 2004; 49: 576-602.
- [20] Bilgihan K, Hondur A, Hasanreisoglu B. Laser subepithelial keratomileusis for myopia of -6 to -10 diopters with astigmatism with the MEL60 laser. *J Refract Surg* 2004; 20: 121-126.
- [21] Taneri S, Feit R, Azar DT. Safety, efficacy, and stability indices of LASEK correction in moderate myopia and astigmatism. *J Cataract Refract Surg* 2004; 30: 2130-2137.
- [22] Herrmann WA, Hillenkamp J, Hufendiek K et al. Epilaser in situ keratomileusis: comparative evaluation of epithelial separation with 3 microkeratomes. *J Cataract Refract Surg* 2008; 34: 1761-1766.
- [23] Taneri S, Weisberg M, Azar DT. Surface ablation techniques. *J Cataract Refract Surg* 2011; 37: 392-408.
- [24] Binder PS. One thousand consecutive IntraLase laser in situ keratomileusis flaps. *J Cataract Refract Surg* 2006; 32: 962-969.
- [25] Saloma MQ, Wilson SE. Femtosecond laser in laser in situ keratomileusis. *J Cataract Refract Surg* 2010; 36: 1024-1032.
- [26] Stonecipher KG, Kezirian GM, Stonecipher M. LASIK for -6.00 to -12.00 D of myopia with up to 3.00 D of cylinder using the ALLEGRETTO WAVE: 3- and 6-month results with the 200- and 400-Hz platforms. *J Refract Surg* 2010; 26: 814-818.
- [27] American Academy of Ophthalmology. Refractive Surgery in Ocular and Systemic Disease. In: American Academy of Ophthalmology. Refractive surgery, Section 13, 2010-2011. Singapore: American Academy of Ophthalmology; 2010. p. 203-222.
- [28] Astle WF, Huang PT, Ereifej I, Paszuk A. Laser-assisted subepithelial keratectomy for bilateral hyperopia and hyperopic anisometropic amblyopia in children. *J Cataract Refract Surg* 2010; 36:260-267.
- [29] Astle WF, Fawcett SL, Huang PT, Alewenah O, Ingram A. Long-term outcomes of photorefractive keratectomy and laser-assisted subepithelial keratectomy in children *J Cataract Refract Surg* 2008; 34: 411-416.
- [30] Autrata R, Rehurek J. Clinical results of excimer laser photorefractive keratectomy for high myopic anisometropia in children: Four-year follow-up. *J Cataract Refract Surg* 2003; 29: 694-702.
- [31] Yin ZQ, Wang H, Yu T, Ren Q, Chen Li. Facilitation of amblyopia management by laser in situ keratomileusis in high anisometropic hyperopic and myopic children. *J AAPOS* 2007; 11: 571-576.

- [32] Astle WF, Rahmat J, Ingram AD, Huang PT. Laser-assisted subepithelial keratectomy for anisometropic amblyopia in children: Outcomes at 1 year. *J Cataract Refract Surg* 2007; 33: 2028–2034.

IntechOpen

IntechOpen



Advances in Ophthalmology

Edited by Dr Shimon Rumelt

ISBN 978-953-51-0248-9

Hard cover, 568 pages

Publisher InTech

Published online 07, March, 2012

Published in print edition March, 2012

This book focuses on the different aspects of ophthalmology - the medical science of diagnosis and treatment of eye disorders. Ophthalmology is divided into various clinical subspecialties, such as cornea, cataract, glaucoma, uveitis, retina, neuro-ophthalmology, pediatric ophthalmology, oncology, pathology, and oculoplastics. This book incorporates new developments as well as future perspectives in ophthalmology and is a balanced product between covering a wide range of diseases and expedited publication. It is intended to be the appetizer for other books to follow. Ophthalmologists, researchers, specialists, trainees, and general practitioners with an interest in ophthalmology will find this book interesting and useful.

How to reference

In order to correctly reference this scholarly work, feel free to copy and paste the following:

Miroslav Vukosavljević, Milorad Milivojević and Mirko Resan (2012). Corneal Surgical Techniques, *Advances in Ophthalmology*, Dr Shimon Rumelt (Ed.), ISBN: 978-953-51-0248-9, InTech, Available from: <http://www.intechopen.com/books/advances-in-ophthalmology/corneal-surgical-techniques>

INTech
open science | open minds

InTech Europe

University Campus STeP Ri
Slavka Krautzeka 83/A
51000 Rijeka, Croatia
Phone: +385 (51) 770 447
Fax: +385 (51) 686 166
www.intechopen.com

InTech China

Unit 405, Office Block, Hotel Equatorial Shanghai
No.65, Yan An Road (West), Shanghai, 200040, China
中国上海市延安西路65号上海国际贵都大饭店办公楼405单元
Phone: +86-21-62489820
Fax: +86-21-62489821

© 2012 The Author(s). Licensee IntechOpen. This is an open access article distributed under the terms of the [Creative Commons Attribution 3.0 License](https://creativecommons.org/licenses/by/3.0/), which permits unrestricted use, distribution, and reproduction in any medium, provided the original work is properly cited.

IntechOpen

IntechOpen