

We are IntechOpen, the world's leading publisher of Open Access books Built by scientists, for scientists

6,900

Open access books available

185,000

International authors and editors

200M

Downloads

Our authors are among the

154

Countries delivered to

TOP 1%

most cited scientists

12.2%

Contributors from top 500 universities



WEB OF SCIENCE™

Selection of our books indexed in the Book Citation Index
in Web of Science™ Core Collection (BKCI)

Interested in publishing with us?
Contact book.department@intechopen.com

Numbers displayed above are based on latest data collected.
For more information visit www.intechopen.com



Hypopharyngeal Cancer

Valentina Krstevska

*Department of Head and Neck Cancer,
University Clinic of Radiotherapy and Oncology, Skopje
Republic of Macedonia*

1. Introduction

Hypopharyngeal cancers arise from the mucosa of one of the three anatomical subsites of the hypopharynx and are characterised by advanced disease at presentation mainly because the hypopharynx, laying outside the glottis and being a silent area, allows tumours to grow for a substantial period of time before symptoms occur (Elias et al., 1995; Sewnaik et al., 2005). Hypopharyngeal cancers are relatively rare neoplasms and have one of the most unfavourable prognosis among all cancers of the upper aerodigestive tract (Prades et al., 2002; Samant et al., 1999). The reasons for the remarkably poor prognosis of hypopharyngeal cancers is their aggressive behaviour represented by strong tendency for submucosal spread, early occurrence of nodal metastatic involvement, propensity for direct invasion of adjacent structures in the neck and high incidence of distant metastases (Elias et al., 1995; Johansen et al., 2000).

Treatment options for early stage hypopharyngeal cancer include conservation or radical surgery or radiotherapy, whereas total laryngectomy with partial or total pharyngectomy followed by postoperative radiotherapy have been the standard form of treatment for advanced stage disease. Over the past two decades, organ preservation strategies with either altered fractionation radiotherapy or combination of chemotherapy and radiotherapy have been used for the treatment of advanced hypopharyngeal cancers. Progressive tumour-related dysphagia prior to diagnosis, associated tobacco and alcohol use, commonly older age, medical comorbidities and social issues present in most of the patients, unequivocally contribute to additional challenges for employment of aggressive treatment management, and increase the risk of morbidity and mortality following therapy. The complex management of these tumours creates an essential need for multidisciplinary team approach involving a head and neck surgeon, radiation oncologist, medical oncologist, radiologist, pathologist, nutritionist, speech and swallow therapist, and social worker. This chapter will review the epidemiology and etiology, clinical presentation, diagnosis, prognosis, treatment modalities for early and locally-regionally advanced resectable hypopharyngeal cancer, management of unresectable disease, and treatment of recurrent and metastatic disease.

2. Epidemiology and etiology

Hypopharyngeal cancer is a rare disease representing about 0.5% of all human malignancies with an incidence of less than 1 per 100,000 population and constituting only 3% – 5% of all

head and neck cancers (Cooper et al., 2009; Hoffman et al., 1998; Johansen et al., 2000). Hypopharyngeal cancers are more common in men than in women. Increased incidence in males of over 2.5:100,000 is seen in India, Brazil, Central and Western Europe and decreased incidence under 0.5:100,000 in Eastern Asia, Africa and Northern Europe. The incidence in women is as high as 0.2:100,000 in the majority of the countries, except for India (1:100,000) (Popescu et al., 2010). These tumours typically occur in individuals who are older than 50 years of age, with a peak incidence in the sixth and seventh decades and their occurrence is extremely rare in children (Siddiqui et al., 2003). The most common site of origin of hypopharyngeal cancer is the pyriform sinus (66%-75%), followed by the posterior pharyngeal wall, and postcricoid area (20%-25%) (Carpenter & DeSanto, 1977). There are differences in the geographical distribution of the hypopharyngeal cancer with regard to tumour location and patient gender, with postcricoid lesions showing a consistent moderate female preponderance particularly in Scandinavia (Farrington et al., 1986; Kajanti & Mantyla, 1990; Lederman, 1962; Popescu et al., 2010; Tandon et al., 1991). Pyriform sinus and posterior pharyngeal wall lesions demonstrate typical male predominance in North America and especially in France (Vandenbrouck et al., 1987).

Excessive tobacco and alcohol consumption contribute to the development of squamous cell carcinomas in the upper aerodigestive tract (Flanders & Rothman, 1982; Jayant et al., 1977). Tobacco and alcohol represent the major risk factors for the development of hypopharyngeal cancer with more than 90% of patients presenting with a history of tobacco use (Hoffman et al., 1997). Risk increases with both the quantity and duration of tobacco and alcohol use (Menvielle et al., 2004; Tuyns et al., 1988). An increased smoking rate in women resulted in narrowing the gap between genders in some countries (Llatas et al., 2009; Popescu et al., 2010). Also, the early introduction of smoking in the individual habits could be considered as a factor contributing to a downward readjustment of the age of appearance of hypopharyngeal cancer (Lefebvre & Chevalier, 2004). The high rate of synchronous and metachronous primary tumours identified in patients with hypopharyngeal cancer and the concomitant mucosal dysplasia frequently found surrounding primary tumours appear to relate to a field cancerisation effect, which is consistent with widespread exposure to carcinogens (Shah et al., 2008; Slaughter et al., 1953; Van Oijen & Slootweg, 2000).

The importance of the role of genetic factors for the development of head and neck cancer is not fully understood at the present time. Abnormalities of the tumour suppressor gene p53 are common in hypopharyngeal cancer, occurring in up to 70% of patients (Somers et al., 1992). The association between tobacco use and p53 mutations is found in a much larger percentage of smokers and drinkers than that of nonsmokers and nondrinkers (Brennan et al., 1995; Koch et al., 1999; Sorensen et al., 1997). Also, the overexpression of oncogenes at the 11q13 locus appears to be more frequent in hypopharyngeal cancers compared with other head and neck cancer (Muller et al., 1997; Williams et al., 1993). The loss of heterozygosity at 9p and abnormalities in chromosome 11 present in histologically normal mucosa adjacent to hypopharyngeal cancers further support the field cancerisation effect hypothesis (Van der Riet et al., 1994). Mutations in the p21 gene have also been identified in hypopharyngeal cancers (Ernoux-Neufcoeur et al., 2011).

The role of human papilloma virus (HPV) as a contributing factor to carcinogenesis in head and neck squamous cell carcinomas represent an area of active investigation (Fakhry & Gillison, 2006). Although the association of HPV with head and neck cancer, especially with

oropharyngeal tumours has been supported by epidemiologic and molecular biology studies (Franceschi et al., 1996; McKaig et al., 1998), HPV in the carcinogenesis of hypopharyngeal cancer is less well defined. Studies have demonstrated rates of detection of HPV DNA in patients with hypopharyngeal cancer ranging from 20% to 25% (Mineta et al., 1998). However, the clinical implications of the presence of the genome of the oncogenic high-risk HPV types in hypopharyngeal cancer are yet to be defined.

The development of hypopharyngeal cancers in the postcricoid area in women aged 30 to 50 without a history of tobacco or alcohol use is associated with previous Plummer-Vinson syndrome, also termed Patterson-Brown-Kelly syndrome (Goldstein et al., 2008; Kajanti & Mantyla, 1990; Stell et al., 1978). This syndrome is characterised by hypopharyngeal webs, dysphagia, weight loss, and iron-deficiency anemia. Its early diagnosis and treatment with supplemental iron were shown to be effective in stopping further cancer development (Pfister et al., 2009).

A substantial proportion of hypopharyngeal cancers could be attributable to occupational exposures (Menvielle et al., 2004). Possible environmental carcinogens that have been implicated in hypopharyngeal cancer include asbestos and welding fumes (Gustavsson et al., 1998; Marchand et al., 2000; Shangina et al., 2006).

3. Anatomy of the hypopharynx

The hypopharynx is the part of the pharynx that is contiguous superiorly with the oropharynx and is situated posterior and lateral to the larynx. The hypopharynx extends from the superior border of the epiglottis and the pharyngoepiglottic folds from the level of the hyoid bone superiorly to the lower border of the cricoid cartilage inferiorly where it narrows and becomes continuous with the esophagus (Gale et al., 2006; Moore et al., 2010). It is divided into three primary anatomic subsites: the pyriform sinuses, the postcricoid area, and the posterior pharyngeal wall.

The pyriform sinuses are analogous to an inverted pyramids situated lateral to the larynx with their base located superiorly and with the anterior, lateral, and medial walls narrowing inferiorly to form the apices with their tips extending slightly below the cricoid cartilage. It is separated from the laryngeal inlet by the aryepiglottic fold. The superior limit of the base is the pharyngoepiglottic fold and the free margin of the aryepiglottic fold. The lateral wall of the pyriform sinus is formed by the inferior constrictor muscles and the internal branches of the superior laryngeal neurovascular bundle. Its superior aspect is bordered by the thyrohyoid membrane. Inferiorly, it is bounded by the thyroid cartilage. Its medial boundary is the lateral surface of the aryepiglottic fold, arytenoids, and lateral aspect of the cricoid cartilage. The median wall is formed by the lateral surface of the aryepiglottic fold, arytenoids, and lateral aspect of the cricoid cartilage (Moore et al., 2010).

The postcricoid area includes the mucosa that overlies the cricoid cartilage and represents the anterior surface extending from the superior aspect of the arytenoid cartilages to the inferior border of the cricoid cartilage. Inferiorly, it is contiguous with the cervical esophagus. Its important relations are the arytenoids, the cricoarytenoid joints, the intrinsic laryngeal muscles, and inferiorly, below the cricoid, the trachealis muscle and recurrent laryngeal nerves.

Posterior pharyngeal wall extends superiorly from the horizontal level of the floor of the vallecula (the level of the hyoid bone) to the inferior border of the cricoid inferiorly and laterally from the apex of one pyriform sinus to the other being contiguous with the lateral wall of the pyriform sinus. The posterior pharyngeal wall is predominantly comprised of mucosa covering the middle and inferior pharyngeal constrictor muscles. Posteriorly, it is related to the bodies of the third through sixth cervical vertebra. It is separated from the prevertebral fascia by retropharyngeal space. The posterior pharyngeal wall is contiguous with the lateral wall of the pyriform sinus.

There is a rich network of lymphatic channels within the hypopharynx. The first echelon of lymphatic drainage is represented by the upper and midjugular (level II and III) nodes. Lymphatic channels from the pyriform sinuses drain through the thyrohyoid membrane following the superior laryngeal artery to the jugulodigastric, midjugular (level II and III), and retropharyngeal nodes. The lymphatics of the postcricoid area may drain directly to local lymph nodes, may ascend with the lymphatic drainage of the pyriform sinus (levels II and III), but mainly tend to follow the retropharyngeal lymph nodes to the paratracheal, paraesophageal, and lower jugular nodes (level IV and VI), or may occasionally drain down into the superior mediastinum (Clayman & Weber, 1996). Lymphatics of the posterior pharyngeal wall may drain bilaterally, passing to the lateral retropharyngeal nodes including the most cephalad retropharyngeal nodes of Rouviere, or to the upper jugular nodes (level II).

The sensory innervation of the hypopharynx is by the glossopharyngeal and vagus nerves via the pharyngeal plexus, superior laryngeal nerves, and recurrent laryngeal nerves (Moore et al., 2010). The common origin of the auricular nerve of Arnold from the synapsis of the internal branch of the superior laryngeal nerve and the vagal branches from the middle ear in the jugular ganglion results in the phenomenon of referred otalgia seen in patients presenting with hypopharyngeal cancer (Clayman & Weber, 1996). Motor innervation of the hypopharynx is from the pharyngeal plexus and recurrent laryngeal nerves. The arterial supply is derived from the superior laryngeal, lingual, and ascending pharyngeal collateral arteries (Standring, 2004).

4. Patterns of spread and clinical presentation

4.1 Patterns of spread

Hypopharyngeal cancers, particularly those arising in the postcricoid area, have a strong tendency for extensive submucosal spread. The extent of subclinical spread beyond the macroscopic tumour edge is greatest in the inferior direction ranging between 5 and 30 mm (Davidge-Pitts & Mannel, 1983; Hong et al., 2005). The presence of submucosal tumour extension frequently demonstrated in surgical specimens can result in inaccuracy in the estimation of tumour volume. Therefore, the submucosal spread as a characteristic feature for hypopharyngeal cancer should be taken into consideration during the treatment being either surgery or radiotherapy. Pyriform sinus cancers with lateral extension can invade the thyroid cartilage (Kirchner, 1975), but cricoid cartilage and thyroid gland involvement is also possible by the extension through the cricothyroid membrane. Medial extension is associated with invasion of the aryepiglottic folds, preepiglottic and paraglottic space, and intrinsic laryngeal muscles that results in a loss of vocal cord mobility (Kirchner, 1975; Tani

& Amatsu, 1987). Superior tumour extension beyond the lateral pharyngoepiglottic fold into the vallecula can involve the base of the tongue and inferior tumour extension beyond the apex can involve the thyroid gland. Postcricoid tumours tending to grow circumferentially frequently involve the cricoid cartilage, arytenoids and intrinsic laryngeal muscles with resultant vocal cord fixation. Involvement of the recurrent laryngeal nerve can also result in vocal cord immobility. The inferior tumour spread can lead to invasion of cervical esophagus and trachea. Posterior pharyngeal wall tumours with their superior spread may invade the base of the tonsil and the oropharyngeal wall, while inferior extension may be associated with invasion of the postcricoid hypopharynx. These tumours may also invade through the posterior wall to involve the prevertebral fascia and the vertebral bodies.

Lymph node metastases in the neck are associated with even the earliest stages of hypopharyngeal cancer. Metastases in the neck lymph nodes are already present in approximately 70% of patients at the time of presentation with levels II and III being the most frequently affected sites (Lefebvre et al., 1987; Vandenbrouck et al., 1987). Metastases in paratracheal and paraesophageal nodes (level VI) are most commonly present in patients with cancers in the postcricoid area (De Bree et al., 2011; Joo et al., 2010; Timon et al., 2003; Weber et al., 1993). Retropharyngeal lymph node metastases are most frequently present in patients with cancers of the posterior pharyngeal wall and the postcricoid area, but can also be present in those patients who have positive nodes in other levels in the neck (Amatsu et al., 2001; Hasegawa & Matsuura, 1994; Kamiyama et al., 2009). Apart from the high incidence of clinically apparent regional spread, another striking problem is the presence of occult nodal disease in high percentage of patients with hypopharyngeal primaries. Thus, in patients with clinically positive neck, the incidence of bilateral occult lymph node metastases is at least 50% (Byers et al., 1988; Buckley & MacLennan, 2000). The reported percentage of occult contralateral neck metastases in patients with pyriform sinus cancer and ipsilateral metastatic neck nodes involvement is 77% (Aluffi et al., 2006). Bilateral occult lymph node metastases in patients with clinically negative neck are most frequently associated with cancers of the pyriform sinus (Buckley & MacLennan, 2000; Koo et al., 2006). The risk of occult lymph node metastases at levels IV and V in patients with clinically negative neck is low, whereas in patients with clinically positive neck is more than 20% (Byers et al., 1988; Buckley & MacLennan, 2000; Gregoire et al., 2000). Occult nodal disease in ipsilateral paratracheal lymph nodes has been reported in 20% of patients with tumours arising from postcricoid area or pyriform sinus apex presenting with clinically negative neck (Buckley & MacLennan, 2000).

Distant metastases at presentation are more common in hypopharyngeal cancers than in other head and neck cancers. At the time of clinical diagnosis distant metastatic disease is present in approximately 17% of hypopharyngeal cancers (Hsu & Chen, 2005; Spector, 2001). The frequency of distant metastatic development in patients with hypopharyngeal cancer during the course of the disease is also among the highest of all head and neck cancers. In the ten years experience of treatment for advanced hypopharyngeal cancer reported by Hirano et al. (Hirano et al., 2010), approximately half of the recurrences was distant metastatic disease. The most common site for distant metastases is the lung. According to Spector et al. (Spector et al., 2001), development of distant metastases at some time following initial treatment is associated with tumour recurrence at the primary site, or neck metastases.

4.2 Clinical presentation

Early hypopharyngeal cancers produce a mild, nonspecific sore throat or vague discomfort on swallowing. In these patients, globus sensation can be the only complaint with normal clinical findings (Tsikoudas et al., 2007). However, the majority of patients with cancers of the hypopharynx presents with advanced local and/or regional disease and provide a history of significant tobacco or alcohol use. Most patients have also poor dentition and halitosis. Predominating symptoms are those related to the locoregional disease spread including sore throat, odynophagia and dysphagia, weight loss, and a mass in the neck. Referred otalgia (external auditory canal pain) frequently present in patients with pyriform sinus cancers may be referred via the superior laryngeal nerve through the auricular branch of the vagal nerve (Arnold's nerve). Development of hoarseness (vocal cord paralysis) may be a result of either direct invasion of the larynx or involvement of recurrent laryngeal nerve indicating more advanced disease. A "hot potato" voice may be due to the involvement of the base of the tongue. Approximately 50% of patients present with palpable neck lymphadenopathy as the only complaint on initial clinical examination (Keane, 1982; Uzcudun et al., 2001).

5. Diagnosis, staging, and prognosis

5.1 Diagnosis

Pretreatment diagnostic workup of hypopharyngeal cancer starts with a complete medical history with attention paid to disease-related signs and symptoms, and continues with clinical examination and endoscopy including indirect mirror exam and fiberoptic endoscopy under local anesthesia. Clinical and endoscopic assessment should be focused on determining the extent of the primary tumour and laryngeal mobility. Endoscopy can often easily reveal tumours arising in the upper pyriform sinus and the posterior pharyngeal wall, whereas for tumours located in the apex of the pyriform sinus and obscured by pooled secretions, and for those arising in postcricoid area and causing significant arytenoid edema, the visualisation of the tumour during endoscopy is much more difficult. Panendoscopy under general anesthesia allows the physician a thorough evaluation of the entire upper aerodigestive tract with consequent precise assessment of the macroscopic extent of the primary tumour as well as detection of synchronous primary tumours. Detection of regional disease is obtained by careful examination of both sites of the neck.

Imaging studies including computed tomography (CT) and/or magnetic resonance imaging (MRI) and/or positron emission tomography (PET)/CT of the head and neck region are required to define the extent of the disease at the primary site in surrounding structures, such as the paralaryngeal space, preepiglottic space, laryngeal cartilages, extralaryngeal soft tissue, prevertebral space, and parapharyngeal space, and also to evaluate the extent of the disease in regional lymph nodes. Imaging studies are primarily helpful for staging the primary tumour and neck, but may also help in determining mediastinal spread and distant metastatic disease in the lung and can also inform on possible synchronous tumours in the upper aerodigestive tract. Fluorodeoxyglucose-PET (FDG-PET) scans, although not routinely indicated, may be helpful in the evaluation of locally advanced hypopharyngeal cancer. Histological confirmation is mandatory for the diagnosis of hypopharyngeal cancer.

Biopsy of primary tumour site is usually performed during endoscopic examination under anesthesia. If a neck adenopathy is present, ultrasound with a fine-needle aspiration or core biopsy is performed obtaining sufficient tumour to confirm diagnosis of suspicious metastatic lymph node. More than 95% of hypopharyngeal malignancies are squamous cell carcinomas which are often poorly differentiated. Uncommon nonsquamous cell malignancies include adenocarcinoma, composing the majority of the remaining 5% of the primary hypopharyngeal tumours, as well as lymphoma, and other rare neoplasms such as malignant fibrous histiocytoma, liposarcoma, fibrosarcoma, chondrosarcoma, and mucosal malignant melanoma.

Pretreatment evaluations should also include routine laboratory studies (a complete blood count, basic blood chemistry, liver function tests, and renal function tests), chest x-ray, and liver ultrasound. Swallowing and nutrition status should be also evaluated. When radiotherapy planned, preventive dental care and dental extractions should be dealt with 10 to 14 days prior to treatment commencement.

5.2 Staging

The accepted standard for staging of hypopharyngeal squamous cell carcinoma is represented by the American Joint Committee on Cancer (AJCC) Tumour Node Metastasis (TNM) staging system (Edge & Byrd, 2009) (Table 1). Clinical staging is based on data from medical history, clinical examination, endoscopy, and imaging studies. Regarding the primary tumour, the AJCC staging system does not differentiate the specific tumour subsite. Regional lymph nodes staging and stage grouping is identical to other sites within the oral cavity and pharynx with exception of nasopharynx. Pathologic staging is based on findings from clinical staging and data included in the report of histopathological analysis for resected specimen including the type, size, and grade of the primary tumour, the pattern of invasion, the minimum resection margin, the regional lymph nodes status, and the presence of nodal extracapsular extension.

5.3 Prognostic factors

Overall stage grouping (anatomic stage), stage of primary tumour (T stage), and stage of regional lymph nodes (N stage) are important prognostic factors for cancer of the hypopharynx. Regarding the data from literature concerning prognostic factors for hypopharyngeal cancer, it is apparent that the results of the analysis of different authors are not consistent. Thus, some authors showed nodal staging as the most important independent prognostic factor (Keane et al., 1983; Pivot et al., 2005; Sakata et al., 1998), whereas other authors confirmed the statistical significance of T stage (Toita et al., 1996; Tsou et al., 2006). According to some authors, overall stage grouping remains the most important determinants of outcome (Barzan et al., 1990; Gupta et al., 2009a), while other authors revealed T stage and N stage as dominant prognostic factors in hypopharyngeal cancer (Hall et al., 2009; Johansen et al., 2000; Spector et al., 1995; Wygoda et al., 2000).

Age and gender have been also shown to have prognostic significance in hypopharyngeal cancer with increased age and male gender negatively influencing patients' outcome (Nishimaki et al., 2002; Rapoport & Franco, 1993; Spector et al., 1995).

Primary tumour (T)	
TX:	Primary tumour cannot be assessed
T0:	No evidence of primary tumour
Tis:	Carcinoma in situ
T1:	Tumour limited to one subsite of hypopharynx and/or 2 cm or less in greatest dimension
T2:	Tumour invades more than one subsite of hypopharynx or an adjacent site, or measures more than 2 cm, but not more than 4 cm in greatest dimension without fixation of hemilarynx
T3:	Tumour more than 4 cm in greatest dimension or with fixation of hemilarynx or extension to esophagus
T4a:	Moderately advanced local disease. Tumour invades thyroid/cricoid cartilage, hyoid bone, thyroid gland, or central compartment soft tissue*
T4b:	Very advanced local disease. Tumour invades prevertebral fascia, encases carotid artery, or involves mediastinal structures
*Note:	Central compartment soft tissue includes prelaryngeal strap muscles and subcutaneous fat
Regional lymph nodes (N)	
Nx:	Regional lymph nodes cannot be assessed
N0:	No regional lymph node metastasis
N1:	Metastasis in a single ipsilateral lymph node, 3 cm or less in greatest dimension
N2:	Metastasis in a single ipsilateral lymph node, more than 3 cm but not more than 6 cm in greatest dimension; or in multiple ipsilateral lymph nodes, not more than 6 cm in greatest dimension; or in bilateral or contralateral lymph nodes, not more than 6 cm in greatest dimension
N2a:	Metastasis in a single ipsilateral lymph node more than 3 cm but not more than 6 cm in greatest dimension
N2b:	Metastasis in multiple ipsilateral lymph nodes, not more than 6 cm in greatest dimension
N2c:	Metastasis in bilateral or contralateral lymph nodes, not more than 6 cm in greatest dimension
N3:	Metastasis in a lymph node, more than 6 cm in greatest dimension
Distant metastasis (M)	
M0:	No distant metastasis
M1:	Distant metastasis
Anatomic stage/prognostic groups	
0:	Tis N0 M0
I:	T1 N0 M0
II:	T2 N0 M0
III:	T3 N0 M0, T1-T3 N1 M0
IVA:	T4a N0 M0, T4a N1 M0, T1-T3 N2 M0, T4a N2 M0
IVB:	Any N M0, Any T N3 M0
IVC:	Any T Any N M1

Table 1. American Joint Committee on Cancer (AJCC) TNM classification of hypopharyngeal cancer

Several pathologic factors have been demonstrated to impact upon outcome in surgical treatment of hypopharyngeal cancer (Hall et al., 2009; Lee et al., 2008; Mochiki et al., 2007). Several studies reported the adverse impact of advanced stage, (Dinshaw et al., 2005; Hall et al., 2009; Lee et al., 2008; Mochiki et al., 2007), nodal extracapsular extension (Vandenbrouck et al., 1987; Lee et al., 2008), perineural invasion (Bova et al., 2005), and lymphovascular invasion (Bova et al., 2005; Mochiki et al., 2007). Increasing pathological nodal stage (Chu et al., 2008; Hall et al., 2009; Mochiki et al., 2007), and quality of tumour clearance were also revealed as significant prognostic factors (Gupta et al., 2010; Nishimaki et al., 2002).

Tumour volume is the most important prognostic factor of treatment outcome for patients with advanced hypopharyngeal cancer treated with concurrent chemoradiotherapy and should always be taken into consideration in treatment planning (Plataniotis et al., 2004; Tsou et al., 2006). Thus, confirming the significance of gross tumour volume as the only independent prognostic factor for treatment outcome, Chen et al. (Chen et al., 2009) concluded that pretreatment CT-based gross tumour volume measurements could be considered as strong predictor of local control and survival in patients with advanced stage hypopharyngeal cancers treated with concurrent chemoradiotherapy. For this patients category, low pretreatment hemoglobin level (Lee et al., 1998; Prosnitz et al., 2005) and age older than 70 years (Pignon et al., 2009) were revealed as negative prognostic factors.

6. Treatment of hypopharyngeal cancer

6.1 Treatment of small lesions (T1N0-1 and small T2N0)

Early-stage hypopharyngeal cancers include most T1N0-1 and small T2N0 cancers that do not require total laryngectomy. Patients with small lesions of the hypopharynx constitute approximately 20% of all patients presenting with hypopharyngeal cancer (Spector et al., 2001). Conservation surgery or radiotherapy alone are considered effective treatment modalities for patients who present with T1N0-1 and selected T2N0 obtaining satisfactory rates of local control while optimising functional outcome (Allal, 1997; Jones et al., 1994; Jones & Stell, 1991). However, discrepancies exist among different authors in the choice of treatment approach for early hypopharyngeal lesions. Thus, some authors advocate conservation surgery with or without postoperative radiotherapy whereas other authors advocate radiotherapy alone. The study conducted by Groupe d'Etude des Tumeurs de la Tête et du Cou (GETTEC) (Foucher et al., 2009), supported conservation surgery procedures in patients with T1 or T2N0 hypopharyngeal lesions showing that transoral approach or partial pharyngolaryngectomy led to completely satisfactory results in terms of survival and locoregional control. Comparing the effect of surgery or radiotherapy in the treatment of postcricoid carcinoma, Axon et al. (Axon et al., 1997) recommended surgery as a better method of improving survival, especially in patients with no nodal disease. El Badawi et al. (El Badawi et al., 1982) reviewing patients with cancer of the pyriform sinus treated with radiotherapy, surgery, or surgery and postoperative radiotherapy, concluded that superficial lesions without vocal cord mobility impairment were suitable for definitive radiotherapy. Similar conclusion regarding the effectiveness of radiotherapy alone in the management of small tumours in the postcricoid area with no clinical evidence of neck lymph node metastasis was drawn by Stell et al. (Stell et al., 1982). Levebvre & Lartigau (Levebvre & Lartigau, 2003), considering surgery and radiotherapy as approaches comparable in terms of local control and functional results in early hypopharyngeal cancer,

emphasized that the impressive improvement in radiotherapy techniques unequivocally enabled the acceptance of radiotherapy as an indisputable alternative to surgery. Furthermore, additional arguments supporting definitive radiotherapy as a treatment of choice for small hypopharyngeal tumours are the expected superior functional outcome (Freeman et al., 1979; Marks et al., 1978), the necessity for postoperative radiotherapy because of positive resection margin or extracapsular spread of nodal disease with its related morbidity following conservation surgery, and the need for elective irradiation of the lymph nodes in the neck when elective dissection had not been performed during the surgical procedure. The selection of patients for conservation surgical procedures or radiotherapy as a primary treatment modality must be carefully accomplished. Because of the lack of studies that analyse and compare the results of conservation surgery and definitive radiotherapy in terms of local control and functional outcome in patients with early hypopharyngeal cancers, the decision for adoption of one of these two treatment modalities should incorporate a complex assessment of the extent and volume of tumour and expected response to treatment modalities, patient age and physical status, patient preference including occupational considerations, patient compliance, prior head and neck malignancy, risk for second head and neck primary cancer, the ability to deliver an adequate radiotherapy, or the expertise of the surgical team to effectively realise conservation surgery, treatment cost, and physician and institutional bias.

6.1.1 Surgery

Summarising the results of surgery reported in published series, Levebvre (Levebvre, 2000) revealed that the treatment of early hypopharyngeal cancers with properly selected conservation surgical procedure provides a 5-year local control ranging between 90% and 95% with a 5-year larynx function preservation ranging between 85% and 100%. For the small lesions of the pyriform sinuses, partial pharyngectomy or partial pharyngolaryngectomy should be considered. The indications for conservation surgery are represented by the absence of gross tumour involvement and impaired mobility of vocal cords and arytenoids, as well as by the absence of thyroid cartilage invasion and involvement of the apex of the pyriform sinus and postcricoid area (Freeman et al., 1979; Marks et al., 1978). Additionally, attention must be paid to the possible caudal, contralateral, and extralaryngeal extension, and soft tissue invasion. In selected patients with T1 and T2 lesions of the medial wall of the pyriform sinus a supracricoid hemilaryngopharyngectomy is advocated (Freeman et al., 1979; Laccourreye et al., 1987). In patients with T1 and T2 lesions of the lateral wall of the pyriform sinus, partial pharyngectomy through a lateral approach is indicated. Partial pharyngectomy through a transhyoid pharyngotomy, posterior pharyngectomy, or lateral pharyngotomy are conservation surgery procedures that allow the excision of T1 and small T2 lesions confined to the posterior wall of the hypopharynx. The lateral pharyngotomy as an approach that allows access to all subsites of the hypopharynx is also very suitable for small tumours of the posterior pharyngeal wall. Median labiomandibular glossotomy and transoral approach can also be employed for small lesions of the posterior pharyngeal wall. The reconstruction following excision of larger posterior wall lesions involves a free vascularised graft (Jol et al., 2003; Schwager et al., 1999). Tumours arising in the postcricoid area are usually presented as advanced lesions. Surgical excision followed by postoperative radiation is the treatment of choice for cancers not amenable to a conservation protocol (i.e., tumours destroying cartilage, tumours too

bulky for control with primary radiation). The minimum operation recommended is total laryngectomy and partial pharyngectomy and pharyngoesophagectomy with reconstruction if extension into the esophagus is present. In several studies analysing the results obtained with partial surgery in patients with early cancer of the pyriform sinus the reported 5-year survival rates range between 47% and 83% (Barton, 1973; Chevalier et al., 1997; Laccourreye et al., 1993; Makeieff et al., 2004; Marks et al., 1978). Partial pharyngolaryngectomy also resulted in a 5-year local recurrence rate below 5% (Chevalier et al., 1997; Laccourreye et al., 1993). In the retrospective study of Vandenbrouck et al. (Vandenbrouck et al., 1987), the reported rate of locoregional control was 89% in patients with T1 and T2 cancers of the pyriform sinus treated with conservation surgery. In the retrospective study of Pene et al. (Pene et al., 1978), primary surgery and postoperative radiotherapy in patients with early lesions of posterior pharyngeal wall (T1 and T2) resulted in 5-year survival rate of 30%. In the study of Jones et al. (Jones et al., 1995), the results of surgery and radiotherapy alone in patients with carcinoma of the postcricoid area showed no significant difference in the observed tumour-specific five-year survival rates between surgery and radiotherapy group.

The transoral laser endoscopic resection is a new conservation surgical approach suitable for T1 and T2 exophytic, highly differentiated squamous cell carcinomas of the upper part of the hypopharynx without extension to the apex of the pyriform sinus or to the postcricoid area (Glanz, 1999; Rudert & Hoft, 2003; Vilaseca et al., 2004). Few non-randomised studies evaluating transoral laser surgery in hypopharyngeal cancer reported 5-year overall survival rate of approximately 70% (Foucher et al., 2009; Rudert et al., 2003; Steiner et al., 2001), and local control rate at 5 years ranging between 82% and 90% (Foucher et al., 2009; Steiner et al., 2001).

Hypopharyngectomy by transoral robotic surgery as a procedure proposed to minimise the treatment-related morbidity following conventional surgical approaches for T1 or T2 lesions arising in the pyriform sinus analysed in terms of efficacy and feasibility has been also shown to be a safe technique for the treatment of early hypopharyngeal cancer (Park et al., 2010).

6.1.2 Radiotherapy

The use of radiotherapy as a single treatment approach for small hypopharyngeal lesions (T1N0-1 and small T2N0) offers treatment for both the primary tumour and the neck, thereby obviating the need for neck dissections and their associated morbidity. Definitive radiotherapy could be considered as treatment of choice for non-circumferential postcricoid lesions allowing organ preservation and a reasonable probability of cure and restoration of swallow. Additionally, definitive radiotherapy could be effectively employed in patients who refuse surgery or who are poor surgical candidates because of underlying medical conditions.

Several non-randomised controlled trials exploring the role of definitive radiotherapy in the treatment of early hypopharyngeal cancer, reported local control rates for T1 lesions arising from pyriform sinus ranging between 60% and 100% (Bataini et al., 1982; Mendenhall et al., 1987a; Million & Cassisi, 1981). However, in the reported update of the University of Florida experience with early pyriform sinus cancer, the involvement of the apex of the pyriform sinus and the high probability for early cartilaginous involvement was shown to

significantly reduce local control for T1 lesions (Amdur et al., 2001). The rates of local control also decrease in bulky T2 lesions and in those larger than 2.5 cm (Pameijer et al., 1998; Mendenhall et al., 1987b). The published data for hypopharyngeal sites other than pyriform sinus are more limited. Most of the studies reporting results of definitive radiotherapy in patients with carcinoma of the pharyngeal wall included lesions arising from both hypopharynx and oropharynx, and there is also a lack of randomised controlled trials exploring the role of definitive radiotherapy in early hypopharyngeal cancer arising in the postcricoid area. In the study of Fein et al. (Fein et al., 1993), the achieved 2-year local control rates for T1 and T2 pharyngeal wall cancer treated with definitive radiotherapy using conventional fractionation were 100% and 67%, respectively. Meoz-Mendez et al. (Meoz-Mendez et al., 1978) analysing the results of irradiation in the treatment of cancers of the pharyngeal walls emphasized that the recurrence rate at the primary site was associated with increasing T stage, while Talton et al. (Talton et al., 1981) considered radiotherapy as the most effective treatment in the posterior wall lesions. In a series of Farrington et al. (Farrington et al., 1986), a significant survival rate decrease in lesions of the postcricoid area more than 2 cm in length was observed following radiotherapy alone. The disease-free survival in patients who completed radiotherapy was 66% and 21% in stages I and II, respectively. In the study of Garden et al. (Garden et al., 1996), the observed 2-year local control rates in patients with early stage hypopharyngeal cancer from all sites treated with definitive radiotherapy were 89% for T1 lesions and 77% for T2 lesions. Nakamura et al. (Nakamura et al., 2006) reported 5-year local control rates of 85% and 65% for T1 and T2 hypopharyngeal lesions. The observed overall survival at 5 years for stage I and II hypopharyngeal cancer from all sites treated by radiotherapy alone ranged between was 40% and 78% (Pingree et al., 1987; Van Mierlo et al., 1995). In summary, primary conventionally fractionated radiotherapy for T1-2 hypopharyngeal cancers results in a 2-year local control rate of 89-100% for T1 tumours and 60-70% for T2 tumours (Fein et al., 1993; Garden et al., 1996; Van Mierlo et al., 1995). In order to improve local control rates in patients with early hypopharyngeal lesions treated with definitive radiotherapy, altered fractionation regimens were also explored by several authors. It was shown that hyperfractionation and accelerated fractionation significantly improve the local control of hypopharyngeal cancers of T2 or greater, and possibly also for T1 tumours. (Fu et al., 2000; Garden et al., 1996 ; Nübe et al., 2003 ; Parsons et al., 1984 ; Rosenthal & Ang, 2004).

The employment of postoperative radiotherapy is recommended in the presence of microscopically involved surgical margins being a pathological feature predicting a high-risk for local recurrence (Cooper et al., 1998). Postoperative concurrent chemoradiotherapy is recommended in the presence of multiple high-risk factors represented by close or positive margins of resection, lymphatic and vascular embolism, perineural infiltration, and cartilage invasion (Bernier et al., 2004; Cooper et al., 2004).

6.1.3 Neck management

Neck management in patients with early hypopharyngeal cancer is also indicated because of the high risk of lymph node metastases (Layland & Sessions, 2005). Elective neck irradiation and elective neck dissection including retropharyngeal nodes are equally and highly effective in managing subclinical neck disease providing regional control of more than 90% (Ambrosch et al., 2001; Bataini, 1993; Pillsbury et al., 1997). Neck lymph node dissection

should be performed according to the definitions of the American Academy of Otolaryngology Head and Neck Surgery (AAOHNS) (Robbins et al., 2008). In patients with clinically negative neck, ipsilateral selective neck dissection for lateralised lesions or bilateral selective neck dissection for midline lesions of levels II, III, IV is performed. Neck dissection in clinically N0 patients represents a procedure that has therapeutic value by removal of occult metastatic disease. Neck dissection identifies subclinical nodal disease and, based on pathologic staging, allows the selective use of postoperative concurrent chemoradiotherapy in cases with pathologically proven multiple metastases or nodal extracapsular extension (Pillsbury et al., 1997; Clayman & Frank, 1998). Nodal disease in patients with clinically positive neck (N1) is treated with ipsilateral or bilateral radical neck dissection that refers to the removal of all lymph nodes from levels I through V. Retropharyngeal nodes could be also resected at the time of partial pharyngectomy in patients with radiographic evidence of metastases in this lymph node group. Investigating the significance of dissection of retropharyngeal nodes in hypopharyngeal cancer, Kamiyama R et al. (Kamiyama et al., 2009) concluded that in order to improve prognosis, this dissection should be recommended at the time of primary surgical treatment in cancers whose primary subsites are posterior wall or pyriform sinus.

Patients with clinical N0 disease are eligible for elective radiotherapy of the neck encompassing bilateral lymph nodes in levels II, III and IV. Elective treatment of level VI is indicated for patients with cancer of the pyriform sinus (particularly those located in the apex) and postcricoid area, and for those with esophageal involvement. Elective treatment of the retropharyngeal lymph nodes is indicated for cancer of the posterior pharyngeal wall or postcricoid area, and for those with invasion of the posterior pharyngeal wall from other sites (Gregoire et al., 2003). The determination of the target volume of elective radiotherapy of the neck should follow the consensus guidelines developed by the European Organization for Research and Treatment of Cancer/Radiation Therapy Oncology Group/Danish Head and Neck Cancer Group (EORTC/RTOG/DAHANCA) (Gregoire et al., 2003). According to the recommendations given by Gregoire et al. (Gregoire et al., 2006) for selection and delineation of the levels of lymph nodes for elective irradiation in patients with clinically positive neck and in those with positive neck nodes determined in the surgical specimen following neck dissection, the levels that should be electively treated are I, II, III, IV, V and retropharyngeal nodes, and level VI for esophageal extension. Retrostyloid space should be also included in cases with positive lymph node in Level II whereas supraclavicular fossa should be electively irradiated if there were positive nodes in level IV or V. Given the radiotherapy as primary treatment approach in patients with positive lymph node smaller than 3 cm (N1), it should be mentioned that although there are data from the literature showing that using conventional fractionation, regional control could be achieved in 75%-90% of cases (Bataini et al., 1990; Mendenhall et al., 1984; Taylor et al., 1991), some authors reported lower rates of regional control observed in their studies. Thus, in the study of Johansen et al. (Johansen et al., 2000), definitive radiotherapy resulted in 5-year regional control of 36% for N1 disease. Similar results were found in the retrospective review of patients with hypopharyngeal cancers treated with definitive radiotherapy performed by Gupta et al. (Gupta et al., 2009a) with 3-year locoregional control rate of 41% in patients with N1 disease.

6.2 Surgery and postoperative radiotherapy in locally-regionally advanced resectable lesions

In order to improve outcome in patients with advanced stage resectable hypopharyngeal cancer (T2N1-3M0, T3-4N0-3M0), the role of postoperative radiotherapy following nonconservation surgery became a subject of analysis in many single-institution studies. An improvement in overall and disease-free survival was obtained in patients with locally-regionally advanced hypopharyngeal cancer if combined treatment modality with radical surgery consisting of total laryngectomy, total or partial pharyngectomy and unilateral or bilateral neck dissection followed by radiotherapy was used. Thus, in the 1970s and 1980s, surgery (i.e., total laryngectomy and pharyngectomy with or without neck dissection) followed by postoperative radiotherapy was the standard form of therapy for advanced stage disease (Arriagada et al., 1983; Mirimanoff et al., 1985) with reported 5-year survival rates varying between 19% and 48% (Elias et al., 1995; Kim et al., 2001; Kraus et al., 1997; Lajtmam & Manestar, 2001; Pingree et al., 1987). Comparing the results of total pharyngolaryngectomy, neck dissection, and postoperative radiotherapy in patients with squamous cell carcinoma of the pyriform sinus with those obtained by surgery alone, El Badawi et al. (El Badawi et al., 1982) showed an increased locoregional recurrence rate after surgery alone (39%) as opposed to that following combined therapy (11%). In the analysis of Frank et al. (Frank et al., 1994) surgery and postoperative radiotherapy was found to improve survival in patients with advanced hypopharyngeal cancer. Survival rates at five years for postoperative radiotherapy group and for surgery alone group were 48% and 18%, respectively. Lee et al. (Lee et al., 2008) reported that total laryngectomy with partial or total pharyngectomy with unilateral or bilateral radical neck dissection and postoperative radiotherapy resulted in 3-year local control, disease-free survival, and overall survival rate of 44%, 44%, and 39%, respectively. However, there are some conflicting data in the literature regarding the role of adjuvant radiotherapy. Thus, Yates et al. (Yates et al., 1984), analysing the impact of addition of adjuvant radiotherapy following surgery on survival of patients with squamous cell carcinoma of the pyriform sinus, found that the surgery alone group demonstrated the best results with 5-year survival rate of 56% as compared to 33% for the groups treated with pre- or postoperative radiotherapy. Worse outcome in patients with hypopharyngeal cancer treated with surgery and postoperative radiotherapy as compared with those treated with surgery or radiotherapy alone was also found in the study of Pingree et al. (Pingree et al., 1987). The reported 5-year survival rates for surgery alone, surgery and postoperative radiotherapy, and radiotherapy alone were 40%, 32%, and 11%, respectively.

The prognosis of patients with primary hypopharyngeal tumour and extensive and/or large lymph node metastases is highly determined by the N stage. Radiotherapy or surgery alone in the treatment of advanced nodal disease (N2-3) resulted in poor rates of regional control and survival (Gupta et al., 2009a; Johansen et al., 2000; Lou et al., 2008). In 1988, Teshima et al. (Teshima et al., 1988), analysing the results of radiotherapy in hypopharyngeal cancer with special attention paid to the nodal control, pointed out the role of postoperative radiotherapy in obtaining an effective nodal control for patients with clinically positive nodes. The use of postoperative radiotherapy following neck lymph node dissection is recommended for patients with N2 and N3 disease. Data from literature show improved regional control even in patients with very advanced nodal disease when postoperative

radiotherapy was used following radical neck dissection (Ambrosch et al., 2001; Lundahl et al., 1998; Richards & Spiro, 2000; Smeele et al., 2000). Postoperative radiotherapy in patients with resectable locally and/or regionally advanced hypopharyngeal cancer should be prescribed to the entire operative bed and draining nodes. The determination of the target volume of elective radiotherapy of the neck should follow the proposal for delineation of the nodal clinical target volume in the node positive and postoperative neck by Gregoire et al. (Gregoire et al., 2006) (see section 6.1.3). According to the European Society for Medical Oncology (ESMO) clinical recommendations for treatment of squamous cell carcinoma of the head and neck, the standard option for advanced resectable hypopharyngeal cancers is represented by surgery and postoperative radiotherapy in patients without high-risk pathological features found at surgery (Pivot & Felip, 2008). However, despite such radical therapy leading to the loss of natural speech function and impairment of swallowing ability with a consequent negative impact on the quality of life, cure rates for advanced disease remained low with reported 5-year survival rates varying between 20% and 50% (Beauvillain et al., 1997; Hoffman et al., 1998; Johansen et al., 2000; Kim et al., 2004; Lajtmam & Manestar, 2001).

The confirmed negative influence of high-risk pathological features represented by surgical margins microscopically involved, extracapsular extension in positive lymph node, two or more positive lymph nodes, vascular embolism and perineural infiltration on patients outcome following surgery and postoperative radiotherapy (Ang et al., 2001), emerged the need for investigation of different treatment approaches including concomitant use of chemotherapy. Two similar, large-scale, postoperative randomised independent trials designed by the EORTC and RTOG were conducted to evaluate the role of high dose concurrent chemoradiotherapy in the postoperative treatment of high risk head and neck tumours (Bernier et al., 2004; Cooper et al., 2004). Both trials evaluated the role of concomitant cisplatin given every 3 weeks (100 mg/m² on days 1, 22, 43) during radiotherapy course (Table 2). Retrospective analysis of data from both trials, revealed that extracapsular extension of nodal disease and/or microscopically involved surgical margins were the only risk factors for which the impact of concurrent chemoradiotherapy was significant in both trials (Bernier & Cooper, 2005). In 2004, National Cancer Institute (NCI) level I evidence for recommendation was established, because both studies demonstrated that adjuvant concurrent chemoradiotherapy was more efficacious with respect to radiotherapy alone in terms of locoregional control and disease-free survival (Bernier & Cooper, 2005). Currently, concurrent chemoradiotherapy with single agent platinum should be the gold standard for those patients found at surgery to have high-risk features (extracapsular extension and positive margins of resection) (Pivot et al., 2008).

Based on the assumption that surgery may be a trigger of accelerated proliferation of remaining tumour cells, two phase III trials conducted to investigate the role of accelerated fractionation in the postoperative setting compared to conventionally fractionated postoperative radiotherapy (Ang et al., 2001; Sanguineti et al., 2005) failed to demonstrate any significant improvement of locoregional control and survival with accelerated postoperative radiotherapy. However, when in a phase III trial a weekendless continuous accelerated hyperfractionation postoperative radiotherapy (CHARTWEL) was employed in advanced squamous cell carcinoma of the oral cavity, larynx and hypopharynx who underwent radical surgery, the overall treatment time was shortened to only 12 days

compared with conventionally fractionated radiotherapy (Awwad et al., 2002). The data from this trial revealed significantly better 3-year locoregional control rate in the accelerated fractionation group than in the conventional fractionation group (88% and 57%, respectively) suggesting that accelerated proliferation could be considered an important determinant of treatment outcome.

<i>Trial</i>	DFS	OS	LRFR
Bernier et al. (Bernier et al., 2004), (EORTC 22931)	(5-year estimates)	(5-year estimates)	(5-year estimates)
Experimental arm:	47% (p=0.04)	53% (p=0.02)	17% (p=0.007)
Control arm:	36%	40%	31%
Cooper et al. (Cooper et al., 2004), (RTOG 9501)	(2-year estimates)	(2-year estimates)	(2-year estimates)
Experimental arm:	54% (p=0.04)	64% (p=0.19)	18% (p=0.01)
Control arm:	45%	57%	28%

EORTC: European Organization for Research and Treatment of Cancer; DFS: disease-free survival; OS: overall survival; LRFR: locoregional failure rate; RTOG, Radiation Therapy Oncology Group

Table 2. Comparative analysis of treatment outcome in EORTC trial 22931 and RTOG trial 9501

6.3 Definitive treatment for anatomic and functional organ preservation in locally-regionally advanced resectable lesions

Primary definitive therapy in patients with advanced resectable hypopharyngeal cancers requiring total laryngectomy and partial or total pharyngectomy can also be realised with treatment modalities allowing organ preservation. Strategies employed to increase locoregional control and survival attempting at the same time to achieve anatomic and functional organ preservation include concurrent chemoradiotherapy, altered fractionation radiotherapy, intensified radiotherapy regimens in combination with chemotherapy, induction chemotherapy followed by radiotherapy, and targeted therapy using cetuximab. Concurrent drug-enhanced radiotherapy i.e. concurrent chemoradiotherapy (in relatively healthy patients) and altered fractionation radiation regimens (in relatively unfit patients), are considered best established as organ preservation approaches for cancers arising from hypopharynx and other sites in the head and neck region (Adelstein et al., 2000; Forastiere et al., 2001a; Fu et al., 2000; Koch et al., 1995; Pignon et al., 2000).

6.3.1 Concurrent chemoradiotherapy

Concurrent chemoradiotherapy as definitive treatment for advanced head and neck cancers including those arising from the hypopharynx has been studied in the past 15 years. However, due to the low incidence, hypopharyngeal cancers grouped with other head and neck cancers usually represented only smaller subgroups with details of their treatment being rarely specifically reported (Tai et al., 2008; Robson, 2002). The rarity of this disease, and the time needed for data collection could be accepted as an explanation for the absence

of multicenter randomised clinical trials undertaken to evaluate the role of concurrent chemoradiotherapy in the treatment of advanced hypopharyngeal cancer. In 1990 Sanchiz et al. (Sanchiz et al., 1990) reported the results of a prospective randomised trial on 859 patients with advanced head and neck cancer including those having hypopharynx as a primary site. Patients were randomly assigned to receive conventionally fractionated radiotherapy, radiotherapy with standard fractionation with concomitant use of 5-fluorouracil or hyperfractionated radiotherapy. Significant improvement in survival compared with the group treated with conventional fractionation was obtained in groups treated either with concurrent chemoradiotherapy or altered fractionation (Table 3). Adelstein et al. (Adelstein et al., 2000) reported a single institution trial that enrolled 100 patients with stages III and IV squamous cell head and neck carcinoma. Patients were randomly assigned to receive conventionally fractionated radiotherapy alone or with concurrent chemotherapy consisting of two cycles of cisplatin and 5-fluorouracil. Planned neck dissection was encountered for patients with N2 and N3 disease. A significant improvement in the rates of local control (77% vs. 45%, $p < 0.001$), distant metastasis-free survival (84% vs. 75%, $p = 0.09$), and 5-year recurrence-free survival (62% vs. 51%, $p = 0.04$) was obtained with concurrent chemoradiotherapy (Table 3). The superiority of concurrent chemoradiotherapy in the improvement of overall survival in patients with advanced head and neck cancer has been confirmed in several meta-analyses (Browman et al., 2001; El-Sayed & Nelson, 1996; Munro, 1995; Pignon et al., 2000). The results of meta-analysis reported by Munro (Munro, 1995), and the results of meta-analysis of El-Sayed and Nelson (El-Sayed & Nelson, 1996) showed a statistically significant improvement in survival for chemotherapy given concurrently with radiotherapy. The largest meta-analysis performed by the Meta-Analysis of Chemotherapy on Head and Neck Cancer (MACH-NC) Collaborative Group and published by Pignon et al. (Pignon et al., 2000) in 2000, evaluated individual patient data from 63 randomised trials excluding trials on nasopharyngeal carcinoma. This meta-analysis confirmed the superiority of the overall use of chemotherapy with 5% improvement in 5-year overall survival with highest increase in survival with use of concurrent chemoradiotherapy (8% at 5-years; $p < 0.0001$). There was also an evident benefit when cisplatin was used in the combined approach. In patients over 70 years the benefit was less evident. In the updated meta-analysis published in 2004 (Bourhis et al., 2004), 24 new trials, most of them on concurrent chemoradiotherapy, were included totalising 87 trials and 16,000 patients. The update confirmed survival benefit of 8% at 5 years ($p < 0.0001$) of concurrent chemoradiotherapy. This updated analysis also confirmed the higher magnitude of the benefit for platinum-based chemotherapy. A decreasing effect of chemotherapy with age was also shown ($p = 0.01$). The overall survival gain was better for concurrent chemoradiotherapy with altered fractionation compared with concurrent chemoradiotherapy with conventional fractionation, indicating that alteration of fractionation might boost the effect of chemoradiotherapy. In the meta-analysis conducted by Browman et al. (Browman et al., 2001), only platinum-based chemotherapy given concomitantly with radiotherapy was found highly significant in overall survival improvement ($p < 0.0001$). The German meta-analysis suggested that, considering only concurrent chemoradiotherapy without prolonged overall treatment time, an absolute survival gain of 13% to 15% at 2 years with respect to conventional radiotherapy can be obtained (Budach et al., 2006). The extensive

research of the influence of the addition of chemotherapy to radiotherapy on overall survival resulted in confirmation that only concurrent chemoradiotherapy as definitive treatment for patients with locoregionally advanced head and neck cancer including those with advanced hypopharyngeal cancer has succeeded to improve outcomes. Thus, evidence based medicine has shown that concurrent chemoradiotherapy without prolongation of overall treatment time and including cisplatin only or cisplatin-5-fluorouracil should be considered the treatment of choice for patients who fit chemotherapy (National Cancer Institute [NCI] level 1 of evidence supporting recommendation) (Corvo, 2007).

Authors	Number of patients	Therapy regimens	Treatment results	Complications
Chemotherapy given concurrently with conventionally fractionated radiotherapy regimens				
Sanchiz et al. (Sanchiz et al., 1990)	N=859, Arm A=277, Arm B=282, Arm C=300 Nh=119, Arm A=37, Arm B=36, Arm C=46	Arm A: 60 Gy given with 2.0 Gy/fx/d, 5 fx /wk vs. Arm B: 70.4 Gy given in 2.2 Gy/fx/twice daily vs. Arm C: 60 Gy given with 2.0 Gy/fx/d, 5 fx /wk plus 5-FU 250 mg/m ² given i.v. on alternate days	5-year OS, 31% in Arm A vs. 59% in Arm B vs. 63% in Arm C Arm A vs. Arm B (p<0.001); Arm A vs. Arm C (p<0.001); B vs. Arm C (n.s.)	Grade 3 mucositis, 6% in Arm A vs. 4% in Arm B vs. 10% in Arm C; no significant difference in acute and late toxic effects
Adelstein et al. (Adelstein et al., 2000)	N=100, Arm A=50, Arm B=50 Nh=16, Arm A=9, Arm B=7	Arm A: 66-72 Gy given with 1.8-2.0 Gy/fx/d, 5 fx /wk vs. Arm B: same RT regimen plus concurrent 5-FU 1000 mg/m ² /d and cisplatin 20 mg/m ² /d both given as continuous infusion over 4 days beginning on days 1 and 22 of RT	5-year LRC, 45% in Arm A vs. 77% in Arm B (p<0.001); 5-year RFS, 51% in Arm A vs. 62% in Arm B (p=0.04); 5-year DMFS, 75% in Arm A vs. 84% in Arm B (p=0.09) 5-year OS, 34% in Arm A vs. 42% in Arm B (p=0.004)	Significantly more acute toxicity in Arm B (Grade 3 or 4 neutropenia, thrombocytopenia, cutaneous reactions, and mucositis); no significant difference in late toxic effects.
Adelstein et al. (Adelstein et al., 2003)	N=271, Arm A=95, Arm B=87, Arm C=89 Nh=50, Arm A=19, Arm B=17, Arm C=14	Arm A: 70 Gy given with 2.0 Gy/fx/d, 5 fx /wk vs. Arm B: same RT regimen plus concurrent cisplatin 100 mg/m ² i.v. on days 1, 22 and 43 vs. Arm C: same RT regimen with 3 courses of a 4-day continuous infusion of 5-FU 1,000 mg/m ² /d, with cisplatin bolus injection of 75 mg/m ² on day 1, given every 4 weeks	3-year DSS, 33% in Arm A vs. 51% in Arm B vs. 41% in Arm C Arm A vs. Arm B (p=0.01); Arm A vs. Arm C (n.s.) 3-year OS, 23% in Arm A vs. 37% in Arm B vs. 27% in Arm C Arm A vs. Arm B (p=0.014); Arm A vs. Arm C (n.s.); Arm B vs. Arm C (n.s.)	Grade 3 or worse acute toxic effects, 52% in Arm A vs. 89% in Arm B (p<0.0001); late toxic effects not reported
Chemotherapy given concurrently with intensified radiotherapy regimens				
Brizel et al. (Brizel et al., 1998)	N=116, Arm A=60, Arm B=56 Nh=23, Arm A=10, Arm B=13	Arm A: 75 Gy as 1.25 Gy/fx/twice daily vs. Arm B: 70 Gy given with 1.25 Gy/fx/twice daily (7-10 days break after 40 Gy) plus cisplatin 12 mg/m ² /d and 5-FU 600 mg/m ² /d in week 1 and 6	3-year LRC, 44% in Arm A vs. 70% in Arm B (p=0.01); 3-year RFS, 41% in Arm A vs. 61% in Arm B (p=0.08); 3-year OS, 34% in Arm A vs. 55% in Arm B (p=0.07)	Similar mucositis; increased enteral feeding and sepsis with combination therapy; no difference in late toxic effects
Wendt et al. (Wendt et al., 1998)	N=270, Arm A=140, Arm B=130 Nh=97, Arm A=50, Arm B=47	Arm A: 70.2 Gy given with 1.8 Gy/fx/twice daily in 3 courses with 10-day break vs. Arm B: same RT regimen plus cisplatin 60 mg/m ² , 5-FU 350 mg/m ² by i.v. bolus, and LV 50 mg/m ² by i.v. bolus given on day 2, and 5-FU 350 mg/m ² /24 hour by continuous infusion and LV 100 mg/m ² /24 hours by continuous infusion given from day 2 to 5 starting on days 22 and 44	3-year LRC, 17% in Arm A vs. 36% in Arm B (p<0.004); 3-year OS, 24% in Arm A vs. 48% in Arm B (p<0.0003)	Grade 3-4 acute mucositis, 16% in Arm A vs. 38% in Arm B (p<0.001); no significant difference in late toxic effects

Authors	Number of patients	Therapy regimens	Treatment results	Complications
Jeremic et al. (Jeremic et al., 2000)	N=130, Arm A=65, Arm B=65 Nh=21, Arm A=11, Arm B=10	Arm A: 77 Gy given in 1.1 Gy/fx/twice daily vs. Arm B: same RT regimen plus cisplatin 6 mg/m ² /d	5-year LRPFS, 36% in Arm A vs. 50% in Arm B (p=0.04); 5-year PFS, 25% in Arm A vs. 46% in Arm B (p=0.007); 5-year DMFS, 57 in Arm A % vs. 86% in Arm B (p=0.001); 5-year OS, 25% in Arm A vs. 46% in Arm B (p=0.008)	No significant difference in acute toxic effects with exception to leucopenia grade 3/4 (0% in Arm A vs. 12%, in Arm B [p=0.006]); no difference in late toxic effects
Staar et al. (Staar et al., 2001)	N=240, Arm A=127, Arm B=113 Nh=62, Arm A=26, Arm B=36	Arm A: 69.9 Gy over 5,5 weeks (1.8 Gy/fx/d for 3.5 weeks, then, individual fx of 1.8 Gy and 1.5 Gy daily for 2 weeks plus carboplatin 70 mg/m ² /d and 5-FU (600 mg/m ² /d) for 2 cycles of 5 days vs. Arm B: same RT regimen alone	2-year LRC, 51% in Arm A vs. 45% in Arm B (p=0.14) 1-year SLC, 58% in Arm A vs. 44% in Arm B (p=0.05); 2-year OS, 48% in Arm A vs. 39% in Arm B (p=0.09)	Grade 3-4 mucositis, 68% in Arm A vs. 52% in Arm B (p=0.01); feeding tube dependency, 51% in Arm A vs. 25% Arm B (p=0.02)
Huguenin et al. (Huguenin et al., 2004)	N=224, Arm A=112, Arm B=112 Nh=55, Arm A=27, Arm B=28	Arm A: 74.4 Gy given in 1.2 Gy/fx/twice daily vs. Arm B: same RT regimen plus cisplatin 20 mg/m ² /d on 5 days of weeks 1 and 5	5-year LRC, 33% in Arm A vs. 51% in Arm B (p=0.039); 5-year OS, 32% in Arm A vs. 46% in Arm B (p=0.15)	Grade 3 mucositis, 61% in Arm A vs. 59% in Arm B; no significant differences in acute and late toxic effects
Budach et al. (Budach et al., 2005)	N=384, Arm A=194, Arm B=190 Nh=124, Arm A=62, Arm B=62	Arm A: 14 Gy given with 2.0 Gy/fx/d, followed by 1.4 Gy/fx/twice daily to a total dose of 77.6 Gy vs. Arm B: 30 Gy given with 2.0 Gy/fx/d, followed by 1.4 Gy/fx/twice daily to a total dose of 70.6 Gy concurrently with 5-FU 600 mg/m ² given as continuous infusion and mitomycin 10 mg/m ² given on days 5 and 36	5-year LRC, 37.4% in Arm A vs. 49.9% in Arm B (p=0.001); 5-year OS, 23.7% in Arm A vs. 28.6% in Arm B (p=0.023); 5-year PFS, 26.6% in Arm A vs. 29.3% in Arm B (p=0.009)	Grade 3-4 mucositis, 65.7% in Arm A vs. 75.7% in Arm B (p=0.045); grade 3 skin reaction 29.6% in Arm A vs. 46.3% in Arm B (p=0.002); no difference in late toxic effects

Nh: number of patients with hypopharyngeal cancer; fx: fraction, d: day, wk: per week; 5-FU: 5-fluorouracil; i.v.: intravenously; OS: overall survival; n.s.: not significant; RT: radiotherapy; LRC: locoregional control; RFS: recurrence-free survival; DMFS: distant metastases-free survival; DSS: disease-specific survival; LV: leucovorin; LRPFS: locoregional progression-free survival; PFS: progression-free survival; SLC: survival with local control

Table 3. Randomised studies comparing concurrent chemoradiotherapy with radiotherapy alone in patients with advanced head and neck cancer

Regarding the question about the number of drugs that can be added to radiotherapy and the timing of drug delivery once must be admitted that the optimum regimen is not yet known. The most common method used was delivery of drugs every 3 weeks (Adelstein et al., 1997; Adelstein et al., 2000) with the most frequently used regimen being the one proposed by Adelstein et al. (Adelstein et al., 2003) based on three courses of cisplatin every 3 weeks (100 mg/m² on days 1, 22, and 43) (Table 3). Weekly (Gupta et al., 2009b), or daily (Jeremic et al., 1997; Jeremic et al., 2000) administration of single-agent cisplatin has been also studied. According to the results of the meta-analysis of the MACH-NC Collaborative Group, platinum-based chemotherapy was more effective than non-platinum containing regimens, but multiagent therapy was not better than single agent. The superiority of platinum-based chemotherapy has been also confirmed in the meta-analysis of Browman et al. (Browman et al., 2001). According to Pignon et al. (Pignon et al., 2005), clinical benefit

might be obtained even with a total dose of cisplatin of only 200 mg given in different timing concurrently with radiotherapy. Preliminary results from Radiation Therapy Oncology Group (RTOG) 97-03 three-arm randomised phase II trial enrolling patients with stage III or IV squamous carcinoma of the oral cavity, oropharynx, or hypopharynx revealed that concurrent radiotherapy and two-drug chemotherapy using either paclitaxel plus cisplatin, 5-fluorouracil plus cisplatin, or hydroxyurea plus 5-fluorouracil was feasible (Garden et al., 2004a). However, there was no phase III trial performed to show taxane-based concurrent chemoradiotherapy to be superior to radiotherapy alone, and no randomised trial has demonstrated a taxane, either as a single agent or in combination with other drugs to be superior to single-agent, platinum-based concurrent chemoradiotherapy.

6.3.2 Altered fractionation radiotherapy

Another approach focused on improvement of locoregional control and organ preservation in patients with locally advanced head and neck cancer was the investigation of modification of conventionally fractionated radiotherapy. Two prototypes of altered radiation fractionation regimens (hyperfractionation and accelerated fractionation) have been tested in retrospective and randomised trials for the last three decades. Promising improvements in locoregional control with the use of altered fractionated radiation schedules in the treatment of advanced head and cancer were demonstrated in several single-institution studies (Parsons et al., 1993; Wang et al., 1985). On the contrary, a retrospective study of Garden et al (Garden et al., 1995) did not reveal statistically significant differences in local control rates and survival rates between patients with carcinoma of the larynx or hypopharynx treated with conventional fractionation and those irradiated with hyperfractionation. However, only small number of studies referred on the role of altered fractionation exclusively in patients with advanced hypopharyngeal cancer. In one of those studies in which conventional radiotherapy was compared with hyperfractionated radiotherapy, multivariate analysis showed that twice-daily fractionation was the most important treatment-related variable in patients with squamous cell carcinoma of the pharyngeal wall (Fein et al., 1993). Retrospectively analysing the results of definitive radiotherapy in patients with hypopharyngeal cancer, Antognoni et al (Antognoni et al., 1991) did not show any impact of fractionation regimen on patients outcome. On the contrary, in the retrospective study on 52 patients with hypopharyngeal carcinoma, significantly better 5-year survival rate was obtained with accelerated hyperfractionation (44%) than with conventional fractionation (12%) (Akimoto et al., 1996).

The largest prospective randomised trial undertaken to compare standard fractionation radiotherapy against hyperfractionation and accelerated fractionation with split course and accelerated radiotherapy with concomitant boost in the management of patients with advanced head and neck squamous cell carcinoma was RTOG trial 9003 (Fu et al., 2000). The results of this four-arm trial of 1073 patients with locally advanced head and neck cancer, showed that the locoregional control was significantly increased by increase of the total dose without changing the overall time using hyperfractionation (2-year locoregional control 54.4% with hyperfractionation vs. 46% with conventional fractionation, $p = 0.045$) without increase in overall survival. The results also revealed that accelerated fractionation with concomitant boost yielded a significantly better locoregional control than standard radiotherapy (2-year locoregional control 54.5% with accelerated fractionation with

concomitant boost vs. 46% with conventional fractionation, $p = 0.05$) and a trend toward improved disease-free survival (2-year disease-free survival 39% with accelerated fractionation with concomitant boost vs. 32% with conventional fractionation, $p = 0.054$). Concerning the treatment related toxicity, hyperfractionation induced more severe acute mucositis compared to the conventional fractionation arm, and accelerated fractionation with concomitant boost-arm had significantly higher grade 3 or worse acute side effects ($p < 0.0001$) and significantly increased grade 3 or worse late side effects ($p < 0.011$). It should be pointed out that this most important randomised trial was not site specific to the hypopharynx. Results of recently published randomised controlled clinical study of accelerated fractionation performed by the national Swedish group including 750 patients with squamous cell carcinoma of the oral cavity, oropharynx, larynx and hypopharynx did not prove that accelerated radiotherapy was more efficacious compared with conventional radiotherapy in terms of both locoregional control and overall survival (Zackrisson et al., 2011). This randomised trial was also not site specific to the hypopharynx.

Meta-analysis undertaken by Meta-Analysis of Radiotherapy in Carcinomas of the Head and Neck (MARCH) Collaborative Group (Bourhis et al., 2006) and aimed to assess whether different types of altered fractionated radiotherapy in head and neck squamous cell carcinoma could improve survival compared with conventional radiotherapy, included findings of 15 trials with 6,515 patients. This meta-analysis of updated individual patient data showed an improvement of 6.4% of locoregional control (from 46% to 53%, $p < 0.0001$), and an improvement of 3.4% of overall survival (from 36% to 39%, $p < 0.03$) with altered fractionation. The benefit in overall survival was significantly higher with hyperfractionation regimen (8% at 5 years) than with accelerated radiotherapy. The advantage of hyperfractionation was also confirmed in the German meta-analysis by Budach et al (Budach et al., 2006). The findings of this meta-analysis based on published data suggested that, among different types of altered radiotherapy, hyperfractionation obtained better 2-year overall survival than conventional radiotherapy with a significant benefit of 12 months ($p < 0.001$). According to the results of randomised trials exploring altered fractionation regimens and considering the results of the two meta-analyses, evidence based medicine showed that acceleration of radiation of one week without dose reduction and hyperfractionation are consistently better than conventional fractionation for locoregional control of intermediate to advanced carcinomas without an increase in late toxic effects (National Cancer Institute [NCI] level 1 of evidence supporting recommendation).

6.3.3 Intensified radiotherapy regimens in combination with chemotherapy

Altered fractionated radiotherapy with concurrent chemotherapy has been also evaluated. In a phase II study at a single institution conducted by Prades et al. (Prades et al., 2002), there were no statistically significant differences observed in overall and disease-free survival between patients with pyriform sinus cancer treated with accelerated radiotherapy alone and those treated with intensified concurrent chemoradiotherapy. In a single institution phase II trial exploring organ preservation using split hyperfractionated accelerated radiation therapy and concomitant cisplatin in patients with advanced cancer of the larynx and hypopharynx, De la Vega et al. (De la Vega et al., 2003) found organ preservation possible in 44% of patients. The encouraging results of RTOG phase II trial 99-14 conducted to evaluate the accelerated radiotherapy using concomitant boost combined

with two cycles of concurrent cisplatin in patients with stage III and IV squamous cell carcinoma of the oral cavity, oropharynx, hypopharynx, or larynx (Ang et al., 2005) suggesting that intensified radiotherapy regimens could be combined safely with chemotherapy motivated a phase III trial (RTOG H0129) predicted to determine whether accelerated fractionation using concomitant boost plus cisplatin can lead to better results compared with conventionally fractionated radiotherapy in combination with concurrent use of cisplatin.

Several randomised trials exploring intensified radiotherapy regimens in combination with chemotherapy in advanced head and neck cancer included patients with hypopharyngeal cancer (Brizel et al., 1998; Budach et al., 2005; Huguenin et al., 2004; 2004; Jeremic et al., 2000; Staar et al., 2001; Wendt et al., 1998) (Table 3). In a single institution study reported by Brizel et al. (Brizel et al., 1998) better locoregional control was achieved by concurrent chemoradiotherapy without any improvement in overall survival (Table 3). Wendt et al. (Wendt et al. 1998) reporting the results of a regimen consisting of split-course altered fractionation plus chemotherapy concluded that concurrent chemoradiotherapy offered significantly improved 3-year locoregional control and overall survival rate with acute reactions more pronounced in the concurrent chemoradiotherapy arm (Table 3). In a study of hyperfractionation, Jeremic et al. (Jeremic et al., 2000) reported a significant improvement in 3-year locoregional control, overall survival and distant-metastases-free survival with hyperfractionated radiotherapy and concurrent low-dose daily cisplatin as compared with hyperfractionation alone (Table 3). The reported frequency of acute mucositis and late complications were similar in both arms. The improvement of therapeutic index of hyperfractionated radiotherapy by concomitant cisplatin has been also confirmed in the randomised trial conducted by Huguenin et al. (Huguenin et al., 2004). In the multicentric randomised German trial conducted by German Cooperative Group (Staar et al., 2001), a concomitant boost accelerated fractionation alone was compared with the same radiotherapy regimen plus carboplatin and 5-fluorouracil (Table 3). The authors concluded that the efficiency of intensified concurrent chemoradiotherapy was less than expected when compared to radiotherapy alone. Updated results of this trial have shown no improvement in locoregional failure-free survival and overall survival among patients with hypopharyngeal cancer treated with intensified regimen (Semrau et al., 2006). Reporting final results of a prospective randomised study in locally advanced head and neck cancer comparing concurrent 5-fluorouracil and mitomycin chemotherapy and hyperfractionated accelerated radiotherapy to hyperfractionated accelerated radiotherapy alone, Budach et al. (Budach et al., 2005) have shown a locoregional control and survival benefit when altered fractionation in combination with chemotherapy was used without any efficacy benefit revealed in patients with advanced hypopharyngeal cancer (Table 3). It must be emphasized that in patients with advanced cancer of the hypopharynx intensified radiotherapy regimens in combination with chemotherapy currently do not represent a routinely recommended treatment.

6.3.4 Adjuvant neck dissection following concurrent chemoradiotherapy

General consensus exists that adjuvant neck dissection is not necessary for patients with N1 disease who have complete response to concurrent chemoradiotherapy in the neck. Although it has been shown that concurrent chemoradiotherapy provided good regional

control even in patients with advanced N-stage disease, there was an increased risk of residual disease observed with the increased stage of nodal disease (Boyd et al., 1998) with residual tumour found in approximately one third of the surgical specimens when treatment included planned neck dissection following chemoradiotherapy (Haraf et al., 1991; Sanguineti et al., 1999). Randomised studies addressing the question of best approach for patients who achieved a clinical complete response after concurrent chemoradiotherapy for initial N2 or N3 disease are lacking. Although regional control remained higher with adjuvant neck dissection following hyperfractionated or accelerated radiotherapy regimens (Mendenhall et al., 2002) the role of adjuvant neck dissection following concurrent chemoradiotherapy for patients with N2 or N3 disease is controversial (Brizel et al., 2004; Grabenbauer et al., 2003). Current recommendations range from planned neck dissection for all patients with pretreatment N2 or N3 disease to neck dissection only in patients with radiographic or clinical evidence of residual disease. Adjuvant neck dissection should be performed 6 to 10 weeks after completion of concurrent chemoradiotherapy. The avoidance of expected increased treatment related morbidity should be obtained by performing modified or selective dissections with removal of nodes only from levels II-IV.

6.3.5 Induction chemotherapy

Several studies were performed to evaluate the role of induction chemotherapy followed by definitive radiotherapy in obtaining functional organ preservation in advanced resectable hypopharyngeal cancer. The general approach was that patients were given two to three cycles of induction chemotherapy followed by definitive radiotherapy, with surgery reserved for nonresponse to induction chemotherapy, persistent disease after radiation, or relapse. Results of retrospective studies on patients with resectable, locally advanced hypopharyngeal cancers requiring total laryngectomy treated with one to three cycles of induction cisplatin-based chemotherapy followed by definitive radiotherapy in the presence of complete or partial response to chemotherapy at the primary site have shown a rate of larynx preservation ranging between 32% and 52% (Kim et al., 1998; Kraus et al., 1994; Zelefsky et al., 1996). Comparing results regarding locoregional control, disease-free survival, and overall survival achieved with this treatment approach with results obtained with surgery and postoperative radiotherapy in patients with similarly staged disease, it has been suggested that induction chemotherapy followed by definitive radiotherapy could be considered an effective strategy to achieve organ preservation without compromising survival in patients with advanced cancer of the hypopharynx (Kim et al., 1998).

There were few randomised phase III studies conducted on patients with hypopharyngeal cancers eligible only for total laryngectomy with partial pharyngectomy, comparing surgery and postoperative radiotherapy with two or three cycles of induction cisplatin/5-fluorouracil chemotherapy followed by radiotherapy in clinically complete responders, or total laryngectomy for those who had not a complete response (Lefebvre et al., 1996), or induction chemotherapy plus radiotherapy with induction chemotherapy plus surgery plus radiotherapy (Beauvillain et al., 1997), or induction chemotherapy followed by radiotherapy with concurrent chemoradiotherapy (Prades et al., 2010). In the randomised phase III study 24891 conducted by EORTC, survival did not differ between treatment groups and functional larynx was retained in 50% of the survivors in the chemoradiotherapy group (Lefebvre et al., 1996). The results from this trial were confirmed by its long term evaluation

(Lefebvre et al., 2004). In the French randomised trial conducted by Beauvillian et al. (Beauvillian et al., 1997), statistically improved 5-year local control and overall survival was found in patients treated with induction chemotherapy followed by total laryngopharyngectomy and postoperative radiotherapy. Larynx preservation was obtained in 38% of patients treated with induction chemotherapy followed by definitive radiotherapy. Nevertheless, several meta-analyses have failed to demonstrate any significant improvement in survival after induction chemotherapy followed by radiotherapy (Browman, 1994; El-Sayed & Nelson, 1996; Pignon et al., 2000). The largest and most detailed of these, the meta-analysis of the MACH-NC Collaborative Group, analysed data from 31 trials of induction chemotherapy with more than 5,200 patients enrolled, and reported 2% 5-year improvement in overall survival being statistically nonsignificant ($p = 0.38$) (Pignon et al., 2000).

The renewed interest in induction chemotherapy arisen from data showing treatment failure due to the development of distant metastases in 1 of 5 patients with stage III-IV head and neck cancer treated with multimodality approaches including concurrent chemoradiotherapy (Bernier & Bentzen, 2003) led to the evaluation of the use of both induction chemotherapy and concurrent chemoradiotherapy in a sequential approach supposed to provide optimal benefit for this patients category. In the light of emerged need to improve overall treatment outcome in patients with locoregionally advanced head and neck cancer, the results of sequential therapy could be considered especially important for patients with advanced cancers of the hypopharynx because this primary site has been found to be an independent predictor for distant metastases development (Adelstein et al., 2006a). Both randomised phase III studies performed to evaluate sequential therapy with induction chemotherapy, the TAX 324 study (Posner et al., 2007) and the study conducted by the investigators in Madrid (Hitt et al., 2005) confirmed the benefit of induction chemotherapy using a triplet combination including taxane followed by concurrent chemoradiotherapy. However, there would be no level 1 of evidence data showing the superiority of induction chemotherapy followed by concurrent chemoradiotherapy over concurrent chemoradiotherapy until ongoing randomised, phase III trials comparing sequential therapy versus concurrent chemoradiotherapy complete (Adelstein et al., 2006b; Posner, 2005).

6.3.6 Targeted therapy with cetuximab

Based upon the evidence of increased levels of Epidermal Growth Factor Receptor (EGFR) expression in the majority of head and neck cancer, and the associated poor outcome with its presence (Chung et al., 2006), the addition of molecular targeted therapies in head and neck cancer was assumed as another potential method offering further improve outcome. A large international multicenter randomised phase III clinical study was performed in which radiotherapy alone was compared with radiotherapy plus weekly cetuximab at an initial dose of 400 mg/m² followed by 250 mg/m² weekly for the duration of radiotherapy in patients with stage III-IV cancer of the oropharynx, larynx or hypopharynx (Bonner et al., 2006). In this study, radiotherapy was delivered either with conventional fractionation or with altered fractionation (hyperfractionation or concomitant boost accelerated radiotherapy). The median survival, and the observed rates of locoregional control and overall survival at 3 years were significantly higher in patients treated with radiotherapy

plus cetuximab than those in patients treated with radiotherapy alone. However, the median duration of overall survival for patients with hypopharyngeal cancer was equal in both treatment groups. Reporting the 5-year survival data from this study, Bonner et al. (Bonner et al., 2010) showed significantly improved overall survival at 5 years for patients treated with cetuximab and radiotherapy compared with that achieved in the radiotherapy-alone group. The results from this prospective randomised trial support the superiority of concurrent targeted antibody enhanced radiotherapy over radiotherapy alone for advanced disease (NCI level of evidence Iii A for a single phase III trial, level 2 for recommendation). It has been suggested that it is reasonable to consider this regimen of radiotherapy plus cetuximab in patients with coexisting medical conditions and poor performance status who are not good candidates for concurrent chemoradiotherapy or surgery (Garden et al., 2004b; Seiwert & Cohen, 2005).

6.4 Unresectable M0 disease

The published guidelines by the National Comprehensive Cancer Network (NCCN) for technical unresectability criteria including evidence for direct invasion of cervical vertebrae or brachial plexus and direct involvement of deep muscles of the neck or carotid artery, provided a general framework to clearly define tumours being unresectable if anatomic considerations make it unlikely that all gross tumour can be removed or that local control can be achieved after resection even with the addition of postoperative radiotherapy (Forastiere et al., 2005). Patients presenting with unresectable hypopharyngeal cancer without evidence of distant metastases may be considered appropriate for localised and systemic treatment. However, historically speaking, conventionally fractionated radiotherapy offering low probability of cure was considered palliative when used as a single treatment modality in patients with unresectable disease. In order to improve locoregional control and to influence on prolongation of survival, the integration of chemotherapy with radiotherapy has been used as multimodality treatment approach for unresectable disease (Vokes & Weichselbaum, 1990). Induction chemotherapy with rare exception has not been shown to improve survival in patients with unresectable disease. A benefit from induction chemotherapy in term of overall survival has been suggested in the subset analysis of inoperable patients in the large study by Paccagnella et al. (Paccagnella et al., 1994). The subset analysis of the updated results for overall survival after a minimum follow-up of 10 years reported by Zorat et al. (Zorat et al., 2004) showed that among inoperable patients, there was a statistically significant better survival observed in the induction chemotherapy group compared to patients who did not receive induction chemotherapy. The EORTC 24971/TAX 323, a phase III study of 358 patients with unresectable locoregionally advanced head and neck cancer showed that the addition of docetaxel to cisplatin and 5-fluorouracil for induction and given before radiotherapy improved both progression-free and overall survival with less toxicity compared to cisplatin and 5-fluorouracil induction chemotherapy (Vermorken et al., 2007). Analysing the results of EORTC 24971/TAX 323 study in terms of symptom control and quality of life, Van Herpen et al. (Van Herpen et al., 2010) revealed that induction chemotherapy with docetaxel, cisplatin and 5-fluorouracil followed by definitive radiotherapy not only improved survival and reduced toxicity compared with cisplatin plus 5-fluorouracil based induction chemotherapy, but also had a substantial impact on improvement of quality of life in patients with unresectable locoregionally advanced disease. Randomised phase II studies

comparing concurrent cisplatin-based chemoradiotherapy and induction chemotherapy followed by definitive radiotherapy in patients with unresectable head and neck cancer did not reveal any statistically significant difference in the overall survival between treatment groups, but taking into account the similar activity of two treatment schedules and the better compliance associated with the concurrent treatment, authors suggested that concurrent chemoradiotherapy might be considered an option in this patients category (Pinnaro et al., 1994; Taylor et al., 1994). In the Intergroup phase III study of Southwest Oncology Group (SWOG) and Eastern Cooperative Oncology Group (ECOG) for locally advanced and unresectable head and neck cancer, statistically significant difference in favour of concurrent chemoradiotherapy was observed only between cisplatin plus radiotherapy and radiotherapy alone (Adelstein et al., 2003). However, although randomised phase III trials comparing radiotherapy alone to concurrent chemoradiotherapy in advanced head and neck cancer were not specific for unresectable disease and hypopharyngeal primaries, the consistent improvement in locoregional control and survival obtained with concurrent chemoradiotherapy as well as the small, but consistent statistically significant benefit of this treatment modality revealed in the meta-analyses (Bourhis et al., 2004; Pignon et al., 2000) led to recommendation supporting radiotherapy and concurrent cisplatin-based chemoradiotherapy as standard treatment for patients with unresectable hypopharyngeal cancers. Recently reported definitive results of a phase III prospective multicenter randomised study conducted in Italy in which 164 patients with unresectable head and neck cancer were randomised to receive radiotherapy alone or combined with daily low-dose carboplatin showed statistically significant improvement in 3, 5 and 10-year overall survival rates in the group treated with concurrent chemoradiotherapy (Ruo Redda et al., 2010). In the absence of conclusive arguments supporting exact schedule of cisplatin administration, a nonrandomised study was conducted to compare two courses cisplatin or two courses of cisplatin plus 5-fluorouracil in 128 patients with locally advanced unresectable head and neck cancer. The results showed that two courses of fractionated cisplatin were accompanied with less acute toxicity whereas similar outcome and incidence of late toxicities were observed with both chemotherapy schedules (Tribius et al., 2009). The use of altered fractionation regimes in the management of unresectable, locoregionally advanced head and neck cancer have also been a part of an intensive clinical research focused on the improvement of locoregional control and overall survival. Based on the results of a large non-site-specific randomised RTOG 90-03 trial demonstrating an improvement in local control with accelerated fractionation using concomitant boost and hyperfractionated radiotherapy compared with conventional fractionation (Fu et al., 2000), and in accordance with the assessment of MARCH Collaborative Group (Bourhis et al., 2006) showing statistically significant improvement in locoregional control and an improvement in overall survival achieved with the use of accelerated radiotherapy, and especially with hyperfractionated radiotherapy, altered fractionation has been recommended as an alternative to concurrent chemoradiotherapy in patients with unresectable head and neck cancer. Nevertheless, both concurrent chemoradiotherapy and altered fractionation are accompanied with increased rates of acute and late toxicity. Intensified radiotherapy regimens in combination with chemotherapy are not routinely recommended in patients with unresectable head and neck cancer. A TAX 324 randomised phase III trial (Posner et al., 2007) demonstrated significant advantage of cisplatin/5-

fluorouracil/docetaxel induction chemotherapy followed by concurrent platinum based chemoradiotherapy in patients with advanced or unresectable head and neck disease including patients with hypopharyngeal cancer. However, despite the encouraging results observed with sequential therapy incorporating taxane in the induction chemotherapy setting, because of the lack of published data from phase III trials comparing induction chemotherapy followed by concurrent chemoradiotherapy with the standard treatment of concurrent chemoradiotherapy alone, this treatment approach in patients with unresectable hypopharyngeal cancer remains investigational. Besides induction chemotherapy followed by concurrent chemoradiotherapy, targeted therapy with cetuximab, tyrosine kinase inhibitor drugs, and the association of cetuximab with cisplatin-based concurrent chemoradiotherapy, also represent treatment approaches whose role in the management of unresectable hypopharyngeal cancer is yet to be established.

6.5 Radiation techniques

6.5.1 Two-dimensional (2D) radiotherapy

In conventional 2D radiotherapy, treatment setup is customized using conventional simulator and the placement of the radiation fields and their shapes are based on the bony anatomy acquired by the simulator diagnostic-quality films. A shrinking field technique initiating with opposed pair of lateral fields and a low anterior field covering the postoperative bed in patients treated with postoperative radiotherapy, or the primary tumour and clinically positive neck nodes in patients treated with definitive radiotherapy, and subclinical disease in the neck nodes including node levels in accordance with the nodal status and the subsite and the extension of the primary tumour is used (see section 6.1.3).

6.5.2 Three-dimensional (3D) conformal radiotherapy

In 3D conformal radiotherapy, treatment planning CT scans are required to define and delineate gross tumour volumes (GTVs), and clinical target volumes (CTVs). Determination of postoperative treatment volumes (CTVs) is based on preoperative staging results, pathologic review of surgical specimens, operative findings, and postoperative clinical assessment (see section 6.1.3). In definitive radiotherapy, the GTV of the primary tumour and the metastatic lymph nodes is defined as any visible tumour and the gross nodal disease revealed on imaging studies and/or physical examination. The CTV encompasses the GTV plus a margin around the tumour for the potential microscopic extension of the disease according to anatomical barriers, and also includes node levels in the neck according to the nodal status as well as the subsite of the primary tumour (see section 6.1.3). The planning target volumes (PTVs) are obtained by adding a margin of 0.5 cm around the adequate CTVs. The definition of contoured volumes and organs of risk is as recommended by International Commission on Radiation Units and Measurements (ICRU) Report 62 (International Commission on Radiation Units and Measurements [ICRU] Report 62, 1999). Delineation of the neck lymph node levels should be realised according to DAHANCA, EORTC, GORTEC, NCIC, RTOG consensus guidelines (Gregoire et al., 2003) and proposals for the delineation of the nodal clinical target volume in the node positive and the postoperative neck (Gregoire et al., 2006) (Fig. 1 a-b).

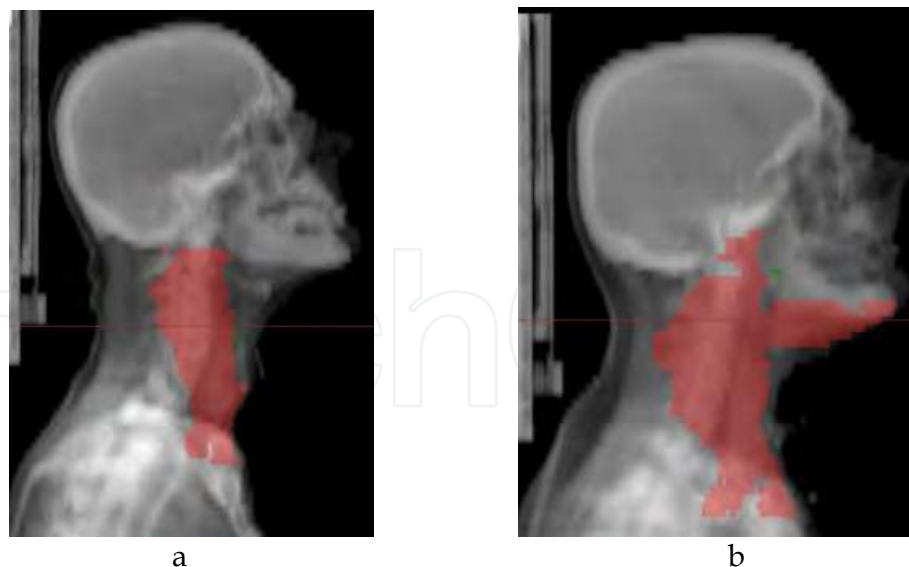


Fig. 1. a-b. Sagittal view of contoured clinical target volumes for elective neck nodal irradiation. a. Clinical target volume encompassing levels II, III, IV, and IV in patient with hypopharyngeal cancer arising from pyriform sinus apex with clinically negative neck. b. Clinical target volume encompassing levels I, II, III, IV, V, IV, retropharyngeal nodes and retrostyloid space in patient with hypopharyngeal cancer with esophageal extension and positive neck nodes in level II determined in the surgical specimen following neck dissection.

6.5.3 Intensity modulated radiotherapy (IMRT)

Clinical data evaluating the efficacy of IMRT for cancers of the hypopharynx are scarce, and the suggestions for satisfactory disease control come from small single-institution series with relatively short follow-up (Daly et al., 2011; Studer et al., 2006; Studer et al., 2010). Although prospective studies evaluating the efficacy and toxicity profile of IMRT to the hypopharynx are needed, IMRT techniques can be used to cover equivalent volumes of concern for hypopharyngeal cancers that involve the posterior pharyngeal wall, and for those primary tumours or metastatic lymphadenopathy that extending posterolaterally would overlie the spinal cord. The GTV is defined as all known gross disease determined from CT, MRI, clinical information, and endoscopic findings including abnormal lymph nodes identified on CT. The CTV1 is defined as the GTV with a 0.5-2 cm margin on primary and or nodal GTV (depending on the presence or absence of anatomic boundaries to microscopic spread). The CTV2 refers on the elective neck irradiation and includes the uninvolved neck lymph nodes. Final treatment target volumes include a PTV (GTV plus a margin of 0.3 to 0.5 cm margin), a PTV1 (CTV1 plus a margin of 0.3 to 0.5 cm margin), and a PTV2 (CTV2 plus a margin of 0.3 to 0.5 cm margin). Details about levels proposed for elective irradiation in dependence of the subsite of the primary tumour as well as with the nodal status are given in section 6.1.3.

6.5.4 Dose prescriptions

For small lesions (T1N0-1 and small T2N0), conventionally fractionated radiotherapy should be realised with a fraction size of 2 Gy to a total dose of 66 to 70 Gy.

For locally-regionally advanced lesions treated with concurrent chemoradiotherapy, conventional fractionation should be used with a total dose of 70 Gy in 7 weeks with a daily fraction of 2 Gy.

For locally-regionally advanced lesions treated with definitive radiotherapy using altered fractionation regimens following options can be offered: hyperfractionated radiotherapy with 79.2 Gy in 66 fractions over 6.5 weeks using 1.2 Gy per fraction twice a day, or accelerated fractionation with concomitant boost delivering a total dose of 72 Gy in 6 weeks, (1.8 Gy per fraction a day for the large field and 1.5 Gy boost as second daily fraction during the last 12 treatment days).

For lesions treated with postoperative radiotherapy or postoperative concurrent chemoradiotherapy, conventional fractionation with a total dose of 60 to 66 Gy at 2Gy per fraction to the postoperative bed and high-risk areas should be used.

Elective neck irradiation to uninvolved nodal regions should be realised with a total dose of 50 Gy using 2 Gy per fraction.

If simultaneous integrated boost IMRT technique in 33 fractions is used, the recommended dose to the planning target volume PTV (i.e., GTV with a margin) is ~ 70 Gy at 2.12 Gy per fraction. The PTV1 will receive 59.4 Gy at 1.8 Gy per fraction, and PTV2 will receive 54 Gy at 1.64 Gy per fraction.

If simultaneous integrated boost IMRT technique in 35 fractions is used, the PTV (i.e., GTV with a margin) will receive 70 Gy at 2 Gy per fraction, the PTV1 will receive 63 Gy at 1.8 Gy per fraction, and PTV2 will receive 56 Gy at 1.6 Gy per fraction.

If sequential IMRT technique is used, two to three different separate dose plans are used with initial lower dose phase (weeks 1-5) followed by high-dose boost volume phase (weeks 6 and 7).

If IMRT with concomitant boost schedule is used, the dose to subclinical targets is delivered once daily for 6 weeks, and a separate boost plan as second daily treatment is used for the last 12 treatment days.

6.5.5 Dose limitations

The maximum dose delivered to the spinal cord should range between 45 and 50 Gy. The maximum dose given to the brain stem is limited at 54 Gy. Mandible maximum dose is equal or less than 70 Gy. The mean dose to each parotid gland should be less than 26 Gy, and if possible, the dose to 50% of the volume of each parotid gland should be kept equal to or less than 20 Gy. The brachial plexus dose should be less than 60 Gy, and the dose to the tracheotomies is limited to 50 Gy. It should be also recognised that dose of 70 Gy carries 5% risk for laryngeal cartilage necrosis.

7. Treatment of recurrent and metastatic hypopharyngeal cancer

Surgery is the optimal therapy for patients with local and/or regional recurrence who were previously treated with radiotherapy alone or in combination with chemotherapy. The

reported successful salvage rate for local recurrence in hypopharyngeal cancer in the retrospective study of Taki et al. (Taki et al., 2010) was 17%. In the randomised controlled trial conducted at the Princess Margaret Hospital in Toronto, the overall survival rate at 3 years after surgery salvage for patients with recurrent laryngopharyngeal cancer treated with primary radiotherapy was 22% (Davidson et al., 1997). Unfortunately, the vast majority of recurrent hypopharyngeal tumours appear to be unsuitable for surgical intervention because of their unresectability mostly due to the presence of direct extension into the neck including encasement of the carotid artery. Additionally, there is also a proportion of recurrences that are technically resectable but could not be resected because of patient comorbidities or patient refusal.

Radiotherapy with or without chemotherapy is the treatment of choice for patients initially treated with surgery alone. Reirradiation as an approach appearing to be a treatment with the most potential for cure in selected patients who previously underwent radiotherapy or chemoradiotherapy remains to be investigational. The reported local control rates following reirradiation for patients with recurrent head and neck cancer range between 13% and 42%, and 5-year survival rates range from 13% in unselected to 93% in highly selected series (Goldstein et al., 2008). However, the efficacy of reirradiation for hypopharyngeal cancer is difficult to be evaluated because most of the data are coming from series of highly heterogeneous patients.

The addition of concurrent chemotherapy to reirradiation in the management of recurrences of head and neck cancer was a reasonable effort made to improve the results of treatment by improving the efficacy of radiotherapy through the radiosensitising effects of chemotherapy. Rates of overall survival at two years in multi-institutional trials of concurrent reirradiation and chemotherapy conducted by RTOG ranged between 17% and 25% (Horwitz et al., 2005; Spencer et al., 2001). Reirradiation alone and especially when combined with concurrent chemotherapy is associated with potentially severe and life-threatening treatment-related toxicities that occur in 9% to 32% of patients (Creak et al., 2005). Therefore, physicians, making a decision for the management of recurrent unresectable hypopharyngeal cancer, must be aware of the insufficient data confirming reirradiation as advocated standard of care and must balance the potential risk of severe complications and quality-of-life issues associated with reirradiation with only a small possibility for long-term survival.

For patients with recurrent, hypopharyngeal cancer who are not candidates for salvage surgery or radiation treatment as well as for patients presenting with metastatic disease and therefore not eligible for multimodality potentially curative treatment, chemotherapy, being the historical palliative option, often represents the treatment of last resort. Generally aimed at prolonging survival, and also at improving the quality of life by controlling existing symptoms, and preventing of new cancer-related symptoms, chemotherapy, despite the use of more aggressive combinations and the achievement of higher response rates, has not been convincingly demonstrated to improve survival (Colevas, 2006). Further, despite the palliative intent of chemotherapy in this patients category, there is infrequent assessment of the correlation between tumour shrinkage and benefit such as symptom reduction, and there are also no generated data to support a positive impact of chemotherapy on patients' quality of life. Clinical studies focused on the evaluation of the role of chemotherapy in

patients with incurable locoregionally recurrent or metastatic head and neck cancer are not site specific. The best studied single agents are methotrexate, cisplatin, 5-fluorouracil and the taxanes (paclitaxel and docetaxel). In general, the response rate of single-agent and combination chemotherapy ranges between 10% and 40% (Colevas, 2006; Vokes & Choong, 2008). Various combinations of cytotoxic agents were compared in randomised clinical trials. The review analysis of these trials confirming the demonstrated statistically significant response superiority of combination versus monotherapy approaches has also shown that cisplatin and 5-fluorouracil was the only combination with superior response rate over single-agent chemotherapy without associated trend to a lower median survival (Browman & Cronin, 1994). Treatment results achieved in randomised studies exploring the role of different chemotherapy regimens in the treatment of recurrent or metastatic head and neck cancer are summarised in Table 4. The utility of paclitaxel plus cisplatin in patients with recurrent or metastatic head and neck cancer was defined in two randomised trials conducted by the ECOG (Forastiere et al., 2001b; Gibson et al., 2005) (Table 4). In the randomised study of Vermorken et al. (Vermorken et al., 2008) conducted to investigate the efficacy of cetuximab plus platinum-based chemotherapy as first-line treatment in patients with recurrent or metastatic head and neck cancer, the combination of platinum agent (either cisplatin or carboplatin), 5-fluorouracil, and cetuximab has been shown to significantly improve the median overall survival and progression-free survival as compared with chemotherapy alone consisting of platinum agent and 5-fluorouracil (Table 4). Although there are many options for palliative chemotherapy in patients with recurrent or metastatic head and neck cancer, treatment commencement should not ultimately follow the documentation of recurrent disease or presence of distant metastases. However, patients' selection focused on relation between possible benefits of palliation and the risks of treatment induced toxicity should represent more important procedure than the selection of particular cytotoxic agents. Regimens in wide clinical use are: methotrexate given at 40 to 60 mg/m² intravenously weekly; paclitaxel 80-100 mg/m² given as 1-hour weekly infusion; docetaxel given intravenously at 75-100 mg/m² over 1 hour every 21 days; cisplatin-5-fluorouracil combination with cisplatin 100 mg/m² given intravenously on day 1 and 5-fluorouracil 1,000 mg/m² every day given as continuous infusion over days 1 to 4, repeated every 21 to 28 days; cisplatin-paclitaxel combination with cisplatin 75 mg/m² given intravenously and paclitaxel 175 mg/m² given intravenously over 3 hours, both on day 1, repeated every 21 days; cisplatin-docetaxel combination with cisplatin 75 mg/m² given intravenously and docetaxel 75 mg/m² given intravenously over 1 hour, both on day 1 and repeated every 21 days; carboplatin-paclitaxel combination with carboplatin given at Area Under the Curve (AUC) 6 and paclitaxel 200 mg/m² given intravenously over 3 hours, both on day 1, every 21 days, or carboplatin given at AUC 2 and paclitaxel 80 mg/m² given intravenously over 1 hour, both on day 1 administered on a weekly basis.

8. Complications of treatment

Poor general health, chronic malnutrition, alcoholism, and advanced age of the patient, or the use of preoperative radiotherapy, represent factors influencing the increased risk for surgical complications. Hemorrhage and damage to cranial nerves are most frequently observed intraoperative complications. The most common complication after laryngopharyngectomy is pharyngocutaneous fistula as a result from a leakage at the site of the pharyngeal closure that might be a consequence of tight closure or presence of tumour at

Authors	Therapy regimens	Response rate % (CR %)	Median survival (months)
Taylor et al. (Taylor et al., 1984)	MTX 1,500 mg/m ² given as continuous infusion over 24 hours with leucovorin vs. 40 mg/m ² given i.m.	32 vs. 22; p=0.52	4.2 for both treatments
Vogl et al. (Vogl et al., 1985)	MTX 40 mg/m ² i.v. weekly, with escalation to 60 mg/m ² on day 8 and subsequently in the absence of toxicity vs. MTX 40 mg/m ² i.m. on days 1 and 15, bleomycin 10 U i.m. on day 1, 8 and 15, and cisplatin 50 mg/m ² i.v. on day 4, repeated every 21 days	35 vs. 48; p=0.04 (8 vs. 16; p=0.04)	5.6 for both treatments
Williams et al. (Williams et al., 1986)	MTX 45 mg/m ² given as weekly i.v. bolus with escalation to 60 mg/m ² in the absence of toxicity v.s. four-week courses of cisplatin 60 mg/m ² on day 1 plus vinblastine 0.1 mg/kg on days 1 and 15 i.v. plus bleomycin 15 U i.v. weekly	16 vs. 24; n.s.	7.8 vs. 7.2; n.s.
Eisenberger et al. (Eisenberger et al., 1989)	MTX 40 mg/m ² given i.v. weekly vs. carboplatin 400 mg/m ² given i.v. monthly in combination with MTX given at the same dose/schedule	25 vs. 25; n.s.	2 vs. 3; n.s.
Forastiere et al. (Forastiere et al., 1992)	MTX 40 mg/m ² given i.v. weekly (MTX) vs. cisplatin 100 mg/m ² given i.v. on day 1 and 5-FU 1,000 mg/m ² per day for a 96-hour continuous infusion, repeated every 21 days (CP + 5FU) vs. carboplatin 300 mg/m ² given i.v. on day 1 and 5-FU 1,000 mg/m ² per day for a 96-hour continuous infusion, repeated every 28 days (CB + 5-FU)	10 vs. 32 vs. 21; CP + 5-FU superior to MTX with p<0.001	5.6 vs. 6.6 vs. 5.0; n.s.
Jacobs et al. (Jacobs et al., 1992)	Cisplatin 100 mg/m ² given i.v. on day 1 and 5-FU 1,000 mg/m ² per day for a 96-hour continuous infusion, repeated every 21 days (CP + 5-FU) vs. cisplatin 100 mg/m ² given i.v. on day 1 and repeated every 21 days (CP) v.s 5-FU 1,000 mg/m ² per day for a 96-hour continuous infusion, repeated every 21 days (5-FU)	32 vs. 17 vs. 13; CP + 5-FU superior to CP and to 5-FU with p=0.035	5.7 for all treatments
Clavel et al. (Clavel et al., 1994)	MTX 40 mg/m ² given i.v. on days 1 and 15, weekly, bleomycin 10 mg and vincristine 2 mg given on days 1, 8 and 15, CP 50 mg/m ² given on day 4, repeated every 21 days (CABO) vs. cisplatin 100 mg/m ² given i.v. on day 1 and 5-FU 1,000 mg/m ² per day for a 96-hour continuous infusion, repeated every 21 days (CF) vs. cisplatin 50 mg/m ² given on days 1 and 8, repeated every 28 days (C)	34 vs. 31 vs. 15; CABO and CF superior to C with p<0.001, p=0.003, respectively (9.5 vs. 1.7 vs. 2.5; CABO superior to CF with p=0.01 and superior to C with p=0.02)	7.3 for all treatments

Authors	Therapy regimens	Response rate % (CR %)	Median survival (months)
Schrijvers et al. (Schrijvers et al., 1998)	Cisplatin 100 mg/m ² given i.v. on day 1 and 5-FU 1,000 mg/m ² per day for a 96-hour continuous infusion, repeated every 21 days vs. same schedule with interferon alfa-2b given s.c. 3 x 10 ⁶ U/day on days 1 to 5, repeated every 21 days	47 vs. 48; p<0.70 (10.7 vs. 6.8; p<0.50)	6.3 vs. 6; p=0.49
Forastiere et al. (Forastiere et al., 2001b)	Paclitaxel 200 mg/m ² for a 24-hour continuous infusion plus cisplatin 75 mg/m ² + granulocyte colony-stimulating factor, repeated every 21 days vs. paclitaxel 135 mg/m ² for a 24-hour continuous infusion plus cisplatin 75 mg/m ² , repeated every 21 days	35 vs. 36; n.s. (4 vs. 12; p=0.038)	7.6 vs. 6.8; p=0.759
Gibson et al. (Gibson et al., 2005)	Cisplatin 100 mg/m ² given i.v. on day 1 and 5-FU 1,000 mg/m ² per day for a 96-hour continuous infusion, repeated every 21 days vs. cisplatin 75 mg/m ² given i.v. on day 1 and paclitaxel 175 mg/m ² given over 3 hours on day 1, repeated every 21 days	27 vs. 26; n.s. (6.7 vs. 7.0; n.s.)	8.7 vs. 8.1; n.s.
Burtneess et al. (Burtneess et al., 2005)	Cetuximab 200 mL/m ² given i.v. on day 1 over 2 hours for cycle 1, and in subsequent cycles cetuximab 125 mL/m ² given i.v. weekly over 1-hour plus cisplatin 100 mg/m ² given i.v. on day 1 every 4 weeks vs. placebo plus cisplatin 100 mg/m ² given i.v. on day 1 every 4 weeks	26 vs. 10; p=0.03	8.0 vs. 9.2; p=0.21
Vermorken et al. (Vermorken et al., 2008)	Cisplatin 100 mg/m ² given i.v. on day 1 or carboplatin 5 mg per milliliter per minute at an AUC given on day 1 as a 1-hour infusion plus 5-FU 1,000 mg/m ² per day for a 96-hour continuous infusion, repeated every 21 days vs. the same chemotherapy regimen plus cetuximab 400 mg/m ² given initially as intravenous infusion over 2-hours, then 250 mg/m ² given weekly as a 1-hour intravenous infusion	20 vs. 36; p<0.001	7.4 vs. 10; p=0.04

CR: complete response; MTX: methotrexate; i.m.: intramuscularly; i.v.: intravenously; U: units; 5-FU: 5-fluorouracil; s.c.: subcutaneously; AUC: area under the curve

Table 4. Randomised studies of chemotherapy in recurrent/metastatic head and neck cancer

the margins of resection. Aspiration pneumonia after partial laryngectomy is postoperative complication occasionally requiring total laryngectomy. Pharyngeal stenosis is commonly manifested following a jejunal free flap reconstruction of a total laryngopharyngectomy. Late complications include pharyngoesophageal stenosis and stricture, chronic pharyngocutaneous fistula and functional deficits in swallowing.

Acute complications of radiotherapy include development of mucositis, dermatitis, xerostomia, and dysgeusia. Acute mucositis as the most frequently observed radiation-induced morbidity is related to the intensity of the treatment regimen with a greater incidence of grade 3-4 reactions associated with accelerated fractionation and concurrent chemoradiotherapy. The occurrence of arytenoid edema being well known consequence of radiotherapy lead to tracheotomy in less than 10% of patients. Late complications of radiotherapy include fibrosis of the soft tissues in the neck, fibrosis of the esophagus, which may develop into an esophageal stricture or tracheoesophageal fistula, and radiation-induced hypothyroidism requiring thyroid-replacement therapy. Rarely seen, but potentially serious late complications are carotid rupture, pharyngocutaneous fistula, laryngeal chondronecrosis or soft tissue necrosis of the posterior pharyngeal wall, laryngeal strictures, brachial plexus injury, and the possibility of spinal cord injury. When keeping the dose to the spinal cord under 50 Gy, myelitis is rarely occurred complication (Emami et al., 1991; Marcus & Million, 1990). However, L'Hermitte sign can occur 2 to 3 months after treatment and last several weeks to months.

Chemotherapy complications include adverse effects in dependence of the specific cytotoxic agents used. Cisplatin-based regimens induce nausea and vomiting, and cumulative toxicities from cisplatin such as ototoxicity, peripheral neuropathy, nephrotoxicity, or myelosuppression. The use of 5-fluorouracil can cause myelosuppression in addition to mucositis, diarrhoea, and vascular irritation. Common adverse effects of taxanes are peripheral neuropathy, myelosuppression, alopecia, and potential hypersensitivity reactions.

9. Follow-up

Post treatment follow-up is required to evaluate treatment response, and is also intended to detect early recurrence, and identify second primary cancers. The majority of local recurrences occur within the first 2 years of treatment (Fu et al., 2000; Ho et al., 1993). Independent second malignancies in the upper aerodigestive tract have an annual incidence of approximately 3% (Cooper et al., 1989; Spector et al., 2001), and the risk for their development is not time limited.

Patients should be followed up every 1-3 months over the first year after treatment, every 2-4 months in the second year after treatment, every 4-6 months in the third through the fifth years after treatment, and every 6-12 months thereafter (National Comprehensive Cancer Network [NCCN], 2011).

Each follow-up examination should include history, physical examination, and fiberoptic endoscopy, or indirect mirror exam. Diagnostic imaging of the neck should be performed for the assessment of response to treatment and must be also performed in any patient with new signs and symptoms suggesting recurrence development. If PET-CT scan is used for follow-up, the first scan should be performed at not less than 3 months after treatment to reduce false-positive scans that can result from active inflammation following treatment (Robson, 2002). Biopsy is mandatory if there is clinical suspicion of residual or recurrent disease. Annual chest is primarily recommended for detection of second primary tumours. In patients who received surgery or radiation to a substantial proportion of the thyroid

gland, monitoring of thyroid-stimulating hormone (TSH) levels is recommended every 6 to 12 months.

10. Conclusion

Patients with early-stage hypopharyngeal cancers including T1N0-1 and small T2N0 lesions achieve satisfactory rates of local control when treated with either conservation surgery or radiotherapy as a single treatment modality. Patients with locally-regionally advanced resectable hypopharyngeal cancers could be treated with radical surgery followed by postoperative radiotherapy or postoperative concurrent chemoradiotherapy. In patients with advanced resectable hypopharyngeal cancers requiring laryngopharyngectomy for the surgical approach, concurrent chemoradiotherapy or altered fractionation radiotherapy are treatment modalities allowing anatomic and functional organ preservation while demonstrating equivalent results in terms of survival with those obtained with immediate surgery. For patients presenting with unresectable hypopharyngeal cancer without evidence of distant metastases, radiotherapy and concurrent cisplatin-based chemotherapy should be considered standard treatment approach. The adoption of IMRT, considering its more conformal dose distribution with steep gradients between planning target volumes and critical structures, should be advocated in the routine clinical practice as radiotherapy technique in the treatment of hypopharyngeal cancer.

However, patients with early stage disease are relatively rare, and for those with advanced disease being most frequently present, the results in the achievement of long-term control and survival with the advancement made using aggressive therapeutic approaches remain quite unsatisfactory. Sequential therapy (induction chemotherapy followed by concurrent chemoradiotherapy), intensified radiotherapy regimens in combination with chemotherapy, and the incorporation of molecular targeted therapies in combination with traditional chemotherapy and radiotherapy are strategies currently investigated in an effort to improve outcomes in patients with advanced hypopharyngeal cancer.

11. References

- Adelstein, D.J. & LeBlanc, M. (2006b). Does Induction Chemotherapy Have a Role in the Management of Locoregionally Advanced Squamous Cell Head and Neck Cancer? *J Clin Oncol*, Vol.24, No.17, (June 2006), pp. 2624-2628, ISSN 0732-183X
- Adelstein, D.J.; Lavertu, P.; Saxton, J.P.; Secic, M.; Wood, B.G.; et al. (2000). Mature Results of a Phase III Randomized Trial Comparing Chemoradiotherapy With Radiation Therapy Alone in Patients With Stage III and IV Squamous Cell Carcinoma of the Head and Neck. *Cancer*, Vol.88, No.4, (February 2000), pp. 876-883, ISSN 0008-543X
- Adelstein, D.J.; Li, Y.; Adams, G.L.; Wagner, H.; Kish, J.A.; et al. (2003). An Intergroup Phase III Comparison of Standard Radiation and Two Schedules of Concurrent Chemoradiotherapy in Patients With Unresectable Squamous Cell Head and Neck Cancer. *J Clin Oncol*, Vol.21, No.1, (January 2003), pp. 92-98, ISSN 0732-183X
- Adelstein, D.J.; Saxton, J.P.; Lavertu, P.; Tuason, L.; Wood, B.G.; et al. (1997). A Phase III Randomized Trial Comparing Concurrent Chemotherapy and Radiotherapy With Radiotherapy Alone in Resectable Stage III and IV Squamous Cell Head and Neck

- Cancer: Preliminary Results. *Head Neck*, Vol.19, No.7, (October 1997), pp. 567-575, ISSN 1043-3074
- Adelstein, D.J.; Saxton, J.P.; Rybicki, L.A.; Esclamado, R.M.; Wood, B.G.; et al. (2006a). Multiagent Concurrent Chemoradiotherapy for Locoregionally Advanced Squamous Cell Head and Neck Cancer: Mature Results from a Single Institution. *J Clin Oncol*, Vol.24, No.7, (March 2006), pp. 1064-1071, ISSN 0732-183X
- Akimoto, T.; Mitsuhashi, N.; Sakurai, H.; Takahashi, T.; Yamakawa, M.; et al. (1996). Results of Radiation Therapy for Hypopharyngeal Carcinoma: Impact of Accelerated Hyperfractionation on Prognosis. *Japanese Journal of Clinical Oncology*, Vol.26, No.3, (June 1996), pp. 169-174, ISSN 0368-2811
- Allal, A.S. (1997). Cancer of the Pyriform Sinus: Trends Towards Conservative Treatment. *Bulletin du Cancer*, Vol.84, No.7, (July 1997), pp. 757-762, ISSN 1769-6917
- Aluffi, P.; Pisani, P.; Policarpo, M. & Pia F. (2006). Contralateral Cervical Lymph Node Metastases in Pyriform Sinus Carcinoma. *Otolaryngol Head Neck Surg*, Vol.134, No.4, (April 2006), pp. 650-653, ISSN 0194-5998
- Amatsu, M.; Mohri, M. & Kinishi M. (2001). Significance of Retropharyngeal Node Dissection at Radical Surgery for Carcinoma of the Hypopharynx and Cervical Esophagus. *Laryngoscope*, Vol.111, No.6, (June 2001), pp. 1099-1103, ISSN 0023-852X
- Ambrosch, P.; Kron, M.; Pradier, O. & Steiner W. (2001). Efficacy of Selective Neck Dissection: A Review of 503 Cases of Elective and Therapeutic Treatment of the Neck in Squamous Cell Carcinoma of the Upper Aerodigestive Tract. *Otolaryngol Head Neck Surg*, Vol.124, No.2, (February 2001), pp. 180-187, ISSN 0194-5998
- Amdur, R.J.; Mendenhall, W.M.; Stringer, S.P.; Villaret, D.B. & Cassisi N.J. (2001). Organ Preservation With Radiotherapy for T1-T2 Carcinoma of the Pyriform Sinus. *Head Neck*, Vol.23, No.5, (May 2001), pp. 353-362, ISSN 1043-3074
- Ang, K.K.; Harris, J.; Garden, A.S.; Trotti, A.; Jones, C.U.; et al. (2005). Concomitant Boost Radiation Plus Concurrent Cisplatin for Advanced Head and Neck Carcinomas: Radiation Therapy Oncology Group Phase II Trial 99-14. *J Clin Oncol*, Vol.23, No.13, (May 2005), pp. 3008-3015, ISSN 0732-183X
- Ang, K.K.; Trotti, A.; Brown, B.W.; Garden, A.S.; Foote, R.L.; et al. (2001). Randomized Trial Addressing Risk Features and Time Factors of Surgery plus Radiotherapy in Advanced Head and Neck Cancer. *Int J Radiat Oncol Biol Phys*, Vol.51, No.3, (November 2001), pp. 571-578, ISSN 0360-3016
- Antognoni, P.; Bossi, A.; Cerizza, L.; Esposito, E.; Molteni, M.; et al. (1991). Exclusive Radiotherapy of Carcinoma of the Hypopharynx. Retrospective Study of a Series of 100 Patients. *La Radiologia Medica*, Vol.82, No.3, (September 1991), pp. 328-333, ISSN 0033-8362
- Arriagada, R.; Eschwege, F.; Cachin, Y. & Richard J.M. (1983). The Value of Combining Radiotherapy With Surgery in the Treatment of Hypopharyngeal and Laryngeal Cancers. *Cancer*, Vol.51, No.10, (May 1983), pp. 1819-1825, ISSN 0008-543X
- Awwad, H.K.; Lotayef, M.; Shouman, T.; Begg, A.C.; Wilson, G.; et al. (2002). Accelerated Hyperfractionation (AHF) Compared to Conventional Fractionation (CF) in the Postoperative Radiotherapy of Locally Advanced Head and Neck Cancer: Influence

- of Proliferation. *Br J Cancer*, Vol.86, No.4, (February 2002), pp. 517-523, ISSN 0007-0920
- Axon, P.R.; Woolford, T.J.; Hargreaves, P.; Yates, P.; Birzgalis, E.R.; et al. (1997). A Comparison of Surgery and Radiotherapy in the Management of Post-Cricoid Carcinoma. *Clinical Otolaryngology and Allied Sciences*, Vol.22, No.4, (August 1997), pp. 370-374, ISSN 0307-7772
- Barton, R.T. (1973). Surgical Treatment of Carcinoma of the Pyriform Sinus. *Arch Otolaryngol*, Vol.97, No.4, (April 1973), pp. 337-339, ISSN 0003-9977
- Barzan, L.; Veronesi, A.; Caruso, G.; Serraino, D.; Magri, D.; et al. (1990). Head and Neck Cancer and Ageing: A Retrospective Study in 438 Patients. *Journal of Laryngology and Otology*, Vol.104, No.8, (August 1990), pp. 634-640, ISSN 0022-2151
- Bataini, J.P. (1993). Radiotherapy in N0 Head and Neck Cancer Patients. *European Archives of Oto-Rhino-Laryngology*, Vol.250, No.8, (February 1993), pp. 442-445, ISSN 0937-4477
- Bataini, J.P.; Bernier, J.; Jaulerry, C.; Brunin, F. & Pontvert D. (1990). Impact of Cervical Disease and Its Definitive Radiotherapeutic Management on Survival: Experience in 2013 Patients With Squamous Cell Carcinomas of Oropharynx and Pharyngolarynx. *Laryngoscope*, Vol.100, No.7, (July 1990), pp. 716-723, ISSN 0023-852X
- Bataini, P.; Brugere, J.; Bernier, J.; Jaulerry, C.H.; Picot, C. & Ghossein N.A. (1982). Results of Radical Radiotherapeutic Treatment of Carcinoma of the Pyriform Sinus: Experience of the Institut Curie. *Int J Radiat Oncol Biol Phys*, Vol.8, No.8, (August 1982), pp. 1277-1286, ISSN 0360-3016
- Beauvillain, C.; Mahe, M.; Bourdin, S.; Peuvrel, P.; Bergerot, P.; et al. (1997). Final Results of a Randomized Trial Comparing Chemotherapy plus Radiotherapy With Chemotherapy plus Surgery plus Radiotherapy in Locally Advanced Resectable Hypopharyngeal Carcinomas. *Laryngoscope*, Vol.107, No.5, (May 1997), pp. 648-653, ISSN 0023-852X
- Bernier, J. & Bentzen, S.M. (2003). Altered Fractionation and Combined Radio-Chemotherapy Approaches: Pioneering New Opportunities in Head and Neck Oncology. *Eur J Cancer*, Vol.39, No.5, (March 2003), pp. 560-571, ISSN 0014-2964
- Bernier, J. & Cooper J.S. (2005). Chemoradiation After Surgery for High-Risk Head and Neck Patients: How Strong is the Evidence? *Oncologist*, Vol.10, No.3, (March 2005), pp. 215-224, ISSN 1083-7159
- Bernier, J.; Domenge, C.; Ozsahin, M.; Matuszewska, K.; Levebvre, J.L.; et al. (2004). Postoperative Irradiation With or Without Concomitant Chemotherapy for Locally Advanced Head and Neck Cancer. *N Engl J Med*, Vol.350, No.19, (May 2004), pp. 1945-1952, ISSN 0028-4793
- Bonner, J.A.; Harari, P.M.; Giralt, J. ; Cohen, R.B.; Jones, C.U.; et al. (2010). Radiotherapy plus Cetuximab for Locoregionally Advanced Head and Neck Cancer: 5-Year Survival Data from a Phase 3 Randomised Trial, and Relation Between Cetuximab-Induced Rash and Survival. *Lancet Oncol*, Vol.11, No.1, (January 2010), pp. 21-28, ISSN 1470-2045

- Bonner, J.A.; Harari, P.M.; Giralt, J.; Azarnia, N.; Shin, D.M.; et al. (2006). Radiotherapy plus Cetuximab for Squamous-Cell Carcinoma of the Head and Neck. *N Engl J Med*, Vol.354, No.6, (February 2006), pp. 567-578, ISSN 0028-4793
- Bourhis, J.; Amand, C.; Pignon, J.P.; MACH-NC Collaborative Group. (2004). Update of MACH-NC (Meta-Analysis of Chemotherapy in Head & Neck Cancer) Database Focused on Concomitant Chemotherapy. *J Clin Oncol, 2004 ASCO Annual Meeting Proceedings (Post-Meeting Edition)*, Vol.22, Suppl.14, (July 2004), 5505, ISSN 0732-183X
- Bourhis, J.; Overgaard, J.; Audry, H.; Ang, K.K.; Saunders, M.; Bernier, J.; et al. (2006). Hyperfractionated or Accelerated Radiotherapy in Head and Neck Cancer: A Meta-Analysis. *Lancet*, Vol.368, No.9538, (September 2006), pp. 843-854, ISSN 0023-7507
- Bova, R.; Goh, R.; Poulson, M. & Coman, W.B. (2005). Total Pharyngolaryngectomy for Squamous Cell Carcinoma of the Hypopharynx: A Review. *Laryngoscope*, Vol.115, No.5, (May 2005), pp. 864-69, ISSN 0023-852X
- Boyd, T.S.; Harari, P.M.; Tannehill, S.P.; Voytovich, M.C.; Hartig, G.K.; et al. (1998). Planned Postradiotherapy Neck Dissection in Patients With Advanced Head and Neck Cancer. *Head Neck*, Vol.20, No.2, (March 1998), pp. 132-137, ISSN 1043-3074
- Brennan, J.A.; Boyle, J.O.; Koch, W.M.; Goodman, S.N.; Hruban, R.H.; et al. (1995). Association Between Cigarette Smoking and Mutation of the P53 Gene in Squamous-Cell Carcinoma of the Head and Neck. *N Engl J Med*, Vol.332, No.11, (March 1995), pp. 712-717, ISSN 0028-4793
- Brizel, D.M.; Albers, M.E.; Fisher, S.R.; Scher, R.L.; Richtsmeier, W.J.; et al. (1998). Hyperfractionated Irradiation With or Without Concurrent Chemotherapy for Locally Advanced Head and Neck Cancer. *N Engl J Med*, Vol.338, No.25, (June 1998), pp. 1798-1804, ISSN 0028-4793
- Brizel, D.M.; Prosnitz, R.G.; Hunter, S.; Fisher, S.R.; Clough, R.L.; et al. (2004). Necessity for Adjuvant Neck Dissection in Setting of Concurrent Chemoradiation for Advanced Head-And-Neck Cancer. *Int J Radiat Oncol Biol Phys*, Vol.58, No.5, (April 2004), pp. 1418-1423, ISSN 0360-3016
- Browman, G.P. & Cronin, L. (1994). Standard Chemotherapy in Squamous Cell Head and Neck Cancer: What We Have Learned from Randomized Trials. *Seminars in Oncology*, Vol.21, No.3, (June 1994), pp. 311-319, ISSN 0093-7754
- Browman, G.P. (1994). Evidence-Based Recommendations Against Neoadjuvant Chemotherapy for Routine Management of Patients With Squamous Cell Head and Neck Cancer. *Cancer Investigation*, Vol.12, No.6, (January 1994), pp. 662-670, ISSN 0735-7907
- Browman, G.P.; Hodson, D.I.; Mackenzie, R.J.; Bestic, N.; Zuraw, L.; Cancer Care Ontario Practice Guideline Initiative Head and Neck Cancer Disease Site Group. (2001). Choosing a Concomitant Chemotherapy and Radiotherapy Regimen for Squamous Cell Head and Neck Cancer: A Systematic Review of the Published Literature With Subgroup Analysis. *Head Neck*, Vol.23, No.7, (July 2001), pp. 579-589, ISSN 1043-3074

- Buckley, J.G. & MacLennan K. (2000). Cervical Node Metastases in Laryngeal and Hypopharyngeal Cancer: A Prospective Analysis of Prevalence and Distribution. *Head Neck*, Vol.22, No.4, (July 2000), pp. 380-385, ISSN 1043-3074
- Budach, V.; Stuschke, M.; Budach, W.; Baumann, M.; Geismar, D.; et al. (2005). Hyperfractionated Accelerated Chemoradiation With Concurrent Fluorouracil-Mitomycin is More Effective than Dose-Escalated Hyperfractionated Accelerated Radiation Therapy Alone in Locally Advanced Head and Neck Cancer: Final Results of the Radiotherapy Cooperative Clinical Trials Group of the German Cancer Society 95-06 Prospective Randomized Trial. *J Clin Oncol*, Vol.23, No.6, (February 2005), pp. 1125-1135, ISSN 0732-183X
- Budach, W.; Hehr, T.; Budach, V.; Belka, C. & Dietz K. (2006). A Meta-Analysis of Hyperfractionated and Accelerated Radiotherapy and Combined Chemotherapy and Radiotherapy Regimens in Unresected Locally Advanced Squamous Cell Carcinoma of the Head and Neck. *BMC Cancer*, Vol.6, (January 2006), p. 28, ISSN 1471-2407
- Burtneess, B.; Goldwasser, M.A.; Flood, W.; Mattar, B.; Forastiere, A.A. (2005). Phase III Randomized Trial of Cisplatin Plus Placebo Compared With Cisplatin Plus Cetuximab in Metastatic/Recurrent Head and Neck Cancer: An Eastern Cooperative Oncology Group Study. *J Clin Oncol*, Vol.23, No.34, (December 2005), pp. 8646-8654, ISSN 0732-183X
- Byers, R.M.; Wolf, P.F. & Ballantyne, A.J. (1988). Rationale for Elective Modified Neck Dissection. *Head Neck Surg*, Vol.10, No.3, (January-February 1988), pp. 160-7, ISSN 0148-6403
- Carpenter, R.J. 3rd. & DeSanto, L.W. (1977). Cancer of the Hypopharynx. *Surgical Clinics of North America*, Vol.57, No.4, (August 1977), pp. 723-735, ISSN 0960-7404
- Chen, S.W.; Yang, S.N.; Liang, J.A.; Lin, F.J. & Tsai, M.H. (2009). Prognostic Impact of Tumor Volume in Patients With Stage III-IVA Hypopharyngeal Cancer Without Bulky Lymph Nodes Treated With Definitive Concurrent Chemoradiotherapy. *Head Neck*, Vol.31, No.6, (June 2009), pp. 709-716, ISSN 1043-3074
- Chevalier, D.; Watelet, J.B.; Darras, J.A. & Piquet J.J. (1997). Supraglottic Hemilaryngopharyngectomy plus Radiation for the Treatment of Early Lateral Margin and Pyriform Sinus Carcinoma. *Head Neck*, Vol.19, No.1, (January 1997), pp. 1-5, ISSN 1043-3074
- Chu, P.Y.; Li, W.Y. & Chang, S.Y. (2008). Clinical and Pathologic Predictors of Survival in Patients With Squamous Cell Carcinoma of Hypopharynx After Surgical Treatment. *Annals of Otology, Rhinology and Laryngology*, Vol.117, No.3, (March 2008), pp. 201-06, ISSN 0003-4894
- Chung, C.H.; Ely, K.; McGavran, L.; Varella-Garcia, M.; Parker, J.; et al. (2006). Increased Epidermal Growth Factor Receptor Gene Copy Number is Associated With Poor Prognosis in Head and Neck Squamous Cell Carcinomas. *J Clin Oncol*, Vol.24, No.25, (September 2006), pp. 4170-4176, ISSN 0732-183X
- Clavel, M.; Vermorken, J.B.; Cognetti, F.; Cappelaere, P.; de Mulder, P.H.; et al. (1994). Randomized Comparison of Cisplatin, Methotrexate, Belomycin and Vincristine (CABO) Versus Cisplatin and 5-Fluorouracil (CF) Versus Cisplatin (C) in Recurrent

- or Metastatic Squamous Cell Carcinoma of the Head and Neck. A Phase III Study of the EORTC Head and Neck Cancer Cooperative Group. *Annals of Oncology*, Vol.5, No.6, (July 1994), pp. 521-526, ISSN 0923-7534
- Clayman, G.L. & Frank, D.K. (1998). Selective Neck Dissection of Anatomically Appropriate Levels is as Efficacious as Modified Radical Neck Dissection for Elective Treatment of the Clinically Negative Neck in Patients With Squamous Cell Carcinoma of the Upper Respiratory and Digestive Tracts. *Archives of Otolaryngology – Head & Neck Surgery*, Vol.124, No.3, (March 1998), pp. 348-352, ISSN: 0886-4470
- Clayman, G.L. & Weber, R.S. (1996). Cancer of the Hypopharynx and Cervical Esophagus, In: *Cancer of the Head and Neck*, E. Myers & J.Y. Suen, (Eds.), 423-438, W.B. Saunders, ISBN 978-0721655505, New York
- Colevas, A.D. (2006). Chemotherapy Options for Patients With Metastatic or Recurrent Squamous Cell Carcinoma of the Head and Neck. *J Clin Oncol*, Vol.24, No.17, (June 2006), pp. 2644-2652, ISSN 0732-183X
- Cooper, J.S.; Pajak, T.F.; Forastiere, A.; Jacobs, J.; Fu, K.K.; et al. (1998). Precisely Defining High-Risk Operable Head and Neck Tumors Based on RTOG #85-03 and #88-24: Targets for Postoperative Radiochemotherapy? *Head Neck*, Vol.20, No.7, (October 1998), pp. 588-594, ISSN 1043-3074
- Cooper, J.S.; Pajak, T.F.; Rubin, P.; Tupchong, L.; Brady, L.W.; et al. (1989). Second Malignancies in Patients who Have Head and Neck Cancer: Incidence, Effect on Survival and Implications Based on RTOG Experience. *Int J Radiat Oncol Biol Phys*, Vol.17, No.3, (September 1989), pp. 449-456, ISSN 0360-3016
- Cooper, J.S.; Pajak, T.H.; Forastiere, A.A.; Jacobs, J.; Campbell, B.H.; et al. (2004). Postoperative Concurrent Radiotherapy and Chemotherapy for High-Risk Squamous-Cell Carcinoma of the Head and Neck. *N Engl J Med*, Vol.350, No.19, (May 2004), pp. 1937-1944, ISSN 0028-4793
- Cooper, J.S.; Porter, K.; Mallin, K.; Hoffman, H.T.; Weber, R.S.; et al. (2009). National Cancer Database Report on Cancer of the Head and Neck: 10-Year Update. *Head Neck*, Vol.31, No.6, (June 2009), pp. 748-758, ISSN 1043-30742009
- Corvo, R. (2007). Evidence-Based Radiation Oncology in Head and Neck Squamous Cell Carcinoma. *Radiother Oncol*, Vol.85, No.1, (October 2007), pp. 156-170, ISSN 0167-8140
- Creak, A.L.; Harrington, K. & Nutting, C. (2005). Treatment of Recurrent Head and Neck Cancer: Re-Irradiation or Chemotherapy? *Clinical Oncology (Royal College of Radiologists)*, Vol.17, No.3, (May 2005), pp. 138-147, ISSN 0936-6555
- Daly, M.E.; Le, Q.T.; Jain, A.K.; Maxim, P.G.; Hsu, A.; et al. (2011). Intensity-Modulated Radiotherapy for Locally Advanced Cancers of the Larynx and Hypopharynx. *Head Neck*, Vol.33, No.1, (January 2011), pp. 103-111, ISSN 1043-3074
- Davidge-Pitts, K.J. & Mannel A. (1983). Pharyngolaryngectomy With Extrathoracic Esophagectomy. *Head Neck Surg*, Vol.6, No.1, (September-October 1983), pp. 571-574 ISSN 0148-6403
- Davidson, J.; Keane, T.; Brown, D.; Freeman, J.; Gullane, P.; et al. (1997). Surgical Salvage After Radiotherapy for Advanced Laryngopharyngeal Carcinoma. *Archives of*

- Otolaryngology – Head & Neck Surgery*, Vol.123, No.4, (April 1997), pp. 420-424, ISSN 0886-4470
- De Bree, R.; Leemans, C.R.; Silver, C.E.; Robbins, K.T.; Rodrigo, J.P.; et al. (2011). Paratracheal Lymph Node Dissection in Cancer of the Larynx, Hypopharynx, and Cervical Esophagus: The Need for Guidelines. *Head Neck*, Vol.33, No.6, (June 2011), pp. 912-916, ISSN 1043-3074
- De la Vega, F.A.; Garcia, R.V.; Dominguez, D.; Iturre, E.V.; Lopez, E.M.; et al. (2003). Hyperfractionated Radiotherapy and Concomitant Cisplatin for Locally Advanced Laryngeal and Hypopharyngeal Carcinomas: Final Results of a Single Institutional Program. *Am J Clin Oncol*, Vol.26, No.6, (December 2003), pp. 550-557, ISSN 0277-3732
- Dinshaw, K.A.; Agarwal, J.P.; Laskar, S.G.; Gupta, T.; Shrivastava, S.K.; et al. (2005). Head and Neck Squamous Cell Carcinoma: The Role of Post-Operative Adjuvant Radiotherapy. *J Surg Oncol*, Vol.91, No.1, (July 2005), pp. 48-55, ISSN 0022-4790
- Edge, S.B.; Byrd, D.R.; Compton, C.C.; Fritz, A.G.; Greene, F.L. & Trotti, A. (Eds). (2009). *AJCC Cancer Staging Manual*, Springer, ISBN 978-0-387-88440-0, New York
- Eisenberger, M.; Krasnow, S.; Ellenberg, S.; Silva, H.; Abrams, J.; et al. (1989). A Comparison of Carboplatin Plus Methotrexate Versus Methotrexate Alone in Patients With Recurrent and Metastatic Head and Neck Cancer. *J Clin Oncol*, Vol.7, No.9, (September 1989), pp. 1341-1345, ISSN 0732-183X
- El Badawi, S.A.; Goepfert, H.; Fletcher, G.H.; Herson, J. & Oswald, M.J. (1982). Squamous Cell Carcinoma of the Pyriform Sinus. *Laryngoscope*, Vol.92, No.4, (April 1982), pp. 357-364, ISSN 0023-852X
- Elias, M.M.; Hilgers, F.J.M.; Keus, R.B.; Gregor, R.T.; Hart, A.A.M.; et al. (1995). Carcinoma of the Pyriform Sinus: A Retrospective Analysis of Treatment Results Over a 20-Year Period. *Clinical Otolaryngology and Allied Sciences*, Vol.20, No.3, (June 1995), pp. 249-53, ISSN 0307-7772
- El-Sayed, S. & Nelson, N. (1996). Adjuvant and Adjunctive Chemotherapy in the Management of Squamous Cell Carcinoma of the Head and Neck Region. A Meta-Analysis of Prospective and Randomized Trials. *J Clin Oncol*, Vol.14, No.3, (March 1996), pp. 838-847, ISSN 0732-183X
- Emami, B.; Lyman, J.; Brown, A.; Coia, L.; Goitein, M.; et al. (1991). Tolerance of Normal Tissue to Therapeutic Irradiation. *Int J Radiat Oncol Biol Phys*, Vol.21, No.1, (May 1991), pp. 109-122, ISSN 0360-3016
- Ernoux-Neufcoeur, P.; Arafa, M.; Decaestecker, C.; Duray, A.; Remmelink, M.; et al. (2001). Combined Analysis of HPV DNA, P16, P21 and P53 to Predict Prognosis in Patients With Stage IV Hypopharyngeal Carcinoma. *Journal of Cancer Research and Clinical Oncology*, Vol.137, No.1, (January 2011), pp. 173-181, ISSN 0171-5216
- Fakhry, C. & Gillison, M. (2006). Clinical Implications of Human Papillomavirus in Head and Neck Cancers. *J Clin Oncol*, Vol.24, No.17, (June 2006), pp. 2606-2611, ISSN 0732-183X
- Farrington, W.T.; Weighill, J.S. & Jones P.H. (1986). Post-Cricoid Carcinoma (Ten-Year Retrospective Study). *Journal of Laryngology and Otology*, Vol.100, No.1, (January 1986), pp. 79-84, ISSN 0022-2151

- Fein, D.A.; Mendenhall, W.M.; Parsons, J.T.; Stringer, S.P.; Cassisi, N.J.; et al. (1993). Pharyngeal Wall Carcinoma Treated With Radiotherapy: Impact of Treatment Technique and Fractionation. *Int J Radiat Oncol Phys*, Vol.26, No.5, (August 1993), pp. 751-757, ISSN 0360-3016
- Flanders, W.D. & Rothman, K.J. (1982). Interaction of Alcohol and Tobacco in Laryngeal Cancer. *Am J Epidemiol*, Vol.115, No.3, (March 1982), pp. 371-379, ISSN 0002-9262
- Forastiere, A.A.; Ang, K.; Brizel, D.; Brockstein, B.E.; Dunphy, F.; et al. (2005). Head and Neck Cancers. *Journal of the National Comprehensive Cancer Network*, Vol.3, No.3, (May 2005), pp. 316-391, ISSN 1540-1405
- Forastiere, A.A.; Berkey, B.; Maor, M.; Weber, R.; Goepfert, H.; et al. (2001a). Phase III Trial to Preserve the Larynx: Induction Chemotherapy and Radiotherapy Versus Concomitant Chemoradiotherapy Versus Radiotherapy Alone, Intergroup Trial R91-11, *Proceedings of the American Society of Clinical Oncology 2001 37th ASCO Annual Meeting*, 20(abstr. 4), ISSN 0732-183X, San Francisco, California, USA, May 12-15, 2001
- Forastiere, A.A.; Leong, T.; Rowinsky, E.; Murphy, B.A.; Vlock, D.R.; et al. (2001b). Phase III Comparison of High-Dose Paclitaxel + Cisplatin + Granulocyte Colony-stimulating Factor Versus Low-Dose Paclitaxel + Cisplatin in Advanced Head and Neck Cancer: Eastern Cooperative Oncology Group Study E1393. *J Clin Oncol*, Vol.19, No.4, (February 2001), pp. 1088-1095, ISSN 0732-183X
- Forastiere, A.A.; Metch, B.; Schuller, D.E.; Ensley, J.F.; Hutchins, L.F.; et al. (1992). Randomized Comparison of Cisplatin Plus Fluorouracil and Carboplatin Plus Fluorouracil Versus Methotrexate in Advanced Squamous-Cell Carcinoma of the Head and Neck: A Southwest Oncology Group Study. *J Clin Oncol*, Vol.10, No.8, (August 1992), pp. 1245-1251, ISSN 0732-183X
- Foucher, M.; Poissonnet, G.; Rame, J.P.; Toussaint, B.; Vedrine, P.O.; et al. (2009). T1-T2 N0 Hypopharyngeal Cancers Treated With Surgery Alone. A GETTEC Study (French Neck Study Group). *Annales d'Oto-Laryngologie et de Chirurgie Cervico-Faciale*, Vol.126, No.4, (September 2009), pp. 203-207, ISSN 0003-438X
- Franceschi, S.; Munoz, N.; Bosch, X.F.; Snijders, P.J. & Walboomers, J.M. (1996). Human Papillomavirus and Cancers of the Upper Aerodigestive Tract: A Review of Epidemiological and Experimental Evidence. *Cancer Epidemiology, Biomarkers & Prevention*, Vol.5, No.7, (July 1996), pp. 567-575, ISSN 1055-9965
- Frank, J.L.; Garb, J.L.; Kay, S.; McClish, D.K.; Bethke, K.P.; et al. (1994). Postoperative Radiotherapy Improves Survival in Squamous Cell Carcinoma of the Hypopharynx. *Am J Surg*, Vol.168, No.5, (November 1994), pp. 476-480, ISSN 0899-7403
- Freeman, R.B.; Marks, J.E. & Ogura J.H. (1979). Voice Preservation in Treatment of Carcinoma of the Pyriform Sinus. *Laryngoscope*, Vol.89, No.11, (November 1979), pp. 1855-1863, ISSN 0023-852X
- Fu, K.K.; Pajak, T.F.; Trotti, A.; Jones, C.U.; Spencer, S.A.; et al. (2000). A Radiation Therapy Oncology Group (RTOG) Phase III Randomized Study to Compare Hyperfractionation and Two Variants of Accelerated Fractionation to Standard Fractionation Radiotherapy for Head and Neck Squamous Cell Carcinoma: First

- Report of RTOG 9003. *Int J Radiat Oncol Biol Phys*, Vol.48, No.1, (August 2000), pp. 7-16, ISSN 0360-3016
- Gale, N.; Cardesa, A. & Zidar N. (2006). Larynx and Hypopharynx, In: *Pathology of the Head and Neck*, A. Cardesa & P.J. Slootweg, (Eds), 198-226, Springer-Verlag, ISBN-10 3-540-30628-5, Berlin Heidelberg
- Garden, A.S.; Asper, J.A.; Morrison, W.H.; Schechter, N.R.; Glisson, B.S.; et al. (2004b). Is Concurrent Chemoradiation the Treatment of Choice for All Patients With Stage III or IV Head and Neck Carcinoma? *Cancer*, Vol.100, No.6, (March 2004), pp. 1171-1178, ISSN 0008-543X
- Garden, A.S.; Harris, J.; Vokes, E.E.; Forastiere, A.A.; Ridge, J.A.; et al. (2004a). Preliminary Results of Radiation Therapy Oncology Group 97-03: A Randomized Phase II Trial of Concurrent Radiation and Chemotherapy for Advanced Squamous Cell Carcinomas of the Head and Neck. *J Clin Oncol*, Vol.22, No.14, (July 2004), pp. 2856-2864, ISSN 0732-183X
- Garden, A.S.; Morrison, W.H.; Ang, K.K. & Peters, L.J. (1995). Hyperfractionated Radiation in the Treatment of Squamous Cell Carcinomas of the Head and Neck: A Comparison of Two Fractionation Schedules. *Int J Radiat Oncol Biol Phys*, Vol.31, No.3, (February 1995), pp. 493-502, ISSN 0360-3016
- Garden, A.S.; Morrison, W.H.; Clayman, G.L.; Ang, K.K. & Peters, L.J. (1996). Early Squamous Cell Carcinoma of the Hypopharynx: Outcomes of Treatment With Radiation Alone of the Primary Disease. *Head Neck*, Vol.18, No.4, (July-August 1996), pp. 317-322, ISSN 1043-3074
- Gibson, M.K.; Li, Y.; Murphy, B.; Hussain, M.H.A.; DeConti, R.C.; et al. (2005). Randomized Phase III Evaluation of Cisplatin plus Fluorouracil Versus Cisplatin plus Paclitaxel in Advanced Head and Neck Cancer (E1395): An Intergroup Trial of the Eastern Cooperative Oncology Group. *J Clin Oncol*, Vol.23, No.15, (May 2005), pp. 3562-3567, ISSN 0732-183X
- Glanz, H. (1999). Pathomorphological Aspects of Transoral Resection of Hypopharyngeal Carcinoma With Preservation of the Larynx. Patient Selection, Treatment Results. *Laryngorhinootologie*, Vol.78, No.12, (December 1999), pp. 654-662, ISSN 0935-8943
- Goldstein, D.P.; Clark, J.; Gullane P.J.; Dawson, L.A.; Siu, L.L.; et al. (2008). Carcinoma of the Hypopharynx. In: *Head and Neck Cancer: An Evidence-based Team Approach*, E.M. Genden & M.A. Varvares, (Eds.), 44-69, Thieme Medical Publishers, Inc, ISBN 978-1-58890-636-6, New York
- Grabenbauer, G.G.; Rodel, C.; Ernst-Stecken, A.; Brunner, T.; Hornung, J.; et al. (2003). Neck Dissection Following Radiochemotherapy of Advanced Head and Neck Cancer-for Selected Cases Only? *Radiother Oncol*, Vol.66, No.1, (January 2003), pp. 57-63, ISSN 0167-8140
- Gregoire, V.; Coche, E.; Cosnard, G.; Hamoir, M. & Reychler H. (2000). Selection and Delineation of Lymph Node Target Volumes in Head and Neck Conformal Radiotherapy. Proposal for Standardizing Terminology and Procedure Based on Surgical Experience. *Radiother Oncol*, Vol.56, No.2, (August 2000), pp. 135-150, ISSN 0167-8140

- Gregoire, V.; Eisbruch, A.; Hamoir, M. & Levendag P. (2006). Proposal for the Delineation of the Nodal CTV in the Node-Positive and Post-Operative Neck. *Radiother Oncol*, Vol.79, No.1, (April 2006), pp. 15-20, ISSN 0167-8140
- Gregoire, V.; Levendag, P.; Ang, K.K.; Bernier, J.; Braaksma, M.; et al. (2003). CT-Based Delineation of Lymph Node Levels Related CTVs in the Node Negative Neck: DAHANCA, EORTC, GORTEC, NCIC, RTOG Consensus Guidelines. *Radiother Oncol*, Vol.69, No.3, (December 2003), pp. 227-236, ISSN 0167-8140
- Gupta, T.; Agarwal, J.P.; Ghosh-Laskar, S.; Parikh, P.M.; D'Cruz, A.K.; et al. (2009b). Radical Radiotherapy With Concurrent Weekly Cisplatin in Locoregionally Advanced Squamous Cell Carcinoma of the Head and Neck: A Single-Institution Experience. *Head and Neck Oncology*, Vol.1, (June 2009), p. 17, ISSN1758-3284
- Gupta, T.; Chopra, S.; Agarwal, J.P.; Ghosh-Laskar, S.; D'Cruz, A.; et al. (2010). Postoperative Radiotherapy in Hypopharyngeal Cancer: Single-Institution Outcome Analysis. *International Journal of Head and Neck Surgery*, Vol.1, No.1, (January-April 2010), pp. 1-8, ISSN 0975-7899
- Gupta, T.; Chopra, S.; Agarwal, J.P.; Laskar, S.G.; D'Cruz, A.K.; et al. (2009a). Squamous Cell Carcinoma of the Hypopharynx: Single-Institution Outcome Analysis of a Large Cohort of Patients Treated With Primary Non-Surgical Approaches. *Acta Oncol*, Vol.48, No.4, (January 2009), pp. 541-548, ISSN 0284-186X
- Gustavsson, P.; Jakobsson, R.; Johansson, H.; Lewin, F.; Norell, S.; et al. (1998). Occupational Exposures and Squamous Cell Carcinoma of the Oral Cavity, Pharynx, Larynx, and Oesophagus: A Case-Control Study in Sweden. *Occupational and Environmental Medicine*, Vol.55, No.6, (June 1998), pp. 393-400, ISSN 1351-0711
- Hall, S.F.; Groome, P.A.; Irish, J. & O'Sullivan, B. (2009). Towards Further Understanding of Prognostic Factors for Head and Neck Cancer Patients: The Example of Hypopharyngeal Cancer. *Laryngoscope*, Vol.119, No.4, (April 2009), pp. 696-702, ISSN 0023-852X
- Haraf, D.J.; Vokes, E.E.; Panje, W.R. & Weichselbaum R.R. (1991). Survival and Analysis of Failure Following Hydroxyurea, 5-Fluorouracil and Concomitant Radiation Therapy in Poor Prognosis Head and Neck Cancer. *Am J Clin Oncol*, Vol.14, No.5, (October 1991), pp. 419-422, ISSN 0277-3732
- Hasegawa, Y. & Matsuura, H. (1994). Retropharyngeal Node Dissection in Cancer of the Oropharynx and Hypopharynx. *Head Neck*, Vol.16, No.2, (March-April 1994), pp. 173-180, ISSN 1043-3074
- Hirano, S.; Tateya, I.; Kitamura, M.; Kada, S.; Ishikawa, S.; et al. (2010). Ten Years Single Institutional Experience of Treatment for Advanced Hypopharyngeal Cancer in Kyoto University. *Acta Oto-Laryngologica.Supplementum*, Vol.563, (November 2010), pp. 56-61, ISSN 0365-5237
- Hitt, R.; Lopez-Pousa, A.; Martinez-Trufero, J.; Escrig, V.; Carles, J.; et al. (2005). Phase III Study Comparing Cisplatin plus Fluorouracil to Paclitaxel, Cisplatin, and Fluorouracil Induction Chemotherapy Followed by Chemoradiotherapy in Locally Advanced Head and Neck Cancer. *J Clin Oncol*, Vol.23, No.34, (December 2005), pp. 8636-8645, ISSN 0732-183X

- Ho, C.M.; Lam, K.H.; Wei, W.I.; Yuen, P.W. & Lam L.K. (1993). Squamous Cell Carcinoma of the Hypopharynx-Analysis of Treatment Results. *Head Neck*, Vol.15, No.5, (September-October 1993), pp. 405-412, ISSN 1043-3074
- Hoffman, H.T.; Karnell, L.H.; Funk, G.F.; Robinson, R.A. & Menck, H.R. (1998). The National Cancer Data Base Report on Cancer of the Head and Neck. *Archives of Otolaryngology – Head & Neck Surgery*, Vol.124, No.9, (September 1998), pp. 951-962, ISSN 0886-4470
- Hoffman, H.T.; Karnell, L.H.; Shah, J.P.; Ariyan, S.; Brown, G.S.; et al. (1997). Hypopharyngeal Cancer Patient Care Evaluation. *Laryngoscope*, Vol.107, No.8, (August 1997), pp. 1005-1017, ISSN 0023-852X
- Hong, T.S.; Tome, W.A.; Chappell, R.J.; Chinnaiyan, P.; Mehta, M.P.; et al. (2005). The Impact of Daily Setup Variations on Head-And-Neck Intensity Modulated Radiation Therapy. *Int J Radiat Oncol Biol Phys*, Vol.61, No.3, (March 2005), pp. 779-788, ISSN 0360-3016
- Horwitz, E.M.; Harris, J.; Langer, C.J.; Nicolaou, N.; Kies, M.; et al. (2005). Concurrent Split Course Hyperfractionated Radiotherapy (Hfx RT), Cisplatin (DDP) and Paclitaxel (P) in Patients With Recurrent, Previously Irradiated Squamous Cell Carcinoma of the Head and Neck (SCCHN): Update of RTOG 9911. *J Clin Oncol*, 2005 ASCO Annual Meeting Proceedings, Vol.23, Suppl.16, Part I of II, (June 2005), 5577, ISSN 0732-183X
- Hsu, L.P. & Chen, P.R. (2005). Distant Metastases of Head and Neck Squamous Cell Carcinomas-Experience from Eastern Taiwan. *Tzu Chi Medical Journal*, Vol.17, No.2, pp. 99-104, ISSN 1016-3190
- Huguenin, P.; Beer, K.T.; Allal, A.; Rufibach, K.; Friedli, C.; et al. (2004). Concomitant Cisplatin Significantly Improves Locoregional Control in Advanced Head and Neck Cancers Treated With Hyperfractionated Radiotherapy. *J Clin Oncol*, Vol.22, No.23, (December 2004), pp. 4665-4673, ISSN 0732-183X
- International Commission on Radiation Units and Measurements (ICRU) Report 62. (1999). Prescribing, Recording, and Reporting Photon Beam Therapy (Supplement to ICRU Report 50), ICRU, pp. ix 52, ISBN 0-913394-61-0, Bethesda
- Jacobs, C.; Lyman, G.; Velez-Garcia, E.; Sridhar, K.S.; Knight, W.; et al. (1992). A Phase III Randomized Study Comparing Cisplatin and Fluorouracil as Single Agents and in Combination for Advanced Squamous Cell Carcinoma of the Head and Neck. *J Clin Oncol*, Vol.10, No.2, (February 1992), pp. 257-263, ISSN 0732-183X
- Jayant, K.; Balakrishnan, V.; Sanghvi, L.D. & Jussawalla, D.J. (1977). Quantification of the Role of Smoking and Chewing Tobacco in Oral, Pharyngeal and Oesophageal Cancers. *Br J Cancer*, Vol.35, No.2, (February 1977), pp. 232-235, ISSN 0007-0920
- Jeremic, B.; Shibamoto, Y.; Milicic, B.; Nikolic, N.; Dagovic, A.; Aleksandrovic, J.; et al. (2000). Hyperfractionated Radiation Therapy With or Without Concurrent Low-Dose Daily Cisplatin in Locally Advanced Squamous Cell Carcinoma of the Head and Neck: A Prospective Randomized Trial. *J Clin Oncol*, Vol.18, No.7, (April 2000), pp. 1458-1464, ISSN 0732-183X
- Jeremic, B.; Shibamoto, Y.; Stanisavljevic, B.; Milojevic, L.; Milicic, B. & Nikolic, N. (1997). Radiation Therapy Alone or With Concurrent Low-Dose Daily Either Cisplatin or

- Carboplatin in Locally Advanced Unresectable Squamous Cell Carcinoma of the Head and Neck: A Prospective Randomized Trial. *Radiother Oncol*, Vol.43, No.1, (April 1997), pp. 29-37, ISSN 0167-8140/1997
- Johansen, L.V.; Grau, C. & Overgaard, J. (2000). Hypopharyngeal Squamous Cell Carcinoma: Treatment Results in 138 Consecutively Admitted Patients. *Acta Oncol*, Vol.39, No.4, (January 2000), pp. 529-536, ISSN 0284-186X
- Jol, J.K. ; Quak, J.J.; de Bree, R. & Leemans, C.R. (2003). Larynx Preservation Surgery for Advanced Posterior Pharyngeal Wall Carcinoma With Free Flap Reconstruction: A Critical Appraisal. *Oral Oncology*, Vol.39, No.6, (September 2003), pp. 552-558, ISSN 1368-8375
- Jones, A.S. & Stell, P.M. (1991). Squamous Cell Carcinoma of the Posterior Pharyngeal Wall. *Clinical Otolaryngology and Allied Sciences*, Vol.16, No.5, (October 1991), pp. 462-465, ISSN 0307-7772
- Jones, A.S.; McRae, R.D.; Phillips, D.E.; Hamilton, J.; Field, J.K.; et al. (1995). The Treatment of Node Negative Squamous Cell Carcinoma of the Postcricoid Region. *Journal of Laryngology and Otology*, Vol.109, No.2, (February 1995), pp. 114-119, ISSN 0022-2151
- Jones, A.S.; Wilde, A.; McRae, R.D.; Phillips, D.E.; Field, J.K.; et al. (1994). The Treatment of Early Squamous Cell Carcinoma of the Piriform Fossa. *Clinical Otolaryngology and Allied Sciences*, Vol.19, No.6, (December 1994), pp. 485-490, ISSN 0307-7772
- Joo, Y.H.; Sun, D.I.; Cho, K.J.; Cho, J.H. & Kim, M.S. (2010). The Impact of Paratracheal Lymph Node Metastasis in Squamous Cell Carcinoma of the Hypopharynx. *European Archives of Oto-Rhino-Laryngology*, Vol.267, No.6, (January 2010), pp. 945-950 ISSN 0937-4477
- Kajanti, M. & Mantyla, M. (1990). Carcinoma of the Hypopharynx. *Acta Oncol*, Vol.29, No.7, (January 1990), pp. 903-907, ISSN 0284-186X
- Kamiyama, R.; Saikawa, M. & Kishimoto, S. (2009). Significance of Retropharyngeal Lymph Node Dissection in Hypopharyngeal Cancer. *Japanese Journal of Clinical Oncology*, Vol.39, No.10, (October 2009), pp. 632-637, ISSN 0368-2811
- Keane, T.J. (1982). Carcinoma of the Hypopharynx. *Journal of Otolaryngology*, Vol.11, No.4, (August 1982), pp. 227-231, ISSN 0381-6605
- Keane, T.J.; Hawkins, N.V.; Beale, F.A.; Cummings, B.J.; Harwood, A.R.; et al. (1983). Carcinoma of the Hypopharynx-Results of Primary Radical Radiation Therapy. *Int J Radiol Oncol Biol Phys*, Vol.9, No.5, (May 1983), pp. 659-664, ISSN 0360-3016
- Kim, K.H.; Sung, M.W.; Rhee, C.S.; Koo, J.W.; Koh, T.Y.; Lee, D.W.; et al. (1998). Neoadjuvant Chemotherapy and Radiotherapy for the Treatment of Advanced Hypopharyngeal Carcinoma. *American Journal of Otolaryngology*, Vol.19, No.1, (January-February 1998), pp. 40-44, ISSN 0196-0709
- Kim, S.; Wu, H.G.; Heo, D.S.; Kim, K.H.; Sung, M.W.; et al. (2001). Advanced Hypopharyngeal Carcinoma Treatment Results According to Treatment Modalities. *Head Neck*, Vol.23, No.9, (September 2001), pp. 713-717, ISSN 1043-3074
- Kim, W.T.; Ki, Y.K.; Nam, J.H.; Kim, D.W.; Lee, B.J.; et al. (2004). The Results of Postoperative Radiotherapy for Hypopharyngeal Carcinoma. *The Korean Society of*

- Therapeutic Radiology and Oncology*, Vol.22, No.4, (December 2004), pp254-264, ISSN 0368-2811
- Kirchner, J.A. (1975). Pyriform Sinus Cancer: A Clinical and Laboratory Study. *Annals of Otolaryngology, Rhinology and Laryngology*, Vol.84, No.6, (November-December 1975), pp. 793-803, ISSN 0003-4894
- Koch, W.M.; Lango, M.; Sewell, D.; Zahurak, M. & Sidransky, D. (1999). Head and Neck Cancer in Nonsmokers: A Distinct Clinical and Molecular Entity. *Laryngoscope*, Vol.109, No.10, (October 1999), pp. 1544-1551, ISSN 0023-852X
- Koch, W.M.; Lee, D.J.; Eisele, D.W.; Miller, D.; Poole, M.; Cummings, C.W.; et al. (1995). Chemoradiotherapy for Organ Preservation in Oral and Pharyngeal Carcinoma. *Archives of Otolaryngology - Head & Neck Surgery*, Vol.121, No.9, (September 1995), pp. 974-980, ISSN 0886-4470
- Koo, B.S.; Lim, Y.C.; Lee, J.S.; Kim, Y.H.; Kim, S.H.; et al. (2006). Management of Contralateral N0 Neck in Pyriform Sinus Carcinoma. *Laryngoscope*, Vol.116, No.7, (July 2006), pp. 1268-1272 ISSN 0023-852X
- Kraus, D.H.; Pfister, D.G.; Harrison, L.B.; Shah, J.P.; Spiro, R.H.; et al. (1994). Larynx Preservation With Combined Chemotherapy and Radiation Therapy in Advanced Hypopharynx Cancer. *Otolaryngol Head Neck Surg*, Vol.111, No.1, (July 1994), pp. 31-37, ISSN 0194-5998
- Kraus, D.H.; Zelefsky, M.J.; Brock, H.A.; Huo, J.; Harrison, L.B.; et al. (1997). Combined Surgery and Radiation Therapy for Squamous Cell Carcinoma of the Hypopharynx. *Otolaryngol Head Neck Surg*, Vol.116, No.6, Pt.1, (June 1997), pp. 637-641, ISSN 0194-5998
- Laccourreye, H.; Lacau St Guily, J.; Brasnu, D.; Fabre, A. & Menard, M. (1987). Supracricoid Hemilaryngopharyngectomy. Analysis of 240 Cases. *Annals of Otolaryngology, Rhinology and Laryngology*, Vol.96, No.2, Pt.1, (March-April 1987), pp. 217-221, ISSN 0003-4894
- Laccourreye, O.; Merite-Drancy, A.; Brasnu, D.; Chabardes, E.; Cauchois, R.; et al. (1993). Supracricoid Hemilaryngopharyngectomy in Selected Pyriform Sinus Carcinoma Staged as T2. *Laryngoscope*, Vol.103, No.12, (December 1993), pp. 1373-1379, ISSN 0023-852X
- Lajtmam, Z. & Manestar, D. (2001). A Comparison of Surgery and Radiotherapy in the Management of Advanced Pyriform Fossa Carcinoma. *Clin Otolaryngol*, Vol.26, No.1, (January 2001), pp. 59-61, ISSN 1749-4478
- Layland, M.K. & Sessions, D.G. (2005). The Influence of Lymph Node Metastasis in the Treatment of Squamous Cell Carcinoma of the Oral Cavity, Oropharynx, Larynx and Hypopharynx: N0 Versus N+. *Laryngoscope*, Vol.115, No.4, (April 2005), pp. 629-639, ISSN 0023-852X
- Lederman M. (1962). Carcinoma of Laryngopharynx. Results of Radiotherapy. *Journal of Laryngology and Otolaryngology*, Vol.76, No.5, (May 1962), pp. 317-334, ISSN 0022-2151
- Lee, M.S.; Ho, H.C.; Hsiao, S.H.; Hwang, J.H.; Lee, C.C.; et al. (2008). Treatment Results and Prognostic Factors in Locally Advanced Hypopharyngeal Cancer. *Acta Otolaryngol*, Vol.128, No.1, (January 2008), pp. 103-109, ISSN 0001-6489
- Lee, W.R.; Berkey, B.; Marcial, V.; Fu, K.K.; Cooper, J.S.; et al. (1998). Anemia is Associated With Decreased Survival and Increased Locoregional Failure in Patients With

- Locally Advanced Head and Neck Carcinoma: A Secondary Analysis of RTOG 85-27. *Int J Radiat Oncol Biol Phys*, Vol.42, No.5, (December 1998), pp.1069-1075, ISSN 0360-3016
- Lefebvre, J. & Chevalier, D. (2004). Cancer De l'Hypopharynx, *EMC - Oto-rhino-laryngologie*, Vol.1, No.4, (November 2004), pp. 274-289, ISSN 1762-5688
- Lefebvre, J.L.; Castelain, B.; La De Torre, J.C.; Delobelle-Deroide, A. & Vankemmel, B. (1987). Lymph Node Invasion in Hypopharynx and Lateral Epilarynx: A Prognostic Factor. *Head Neck Surg*, Vol.10, No.1, (September-October 1987), pp 14-18 ISSN 0148-6403
- Lefebvre, J.L.; Chevalier, D.; Luboinski, B.; Kirkpatrick, A.; Collette, L.; et al. (1996). Larynx Preservation in Pyriform Sinus Cancer: Preliminary Results of a European Organization for Research and Treatment of Cancer Phase III Trial. EORTC Head and Neck Cancer Cooperative Group. *The Journal of the National Cancer Institute*, Vol.88, No.13, (July 1996), pp. 890-899, ISSN 0027-8874
- Lefebvre, J.L.; Chevalier, D.; Luboinski, B.; Traissac, L.; Andry, G.; et al. (2004). Is Laryngeal Preservation (LP) With Induction Chemotherapy (ICT) Safe in the Treatment of Hypopharyngeal SCC? Final Results of the Phase III EORTC 24891 Trial. *J ClinOncol, 2004 ASCO Annual Meeting Proceedings (Post-Meeting Edition)*, Vol.22, Suppl.14, (July 2004), 5505, ISSN 0732-183X
- Levebvre, J.L. & Lartigau, E. (2003). Preservation of Form and Function during Management of Cancer of the Larynx and Hypopharynx. *World Journal of Surgery*, Vol.27, No.7, (July 2003), pp. 811-816, ISSN 0364-2313
- Levebvre, J.L. (2000). What is the Role of Primary Surgery in the Treatment of Laryngeal and Hypopharyngeal Cancer? Hayes Martin Lecture. *Archives of Otolaryngology – Head & Neck Surgery*, Vol.126, No.3, (March 2000), pp. 285-288, ISSN 0886-4470
- Llatas, M.C.; Molla, C.L.; Garcia, R.B.; Ramirez, M.J.F.; Domenech, F.G.; et al. (2009). Hypopharyngeal Cancer: Analysis of Evolution and Treatment Results. *Acta Otorrinolaringologica Espanola*, Vol.60, No.1, (January-February 2009), pp. 3-8, ISSN 0001-6519
- Lou, H.F.; Xiao, S.F.; Zhao, E.M.; Guo, M.; Wang, Q.G.; et al. (2008). Selective Neck Dissection on the Treatment of Neck Metastases in 63 Patients With Squamous Cell Carcinoma of Hypopharynx. *Zhonghua Er Bi Yan Hou Tou Jing Wai Ke Za Zhi*, Vol.43, pp. 202-207, ISSN 1673-0860
- Lundahl, R.E.; Foote, R.L.; Bonner, J.A.; Suman, V.J.; Lewis, J.E.; et al. (1998). Combined Neck Dissection and Postoperative Radiation Therapy in the Management of High-Risk Neck: A Matched-Pair Analysis. *Int J Radiat Oncol Biol Phys*, Vol.40, No.3, (February 1998), pp. 529-534, ISSN 0360-3016
- Makeieff, M.; Mercante, G.; Jouzdani, E.; Garrel, R.; Crampette, L.; et al. (2004). Supraglottic Hemipharyngolaryngectomy for the Treatment of T1 and T2 Carcinomas of Laryngeal Margin and Piriform Sinus. *Head Neck*, Vol.26, No.8, (August 2004), pp. 701-705, ISSN 1043-3074
- Marchand, J.L.; Luce, D.; Leclerc, A.; Goldberg, P.; Orlowski, E.; et al. (2000). Laryngeal and Hypopharyngeal Cancer and Occupational Exposure to Asbestos and Man-Made

- Vitreous Fibers: Results of a Case-Control Study. *American Journal of Industrial Medicine*, Vol.37, No.6, (June 2000), pp. 581-589, ISSN 0271-3586
- Marcus, R.B. Jr. & Million, R.R. (1990). The Incidence of Myelitis After Irradiation of the Cervical Spinal Cord. *Int J Radiat Oncol Biol Phys*, Vol.19, No.1, (July 1990), pp. 3-8, ISSN 0360-3016
- Marks, J.E.; Kurnik, B.; Powers, W.E. & Ogura, J.H. (1978). Carcinoma of the Pyriform Sinus. An Analysis of Treatment Results and Patterns of Failure. *Cancer*, Vol.41, No.3, (March 1978), pp. 1008-1015, ISSN 0008-543X
- McKaig, R.G.; Baric, R.S. & Olshan, A.F. (1998). Human Papillomavirus and Head and Neck Cancer: Epidemiology and Molecular Biology. *Head Neck*, Vol.20, No.3, (May 1998), pp. 250-65, ISSN 1043-3074
- Mendenhall, W.M.; Million, R.R. & Bova, F.I. (1984). Analysis of Time-Dose Factors in Clinically Positive Neck Nodes Treated With Irradiation Alone in Squamous Cell Carcinoma of the Head and Neck. *Int J Radiat Oncol Biol Phys*, Vol.10, No.5, (April 1984), pp. 639-643, ISSN 0360-3016
- Mendenhall, W.M.; Parsons, J.T.; Cassisi, N.J. & Million, R.R. (1987a). Squamous Cell Carcinoma of the Pyriform Sinus Treated With Radical Radiation Therapy. *Radiother Oncol*, Vol.9, No.3, (July 1987), pp. 201-208, ISSN 0167-8140
- Mendenhall, W.M.; Parsons, J.T.; Devine, J.W.; Cassisi, N.J. & Million, R.R. (1987b). Squamous Cell Carcinoma of the Pyriform Sinus Treated With Surgery and/or Radiotherapy. *Head Neck Surg*, Vol.10, No.2, (November-December 1987), pp. 88-92, ISSN 0148-6403
- Mendenhall, W.M.; Villaret, D.B.; Amdur, R.J.; Hinerman, R.W. & Mancuso, A.A. (2002). Planned Neck Dissection After Definitive Radiotherapy for Squamous Cell Carcinoma of the Head and Neck. *Head Neck*, Vol.24, No.11, (November 2002), pp. 1012-1018, ISSN 1043-3074
- Menvielle, G.; Luce, D.; Goldberg, P.; Bugel, I. & Leclerc, A. (2004). Smoking, Alcohol Drinking and Cancer Risk for Various Sites of the Larynx and Hypopharynx. A Case-Control Study in France. *European Journal of Cancer Prevention*, Vol.13, No.3, (June 2004), pp. 165-172, ISSN: 0959-8278
- Meoz-Mendez, R.T.; Fletcher, G.H.; Guillaumondegui, O.M. & Peters, L.J. (1978). Analysis of the Results of Irradiation in the Treatment of Squamous Cell Carcinomas of the Pharyngeal Walls. *Int J Radiat Oncol Biol Phys*, Vol.4, No.7, (July 1978), pp. 579-585, ISSN 0360-3016
- Million, R.R. & Cassisi, N.J. (1981). Radical Irradiation for Carcinoma of the Pyriform Sinus. *Laryngoscope*, Vol.91, No.3, (March 1981), pp. 439-450, ISSN 0023-852X
- Mineta, H.; Ogino, T.; Amano, H.M.; Ohkawa, Y.; Araki, K.; et al. (1998). Human Papilloma Virus (HPV) Type 1 and 18 Detected in Head and Neck Squamous Cell Carcinoma. *Anticancer Research*, Vol.18, No.6B, (November-December 1998), pp. 4765-4768, ISSN 0250-7005
- Mirimanoff, R.O.; Wang, C.C. & Doppke, K.P. (1985). Combined Surgery and Postoperative Radiation Therapy for Advanced Laryngeal and Hypopharyngeal Carcinomas. *Int J Radiat Oncol Biol Phys*, Vol.11, No.3, (March 1985), pp. 499-504, ISSN 0360-3016

- Mochiki, M.; Sugawasa, M.; Nibu, K.; Asai, M.; Nakao, K.; et al. (2007). Prognostic Factors for Hypopharyngeal Cancer: A Univariate and Multivariate Study of 142 Cases. *Acta Oto-Laryngologica. Supplementum*, Vol.559, (December 2007), pp. 136-144, ISSN 0365-5237
- Moore, K.L.; Agur, A.M.R & Dalley, A.F. (Eds). (2010). *Essential Clinical Anatomy*, Lippincott Williams & Wilkins, ISBN 978-0-7817-9915-7, Baltimore
- Muller, D.; Millon, R.; Velten, M.; Bronner, G.; Jung, G.; et al. (1997). Amplification of 11q13 DNA Markers in Head and Neck Squamous Cell Carcinomas: Correlation With Clinical Outcome. *Eur J Cancer*, Vol.33, No.13, (November 1997), pp. 2203-2210, ISSN 0014-2964
- Munro, A.J. (1995). An Overview of Randomized Controlled Trials of Adjuvant Chemotherapy in Head and Neck Cancer. *Br J Cancer*, Vol.71, No.1, (January 1995), pp. 83-91, ISSN 0007-0920
- Nakamura, K.; Shioyama, Y.; Kawashima, M.; Saito, Y.; Nakamura, N.; et al. (2006). Multi-Institutional Analysis of Early Squamous Cell Carcinoma of the Hypopharynx Treated With Radical Radiotherapy. *Int J Radiat Oncol Biol Phys*, Vol.65, No.4, (July 2006), pp. 1045-1050, ISSN 0360-3016
- National Comprehensive Cancer Network (NCCN) Clinical Practice Guidelines in Oncology: Head and Neck Cancers – V.2.2011, 30.04.2011, Available from http://www.nccn.org/professionals/physicians_gls/PDF/head-and-neck.pdf
- Niibe, Y.; Karasawa, K.; Mitsuhashi, T. & Tanaka, Y. (2003). Hyperfractionated Radiation Therapy for Hypopharyngeal Carcinoma Compared With Conventional Radiation Therapy: Local Control, Laryngeal Preservation and Overall Survival. *Japanese Journal of Clinical Oncology*, Vol.33, No.9, (September 2003), pp. 450-455, ISSN 0368-2811
- Nishimaki, T.; Kanda, T.; Nakagawa, S.; Kosuqi, S.; Tanabe, T.; et al. (2002). Outcomes and Prognostic Factors After Surgical Resection of Hypopharyngeal and Cervical Esophageal Carcinomas. *International Surgery*, Vol.87, No.1, (January-March 2002), pp. 38-44, ISSN: 0020-8868
- Paccagnella, A.; Orlando, A.; Marchiori, C.; Zorat, P.L.; Cavaniglia, O.; et al. (1994). Phase III Trial of Initial Chemotherapy in Stage III or IV Head and Neck Cancers: A Study by the Gruppo di Studio sui Tumori della Testa e del Collo. *The Journal of the National Cancer Institute*, Vol.86, No.4, (February 1994), pp. 265-272, ISSN 0027-8874
- Pameijer, F.A.; Mancuso, A.A.; Mendenhall, W.M.; Parsons, J.T.; Mukherji, S.K.; et al. (1998). Evaluation of Pretreatment Computed Tomography as a Predictor of Local Control in T1/T2 Pyriform Sinus Carcinoma Treated With Definitive Radiotherapy. *Head Neck*, Vol.20, No.2, (March 1998), pp. 159-168, ISSN 1043-3074
- Park, Y.M.; Kim, W.S.; Byeon, H.K.; De Virgilio, A.; Jung, J.S.; et al. (2010). Feasibility of Transoral Robotic Hypopharyngectomy for Early-Stage Hypopharyngeal Carcinoma. *Oral Oncology*, Vol.46, No.8, (August 2010), pp. 597-602, ISSN 1368-8375
- Parsons, J.T.; Cassisi, N.J. & Million, R.R. (1984). Results of Twice-a-Day Irradiation of Squamous Cell Carcinomas of the Head and Neck. *Int J Radiat Oncol Biol Phys*, Vol.10, No.11, (November 1984), pp. 2041-2051, ISSN 0360-3016

- Parsons, J.T.; Mendenhall, W.M.; Stringer, S.P.; Cassisi, N.J. & Million, R.R. (1993). Twice-a-Day Radiotherapy for Squamous Cell Carcinoma of the Head and Neck: The University of Florida Experience. *Head Neck*, Vol.15, No.2, (April 1993), pp. 87-96, ISSN 1043-3074
- Pene, F.; Avedian, V.; Eschwege, F.; Barrett, A.; Schwaab, G.; et al. (1978). A Retrospective Study of 131 Cases of Carcinoma of the Posterior Pharyngeal Wall. *Cancer*, Vol.42, No.5, (November 1978), pp. 2490-2493, ISSN 0008-543X
- Pfister, D.G.; Hu, K.S. & Levebvre, J.L. (2009). Cancer of the Hypopharynx and Cervical Esophagus. Part A: General Principles and Management. In: *Head and Neck Cancer: A Multidisciplinary Approach*, L.B. Harrison, R.B. Session & W.K. Hong, (Eds.), 398-436, Lippincott Williams & Wilkins, ISBN 978-0-7817-7136-8, Philadelphia
- Pignon, J.P.; Baujat, B. & Bourhis, J. (2005). Individual Patient Data Meta-Analyses in Head and Neck Carcinoma: What Have We Learnt? *Cancer Radiotherapie*, Vol.9, No.1, (February 2005), pp. 31-36, ISSN 1278-3218
- Pignon, J.P.; Bourhis, J.; Domenge, C. & Designe, L. (2000). Chemotherapy Added to Locoregional Treatment for Head and Neck Squamous-Cell Carcinoma: Three Meta-Analyses of Updated Individual Data. MACH-NC Collaborative Group. Meta-Analysis of Chemotherapy on Head and Neck Cancer. *Lancet*, Vol.355, No.9208, (March 2000), pp. 949-955, ISSN 0023-7507
- Pignon, J.P.; le Maitre, A.; Maillard, E. & Bourhis, J. (2009). Meta-Analysis of Chemotherapy in Head and Neck Cancer (MACH-NC): An Update on 93 Randomized Trials and 17,346 Patients. *Radiother Oncol*, Vol.92, No.1, (July 2009), pp. 4-14, ISSN 0167-8140
- Pillsbury, H.C. & Clark, M. (1997). A Rationale for Therapy of the N0 Neck. *Laryngoscope*, Vol.107, No.10, (October 1997), pp. 1294-1315, ISSN 0023-852X
- Pingree, T.F.; Davis, R.K.; Reichman, O. & Derrick, L. (1987). Treatment of Hypopharyngeal Carcinoma: A 10-Year Review of 1,362 Cases. *Laryngoscope*, Vol.97, No.8, Pt.1, (August 1987), pp. 901-904, ISSN 0023-852X
- Pinnaro, P.; Cercato, C.; Giannarelli, D.; Carlini, P.; Del Vecchio, M.R.; et al. (1994). A Randomized Phase II Study Comparing Sequential Versus Simultaneous Chemo-Radiotherapy in Patients With Unresectable Locally Advanced Squamous Cell Cancer of the Head and Neck. *Annals of Oncology*, Vol.5, No.6, (July 1994), pp. 513-519, ISSN 0923-7534
- Pivot, X.; Felip, E.; ESMO Guidelines Working Group. (2008). Squamous Cell Carcinoma of the Head and Neck: ESMO Clinical Recommendations for Diagnosis, Treatment and Follow-Up. *Annals of Oncology*, Vol.19, Suppl.2, (May 2008), ii79-ii80, ISSN 0923-7534
- Pivot, X.; Magne, N.; Guadiola, E.; Poissonnet, G.; Dassonville, O. ; et al. (2005). Prognostic Impact of the Epidermal Growth Factor Receptor Levels for Patients With Larynx and Hypopharynx Cancer. *Oral Oncology*, Vol.41, No.3, (March 2005), pp. 320-327, ISSN 1368-8375
- Plataniotis, G.A.; Theofanopoulou, M.E.; Kalogera-Fountzila, A.; Haritanti, A.; Ciuleanu, E.; et al. (2004). Prognostic Impact of Tumor Volumetry in Patients With Locally Advanced Head and Neck Carcinoma (Non-Nasopharyngeal) Treated by

- Radiotherapy Alone or Combined Radiochemotherapy in a Randomized Trial. *Int J Radiat Oncol Biol Phys*, Vol.59, No.4, (July 2004), pp. 1018-1026, ISSN 0360-3016
- Popescu, C.R.; Bertesteanu, S.V.G.; Mirea, D.; Grigore, R.; Ionescu, D.; et al. (2010). The Epidemiology of Hypopharynx and Cervical Esophagus Cancer. *Journal of Medicine and Life*, Vol.3, No.4, (November 2010), pp. 396-401, ISSN 1844-122x
- Posner, M.R. (2005). Paradigm Shift in the Treatment of Head and Neck Cancer: The Role of Neoadjuvant Chemotherapy. *Oncologist*, Vol.10, Suppl3, (October 2005), pp. 11-19, ISSN 1083-7159
- Posner, M.R.; Hershock, D.M.; Blajman, C.R.; Mickiewicz, E.; Winkquist, E.; et al. (2007). Cisplatin and Fluorouracil Alone or With Docetaxel in Head and Neck Cancer. *N Engl J Med*, Vol.357, No.17, (October 2007), pp. 1705-1715, ISSN 0028-4793
- Prades, J.M.; Lallemand, B.; Garrel, R.; Reyt, E.; Righini, C.; et al. (2010). Randomized Phase III Trial Comparing Induction Chemotherapy Followed by Radiotherapy to Concomitant Chemoradiotherapy for Laryngeal Preservation in T3M0 Pyriform Sinus Carcinoma. *Acta Otolaryngol*, Vol.130, No.1, (May 2010), pp. 150-155, ISSN 0001-6489
- Prades, J.M.; Schmitt, T.M.; Timoshenko, A.P.; Simon, P.G.; de Cornulier, J.; et al. (2002). Concomitant Chemoradiotherapy in Pyriform Sinus Carcinoma. *Archives of Otolaryngology – Head & Neck Surgery*, Vol.128, No.4, (April 2002), pp. 384-388, ISSN 0886-4470
- Prosnitz, R.G.; Yao, B.; Farell, C.L.; Clough, R. & Brizel, D.M. (2005). Pretreatment Anemia is Correlated With the Reduced Effectiveness of Radiation and Concurrent Chemotherapy in Advanced Head and Neck Cancer. *Int J Radiat Oncol Biol Phys*, Vol.61, No.4, (March 2005), pp. 1087-95, ISSN 0360-3016
- Rapoport, A. & Franco, E.L. (1993). Prognostic Factors and Relative Risk in Hypopharyngeal Cancer-Related Parameters Concerning Stage, Therapeutics and Evolution. *Revista Paulista de Medicina*, Vol.111, No.2, (March-April 1993), pp. 337-343, ISSN, 0035-0362
- Richards, B.L. & Spiro, J.D. (2000). Controlling Advanced Neck Disease: Efficacy of Neck Dissection and Radiotherapy. *Laryngoscope*, Vol.110, No.7, (July 2000), pp. 1124-1127, ISSN 0023-852X
- Robbins, K.T.; Shaha, A.R.; Medina, J.E.; Califano, J.A.; Wolf, G.T.; et al. (2008). Consensus Statement on the Classification and Terminology of Neck Dissection. *Archives of Otolaryngology – Head & Neck Surgery*, Vol.134, No.5, (May 2008), pp. 536-538, ISSN 0886-4470
- Robson, A. (2002). Evidence-Based Management of Hypopharyngeal Cancer. *Clinical Otolaryngology and Allied Sciences*, Vol.27, No.5, (October 2002), pp. 413-420, ISSN 0307-7772
- Rosenthal, D.I. & Ang, K.K. (2004). Altered Radiation Therapy Fractionation, Chemoradiation, and Patient Selection for the Treatment of Head and Neck Squamous Carcinoma. *Seminars in Radiation Oncology*, Vol.14, No.2, (April 2004), pp. 153-166, ISSN 1053-4296

- Rudert, H.H. & Hoft, S. (2003). Transoral Carbon-Dioxide Laser Resection of Hypopharyngeal Carcinoma. *European Archives of Oto-Rhino-Laryngology*, Vol.260, No.4, (April 2003), pp. 198-206, ISSN 0937-4477
- Ruo Redda, M.G.; Ragona, R.; Ricardi, U.; Beltramo, G.; Rampino, M.; et al. (2010). Radiotherapy Alone or With Concomitant Daily Low-Dose Carboplatin in Locally Advanced, Unresectable Head and Neck Cancer: Definitive Results of a Phase III Study With a Follow-Up Period of up to Ten Years. *Tumori*, Vol.96, No.2, (March-April 2010), pp. 246-253, ISSN 0300-8916
- Sakata, K.; Aoki, Y.; Karasawa, K.; Nakagawa, K.; Hasezawa, K.; et al. (1998). Analysis of Treatment Results of Hypopharyngeal Cancer. *Radiation Medicine*, Vol.16, No.1, (January-February 1998), pp. 31-36, ISSN 0288-2043
- Samant, S.; Kumar, P.; Wan, J.; Hanchett, C.; Vieira, F.; et al. (1999). Concomitant Radiation Therapy and Targeted Cisplatin Chemotherapy for the Treatment of Advanced Pyriform Sinus Carcinoma: Disease Control and Preservation of Organ Function. *Head Neck*, Vol.21, No.7, (October 1999), pp. 595-601, ISSN 1043-3074
- Sanchiz, F.; Milla, A.; Torner, J.; Bonet, F.; Artola, N.; et al. (1990). Single Fraction per Day Versus Two Fractions per Day Versus Radiochemotherapy in the Treatment of Head and Neck Cancer. *Int J Radiat Oncol Biol Phys*, Vol.19, No.6, (December 1990), pp. 1347-1350, ISSN 0360-3016
- Sanguineti, G.; Corvo, R.; Benasso, M.; Margarino, G.; Sormani, M.; et al. (1999). Management of the Neck After Alternating Chemoradiotherapy for Advanced Head and Neck. *Head Neck*, Vol.21, No.3, (May 1999), pp. 223-228, ISSN 1043-3074
- Sanguineti, G.; Richetti, A.; Bignardi, M.; Corvo, R.; Gabriele, P.; et al. (2005). Accelerated Versus Conventional Fractionated Postoperative Radiotherapy for Advanced Head and Neck Cancer: Results of a Multicenter Phase III Study. *Int J Radiat Oncol Biol Phys*, Vol.61, No.3, (March 2005), pp. 762-771, ISSN 0360-3016
- Schrijvers, D.; Johnson, J.; Jiminez, U.; Gore, M.; Kosmidis, P.; et al. (1998). Phase III Trial of Modulation of Cisplatin/Fluorouracil Chemotherapy by Interferon Alfa-2b in Patients With Recurrent or Metastatic Head and Neck Cancer. *J Clin Oncol*, Vol.16, No.3, (March 1998), pp. 1054-1059, ISSN 0732-183X
- Schwager, K.; Hoppe, F.; Hagen, R. & Brunner, F.X. (1999). Free-Flap Reconstruction for Laryngeal Preservation After Partial Laryngectomy in Patients With Extended Tumors of the Oropharynx and Hypopharynx. *European Archives of Oto-Rhino-Laryngology*, Vol.256, No.6, (July 1999), pp. 280-282, ISSN 0937-4477
- Seiwert, T.Y. & Cohen, E.E.W. (2005). State-of-the-Art Management of Locally Advanced Head and Neck Cancer. *Br J Cancer*, Vol.92, No.8, (April 2005), pp. 1341-1348, ISSN 0007-0920
- Semrau, R.; Mueller, R.P.; Stuetzer, H.; Staar, S.; Schroeder, U.; et al. (2006). Efficacy of Intensified Hyperfractionated and Accelerated Radiotherapy and Concurrent Chemotherapy With Carboplatin and 5-Fluorouracil: Updated Results of a Randomized Multicentric Trial in Advanced Head-and-Neck Cancer. *Int J Radiat Oncol Biol Phys*, Vol.64, No.5 (April 2006), pp. 1308-1316, ISSN 0360-3016
- Sewnaik, A.; Hoorweg, J.J.; Knecht, P.P.; Wieringa, M.H.; van der Beek, J.M.H.; et al. (2005). Treatment of Hypopharyngeal Carcinoma: Analysis of Nationwide Study in the

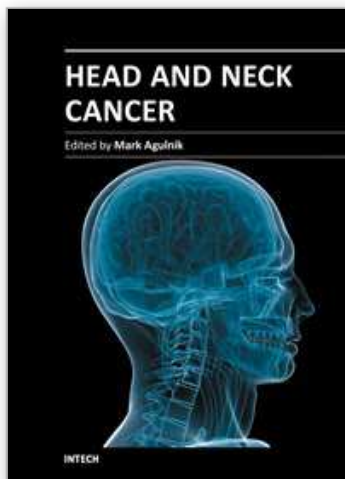
- Netherlands Over a 10-Year Period. *Clin Otolaryngol*, Vol.30, No.1, (February 2005), pp. 52-57, ISSN 1749-4478
- Shah, H.K.; Khuntia, D.; Hoffman, H.T. & Harari, P.M. (2008). Hypopharyngeal Cancer, In: *Perez and Brady's Principles and Practice of Radiation Oncology*, E.C. Halperin, C.A. Perez, L.W. Brady LW, (Eds.), 958-974, Lippincot Williams & Wilkins, a Wolters Kluwer business, ISBN 078176369X, Philadelphia
- Shangina, O.; Brennan, P.; Szeszenia-Dabrowska, N.; Mates, D.; Fabianova, E.; et al. (2006). Occupational Exposure and Laryngeal and Hypopharyngeal Cancer Risk in Central and Eastern Europe. *American Journal of Epidemiology*, Vol.164, No.4, (August 2006), pp. 367-375, ISSN 0002-9262
- Siddiqui, F.; Sarin, R.; Agarwal, J.P.; Thotathil, Z.; Mistry, R.; et al. (2003). Squamous Carcinoma of the Larynx and Hypopharynx in Children: A Distinct Clinical Entity? *Medical and Pediatric Oncology*, Vol.40, No.5, (May 2003), pp. 322-324, ISSN 0098-1532
- Slaughter, D.P.; Southwick, H.W. & Smejkal, W. (1953). Field Cancerization in Oral Stratified Squamous Epithelium; Clinical Implications of Multicentric Origin. *Cancer*, Vol.6, No.5, (September 1952), pp. 963-968, ISSN 0008-543X
- Smeele, L.E.; Leemans, C.R.; Langendijk, J.A.; Tiwari, R.; Slotman, B.J.; et al. (2000). Positive Surgical Margins in Neck Dissection Specimens in Patients With Head and Neck Squamous Cell Carcinoma and the Effect of Radiotherapy. *Head Neck*, Vol.22, No.6, (September 2000), pp. 559-563, ISSN 1043-3074
- Somers, K.D.; Merrick, M.A.; Lopez, M.E.; Incognito, L.S.; Schechter, G.L.; et al. (1992). Frequent P53 Mutations in Head and Neck Cancer. *Cancer Research*, Vol.52, No.21, (November 1992), pp. 5997-6000, ISSN 0008-5472
- Sorensen, D.M.; Lewark, T.M.; Haney, J.L.; Meyers, A.D.; Krause, G.; et al. (1997). Absence of P53 Mutations in Squamous Carcinomas of the Tongue in Nonsmoking and Nondrinking Patients Younger than 40 Years. *Archives of Otolaryngology - Head & Neck Surgery*, Vol.123, No.5, (May 1997), pp. 503-506, ISSN 0886-4470
- Spector, G.J. (2001). Distant Metastases from Laryngeal and Hypopharyngeal Cancer. *Journal for Oto-Rhino-Laryngology and Its Related Specialties*, Vol.63, No.4, (July-August 2001), pp. 224-228, ISSN 0301-1569
- Spector, G.J.; Sessions, D.G.; Emami, B.; Simpson, J.; Haughey, B.; et al. (1995). Squamous Cell Carcinoma of the Pyriform Sinus: A Nonrandomized Comparison of Therapeutic Modalities and Long Term Results. *Laryngoscope*, Vol.105, No.4, (April 1995), pp. 397-406, ISSN 0023-852X
- Spector, G.J.; Sessions, D.G.; Haughey, B.H.; Chao, K.S.C.; Simpson, J.; et al. (2001). Delayed Regional Metastases, Distant Metastases, and Second Primary Malignancies in Squamous Cell Carcinomas of the Larynx and Hypopharynx. *Laryngoscope*, Vol.111, No.6, (June 2001), pp. 1079-1087, ISSN 0023-852X
- Spencer, S.A.; Harris, J.; Wheeler, R.H.; Machtay, M.; Schultz, C.; et al. (2001). RTOG 96-10: Reirradiation With Concurrent Hydroxyurea and 5-Fluorouracil in Patients With Squamous Cell Cancer of the Head and Neck. *Int J Radiat Oncol Biol Phys*, Vol.51, No.5, (December 2001), pp. 1299-1304, ISSN 0360-3016

- Staar, S.; Rudat, V.; Stuetzer, H.; Dietz, A.; Volling, P.; et al. (2001). Intensified Hyperfractionated Accelerated Radiotherapy Limits the Additional Benefit of Simultaneous Chemotherapy-Results of a Multicentric Randomized German Trial in Advanced Head-and-Neck Cancer. *Int J Radiat Oncol Biol Phys*, Vol.50, No.5, (August 2001), pp. 1161-1171, ISSN 0360-30162001
- Standring, S. (Ed). (2004). *Gray's Anatomy: The Anatomical Basis of Clinical Practice*, Churchill Livingstone, ISBN 0-443-07168-3, Philadelphia
- Steiner, W.; Ambrosch, P.; Hess, C.F. & Kron, M. (2001). Organ Preservation by Transoral Laser Microsurgery in Piriform Sinus Carcinoma. *Otolaryngology-Head and Neck Surgery*, Vol.124, No.1, (January 2001), pp. 58-67, ISSN 0194-5998
- Stell, P.M.; Carden, E.A.; Hibbert, J. & Dalby, J.E. (1978). Post Cricoid Carcinoma. *Clin Oncol*, Vol.4, No.3, (September 1978), pp. 215-226, ISSN 0305-7399
- Stell, P.M.; Ramadan, M.F.; Dalby, J.E.; Hibbert, J.; Raab, G.M.; et al. (1982). Management of Postcricoid Carcinoma. *Clinical Otolaryngology and Allied Sciences*, Vol.7, No.3, (June 1982), pp. 145-152, ISSN 0307-7772
- Studer, G.; Lutolf, U.M.; Davis, J.B. & Glanzmann, C. (2006). IMRT in Hypopharyngeal Tumors. *Strahlenther Onkol*, Vol.182, No.6, (June 2006), pp. 331-335, ISSN 0179-7158
- Studer, G.; Peponi, E.; Kloeck, S.; Dossenbach, T.; Huber, G.; et al. (2010). Surviving Hypopharynx-Larynx Carcinoma in the Era of IMRT. *Int J Radiat Oncol Biol Phys*, Vol.77, No.5, (August 2010), pp. 1391-1396, ISSN 0360-3016
- Tai, S.K.; Yang, M.H.; Wang, L.W.; Tsai, T.L.; Chu, P.Y.; et al. (2008). Chemoradiotherapy Laryngeal Preservation for Advanced Hypopharyngeal Cancer. *Japanese Journal of Clinical Oncology*, Vol.38, No.8, (August 2008), pp. 521-527, ISSN 0368-2811
- Taki, S.; Homma, A.; Oridate, N.; Suzuki, S.; Suzuki, F.; et al. (2010). Salvage Surgery for Local Recurrence After Chemoradiotherapy or Radiotherapy in Hypopharyngeal Cancer Patients. *European Archives of Oto-Rhino-Laryngology*, Vol.267, No.11, (November 2010), pp. 1765-1769, ISSN 0937-4477
- Talton, B.M.; Elkon, D.; Kim, J.A.; Fitz-Hugh, G.S. & Constable, W. (1981). Cancer of the Posterior Hypopharyngeal Wall. *Int J Radiat Oncol Biol Phys*, Vol. 7, No.5, (May 1981), pp. 597-599, ISSN 0360-3016
- Tandon, D.A.; Bahadur, S.; Chatterji, T.K. & Rath, G.K. (1991). Carcinoma of the Hypopharynx: Results of Combined Therapy. *Indian Journal of Cancer*, Vol.28, No.3, (September 1991), pp. 131-138, ISSN 0019-509X
- Tani, M. & Amatsu, M. (1987). Discrepancies Between Clinical and Histopathologic Diagnoses in T3 Piriform Sinus Cancer. *Laryngoscope*, Vol.97, No.1, (January 1987), pp. 93-96, ISSN 0023-852X
- Taylor, J.M.; Mendenhall, W.M. & Lavey, R.S. (1991). Time-Dose Factors in Positive Neck Nodes Treated With Irradiation Only. *Radiother Oncol*, Vol.22, No.3, (November 1991), pp. 167-173, ISSN 0167-8140
- Taylor, S.G. 4th; McGuire, W.P.; Hauck, W.W.; Showel, J.L. & Lad T.E. (1984). A Randomized Comparison of High-Dose Infusion Methotrexate Versus Standard-Dose Weekly Therapy in Head and Neck Squamous Cancer. *J Clin Oncol*, Vol.2, No.9, (September 1984), pp. 1006-1010, ISSN 0732-183X

- Taylor, S.G. 4th; Murthy, A.K.; Vannetzel, J.M.; Colin, P.; Dray, M.; et al. (1994). Randomized Comparison of Neoadjuvant Cisplatin and Fluorouracil Infusion Followed by Radiation Versus Concomitant Treatment in Advanced Head and Neck Cancer. *J Clin Oncol*, Vol.12, No.2, (February 1994), pp. 385-395, ISSN 0732-183X
- Teshima, T.; Chatani, M.; Inoue, T.; Miyahara, H. & Sato, T. (1988). Radiation Therapy for the Carcinoma of the Hypopharynx With Special Reference to Nodal Control. *Laryngoscope*, Vol.98, No.5, (May 1988), pp. 564-567, ISSN 0023-852X
- Timon, C.V.; Toner, M. & Conlon, B.J. (2003). Paratracheal Lymph Node Involvement in Advanced Cancer of the Larynx, Hypopharynx and Cervical Oesophagus. *Laryngoscope*, Vol.113, No.9, (September 2003), pp. 1595-1599, ISSN 0023-852X
- Toita, T.; Nakano, M.; Ogawa, K.; Koja, S.; Maeshiro, N.; et al. (1996). Prognostic Factors for Local Control in Hypopharyngeal Cancer Treated With Radical Irradiation. *Strahlenther Onkol*, Vol.172, No.1, (January 1996), pp. 30-33, ISSN 0179-7158
- Tribius, S.; Kronemann, S.; Kilic, Y.; Schroeder, U.; Hakim, S.; et al. (2009). Radiochemotherapy Including Cisplatin Alone Versus Cisplatin + 5-Fluorouracil for Locally Advanced Unresectable Stage IV Squamous Cell Carcinoma of the Head and Neck. *Strahlenther Onkol*, Vol.185, No.10, (October 2009), pp. 675-681, ISSN 0179-7158
- Tsikoudas, A.; Ghuman, N. & Riad, M.A. (2007). Globus Sensation as Early Presentation of Hypopharyngeal Cancer. *Clin Otolaryngol*, Vol.32, No.6, (December 2007), pp. 452-456, ISSN 1749-4478
- Tsou, Y.A.; Hua, J.H.; Lin, M.H. & Tsai, M.H. (2006). Analysis of Prognostic Factors of Chemoradiation Therapy for Advanced Hypopharyngeal Cancer-Does Tumor Volume Correlate With Central Necrosis and Tumor Pathology? *Journal for Oto-Rhino-Laryngology and Its Related Specialties*, Vol.68, No.4, (February 2006), pp. 206-212, ISSN: 0301-1569
- Tuyns, A.J.; Esteve, J.; Raymond, L.; Berrino, F.; Benhamou, E.; et al. (1988). Cancer of the Larynx/Hypopharynx, Tobacco and Alcohol: IARC International Case-Control Study in Turin and Varese (Italy), Zaragoza and Navarra (Spain), Geneva (Switzerland) and Calvados (France). *International Journal of Cancer*, Vol.41, No.4, (April 1988), pp. 483-491, ISSN 0020-7136
- Uzcudun, A.E.; Bravo Fernández, P.; Sánchez, J.J.; Garcia Grane, A.; Rabanal Retolaza, I.; et al. (2001). Clinical Features of Pharyngeal Cancer: A Retrospective Study of 258 Consecutive Patients. *Journal of Laryngology and Otology*, Vol.115, No.2, (February 2001), pp. 112-118 ISSN 0022-2151
- Van der Riet, P.; Nawroz, H.; Hruban, R.H.; Corio, R.; Tokino, K.; et al. (1994). Frequent Loss of Chromosome 9p21-22 Early in Head and Neck Cancer Progression. *Cancer Research*, Vol.54, No.5, (March 1994), pp. 1156-1158, ISSN 0008-5472
- Van Herpen, C.M.; Mauer, M.E.; Mesia, R.; Degardin, M.; Lelic, S.; et al. (2010). Short-Term Health-Related Quality of Life and Symptom Control With Docetaxel, Cisplatin, 5-Fluorouracil and Cisplatin (TPF), 5-Fluorouracil (PF) for Induction in Unresectable Locoregionally Advanced Head and Neck Cancer Patients (EORTC 24971/TAX 323). *Br J Cancer*, Vol.103, No.8, (October 2010), pp. 1173-1181, ISSN 0007-0920

- Van Mierlo, I.J.; Levendag, P.C.; Eijkenboom, W.M.; Jansen, P.P.; Meeuwis, C.A.; et al. (1995). Radiation Therapy for Cancer of the Piriform Sinus. A Failure Analysis. *Am J Clin Oncol*, Vol.18, No.6, (December 1995), pp. 502-509, ISSN 0277-3732
- Van Oijen, M.G.C.T. & Slootweg P.J. (2000). Oral Field Cancerization: Carcinogen-Induced Independent Events or Micrometastatic Deposits? *Cancer Epidemiology, Biomarkers & Prevention*, Vol. 9, No.3, (March 2000), pp. 249-256, ISSN 1055-9965
- Vandenbrouck, C.; Eschwege, F.; De La Rochefordiere, A.; Sicot, H.; Mamelle, G.; et al. (1987). Squamous Cell Carcinoma of the Piriform Sinus: A Retrospective Study of 351 Cases Treated at the Institut Gustave-Roussy. *Head Neck Surg*, Vol.10, No.1, (September-October 1987), pp. 4-13, ISSN 0148-6403
- Vermorken, J.B.; Mesia, R.; Rivera, F.; Remenar, E.; Kawecki, A.; et al. (2008). Platinum-Based Chemotherapy Plus Cetuximab in Head and Neck Cancer. *N Engl J Med*, Vol.359, No.11, (September 2008), pp. 1116-1127, ISSN 0028-4793
- Vermorken, J.B.; Remenar, E.; van Herpen, C.; Gorlia, T.; Mesia, R.; et al. (2007). Cisplatin, Fluorouracil, and Docetaxel in Unresectable Head and Neck Cancer. *N Engl J Med*, Vol.357, No.17, (October 2007), pp. 1695-1704, ISSN 0028-4793
- Vilaseca, I.; Blanch, J.L.; Bernal-Sprekelsen, M. & Moragas, M. (2004). CO2 Laser Surgery: A Larynx Preservation Alternative for Selected Hypopharyngeal Carcinomas. *Head Neck*, Vol.26, No.11, (November 2004), pp. 953-959, ISSN 1043-3074
- Vogl, S.E.; Schoenfeld, D.A.; Kaplan, B.H.; Lerner, H.J.; Engstrom, P.F.; et al. (1985). A Randomized Prospective Comparison of Methotrexate With a Combination of Methotrexate, Bleomycin, and Cisplatin in Head and Neck Cancer. *Cancer*, Vol.56, No.3, (August 1985), pp. 432-442, ISSN 0008-543X
- Vokes, E.E. & Choong, N. (2008). Chemotherapy of Head and Neck Cancer. In: *The Chemotherapy Source Book*, M.C. Perry, (Ed.), 324-340, Lippincott Williams & Wilkins, ISBN 978-0-7817-7328-7, Philadelphia.
- Vokes, E.E. & Weichselbaum, R.R. (1990). Concomitant Chemoradiotherapy: Rationale and Clinical Experience in Patients With Solid Tumors. *J Clin Oncol*, Vol.8, No.5, (May 1990), pp. 911-934, ISSN 0732-183X
- Wang, C.C.; Blitzner, P.H. & Suit, H.D. (1985). Twice-a-Day Radiation Therapy for Cancer of the Head and Neck. *Cancer*, Vol.55, Suppl.9, (May 1985), pp. 2100-2104, ISSN 0008-543X
- Weber, R.S.; Marvel, J.; Smith, P.; Hankins, P.; Wolf, P. & Goepfert, H. (1993). Paratracheal Lymph Node Dissection for Carcinoma of the Larynx, Hypopharynx, and Cervical Esophagus. *Otolaryngol Head Neck Surg*, Vol.108, No.1, (January 1993), pp. 11-17, ISSN 0194-5998
- Wendt, T.G.; Grabenbauer, G.G.; Rodel, C.M.; Thiel, H.J.; Aydin, H.; et al. (1998). Simultaneous Radiochemotherapy Versus Radiotherapy Alone in Advanced Head and Neck Cancer: A Randomized Multicenter Study. *J Clin Oncol*, Vol.16, No.4, (April 1998), pp. 1318-1324, ISSN 0732-183X
- Williams, M.E.; Gaffey, M.J.; Weiss, L.M.; Wilczynski, S.P.; Schuuring, E.; et al. (1993). Chromosome 11Q13 Amplification in Head and Neck Squamous Cell Carcinoma. *Archives of Otolaryngology – Head & Neck Surgery*, Vol.119, No.11, (November 1993), pp. 1238-1243 ISSN: 0886-4470

- Williams, S.D.; Velez-Garcia, E.; Essessee, I.; Ratkin, G.; Birch, R.; et al. (1986). Chemotherapy for Head and Neck Cancer. Comparison of Cisplatin + Vinblastine + Bleomycin Versus Methotrexate. *Cancer*, Vol.57, No.1, (January 1986), pp. 18-23, ISSN 0008-543X
- Wygoda, A.; Skladowski, K.; Tarnawski, R.; Sasiadek, W.; Mucha, A.; et al. (2000). Prognostic Factors in Radiotherapy for Hypopharyngeal Cancer. *Otolaryngologia Polska*, Vol. 54, Suppl.31, (January 2000), pp. 33-36, ISSN 0030-6657
- Yates, A. & Crumley, R.L. (1984). Surgical Treatment of Pyriform Sinus Cancer: A Retrospective Study. *Laryngoscope*, Vol.94, No.12, Pt.1, (December 1984), pp. 1586-1590, ISSN 0023-852X
- Zackrisson, B.; Nilsson, P.; Kjellen, E.; Johansson, K.A.; Modig, H.; et al. (2011). Two-Year Results from a Swedish Study on Conventional Versus Accelerated Radiotherapy in Head and Neck Squamous Cell Carcinoma - The ARTSCAN Study. *Radiother Oncol*, (2011), doi:10.1016/j.radonc.2010.12.010
- Zelevsky, M.J.; Kraus, D.H.; Pfister, D.G.; Raben, A.; Shah, J.P.; et al. (1996). Combined Chemotherapy and Radiotherapy Versus Surgery and Postoperative Radiotherapy for Advanced Hypopharyngeal Cancer. *Head Neck*, Vol.18, No.5, (September-October 1996), pp. 405-411, ISSN 1043-3074
- Zorat, P.L.; Paccagnella, A.; Cavaniglia, G.; Loreggian, L.; Gava, A.; et al. (2004). Randomized Phase III Trial of Neoadjuvant Chemotherapy in Head and Neck Cancer: 10-Year Follow-Up. *The Journal of the National Cancer Institute*, Vol.96, No.22, (November 2004), pp. 1714-1717, ISSN 0027-8874



Head and Neck Cancer

Edited by Dr. Mark Agulnik

ISBN 978-953-51-0236-6

Hard cover, 440 pages

Publisher InTech

Published online 14, March, 2012

Published in print edition March, 2012

Head and Neck Cancer provides an interesting and comprehensive overview of all aspects of head and neck cancer including overviews of the disease, basic science aspects pertaining to the disease, diagnosis, treatment and outcomes for patients with this disease. The chapters written by world renowned experts cover the entire discipline of head and neck oncology and include discussions of regional disparity is, advances in basic science understanding, advances in her radiotherapy, chemotherapy and targeted agents as well as a focus on reconstruction, prostheses, and aspects of quality of life and health outcomes. The book is designed to be both practical and comprehensive for every physician treating his complex disease.

How to reference

In order to correctly reference this scholarly work, feel free to copy and paste the following:

Valentina Krstevska (2012). Hypopharyngeal Cancer, Head and Neck Cancer, Dr. Mark Agulnik (Ed.), ISBN: 978-953-51-0236-6, InTech, Available from: <http://www.intechopen.com/books/head-and-neck-cancer/hypopharyngeal-cancer>

INTECH
open science | open minds

InTech Europe

University Campus STeP Ri
Slavka Krautzeka 83/A
51000 Rijeka, Croatia
Phone: +385 (51) 770 447
Fax: +385 (51) 686 166
www.intechopen.com

InTech China

Unit 405, Office Block, Hotel Equatorial Shanghai
No.65, Yan An Road (West), Shanghai, 200040, China
中国上海市延安西路65号上海国际贵都大饭店办公楼405单元
Phone: +86-21-62489820
Fax: +86-21-62489821

© 2012 The Author(s). Licensee IntechOpen. This is an open access article distributed under the terms of the [Creative Commons Attribution 3.0 License](#), which permits unrestricted use, distribution, and reproduction in any medium, provided the original work is properly cited.

IntechOpen

IntechOpen