

We are IntechOpen, the world's leading publisher of Open Access books Built by scientists, for scientists

6,900

Open access books available

186,000

International authors and editors

200M

Downloads

Our authors are among the

154

Countries delivered to

TOP 1%

most cited scientists

12.2%

Contributors from top 500 universities



WEB OF SCIENCE™

Selection of our books indexed in the Book Citation Index
in Web of Science™ Core Collection (BKCI)

Interested in publishing with us?
Contact book.department@intechopen.com

Numbers displayed above are based on latest data collected.
For more information visit www.intechopen.com



The Post Thrombotic Syndrome

Paolo Prandoni¹ and Susan R Kahn²

¹*Department of Cardiothoracic and Vascular Sciences,
Thromboembolism Unit, University of Padua, Padua*

²*Centre for Clinical Epidemiology and Community Studies,
Sir Mortimer B. Davis Jewish General Hospital, Montreal, Quebec*

¹*Italy*

²*Canada*

1. Introduction

Despite appropriate anticoagulant therapy, at least 1 of every 2-3 patients with deep-vein thrombosis (DVT) of the lower extremities will develop post-thrombotic sequelae. These vary from minor signs (i.e., stasis pigmentation, venous ectasia, slight pain and swelling) to severe manifestations such as chronic pain, intractable edema and leg ulcers (1). The established post-thrombotic syndrome (PTS) remains a significant cause of chronic illness, with considerable socio-economic consequences for both the patient and the health care services (2,3).

The precise incidence of the PTS following confirmed venous thrombosis is still controversial, as the rate of post-thrombotic sequelae reported in published studies has varied between 20% and 100%. In earlier studies, a surprisingly high rate of severe PTS complications was reported (50 to 100% of the patients within 4 to 10 years after the qualifying thrombotic episode) (4-6). This rate sharply decreased in studies performed in the last 25 years (7-39), which could be due to improved diagnostic and therapeutic approaches to patients with DVT. However, owing to large differences among studies in terms of study design, definition of PTS, sample size, length of follow-up, and use of compression elastic stockings, the reported incidence of both overall and severe PTS still shows considerable variability. In the absence of elastic stockings, PTS is expected to develop in approximately 50% of patients suffering an episode of DVT, and is severe in one fifth of patients (1). Of interest, PTS can develop, although to a lower extent, also after an asymptomatic episode of postoperative DVT (40,41).

According to the results of the most recent studies, most patients who develop post-thrombotic manifestations become symptomatic within two years from the acute episode of DVT (1,18-20,29-32,35-37,39). These findings challenge the general view that the PTS requires many years to become manifest.

2. Clinical diagnosis and objective diagnostic testing

2.1 Clinical diagnosis and scoring systems

The post-thrombotic syndrome is characterized by aching pain on standing, dependent edema, and the frequent development of brawny, tender induration of the subcutaneous

tissues of the medial lower limb, a condition that has been termed "lipodermatosclerosis". Pruritus and eczematous skin changes are frequently present, and a proportion of patients develops secondary superficial varicose veins as the syndrome evolves. Ulceration, often precipitated by minor trauma, arises in a considerable number of patients and is characteristically chronic and indolent with a high recurrence rate, once healing has been achieved. Uncommonly, patients with persistent obstruction may experience venous claudication, a bursting pain in the leg during exercise, which, in some respects, mimics arterial claudication (42).

The clinical picture of the PTS is non-specific, as clinical conditions other than DVT may result in a similar set of symptoms and signs in the lower extremity, including superficial venous insufficiency, increased body mass index, and trauma (43-45).

The diagnosis of the PTS is made based on the development of the above mentioned clinical manifestations in patients with a history of DVT, irrespective of the presence of venous abnormalities as shown by invasive or non-invasive diagnostic procedures. In the absence of characteristic signs and symptoms, the demonstration of venous abnormalities (such as venous reflux, persistent venous obstruction, or both) does not, in itself, allow a patient with a history of DVT to be defined as having PTS.

Subjective Symptoms	Objective Signs
Heaviness	Pretibial edema
Pain	Induration of the skin
Cramps	Hyperpigmentation
Pruritus	New venous ectasia
	Redness
Paresthesia	Pain during calf compression
	Ulceration of the skin

*Each sign or symptom is graded with a score between 0 and 3. The presence of ulcer is only noted. PTS is classified as mild if the score is 5-9, moderate if the score is 10-14, and severe if the score is ≥ 15 or a venous ulcer is present.

Table 1. Villalta scale for the assessment of the PTS

Although the clinical picture of the PTS is classical, there is large variation among published studies as to its clinical classification. Among the suggested scoring systems, the Villalta scale and the CEAP classification are the most widely adopted (46). The former, based on clinical findings alone (Table 1), has high interobserver agreement (47,48), and good ability to discriminate patients with versus those without PTS and patients with mild versus those with severe PTS (1,47,49). In addition, this scale correlates well with the patient's perception of the interference of leg complaints with daily life (31,47,49). The Villalta scale has recently been recommended as a standard to define PTS for use in clinical investigations by the Scientific and Standardization Committee of the International Society on Thrombosis and Haemostasis (50). The latter, known as CEAP (Clinical, Etiologic, Anatomic, Pathophysiologic) classification, was developed as a result of the cooperative work of a panel of experts in the field of vascular disease, and combines clinical and objective findings into a sophisticated scoring system (Table 2) (51).

Clinical signs	Class 0	No visible or palpable signs of venous disease
	Class 1	Telangiectasia or reticular veins
	Class 2	Varicose veins
	Class 3	Edema
	Class 4	Skin changes ascribed to venous disease
	Class 5	Skin changes as described above with healed ulceration
	Class 6	Leg ulceration, skin changes as defined above
Etiologic classificatio	Congenital, primary, secondary	
Anatomic distribution	Superficial, deep, or perforator, alone or in combination	
Pathophysiologic dysfunction	Reflux or obstruction, alone or in combination	

Table 2. CEAP (clinical, etiologic, anatomic, pathophysiologic) classification of the PTS

2.2 Objective diagnostic testing

If a patient with a history of a previous (documented or highly suspected) DVT develops symptoms and signs compatible with PTS there is no need for further investigation. As the clinical picture may be non-specific (43-45), the need for objective confirmation arises in patients with leg complaints but without a likely or objectively proven previous DVT. Ascending phlebography is potentially useful to detect a previous DVT. Suggestive findings include narrowing or occlusion of the deep veins, contrast dye opacification of fewer veins (than normal) or perfusion of superficial or deep collateral veins. Recanalized veins show irregular margins, bizarre-appearing or multi-channeled lumen with webs, and usually have reduced caliber due to fibrotic thickening of their walls. Such veins may subsequently become dilated, probably because of loss of their elastic tissue (52). Despite the predictive value of these venographic patterns in patients with possible PTS, the invasive nature and cost of plebography makes such an approach inapplicable to most patients with a history of clinically suspected DVT.

We have shown that the combination of standardized clinical evaluation with compression ultrasonography and continuous-wave Doppler analysis can reliably diagnose or exclude a prior proximal-vein thrombosis in almost 90% of patients with a suggestive history (53). Compression ultrasonography should be performed first, checking the popliteal and the common femoral vein for compressibility. If either or both veins are incompressible, then a definite diagnosis of previous (proximal) DVT is made. Patients with normal ultrasound test results are interviewed and examined according to a standardized form (Table 1), and subsequently undergo continuous-wave Doppler analysis to test valve function, both in the common femoral and in the popliteal vein. The finding of both a popliteal reflux and/or of a clinical score > 8 is highly specific for the adjudication of a prior DVT in patients with a normal ultrasound test result. If ultrasound testing is normal, deep venous reflux is absent, and the clinical score is < 8, then previous proximal DVT is virtually excluded (53). The widespread availability of Duplex scanning renders our approach even more rapid and precise, as it permits venous flow sampling during direct visualization of the vessels.

Besides the demonstration of previous episodes of DVT, either invasive or non-invasive methods can be employed to document and quantify the presence of obstruction, reflux, or both, that are considered the major determinants of the PTS.

3. Pathophysiology of PTS development

It is generally believed that the PTS develops as a result of the combination of venous hypertension, due to persistent outflow obstruction and/or valvular incompetence, with abnormal microvasculature or lymphatic function. Long-standing venous hypertension in the deep-vein system ultimately leads to the onset of valve incompetence at the level of a constant series of perforating veins located in the medial ankle area. This allows the direct transmission of the high deep-venous pressures (especially during walking) to the venous end of subcutaneous capillaries, resulting in increased endothelial permeability. The escape of large molecules into the interstitial tissue may, in turn, explain the typical pattern of edema, hyperpigmentation and even ulcer formation (42,44,45). A few authors speculate that increased venous pressure with standing or walking causes a reduction in capillary flow rate, resulting in trapping of white blood cells in the leg and the subsequent release of free radical and proteolytic enzymes ultimately responsible for the venous ulceration (54,55).

The presence of reflux in the proximal veins is reputed to be crucial for the development of the PTS, and so is the persistence of venous obstruction, alone or in combination with venous reflux (15,35,56-61). However, this is an area of considerable uncertainty. Recently, we assessed the role of residual vein thrombosis and popliteal valve incompetence for the development of the PTS, as measured with the Villalta scale, in 180 consecutive patients who were followed for at least three years after an episode of acute proximal DVT (62). In the first six months following the thrombotic episode, venous abnormalities were detected in 104 patients (60%). The PTS developed in 18 of the 76 patients (24%) without vein abnormalities, and in 49 of the 104 (47%) with at least one abnormality: in 25 of the 52 (48%) with residual vein thrombosis alone, in 9 of the 24 (37.5%) with popliteal valve incompetence alone, and in 15 of the 28 (54%) with both abnormalities. The relative risk of the PTS was 1.0 (95% CI, 0.5 to 2.2) in patients with popliteal valve incompetence alone; 1.4 (0.9 to 2.3) in patients with transpopliteal reflux alone or combined with persistent venous obstruction; 1.6 (1.0 to 2.4) in patients with residual vein thrombosis alone; and 1.7 (1.2 to 2.3) in patients with persistent venous obstruction alone or combined with popliteal valve incompetence.

Roumen-Klappe and coworkers assessed the role of residual thrombosis, reflux and venous outflow resistance in 93 patients with proximal and distal DVT, followed for 6 years; the incidence of the PTS was 49% after 1 year, 55% after 2 years, without further increase up to 6 years. While the presence of reflux had only moderate predictive value, a strong increase in the predictive value was achieved by combining measures of residual thrombus, assessed by a thrombosis score, and venous outflow resistance, at three months (32). On the basis of these findings, a lack of recanalization within the first six months after the thrombotic episode appears to be an important predictor of PTS, while the development of transpopliteal venous reflux is not. However, incompetence of the popliteal valve increases the risk of the PTS when combined with residual vein thrombosis (32,62).

In a recent report, increased levels of inflammatory cytokines or adhesion molecules such as IL-6 and ICAM-1 were linked with the subsequent development of PTS (63). This suggests

that inflammation at the time of, or consequent to the episode of acute DVT may play a role in the pathophysiology of PTS, a hypothesis that is being further explored in a large prospective study (64).

4. Predictors of PTS development

Among parameters that have been found to be associated with an increased risk of the PTS are proximal DVT (33,38,39,60), previous ipsilateral DVT (14,16,18,28,29,33,39), older age (29,65), obesity (38,39,65-67), and varicose veins (38). In one investigation the male gender was a predictor of the PTS (33), while in others the opposite was seen (38,39). Finally, whether the carriage of factor V Leiden or the prothrombin mutation are predictors of a lower risk or reduced severity of the PTS is controversial, as there are data in favor (31) and against (38,39) this association.

In order to determine the frequency, time course, and predictors of the PTS after acute DVT, we followed 387 patients for up to two years after an episode of acute symptomatic DVT (39). With the use of the Villalta score, greater postthrombotic severity category at the 1-month visit strongly predicted higher mean postthrombotic scores throughout 24 months of follow-up (1.97, 5.03, and 7.00 increase in Villalta score for mild, moderate, and severe 1-month severity categories, respectively, vs. none). Additional predictors of higher scores over time were venous thrombosis of the common femoral or iliac vein (2.23 increase in score vs. distal venous thrombosis), higher body mass index (0.14 increase in score per kg/m²), previous ipsilateral venous thrombosis (1.78 increase in score), older age (0.30 increase in score per 10-year age increase), and female sex (0.79 increase in score). Accordingly, appropriate strategies aimed at reducing the risk of recurrent DVT, and reducing the body weight in obese patients have the potential to help prevent late post-thrombotic sequelae.

Proximal DVT is associated with a higher frequency and more severe PTS than distal DVT. In the abovementioned study, patients with more extensive proximal (femoral or iliac vein) DVT had significantly worse PTS scores at all visits (adjusted average increase of > 2 points on the Villalta scale) than those with distal or popliteal vein DVT (39). Similarly, in another recent prospective study, proximal DVT was found to be associated with a 2-fold increased risk of PTS compared with distal DVT (33). As the rates of PTS in the control arms of trials of compression stockings to prevent PTS in patients with proximal DVT ranged from 40-50%, the rate of PTS after distal DVT is likely to be in the range of 20-25%, however in one study, symptoms of PTS after distal DVT were relatively mild (23).

Finally, an insufficient quality of oral anticoagulant therapy following the acute thrombotic episode has been found to be associated with an increased risk of the PTS (28,65). Accordingly, appropriate attention to the monitoring of oral anticoagulant therapy following the initial thrombotic episode, in terms of both adequate intensity and duration, has the potential to help prevent late post-thrombotic sequelae.

5. Treatment of the PTS

Once established, PTS, especially when complicated by leg ulceration, is a significant cause of disability with a considerable economic burden for both patients and the health care

system (1,2). The management of this condition is demanding and oftentimes frustrating. Several treatment strategies, both conservative and surgical, have been tested, especially aimed at ulcer healing.

5.1 Conservative treatment

Compression therapy, either obtained with short stretch bandages, adhesive bandages, multiple layer bandages (with orthopedic wool plus compressive layers), stockings or zinc bandages, and frequent leg elevation are the cornerstones of the conservative management of venous ulcer (67). Irrespective of the choice, effective compression therapy is obtained with implements exerting a 35 to 40 mm Hg pressure at the ankle (68). Greater benefits (higher and faster healing rates, and low recurrence rates) are to be expected if compliance with compression therapy is monitored through ambulatory care programs, and if patients are encouraged to take regular exercise and to elevate the extremities while resting (69-71). According to the results of a survey conducted among Canadian physicians and patients, most patients with DVT reported being willing to comply with elastic stockings therapy and found them useful (72), although their use neither improves leg symptoms and signs during exercise nor increases exercise capacity (73).

In a randomized clinical trial conducted in a small number of patients with severe PTS, the adoption of cycles of intermittent pneumatic compression was found to reduce both intractable edema and leg swelling (74). In another randomized trial, a novel lower-limb venous-return assist device (VENOPTS) was found to considerably improve the clinical manifestations of severe PTS both alone and in combination with compression stockings (75). Finally, in a recent randomized clinical trial patients with PTS were found to benefit from an exercise training (a six-month trainer-supervised program that included aerobic, leg stretching and strengthening components) to a greater extent than those who had conventional treatment alone both in terms of severity of complaints and improvement in quality of life (76).

In addition to compressive therapy, a number of active compounds have been evaluated in a series of small randomized trials for the healing of venous ulcers. Among these oxpentifylline (77), aspirin (78), intravenous prostaglandin E1 (79), sulphhydryl-containing agents (DL-cysteine or DL-methionine) (80), radical scavengers (allopurinol or dimethyl sulfoxide) (81), and sulodexide (82) significantly improved the ulcer-healing rate.

With regards to other manifestations of the PTS, two small randomized trials demonstrated some beneficial effect of an anabolic steroid (stanozolol) plus elastic stockings on lipodermatosclerosis (83), and that of O-(β -hydroxyethyl)-rutosides on edema and several milder PTS symptoms (84), respectively.

In a recent clinical trial, we evaluated the efficacy of elastic compression stockings, hydroxyethylrutosides or both for the treatment of PTS (85). In 120 consecutive patients with PTS who were randomized to receive below-knee elastic stockings (30-40 mm Hg at the ankle), oral administration of hydroxyethylrutosides (1000 mg b.i.d.) or both for one year, an improvement of PTS manifestations was observed in similar proportions of patients in each study group. According to these results, elastic stockings and hydroxyethylrutosides seem equally effective in patients with the PTS. The combination of the two remedies does not seem to improve the results obtained by each strategy alone.

5.2 Surgical treatment

Surgery is often advocated when severe clinical manifestations (e.g. ulcer) cannot be managed by conservative treatment: various strategies are available, among whom subfascial perforator ligation and valvuloplasty appear to be the most promising (86). A more recent trial on subfascial endoscopic perforator surgery plus correction of superficial venous reflux indicates that, although effective in improving symptoms and ulcer healing in patients with primary venous insufficiency, this procedure is not as effective in patients with PTS (87). Similarly, deep (femoral-popliteal) valve reconstruction surgery performed after unsuccessful endoscopic perforator surgery, and correction of superficial venous reflux, yields significantly better results in patients with primary venous insufficiency than in patients with PTS (88).

6. Prevention of the PTS

6.1 Initial treatment of DVT with thrombolytic drugs

Thrombolysis has been traditionally advocated as an alternative strategy to heparins for the initial treatment of DVT, based on the assumption that early vein recanalization will result in a more favorable long-term outcome. This assumption is in agreement with the findings from several recent studies, which have identified that proximal location of the initial thrombosis is among the strongest predictors of PTS development (33,38,60), especially when the thrombus involves the ilio-femoral segments (39). Consistent with this assumption is the demonstration that post-thrombotic complications develop predominantly in those patients in whom the initial complaints tend to persist (39). Both the intravenous infusion of thrombolytic drugs and the use of catheter-directed thrombolysis are likely to result in a higher frequency of early vein patency as compared to heparin (89-92). However, whether these therapeutic approaches improve the long-term patients' outcome as well is controversial, as there is data in favour (93-96) and against (97,98) this possibility. In addition, the use of either intravenous or catheter-directed thrombolysis is associated with a higher risk of complications compared with treatment with anticoagulants alone (90,100). Thus, the routine use of early thrombolytic therapy for the prevention of long-term sequelae of DVT does not seem to be currently justified, but is the subject of ongoing multicenter randomized trials (100).

6.2 Compression bandaging in the acute phase of DVT

In order to assess the influence of immediate multilayer compression bandages before application of elastic stockings in the acute phase of DVT on development of the PTS, 69 patients with acute symptomatic DVT were recently randomized to immediate bandaging or no bandaging (36). While bandaging resulted in a considerable improvement of clinical symptoms and decrease of leg circumference in the first week of treatment, no difference in the development of late sequelae was observed between the two groups after one year. Thus, the early application of bandages in patients with DVT is unlikely to improve the long-term patients' outcome.

6.3 Elastic compression stockings

Elastic compression stockings have long been utilized for the prevention of the PTS in patients with acute DVT (72). However, their efficacy had not been systematically investigated until a few years ago.

In 1997, the results of a prospective randomized Dutch study on the prevention of the PTS became available (19). In this trial, 194 consecutive patients with confirmed proximal DVT were allocated to wear or to not wear elastic compression stockings. A predefined scoring system was used to classify patients into three categories: no, mild-to-moderate, and severe PTS. After a median follow-up of 76 months, mild-to-moderate PTS occurred in 19 (20%) and severe PTS in 11 (11.5%) of the 96 patients with stockings, while these occurred in 46 (47%) and 23 (23.5%) of the 98 patients without stockings, respectively ($p < 0.001$).

These results were recently confirmed by a prospective, controlled, randomized study performed in Italy (29), in which 180 consecutive patients with a first episode of symptomatic proximal DVT who were planned to receive conventional anticoagulant treatment were randomized to wear or to not wear below-knee compression (30-40 mm Hg at the ankle) elastic stockings for two years. Follow-up was performed for up to 5 years. Post-thrombotic sequelae, as assessed with the Villalta scale, developed in 44 of the 90 control patients (severe in 10), and in 23 of the 90 patients who were randomized to wear elastic stockings (severe in 3). After adjustment for baseline characteristics, the hazard ratio for the PTS in the stockings group as compared to the control group was 0.5 (0.3 to 0.8). A large, multicenter randomized trial is currently underway in North America to compare active versus placebo stockings to prevent PTS after proximal DVT (64).

Although the results of an investigation conducted in Canada (101) were not consistent with those of the above described studies (19,29,37), a recent meta-analytic review emphasized the role of graduated compression stockings for preventing long-term post-thrombotic sequelae (102). Accordingly, the latest edition of the American College of Chest Physicians has recently recommended elastic stockings beside conventional anticoagulation in all patients with acute symptomatic DVT, if feasible (99). While the effectiveness of compression stockings to prevent PTS after distal DVT has not been studied, it would be reasonable to offer compression stockings to patients with severe symptoms related to distal DVT.

Knee-length and thigh-length compression elastic stockings have similar physiologic effects in decreasing venous stasis of the lower limb, but the former are easier to apply and are more comfortable (103). A recent systematic review of knee versus thigh length graduated compression stockings for the prevention of DVT concluded that knee length were as effective as thigh length stockings and offer advantages in terms of patient compliance and cost (104). In order to directly compare the effectiveness and tolerability of below-knee versus thigh length stockings at the time of acute DVT to prevent PTS a randomized clinical trial has been conducted at our institution, whose results will be available soon (105).

The optimal duration of the treatment with elastic stockings has received little attention. In a recent trial, 169 patients with a first or recurrent proximal DVT who had received 6 months of standard compression treatment were randomized to wear or to not wear graduated elastic stockings for an additional 18 months (37). Overall, after 6 years of follow-up, prolongation of compression therapy failed to confer an additional advantage - according to the CEAP classification - over and above the initial 6-month period. However, when the analysis was confined to women, there was a statistically significant advantage to prolonging treatment with compression stockings. In a prospective cohort management study, the discontinuation of elastic stockings in patients free from PTS complaints who had been offered at least six months of compression therapy did not increase the rate of PTS development over patients in whom stockings had been used for at least two years

irrespective of the presence of post-thrombotic manifestations (106). Further studies are needed to show whether compression therapy is or is not indicated in asymptomatic patients who have completed an initial 6-month period.

To our knowledge, there are no studies that have compared different compression strengths of stockings to prevent PTS. It would be worth studying the effectiveness of lighter compression (20-30 mm Hg) stockings as they are easier to apply, especially for elderly patients, than 30-40 mm Hg stockings. Of note, in a study of stockings to prevent recurrent venous ulcer, there was no difference in effectiveness between class 2 and class 3 stockings (107).

Interestingly enough, immediate mobilization in patients with acute DVT may reduce the rate of PTS development, provided that patients are provided with adequate compression therapy (108).

6.4 The potential of new anticoagulant drugs

An insufficient quality of oral anticoagulant therapy following the acute thrombotic episode has been found to be associated with an increased risk of the PTS (28,65). Conversely, the long-term use of LMWH has been found to reduce the PTS rate in comparison with vitamin K antagonists (35,109). We cannot exclude, therefore, the potential of a few emerging antithrombotic compounds (such as dabigatran etexilate and rivaroxaban), which can be administered orally in fixed daily dosage and have been found to be at least as effective and safe as conventional anticoagulation for the initial and long-term treatment of DVT (110,111), for further reducing the incidence and the severity of the PTS.

7. Prognosis

It is commonly believed that patients with established PTS have a poor prognosis, and that the majority will have sustained disability. In recent years, a few reports have suggested that prognosis of the PTS might not be as poor as previously reported (69-71). Indeed, when provided with elastic compression stockings and regularly supervised, more than 50% of patients either remain stable or improve during long-term follow-up, irrespective of the initial degree of PTS (69-71). Clinical presentation helps predict the prognosis, as the outcome of patients who have initially severe manifestations appears to be more favorable than that of patients whose symptoms progressively deteriorate over time (71). However, at present there is no way to reliably predict the course of PTS in individual patients.

8. Conclusion

PTS is a frequent, burdensome and costly complication of DVT. Currently, there are few effective treatments for PTS. Until such treatments are identified, prevention of PTS will have the greatest impact on reducing the overall burden of PTS on patients and society. Preventing DVT recurrence is likely to reduce the risk of PTS. Daily use of graduated ECS after DVT appears to reduce the risk of PTS. As of yet, there is no established role for thrombolysis in preventing PTS, but trials are underway to address this important question. Research is also underway to identify biologic markers that may predict the risk of PTS in individual patients. Finally, a few emerging antithrombotic compounds may have the potential to reduce the risk of PTS, however this requires further study.

9. Acknowledgements

Dr Kahn is a recipient of a Senior Clinical Research Scientist Award from the Fonds de la Recherche en Santé du Québec and received research funding from the Canadian Institutes of Health Research and the Heart and Stroke Foundation of Canada.

10. References

- [1] Kahn SR, Ginsberg JS. Relationship between deep venous thrombosis and the postthrombotic syndrome. *Arch Intern Med* 2004; 164: 17-26.
- [2] Bergqvist D, Jendteg S, Johansen L, Persson U, Ödegaard K. Cost of long term complications of deep venous thrombosis of the lower extremities: an analysis of a defined patient population in Sweden *Ann Intern Med* 1997; 126: 454-457.
- [3] Kahn SR, M'LAN CE, Lamping DL, Kurz X, Bérard A, Abenhaim L. The influence of venous thromboembolism on quality of life and severity of chronic venous disease. *J Thromb Haemost* 2004; 2: 2146-2151.
- [4] Bauer G. Roentgenological and clinical study of the sequelae of thrombosis *Acta Chir Scand* 1942; 86 (suppl 74): 1-110.
- [5] Gjores JE. The incidence of venous thrombosis and its sequelae in certain districts of Sweden. *Acta Chir Scand* 1956; 206 (suppl 1): 1-88.
- [6] O'Donnell TF, Browse NL, Burnand KG, Lea Thomas M. The socioeconomic effects of an ilio-femoral venous thrombosis. *J Surg Res* 1977; 22: 483-488.
- [7] Strandness DE, Langlois Y, Cramer M, Randlett A, Thiele BL. Long-term sequelae of acute venous thrombosis. *JAMA* 1983; 250: 1289-1292.
- [8] Widmer LK, Zemp E, Widmer T, Schmitt HE, Brandenburg E, Voelin R, Biland L, da Silva A, Magos M. Late results in deep vein thrombosis of the lower extremity. *Vasa* 1985; 14: 264-268.
- [9] Lindner DJ, Edwards JM, Phinney ES, Taylor LM, Porter JM. Long-term hemodynamic and clinical sequelae of lower extremity deep vein thrombosis. *J Vasc Surg* 1986; 4: 436-442.
- [10] Høldal M, Seem E, Snadset PM, Abildgaard U. Deep vein thrombosis: a 7-year follow-up study. *J Intern Med* 1993; 234: 71-75.
- [11] Lagerstedt C, Olsson CG, Fagher B, Norgren L, Tengborn L. Recurrence and late sequelae after first-time deep vein thrombosis Relationship to initial signs. *Phlebology* 1993; 8: 62-67.
- [12] Monreal M, Martorell A, Callejas JM, Valls R, Llamazares J, Lafoz E, Arias A. Venographic assessment of deep vein thrombosis and risk of developing post-thrombotic syndrome: a prospective study. *J Intern Med* 1993; 233: 854-859.
- [13] Eichlisberger R, Frauchiger B, Widmer MT, Widmer LK, Jager K. Late sequelae of deep venous thrombosis: a 13-year follow-up of 223 patients. *Vasa* 1994; 23: 234-243.
- [14] Beyth RJ, Cohen AM, Landefeld CS. Long-term outcomes of deep-vein thrombosis. *Arch Intern Med* 1995; 155: 1031-1037.
- [15] Johnson BF, Manzo RA, Bergelin RO, Strandness DE. Relationship between changes in the deep venous system and the development of the postthrombotic syndrome after an acute episode of lower limb deep vein thrombosis: a one- to six-year follow-up. *J Vasc Surg* 1995; 21: 307-313.
- [16] Saarinen J, Sisto T, Laurikka J, Salenius JP, Tarkka M. Late sequelae of acute deep venous thrombosis: evaluation five and ten years after. *Phlebology* 1995; 10: 106-109.

- [17] Franzeck UK, Schalch I, Jäger KA, Schneider E, Grimm J, Bollinger A. Prospective 12-year follow-up study of clinical and haemodynamic sequelae after deep vein thrombosis in low-risk patients (Zürich study). *Circulation* 1996; 93: 74-79.
- [18] Prandoni P, Lensing AWA, Cogo A, Cuppini S, Villalta S, Carta M, Cattelan AM, Polistena P, Bernardi E, Prins MH. The long-term clinical course of acute deep venous thrombosis. *Ann Intern Med* 1996; 125: 1-7.
- [19] Brandijes DPM, Büller HR, Heijboer H, Huisman MV, de Rijk M, Jagt H. Randomised trial of effect of compression stockings in patients with symptomatic proximal-vein thrombosis. *Lancet* 1997; 349: 759-762.
- [20] Prandoni P, Villalta S, Bagatella P, Rossi L, Marchiori A, Piccioli A, Bernardi E, Girolami B, Simioni P, Girolami A. The clinical course of deep-vein thrombosis Prospective long-term follow-up of 528 symptomatic patients. *Haematologica* 1997; 2: 423-428.
- [21] Biguzzi E, Mozzi E, Alatri A, Taioli E, Moia M, Mannucci PM. The post-thrombotic syndrome in young women: retrospective evaluation of prognostic factors. *Thromb Haemost* 1998; 80: 575-577.
- [22] Masuda EM, Kessler DM, Kistner RL, Eklof B, Sato DT. The natural history of calf vein thrombosis: lysis of thrombi and development of reflux. *J Vasc Surg* 1998; 8: 67-74.
- [23] McLafferty RB, Moneta GL, Passmann MA, Brant BM, Taylor LM, Porter JM. Late clinical and hemodynamic sequelae of isolated calf vein thrombosis. *J Vasc Surg* 1998; 27: 50-57.
- [24] Haenen JH, Janssen MCH, van Langen H, van Asten WNJC, Wollersheim H, van't Hof MA, Skotnicki SH, Thien T. The postthrombotic syndrome in relation to venous hemodynamics as measured by means of duplex scanning and strain-gauge plethysmography. *J Vasc Surg* 1999; 29: 1071-1076.
- [25] Holmström M, Åberg W, Lockner C, Paul C. Long term clinical follow-up in 256 patients with deep-vein thrombosis initially treated with either unfractionated heparin or dalteparin: a retrospective analysis. *Thromb Haemost* 1999; 82: 1222-1226.
- [26] Saarinen J, Kallio T, Lehto M, Hiltunen S, Sisto T. The occurrence of the post-thrombotic changes after an acute deep venous thrombosis. A prospective two-year follow-up study *J Cardiovasc Surg* 2000; 41: 441-446.
- [27] Mohr DN, Silverstein MD, Heit JA, Petterson TM, O'Fallon M, Melton LJ. The venous stasis syndrome after deep venous thrombosis or pulmonary embolism: a population-based study. *Mayo Clin Proc* 2000; 75: 1249-1256.
- [28] Ziegler S, Schillinger M, Maca TH, Minar E. Post-thrombotic syndrome after primary event of deep venous thrombosis 10 to 20 years ago. *Thromb Res* 2001; 101: 23-33.
- [29] Prandoni P, Lensing AWA, Prins MH, Frulla M, Marchiori A, Bernardi E, Tormene D, Mosen L, Pagnan A, Girolami A. Below-knee elastic compression stockings to prevent the post-thrombotic syndrome A randomized controlled trial. *Ann Intern Med* 2004; 141: 249-256.
- [30] Gabriel F, Labios M, Portoles O, Guillen M, Corella D, Frances F, Martinez M, Gil J, Saiz C. Incidence of post-thrombotic syndrome and its association with various risk factors in a cohort of Spanish patients after one year of follow-up following acute deep venous thrombosis. *Thromb Haemost* 2004; 92: 328-336.
- [31] Kahn SR, Kearon C, Julian JA, Mackinnon B, Kovacs MJ, Wells P, Crowther MA, Anderson DR, Van Nguyen P, Demers C, Solymoss S, Kassis J, Geerts W, Rodger M, Hambleton J, Ginsberg JS. Predictors of the post-thrombotic syndrome during long-

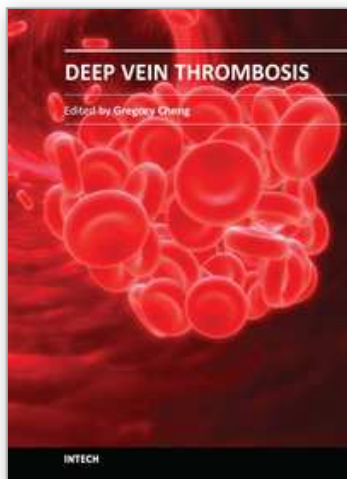
- term treatment of proximal deep vein thrombosis. *J Thromb Haemost* 2005; 3: 718-723.
- [32] Roumen-Klappe EM, den Heijer M, Janssen MCH, van der Vleuten C, Thien T, Wollersheim H. The post-thrombotic syndrome: incidence and prognostic value of non-invasive venous examinations in a six-year follow-up study. *Thromb Haemost* 2005; 94: 825-830.
- [33] Stain M, Schönauer V, Minar E, Bialonczyk C, Hirschl M, Weltermann A, Kyrle PA, Eichinger S. The post-thrombotic syndrome: risk factors and impact on the course of thrombotic disease. *J Thromb Haemost* 2005; 3: 2671-2676.
- [34] Schulman S, Lindmarker P, Holmstrom M, Larfars G, Carlsson A, Nicol P, Svensson E, Ljungberg B, Viering S, Nordlander S, Leijd B, Jahed K, Hjorth M, Linder O, Beckman M. Post-thrombotic syndrome recurrence and death 10 years after the first episode of venous thromboembolism treated with warfarin for 6 weeks or 6 months. *J Thromb Haemost* 2005; 4: 734-742.
- [35] González-Fajardo JA, Martín-Pedrosa M, Castrodeza J, Tamames S, Vaquero-Puerta C. Effect of the anticoagulant therapy in the incidence of post-thrombotic syndrome and recurrent thromboembolism: Comparative study of enoxaparin versus coumarin. *J Vasc Surg* 2008; 48: 953-959.
- [36] Roumen-Klappe EM, den Heijer M, van Rossum J, Wollersheim H, van der Vleuten C, Thien T, Janssen MC. Multilayer compression bandaging in the acute phase of deep-vein thrombosis has no effect on the development of the post-thrombotic syndrome. *J Thromb Thrombolysis* 2009; 27: 400-405.
- [37] Aschwanden M, Jeanneret C, Koller MT, Thalhammer C, Bucher HC, Jaeger KA. Effect of prolonged treatment with compression stockings to prevent post-thrombotic sequelae: a randomized controlled trial. *J Vasc Surg* 2008; 47: 1015-1021.
- [38] Tick LW, Kramer MH, Rosendaal FR, Faber WR, Doggen CJJ. Risk factors for post-thrombotic syndrome in patients with a first deep venous thrombosis. *J Thromb Haemost* 2008; 6: 2075-2081.
- [39] Kahn SR, Shrier I, Julian JA, Ducruet T, Arsenault L, Miron MJ, Roussin A, Desmarais S, Joyal F, Kassis J, Solymoss S, Desjardins L, Lamping DL, Johri M, Ginsberg JS. Determinants and time course of the postthrombotic syndrome after acute deep venous thrombosis. *Ann Intern Med* 2008; 149: 698-707.
- [40] Wille-Jorgensen P, Jorgensen LN, Crawford M. Asymptomatic postoperative deep vein thrombosis and the development of postthrombotic syndrome A systematic review and meta-analysis. *Thromb Haemost* 2005; 93: 236-241.
- [41] Lonner JH, Frank J, McGuire K, Lotke PA. Postthrombotic syndrome after asymptomatic deep vein thrombosis following total knee and hip arthroplasty. *Am J Orthop* 2006; 35: 469-472.
- [42] Immelman EJ, Jeffrey PC. The postphlebitic syndrome Pathophysiology prevention and management. *Clin Chest Med* 1984; 5: 537-550.
- [43] Browse NL, Clemenson G, Lea Thomas M. Is the postphlebitic leg always postphlebitic? Relation between phlebographic appearances of deep-vein thrombosis and late sequelae. *Br Med* 1980; 281: 1167-1170.
- [44] Raju S. Venous insufficiency of the lower limbs and stasis ulceration. *Ann Surg* 1983; 197: 688-697.
- [45] Scott TE, LaMorte WW, Gorin DR, Menzoian JO. Risk factors for chronic venous insufficiency: a dual case-control study. *J Vasc Surg* 1995; 22: 622-628.

- [46] Kolbach DN, Neumann HA, Prins MH. Definition of the post-thrombotic syndrome differences between existing classifications. *Eur J Vasc Endovasc Surg* 2005; 30: 404-414.
- [47] Villalta S, Bagatella P, Piccioli A, Lensing AWA, Prins MH, Prandoni P. Assessment of validity and reproducibility of a clinical scale for the post-thrombotic syndrome. *Haemostasis* 1994; 24 (Suppl 1): 57a.
- [48] Rodger MA, Kahn SR, Le Gal G, Solymoss S, Chagnon I,
- [49] Anderson DR, Wells PS, Kovacs MJ. Inter-observer reliability of measures to assess the post-thrombotic syndrome. *Thromb Haemost* 2008; 100: 164-166.
- [50] Kahn SR, Hirsch A, Shrier I. Effect of post-thrombotic syndrome on health-related quality of life after deep venous thrombosis. *Arch Intern Med* 2002; 162: 1144-1148.
- [51] Kahn SR, Partsch H, Vedantham S, Prandoni P, Kearon C. Definition of post-thrombotic syndrome of the leg for use in clinical investigations: A recommendation for standardization. *J Thromb Haemost* 2009; 7: 879-883.
- [52] Porter JM, Moneta GL. Reporting standards in venous disease: an update International Consensus Committee on Chronic Venous Disease. *J Vasc Surg* 1995; 21: 635-645.
- [53] Bettmann MA, Paulin, S. Leg phlebography: the incidence, nature, and modification of undesirable side effects *Radiology* 1977; 122: 101-104.
- [54] Villalta S, Prandoni P, Cogo A, Bagatella P, Piccioli A, Bernardi E, Simioni P, Scarano L, Girolami A. The utility of non-invasive tests for detection of previous proximal-vein thrombosis. *Thromb Haemost* 1995; 73: 592-596.
- [55] Coleridge Smith PD, Thomas P, Scurr JH, Dormandy JA. Causes of venous ulceration: a new hypothesis. *Br Med J* 1988; 296: 1726-1727.
- [56] Shami SK, Shields DA, Scurr JH, Coleridge Smith PD. Leg ulceration in venous disease. *Postgrad Med J* 1992; 68: 779-785.
- [57] Lindhagen A, Bergqvist D, Hallböök T, Efsing HO. Venous function five to eight years after clinically suspected deep venous thrombosis. *Acta Med Scand* 1985; 217: 389-395.
- [58] Markel A, Manzo RA, Bergelin RO, Strandness DE. Valvular reflux after deep vein thrombosis: incidence and time of occurrence. *J Vasc Surg* 1992; 15: 377-384.
- [59] Franzeck UK, Schalch I, Bollinger A. On the relationship between changes in the deep veins evaluated by Duplex sonography and the postthrombotic syndrome 12 years after deep vein thrombosis. *Thromb Haemost* 1997; 77: 1109-1112.
- [60] Haenen JH, Janssen MC, Wollersheim H, Van't Hof MA, de Rooij
- [61] MJ, van Langen H, Skotnicki SH, Thien T. The development of postthrombotic syndrome in relationship to venous reflux and calf muscle pump dysfunction at 2 years after the onset of deep venous thrombosis. *J Vasc Surg* 2002; 35: 1184-1189.
- [62] Asbeutah AM, Riha AZ, Cameron JD, McGrath BP. Five-year outcome study of deep vein thrombosis in the lower limbs. *J Vasc Surg* 2004; 40: 1184-1189.
- [63] Singh H, Masuda EM. Comparing short-term outcomes of femoral-popliteal and iliofemoral deep venous thrombosis: early lysis and development of reflux. *Ann Vasc Surg* 2005; 19: 74-79.
- [64] Prandoni P, Frulla M, Sartor D, Concolato A, Girolami A. Vein abnormalities and the post-thrombotic syndrome. *J Thromb Haemost* 2005; 3: 401-402.
- [65] Shbaklo H, Holcroft CA, Kahn SR. Levels of inflammatory markers and the development of the post thrombotic syndrome. *Thromb Haemost* 2009; 101: 505-12.

- [66] Kahn SR, Shbaklo H, Shapiro S, Wells PS, Kovacs MJ, Rodger MA, Anderson DR, Ginsberg JS, Johri M, Tagalakakis V. Effectiveness of compression stockings to prevent the post-thrombotic syndrome (the SOX Trial and Bio-SOX biomarker substudy): a randomized controlled trial. *BMC Cardiovasc Disord* 2007; 7: 21.
- [67] Van Dongen CJ, Prandoni P, Frulla M, Marchiori A, Prins MH, Hutten BA. Relation between quality of anticoagulant treatment and the development of the postthrombotic syndrome. *J Thromb Haemost* 2005; 3: 939-942.
- [68] Ageno W, Piantanida E, Dentali F, Steidl L, Mera V, Squizzato A, Marchesi C, Venco A. Body mass index is associated with the development of the post-thrombotic syndrome. *Thromb Haemost* 2003; 89: 305-309.
- [69] Hafner J, Bounameaux H, Burg G, Brunner U. Management of venous leg ulcers. *Vasa* 1996; 25: 161-167.
- [70] Evers EJ, Wuppermann T. Effect of different compression therapies on the reflux in deep veins with a post-thrombotic syndrome. *Vasa* 1999; 28: 19-23.
- [71] Erickson CA, Lanza DJ, Karp DL, Edwards JW, Seabrook GR, Cambria RA, Freishlag JA, Towne JB. Healing of venous ulcers in an ambulatory care program: the roles of chronic venous insufficiency and patients compliance. *J Vasc Surg* 1995; 22: 629-636.
- [72] Milne AA, Ruckley CV. The clinical course of patients following extensive deep venous thrombosis. *Eur J Vasc Surg* 1994; 8: 56-9.
- [73] Prandoni P, Lensing AWA, Prins MH, Bagatella P, Scudeller A, Girolami A. Which is the outcome of the post-thrombotic syndrome? *Thromb Haemost* 1999; 82: 1196-1197.
- [74] Kahn SR, Elman E, Rodger MA, Wells PS. Use of elastic compression stockings after deep venous thrombosis: a comparison of practices and perceptions of thrombosis physicians and patients. *J Thomb Haemost* 2003; 1: 500-506.
- [75] Kahn SR, Azoulay L, Hirsch A, Haber M, Strulovitch C, Shrier I. Effect of graduated elastic compression stockings on leg symptoms and signs during exercise in patients with deep venous thrombosis: a randomized cross-over trial. *J Thomb Haemost* 2003; 1: 494-499.
- [76] Ginsberg JS, Magier D, Mackinnon B, Gent M, Hirsh J. Intermittent compression units for severe post-phlebotic syndrome: a randomised crossover study. *CMAJ* 1999; 160: 1303-1306.
- [77] O'Donnell MJ, McRae S, Kahn SR, Julian JA, Kearon C, Mackinnon B, Magier D, Strulovich C, Lyons T, Robinson S, Hirsh J, Ginsberg JS. Evaluation of a venous-return assist device to treat severe post-thrombotic syndrome (VENOPTS) A randomized controlled trial. *Thromb Haemost* 2008; 99: 463-464.
- [78] Kahn SR, Shrier I, Shapiro S, Houweling AH, Hirsch AM, Reid RD, Kearon C, Rabhi K, Rodger MA, Kovacs MJ, Anderson DR, Wells PS. Six-month exercise training program to treat post-thrombotic syndrome: a randomized controlled two-centre trial. *CMAJ* 2011; 183: 37-44.
- [79] Colgan MP, Dormandy JA, Jones PW, Schraibman IG, Shanik G, Young RA. Oxpentifylline treatment of venous ulcers of the leg. *Br Med J* 1990; 300: 972-975.
- [80] Layton AM, Ibbotson SH, Davies JA, Goodfield MJ. Randomized trial of oral aspirin for chronic venous leg ulcer. *Lancet* 1994; 344: 164-165.
- [81] Rudofsky G. Intravenous prostaglandin E1 in the treatment of venous ulcers - a double-blind placebo-controlled trial. *Vasa* 1989; 28 (Suppl): 39-43.
- [82] Salim AS. Role of sulphydril-containing agents in the management of venous (varicose) ulceration A new approach. *Clin Exp Dermatol* 1992; 17: 427-432.

- [83] Salim AS. The role of oxygen-derived free radicals in the management of venous (varicose) ulceration. A new approach *World J Surg* 1991; 15: 264-269.
- [84] Coccheri S, Scandotto G, Agnelli G, Aloisi D, Palazzini E, Zamboni V. Randomised double blind multicentre placebo controlled study of sulodexide in the treatment of venous leg ulcers. *Thromb Haemost* 2002; 87: 947-952.
- [85] Burnand K, Clemenson G, Morland M, Jarret PE, Browse NL. Venous lipodermatosclerosis: treatment by fibrinolytic enhancement and elastic compression. *Br Med J* 1980; 280: 7-11.
- [86] de Jongste AB, Jonker JJC, Huisman MV, ten Cate JW, Azar AJ. A double blind three center clinical trial on the short-term efficacy of 0-(β -hydroxyethyl)-rutosides in patients with post-thrombotic syndrome. *Thromb Haemost* 1989; 62: 826-829.
- [87] Frulla M, Marchiori A, Sartor D, Mosena L, Tormene D, Concolato A, Hartmann L, Prandoni P. Elastic stockings hydroxyethylrutosides or both for the treatment of post-thrombotic syndrome. *Thromb Haemost* 2005; 93: 183-185.
- [88] Baste JC, Midy F. Surgery for post-thrombotic syndrome of the lower limbs *Rev Prat* 1994; 44: 781-785.
- [89] Gloviczki P, Bergan JJ, Rhodes JM, Canton LG, Harmsen S, Ilstrup DM. Mid-term results of endoscopic perforator vein interruption for chronic venous insufficiency: lessons learned from the north American subfascial endoscopic perforator surgery registry. The north American study group *J Vasc Surg* 1999; 29: 489-502.
- [90] Perrin M, Hiltbrand B, Bayon JM. Results of valvuloplasty in patients presenting deep venous insufficiency and recurring ulceration. *Ann Vasc Surg* 1999; 13: 524-532.
- [91] Goldhaber SZ, Buring JE, Lipnick RJ, Hennekens CH. Pooled analyses of randomized trials of streptokinase and heparin in phlebographically documented acute deep venous thrombosis. *Am J Med* 1984; 76: 393-397.
- [92] Sidorov J. Streptokinase vs heparin for deep venous thrombosis Can lytic therapy be justified? *Arch Intern Med* 1989; 149: 1841-1845.
- [93] Rogers LQ, Lutcher CL. Streptokinase therapy for deep vein thrombosis: a comprehensive review of the English literature. *Am J Med* 1990; 88: 389-395.
- [94] Alesh I, Kayali F, Stein PD. Catheter-directed thrombolysis (intrathrombus injection) in treatment of deep venous thrombosis: a systematic review. *Catheter Cardiovasc Interv* 2007; 70: 143-148.
- [95] Comerota AJ, Aldridge SC, Cohen G, Ball DS, Pliskin M, White JV. A strategy of aggressive regional therapy for acute iliofemoral venous thrombosis with contemporary venous thrombectomy or catheter-directed Thrombolysis. *J Vasc Surg* 1994; 20: 244-254.
- [96] Bjarnason H, Kruse JR, Asinger DA, Nazarian GK, Dietz CA Jr, Caldwell MD, Key NS, Hirsch AT, Hunter DW. Iliofemoral deep venous thrombosis: safety and efficacy outcome during 5 years of catheter-directed thrombolytic therapy. *JVIR* 1997; 8: 405-418.
- [97] Comerota AJ, Paolini D. Treatment of acute iliofemoral deep venous thrombosis: a strategy of thrombus removal. *Eur J Vasc Endovasc Surg* 2007; 33: 351-360.
- [98] Manninen H, Juutilainen A, Kaukanen E, Lehto S. Catheter-directed thrombolysis of proximal lower extremity deep vein thrombosis: A prospective trial with venographic and clinical follow-up. *Eur J Radiol* 2011; epub ahead of print
- [99] Park YJ, Choi JY, Min SK, Lee T, Jung IM, Chung JK, Chung JW, Park JH, Kim SJ, Ha J. Restoration of patency in iliofemoral deep vein thrombosis with catheter-directed

- thrombolysis does not always prevent post-thrombotic damage. *Eur J Vasc Endovasc Surg* 2008; 36: 725-730.
- [100] Ghanima W, Kleven IW, Enden T, Rosales A, Wik HS, Pederstad L, Holme PA, Sandset PM. Recurrent venous thrombosis, post-thrombotic syndrome and quality of life after catheter-directed thrombolysis in severe proximal deep vein thrombosis. *J Thromb Haemost*. 2011; epub ahead of print.
 - [101] Kearon C, Kahn SR, Agnelli G, Goldhaber S, Raskob GE,
 - [102] Comerota AJ. Antithrombotic therapy for venous thromboembolic disease: American College of Chest Physicians evidence-based clinical practice guidelines (8th edition). *Chest* 2008; 133 (6 Suppl): 454S-545S.
 - [103] Enden T, Sandvik L, Klow NE, Hafsahl G, Holme PA, Holmen LO, Ghanima W, Njaastad AM, Sandbaek G, Slagsvold CE, Sandset PM. Catheter-directed Venous Thrombolysis in acute iliofemoral vein thrombosis-the CaVenT Study: rationale and design of a multicenter randomized controlled clinical trial. *Am Heart J* 2007; 154: 808-814.
 - [104] Ginsberg JS, Hirsh J, Julian J, Vander Laande Vries M, Magier D, MacKinnon B, Gent M. Prevention and treatment of postphlebotic syndrome Results of a 3-part study. *Arch Intern Med* 2001; 161: 2105-2109.
 - [105] Kakkos SK, Daskalopoulou SS, Daskalopoulos ME, Nicolaides AN, Geroulakos G. Review on the value of graduated elastic compression stockings after deep vein thrombosis. *Thromb Haemost* 2006; 96: 441-445.
 - [106] Benko T, Cooke EA, McNally MA, Mollan RA. Graduated compression stockings: knee length or thigh length *Clin Orthop Relat Res* 2001; 383: 197-203.
 - [107] Sajid MS, Tai NR, Goli G, Morris RW, Baker DM, Hamilton G. Knee versus thigh length graduated compression stockings for prevention of deep venous thrombosis: a systematic review. *Eur J Vasc Endovasc Surg* 2006; 32: 730-736.
 - [108] Full-leg vs below-knee elastic stockings for prevention of the post-thrombotic syndrome. *ClinicalTrials.gov* identifier: NCT00426075
 - [109] Ten Cate-Hoek AJ, Ten Cate H, Tordoir J, Hamulyák K, Prins MH. Individually tailored duration of elastic compression therapy in relation to incidence of the postthrombotic syndrome. *J Vasc Surg* 2010; 52: 132-138.
 - [110] Nelson EA, Harper DR, Prescott RJ, Gibson B, Brown D, Ruckley CV. Prevention of recurrence of venous ulceration: randomized controlled trial of class 2 and class 3 elastic compression. *J Vasc Surg* 2006; 44: 803-808.
 - [111] Partsch H, Kaulich M, Mayer W. Immediate mobilisation in acute vein thrombosis reduces post-thrombotic syndrome. *Int Angiol* 2004; 3: 206-212.
 - [112] Hull RD, Pineo GF, Brant R, Liang J, Cook R, Solymoss S, Poon MC, Raskob G. Home therapy of venous thrombosis with long-term LMWH versus usual care: patient satisfaction and post-thrombotic syndrome. *Am J Med* 2009; 122: 762-769.
 - [113] Schulman S, Kearon C, Kakkar AK, Mismetti P, Schellong S, Eriksson H, Baanstra D, Schnee J, Goldhaber SZ. Dabigatran versus warfarin in the treatment of acute venous thromboembolism. *N Engl J Med* 2009; 361: 2342-52.
 - [114] The Einstein Investigators. Oral rivaroxaban for symptomatic venous thromboembolism. *N Engl J Med* 2010; 363: 2499-510.



Deep Vein Thrombosis

Edited by Dr. Gregory Cheng

ISBN 978-953-51-0225-0

Hard cover, 184 pages

Publisher InTech

Published online 07, March, 2012

Published in print edition March, 2012

This book provides a comprehensive review of deep vein thrombosis. There are chapters on risk factors for DVT, post thrombotic syndrome and its management, vena cava malformation as a new etiological factor and thrombosis in the upper limbs. DVT is usually seen in patients undergoing major surgeries. The guidelines for thrombo-prophylaxis in orthopaedic patients, radical pelvic surgeries, laparoscopic operations and risks versus benefits in regions with a low prevalence of DVT are thoroughly addressed. Cancer and its treatment are recognized risk factors for VTE and extended prophylaxis in ambulatory cancer patients is reviewed. The role of imaging and endovascular therapies in acute DVT, hypercoagulability in liver diseases and the challenges in developing countries are discussed.

How to reference

In order to correctly reference this scholarly work, feel free to copy and paste the following:

Paolo Prandoni and Susan R Kahn (2012). The Post Thrombotic Syndrome, Deep Vein Thrombosis, Dr. Gregory Cheng (Ed.), ISBN: 978-953-51-0225-0, InTech, Available from:
<http://www.intechopen.com/books/deep-vein-thrombosis/post-thrombotic-syndrome-of-the-leg>

INTECH
open science | open minds

InTech Europe

University Campus STeP Ri
Slavka Krautzeka 83/A
51000 Rijeka, Croatia
Phone: +385 (51) 770 447
Fax: +385 (51) 686 166
www.intechopen.com

InTech China

Unit 405, Office Block, Hotel Equatorial Shanghai
No.65, Yan An Road (West), Shanghai, 200040, China
中国上海市延安西路65号上海国际贵都大饭店办公楼405单元
Phone: +86-21-62489820
Fax: +86-21-62489821

© 2012 The Author(s). Licensee IntechOpen. This is an open access article distributed under the terms of the [Creative Commons Attribution 3.0 License](https://creativecommons.org/licenses/by/3.0/), which permits unrestricted use, distribution, and reproduction in any medium, provided the original work is properly cited.

IntechOpen

IntechOpen