

We are IntechOpen, the world's leading publisher of Open Access books Built by scientists, for scientists

6,900

Open access books available

186,000

International authors and editors

200M

Downloads

Our authors are among the

154

Countries delivered to

TOP 1%

most cited scientists

12.2%

Contributors from top 500 universities



WEB OF SCIENCE™

Selection of our books indexed in the Book Citation Index
in Web of Science™ Core Collection (BKCI)

Interested in publishing with us?
Contact book.department@intechopen.com

Numbers displayed above are based on latest data collected.
For more information visit www.intechopen.com



Vena Cava Malformations as an Emerging Etiologic Factor for Deep Vein Thrombosis in Young Patients

Massimiliano Bianchi¹, Lorenzo Faggioni¹, Virna Zampa¹,
Gina D'Errico¹, Paolo Marraccini² and Carlo Bartolozzi¹

¹Azienda Ospedaliero-Universitaria Pisana,

²Istituto di Fisiologia Clinica del CNR

^{1,2}Italia

1. Introduction

Deep venous thrombosis (DVT) is an illness of clinical interest, due to the associated morbidity and mortality and its social and health care consequences. The etiology in young patients has shown it frequently associated with congenital coagulation abnormalities and acquired/inherited risk factors (table I) (a,b).

Inherited

Common

G169A mutation in the factor V gene (factor V Leiden)

G20219A mutation in the prothrombin (factor II) gene

Homozygous C677T mutation in the methylenetetrahydrofolate reductase gene

Rare

Antitrombin deficiency

Protein C deficiency

Protein S deficiency

Very rare

Dysfibrinogenemia

Homozygous homocystinuria

Probably inherited

Increased levels of factor VII, IX, XI or fibrinogen

Acquired

Surgery and trauma

Prolonged immobilization

Older age

Cancer

Myeloproliferative disorders

Previous thrombosis

Pregnancy and the puerperium

Use of contraceptives or hormone-replacement therapy

Resistance to activated protein C (not due alterations in the factor V gene
Antiphospholipid antibodies)
Mild to moderate hyperhomocysteinemia

Table 1. inherited and acquired risk factors for DVT.

However, recent radiological advances derived from multislice computerized tomography (CT) and magnetic resonance imaging (MRI) have identified vena cava malformations as a new etiologic factor to be considered.^(c-g)

The objectives of the present chapter are to describe the embryogenesis and the spectrum of congenital anomalies of the inferior vena cava (IVC) as a risk factor in DVT in young patients. Anomalies of the inferior vena cava (IVC) and its tributaries have been known to anatomists since 1793, when Abernethy^(h) described a congenital meso-caval shunt and azygos continuation of the IVC in a 10-month-old infant with polysplenia and dextrocardia. Since the development of cross-sectional imaging, congenital anomalies of the IVC and its tributaries have become more frequently encountered in asymptomatic patients^(c). The imaging study with CT and MRI of the abdominal vein structures require a specific technique of acquisition in relation with contrast medium injection. During the usual vascular study, that are acquired in arterial phase, the visualization of veins is not adequate for the recognition of the vein system. This may be usually readily identified on CT and magnetic resonance (MR) imaging scans of the abdomen and pelvis obtained with intravenously administered contrast medium. In addition, with helical acquisition, the venous structures may be imaged during the arterial phase, when little or no contrast material is present in the veins. Therefore, in these cases the diagnostic request is essential for correct interpretation of vein vasculature and to avoid erroneous diagnosis (retroperitoneal and mediastinal masses or adenopathy) and to alert the surgeon and angiographer about the characteristics of vascular anatomy.

1.1 The embryogenesis of the IVC

The embryogenesis and the anatomic variations of the IVC become more clear with the development of the CT and magnetic resonance (MR) imaging in clinical practice. In the past Phillips⁽ⁱ⁾ has published a comprehensive review of the embryogenesis of the IVC. In brief, the infrahepatic IVC develops between the 6th and 8th weeks of embryonic life as a composite structure formed from the continuous appearance and regression of three paired embryonic veins. In order of appearance, they are the posterior cardinal, the subcardinal, and the supracardinal veins (Fig 1).

Under ordinary circumstances, the prerenal division is formed from union of the hepatic segment (green area), a vitelline vein derivative, and the right subcardinal vein (magenta area). The renal segment is formed from the suprasubcardinal anastomosis (yellow area) and the postsubcardinal anastomosis (light violet area). The infrarenal segment derives from the right supracardinal vein (goldenrod area). The posterior cardinal veins (dark violet area) form the iliac veins (Adapted and reprinted, with permission, from reference d). Initially, all blood return from the body wall caudal to the heart proceeds through the posterior cardinal veins (dark violet in Fig 1). Blood return from the viscera is conveyed by the vitelline veins (green in Fig 1), which drain the yolk sac. Subsequently, the subcardinal veins (magenta in

Finally, the left supracardinal vein is one of the last veins to disappear, although Huntington and McLure⁽ⁱ⁾ state that the vessel does not so much atrophy as become incorporated into the right supracardinal vein by coalescence of the multiple anastomosis. In summary, the normal IVC is composed of four segments: hepatic, suprarenal, renal, and infrarenal. The hepatic segment is derived from the vitelline vein. The right subcardinal vein develops into the suprarenal segment by formation of the subcardinal-hepatic anastomosis. The renal segment develops from the right suprasubcardinal and postsubcardinal anastomosis. It is generally accepted that the infra-renal segment derives from the right supracardinal vein, although this idea is somewhat controversial⁽ⁱ⁾. In the thoracic region, the supracardinal veins give rise to the azygos and hemiazygos veins. In the abdomen, the postcardinal veins are progressively replaced by the subcardinal and supracardinal veins but persist in the pelvis as the common iliac veins.

2. Variations in IVC anatomy

In a study of the development of the IVC in the domestic cat (*Felis domestica*), Huntington and McLure⁽ⁱ⁾ proposed a classification system for IVC anomalies based on abnormal regression or abnormal persistence of various embryonic veins. These investigators suggested that there could be up to 14 theoretical variations in the anatomy of the infra-renal IVC. They noted that 11 of the 14 variants had been observed in the domestic cat or in humans. In addition, these authors observed that other anomalies seen in humans, such as abnormal development of the pre-renal division of the IVC and persistence of the renal collar in the adult, could be explained on a similar basis.

2.1 Left IVC

A left IVC results from regression of the right supra-cardinal vein with persistence of the left supra-cardinal vein. The prevalence is 0.2%–0.5%⁽ⁱ⁾. Typically, the left IVC joins the left renal vein, which crosses anterior to the aorta in the normal fashion, uniting with the right renal vein to form a normal right-sided prerenal IVC (Fig 2).

2.2 Double IVC

Duplication of the IVC results from persistence of both supracardinal veins. The prevalence is 0.2%–3%⁽ⁱ⁾. The left IVC typically ends at the left renal vein, which crosses anterior to the aorta in the normal fashion to join the right IVC (Fig 3).

2.3 Azygos continuation of the IVC

Azygos continuation of the IVC has also been termed absence of the hepatic segment of the IVC with azygos continuation^(k). The embryonic event is theorized to be failure to form the right sub-cardinal-hepatic anastomosis, with resulting atrophy of the right sub-cardinal vein. Consequently, blood is shunted from the supra-sub-cardinal anastomosis through the retro-crural azygos vein, which is partially derived from the thoracic segment of the right supra-cardinal vein. The prevalence is 0.6%^(k). The renal portion of the IVC receives blood return from both kidneys and passes posterior to the diaphragmatic crura to enter the thorax as the azygos vein (Fig 4).

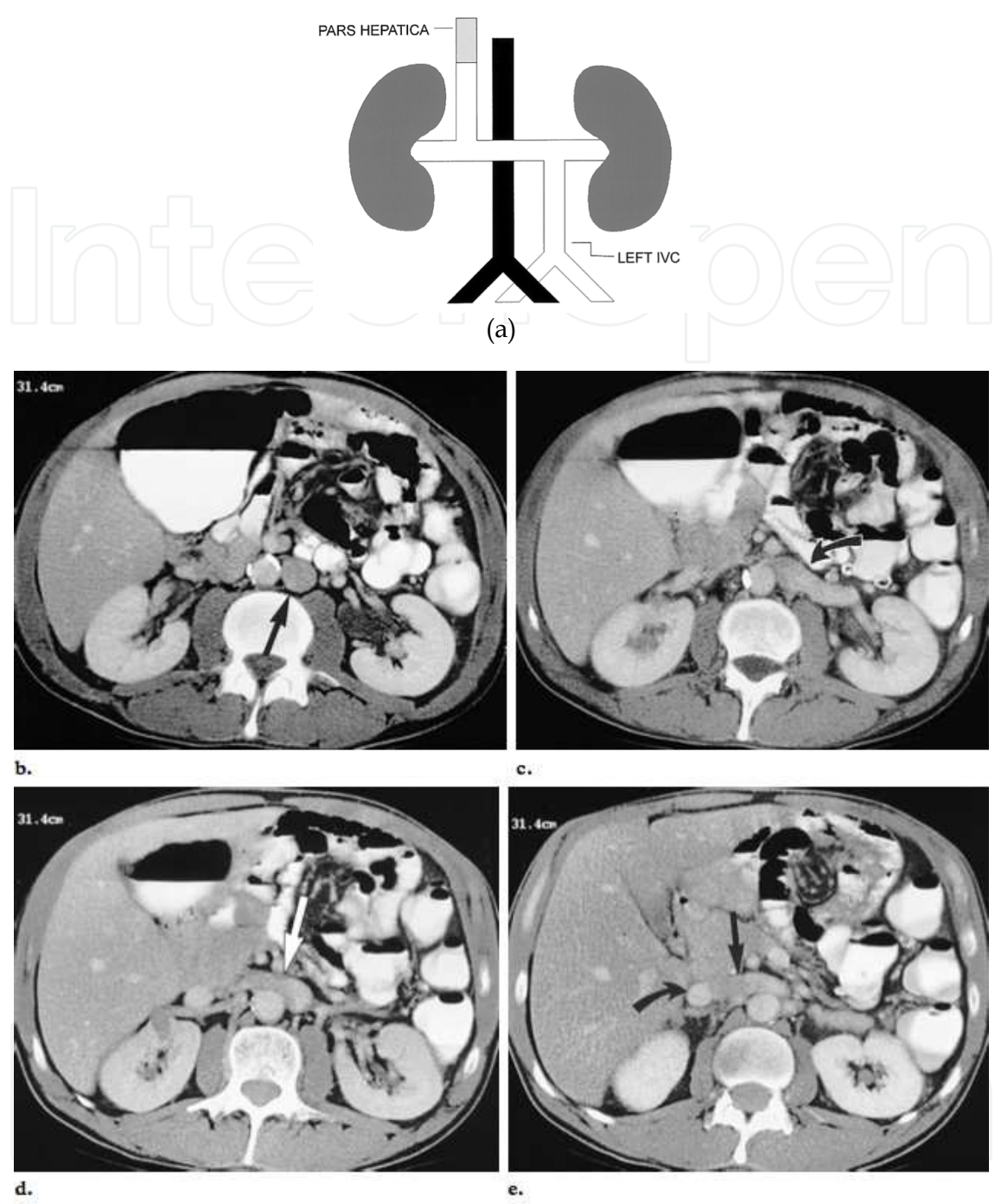

Fig. 2. Partial malrotation and left IVC in a 49-year-old man. (a) Schematic shows a left IVC terminating at the left renal vein. (b-e) CT scans presented from caudal to cranial show the anomaly. (b) Note the left IVC (arrow) inferior to the renal veins. (c) The left IVC joins the left renal vein (arrow). (d) The left renal vein (arrow) crosses anterior to the aorta in the normal fashion. (e) A normal right-sided pre renal IVC is formed from the confluence of the left (straight arrow) and right (curved arrow) renal veins. Note the increased attenuation of the right renal vein relative to that of the left due to absence of dilution from relatively unenhanced lower-extremity venous return. The major clinical significance of this anomaly is the potential for misdiagnosis as left-sided paraaortic adenopathy^(k).

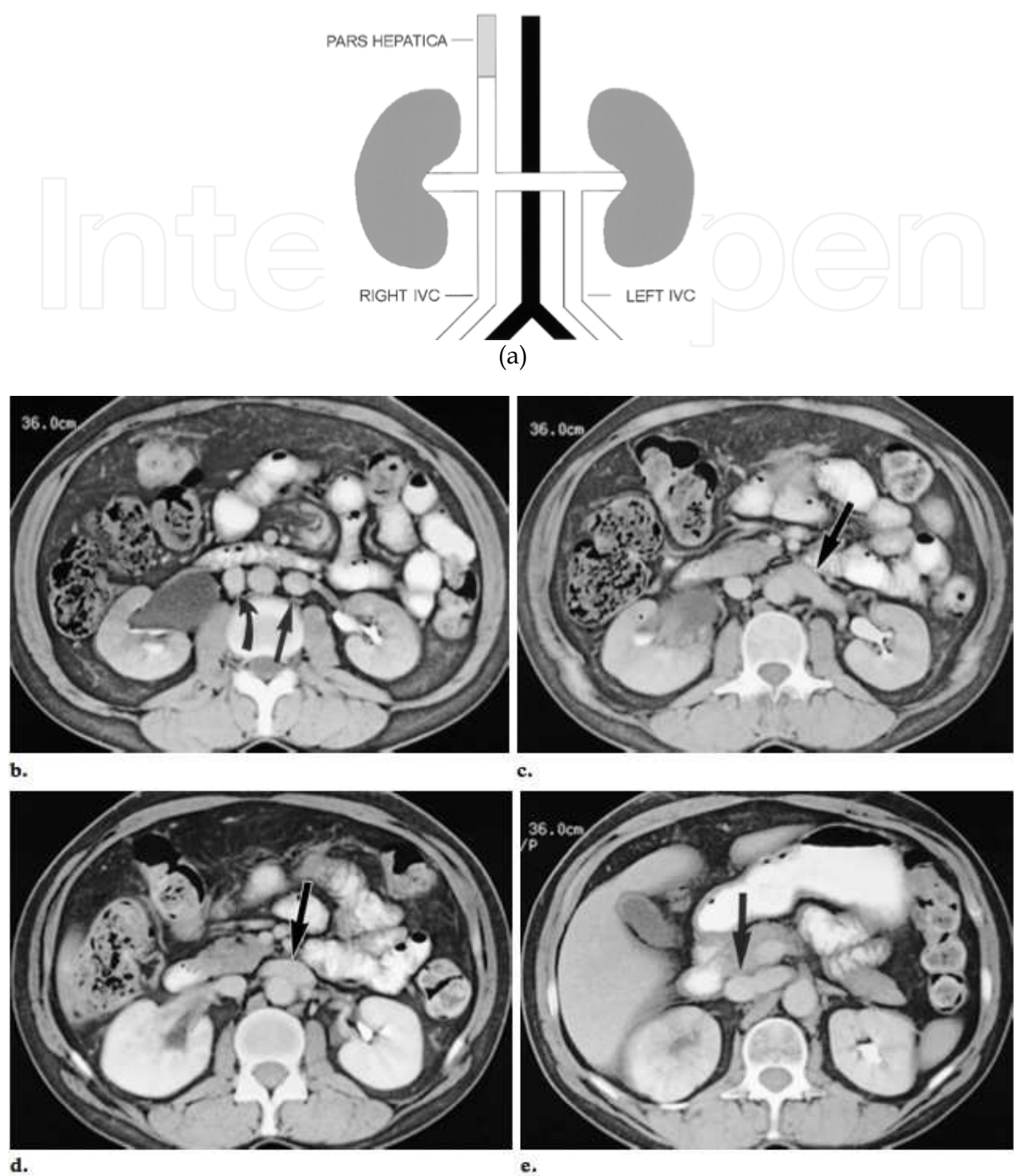


Fig. 3. Double IVC in a 53-year-old woman with lymphoma. (a) Schematic shows left and right infrarenal IVCs. The left IVC terminates at the left renal vein. (b) CT scan obtained inferior to the renal veins shows left (straight arrow) and right (curved arrow) IVCs. (c-e) CT scans show the left IVC ending at the confluence with the left renal vein (arrow in c), which crosses anterior to the aorta in the normal fashion (arrow in d) to join a normal pre-renal IVC (arrow in e). There may be morphological variation and asymmetry of the left and right veins. Double IVC should be suspected in cases of recurrent pulmonary embolism following placement of an IVC filter⁽ⁱ⁾.

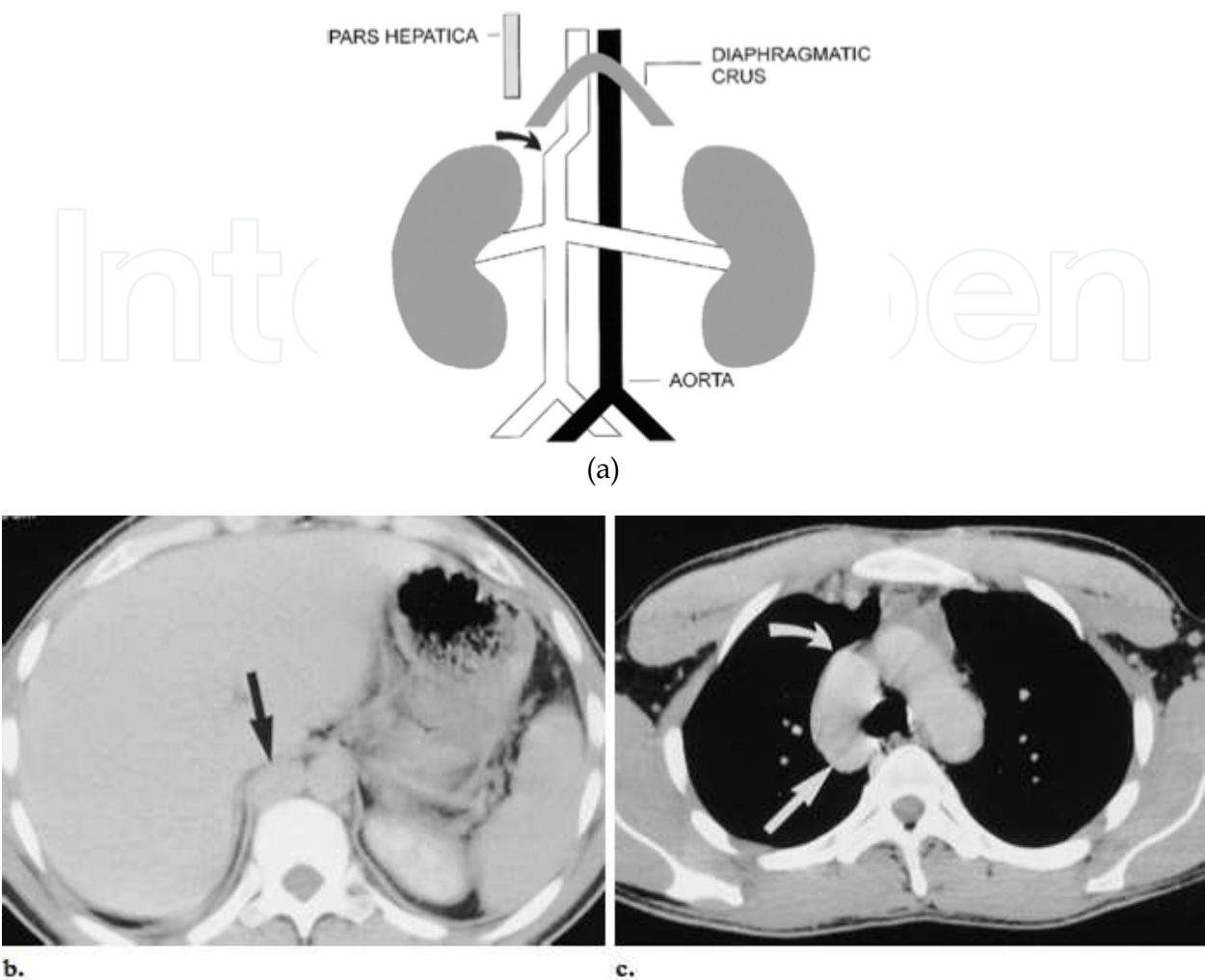


Fig. 4. CT images of azygos continuation of the IVC in a 48-year-old man. (a) Schematic shows lack of contiguity between the pre-renal segment of the IVC (arrow) and the hepatic segment. The vessel parallel to the aorta under the crus is the azygos vein. (b, c) CT scans obtained at the level of the diaphragmatic crus (b) and the level of the azygos vein arch (c) show the enlarged azygos vein (straight arrow) draining into the superior vena cava (curved arrow in c).

The azygos vein joins the superior vena cava at the normal location in the right para-tracheal space. The hepatic segment (often termed the post-hepatic segment) is ordinarily not truly absent; rather, it drains directly into the right atrium. Since the post-sub-cardinal anastomosis does not contribute to formation of the IVC, each gonadal vein drains to the ipsi-lateral renal vein⁽ⁱ⁾. Formerly thought to be predominantly associated with severe congenital heart disease and a-splenia or poly-splenia syndromes, azygos continuation of the IVC has become increasingly recognized in otherwise asymptomatic patients since the advent of cross-sectional imaging. It is important to recognize the enlarged azygos vein at the confluence with the superior vena cava and in the retrocrural space to avoid misdiagnosis as a right-sided para-tracheal mass or retro-crural adenopathy^(k,l). Preoperative knowledge of the anatomy may be important in planning cardiopulmonary bypass and to avoid difficulties in catheterizing the heart^(m).

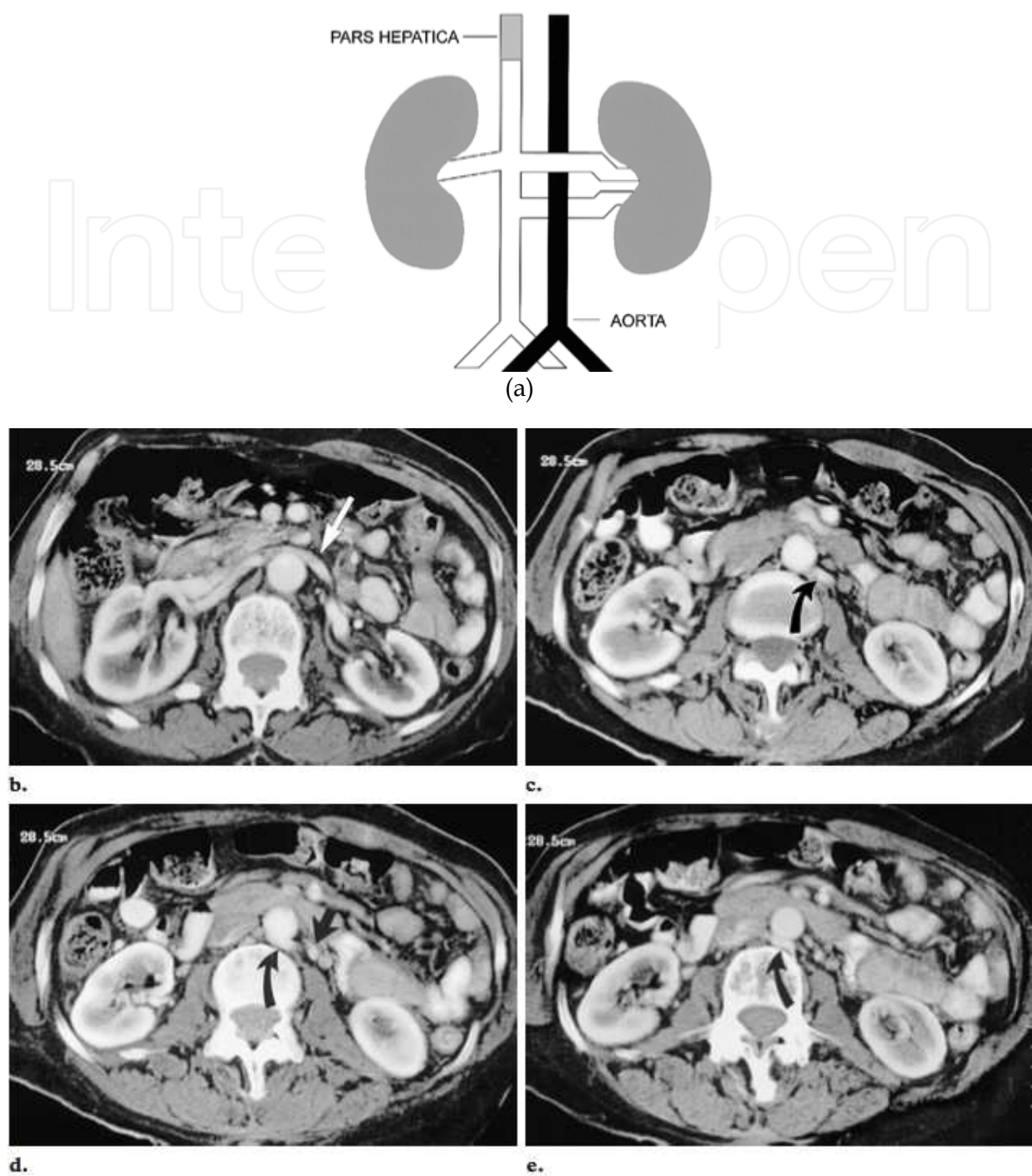


Fig. 5. Circumaortic left renal vein in a 73-year-old woman. (a) Schematic shows two left renal veins, with the inferior vein crossing posterior to the aorta. (b-e) Contiguous 5-mm-thick CT sections presented from cranial to caudal show the anomaly. (b) The superior left renal vein (arrow) crosses anterior to the aorta. (c-e) The inferior vein (curved arrow) descends approximately 2 cm and receives the left gonadal vein (straight arrow in d) before crossing posterior to the aorta. The major clinical significance is in preoperative planning prior to nephrectomy and in renal vein catheterization for venous sampling. Misdiagnosis as retroperitoneal adenopathy should be avoided.

2.4 Circum-aortic left renal vein

A circum-aortic left renal vein results from persistence of the dorsal limb of the embryonic left renal vein and of the dorsal arch of the renal collar (inter-supra-cardinal anastomosis). The prevalence may be as high as 8.7%⁽ⁱ⁾. Two left renal veins are present. The superior renal vein receives the left adrenal vein and crosses the aorta anteriorly. The inferior renal vein receives the left gonadal vein and crosses posterior to the aorta approximately 1–2 cm inferior to the normal anterior vein (Fig 5).

2.5 Retro-aortic left renal vein

As with circum-aortic left renal vein, a retro-aortic left renal vein results from persistence of the dorsal arch of the renal collar. However, in this variation the ventral arch (inter-subcardinal anastomosis) regresses so that a single renal vein passes posterior to the aorta (Fig 6). The prevalence is 2.1%⁽ⁱ⁾. The clinical significance is preoperative recognition of the anomaly.

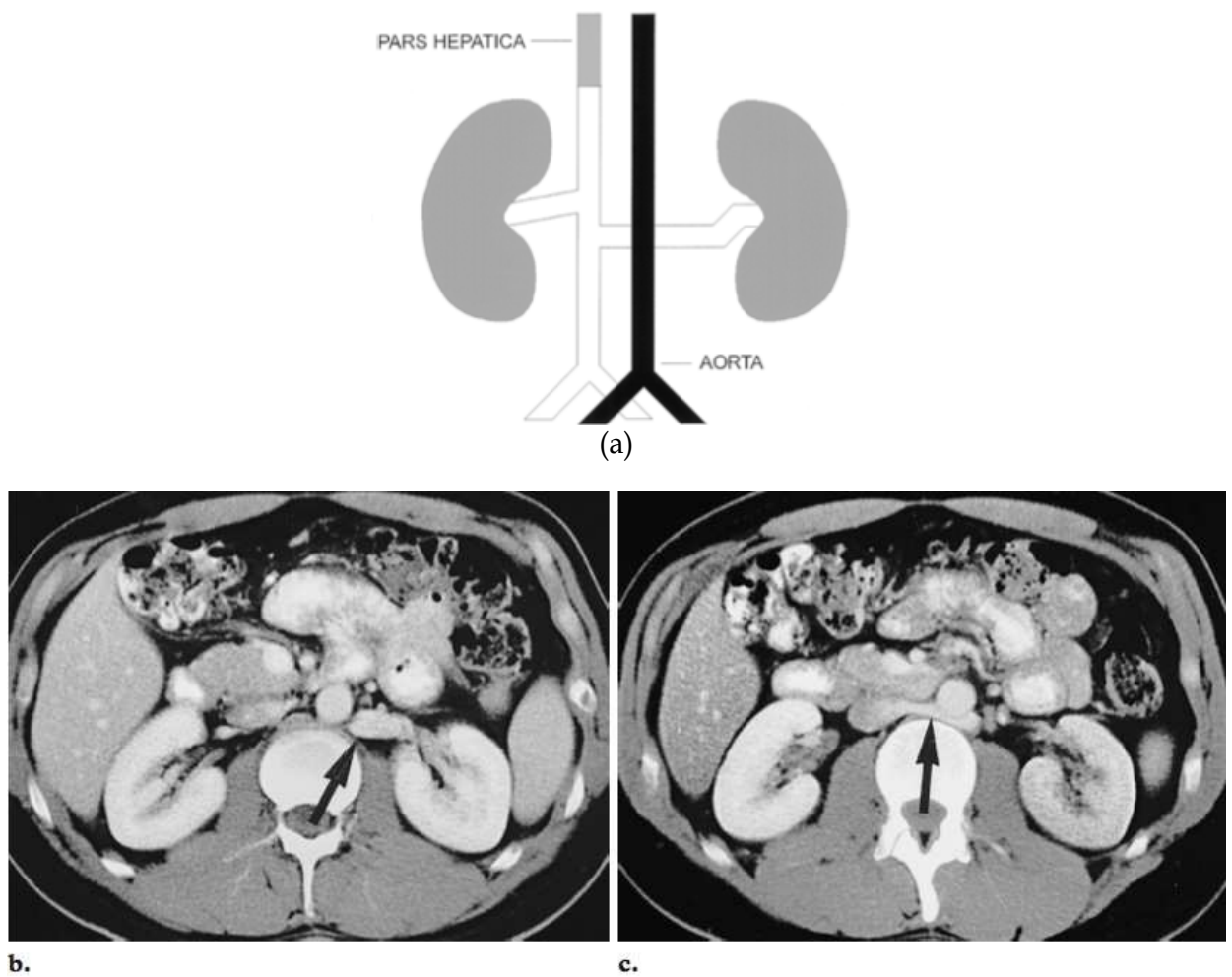


Fig. 6. Retroaortic left renal vein in a 27-year-old man. (a) Schematic shows a single left renal vein, which crosses posterior to the aorta. (b, c) CT scans show the left renal vein (arrow) descending to cross posterior to the aorta.

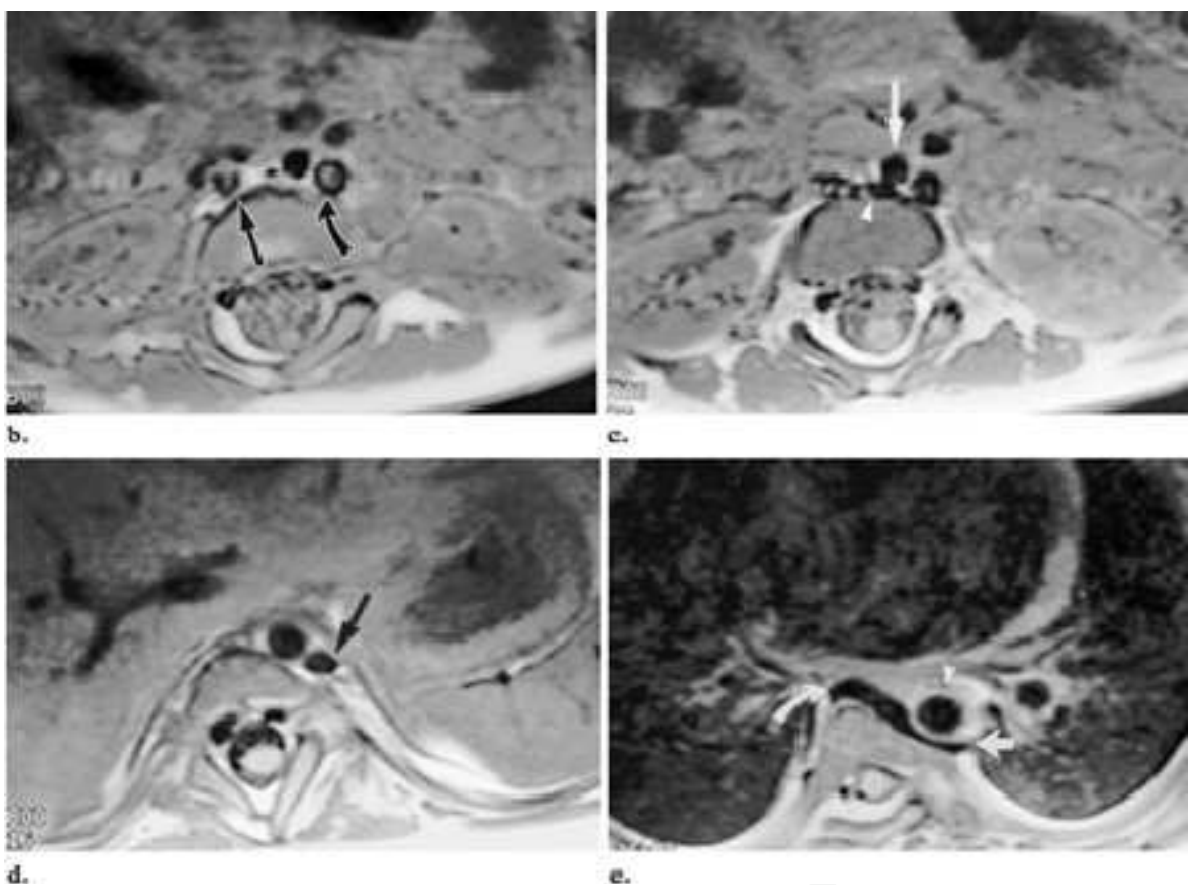
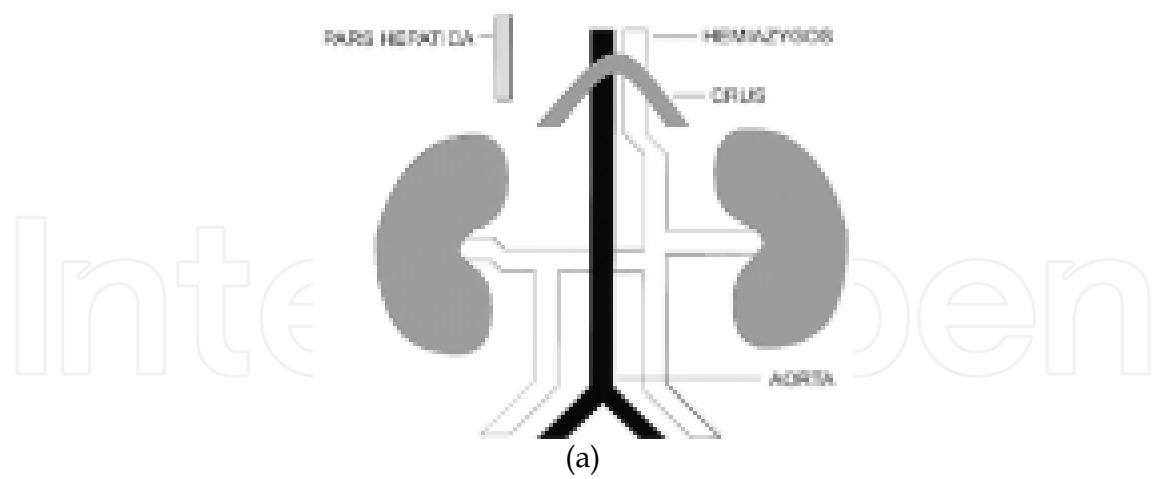


Fig. 7. Spinal dysraphism and double IVC with hemiazygos continuation in a 2-year-old boy. (a) Schematic shows failed development of the right pre-renal IVC and hemi-azygos continuation of the left IVC. (b-e) MR images presented from caudal to cranial show the anomaly. (b) Note the right (straight arrow) and left (curved arrow) IVCs. (c) The right renal vein (arrowhead) descends to receive the right IVC and crosses posterior to the aorta (arrow) to join the left IVC. (d) The left IVC continues cephalad left of the aorta under the diaphragmatic crus as the hemi-azygos vein (arrow). (e) In the thorax, the hemi-azygos vein (straight arrow) crosses posterior to the aorta (arrowhead) to join a rudimentary azygos vein (curved arrow) approximately 1-2 cm below the carina.

2.6 Double IVC with retro-aortic right renal vein and hemi-azygos continuation of the IVC

More than one anomaly can coexist in a patient. In the case of a double IVC with a retro-aortic right renal vein and hemi-azygos continuation of the IVC, the embryologic basis is persistence of the left lumbar and thoracic supra-cardinal vein and the left supra-sub-cardinal anastomosis, together with failure of formation of the right sub-cardinal-hepatic anastomosis. In addition, the right renal vein and right IVC meet and cross posterior to the aorta to join the left IVC and continue cephalad as the hemi-azygos vein (Fig 7). Thus, there is also persistence of the dorsal limb of the renal collar and regression of the ventral limb. In the thorax, the hemi-azygos vein crosses posterior to the aorta at approximately T8 or T9 to join the rudimentary azygos vein. Alternate collateral pathways for the hemi-azygos vein include cephalad continuation to join the coronary vein of the heart via a persistent left superior vena cava and an accessory hemi-azygos continuation to the left brachio-cephalic vein⁽ⁿ⁾.

2.7 Double IVC with retro-aortic left renal vein and hemiazygos continuation of the IVCA

Double IVC with a retro-aortic left renal vein and azygos continuation of the IVC is an interesting combination. It results from persistence of the left supracardinal vein and the dorsal limb of the renal collar with regression of the ventral limb. In addition, the sub-cardinal-hepatic anastomosis fails to form (Fig 7). A recent study demonstrated that azygos continuation of the IVC can be predicted with ultrasonography by identifying the right renal artery crossing abnormally anterior to the IVC ⁽¹⁵⁾.

2.8 Circum-caval ureter

A circum-caval ureter is also termed a retro-caval ureter. The right supra-cardinal system fails to develop, whereas the right posterior cardinal vein persists. The anomaly always occurs on the right side. The proximal ureter courses posterior to the IVC, then emerges to the right of the aorta, coming to lie anterior to the right iliac vessels (Fig 8). Patients with this anomaly may develop partial right ureteral obstruction or recurrent urinary tract infections. Therapeutic options include surgical relocation of the ureter anterior to the cava⁽ⁱ⁾.

2.9 Absent Infra-renal IVC with preservation of the supra-renal segment

Several reports have described absence of the entire IVC ^(o-r) or absence of the infra-renal IVC with preservation of the supra-renal segment (Fig 9) ^(s,t). Absence of the entire posthepatic IVC suggests that all three paired venous systems failed to develop properly.

Absence of the infrarenal IVC implies failure of development of the posterior cardinal and supracardinal veins. Since it is difficult to identify a single embryonic event that can lead to either of these scenarios, there is controversy as to whether these conditions are true embryonic anomalies or the result of perinatal IVC thrombosis ^(p,s,t).

3. Implications for treatment of DVT and prevention of recurrences

The therapy of acute DVT in this kind of patients is similar of the currently recommended strategies and includes un-fractionated heparin, low-molecular weight heparin, fondaparinux

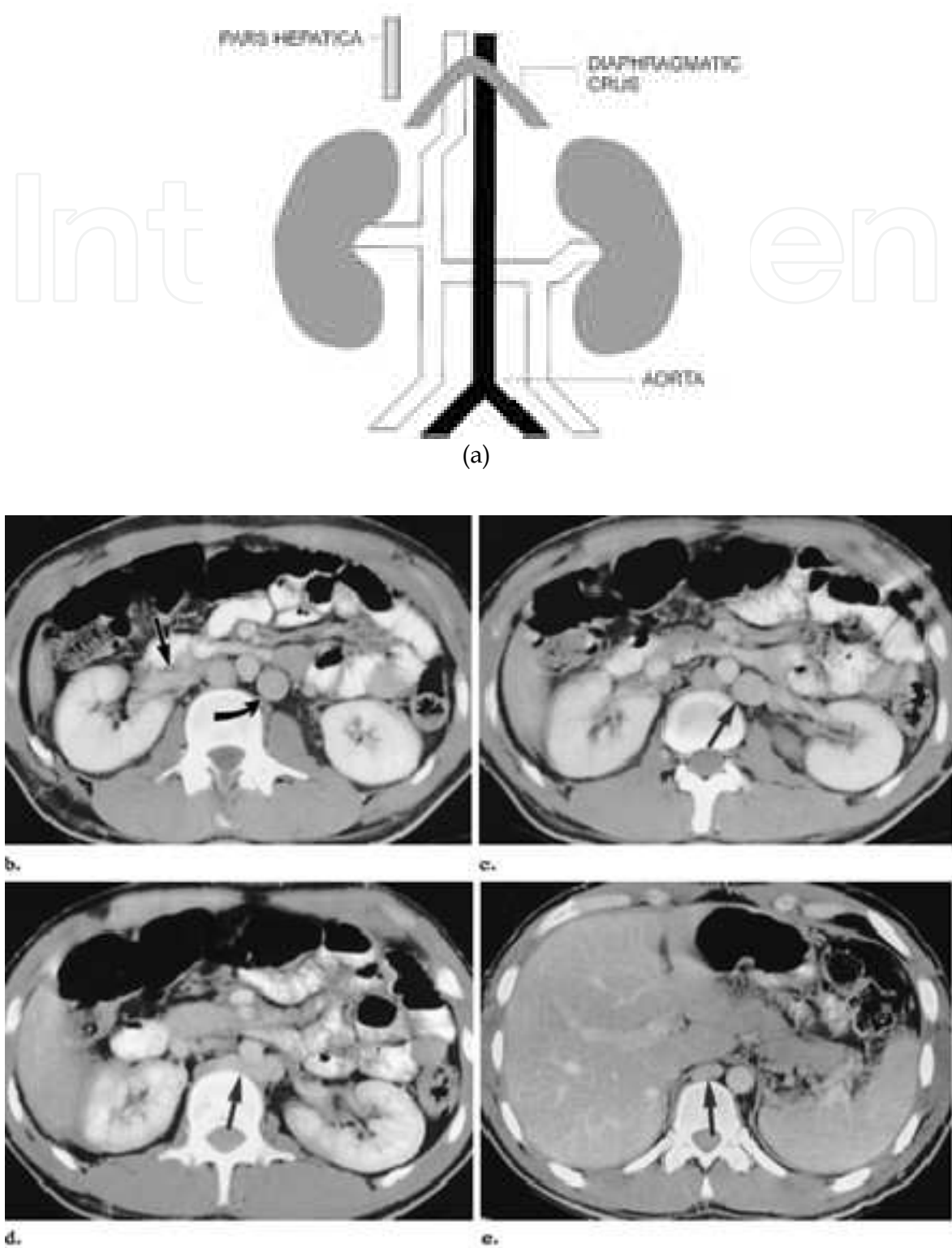


Fig. 8. Circumcaval ureter in a 65-year-old man. (a) Schematic shows the right ureter encircling the IVC. (b-d) CT scans presented from cranial to caudal show the anomaly. (b) The right ureter (arrow) is positioned posterior to the IVC. (c) The ureter (arrow) then courses to the left of the IVC. (d) Finally, the ureter (arrow) crosses anterior to the IVC. (Courtesy of Akira Kawashima, MD, Lyndon B. Johnson General Hospital, Houston, Tex.)

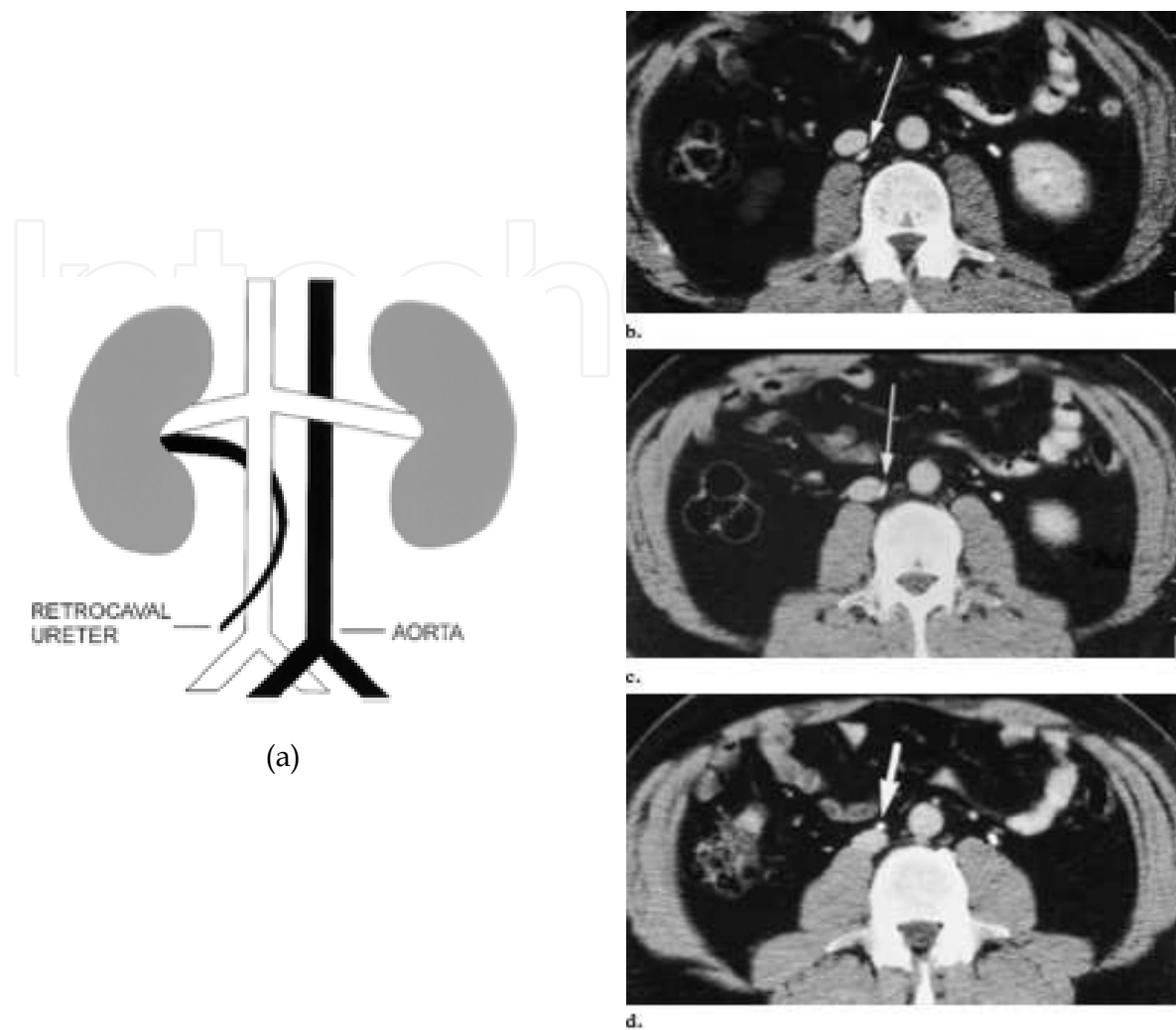


Fig. 9. Absent infra-renal IVC. (a) Schematic shows absence of the IVC below the renal veins. Collateral flow from the lower extremities reaches the azygos vein via para-vertebral collateral veins. (b) CT scan obtained inferior to the aortic bifurcation shows absence of the common iliac veins. Enlarged ascending lumbar veins are present (black arrow). Note the iliac arteries (white arrow). (c) CT scan obtained inferior to the kidneys shows absence of the IVC (white arrow). Enlarged ascending lumbar veins are present (black arrow). (d) CT scan obtained at the level of the renal veins shows a normal pre-renal IVC formed at the confluence of the renal veins (arrow). (e) CT scan obtained at the level of the pre-renal IVC (white arrow) shows prominent para-vertebral collateral veins (black arrow), which lead to a prominent azygos vein (arrowhead). (f) Coronal T1-weighted MR image shows the enlarged ascending lumbar veins (arrow). (g) Lateral maximum-intensity projection reconstruction of two-dimensional time-of-flight MR images shows formation of enlarged ascending lumbar veins at the confluence of the internal and external iliac veins (solid straight arrow). Note the anastomosis between the ascending lumbar veins and the azygos vein (open straight arrow) via prominent anterior para-vertebral veins (white curved arrow). Also note the pre-renal IVC (black arrowhead) posterior to the portal vein (black curved arrow), as well as prominent anterior abdominal wall collateral veins (white arrowheads). (Figs 10b, 10c, and 10g reprinted, with permission, from references).

and vitamin-K antagonists^(u). The diagnosis of anomalies in the inferior vena cava influences the strategy for prevention the pulmonary embolism and long term maintenance treatment.

The use of mechanical device as caval filter is clearly limited by the anomalous anatomy of the inferior vena cava and, generally, is not indicated. On the other hand the use of oral anti-coagulant (commonly warfarin) should be adjusted to maintain a target international normalized ratio of 2.5 (range 2-3) and extended indefinitely in absence of main contraindications^(d).

At present the introduction of new drugs as the factor Xa antagonists (rivarixaban, apixaban, edoxaban, ect) and the direct thrombin inhibitors as dabigatran etexilate could improve the therapeutic options. The promising results of the recent clinical studies in terms of efficacy and safety, suggest that these new drugs may allow a reduction of the length of hospital stay after an acute DVT, and a better adherence to guidelines in the long term treatment. The principal advantages of these drugs are the absence of the need of a routine coagulation monitoring and a therapeutic activity not influenced by dietary regimen and by drugs as NSAIDs and statins^(u). Potential limitations are the lack of specific antidotes (however the half-life of these drugs is relative short) and the absence of a simple assay for quantification of activity or plasma level.

In conclusion these interesting pharmacological characteristics could improve the benefit-risk balance of long-term anti-coagulant therapy and the overall clinical outcome.

4. Conclusions

The complexity of the ontogeny of the IVC, with numerous anastomosis formed between the three primitive paired veins, can lead to a wide array of variations in the basic plan of venous return from the abdomen and lower extremity. Some of these anomalies have significant clinical implications. Although vascular structures can usually be readily identified on contrast-enhanced CT scans, identification of unusual venous arrangements may be difficult in those cases in which intravenous contrast material is contraindicated. In such patients, MR imaging may be used to distinguish aberrant vessels from masses by demonstrating flow voids or flow-related enhancement. The echo-scanning may suggest the presence of venous anomalies but usually it is insufficient for a detailed diagnosis. A knowledge of IVC and renal vein anomalies is essential to avoid diagnostic pitfalls.

5. References

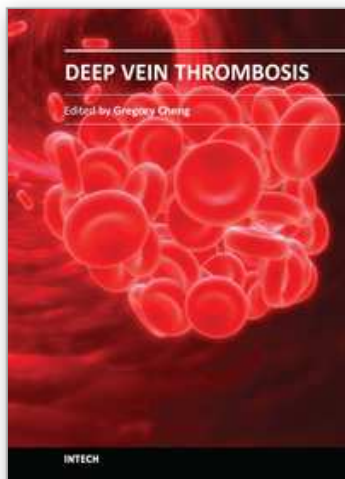
- [1] Rosendaal F. Thrombosis in the young: epidemiology and risk factors. A focus on venous thrombosis. *Thromb Haemost.* 1997;78:1-6.
- [2] García-Fuster MJ, Fernández C, Forner MJ, & Vayá A. Estudio prospectivo de los factores de riesgo y las características clínicas de la enfermedad tromboembólica en pacientes jóvenes. *Med Clin (Barc).* 2004;123:217-9.
- [3] Ruggeri M, Tosseto A, Castaman G & Rodeghiero F. Congenital absence of the inferior vena cava: a rare risk factor for idiopathic deep vein thrombosis. *Lancet.* 2001;357:441.
- [4] M. Bianchi, D. Giannini, A. Balbarini, M.G. & Castiglioni. Congenital hypoplasia of inferior vena cava and inherited thrombophilia: rare associated risk factor for

- idiopathic deep vein thrombosis. A case report. *J Cardiovasc Med* (Hagerstown). 2008 Jan;9(1):101-4.
- [5] Obernosterer A, Aschauer M, Schnedl W & Lipp RW. Anomalies of the inferior vena cava in patients with iliac venous thrombosis. *Ann Intern Med*. 2002;136:37-41.
- [6] Chee YL, Culligan DJ & Watson HG. Inferior vena cava malformation as a risk factor for deep venous thrombosis in the young. *Br J Haematol*. 2001;114:878-80.
- [7] Gayer G, Luboshitz J, Hertz M, Zissen R, Thaler M, Lubetsky A & et al. Congenital anomalies of the inferior vena cava revealed on CT in patients with deep vein thrombosis. *AJR*. 2003;180:729-32.
- [8] Abernethy J. Account of two instances of uncommon formation in the viscera of the human body. *Philos Trans R Soc* 1793; 83:59
- [9] Phillips E. Embryology, normal anatomy, and anomalies. In: Ferris EJ, Hipona FA, Kahn PC, Phillips E, Shapiro JH, eds. *Venography of the inferior vena cava and its branches*. Baltimore, Md: *Williams & Wilkins*, 1969; 1-32.
- [10] Huntington GS, McLure CFW. The development of the veins in the domestic cat (*felis domestica*) with especial reference, 1) to the share taken by the supracardinal vein in the development of the postcava and azygous vein and 2) to the interpretation of the variant conditions of the postcava and its tributaries, as found in the adult. *Anat Rec* 1920; 20:1-29.
- [11] Ginaldi S, Chuang VP & Wallace S. Absence of hepatic segment of the inferior vena cava with azygous continuation. *J Comput Assist Tomogr* 1980; 4:112-114.
- [12] Schultz CL, Morrison S & Bryan PJ. Azygous continuation of the inferior vena cava: demonstration by NMR imaging. *J Comput Assist Tomogr* 1984; 8:774-776.
- [13] Mazzucco A, Bortolotti U, Stellin G & Galucci V. Anomalies of the systemic venous return: a review. *J Card Surg* 1990; 5:122-133.
- [14] Haswell DM, Berrigan TJ, Jr. Anomalous inferior vena cava with accessory hemiazygos continuation. *Radiology* 1976; 119:51-54.
- [15] Geley TE, Unsinn KM, Auckenthaller TM, Fink CJ & Gassner I. Azygos continuation of the inferior vena cava in pediatric patients: sonographic demonstration of the renal artery ventral to the azygos vein as a clue to diagnosis. *Am J Roentgenol* 1999; 172:1659-1662.
- [16] Milner LB, Marchan R. Complete absence of the inferior vena cava presenting as a paraspinous mass. *Thorax* 1980; 35:798
- [17] Dougherty MJ, Calligaro KD, DeLaurentis DA. Congenitally absent inferior vena cava presenting in adulthood with venous stasis and ulceration: a surgically treated case. *J Vasc Surg* 1996; 23:141
- [18] Debing E, Tielemans Y, Jolie E & Van den Brande P. Congenital absence of inferior vena cava. *Eur J Vasc Surg* 1993; 7:201-203.
- [19] D'Archambeau O, Verguts L & Myle J. Congenital absence of the inferior vena cava. *J Belge Radiol* 1990; 73:516-517.
- [20] Bass JE, Redwine MD, Kramer LA & Harris JH, Jr. Absence of the infrarenal inferior vena cava with preservation of the suprarenal segment as revealed by CT and MR venography. *Am J Roentgenol* 1999; 172:1610-1612.

- [21] Mavrakanas T, Bounameaux H. The potential role of new oral anticoagulants in the prevention and treatment of thromboembolism. *Pharmacology & Therapeutics* 130 (2011) 46–58

IntechOpen

IntechOpen



Deep Vein Thrombosis

Edited by Dr. Gregory Cheng

ISBN 978-953-51-0225-0

Hard cover, 184 pages

Publisher InTech

Published online 07, March, 2012

Published in print edition March, 2012

This book provides a comprehensive review of deep vein thrombosis. There are chapters on risk factors for DVT, post thrombotic syndrome and its management, vena cava malformation as a new etiological factor and thrombosis in the upper limbs. DVT is usually seen in patients undergoing major surgeries. The guidelines for thrombo-prophylaxis in orthopaedic patients, radical pelvic surgeries, laparoscopic operations and risks versus benefits in regions with a low prevalence of DVT are thoroughly addressed. Cancer and its treatment are recognized risk factors for VTE and extended prophylaxis in ambulatory cancer patients is reviewed. The role of imaging and endovascular therapies in acute DVT, hypercoagulability in liver diseases and the challenges in developing countries are discussed.

How to reference

In order to correctly reference this scholarly work, feel free to copy and paste the following:

Massimiliano Bianchi, Lorenzo Faggioni, Virna Zampa, Gina D'Errico, Paolo Marraccini and Carlo Bartolozzi (2012). Vena Cava Malformations as an Emerging Etiologic Factor for Deep Vein Thrombosis in Young Patients, Deep Vein Thrombosis, Dr. Gregory Cheng (Ed.), ISBN: 978-953-51-0225-0, InTech, Available from: <http://www.intechopen.com/books/deep-vein-thrombosis/vena-cava-malformations-as-a-new-etilogic-factor-for-deep-vein-thrombosis-in-young-patients->

INTECH
open science | open minds

InTech Europe

University Campus STeP Ri
Slavka Krautzeka 83/A
51000 Rijeka, Croatia
Phone: +385 (51) 770 447
Fax: +385 (51) 686 166
www.intechopen.com

InTech China

Unit 405, Office Block, Hotel Equatorial Shanghai
No.65, Yan An Road (West), Shanghai, 200040, China
中国上海市延安西路65号上海国际贵都大饭店办公楼405单元
Phone: +86-21-62489820
Fax: +86-21-62489821

© 2012 The Author(s). Licensee IntechOpen. This is an open access article distributed under the terms of the [Creative Commons Attribution 3.0 License](https://creativecommons.org/licenses/by/3.0/), which permits unrestricted use, distribution, and reproduction in any medium, provided the original work is properly cited.

IntechOpen

IntechOpen