

# We are IntechOpen, the world's leading publisher of Open Access books Built by scientists, for scientists

6,900

Open access books available

186,000

International authors and editors

200M

Downloads

Our authors are among the

154

Countries delivered to

TOP 1%

most cited scientists

12.2%

Contributors from top 500 universities



WEB OF SCIENCE™

Selection of our books indexed in the Book Citation Index  
in Web of Science™ Core Collection (BKCI)

Interested in publishing with us?  
Contact [book.department@intechopen.com](mailto:book.department@intechopen.com)

Numbers displayed above are based on latest data collected.  
For more information visit [www.intechopen.com](http://www.intechopen.com)



# Osteoarthritis of the Trapeziometacarpal Joint (TMJ): A Review of the Literature

Oliver Boughton and Hugh Mackenzie  
*Department of Trauma and Orthopaedics, Kingston Hospital  
 United Kingdom*

## 1. Introduction

Osteoarthritis (OA) of the base of the thumb is a common, painful and debilitating condition. It is more common in women and most commonly presents in Caucasian women in their late forties (Wilson and Bossley, 1983). It affects approximately 16-20% of women over 45 years old and 6% of men over this age (Bettinger et al., 2001). It is the site most frequently operated on in the upper extremity for primary osteoarthritis. (Pellegrini, 2005). Pain is the main presenting symptom. It is often brought on by writing, by opening jars and using the hand for a long time, particularly in pinching movements and there is difficulty in performing these activities. The patients often have weakness due to the pain that may affect their ability to work, perform activities of daily living and follow leisure pursuits. They may also have an adduction deformity of their thumb. Signs include tenderness over the carpometacarpal joint at the base of the thumb, thenar wasting, reduced pinch grip strength and crepitus on moving the thumb (Wilson and Bossley, 1983; Gwynne-Jones et al., 2006).

The severity of basal thumb osteoarthritis can be graded according to the Eaton stages. Eaton Stage I basal thumb osteoarthritis indicates joint pain and symptoms but no joint space-narrowing or cartilage degeneration shown on X-ray. Eaton stage II is classified as joint space narrowing seen on X-ray with osteophytes present of less than 2mm in size. An osteophyte is a small outgrowth of bone which occurs at joints in association with degeneration of joint cartilage. Eaton Stage III osteoarthritis is characterised by osteophytes of greater than 2mm in size being present on x-ray and significant destruction of the joint. In stage IV basal thumb OA there is significant degeneration of the scaphotrapezial joint in addition to the trapeziometacarpal joint (Eaton et al., 1985).

## 2. The anatomy of the basal joint of the thumb

The basal joint of the thumb is formed by the articulation between the trapezium bone proximally and the first metacarpal bone distally. It is therefore called the trapeziometacarpal joint or the carpometacarpal joint of the thumb. The trapezium, a bone of the second carpal row, articulates with the scaphoid bone proximally, the trapezoid medially and the bases of the first and second metacarpal bones distally. The trapezium is on the palmar and radial side of the wrist. It is angled such that it projects towards the palmar side. It angles the first metacarpal bone (the most proximal bone of the thumb) radially and in a palmar direction. The articular facet of the trapezium with the first

metacarpal is angled 35 degrees towards the palmar direction and 20 degrees radially. This results in the neutral position of the thumb being 35 degrees in a palmar direction and 20 degrees in a radial direction (Zancolli, 1979).

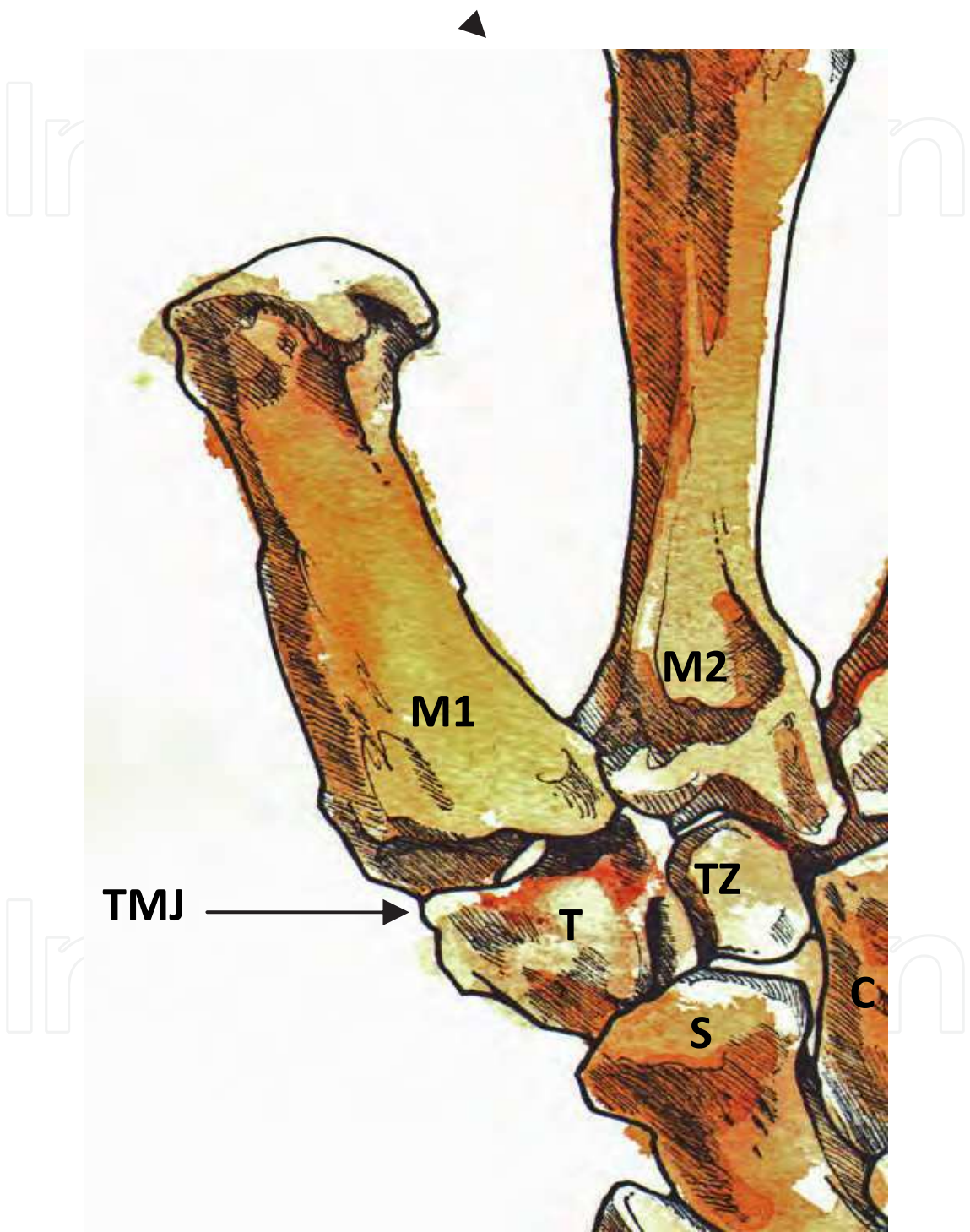


Fig. 1. Illustration of the trapeziometacarpal joint (TMJ) of the left thumb. The first (M1) and second (M2) metacarpals, the trapezium (T), the trapezoid (TZ), the scaphoid (S) and the capitate (C) bones are illustrated. Illustration courtesy of Mr Donald Sammut, Consultant Hand Surgeon, The Hand Clinic, Windsor.

The trapeziometacarpal joint is a saddle joint with wide mobility due to extensive articular surfaces. It is called a saddle joint because the trapezial articular surface is concave in a dorsopalmar direction and convex in the radioulnar direction. The first metacarpal base is complimentary to the trapezial articular surface. The trapezium is compared to the saddle of a horse and the base of the first metacarpal bone may be compared to the horse rider as it is mobile. It is a synovial joint and is surrounded by a joint capsule that is strengthened by three ligaments. The most important of these is the ulnar beak ligament. This is a very thick and wide ligament that runs from the crest of the trapezium and attaches to the ulnar side of the base of the first metacarpal. This ligament maintains the stability of the thumb and is tense in abduction of the first metacarpal. The other two ligaments are less widely described as they are believed to be less important in the stability of the thumb. The radial ligament originates from the radial side of the trapezium and travels dorsally and medially to attach to the dorsal tubercle of the first metacarpal. A palmar wide ligament is also sometimes described (Zancolli, 1979; Zancolli and Cozzi, 1992; Standring, 2008). A wide range of movement is permitted at the trapeziometacarpal joint: flexion, extension, abduction, adduction, opposition and reposition.

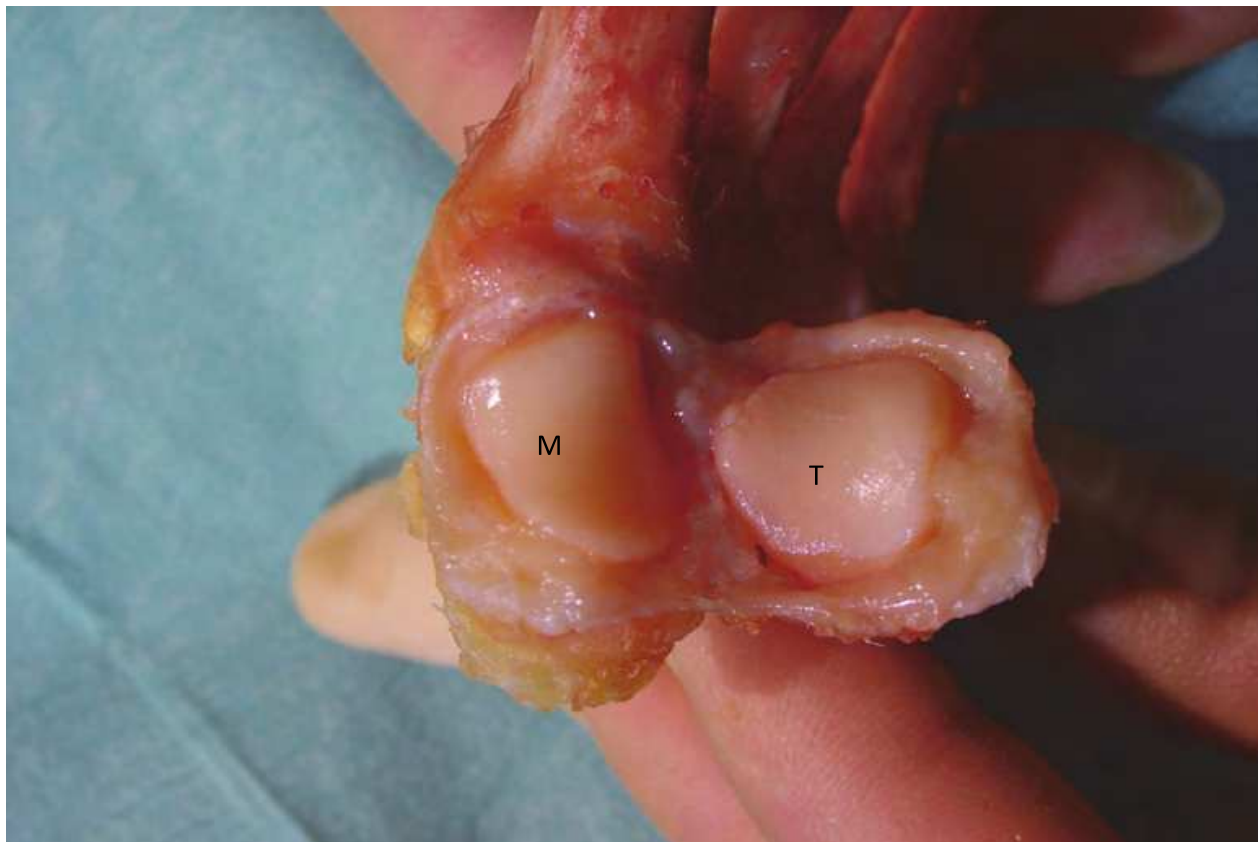


Fig. 2. Dissection of the trapeziometacarpal joint showing, on the left, the base of the first metacarpal (M) and, on the right, the articular surface of the trapezium (T). Dissection courtesy of Mr Donald Sammut, Consultant Hand Surgeon, The Hand Clinic, Windsor.



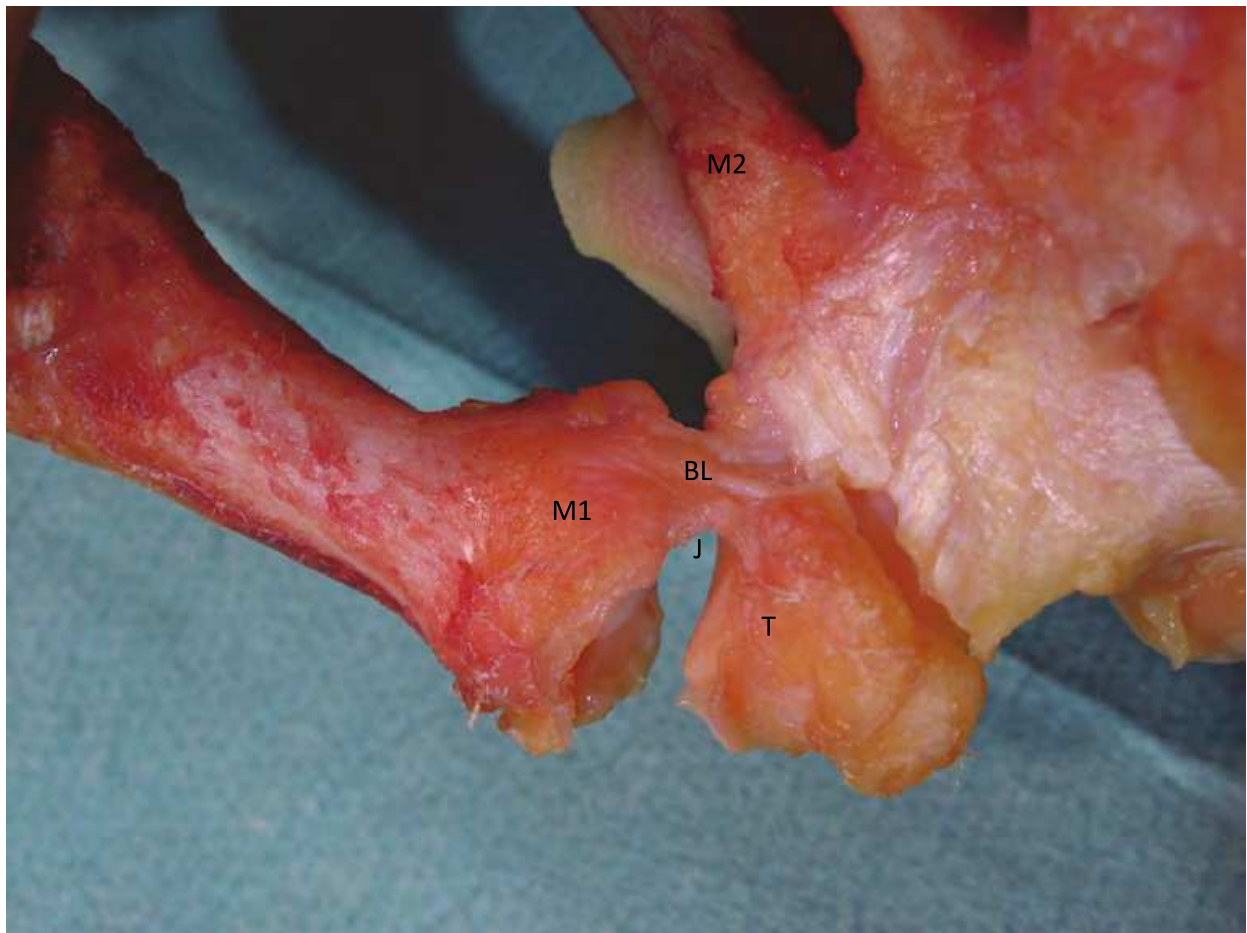


Fig. 3. Dissection displaying the strong ulnar beak ligament (BL) of the trapeziometacarpal joint. Traction is applied to the first metacarpal to open and display the joint (J). The base of the first metacarpal (M1) is on the left side of the joint. The articular surface of the trapezium (T) is on the right side of the joint in this image. The base of the second metacarpal is also seen (M2). Dissection image courtesy of Mr Donald Sammut, Consultant Hand Surgeon, The Hand Clinic, Windsor.

### 3. Pathophysiology of osteoarthritis of the base of the thumb

Many authors have described theories on how osteoarthritis of the base of the thumb occurs. There is often degeneration of the ulnar beak ligament due to recurrent stress and overuse which leads to ligament and joint instability. With increased laxity there may be abnormal translation of the first metacarpal on the trapezium. This can result in excessive shear forces between the joint surfaces (Tomaino, 2000; Kapandji TG and Kapandji AI, 1993). In addition there is articular degeneration. This may be secondary to instability which leads to joint surface incongruity. The incongruity may result in areas of high contact stress developing in the joint. This then causes cartilage erosion and the symptoms and signs of osteoarthritis (Bettinger et al., 2001). It has been shown that articular degeneration occurs on the palmar side first and gradually progresses to dorsoradial cartilage degeneration in the later stages of osteoarthritis of the joint (Pellegrini, 2005; Hobby et al., 1998). Radiological studies looking at the angle of the trapezium compared to the second metacarpal have shown that there is an increased radial trapezial tilt in Eaton stages III and IV compared to Eaton stages

I and II osteoarthritis of the base of the thumb (Bettinger et al., 2001; Kapandji AI and Heim, 2002). Studies have also shown accessory tendons of abductor pollicis longus inserting into the radial side of the metacarpal base in some people. These pull the metacarpal base radially and hence have a tendency to cause joint instability and may contribute to the development of osteoarthritis (Zancolli and Cozzi, 1992).

#### 4. Treatment of trapeziometacarpal osteoarthritis

Trapeziometacarpal osteoarthritis may be treated conservatively with non-steroidal anti-inflammatory drugs (NSAIDs) first. If these are ineffective at symptom control a splint can be used which holds the thumb in abduction preventing the movements of adduction and reposition. This ensures that the metacarpal base is covered by the trapezium and joint stability is increased, reducing metacarpal subluxation and wear of the joint cartilage (Zancolli and Cozzi, 1992). Depending on the severity of the symptoms the splint may be effective if just worn nocturnally (Goubau et al., 2007; Hobby et al., 1998).

For temporary relief of symptoms, lignocaine and steroid injections into the joint are effective. However, repeated injections into the joint are harmful to the joint itself and surrounding tissue. As well as accelerating joint damage, if the steroid leaks into the surrounding tissue it can lead to subcutaneous fat necrosis. This loss of the fatty tissue around the thumb leads to an undesirable cosmetic outcome.

If, despite conservative measures, pain or deformity interferes with daily activities such as holding a key or gripping an object, surgical treatment is advocated. As already mentioned, the trapeziometacarpal joint is the most commonly surgically reconstructed joint for osteoarthritis in the upper limb (Pellegrini, 2005; Tomaino, 2000). The first operation which can be considered for early osteoarthritis is reconstruction of the ulnar beak ligament. This is achieved using a tendon slip from the flexor carpi radialis tendon. As it does not involve any of the articular surfaces it is reserved for patients with joint laxity without appreciable degenerative changes. Thumb metacarpal osteotomy is another operation which can be effective in early disease. It transfers load bearing from the worn volar cartilage to the more intact dorsal articular surface. As well as giving symptom relief it also slows the progression to more severe osteoarthritis (Hobby et al., 1998). Another more experimental method of reconfiguring the joint alignment is wedge osteotomy of the trapezium. This realigns the trapezial saddle reducing metacarpal subluxation. However, studies are in their early stages and evidence for this procedure is limited (Kapandji AI and Heim, 2002).

For more severe disease with significant degenerative changes the surgical options include trapeziectomy, arthrodesis and total joint arthroplasty. Trapeziectomy is associated with good pain relief but can lead to weakness and instability lasting several months so is often reserved for Eaton Stages III and IV osteoarthritis (Hobby et al., 1998; Gwynne-Jones et al., 2006; Wilson and Bossley, 1983). Trapeziectomy may be performed in isolation or in combination with tendon sling interposition or ligament reconstruction. However, the outcome of these operations appears to be equivalent (Davis et al 2004).

Arthrodesis is a less frequently performed procedure in the trapeziometacarpal joint than other joints in the hand. It is associated with increased joint stability but longer immobilisation and an incidence of non-union (Hobby et al., 1998). It leaves a strong but rather immobile thumb.

Total joint arthroplasty has been a less successful procedure in this joint. There is frequent loosening of the components, implant fracture and an increased infection rate. Revision

procedures of total joint replacements of this joint are common (Lanzetta and Foucher, 1995; Wilson and Bossley, 1983).

The choice of surgical procedure for trapeziometacarpal arthritis is still controversial. There is limited evidence as to which procedure produces optimal results whilst limiting complications. Therefore, randomised clinical trials are awaited comparing these surgical techniques (Vermeulen et al, 2011).

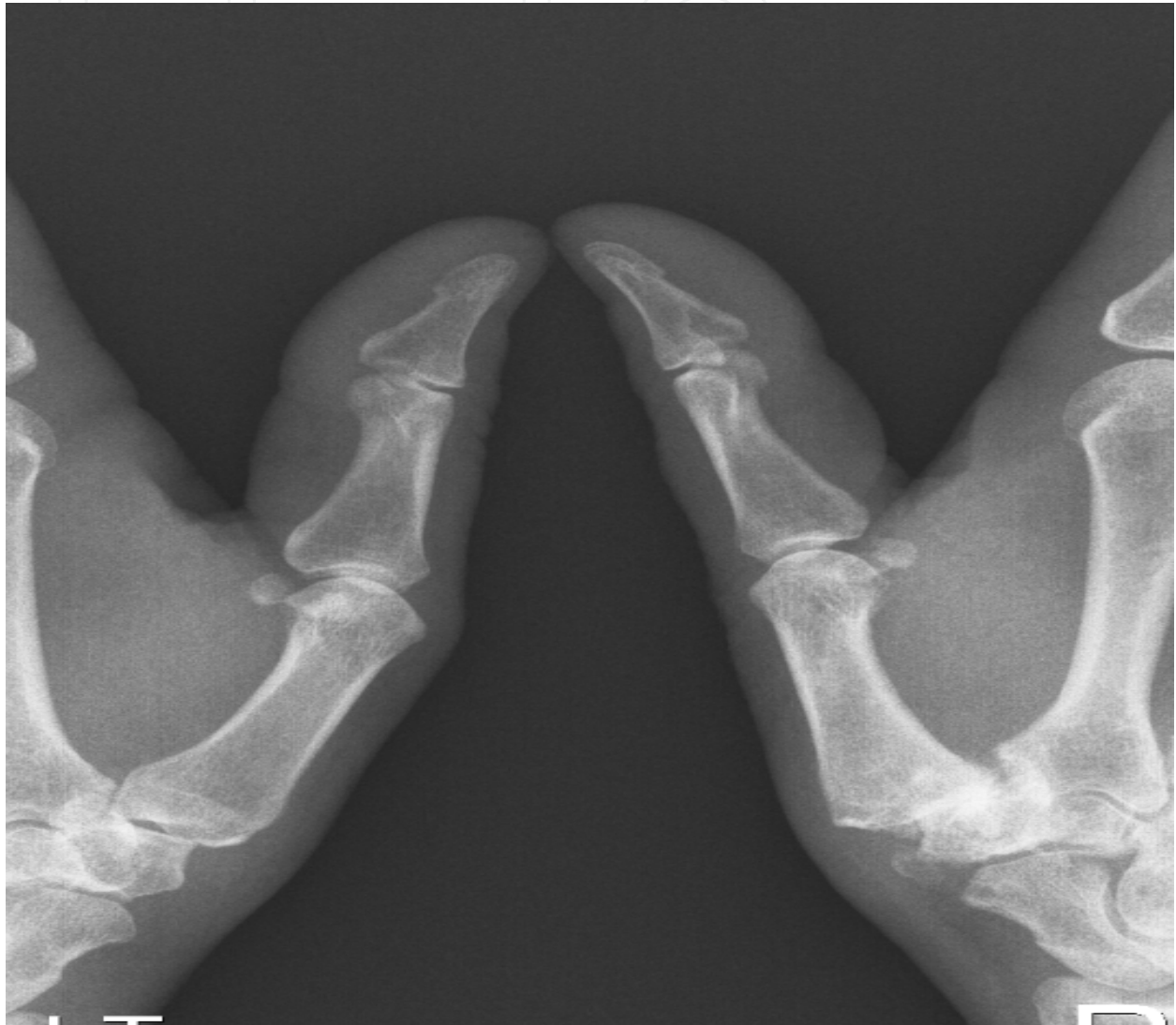

Fig. 4. Plain radiograph showing Eaton Stage III osteoarthritis of the trapeziometacarpal joint of the right thumb

## 5. Conclusion

Trapeziometacarpal arthritis is a common, painful and debilitating condition. The complex anatomy allows for an extensive range of movement. However, it is this inherent instability within the joint that leads to wear of the articular cartilage and osteoarthritis.

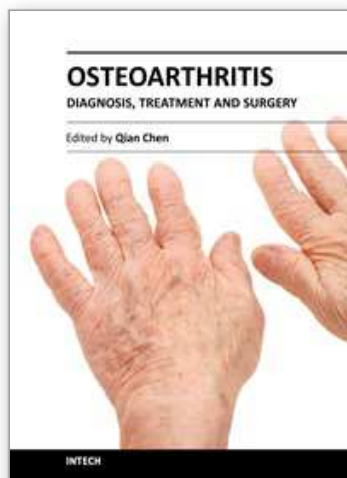
Once conservative measures have failed there are a wide variety of surgical treatment options.

## 6. References

- Bettinger PC, Linscheid RL, Cooney WP 3<sup>rd</sup>, An KN (2001). Trapezial tilt: a radiographic correlation with advanced trapeziometacarpal joint arthritis. *Journal of Hand Surgery - American Volume*. 26(4):692-7
- Davis TR, Brady O, Dias JJ (2004). Excision of the trapezium for osteoarthritis of the trapeziometacarpal joint: a study of the benefit of ligament reconstruction or tendon interposition. *J Hand Surg [Am]*. Volume 29(6):1069-77
- Eaton RG, Glickel SZ, Littler JW (1985). Tendon interposition arthroplasty for degenerative arthritis of the trapeziometacarpal joint of the thumb. *Journal of Hand Surgery - American Volume*. 10(5):645-54
- Eaton RG, Glickel SZ (1987). Trapeziometacarpal osteoarthritis. Staging as a rationale for treatment. *Hand Clinics*. 3(4):455-71
- Goubau JF, Kerckhove D, Berghs B (2007). [Addition-subtraction osteotomy combined with ligamentoplasty for symptomatic trapezial dysplasia with instability]. [French] Traitement des dysplasies trapeziennes symptomatiques instables par osteotomie d'addition-soustraction et ligamentoplastie. *Chirurgie de la Main*. 26(1):26-30
- Gwynne-Jones DP, Penny ID, Sewell SA, Hughes TH (2006). Basal thumb metacarpal osteotomy for trapeziometacarpal osteoarthritis. *Journal of Orthopaedic Surgery*. 14(1):58-63
- Hobby JL, Lyall HA, Meggitt BF (1998). First metacarpal osteotomy for trapeziometacarpal osteoarthritis. *Journal of Bone & Joint Surgery - British Volume*. 80(3):508-12
- Holmberg J, Lundborg G (1996). Osteotomy of the first metacarpal for osteoarthrosis of the basal joints of the thumb. *Scandinavian Journal of Plastic & Reconstructive Surgery & Hand Surgery*. 30(1):67-70
- Kapandji AI, Heim UF (2002). [Reorientation osteotomy of the trapezial saddle]. [French] L'osteotomie de reorientation de la selle trapezienne. *Chirurgie de la Main*. 21(2):124-33
- Kapandji TG, Kapandji AI (1993). [New radiologic data on the trapezo-metacarpal joint. The results of 330 cases]. [French] Nouvelles donnees radiologiques sur la trapezo-metacarpienne. Resultats sur 330 dossiers. *Annales de Chirurgie de la Main et du Membre Superieur*. 12(4):263-74
- Lanzetta M, Foucher G (1995). A comparison of different surgical techniques in treating degenerative arthrosis of the carpometacarpal joint of the thumb. A retrospective study of 98 cases. *Journal of Hand Surgery - British Volume*. 20(1):105-10
- Pellegrini VD Jr (2005). The ABJS 2005 Nicolas Andry Award: osteoarthritis and injury at the base of the human thumb: survival of the fittest? *Clinical Orthopaedics & Related Research*. 438:266-76
- Standring S (2008). *Gray's Anatomy: The Anatomical Basis of Clinical Practice*, 40th Edition. Churchill Livingstone Elsevier. p 857-898
- Tomaino MM (2000). Treatment of Eaton stage I trapeziometacarpal disease with thumb metacarpal extension osteotomy. *Journal of Hand Surgery - American Volume*. 25(6):1100-6
- Vermeulen GM, Slijper H, Feitz R, Hovius SE, Moojen TM, Selles RW (2011). Surgical management of primary thumb carpometacarpal osteoarthritis: a systematic review. *J Hand Surg Am*. 36(1):157-69.



- Wilson JN (1973). Basal osteotomy of the first metacarpal in the treatment of arthritis of the carpometacarpal of the thumb. *The British Journal of Surgery*. 60:854-858
- Wilson JN, Bossley CJ (1983). Osteotomy in the treatment of osteoarthritis of the first carpometacarpal joint. *Journal of Bone & Joint Surgery - British Volume*. 65(2):179-81
- Zancolli E (1979). *Structural and Dynamic Bases of Hand Surgery*, 2<sup>nd</sup> Edition. J.B. Lippincott Company
- Zancolli EA, Cozzi EP (1992). *Atlas of Surgical Anatomy of the Hand*. Churchill Livingstone.



## **Osteoarthritis - Diagnosis, Treatment and Surgery**

Edited by Prof. Qian Chen

ISBN 978-953-51-0168-0

Hard cover, 404 pages

**Publisher** InTech

**Published online** 02, March, 2012

**Published in print edition** March, 2012

Osteoarthritis is one of the most debilitating diseases affecting millions of people worldwide. However, there is no FDA approved disease modifying drug specifically for OA. Surgery remains an effective last resort to restore the function of the joints. As the aging populations increase worldwide, the number of OA patients increases dramatically in recent years and is expected to increase in many years to come. This is a book that summarizes recent advance in OA diagnosis, treatment, and surgery. It includes wide ranging topics from the cutting edge gene therapy to alternative medicine. Such multifaceted approaches are necessary to develop novel and effective therapy to cure OA in the future. In this book, different surgical methods are described to restore the function of the joints. In addition, various treatment options are presented, mainly to reduce the pain and enhance the life quality of the OA patients.

### **How to reference**

In order to correctly reference this scholarly work, feel free to copy and paste the following:

Oliver Boughton and Hugh Mackenzie (2012). Osteoarthritis of the Trapeziometacarpal Joint (TMJ): A Review of the Literature, Osteoarthritis - Diagnosis, Treatment and Surgery, Prof. Qian Chen (Ed.), ISBN: 978-953-51-0168-0, InTech, Available from: <http://www.intechopen.com/books/osteoarthritis-diagnosis-treatment-and-surgery/osteoarthritis-of-the-trapeziometacarpal-joint-tmj-a-review-of-the-literature>

**INTech**  
open science | open minds

### **InTech Europe**

University Campus STeP Ri  
Slavka Krautzeka 83/A  
51000 Rijeka, Croatia  
Phone: +385 (51) 770 447  
Fax: +385 (51) 686 166  
[www.intechopen.com](http://www.intechopen.com)

### **InTech China**

Unit 405, Office Block, Hotel Equatorial Shanghai  
No.65, Yan An Road (West), Shanghai, 200040, China  
中国上海市延安西路65号上海国际贵都大饭店办公楼405单元  
Phone: +86-21-62489820  
Fax: +86-21-62489821

© 2012 The Author(s). Licensee IntechOpen. This is an open access article distributed under the terms of the [Creative Commons Attribution 3.0 License](https://creativecommons.org/licenses/by/3.0/), which permits unrestricted use, distribution, and reproduction in any medium, provided the original work is properly cited.

IntechOpen

IntechOpen