

We are IntechOpen, the world's leading publisher of Open Access books Built by scientists, for scientists

6,900

Open access books available

185,000

International authors and editors

200M

Downloads

Our authors are among the

154

Countries delivered to

TOP 1%

most cited scientists

12.2%

Contributors from top 500 universities



WEB OF SCIENCE™

Selection of our books indexed in the Book Citation Index
in Web of Science™ Core Collection (BKCI)

Interested in publishing with us?
Contact book.department@intechopen.com

Numbers displayed above are based on latest data collected.
For more information visit www.intechopen.com



Radiation Therapy in the Management of Meningiomas

Frederik Vernimmen
University College Cork
Ireland

1. Introduction

Although most meningiomas are benign, they have a surprisingly wide spectrum of clinical and histological characteristics. The WHO classification attempts to better predict the spectrum of clinical characteristics with a histological grading system based on statistically significant clinical-pathological correlations (1). There are three types of meningiomas in this classification; benign (WHO grade I), atypical (WHO grade II) and anaplastic (malignant; WHO grade III). Because the majority of meningiomas, 80%, fall under grade I (1), they are the ones on which the most literature is available. For grade I lesions, complete surgical removal results in a permanent cure in a high percentage of patients. However the anatomic localization of meningiomas, such as at the skull base, can make complete surgery difficult, and gross total resection only, results in control rates that vary from 44% to 90% and carry a high risk of neurologic morbidity. When surgery is incomplete, the recurrence rate is high, and patients suffer long-term morbidity, decreased survival, and the risk of histological dedifferentiation (2-7).

Radiation is well established as a treatment modality to control meningiomas, and can be used for: a) irresectable lesions, b) in patients to whom the risks of a resection are unacceptable, c) inoperable patients, and d) for recurrence or incomplete resection (8-13).

1.1 Diagnosis

The diagnosis usually comes after investigations for neurological complaints, but is also regularly made during imaging of the brain for other reasons. The diagnosis is finalized by the obtaining of histology. Offering the patient surgery for the sole purpose of obtaining histology can sometimes be debatable. This is particularly the case in skull base meningiomas, where the chances of complete removal without additional morbidity are slim and when no debulking is required. In such a scenario it is acceptable to go by the classic clinical picture and the typical radiological characteristics of benign meningiomas, to make the diagnosis (14). However good clinical judgement is required in order to suspect the possibility of a more sinister type of lesion.

2. Radiation therapy

Irradiation is the deposition of energy (dose) in the target by various radiation modalities using a variety of irradiation techniques. This dose is expressed in units of Gray (Gy), and

the beam energy used to deliver the dose is expressed as Mega Volts (MV). It is the absorption of this energy by the cell structures that causes the individual cell damage resulting in control of the disease. The cell damage is on the DNA of the cells. This damage is either direct or indirect, ionizing the atoms which make up the DNA chain. Indirect ionization happens as a result of the ionization of water molecules, forming free radicals, notably hydroxyl radicals. These are “chemically aggressive” compounds which when formed in close proximity to the DNA molecules damage the DNA. Most of the radiation effect is through these free radicals. They cause single and double strand breaks in the DNA. Cells have mechanisms for repairing DNA damage, but double-stranded DNA breaks are difficult to repair and are the most significant way by which cell death occurs. Cancer cells generally are undifferentiated and stem cell-like, they reproduce more, and have a diminished ability to repair sub-lethal damage compared to most healthy differentiated cells. This DNA damage is then passed on through cell division, accumulating damage to the cancer cell's DNA, and causing them to die or reproduce more slowly.

One of the major limitations of photon radiation therapy is that the cells of solid tumors become deficient in oxygen. Solid tumors can outgrow their blood supply, causing a low-oxygen state known as hypoxia. Oxygen is a potent radio sensitizer, increasing the effectiveness of a given dose of radiation by forming DNA damaging free radicals. Tumor cells in a hypoxic environment may be as much as 2 to 3 times more resistant to radiation damage than those in a normal oxygen environment. In the case of meningiomas, seeing that they are usually very vascular lesions this oxygen effect is not a major factor in their treatment with ionizing radiation.

Direct damage to cancer cell DNA occurs through high-LET (linear energy transfer) charged particles irradiation such as with proton, carbon or neon ions which have an antitumor effect which is independent of tumor oxygen supply because these particles act mostly via direct energy transfer usually causing double-stranded DNA breaks. Due to their relatively large mass, protons and other charged particles have little lateral side scatter in the tissue; the beam does not broaden much, hence stays focused on the tumor shape and delivers small dose side-effects to surrounding tissue. These particles can be charged to different levels of energy providing the required tissue penetration to reach the tumor. This reduces damage to healthy tissue between the charged particle radiation source and the tumor and sets a finite range for tissue damage after the tumor has been reached. No energy is deposited beyond the point of the calculated depth penetration saving normal tissue from the radiation effects.

2.1 Dose calculations

Before treatment, a CT scan is performed with the patients head immobilized by either a cast made from a thermoplastic material or by a stereotactic frame directly fixated to the patient's skull. The ability to import other images such as MRI scans into the planning system, a technique called image fusion, allows to identify the tumor and surrounding normal structures with great accuracy.

The delivery parameters of a prescribed dose are determined during treatment planning (part of dosimetry). Treatment planning is generally performed on dedicated computers using specialized treatment planning software. Depending on the radiation delivery

method, several beam angles may be used to sum the total necessary dose. The planner will try to design a plan that delivers a uniform prescription dose to the tumor and minimizes dose to surrounding healthy tissues.

2.2 Radiation equipment

2.2.1 Photon (gamma ray) therapy

A number of radiation therapy machines are available; the most commonly used are the one's using gamma rays (photons) to deliver the therapeutic dose. The Gamma Knife®, Cyberknife®, and the linear accelerator (Linac) fall in this category. In addition a small linear accelerator used in a rotational way around the patient (Tomotherapy) is also available.

With the *gamma knife*, multiple small static beams, each produced by individual Cobalt sources are directed to a fixed single spot or isocenter. This area of convergence of all the small beams can be placed in multiple locations within the target volume by moving the patient's head around with small movements of the head fixation mechanism.

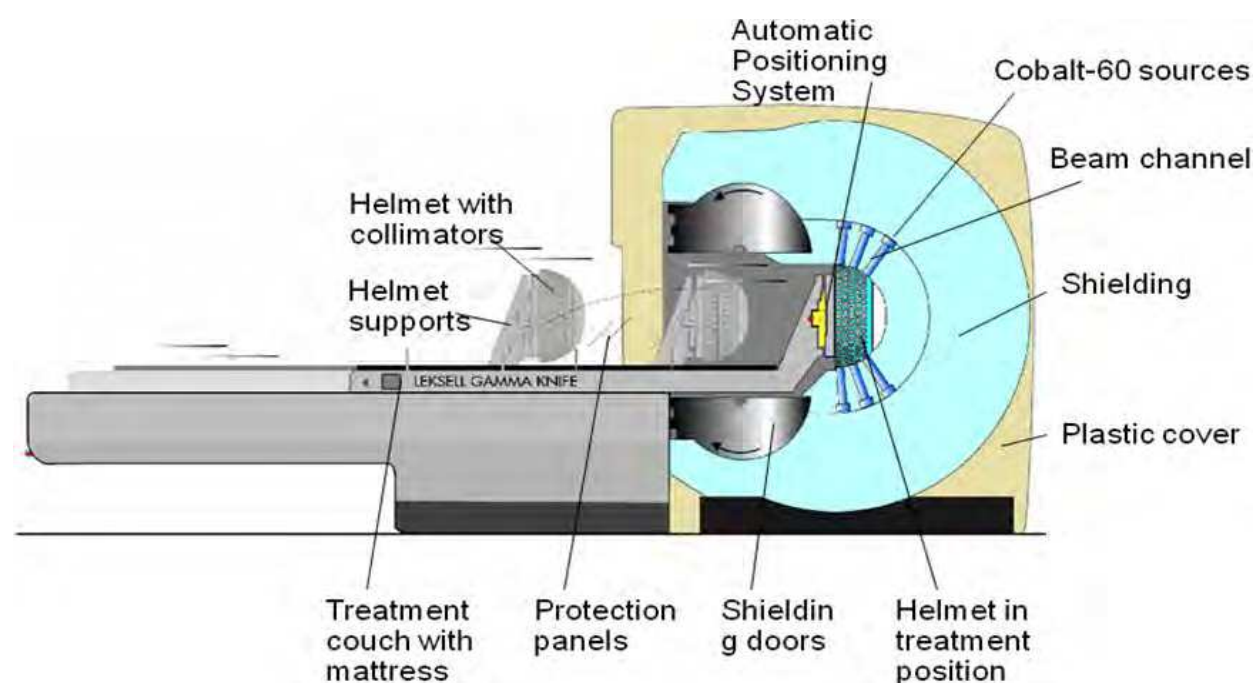


Fig. 1.

With the *linear accelerator* (Fig 2a) the beams are directed at an isocenter, which is in a fixed position in the treatment room and which can be placed in the target volume and shifted around if necessary by moving the couch onto which the patient is lying. Rotation of the gantry, which produces the beam, around this isocenter, together with a couch rotation, provides for a number of individually shaped beams coming from different directions allowing full coverage of the target volume. For stereotactic irradiation additional beam collimation is provided by either a set of cones or by a micro multileaf collimator (Fig 2b). These devices are not part of the standard equipment and have to be acquired separately.

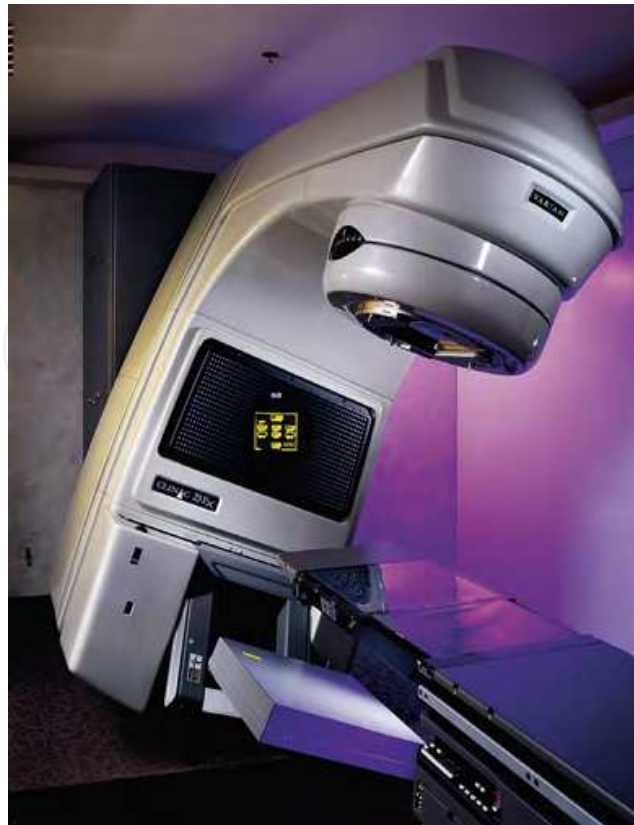

Fig. 2a.

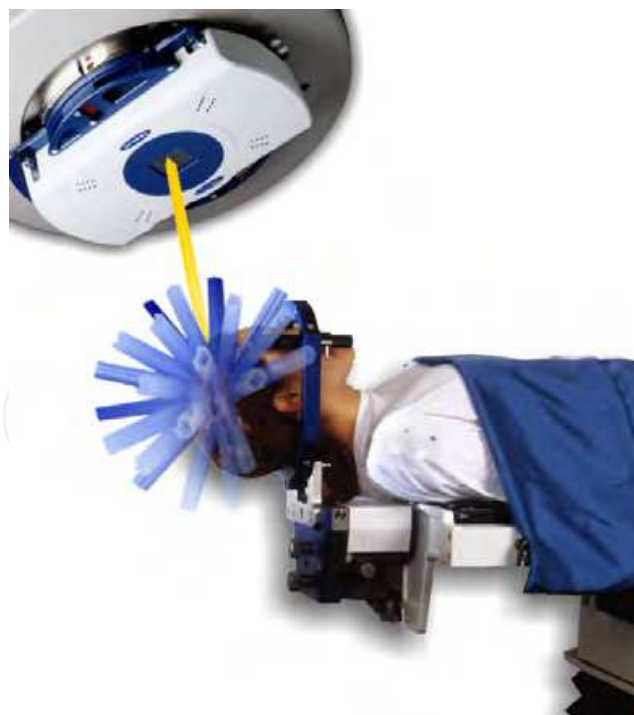

Fig. 2b.

A large body of literature exists for both these techniques in the management of meningiomas

The *Cyberknife*® uses a small linear accelerator supported by a robot arm. This in conjunction with the use of a robotic couch supporting the patient allows for numerous small beams to come in from a large variety of angles. The “cross firing” of these multiple small beams through the target results in the full dose been given to the whole target volume.

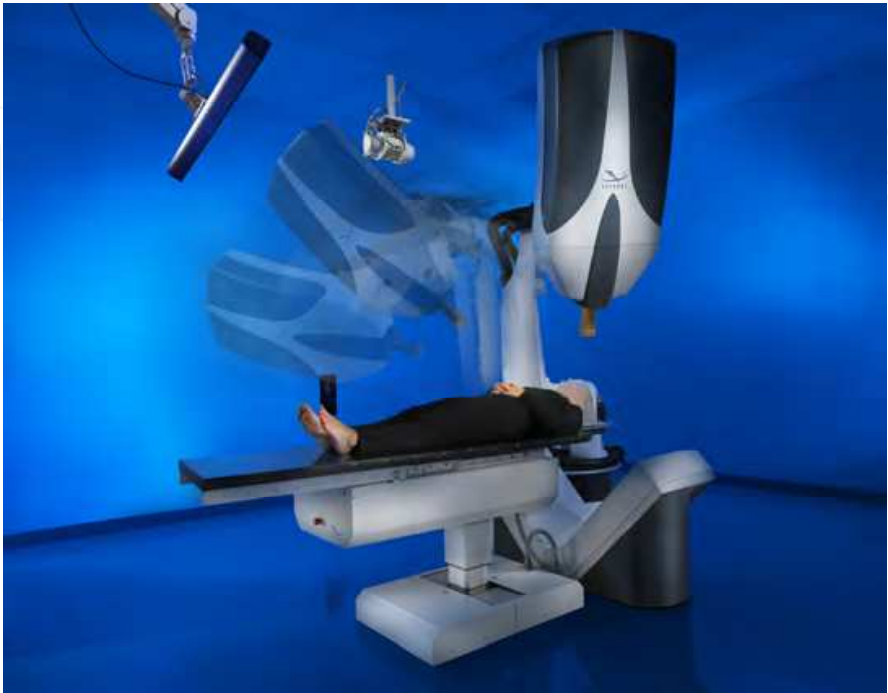

Fig. 3.

Tomotherapy® is very similar in its concept to the use of helical CT-scanning in diagnostic imaging. A narrow beam is rotating through the target whilst the couch onto which the patient is lying is moving perpendicular to the plane of rotation. This technique is mainly used to deliver intensity modulated radiotherapy (IMRT) and limited literature is available concerning its use for intracranial meningiomas (15).

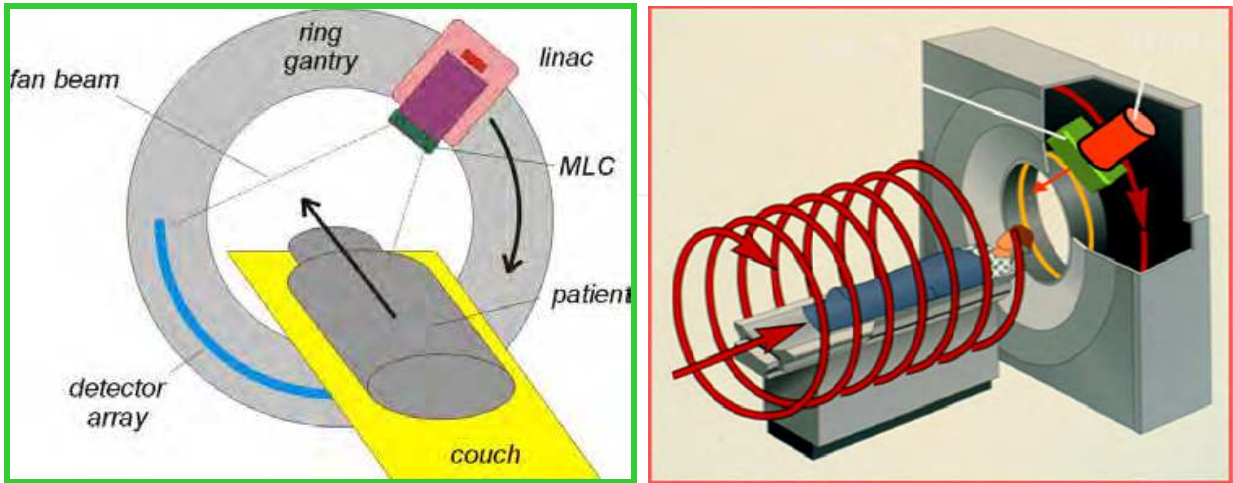


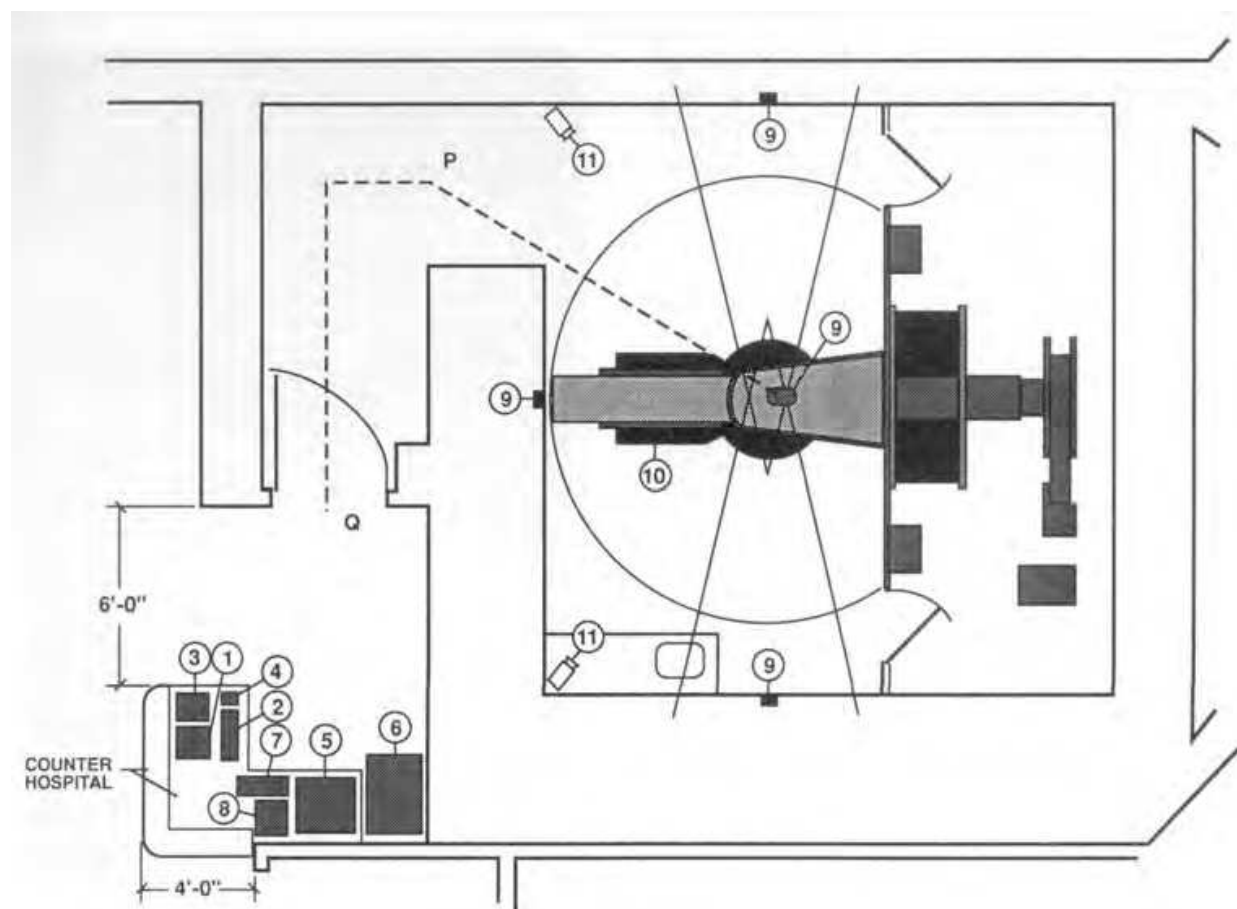
Fig. 4.

All the above techniques use photons, also called gamma rays, to deliver the dose.

The radiation equipment is housed in a treatment unit bunker, whose purpose is to protect the staff and members of the public from the radiation. A typical bunker for a linear accelerator is illustrated. Requirements for a bunker include walls and a roof both of a thickness offering sufficient protection, high density concrete without joints or air pockets and a 'maze' design to reduce the radiation dose reaching the door of the bunker or vault.

2.2.2 Bunker

The wall and roof thickness is determined by the energy (the penetration power) of the radiation. For cobalt sourced radiation the concrete thickness should be approximately 80 cm. For linear accelerators the thickness varies between 2 and 3 meters for covering the range of low, medium and high-energy linear accelerators.



2.2.3 Charged particle therapy

Delivering the required dose with charged particle beams, mainly proton beams, is also possible. A proton beam is produced by a cyclotron (Fig 5b) or a synchrotron and has particular physical characteristics (the Bragg peak) which make it theoretically a better radiation modality in and around sensitive structures such as the brain as there is no dose distal to the peak and a lower dose proximal to the target (Fig 5a).

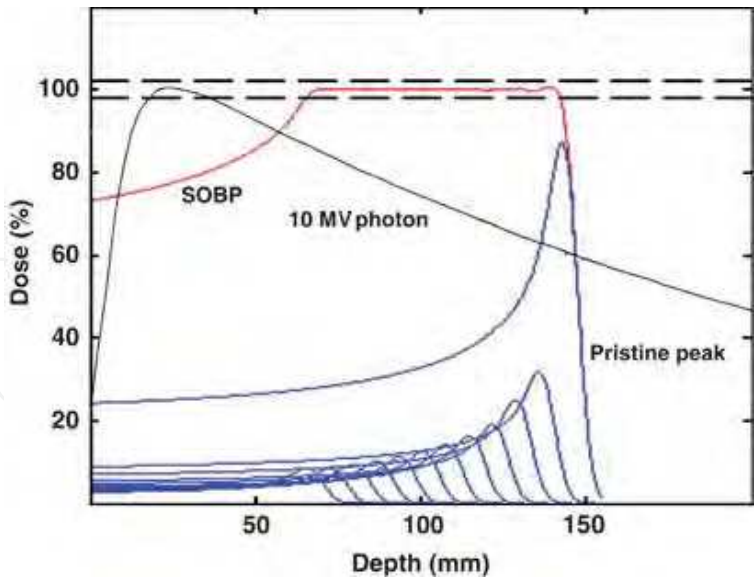


Fig. 5a.

The primary narrow beam leaving the cyclotron or synchrotron is scattered to provide a beam of sufficient size for clinical use. Because the peak is usually too narrow to cover the length of the target volume along the beam axis, this peak needs to be spread out over the full distance of the target in order to cover it with the full dose. This dose delivery technique is referred to as a Spread Out Bragg Peak (SOBP) (16,17). In more and more centres, the primary proton beam is not scattered, but used in a spot scanning mode, whereby the target volume is covered by multiple scanned “spots”. This technique allows for a better dose distribution, but is more complex to deliver and to verify. The availability of proton therapy facilities worldwide is however still limited. The availability of other charged particle beams, such as Carbon ions and Helium ions is even more limited. They have the additional advantage over protons in that they cause more radiobiological damage per unit of dose. In other words their Radiobiological Effect (RBE) is higher (18).




Fig. 5b.

2.3 Irradiation techniques

Technically the radiation can be administered in a variety of ways:

- a. *Conventional 3 dimensional (3-D) way.* The patient's head is immobilized by a cast and images are acquired for planning. A number of beams coming from various angles are directed at the target, but the overall geometric accuracy of the treatment set up is less than for a stereotactic technique, and the dose gradient is also less steep. The 3-D technique is however available in most radiotherapy departments.
- b. *Intensity-modulated radiation therapy (IMRT)* is an advanced type of high-precision radiation that is the next generation of 3DCRT. IMRT also improves the ability to conform the treatment volume to concave tumor shapes, for example when the tumor is wrapped around a vulnerable structure such as the spinal cord or a major organ or blood vessel. The pattern of radiation delivery is determined using highly tailored computing applications to perform optimization and treatment simulation. The radiation dose is consistent with the 3-D shape of the tumor by controlling, or modulating, the radiation beam's intensity. The radiation dose intensity is elevated near the gross tumor volume while radiation among the neighboring normal tissue is decreased or avoided completely. The customized radiation dose is intended to maximize tumor dose while simultaneously protecting the surrounding normal tissue. This may result in better tumor targeting, lessened side effects, and improved treatment outcomes than even 3DCRT. This technique is finding its way into stereotactic radiation
- c. *Stereotactically;* this is a technique for precisely directing the beams of radiation in three planes using x-y-z coordinates in order to target a specific locus in the head, with a geometric accuracy of ≤ 1 mm. This requires accurate immobilisation of the head with either a stereotactic frame fixed to the patient's skull or a well constructed cast, made of some form of thermo plastic material, completely encasing patient's head. With the immobilization device in place, MRI and CT-scan images are acquired for delineating the target and surrounding structures, and for the dose calculations, using specialized dose calculation software. The precise dose delivery along with the presence of very steep dose gradients in all three dimensions facilitates the treatment of target volumes to a high dose while maintaining the dose to the adjacent healthy tissue within the accepted tolerance levels. Careful verification of the target position by advanced imaging techniques is required prior to each radiation session. This technique requires additional infrastructure on top of the normal Linac equipment and is not always available in every radiotherapy department.

The technological progress in equipment is leading to an ever increasing overlap of these techniques.

2.4 Radiobiology

The linear quadratic model is the mathematical model that best describes the biological effect of radiation on cells (19). This biological effect can be expressed as a Biological Effective Dose (BED), and is given by the formula: $BED = \text{total dose} (1 + \text{dose per fraction} / \alpha\text{-}\beta)$. Various radiation schedules can be compared with each other by calculating their respective BED's. For this, the α/β value which is a constant for a very specific radiation effect on a specific type of tissue, needs to be known (20). Knowing the α/β value for a specific effect on a specific target

tissue is useful for the following reasons: 1) It allows for more accurate calculations of biological equivalent fractionation schedules; 2) The α/β value gives an indication of what sort of a fractionation schedule would be beneficial in terms of therapeutic gain; 3) It allows one to determine the minimum number of fractions required in order to keep a critical structure within tolerance when this critical structure is in close proximity to the target

For histological benign radiosurgical targets information on α/β ratios is very limited, but in general low α/β ratios have been assumed, based on the clinical and radiological observation that these targets are slow growing.

For radiological control of histological benign meningiomas (Grade I) this value has been estimated at 3.7 Gy (21). Normal tissue has an α/β in the range of 2-3 Gy (19). This small difference between the α/β values of normal surrounding tissue versus the target tissue theoretically allows for an increase in the differential radiation effect on both these tissues by increasing the number of fractions, this is called therapeutic gain (21,22,23,27). Most of this gain is achieved by going from 1 fraction to about 7-9 fractions and then flattens off going to 25-30 fractions.

3. Total dose/fractionation schedules

For a standard radiation course, the total dose is fractionated (spread out over time) for several important reasons. Fractionation allows normal cells time to recover, while tumor cells are generally less efficient in repair between fractions. Fractionation also allows tumor cells that were in a relatively radio-resistant phase of the cell cycle during one treatment to cycle into a sensitive phase of the cycle before the next fraction is given. Similarly, tumor cells that were chronically or acutely hypoxic (and therefore more radioresistant) may reoxygenate between fractions, improving the tumor cell kill. A typical fractionation schedule for adults is 1.8 to 2 Gy per day, five days a week, for 6 - 7 weeks, i.e. doses in the order of 60 - 70 Gy. For meningiomas, the radiation dose/fractionation schedules used vary. When the total dose is delivered in 1 single session (fraction), this is defined as stereotactic radiosurgery (SRS). Using a small number of fractions (3-7) is called hypofractionated radiotherapy which is commonly applied under stereotactic conditions and hence is called Hypo Fractionated Stereotactic Radiotherapy (HSRT). A conventional fractionation schedule of 25-30 fractions can be used based on 3-D conformal techniques, but is called Fractionated Stereotactic Radiotherapy (FSRT) if all the fractions are delivered under stereotactic conditions. The majority of lesions have historically been treated with SRS, or 3-D RT, and the literature on results with HSRT is still limited.

4. Intracranial meningiomas

1. Grade I meningiomas

Radiation therapy can be used very successfully as the sole modality for unresectable or inoperable lesions. After partial removal serious consideration should be given to offer the patient post operative radiotherapy and radiation should definitely be considered in the management of post surgical recurrences.

There are no major differences in overall results when comparing SRS ⇔ HSRT ⇔ FSRT (table I). For SRS, minimum target doses, covering the surface of the lesion, fall in the range of 13 – 16 Gy (10,11,12,13,14,16, 24).

Author	Total dose/Gy	Fractionation	Radiological control	Complications
Flickinger, et al. ⁽¹⁴⁾	14	SRS	93% -10 years	8.8%
Lo, et al. ⁽³³⁾	14	SRS	93% - 3 years	6%
	54	FSRT	93.3% - 3 years	5.5%
Roche, et al. ⁽⁵³⁾	13	SRS	100% - 4 years	6%
Pollock, et al. ⁽⁵⁴⁾	16	SRS	94% - 3 years	8%
Selch, et al. ⁽⁵⁵⁾	50.4	FSRT	97% - 3 years	0%
Villavincencio, et al. ⁽⁵⁶⁾	15	SRS	95% - 5 years	9%
Vernimmen, et al. ⁽⁵⁷⁾	24.8 *	HSRT	88% - 3 years	5.5%
Debus, et al. ⁽⁵⁸⁾	56.8	FSRT	97% - 5 years	1.6%
Mahadevan, et al. ⁽⁵⁹⁾	25 – 30	HSRT	100% - 2 years	0%
Torres, et al. ⁽⁶⁰⁾	15.7	SRS	90% - 3.5 years	5%
	48.4	FSRT	97.2% - 2 years	5.2%
Spiegelmann, et al. ⁽⁶¹⁾	13.5	SRS	98% - 5.5years	4.9%
Zada, et al. ⁽⁶²⁾	16	SRS	94% - 6 years	8%

* proton beam therapy

Table 1.

For HSRT, total doses in the region of 24 - 40 Gy, given in 3- 5 fractions have been used (18,51). FSRT doses fall in the range of 50 -56 Gy at 1.8 to 2 Gy per fraction.

The question therefore is what is the most appropriate dose/fractionation schedule? Factors that influence the decision are:

a. Volume and shape of the lesion:

Although no absolute guidelines exist in general one can state that as the volume of the lesion increases it becomes more and more difficult to safely offer the patient SRS (25,26,28). As a general rule lesions with a diameter ≤ then 2.5 – 3.0 cm are suitable for SRS. A complex shape of the lesion, which can happen with lesions of the skull base, can also, apart from volume restrictions, give sometimes limitations for the use of SRS (28). Here the different irradiation techniques have slight advantages and disadvantages (29).

Larger volume or complex shaped lesions can be treated with FSRT or HSRT. HSRT has the advantage of an overall shorter treatment time.

b. Proximity of critical normal structures:

Peripheral nerves have a fairly good resistance to radiation induced damage (30); hence the cranial nerves III - XII are usually not a major dose limiting factor. However the optic apparatus and especially the optic chiasma are vulnerable to radiation induced damage due to the late side effects of radiation therapy (31). So even for small lesions in very close proximity to the optic chiasma, FSRT or HSRT might be indicated as fractionation helps in improving the tolerance of the chiasma and other normal surrounding structures. The brain or brainstem are normally not directly invaded by Grade I and II meningiomas, hence there is no need to include them in the target volume. However when close contact exists they can receive a significant dose. Therefore "debulking" surgery with the aim of not only reducing the overall volume, but more importantly to increase the space between the meningioma and the normal tissues can be very valuable. In view of the very rapid dose fall off outside the target volume possible with stereotactic techniques, even a small gain in distance can reduce the dose to the normal structure considerable and hence reduce the chance of late damaging effects.

When a critical structure is totally or partially encased by the meningioma a strong point can be made for FSRT on *radiobiological grounds*. Full fractionation offers the best compromise between disease control and late normal tissue damage.

In a situation of close proximity, and when SRS is deemed not feasible, a hypofractionated schedule (HSRT) should be considered. When there is still concern for late reactions with HSRT or when the disease encases a sensitive structure fully fractionated therapy is required (32,33).

2. Grade II meningiomas

The best treatment protocol for this group is still not clear. In terms of dose/fractionation schedule most centres use the same as for grade I meningiomas. The same dose/fractionation selection factors as for grade I meningiomas apply. It is only their increased propensity to recur that would indicate a more aggressive use of radiation therapy in the post operative situation (34,35,36,37).

3. Grade III meningiomas

Considered malignant in terms of their histology and clinical behaviour they have a high mitotic index. Hence they should be treated as malignancies, with post operative radiation indicated even for completely excised lesions (38). As they can invade surrounding structures, inclusion of some surrounding normal tissue in the target volume is often necessary. This, plus the fact that they are likely to have a high α/β ratio in the order of 10 Gy (23) requires the use of fully fractionated therapy in the order of 56 - 60 Gy in 28- 30 fractions to obtain the best possible results.

5. Results

5.1 Disease control

In evaluating the results of different treatment modalities for meningiomas, it is important to clearly define the end point. For histological benign lesions one expects the lesion to have disappeared radiologically after complete surgical resection. On the other hand, after

primary radiation therapy the lesion rarely disappears completely. However, if after radiation therapy, a lesion remains radiologically stable for many years, and there is no progression of the clinical picture, the patient can be considered cured. Radiological follow up post radiotherapy usually reveals a small to moderate shrinkage of the lesion and a decrease in contrast enhancement. Often patients obtain some improvement of clinical neurological symptoms (39). This clinical improvement can happen without obvious radiological improvement. When used as a primary modality alone, several studies have shown a radiological control in the order of 88 – 100% and a clinical improvement or stable clinical picture in the order of 87-100% (Table I).

Fewer studies are available for the less benign histology's. This is because meningiomas need long term follow up to assess their response to therapy and most study's with long term follow up were based on the old classification. Of note is that whereas in the old classification about 5% of cases were classified as atypical meningiomas, in the current 2007 WHO classification, about 20-35% are classified grade II (40). Atypical meningiomas have a higher propensity to recur (1). Although the role of post operative radiotherapy for completely removed lesions is not well defined, in cases where there is residual disease post operatively, radiotherapy is advisable (41,42,43).

5.2 Side effects

Radiation therapy is in itself painless. Radiation side effects are classified as acute (during treatment) or late, with the late effects presenting themselves many months or years after the radiation was delivered. The nature, severity, and longevity of side effects depends on the organs that receive the radiation, the treatment itself (type of radiation, dose, fractionation), and the patient. Most side effects are predictable and expected. Side effects from radiation are usually limited to the area of the patient's body that is under treatment. One of the aims of modern radiation therapy is to reduce side effects to a minimum, and to help the patient to understand and to deal with those side effects which are unavoidable.

5.2.1 Acute effects

Side effects during therapy are minimal and are usually related to the patients head immobilisation system, and area of brain involved. Even a low dose on the brainstem can cause nausea, and localized headache can occur at the site of the meningeal involvement. The normal brain, connective tissues and the meningioma are late responding tissues (low α/β values) and hence very little acute effects tend to occur during the course of the radiotherapy. Other side effects are fatigue and skin irritation, like a mild to moderate sun burn. During a fully fractionated radiation course, the fatigue often sets in during the middle of the course and can last for weeks after treatment ends. The irradiated skin will heal, but may not be as elastic as it was before. However as the field sizes used in stereotactic irradiation are usually very small compared to conventional radiation for malignancies the areas of skin affected are minimal.

5.2.2 Late side effects

More important are the late side effects which when they occur can either be transient and improve or become permanent. Late side effects occur months to years after treatment

and are generally limited to the area that has been treated. They are often due to damage of blood vessels and connective tissue cells. The seriousness of many late effects are reduced by fractionation.

Most commonly oedema of the surrounding brain is noted on radiological imaging which might or might not be symptomatic (44). Para falx meningiomas have a higher propensity to develop surrounding brain oedema. This might be related to the fact that they tend to have a large contact zone with the surrounding brain in comparison with skull base meningiomas (44,45). The incidence of late effects on cranial nerves is low. Overall the incidence of side effects varies around 3- 6% (28,30,46,47).

Fibrosis: Tissues which have been irradiated tend to become less elastic over time due to a diffuse scarring process.

Epilation may occur on any hair bearing skin. It only occurs within the radiation field. Hair loss may be permanent with a single dose of 10 Gy, but if the dose is fractionated permanent hair loss may not occur until dose exceeds 45 Gy.

Cognitive decline is definitely a side effect that occurs when the whole brain or large parts of the brain are irradiated, such as in the case of whole brain irradiation for multiple brain metastasis or large brain tumors. For large meningiomas this is a factor to take into consideration in the decision on the use of radiation therapy. For small volume stereotactic irradiation the effect on cognition is not well established, but presumed to be minimal, and will primarily depend on the area of brain involved. In middle aged or elderly people it is difficult to distinguish between normal aging processes versus a radiation induced effect. Prospective studies are required to address this issue.

Carcinogenesis; Radiation is a potential cause of cancer, and secondary malignancies are seen in a very small minority of patients - usually less than 1/1000. It usually occurs 20 - 30 years following treatment. In the vast majority of cases, this risk is greatly outweighed by the benefit of the proposed radiation therapy. In elderly patients carcinogenesis is of less a concern in view of the long latent time. However the use of radiation for benign lesions like meningiomas in young people causes more concern and should definitely be addressed in the discussion on treatment options with the patient.

6. Spinal canal meningiomas

Adult primary spinal cord tumours represent 2% to 4% of all central nervous system neoplasms and of these meningiomas constitute about 25% (48, 49). Hence very few centres can report on the results exclusively for spinal meningiomas. Surgery is the main stay for managing these lesions as the spinal cord and the meningioma have an intricate anatomical relation, with spinal cord compression always a possibility if not already present at time of presentation. Spinal meningiomas are separated from the spinal cord by a discrete anatomical barrier, the arachnoid or pia membrane. This allows for removal with a conventional laminectomy in most cases (50). The role of radiotherapy for spinal meningiomas is the same as for intracranial meningiomas. The only difference lies in the tolerance of the spinal cord to radiation which is in the order of 44 - 48 Gy at 1.8 - 2 Gy/fraction. This favours the use of stereotactic irradiation and the same techniques can be used as for intracranial lesions except for the use of the Gammaknife® which by the very

nature of its construction cannot treat spinal lesions. Also the same total dose/fractionation choices and decision parameters apply as for intracranial lesions (51).

7. Conclusion

Although surgery is still regarded as the treatment of choice, radiation therapy is an effective alternative treatment, especially in the case of skull base meningiomas. In this anatomical location surgery carries a high risk of neurological morbidity, with a high chance of incomplete removal. Radiotherapy carries less morbidity than surgery. SRS, HSRT and FSRT all give equally good results. The choice of the radiation schedule is influenced by technical and radiobiological parameters.

8. References

- [1] Riemenschneider M, Perry A, Reifenberger G. Histological classification and molecular genetics of meningiomas. *Lancet Neurol* 2006; 5:1054-54
- [2] Condra KS, Buatti JM, Mendenhall WM, et al. Benign meningiomas: Primary treatment selection affects survival. *Int J Radiat Oncol Biol Phys* 1997;39(2):427- 436.
- [3] Levine ZT, Buchanan RI, Sekhar LN, et al. Proposed grading system to predict the extent of resection and outcomes for cranial base meningiomas. *Neurosurgery* 1999;45(2):221-230.
- [4] Newman SA. Meningiomas: A quest for the optimum therapy. *J Neurosurg* 1994;80:191-194.
- [5] Sekhar LN, Swamy NK, Jaiswal V, et al. Surgical excision of meningiomas involving the clivus: Preoperative and intraoperative features as predictors of postoperative functional deterioration. *J Neurosurg* 1994;81:860-868.
- [6] Kurita H, Sasaki T, Kawamoto S, et al. Role of radiosurgery in the management of cavernous sinus meningiomas. *Acta Neurol Scand* 1997;96(5):297-304.
- [7] Pendl G, Schrottnner O, Eustacchio S, et al. Cavernous sinus meningiomas – what is the strategy: Up-front or adjuvant gamma knife surgery? *Stereotact Funct Neurosurg* 1998; 70(Suppl. 1):33- 40.
- [8] Taylor BW, Marcus RB, Jr, Friedman WA, et al. The meningioma controversy: Postoperative radiation therapy. *Int J Radiat Oncol Biol Phys* 1988;15(2):299 - 304.
- [9] Goldsmith BJ, Wara WM, Wilson CB, et al. Postoperative irradiation for sub totally resected meningiomas. *J Neurosurg* 1994;80:195-201.
- [10] Kondziolka D, Lunsford LD, Coffey RJ, et al. Stereotactic radiosurgery of meningiomas. *J Neurosurg* 1991;74:552-559.
- [11] Shafron DH, Friedman WA, Buatti JM, et al. Linac radiosurgery for benign meningiomas. *Int J Radiat Oncol Biol Phys* 1999;43(2):321-327.
- [12] Subach BR, Lunsford LD, Kondziolka D, et al. Management of petroclival meningiomas by stereotactic radiosurgery. *Neurosurgery* 1998;42(3):437- 445.
- [13] Hakim R, Alexander E III, Loeffler JS, et al. Results of linear accelerator-based radiosurgery for intracranial meningiomas. *Neurosurgery* 1998;42(3):446-454

- [14] Flickinger JC, Kondziolka D, Maitz AH, Lunsford LD. Gamma knife radiosurgery of imaging-diagnosed intracranial meningioma. *Int J Radiat Oncol Biol Phys* 56(3):801-806, 2003
- [15] Schiappacasse L, Cendales R, Sallabanda K, et al. Preliminary results of helical tomotherapy in patients with complex-shape meningiomas close to the optic pathway. *Med Dosim.* 2011, Mar 10
- [16] Schreuder AN, Jones DTL, Symons JE, et al. The NAC protontherapy planning system. *Strahlentherapie und Onkologie* 1999;175(Suppl.2):10 -12.
- [17] Jones DTL, Schreuder AN, Symons JE, et al. The NAC particle therapy facilities. In: Amaldi U, Larsson B, editors. *Hadron therapy in oncology*. Elsevier Science B.V.; 1994.
- [18] Gerweck LE, Kozin SV. Relative biological effectiveness of proton beams in clinical practice. *Radiother Oncol* 1999;50: 135-142.
- [19] Fowler JF. Fractionation and therapeutic gain. *The Biological basis of radiotherapy*, Second Edition. Elsevier Science Publishers B.V. (Biomedical Division), 1989, pp 181-207
- [20] Hall EJ. Inferring the ratio α/β from multifraction experiments in nonclonogenic systems. *Radiobiology for the radiologists* 5th edition. Lippcott, Williams & Wilkins, 2000, pp 335-348
- [21] Vernimmen F.J., Slabbert JP. " Assessment of alpha/beta ratios for arteriovenous malformations, meningiomas, acoustic neuromas, and the optic chiasma" *Int J Radiat Biol.* 2010 Jun; 86(6):486-98
- [22] Liu L, Bassano DA, Prasad SC, Hahn SS, Chung CT. The linear-quadratic model and fractionated stereotactic radiotherapy. *International Journal of Radiation Oncology-Biology-Physics* 57(3):827-832, 2003
- [23] Hall EJ, Brenner DJ. The radiobiology of radiosurgery: Rationale for different treatment regimes for avm's and malignancies. *International Journal of Radiation Oncology-Biology-Physics* 25:381-385, 1993
- [24] Liu D, Xu D, Zhang Z et al. Long term results of Gamma knife surgery for optic nerve sheath meningiomas. *J Neurosurg.* 2010 Dec, 113 Suppl: 28-33
- [25] Morita A, Coffey RJ, Foote RL, et al. Risk of injury to cranial nerves after gamma knife radiosurgery for skull base meningiomas: Experience in 88 patients. *J Neurosurg* 1999;90(1):42-49.
- [26] Verhey LJ, Smith V, Serago CF. Comparison of radiosurgery treatment modalities based on physical dose distributions. *Int J Radiat Oncol Biol Phys* 1998;40(2):497-505.
- [27] Fowler JF. Fractionation and therapeutic gain. In: Steel GG, Adams GE, Horwich A, editors. *The biological basis of radiotherapy*. 2nd ed. Elsevier Publishers B.V. (Biomedical Division) 1989; p:181-207.
- [28] Nedzi LA, Kooy H, Alexander E II, et al. Variables associated with the development of complications from radiosurgery of intracranial tumours. *Int J Radiat Oncol Biol Phys* 1991;21(3): 591-599.


- [29] Smith V, Verhey L, Serago CF. Comparison of radiosurgical treatment modalities based on complication and control probabilities. *Int J Radiat Oncol Biol Phys* 1998;40(2):507-513.
- [30] Tishler RB, Loeffler JS, Lunsford LD, *et al.* Tolerance of cranial nerves of the cavernous sinus to radiosurgery. *Int J Radiat Oncol Biol Phys* 1993;27(2):215-221.
- [31] Leber KA, Bergloff J, Pendl G. Dose-response tolerance of the visual pathways and cranial nerves of the cavernous sinus to stereotactic radiosurgery. *J Neurosurg* 1988;88(1):43-50.
- [32] Stiebel-Kalish H, Reich E, Gal L, *et al.* Visual outcome in meningiomas around anterior visual pathways treated with linear accelerator fractionated stereotactic radiotherapy. *Int J Radiat Oncol Biol Phys* 2011 Feb 5.
- [33] Lo SS, Cho KH, Hall WA, *et al.* Single dose versus fractionated stereotactic radiotherapy for meningiomas. *Can J Neurol Sci*, 2002 Aug; 29(3):240-8
- [34] Jellinger K, Slowik F, Histological subtypes and prognostic problems in meningiomas. *Journal of Neurology*, Volume 208, number 4, 279-298
- [35] Choi CY, Soltys SG, Gibbs IC, *et al.* Cyberknife stereotactic radiosurgery for treatment of atypical (WHO grade II) meningiomas. *Neurosurgery*, 2010 Nov;67(5):1180-8
- [36] Askoxylakis V, Zabel-du Bois A, Schlegel W, *et al.* Patterns of failure after stereotactic radiotherapy of intracranial meningiomas. *J Neurooncol*, 2010 Jul; 98(3):367-72
- [37] Jo K, Park HJ, Nam DH, *et al.* Treatment of atypical meningioma. *J Clin Neurosci*, 2010 Nov; 17(11):1362-6
- [38] Rosenberg LA, Prayson RA, Lee J, *et al.* Long-term experience with World Health Organization grade III (malignant) meningiomas at a single institution. . *Int J Radiat Oncol Biol Phys* 2009 Jun 1; 74(2):427-32
- [39] Kondziolka D, Levy EL, Niranjan A, *et al.* Long-term outcomes after meningioma radiosurgery: Physician and patient perspectives. *J Neurosurg* 1999; 91(1):44 - 50.
- [40] Rogers L, Gilbert M, Vogelbaum MA. Intracranial meningiomas of atypical (WHO grade II) histology. *J Neuroonc.* 2010 Sep; 99(3):393-405
- [41] Mair R, Morris K, Scott I, *et al.* Radiotherapy for atypical meningiomas. *J Neurosurg*, 2011 Jun 24.
- [42] El-Khatib M, El Majdoub F, Hoevels M, *et al.* Stereotactic LINAC radiosurgery for incompletely resected or recurrent atypical and anaplastic meningiomas. *Acta Neurochir (Wien)*, 2011 Jun 25
- [43] Kano H, Takahashi JA, Katsuki T, *et al.* Stereotactic radiosurgery for atypical and anaplastic meningiomas. *J Neuroonc* 2007 Aug; 84(1):41-7
- [44] Cai R, Barnett GH, Novak E, *et al.* Principal risk of peritumoral edema after stereotactic radiosurgery for intracranial meningioma is tumor-brain contact interface area. *Neurosurgery*, 2010 Mar; 66(3):513-22

- [45] Conti A, Pontoriero A, Salamone C, et al. Protecting venous structures during radiosurgery for parasagittal meningiomas. *NeurosurgFocus*, 2009 Nov; 27(5):E11
- [46] Miller RC, Foote RL, Coffey RJ, et al. Decrease in cranial nerve complications after radiosurgery for acoustic neuromas: A prospective study of dose and volume. *Int J Radiat Oncol Biol Phys* 1999; 43(2):305-311.
- [47] Linskey ME, Flickinger JC, Lunsford LD. Cranial nerve length predicts the risk of delayed facial and trigeminal neuropathies after acoustic tumour stereotactic radiosurgery. *Int J Radiat Oncol Biol Phys* 1993; 25(2):227-233.
- [48] Chamberlain MC, Tredway TL. Adult primary intradural spinal cord tumors: a review. *Curr Neurol Neurosci Rep*, 2011 Jun; 11(3):320-8
- [49] Engelhard HH, Villano JL, Porter KR, et al. Clinical presentation, histology, and treatment in 430 patients with primary tumors of the spinal cord, spinal meninges, or cauda equine. *J Neurosurg Spine*. 2010 Jul; 13(1):67-77
- [50] Kim CH, Chung CK. Surgical outcome of a posterior approach for large ventral intradural extramedullary spinal cord tumors. *Spine (Phila Pa 1976)* 2011 Apr 15; 36(8):E531-7
- [51] Chang UK, Rhee CH, Youn SM, et al. Radiosurgery using the Cyberknife for benign spinal tumors: Korea Cancer Center Hospital experience. *J Neuroonc*. 2011 Jan; 101(1):91-9
- [52] Henzel M, Gross MW, Hamm K, et al. Stereotactic radiotherapy of meningiomas; Symptomatology, acute and late toxicity. *Strahlentherapie und Onkologie* 2006 7:382-388
- [53] Roche PH, Pellet W, Fuentes S, et al. Gamma knife radiosurgical management of petroclival meningiomas results and indications. *Acta Neurochir (Wien)*. 2003 Oct; 145(10):883-8.
- [54] Pollock BE. Stereotactic radiosurgery for intracranial meningiomas: indications and results, *Neurosurg Focus*. 2003 May 15; 14(5) :e4.
- [55] Selch MT, Ahn E, Laskari A, et al. Stereotactic radiotherapy for treatment of cavernous sinus meningiomas. *Int J Radiat Oncol Biol Phys* 2004 May 1; 59(1):101-11.
- [56] Villavicencio AT, Black PM, Shrieve DC et al. Linac radiosurgery for skull base meningiomas. *Acta Neurochir (Wien)*. 2001 Nov; 143(11):1141-52.
- [57] Vernimmen FJ, Harris JK, Wilson JA, et al. Stereotactic proton beam therapy of skull base meningiomas. *Int J Radiat Oncol Biol Phys* 2001 Jan 1; 49(1):99-105.
- [58] Debus J., Wuendrich M, Pirzkall A, et. al. High efficacy of fractionated stereotactic radiotherapy of large base-of-skull meningiomas: long-term results. *J Clin Oncol*. 2001 Aug 1; 19(15):3547-53.
- [59] Mahadevan A, Floyd S, Wong E, et al. Clinical outcome after Hypofractionated Stereotactic Radiotherapy (HSRT) for benign skull base tumors. *Comput Aided Surg*. 2011, Apr 6; 16(3):112-20
- [60] Torres RC, Frighetto L, De Salles AA, et al. Radiosurgery and stereotactic radiotherapy for intracranial meningiomas. *Neurosurg Focus*, 2003 May 15; 14(5): e5
- [61] Spiegelmann R, Cohen ZR, Nissim O, et al. Cavernous sinus meningiomas: a large Linac radiosurgery series. *J Neuroonc* Jun; 98(2):195-202

- [62] Zada G, Pagnini PG, Yu C, et al. Long-Term outcomes and patterns of tumor progression after gamma knife radiosurgery for benign meningiomas. *Neurosurgery* 2010 Aug;67(2):322-8

IntechOpen

IntechOpen



Meningiomas - Management and Surgery

Edited by Dr. Daniel Monleon

ISBN 978-953-51-0175-8

Hard cover, 136 pages

Publisher InTech

Published online 02, March, 2012

Published in print edition March, 2012

This book is aimed at neurosurgeons with an interest in updating their knowledge on the latest state of meningiomas surgery and management. The book is focused at performing a portrait of that what is state of the art in management of meningiomas. All the chapters have been developed with high quality and including the most modern approaches for the different aspects they deal with. The book concentrates on those problems that, although perhaps less common in the day to day routine of the average neurosurgeon, when present pose a special challenge. This is neither a "how to" book nor a book about meningioma biology. It presents some of the most relevant aspects in the latest developments for meningioma surgery and management in a clear and professional manner.

How to reference

In order to correctly reference this scholarly work, feel free to copy and paste the following:

Frederik Vernimmen (2012). Radiation Therapy in the Management of Meningiomas, Meningiomas - Management and Surgery, Dr. Daniel Monleon (Ed.), ISBN: 978-953-51-0175-8, InTech, Available from: <http://www.intechopen.com/books/meningiomas-management-and-surgery/the-role-of-radiation-therapy-in-the-management-of-meningiomas>

INTech
open science | open minds

InTech Europe

University Campus STeP Ri
Slavka Krautzeka 83/A
51000 Rijeka, Croatia
Phone: +385 (51) 770 447
Fax: +385 (51) 686 166
www.intechopen.com

InTech China

Unit 405, Office Block, Hotel Equatorial Shanghai
No.65, Yan An Road (West), Shanghai, 200040, China
中国上海市延安西路65号上海国际贵都大饭店办公楼405单元
Phone: +86-21-62489820
Fax: +86-21-62489821

© 2012 The Author(s). Licensee IntechOpen. This is an open access article distributed under the terms of the [Creative Commons Attribution 3.0 License](https://creativecommons.org/licenses/by/3.0/), which permits unrestricted use, distribution, and reproduction in any medium, provided the original work is properly cited.

IntechOpen

IntechOpen