

# We are IntechOpen, the world's leading publisher of Open Access books Built by scientists, for scientists

6,900

Open access books available

186,000

International authors and editors

200M

Downloads

Our authors are among the

154

Countries delivered to

TOP 1%

most cited scientists

12.2%

Contributors from top 500 universities



WEB OF SCIENCE™

Selection of our books indexed in the Book Citation Index  
in Web of Science™ Core Collection (BKCI)

Interested in publishing with us?  
Contact [book.department@intechopen.com](mailto:book.department@intechopen.com)

Numbers displayed above are based on latest data collected.  
For more information visit [www.intechopen.com](http://www.intechopen.com)



# Transarterial Chemoembolization for HCC with Drug-Eluting Microspheres

Maurizio Grosso, Fulvio Pedrazzini, Alberto Balderi,  
Alberto Antonietti, Enrico Peano, Luigi Ferro and Davide Sortino  
*A. O. S. Croce e Carle, Cuneo  
Italy*

## 1. Introduction

HCC is the 5th most common cancer worldwide and the 3rd cause of cancer related deaths. Transarterial chemoembolization (TACE) is the mainstay therapy for intermediate non-resectable HCC, according to the BCLC Staging system. (Bruix & Sherman, 2011).

TACE significantly improves the overall rate of survival after 2 years compared with conservative treatment, but there is no evidence that TACE is more effective than transarterial embolization (TAE). However in more selected patients the 1 year survival rate

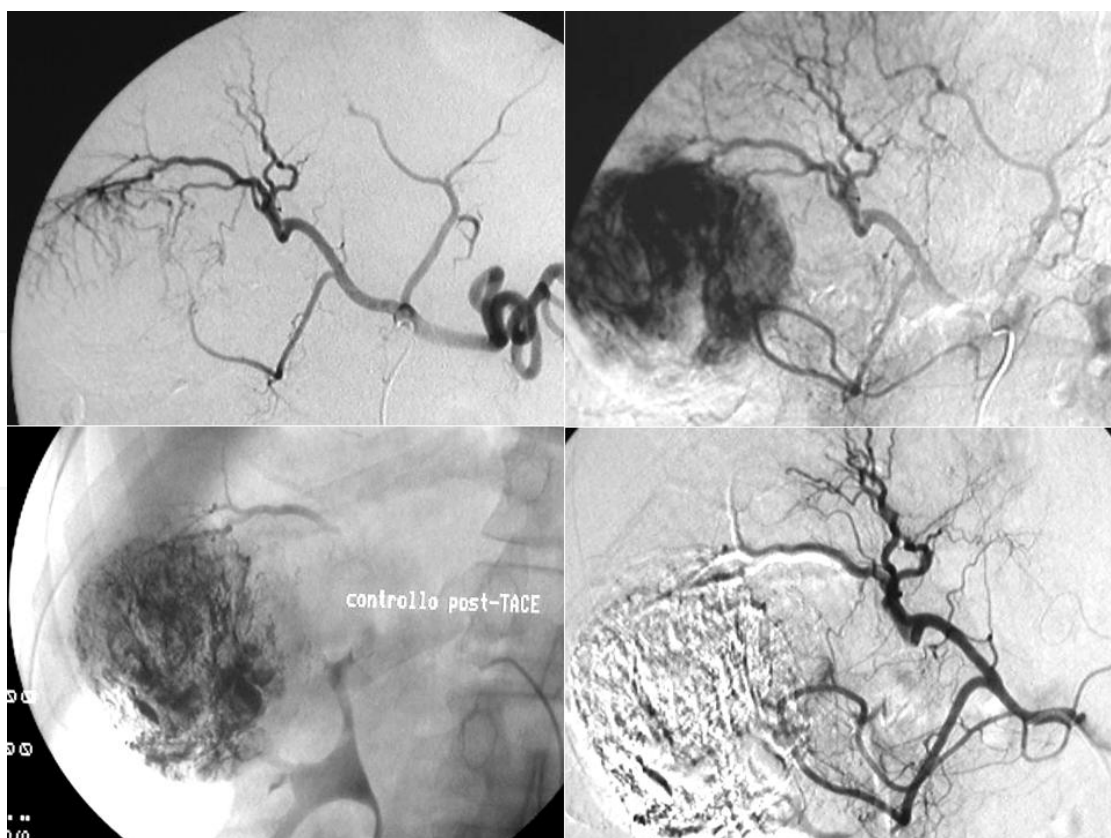


Fig. 1. TACE with Lipiodol.

is 82% after TACE, 75% after TAE and 63% after conservative treatment, while it is 63%, 50% and 27% respectively at 2 years (Llovet et al, 2002). Even if it is well known that Lipiodol stays for a prolonged period in the tumor after TACE, pharmacokinetic studies about traditional TACE with Lipiodol (Figure 1) and drug demonstrate that plasma levels of adriamycin are identical with intraarterial administration with or without Lipiodol.

With the aim of two different kind of drug-loaded carriers have been increasing the local concentration of the drugs and reducing systemic side effects introduced for transarterial treatment of HCC: HepaSphere™ Microspheres (BioSphere Medical, France) and DC Bead™ Microspheres (Biocompatibles, UK).

The aim of this study is to analyze the data recently published regarding DC Bead™ Microspheres and to present our experience with chemoembolization with HepaSphere™ Microspheres.

## 2. Conventional chemoembolization

Transarterial chemoembolization consists of the administration of chemotherapeutic drugs mixed with an embolizing material. It combines therapeutic effects of peripheral arterial occlusion with the local administration of chemotherapeutic agents. The target of arterial chemoembolization through the hepatic artery are to increase the local concentration of chemotherapeutic drugs in the tumor and reduce systemic side effects. The arterial system, mainly supplied vascularization of HCC unlike cirrhotic tissue, where vascularization is mainly supplied by the portal vein system. TACE can involve the whole hepatic parenchyma (embolization of the common hepatic artery or left/right hepatic artery) or can be selective (embolization of segmental/subsegmental hepatic artery) with better tumoral response and lower hepatic damage.

There is a great variability in the nature and description of transarterial techniques. There are at least four different kind of locoregional treatment: TACE (transarterial chemoembolization); TAE (transarterial embolization); TOCE (transarterial oily chemoembolization) and TAC (transarterial chemotherapy). TACE has been already described. TAE refers only to the last process, which may be preceded by the administration of Lipiodol (Lp-TAE), without using any chemotherapeutic agents. TOCE consists in the arterial administration of a mixture of anticancer drugs and Lipiodol without embolization. TAC is the locoregional infusion of chemotherapeutic agents through a catheter placed into the hepatic artery. (Marelli et al, 2007)

There is not yet a wide consensus about the characteristics of the patients suitable to undergo TACE. Selection criteria could be based on any combination of tumor dimension (tumor size, amount of liver replacement by tumor, serum  $\alpha$ -fetoprotein, portal vein thrombosis or obstruction), severity of liver disease (Child-Pugh score, serum bilirubin, serum albumin and ascites), health status (Karnofsky score, Performance Status test, and constitutional syndrome), and response to treatment. All these criteria have been found to be predictors of survival in patients undergoing TACE. The majority of studies included patients defined as having “unresectable HCC,” that is HCC diagnosed according to the 2000 Barcelona EASL criteria, not suitable for curative treatments according to BCLC staging classification and treatment schedule. Exclusion criteria in different trials were: advanced liver disease (Child-Pugh C), active gastrointestinal bleeding, encephalopathy, refractory ascites, presence of vascular

invasion or total portal vein occlusion due to liver tumor, extrahepatic metastases, any contraindication to an arterial procedure (impaired clotting tests and renal failure), WHO performance stage 3 or 4, and end-stage tumoral disease (Okuda III). (Marelli et al, 2007)

The indications have been explained by Barcelona Clinic Liver Cancer (BCLC) tumor staging; it combines the stage of liver disease, tumor stage, clinical performance, and treatment options and is certified by the European Association for the Study of Liver Disease (EASL) and the American Association for the Study of Liver Disease (AASLD). Actually, TACE is indicated in intermediate state (Bruix & Sherman, 2011).

Therefore absolute contraindications to TACE are Child C or Okuda III, tumor resectability or suitable for percutaneous ablations, sepsis, hepatic encephalopathy, uncorrectable contrast allergy or coagulation disorders, leucopenia ( $WBC < 1000/\mu l$ ), cardiac or renal insufficiency (serum creatinine  $> 2$  mg/dl) and complete portal vein thrombosis.

Relative contraindications are: serum bilirubin  $> 3$  mg/dl, LDH (lactate dehydrogenase)  $> 425$  U/l, AST (aspartate aminotransferase)  $> 5X$  the upper limit of normal, extrahepatic metastases, tumor burden involving  $> 50\%$  of the liver, performance status (PS)  $> 2$ , renal or cardiac insufficiency, recent variceal bleeding, or significant thrombocytopenia, intractable fav (arteriovenous fistula), ascites, surgical portocaval anastomosis, tumor invasion to inferior vena cava and right atrium, severe portal vein thrombosis. (Liapi & Geschwind, 2011)

Lipiodol (ethiodized oil) is an oily contrast medium which persists more selectively in tumor nodules for a few weeks or months when injected into the hepatic artery, due to the arterial hypervascularization and absence of Kupffer cells inside the tumor tissue, but it may also persist to a lesser extent in non-neoplastic nodules. Even if some investigators still believe in the embolic effect of lipiodol, nowadays it cannot be considered as an embolic agent since it does not result in arterial occlusion. It is used only as a vehicle to carry and localize chemotherapeutic agents inside the tumor. However, the major problem is how to combine anticancer drugs, which are water-based preparations, and lipiodol, which is an oil-based agent, in a stable formulation able to deliver drugs slowly over time. (Marelli et al, 2007)

The most common sole-agent anticancer drug used in literature is doxorubicin (36%), followed by cisplatin (31%), epi/doxorubicin (12%), mitoxantrone (8%), mitomycin C (8%), and SMANCS (5%). SMANCS is a chemical conjugate of a synthetic copolymer of styrene maleic acid (SMA).

To date there is no evidence of superior efficacy of any chemotherapeutic agent alone or of monotherapy versus combination therapy. Anticancer drugs dosage was variable and not reported according to standards: some studies used a fixed dose, some based the dosage on body surface area and others on patient weight, tumor size or bilirubin level. (Marelli et al, 2007)

The embolization endpoint is to achieve complete occlusion of the neo-vascularity, avoiding complete stasis in the afferent artery, which would lead to endothelial damage and subsequent thrombosis and would preclude future treatments. The embolized vessels are generally segmentary and subsegmentary branches.

Operative indications are:

1. Choose a delivery microcatheter based on the size of the target vessel.
2. Position the catheter tip as close as possible to the treatment site to avoid inadvertent occlusions of normal vessels and damage of "non-target" hepatic tissue. Large catheter causes "stop flow" with less selectivity and less accuracy in target embolization.

Undesirable reflux or passage of chemoembolic agent into normal arteries (adjacent to the target lesion or through the lesion into other arteries or arterial beds) can occur during embolization , with consequent non-target ischaemia (splenic, gastroduodenal, left, or right arteries embolization, etc.).

Post embolic syndrome (fever >38° C, nausea, vomiting, abdominal pain) frequently occurs after conventional TACE (90%), probably caused by inflammatory response and tissue ischemia. Liver ascess and acute liver failure occur in 2%, while ascites, transient abdominal pain, pleuric effusion, haemoperitoneum, splenic embolization, cardiac failure, thrombosis of hepatic artery, gastric ulcer bleeding, esophageal variceal bleeding, between 8 to 1% in the differents series.

The results of TACE in different series are reported in table 1-2-3. In randomized studies TACE improves survival in comparison with conservative treatments. Drug-eluting Microspheres increase the percentage of tumor tissue necrosis against the traditional TACE.

Authors	100%	99-88%	79-50%	< 50%
Hashimoto T Nakamura H Hori S Tomoda K	29%	43%	12%	16%
Morino M Grosso M De Giuli M Bismuth H	27%	30%	19%	23%

Table 1. Necrosis grading post-TACE

Authors	N. Pts	Survival		
		1 year	3 year	5 year
Atanaka	2159	65%	36%	18%
Savastano	57	75%	9 %	-
Shijo	110	79%	38%	14%
Ukida	1075	61%	15%	-
Grosso	340	59%	27%	17%

Table 2. TACE results.

Authors	N. Pts	Survival		
		1 year	3 year	5 year
Yamada	973	51%	12%	6 %
Bronowiki	127	65%	27%	-

Table 3. Segmental TACE results.

2.1 TACE with DcBead™ Microspheres

DC Bead™ Microspheres are Polyvinyl Alcohol polymer hydrogel N-Fil sulfonic acid Microspheres. They can be loaded with doxorubicin to provide accurate dosage of the drug and be suitable for superselective TACE. DC Bead™ primary embolic characteristics allow accurate, targeted delivery. They are available in a range of sizes associated to different colours

(yellow: 100-300  $\mu\text{m}$ ; blue: 300-500  $\mu\text{m}$ ; red: 500-700  $\mu\text{m}$ ; green: 700-900  $\mu\text{m}$ ), while volume of Beads is 2 ml. The 100-300  $\mu\text{m}$  microspheres are generally used in standard TACE, while 300-500  $\mu\text{m}$  or 500-700  $\mu\text{m}$  are used only in huge lesions or presence of arterial-portal fystulas

Choosing the appropriate size of microspheres best matches the pathology (i.e. tumour lesion/vessel size) provides the expected clinical outcome. Systemic plasma level of doxorubicin is 30 times lower in patients treated with DC Bead™ vs those treated with conventional TACE. DC Bead™ are hydrated and interaction of doxorubicin with SO<sub>3</sub> groups displaces water from the hydration shells DC Bead™ drug delivery properties are explained as it follows: loads and elutes drugs relevant to clinical use; uniform distribution of drug throughout the loaded beads; consistent local delivery to the tumour, over an extended period. With DC Bead™ drug elution is dependent on ion exchange and is controlled and sustained – unlike the rapid separation of the drug from Lipiodol. DC Bead™ should enable delivery of drug to the tumour site over an extended period while minimising systemic release of doxorubicin and reducing the side effects associated with conventional TACE.

### 2.1.1 TACE with DcBead™ Microspheres: Preparation

DC Bead™ Microspheres can be loaded with Doxorubicin-HCl (up to 37.5 mg/mL; maximum dose/patient of 150 mg).

1. Reconstitute each 50mg doxorubicin vial with 2ml of sterile water for injection. Mix well to obtain a clear solution.
2. Remove as much saline as possible from DC Bead™ vial(s) using a syringe with a small gauge needle. Pierce bung with a second needle to eliminate vacuum. If a filter needle is not available, place flattened tip of needle against side of vial to prevent beads being drawn up the needle.
3. Using a syringe and needle add the reconstituted doxorubicin solution directly to the vial(s) of DC Bead™.
4. Agitate the DC Bead™/doxorubicin solution gently to encourage mixing then allow to stand until the beads are red and the solution is almost colourless.
5. DC Bead™ loading time is dependent on bead size.
6. Transfer the loaded beads into a 10ml syringe. Add an equal volume of non-ionic contrast media and mix gently (a 3-way connector and second syringe can be used).

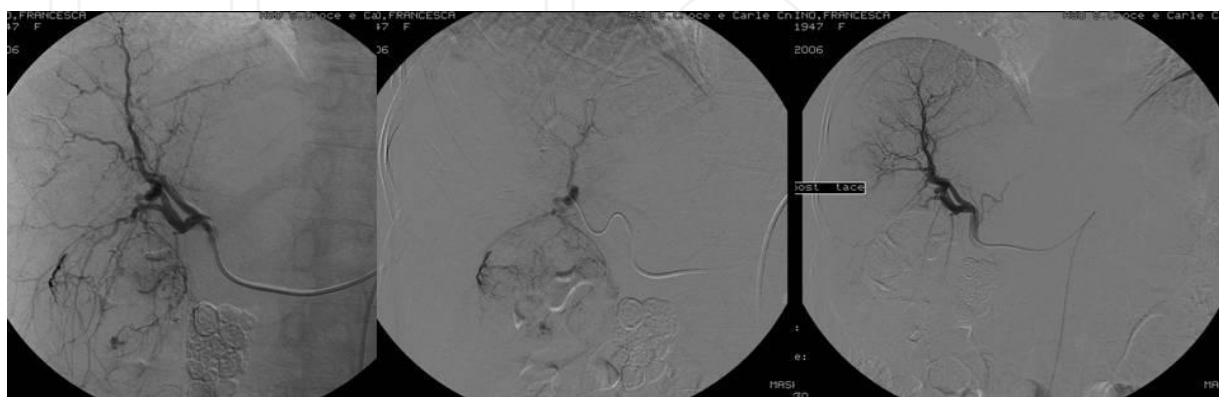


Fig. 2. TACE with DC Bead™ Microspheres.

Figures 2-3-4 demonstrate a case of HCC we treated with TACE with DC Bead™ Microspheres and the CT-follow-up at 1 and 6 months.

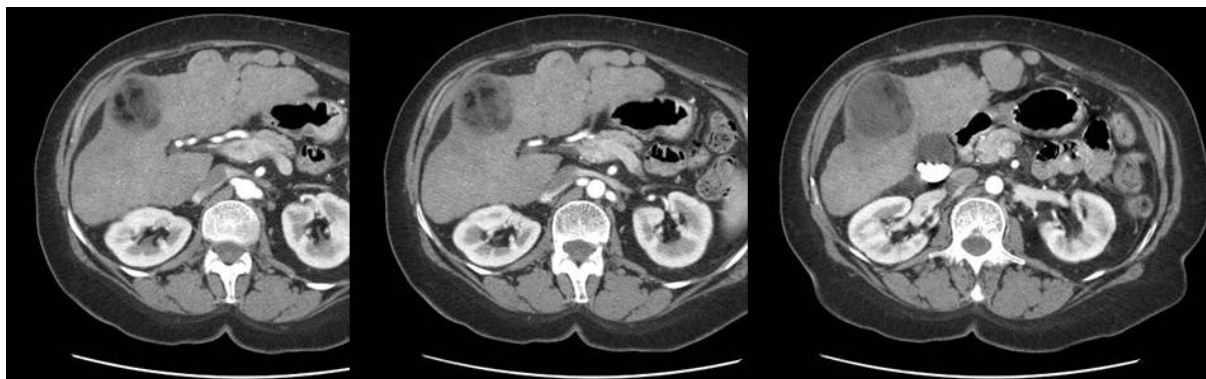


Fig. 3. 1-months CT follow-up of TACE with DC Bead™ Microspheres: complete necrosis of treated lesions.

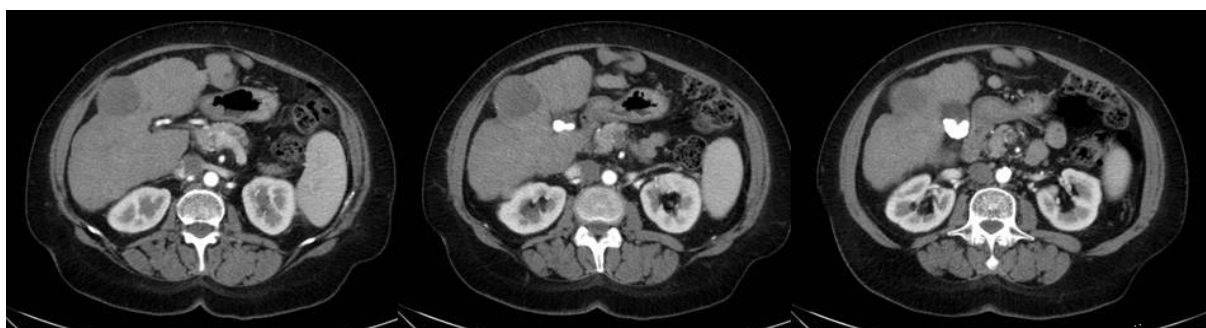

Fig. 4. 6-months CT follow-up of TACE with DC Bead™ Microspheres: complete necrosis of treated lesions.

### 2.1.2 TACE with DcBead™ Microspheres: Clinical experiences

Malagari presented the mid-term results of a single centre study from the 62 patients (cirrhotic with underlying hepatitis infection and documented unresectable HCC of 3-10 cm) Athenian Registry between December 2004 and March 2006. The aim of this study was to assess the safety and efficacy of doxorubicin loaded DC Bead in the treatment of unresectable HCC in cirrhotic patients. These patients were treated by selective or super-selective embolisation using two different sizes of DC Bead: 100-300 $\mu$ m and/or 300-500 $\mu$ m loaded with 37.5mg/mL of doxorubicin. Follow-up lasted 32 months. This shows that chemoembolization using doxorubicin-loaded DC Beads is a safe and effective treatment of HCC as demonstrated by the low complication rate, increased tumor response, and sustained reduction of alpha-fetoprotein levels". (Malagari et al, 2008)

The PRECISION V study (Lammer et al., 2010) support these results. It consists of a randomized trial comparing conventional TACE (cTACE) with TACE using DC Bead™ Microspheres for the treatment of cirrhotic patients with HCC. 212 patients with Child-Pugh A/B cirrhosis and large and/or multinodular, unresectable, N0, M0 HCCs were randomized to receive cTACE with doxorubicin or TACE with DC Bead™ Microspheres loaded with doxorubicin. Randomization was stratified according to performance status (ECOG 0/1), Child-Pugh status (A/B), bilobar disease (yes/no), and prior curative treatment (yes/no). The primary endpoint was tumor response (EASL) at 6 months following independent, blinded review of MRI studies. The drug-eluting bead group showed higher rates of complete response, objective response, and disease control compared with the cTACE group (27% vs. 22%, 52% vs. 44%, and 63% vs. 52%, respectively). The

hypothesis of superiority was not found (one-sided  $P = 0.11$ ). However, patients with Child-Pugh B, ECOG 1, bilobar disease, and recurrent disease showed a significant increase in objective response ( $P = 0.038$ ) compared to cTACE. DC Bead was associated with improved tolerability, with a significant reduction in serious liver toxicity ( $P \leq 0.001$ ) and a significantly lower rate of doxorubicin-related side effects ( $P = 0.0001$ ). This shows that TACE with DC Bead™ Microspheres and doxorubicin is safe and effective in the treatment of HCC and offers a benefit to patients with more advanced disease.

## 2.2 TACE with HepaSphere Microspheres

HepaSphere™ Microspheres are expandable microspheres approved for hepatic embolizations and chemoembolizations. They are Poly-sodium acrylate-vinyl alcohol Microspheres, developed in Japan by Dr Hori. They are available as 50 mg or 25 mg of dry powder, calibrated in 3 different dry sizes associated to different colours (yellow: 50-100  $\mu\text{m}$ ; blue: 100-150  $\mu\text{m}$ ; red: 150-200  $\mu\text{m}$ ), sterilized by irradiation. Their diameter expands x4 and volume x64.

They are negatively charged (anionic polymer), enabling strong interactions with positively charged drugs such as Doxorubicin reducing systemic toxicity.

### 2.2.1 TACE with HepaSphere Microspheres: Preparation

Prepare in Biohazard Hood

1. Using a 30 mL syringe and a 20G needle, reconstitute the 50 mg doxorubicin vial with 20 mL preservative-free 0.9% sodium chloride. Do not use pure sterile water.
2. Lift the cap from the HepaSphere™ vial to the vertical position taking care not to remove the cap or the metal retaining ring from the vial.
3. Roll the HepaSphere™ vial several times to disperse microspheres.
4. Using a new 30 mL syringe with a new 18 G needle, withdraw 20 mL (the entire contents) from the doxorubicin vial (50 mg) prepared in Step 1.
5. Inject 10 mL of doxorubicin from Step 4 to the HepaSphere™ vial. Note: there may be a vacuum in the HepaSphere™ vial.
6. Gently rotate and invert the HepaSphere™ vial back and forth 5 to 10 times so that the liquid contacts the grey stopper (do not shake vigorously). Let the vial stand for 10 minutes; invert every few minutes to continue to mix the spheres with the doxorubicin.
7. After the 10 minutes from Step 6, withdraw the entire contents of the HepaSphere™ vial into the 30 mL syringe containing the remaining doxorubicin (25 mg/10 mL) prepared in Step 4. (Do not attempt to extract every red colored sphere). Gently agitate the syringe back and forth to completely mix and disperse the contents.
8. Remove the needle and cap the syringe. Note the time and wait 60 minutes to optimize the uptake of the doxorubicin into the spheres before administering.
9. Do not begin this step until at least 60 minutes has elapsed from Step 8. Attach syringe to a 3-way stopcock. Allow the spheres to settle at the bottom. Purge 10 mL of the supernatant and discard. Add/replace with 10 mL of non-ionic contrast.
10. Invert this syringe several times to disperse and mix the contents in the syringe until suspension is achieved.

### 2.2.2 TACE with HepaSphere Microspheres: Clinical experiences

We have reported the early results of a multicentre Italian trial using HepaSphere™ Microspheres loaded with chemotherapeutic agents (doxorubicin or epirubicin) for TACE in

patients with unresectable hepatocellular carcinoma (December 2005 – March 2007; 50 patients, 36 male – 14 female, mean age 68.4 years). The diameter of the treated lesions ranged from 20 to 100 mm (mean 42.5; maximum of 4 tumor nodules). Tumor response was evaluated by CT according to the World Health Organization criteria as modified by the European Association for the Study of Liver Diseases. Technical success was performed in all procedures without major complications. At 1-month CT follow-up, complete tumor response was observed in 24 of 50 (48%), partial response in 18 of 50 (36%), and stable disease in 8 of 50 (16%) patients without cases of disease progression. At 6-month follow-up (31/50 patients) complete tumor response was obtained in 16/31 (51.6%), partial response in 8/31 (25.8%), and progressive disease in 7/31 (22.6%) patients. Within the initial 9-month follow-up, TACE with HepaSphere™ Microspheres was successfully repeated twice in 3 patients, while 3 patients underwent the procedure 3 times. Our initial multicentre experience demonstrates that TACE using HepaSphere is feasible, is well tolerated, has a low complication rate, and is associated with promising tumor response. When complete tumor response is not achieved, additional treatments can be performed.

Longer follow-up on larger series is mandatory to confirm these preliminary results. (Grosso et al., 2008)

We compared our experience using HepaSphere™ microspheres (Biosphere Medical) loaded with Doxorubicin in patients with unresectable Hepatocellular Carcinoma with our precedent series of traditional TACE: TACE with Lipiodol and Gelfoam (340 pts treated from December 1991 to April 1996) and TACE with Lipiodol and Embosphere (46 pts treated from February 2000 to November 2005). From December 2005 to December 2010, we treated 111 patients (83 male, 28 female, mean age 71 years; 70% with a minimum follow-up of 6 months) by selective TACE using HepaSphere™ loaded with Doxorubicin in 173 procedures. The diameter of the lesions ranged from 25 to 176 mm (mean diameter: 61.5 mm; maximum: multifocal lesions). Technical success rate was 100%, with complete devascularization of the lesions at the end of all procedures. One month CT follow-up shows complete necrosis (90-100%) of lesions in 39.9%, partial necrosis (50-89%) in 44.2%, progression disease (0-49%) in 15.9%. 6 month follow-up shows complete necrosis in 32.4%, partial in 44.5%, progression disease in 23.1%. 39 patients underwent RFA (29 pre-TACE; 10 post-TACE); 12 were lost at follow-up, 5 died. Survival at 6 months was 93.8% in HepaSphere™, 91.3% in Embosphere,

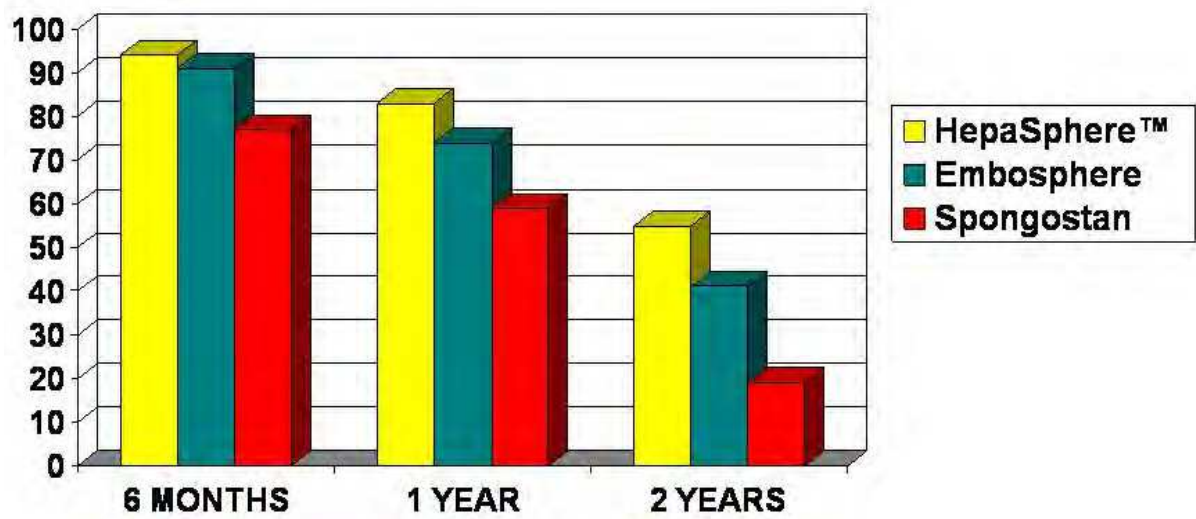


Fig. 5. Personal experience A.S.O. S. croce e Carle – Cuneo. Survival %.

77% in Gelfoam group; at 12 months it was 83.3% in HepaSphere™, 73.9% in Embosphere, 59.1% in Gelfoam group; at 24 months was 55% in HepaSphere™, 41% in Embosphere, 19% in Gelfoam group (Figure 5).

This comparison demonstrates that TACE using HepaSphere™ is feasible, with low complication rate and promising efficacy.

Figures 5-6 demonstrate a case of HCC we treated with TACE with HepaSphere™ Microspheres and 1 months US-follow-up.

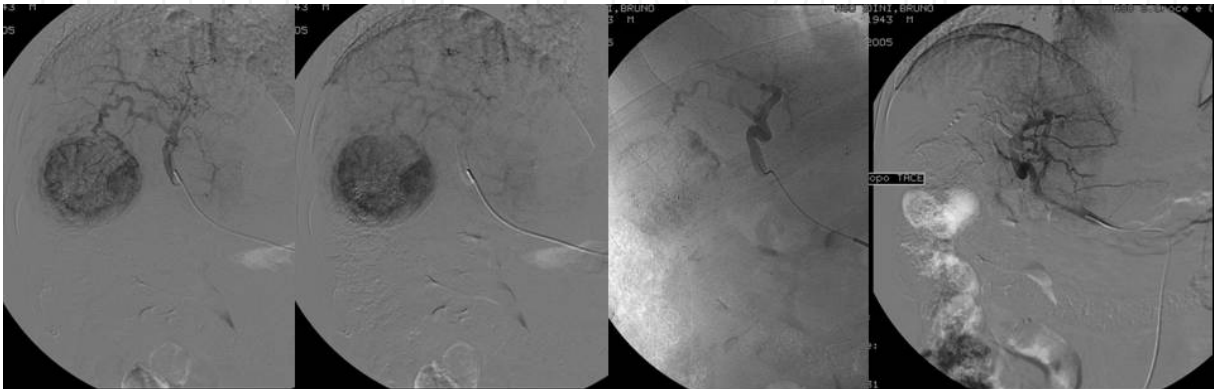


Fig. 6. TACE with HepaSphere™.

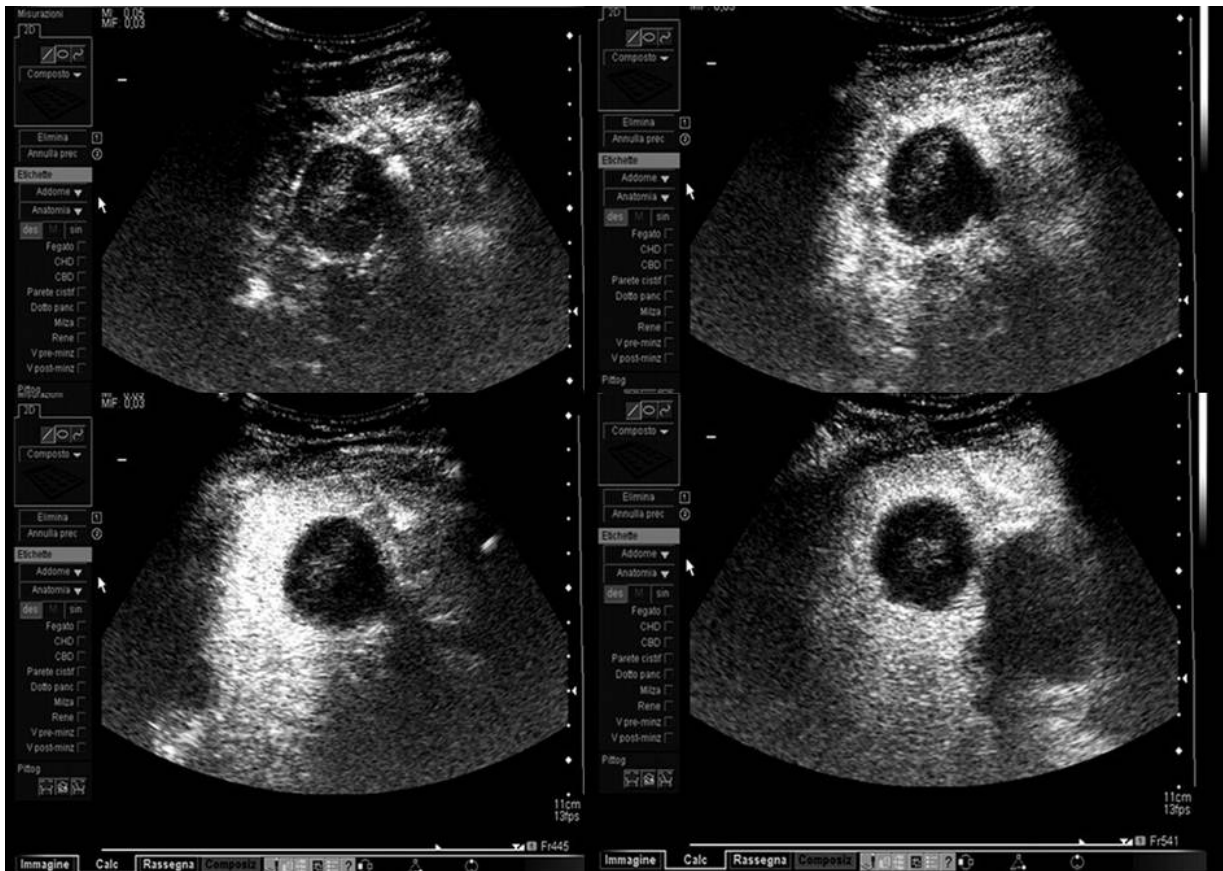


Fig. 7. 1-month US follow-up after TACE with HepaSphere™: complete necrosis of nodule of HCC we treated.


### 3. Conclusions

TACE is the most successful treatment of intermediate HCC or HCC not suitable for resection and percutaneous ablation, improving the life quality and medium/long survival rates in patients with intermediate HCC.

The results of TACE using Microspheres, compared with results of conventional TACE, are promising less side-effects, complications and especially seems to offer benefit to patients with advanced tumor.

### 4. References

- Bruix J. and Sherman M. (2011) Management of Hepatocellular Carcinoma: An Update. *Hepatology*, Mar;53(3):1020-2.
- Grosso M., Vignali C., Quaretti P., Nicolini A., Melchiorre F., Gallarato G., Bargellini I., Petruzzi P., Massa Saluzzo C., Crespi S., Sarti I. (2008). Transarterial chemoembolization for hepatocellular carcinoma with drug-eluting microspheres: preliminary results from an Italian multicentre study. *Cardiovasc Intervent Radiol*. Nov-Dec;31(6):1141-9.
- Lammer J., Malagari K., Vogl T., Pilleul F., Denys A., Watkinson A., Pitton M., Sergent G., Pfammatter T., Terraz S., Benhamou Y., Avajon Y., Gruenberger T., Pomoni M., Langenberger H., Schuchmann M., Dumortier J., Mueller C., Chevallier P., Lencioni R.; PRECISION V Investigators.. (2010) Prospective randomized study of doxorubicin-eluting-bead embolization in the treatment of hepatocellular carcinoma: results of the PRECISION V study. *Cardiovasc Intervent Radiol*. Feb ;33(1):41-52.
- Liapi E., Geschwind J.F. (2011). Transcatheter arterial chemoembolization for liver cancer: is it time to distinguish conventional from drug-eluting chemoembolization? *Cardiovasc Intervent Radiol*. Feb;34(1):37-49.
- Llovet J.M, Real M.I, Montana X, Planas R, Coll S, Aponte J, Ayuso C, Sala M, Muchart J, Sola R, Rodes J and Bruix J. (2002) Arterial embolisation or chemoembolisation versus symptomatic treatment in patients with unresectable hepatocellular carcinoma: a randomised controlled trial. *Lancet*; ; 359 (9319): 1734-1739.
- Malagari K., Chatzimichael K., Alexopoulou E., Kelekis A., Hall B., Dourakis S., Delis S., Gouliamos A., Kelekis D. (2008). Transarterial chemoembolization of unresectable hepatocellular carcinoma with drug eluting beads: results of an open-label study of 62 patients. *Cardiovasc Intervent Radiol*. Mar-Apr; 31(2):269-80.
- Marelli L., Stigliano R., Triantos C., Senzolo M., Cholongitas E., Davies N., Tibballs J., Meyer T., Patch D.W., Burroughs A.K. (2007). Transarterial therapy for hepatocellular carcinoma: which technique is more effective? A systematic review of cohort and randomized studies. *Cardiovasc Intervent Radiol*. Jan-Feb; 30(1):6-25.



## **Hepatocellular Carcinoma - Clinical Research**

Edited by Dr. Joseph W.Y. Lau

ISBN 978-953-51-0112-3

Hard cover, 330 pages

**Publisher** InTech

**Published online** 02, March, 2012

**Published in print edition** March, 2012

This book covers the clinical aspects of hepatocellular carcinoma. This book is a compendium of papers written by experts from different parts of the world to present the most up-to-date knowledge on the clinical aspects of hepatocellular carcinoma. This book is divided into three sections: (I) Diagnosis / Differential Diagnosis; (II) Surgical Treatment; (III) Non-surgical Treatment. There are 19 chapters covering topics from novel diagnostic methods to hepatic lesions mimicking hepatocellular carcinoma, from laparoscopic liver resection to major hepatectomy without allogeneic blood transfusion, from molecular targeted therapy to transarterial radioembolization, and from local ablative therapy to regional therapy. This volume is an important contribution to the clinical management of patients with hepatocellular carcinoma. The intended readers of this book are clinicians who are interested in hepatocellular carcinoma, including hepatologists, liver surgeons, interventional and diagnostic radiologists, pathologists and epidemiologists. General surgeons, general physicians, trainees, hospital administrators, and instruments and drug manufacturers will also find this book useful as a reference.

### **How to reference**

In order to correctly reference this scholarly work, feel free to copy and paste the following:

Maurizio Grosso, Fulvio Pedrazzini, Alberto Balderi, Alberto Antonietti, Enrico Peano, Luigi Ferro and Davide Sortino (2012). Transarterial Chemoembolization for HCC with Drug-Eluting Microspheres, Hepatocellular Carcinoma - Clinical Research, Dr. Joseph W.Y. Lau (Ed.), ISBN: 978-953-51-0112-3, InTech, Available from: <http://www.intechopen.com/books/hepatocellular-carcinoma-clinical-research/transarterial-chemoembolization-for-hepatocellular-carcinoma-with-drug-eluting-microspheres->

**INTECH**  
open science | open minds

### **InTech Europe**

University Campus STeP Ri  
Slavka Krautzeka 83/A  
51000 Rijeka, Croatia  
Phone: +385 (51) 770 447  
Fax: +385 (51) 686 166  
[www.intechopen.com](http://www.intechopen.com)

### **InTech China**

Unit 405, Office Block, Hotel Equatorial Shanghai  
No.65, Yan An Road (West), Shanghai, 200040, China  
中国上海市延安西路65号上海国际贵都大饭店办公楼405单元  
Phone: +86-21-62489820  
Fax: +86-21-62489821

© 2012 The Author(s). Licensee IntechOpen. This is an open access article distributed under the terms of the [Creative Commons Attribution 3.0 License](https://creativecommons.org/licenses/by/3.0/), which permits unrestricted use, distribution, and reproduction in any medium, provided the original work is properly cited.

IntechOpen

IntechOpen