

# We are IntechOpen, the world's leading publisher of Open Access books Built by scientists, for scientists

6,900

Open access books available

186,000

International authors and editors

200M

Downloads

Our authors are among the

154

Countries delivered to

TOP 1%

most cited scientists

12.2%

Contributors from top 500 universities



WEB OF SCIENCE™

Selection of our books indexed in the Book Citation Index  
in Web of Science™ Core Collection (BKCI)

Interested in publishing with us?  
Contact [book.department@intechopen.com](mailto:book.department@intechopen.com)

Numbers displayed above are based on latest data collected.  
For more information visit [www.intechopen.com](http://www.intechopen.com)



# Radiofrequency Ablation for Hepatocellular Carcinoma at the Dome of the Liver: A Review

Kiyoshi Mochizuki

*Department of Gastroenterology and Hepatology, Kansai Rousai Hospital, Hyogo  
Japan*

## 1. Introduction

Hepatocellular carcinoma is the third-leading cause of global cancer-related mortality. Major causes of this disease are hepatotropic viruses including hepatitis B and C viruses, nonalcoholic steatohepatitis, alcohol, autoimmunity, primary biliary cirrhosis, primary sclerosing cholangitis, vascular disorders and so on (Olsen et al., 2010). These factors related to hepatitis lead the patients to the high-risk group for decompensated liver cirrhosis and hepatocellular carcinoma during their clinical course in 20–30 years. Interferon or other medical therapy for each disease have been accommodating better conditions of the liver and make it possible to prolong their lives. However, the possibility of the occurrence of hepatocellular carcinoma could not have been completely avoided in these patients during their lifetime.

Recently, the improvements of surveillance techniques and disease awareness have led to earlier diagnosis and more appropriate treatment for liver tumors. Surgical therapy could be curative treatment to avoid local recurrence, but many patients are unable to undergo surgical resection due to severely compromised liver function or multiple tumors. Moreover, frequent recurrence of hepatocellular carcinoma makes it hazardous for the patients to undergo surgical therapy repeatedly to maintain the liver function after the treatment. Thus, non-surgical interventional therapy has been introduced to control hepatocellular carcinoma and have played an important role in the treatment of hepatocellular carcinoma (Livraghi et al, 1999; Poon et al, 2002). These locoregional therapies including transcatheter arterial chemoembolization, percutaneous ethanol injection therapy, percutaneous radiofrequency ablation therapy and others, have been making significant contributions to reduce the decrease of the liver function and to maintain the condition of the patients (Poon et al, 2002; Buix et al, 2004; Orland et al, 2009). Radiofrequency ablation has provided one of the greatest recent advances in the treatment of hepatocellular carcinoma because of the improvement of the local control and the patient survival. Radiofrequency ablation is reported as a minimally invasive and effective treatment for small hepatocellular carcinoma and now this treatment is the most widely used technique of the therapy for hepatocellular carcinoma worldwide. Many studies have established the effectiveness of radiofrequency ablation in treating hepatocellular carcinoma (McGhana & Dodd, 2001; Livraghi et al, 2003; Lencioni et al, 2005; Tateishi et al, 2005; Choi et al, 2007) and have achieved to expand the indications for radiofrequency ablation.

However, one of the most characteristic complications of this therapy is that related to the thermal effect. We experienced a case that developed diaphragmatic hernia due to the thermal effect of radiofrequency ablation twenty months after the treatment for a tumor located in the segment VIII area of his liver. Patients who have undergone radiofrequency ablation for hepatic tumors adjacent to the diaphragm should be carefully followed up for possible damage of the diaphragm, even after the long postoperative intervals. Recently, the artificial ascites technique has been developed and introduced in this field. This technique could be approved for the prevention of the diaphragmatic damage and the thermal complications of the surrounding organs.

## **2. Radiofrequency ablation for hepatocellular carcinoma**

Radiofrequency ablation includes the methods of tumor necrosis through the direct placement of the needles into the tumor under the ultrasonographical guide and the usage of alternating electrical current to create ionic agitation and frictional heating leading to the tissue damage. The benefits of this therapy include excellent local control comparable to surgical resection, low morbidity, repeatability for recurrence, preservation of liver function, and few complications (Livraghi et al, 1999; Poon et al, 2002).

Although radiofrequency ablation is considered safe (Curley et al, 2000; Livraghi et al, 2000; Wood et al, 2000), some serious complications have been reported. These include bleeding from costal or hepatic artery, pneumothorax or puncture of surrounding organ, infection, pain, nausea or vomiting, and so on (Curley et al, 2000; Livraghi et al, 2000; Wood et al, 2000). One of the most characteristic and unpredictable complications of this therapy is that induced by heat conduction. Even though the needle could be inserted into the appropriate lesion under the ultrasonographic guide, because the ablated area should be larger than the tumor and involving the whole tumor, it is difficult to grasp the ablated area around the tumor and the environmental situation precisely during the treatment. The ablation produce microbubbles due to heating up in the tissue surrounding the tumor resulting in occurrence of difficulty in grasping the precise ablated area. If the physicians could release the needle from the ultrasonographic transducer during the treatment, it could be possible to grasp roughly the area from other view points. However, high echoic area of microbubbles is not always identical to ablated area and sometimes expands beyond the thermal margin of the effective thermal area. Three-dimensional analysis with radiological study should be helpful to evaluate the ablated area, but it is impossible to predict before the treatment because of the existence of environmental factors of the ablated area including blood flow and respiratory movement of the liver.

## **3. Technical difficulties for hepatocellular carcinoma situated at the dome of the liver**

Because all of the procedures for the liver diseases under ultrasonographic guidance need to be performed with the fully clear detection of the target site, insufficient and poor imaging of ultrasonography means the hardly successful treatment. However, ultrasonographic visualization of the whole tumor under the diaphragm is not always possible due to the atrophy of the right lobe of the cirrhotic liver and the normal respiratory expansion of the lung over the liver causing the acoustic shadow. Therefore, the deformity or the atrophy of the liver due to the chronic inflammation and the damage would make ultrasonographically

undetectable region in the liver and lead the physicians to have difficulties in such treatment. Hepatocellular carcinoma can locate in every lobe of the liver, and sometimes locates under the diaphragm dome and this could often be the key factor affecting the effectiveness or the insufficiency of this treatment (Koda et al, 2003; Kang et al, 2009). It may be unavoidable in such cases to make unintended burns to the diaphragm neighboring or close to the target tumor because physicians should burn larger area including hepatocellular carcinoma in order to gain the safety margin around it.

#### **4. Reported complications including a diaphragmatic hernia in the literature, and the case report**

##### **4.1 A review of diaphragmatic hernia reported in the literature**

Mulier et al. reviewed the complication of radiofrequency ablation from 82 reports of 3670 cases and reported that the prevalence of diaphragm burn was estimated as 0.1% (5 out of 3670) (Mulier et al, 2002). However, Head HW et al. reported that 5 (17%) in 29 radiofrequency ablation cases of hepatocellular carcinoma adjacent to the diaphragm had right shoulder pain and 3 cases showed thickening of the diaphragm induced by the thermal effect of radiofrequency ablation (Head et al, 2007). It is also reported that the symptom of diaphragm injury manifests as referred right shoulder pain that occurs during the treatment and can last up to 2 weeks after the ablation (Livraghi et al, 2003). It may be unavoidable in cases that hepatocellular carcinomas locate under the diaphragm dome to make unintended burn to the diaphragm because of the environmental and technical factors (Kang et al, 2009). The unintended burn of the limited area of the diaphragm may not induce any significant phenomena in the short term except in a few cases, but Curly et al. analyzed the data of 608 cases and emphasized the risk of the late complications of the radiofrequency ablation treatment (Curley et al, 2004). It should be known that radiofrequency ablation could induce serious combined diseases more than several months after the treatment.

##### **4.2 Case report: Diaphragmatic hernia twenty months after percutaneous radiofrequency ablation for hepatocellular carcinoma**

In August, 2006, we experienced one case of a 50-year-old man with hepatitis B virus infection who underwent radiofrequency ablation for hepatocellular carcinoma of 2.2 cm in diameter located in the segment VIII area of his liver adjacent to the diaphragm (Figure 1a). The tumor could be almost fully scanned ultrasonographically and it was located just under the costal region close to the costopleural angle. Laboratory tests showed his liver function as Child-Pugh class A liver cirrhosis.

Ultrasound-guided radiofrequency ablation was performed using RITA Medical System 1500 RF generator attached to a 15-gauge Starburst XL model 90 probe needle for 20 minutes and the needle was expanded to 4cm in a stepwise manner. There was no technical problem and enough ablation area around hepatocellular carcinoma could be achieved with a safety margin of the necrotic area (Figure 1b). He did not feel nausea and did not complained about a thermal effect like right shoulder pain which could be a sign of diaphragm damage (Livraghi et al, 2003). After the procedure, he was discharged in a week without any adverse effects. He had been under observation in our hospital regularly and medicated by entecavir

to control hepatitis B virus replication. Since multiple recurrence lesions were detected in the segment VIII later, he was treated with transcatheter arterial chemoembolization therapy in April, 2007 and in February, 2008.

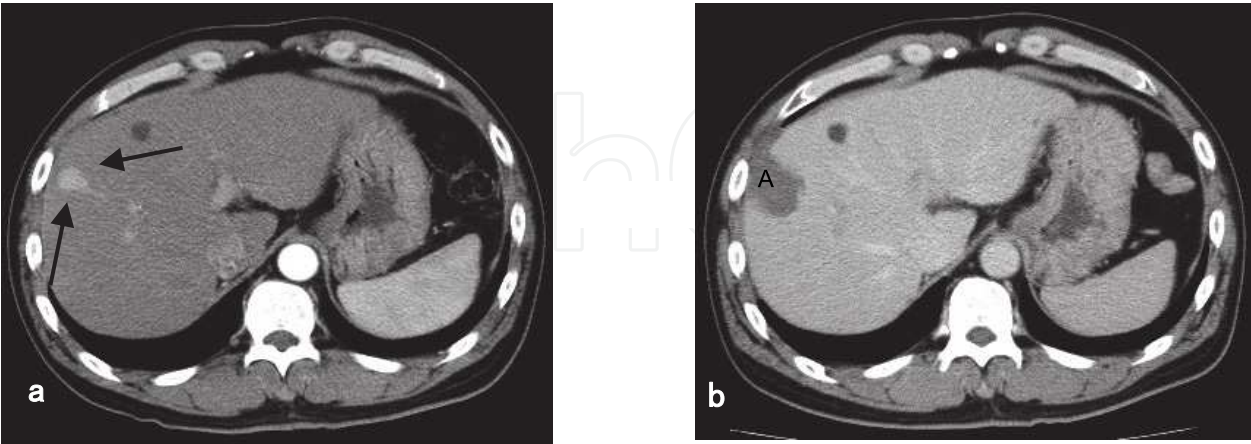


Fig. 1. 50-year-old man with hepatocellular carcinoma. (adapted from Nawa T et al).  
a. Arterial phase computed tomography scan obtained prior to the radiofrequency ablation shows enhancing nodule (black arrows) in the segment VIII of the liver.  
b. Portal phase computed tomography scan obtained after the radiofrequency ablation shows the ablation zone (A).

Twenty months later after the radiofrequency ablation treatment in April 2008, he was admitted to our hospital emergency department because of severe right hypochondralgia and dyspnea.

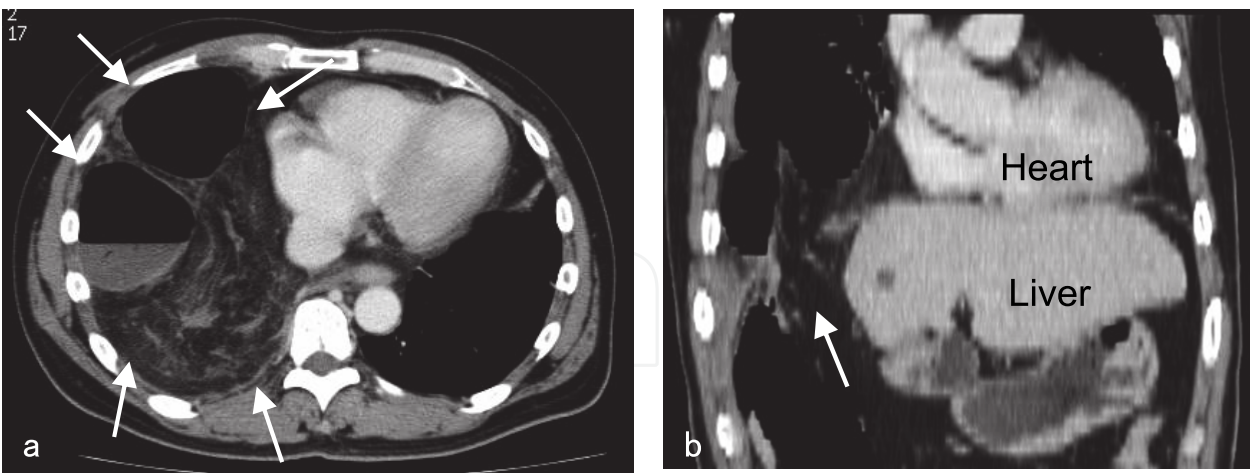


Fig. 2. Computed tomography scan obtained at the hospital emergency department twenty months later after the radiofrequency ablation therapy. (adapted from Nawa T et al).  
a. Computed tomography scan shows the prolapsed large intestine and the omentum in his right pleural cavity (white arrows).  
b. Coronal multidetector computed tomography image of his chest shows the portion of the large intestine in the right lower thorax, indicating the anatomic relationship of the diaphragmatic defect (white arrow) and the surrounding organs.



Computed tomography revealed the prolapsed large intestine and the omentum through a defect on the right diaphragm (Figure 2a, 2b), and emergency surgery was performed to close the hole in the diaphragm following the diagnosis of diaphragmatic hernia. The operation showed that the ascending and transverse colon had been herniated into the right pleural cavity through the diaphragmatic hole which measured 5x3 cm in diameter (Figure 3) and no apparent invasion of hepatocellular carcinoma around the hole was observed. Although the colon was perforated in the pleural cavity and induced pyothorax after the operation, he recovered with the intense care using antibiotics and drainage (Nawa et al, 2010).

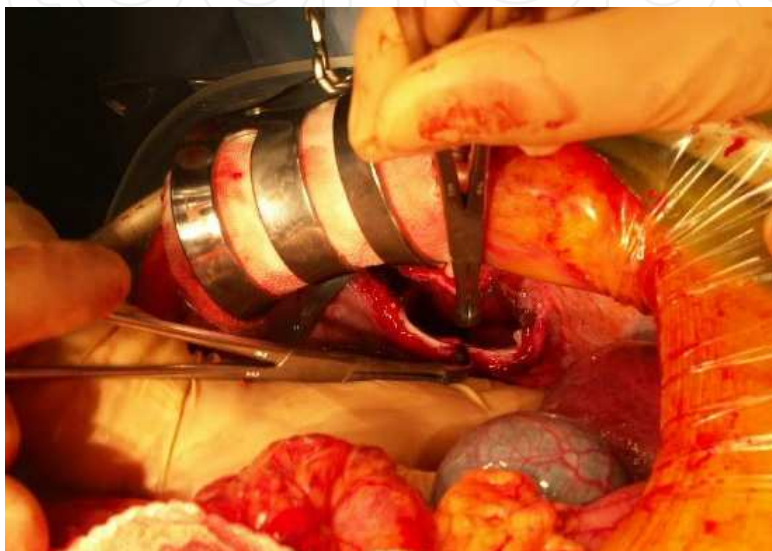

Fig. 3. The photograph taken during the surgery. (adapted from Nawa T et al). This photograph is showing the hole in the diaphragm.

In our case, the location of the diaphragm defect was apparently different from that of congenital diaphragmatic hernia and his clinical history showed that nothing other than the radiofrequency ablation could be the cause of the diaphragmatic perforation. The repeated treatments of transcatheter arterial chemoembolization against hepatocellular carcinoma recurrence during twenty months might accelerate the atrophy of the right lobe of his liver (Figure 4, a-d). This atrophic change could be thought to make the space between the liver and the diaphragm for his large intestine to access to the hole.

It is often a problem of radiofrequency ablation using an expandable electrode that all of the multiple tips of the needle cannot always be detected under ultrasonography because the tips are multidirectional meaning there is a risk of puncture of vessels or other organs close to a tumor beyond the possible scan area. However, diaphragmatic hernia was reported not only in the case of expandable electrodes but also in the case of a single straight electrode. Therefore, the thermal effect for the diaphragm could not always be induced by the direct puncture of expandable electrode.

Because this complication was observed in the cases of hepatocellular carcinoma located in the segment IV, VII or VIII close to the diaphragm, it should be recommended to follow carefully such cases, especially with the apparent atrophic change of the right lobe of the liver, as the high-risk groups of diaphragmatic hernia.

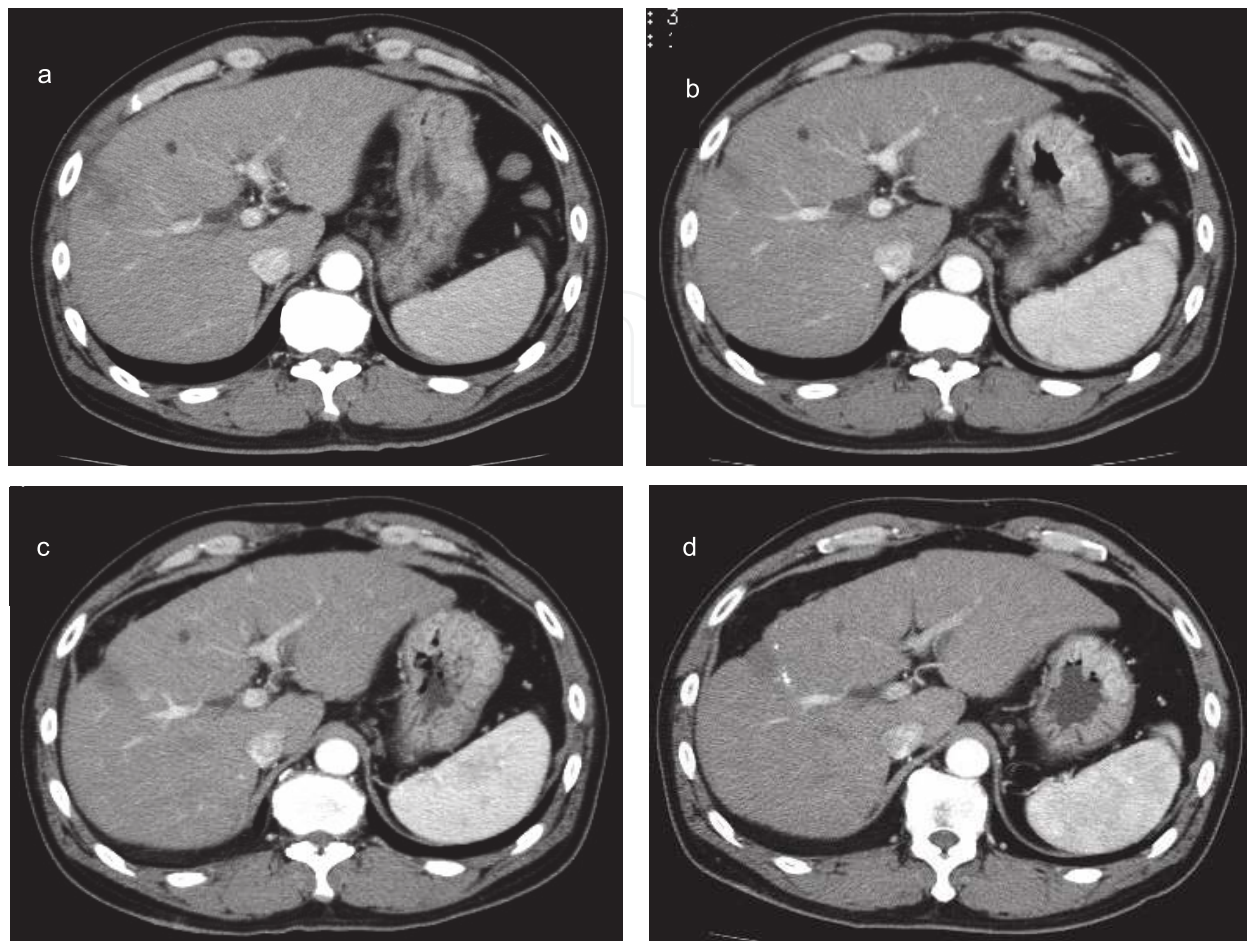


Fig. 4. Computed tomography scan obtained after the radiofrequency ablation therapy. (adapted from Nawa T et al).

Computed tomography obtained in August, 2006, (a); in November, 2006, (b); in March, 2007, (c); in May, 2007, (d). The serial computed tomography scans are showing the gradual atrophic change of the liver causing to space between the diaphragm and the liver.

## 5. Technical solution for radiofrequency ablation for hepatocellular carcinoma at the dome of the diaphragm: The techniques of artificial ascites

### 5.1 The purpose of the artificial ascites technique

Radiofrequency ablation is difficult to perform if a tumor is located under the diaphragm because this region is often invisible or is poorly visible on ultrasonography. Local ablation therapy under laparoscopy or thoracoscopy could be a possible treatment in such case, but it is more invasive than percutaneous procedure and other special equipment would be needed. The artificial pleural or peritoneal effusion has been explored as a beneficial treatment option that offers excellent local control through visualization of hepatocellular carcinoma under the diaphragm (Katayama et al, 2002; Uehara et al, 2007; Rhim et al, 2008). It was meaningful that this method has been reported to be effective to keep enough space between the liver and the adjacent organs including the diaphragm by a solution that can cool down the local ablated area by circulating in the peritoneal space. The procedure of artificial ascites technique is briefly shown below.

## 5.2 Procedure of artificial ascites

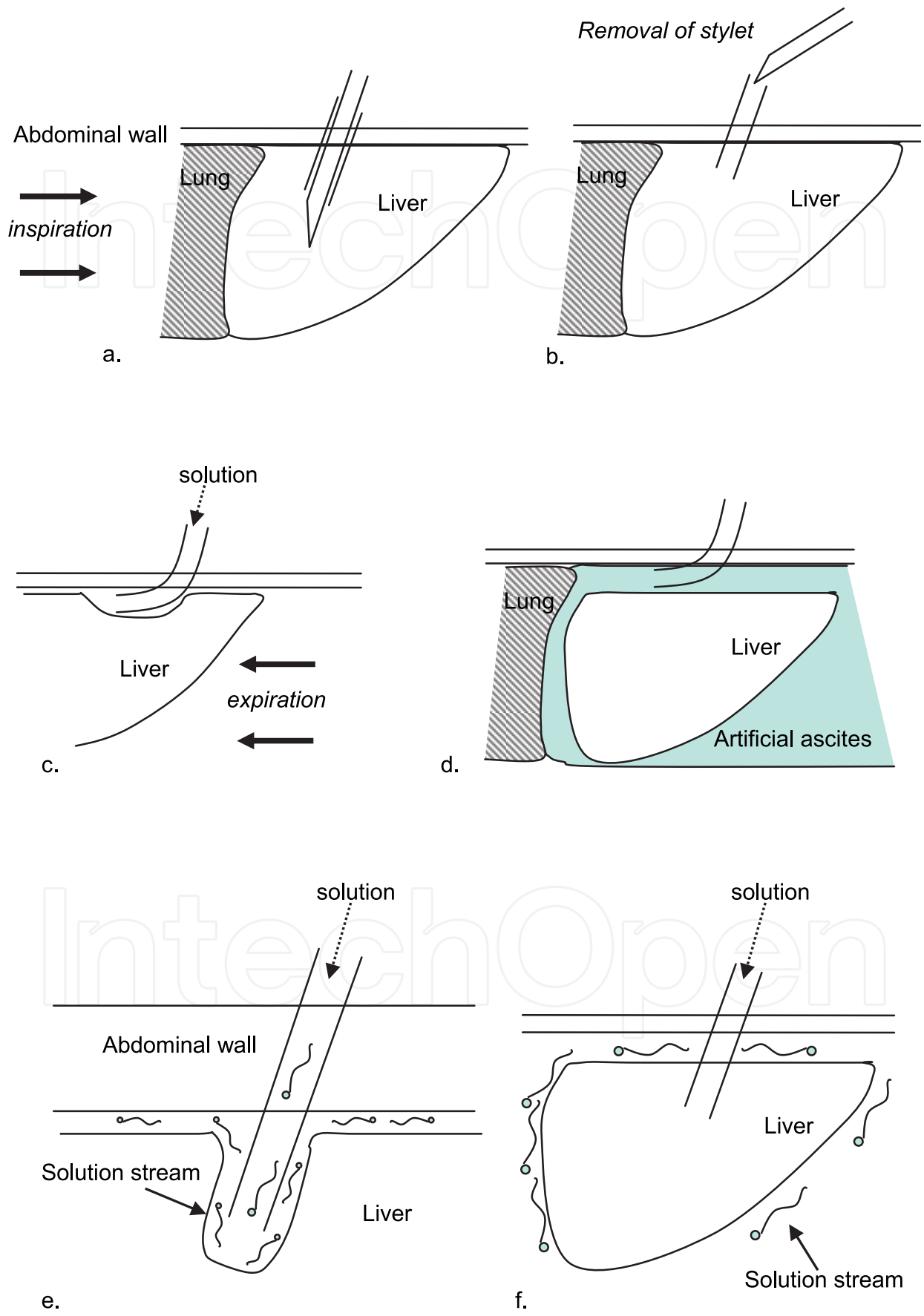
1. The location of the puncture site should be defined first as a clearly visible point in the liver with ultrasonography usually at the sixth to eighth intercostal space along the anterior to middle axillary line. It is necessary to avoid around the radiofrequency ablation puncture site for the artificial ascites puncture site since radiofrequency ablation treatment should be started during the artificial ascites procedure before the ascites spreads to other or lower abdominal cavity. If it is difficult to avoid the ablation puncture site for the artificial ascites puncture site, it is able to start making the artificial ascites at that site and try other sites after gaining a solution space in the abdominal cavity since there should be more puncture sites to make the ascites after gaining it.
2. After the administration of the local anesthesia at the skin of the puncture site, an 18-gauge sheathed needle would be prepared to insert into the peritoneal space. If the outer sheath has a side hole for infusion, it would be much easier and faster to achieve enough volume of ascites. The pneumoperitoneum needle can be used for the puncture of the appropriate site instead of the sheathed needle for this procedure.
3. Patients are asked to perform inspiration to move the liver downward and then to hold the breath for a while. Oxygen administration could be helpful for the patients to hold the breath. The physician inserts the 18-gauge sheathed needle into the parenchyma of the liver (Figure 5a) and removes the inner stylet of the sheathed needle (Figure 5b).
4. Next, the patients are asked to perform full expiration so that the needle sheath can slip away from the hepatic capsule and located in the perihepatic intraperitoneal space (Figure 5c). If the needle sheath could not slip away from the liver, further deep inspiration and expiration could help a successful placement of the sheath.
5. After the placement of the outer sheath into the peritoneal cavity, 500-1500 ml of 5% glucose solution could be infused until the tumor is fully visualized and the path for the radiofrequency ablation electrode could be clearly developed (Figure 5d). In case of diabetic patients, saline could be used instead of glucose solution.

## 5.3 The other issues of artificial ascites technique

### 5.3.1 Learning of the knack of artificial ascites procedure

- a. The puncture directed in the dorsal space of the liver without direct puncture of the liver parenchyma could be selected, but it may take longer time to achieve enough volume of ascites above ventral side of the target liver surface.
- b. Even though the needle sheath could not slip away from the liver parenchyma at step 4), the solution infusion could be started slowly. Sometimes, a blood back flow is seen after stylet removal through the needle sheath, but if the blood flow does not come from a hepatic artery, usually the solution infusion can be started. The back flow of the solution infusion from the liver parenchyma would make the ultrasonographically visible thin layer of the solution showing faint blinking streams around the liver (Figure 4e, 4f). At that time, respiratory movement might affect the drip infusion while it stops during the time of the expiration and it starts during the time of the inspiration due to the change of abdominal pressure.
- c. If an outflow of the blinking stream through hepatic vein could be observed (Figure 4g), the physician should stop infusion and retry the puncture.





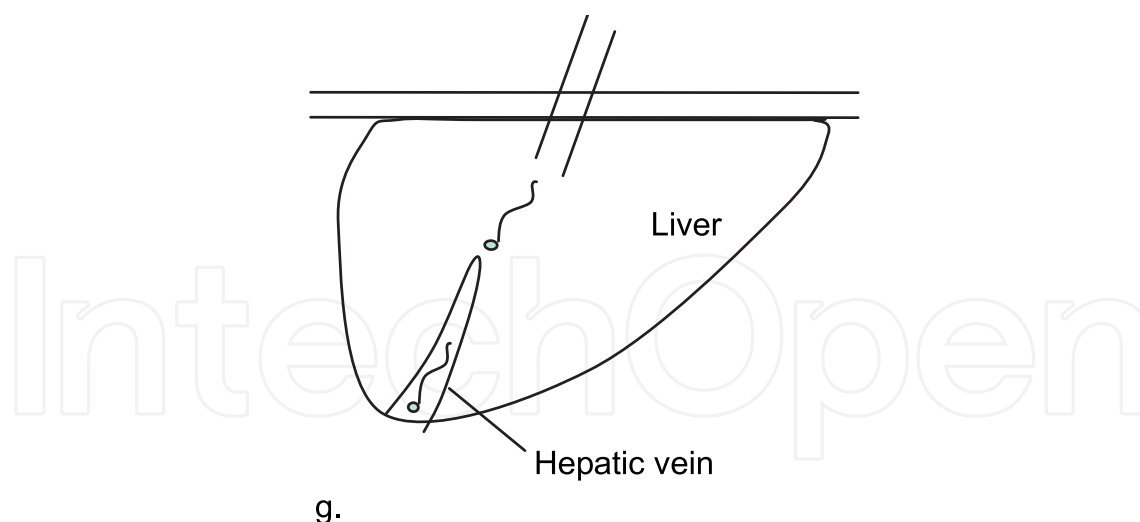


Fig. 5. The diagrams show the procedure to obtain artificial ascites during radiofrequency ablation.

- a. The insertion of the 18-gauge sheathed needle into the parenchyma of the liver.
  - b. The removal of the inner stylet of the sheathed needle.
  - c. The placement of the outer needle sheath in the perihepatic intraperitoneal space.
  - d. The achievement of the artificial ascites that can visualize the whole tumor and the path for the RFA electrode.
  - e. The faint blinking streams of the back flow of the solution infusion from the outer sheath needle in the liver parenchyma.
  - f. The faint blinking streams around the liver.
  - g. The unsuccessful streams of solution outflowing to the hepatic vein
- d. It is reported that oxygen saturation decreased by only 2.3% even in performing artificial pleural effusion (McGhana & Dodd, 2001) and most of the solution infused into the peritoneal cavity would disappear in 3 to 7 days in our experience.
  - e. Artificial ascites technique can be used in the cases that hepatocellular carcinoma is located at ventral or dorsal side beneath the liver capsule in order to avoid the thermal effect to the abdominal wall or gastrointestinal tract (Kondo et al, 2006).

### 5.3.2 Technical pitfalls of artificial ascites procedure

The infusion should not be vigorously performed until enough thickness (about 2 to 5 mm) of the layer could be detected because such infusion often causes the sheath dislocation from the first placed site and produces an unintended inflow to the abdominal wall. The physicians often notice such inflow with the swelling of the puncture site or an ultrasonographic thickening of the abdominal wall. In this case, the physicians should also remove the sheath as soon as possible and retry the puncture, but it often becomes more difficult to insert from the same site because the abdominal wall becomes thicker than the distance that the puncture needle can reach. Therefore, the physicians should try to find another appropriate site for a puncture or try it again another day.

### 5.3.3 Out of the indication of artificial ascites

If the patients have histories of abdominal operation or peritonitis, the adhesions between the liver and the abdominal wall might be hazardous to have successful artificial ascites. In

those cases, the other locoregional treatments like transcatheter arterial chemoembolization, percutaneous ethanol injection therapy, or computed tomography guided radiofrequency ablation could be suitable procedures to treat the patients.

## 6. Conclusion

The patients who have undergone radiofrequency ablation for hepatic tumors adjacent to the diaphragm should be carefully followed up for possible diaphragmatic hernia, even after the long postoperative intervals. The artificial ascites technique can be used not only to visualize the whole HCC under the diaphragm, but also to reduce the unavoidable and unintended thermal complications of the diaphragm and the surrounding organs if successfully performed.

## 7. References

- Bruix J, Sala M, Llovet JM. (2004). Chemoembolization for hepatocellular carcinoma. *Gastroenterology* 127. 5, (Nov 2004), S179-188, 0016-5085.
- Choi D, Lim HK, Rhim H, Kim YS, Lee WJ, Palk SW, Koh KC, Lee JH, Choi MS, Yoo BC. (2007). Percutaneous radiofrequency ablation for early-stage hepatocellular carcinoma as a first-line treatment: long-term results and prognostic factors in a large single-institution series. *Eur Radiol* 17. 3, (Mar 2007), 684-692, 0938-7994.
- Curley SA, Izzo F, Ellis LM, Nicolas Vaughey J, Vallone P. (2000). Radiofrequency ablation of hepatocellular cancer in 110 patients with cirrhosis. *Ann Surg* 232. 3, (Sep 2000), 381-391, 0003-4932.
- Curley SA, Marra P, Beaty K, Ellis LM, Vauthey JN, Abdalla EK, Scalfe C, Raut C, Wolff R, Choi H, Loyer E, Vallone P, Flore F, Scordino F, De Rosa V, Orlando R, Pignata S, Daniele B, Izzo F. (2004). Early and late complications after radiofrequency ablation of malignant liver tumors in 608 patients. *Ann Surg* 239. 4, (Apr 2004), 450-458, 0003-4932.
- Head HW, Dodd III GD, Dalrymple NC, Prasad SR, El-Merhi FM, Freckleton MW, Hubbard LG. (2007). Percutaneous radiofrequency ablation of hepatic tumors against the diaphragm: frequency of diaphragmatic injury. *Radioilogy* 243. 3, (Jun 2007), 877-884, 0033-8419.
- Kang TW, Rhim H, Kim EY, Kim Ys, Choi D, Lee Wj, Lim HK (2009). Percutaneous radiofrequency ablation for the hepatocellular carcinoma abutting the diaphragm: assessment of safety and therapeutic efficacy. *Korean J Radiol* 10. 1, (Jan-Feb 2009), 34-42, 1229-6929.
- Katayama K, Ohka Y, Uemura A, Shinzaki S, Egawa S, Naito M, Ishibashi K, Kamei R. (2002). Saline injection into the pleural cavity to detect tumors of the hepatic dome with sonography; A new approach for treatment of hepatocellular carcinoma. *AJR Am J Roentgenol* 179. 1, (Jul 2002), 102-104. 0361-803X.
- Koda M, Ueki M, Maeda N, Murawaki Y. (2003). Diaphragmatic perforation and hernia after hepatic radiofrequency ablation. *AJR Am J Roentgenol* 180. 6, (Jun 2003), 1561-1562. 0361-803X.
- Kondo Y, Yoshida H, Shiina S, Tateishi R, Teratani T, Omata M. (2006). Artificial ascites technique for percutaneous radiofrequency ablation of liver cancer adjacent to the gastrointestinal tract. *Br J Surg* 93. 10, 1277-1292, 0007-1323.


- Lencioni R, Cioni D, Crocetti L, Franchini C, Pina CD, Lera J, Bartolozzi C. (2005). Early-stage hepatocellular carcinoma in patients with cirrhosis: long-term results of percutaneous image-guided radiofrequency ablation. *Radiology* 234. 3, (Mar 2005), 961-967, 0033-8419.
- Livraghi T, Golberg SN, Lazzaroni S, Meloni F, Solbiati L, Gazelle GS. (1999). Small hepatocellular carcinoma: treatment with radio-frequency ablation versus ethanol injection. *Radiology* 210. 3, (Mar 1999), 655-661, 0033-8419.
- Livraghi T, Goldberg SN, Lazzaroni S, Meloni F, Ierace T, Solbiati L, Gazelle GS. (2000). Hepatocellular carcinoma: radio-frequency ablation of medium and large lesions. *Radiology* 214. 3, (Mar 2000), 761-768, 0033-8419.
- Livraghi T, Solbiati L, Meloni MF, Gazelle GS, Halpern EF, Goldberg SN. (2003). Treatment of focal liver tumors with percutaneous radio-frequency ablation: complications encountered in a multicenter study. *Radiology* 226. 2, (Feb 2003), 441-451, 0033-8419.
- McGhana JP, Dodd GD 3<sup>rd</sup>. (2001). Radiofrequency ablation of the liver; current status. *AJR Am J Roentgenol* 176. 1, (Jan 2001), 3-16, 0361-803X.
- Mulier S, Mulier P, Ni Y, Miao Y, Dupas B, Marchal G, DeWever I, Michel L. (2002). Complications of radiofrequency coagulation of liver tumors. *Br J Surg* 89. 10, (Oct 2002), 1206-1222. 0007-1323.
- Nawa T, Mochizuki K, Yakushijin T, Hamano M, Itose I, Egawa S, Nishida T, Tsutsui S, Hiramatsu N, Kanto T, Takehara T, Hayashi N. (2010). A patient who developed diaphragmatic hernia 20 months after percutaneous radiofrequency ablation for hepatocellular carcinoma. *Nippon Shokakibyo Gakkai Zasshi* 107. 7, (Jul 2010), 1167-1174. 0446-6586.
- Olsen SK, Brown RS, and Siegel AB. (2010). Hepatocellular carcinoma: review of current treatment with a focus on targeted molecular therapies, *Therap Adv Gastroenterol*, 3. 1, (Jan 2010), 55-66, 1756-283X
- Orlando A, Learndro G, Olivo M, Andriulli A, Cottone M. (2009). Radiofrequency thermal ablation vs. percutaneous ethanol injection for small hepatocellular carcinoma in cirrhosis: meta-analysis of randomized controlled trials. *Am J Gastroenterol* 104. 2, (Feb 2009), 514-524, 0002-9270.
- Poon RT, Fan ST, Tsan FH, Wong J. (2002). Locoregional therapies for hepatocellular carcinoma: a critical review from the surgeon's perspective. *Ann Surg*, 235. 4, (Apr 2002), 466-486, 0003-4932.
- Rhim H, Lim Hk, Kim YS, Choi D. (2008). Percutaneous Radiofrequency ablation with artificial ascites for hepatocellular carcinoma in the hepatic dome : initial experience. *AJR Am J Roentgenol*. 190. 1, (Jan 2008), 91-97. 0361-803X.
- Tateishi R, Shiina S, Teratani T, Obi S, Sato S, Koike Y, Fujishima T, Yoshida H, Kawabe T, Omata M. (2005). Percutaneous radiofrequency ablation for hepatocellular carcinoma: an analysis of 1000 cases. *Cancer* 103. 6, (Mar 2005), 1201-1209, 0008-543X.
- Uehara T, Hirooka M, Ishida K, Hiraoka A, Kumagi T, Kisaka Y, Hiasa Y, Onji M. (2007). Percutaneous ultrasound-guided radiofrequency ablation of hepatocellular carcinoma with artificially induced pleural effusion and ascites. *J Gastroenterol* 42. 4, (Apr 2007), 306-311, 0944-1174.



Wood TF, Rose DM, Chung M, Allegra DP, Foshag LJ, Bilchik AJ. (2000). Radiofrequency ablation of 231 unresectable hepatic tumors: indications, limitations, and complications. *Ann Surg Oncol* 7. 8, (Sep 2000), 593-600, 1068-9265.

IntechOpen

IntechOpen



## **Hepatocellular Carcinoma - Clinical Research**

Edited by Dr. Joseph W.Y. Lau

ISBN 978-953-51-0112-3

Hard cover, 330 pages

**Publisher** InTech

**Published online** 02, March, 2012

**Published in print edition** March, 2012

This book covers the clinical aspects of hepatocellular carcinoma. This book is a compendium of papers written by experts from different parts of the world to present the most up-to-date knowledge on the clinical aspects of hepatocellular carcinoma. This book is divided into three sections: (I) Diagnosis / Differential Diagnosis; (II) Surgical Treatment; (III) Non-surgical Treatment. There are 19 chapters covering topics from novel diagnostic methods to hepatic lesions mimicking hepatocellular carcinoma, from laparoscopic liver resection to major hepatectomy without allogeneic blood transfusion, from molecular targeted therapy to transarterial radioembolization, and from local ablative therapy to regional therapy. This volume is an important contribution to the clinical management of patients with hepatocellular carcinoma. The intended readers of this book are clinicians who are interested in hepatocellular carcinoma, including hepatologists, liver surgeons, interventional and diagnostic radiologists, pathologists and epidemiologists. General surgeons, general physicians, trainees, hospital administrators, and instruments and drug manufacturers will also find this book useful as a reference.

### **How to reference**

In order to correctly reference this scholarly work, feel free to copy and paste the following:

Kiyoshi Mochizuki (2012). Radiofrequency Ablation for Hepatocellular Carcinoma at the Dome of the Liver: A Review, *Hepatocellular Carcinoma - Clinical Research*, Dr. Joseph W.Y. Lau (Ed.), ISBN: 978-953-51-0112-3, InTech, Available from: <http://www.intechopen.com/books/hepatocellular-carcinoma-clinical-research/radiofrequency-ablation-of-hepatocellular-carcinoma-at-the-dome-of-the-liver-a-review->

**INTech**  
open science | open minds

### **InTech Europe**

University Campus STeP Ri  
Slavka Krautzeka 83/A  
51000 Rijeka, Croatia  
Phone: +385 (51) 770 447  
Fax: +385 (51) 686 166  
[www.intechopen.com](http://www.intechopen.com)

### **InTech China**

Unit 405, Office Block, Hotel Equatorial Shanghai  
No.65, Yan An Road (West), Shanghai, 200040, China  
中国上海市延安西路65号上海国际贵都大饭店办公楼405单元  
Phone: +86-21-62489820  
Fax: +86-21-62489821

© 2012 The Author(s). Licensee IntechOpen. This is an open access article distributed under the terms of the [Creative Commons Attribution 3.0 License](https://creativecommons.org/licenses/by/3.0/), which permits unrestricted use, distribution, and reproduction in any medium, provided the original work is properly cited.

IntechOpen

IntechOpen