

We are IntechOpen, the world's leading publisher of Open Access books Built by scientists, for scientists

6,900

Open access books available

186,000

International authors and editors

200M

Downloads

Our authors are among the

154

Countries delivered to

TOP 1%

most cited scientists

12.2%

Contributors from top 500 universities



WEB OF SCIENCE™

Selection of our books indexed in the Book Citation Index
in Web of Science™ Core Collection (BKCI)

Interested in publishing with us?
Contact book.department@intechopen.com

Numbers displayed above are based on latest data collected.
For more information visit www.intechopen.com



MRS in MS, With and Without Interferon Beta 1a Treatment, to Define the Dynamic Changes of Metabolites in the Brain, and to Monitor Disease Progression

Münire Kılınç Toprak^{1,*}, Banu Çakır²,
E.Meltem Kayahan Ulu² and Zübeyde Arat³

¹*Baskent University, Faculty of Medicine, Department of Neurology,
Fevzi Cakmak Caddesi, Bahcelievler, Ankara*

²*Baskent University, Faculty of Medicine, Department of Radiology, Ankara*

³*Baskent University, Faculty of Medicine, Department of Internal Medicine, Ankara
Turkey*

1. Introduction

Multiple sclerosis (MS) is a common cause of chronic neurological disability in young adults. Magnetic Resonance Imaging (MRI) readily identifies multifocal white matter lesions (WML) that represent areas of demyelination and is thus useful in supporting the diagnosis of MS, even after a single clinical episode (McDonald et al., 2001). MRI is also widely used to monitor disease progression in natural history and in therapeutic trial studies. However, conventional MRI does not detect the subtle histopathological changes that are described in the normal-appearing white matter (NAWM) in patients with MS (Allen & McKeown, 1979; Bitsch et al., 1999). MRS has been used in the evaluation of MS to help further define the nature of the lesions revealed by T2-weighted MRI (Arnold, Matthews, Francis, O'Connor, & Antel, 1992; Arnold et al., 1994; Bitsch et al., 1999; Davie et al., 1997; De Stefano et al., 1995; Fu et al., 1998; Gonen et al., 2000; Matthews et al., 1996; Narayana, Doyle, Lai, & Wolinsky, 1998; Pan et al., 1996; Rooney et al., 1997; Sarchielli et al., 1999; Tourbah et al., 1999; van Walderveen, Barkhof et al., 1999). The measurement of N-acetylaspartic acid (NAA) is thought to be a marker of axonal loss, damage or dysfunction. Many studies (Arnold et al., 1992; Arnold et al., 1994; Davie et al., 1997; De Stefano et al., 1995; Husted et al., 1994; Narayana et al., 1998; (Allen & McKeown, 1979; De Stefano et al., 1995; Fu et al., 1998; Husted et al., 1994; Narayana et al., 1998) have shown a reduction in the absolute concentration of NAA or the NAA/Cr ratio in MS lesions. However, pathological (Allen & McKeown, 1979) and quantitative MRSI studies (Armstrong, Gounot, Rumbach, & Chambrun, 1991; Filippi et al., 1995; Gasperini et al., 1996; Loevner et al., 1995) have shown that in patients with clinically definite MS, abnormalities also occur in the NAWM (Arnold et al., 1992; Davie et al., 1997; Davie et al.,

* Corresponding Author

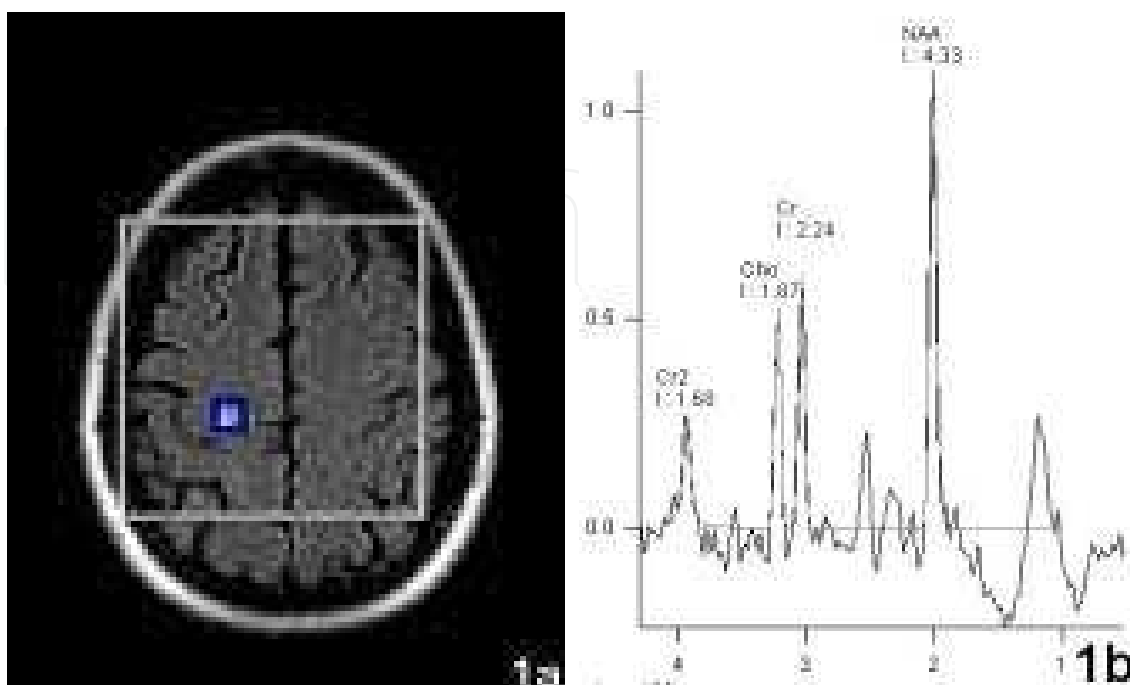
1994; Fu et al., 1998; Husted et al., 1994; Narayana et al., 1998). Although the principal finding of MRS studies in patients with MS was a decrease in the NAA peak area, opposite results were obtained for other metabolites (Davie et al., 1994; Davies, Newcombe, Williams, McDonald, & Clark, 1995; De Stefano et al., 1995; Husted et al., 1994; Larsson et al., 1991). Despite the difficulties in interpreting data obtained in vivo, MRS provides direct information about metabolic variations and the damage to or integrity of myelin and axons, which are not revealed by traditional MRI (Arnold et al., 1994; Ferguson, Matyszak, Esiri, & Perry, 1997; Fernando et al., 2004).

In patients with relapsing remitting multiple sclerosis (RRMS), interferons reduce the attack frequency of the disease, the mean attack duration, the annual lesion burden, and the frequency of gadolinium (Gd) enhancement on MRI. However the mechanism of action of interferons in patients with MS and the effect of interferons on axonal injury remain undefined. We questioned whether treatment with interferon beta-1a (INF β -1a) would enable the recovery of injured axons. To determine this, we used MRSI to examine changes in the metabolic peaks of neuronal markers NAA, Cho (Choline), and Cr (Creatine) after treatment with INF β -1a (Rebif 44 μ g) in a small group of patients with RRMS. An untreated group was studied for comparison, and healthy volunteers were used as controls.

2. Materials and methods

2.1 Patients and methods

We studied 10 patients (7 women 3 men) with clinically definite RRMS (median age, 39 years; age range 22-50 years). The median expanded status scale score (EDSS) was 2.1 (range 1.0-3.0), and the median duration of disease was 4.7 years (range, 1-20 years). In the 2 years before their participation in the study, all patients had had at least one relapse. None of the patients had undergone immunosuppressant therapy ever before, or corticosteroid treatment within 2 months before the initiation of the study. Five patients elected not to be



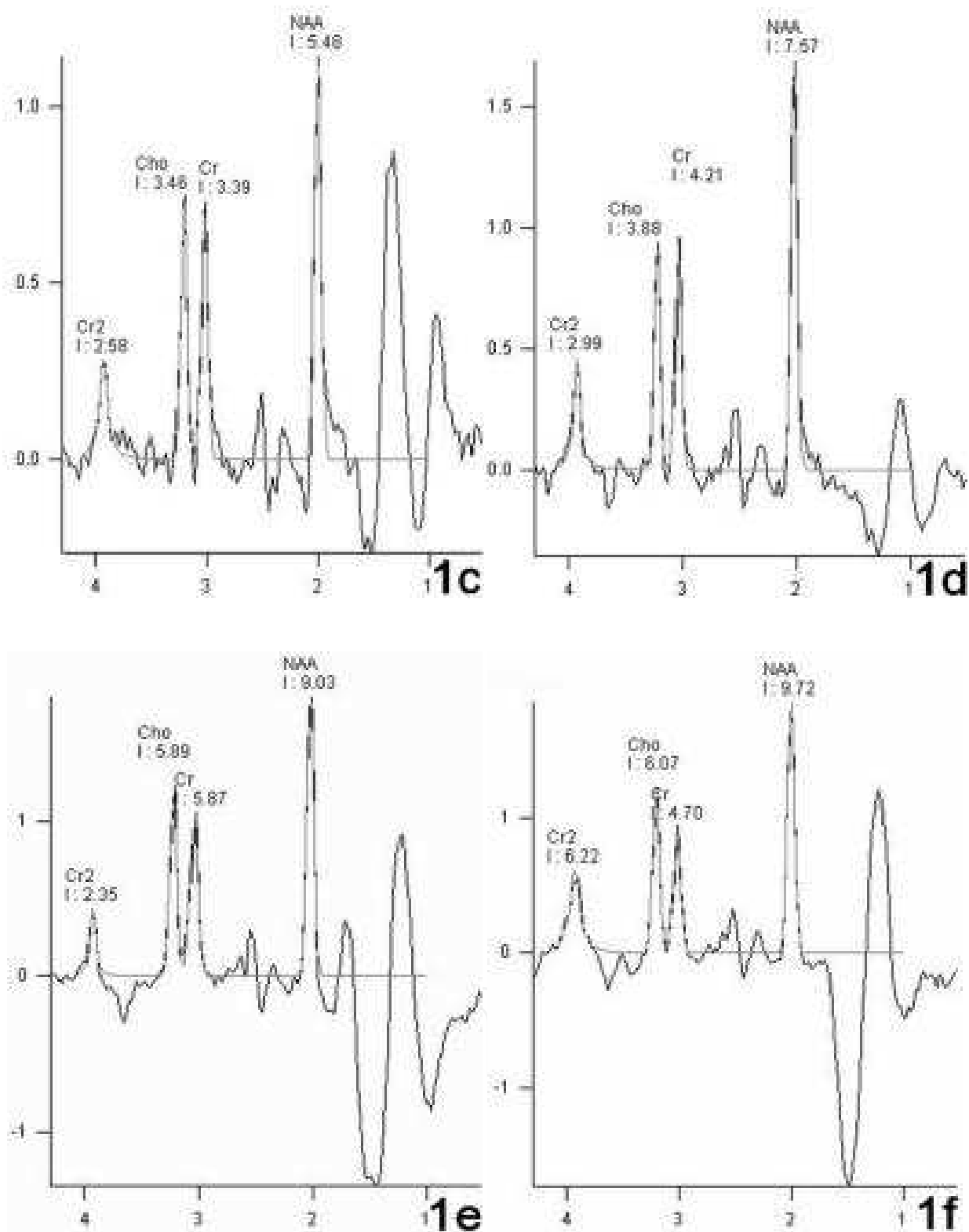


Fig. 1. a-f: Axial fluid-attenuated, inversion recovery (FLAIR) MR image of a 50-year-old woman receiving INF β -1a treatment shows a voxel placed over a WM lesion in the right centrum semiovale (1a). The multivoxel CSI MRI spectrum of this lesion is obtained during study months zero, 1, 3, 6, and 12 (b-f). The results of proton MRSI show that there is a statistically significant increment in absolute NAA and Cho values.

treated. Five other patients received INF β -1a treatment. All patients were evaluated at the beginning of the study and during the first, third, sixth, and twelfth month. During their follow-up evaluations, neurological examinations that included EDSS assessment were performed in addition to MR studies with gadopentetate dimeglumine (Gd) 0.1 mmol/kg intravenously, and MRSI (Figure 1a-f). A relapse was defined as the appearance of new neurological symptoms or worsening of prior neurological symptoms of 48 hours' duration in addition to objective evidence of a change in neurological status of a patient who has been clinically stable for the 4 prior weeks. All patients suspected of having an attack were examined within 7 days of the onset of symptoms and were treated with intravenous methylprednisolone (IVMP) at a dose of 1 g/day for 5 days. At the beginning of the study, MRI and MRSI studies were also performed on 6 healthy, age-matched and sex-matched control subjects (4 women, 2 men; median age, 33.6 years, age range, 27-48 years) who had neither systemic nor neurologic disease. The local ethics committee approved the study.

2.1.1 MRI studies

All MRI and MRSI studies were performed with a 1.5 Tesla MR unit (Siemens Magnetom Symphony, Erlangen, Germany) with a standard quadrature head coil. To detect focal WM lesions, we used conventional MRI, including axial T1 weighted (TR 586 ms, TE 15 ms, 5 mm slice thickness), fluid-attenuated, inversion recovery (FLAIR) (TR 9000 ms, TE 98 ms, 5 mm slice thickness), axial and sagittal proton density (TR 2200 ms, TE 30 ms, 5 mm slice thickness), T2-weighted spin echo sequences (TR 2200 ms, TE 80 ms, 5 mm slice thickness) and post-gadolinium axial and sagittal T1 weighted (TR 779 ms, TE 15 ms, 5 mm slice thickness) spin echo sequences. MRI images were acquired with a matrix size of 145x256 mm and FOV of 230x230 mm. During the same session, water-suppressed proton MRSI was performed by means of multivoxel chemical shift imaging (TR/TE: 1500/135, voxel volume 1 cm³). Metabolite peaks of NAA, Cho, and Cr were assessed in both WML -without Gd enhancement- and in NAWM.

2.1.2 Statistics

SPSS 11 for Windows was used for statistical analysis. The Kruskal-Wallis Test was used to compare the basal NAWM metabolite peaks among treated, untreated and healthy control subjects. The Mann-Whitney U test was used to compare the basal WML metabolite peaks in treated and untreated patients. Then, multivariate analysis of variance (MANOVA) was used to compare the NAWM and WML metabolite peaks in treated and untreated patients throughout the study period. The Wilcoxon signed rank test was used to compare changes in the NAWM and WML metabolite peaks during study months zero, 1, 3, 6, and 12. Results with $p < .05$ were considered as significant.

3. Results

3.1 Treatment effect as assessed by relapse rate, and new T2 lesions with and without GD enhancement

Five patients (3 women and 2 men) elected not to be treated. Four of those 5 patients experienced no attacks during the 12 months of the study. However, the results of MRI examination revealed new Gd-enhancing lesions without a trace of an accompanying

clinical MS attack at the initiation of the study in 3 patients during the sixth month of the study. The results of serial MR examinations of another patient revealed new T2 lesions without Gd-enhancement that were present without evidence of a clinical MS attack from the initiation of the study until the twelfth study month. However, during the twelfth month, that patient experienced a clinical MS attack (moderate paresis [4/5] of the left leg), and a new Gd-enhancing lesion was identified. And only that patient received pulse steroid therapy once daily for 5 days.

Five other patients received INFβ-1a treatment (subcutaneous INFβ-1a 44 µg –Rebif-3 times per week). Among the subjects who received INFβ, two patients had Gd-enhancing new T2 lesions on almost every MRI examination, another patient had a Gd-enhancing lesion only on the last MRI examination of the study, and the remaining patients exhibited no new lesions. None of those patients experienced a clinical MS attack accompanying the MRI activities. There was no significant change in the EDSS scores of the patients in either group throughout the study.

3.2 MRSI results

There was no statistically significant difference between the basal metabolite levels in the NAWM of patients with MS and the healthy control subjects (*P* > .005) (Table 1). There was also no statistically significant difference between the basal metabolite peaks in the WML between the untreated and treated MS patients (Table 2).

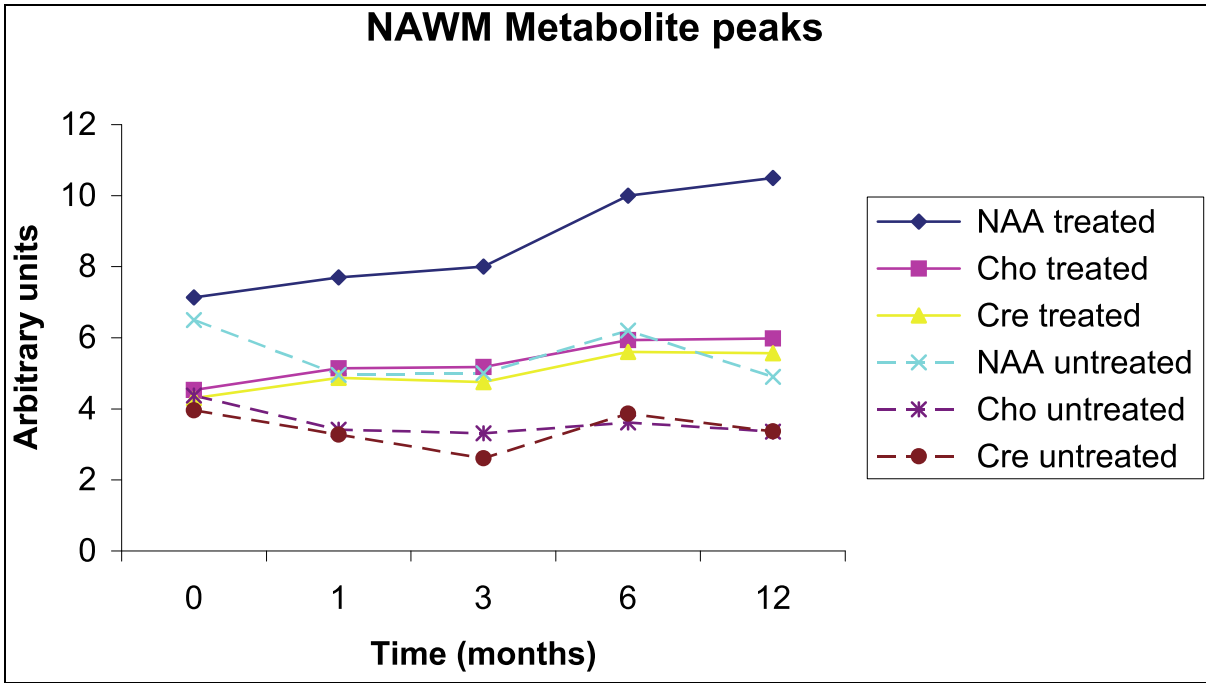
NAWM metabolic peaks		NAA Basal	CHO Basal	CR Basal
Untreated	Mean	6,5±4,6	4,3±1,9	3,9±1,8
	Median	4,8950	3,4650	3,1650
Treated	Mean	7,1±2,3	4,5±1,4	4,3±1,3
	Median	7,8100	4,7550	4,5200
Control	Mean	6,8±0,4	4,1±0,7	4,0±0,2
	Median	6,9250	4,2900	3,9800
WML metabolic peaks		NAA Basal	CHO Basal	CR Basal
Untreated	Mean	6,0±3,7	4,4±1,9	3,8±1,8
	Median	4,8900	4,6700	3,1900
Treated	Mean	6,8±2,5	4,8±1,6	3,9±1,2
	Median	5,4800	5,0950	3,7900

NAA: N-acetyl aspartate, Cho: Choline, Cr: Creatine

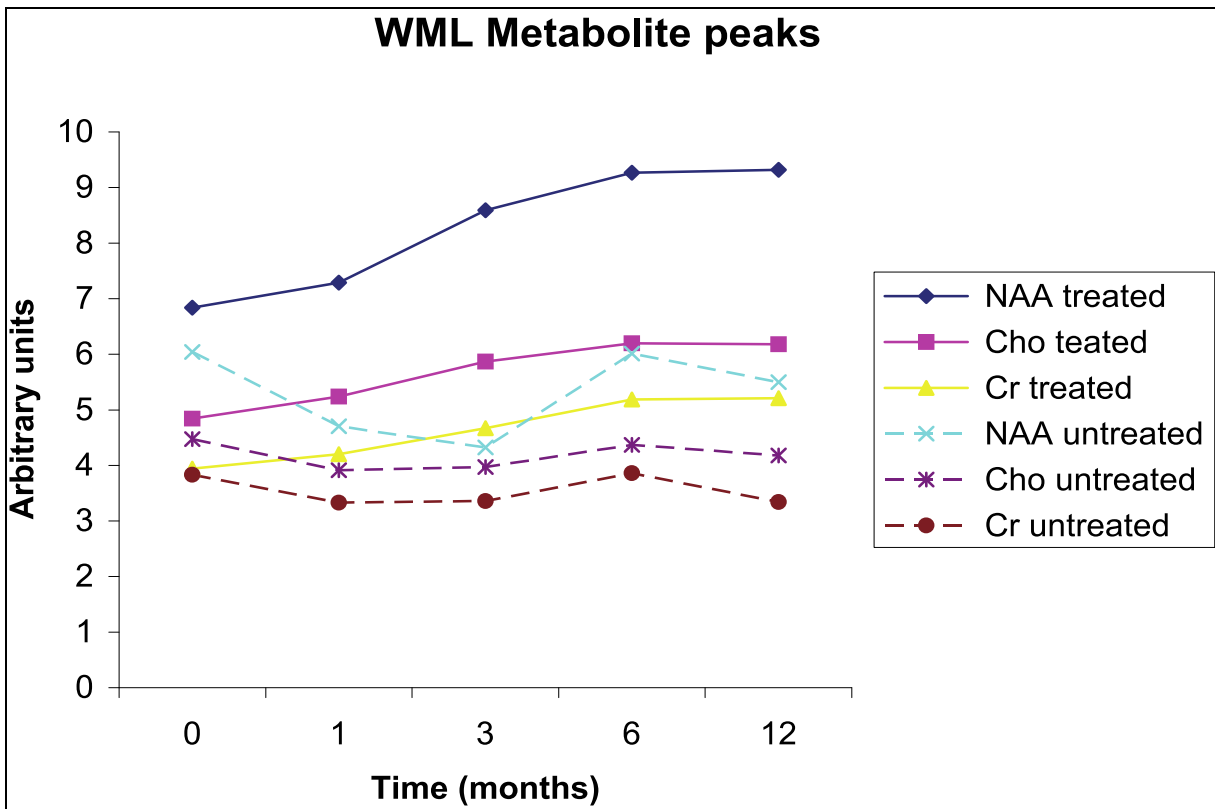
Table 1. Basal normal-appearing white matter and white matter metabolite levels in treated and untreated patients and controls

We analyzed whether any difference emerged in the NAWM metabolite peaks between the treated and untreated patients throughout the study period and found that a significant difference existed in NAWM NAA peaks (*P* = .003); Cho peaks (*P* = .001); and Cr peaks (*P* = .006) beginning from the first month of the study. When we evaluated the groups separately to assess when that difference emerged between the basal and the following months' NAA, Cho and Cr peaks we noted that in the treatment group, the NAA peaks began to increase during the sixth month (*P* = .000); Cho peaks increased during the sixth and twelfth months (*P* = .000); and an increment in the Cr peak was found in the third (*P* < .04), sixth (*P* = .001), and twelfth

study months ($P = .00$). However, in the untreated group, none of the NAA, Cho or Cr peaks (in NAWM) varied significantly during the entire study period ($P > .05$) (Graphic 1).



Graphic 1.



Graphic 2.

We found a significant difference between the changes in WML NAA ($P = .001$), Cho ($P = .025$); and Cr ($P = .031$) peaks of untreated and treated patients, beginning from the first month. When we evaluated the groups separately to determine when the difference emerged between the basal WML NAA peaks and the following months' NAA peaks, we noted that the NAA peaks started to increase during the sixth month in the treatment group ($P = .001$); the Cho peak started to increase during the first month ($P = .03$); and the Cr peak began to increase during the third month in the treatment group ($P = .04$). However, NAA, Cho or Cr peaks did not vary significantly in WML over the entire period of study in the untreated group ($P > .05$) (Graphic 2).

4. Discussion

In this study, variations in cerebral metabolites were assessed during treatment with INF β -1a in a small group of patients with RRMS, and the results were compared with those in untreated patients matched for age and disability. We used the absolute quantification of the metabolites. The use of ratios is potentially less sensitive to the effects of disease in MS than is the use of absolute values; measurement error may be increased when two measures rather than one are required (Fernando et al., 2004). The use of the ratio to Cr also requires the assumption that Cr is normal in the patients' NAWM. However, there have been reports of abnormalities of Cr levels in demyelinating lesions and in the NAWM in patients with MS (Brex et al., 1999; Pan et al., 1996; Rooney et al., 1997; Suhy et al., 2000; van Walderveen, Truyen et al., 1999). Pan and colleagues found an isolated increase in Cr without a change in the level of Cho or NAA in the NAWM (Pan et al., 1996) of patients with MS. An increase in Cr was also found in a clinically isolated syndrome (CIS) group (Fernando et al., 2004). In that study, an increase in Cr was found in a subgroup of subjects with abnormal T2-weighted MRI results and in those with MS defined according to the McDonald criteria (Fernando et al., 2004). Those studies suggest that Cr may not be a reliable internal standard for use in the investigation of the effects of demyelinating disease upon metabolite concentrations.

We have found no significant difference between the basal metabolite peak areas of NAA, Cho and Cr in the NAWM of patients with MS and that of healthy controls ($P > .005$). This was attributed to the patients' having been on relatively early stages of the disease (primarily 2-5 years after diagnosis) and their low EDSS levels. Those factors indicate that widespread axonal damage either had not occurred or was not detectable at this stage and that the reduced NAA found in established MS is acquired later in the disease course. In a study, when 15 clinically isolated syndrome patients with T2 abnormalities were considered separately, their NAWM NAA concentrations were not found to be significantly different from those in controls (Brex et al., 1999). In our study, there was no significant difference between NAWM metabolite peaks of the treated and untreated groups in the results of the initial MRSI ($P > .005$) showing that the 2 patient groups were homogenous. We found that in the treatment group, NAWM NAA and Cho peaks began to increase during the sixth month, and that Cr peaks began to increase during the third month. No change was observed in the untreated group. When we evaluated WML metabolite changes, we found that in the treatment group, NAA and Cr peaks began to increase during the third month and Cho peaks began to increase during the first month. No changes in the metabolite peak areas of WML were observed in the untreated group.

There are a number of possible explanations for the increase in NAA that occurred between the sixth and twelfth months of treatment. Chronic low-grade encephalitis is probably present in patients with MS. There is pathological evidence of an increase in inflammatory cells in the NAWM of such patients (Allen & McKeown, 1979). The results of studies using Gd-enhanced MRI suggest that the blood-brain barrier is diffusely impaired in patients with MS. This chronic, low-level inflammation could result in widespread, partially reversible axonal damage and loss, and INF β could induce its reversal.

A number of tissue injury mediating factors have been implicated in the production of the symptoms of MS (Moreau et al., 1996). INF β directly or indirectly inhibits both the production of a number of those associated inflammatory factors (including interferon gamma) and the ability of those factors to stimulate nitric oxide release from astrocytes (Stewart et al., 1997). Elevated nitric oxide production and the consequent damage to mitochondria in surrounding neurons may be mitigated by INF β and this could be a mechanism of action of INF β in patients with MS (Stewart, Land, Clark, & Heales, 1998). NAA is produced by neuronal mitochondria (Patel & Clark, 1979), this could explain the recovery of NAA in patients with MS who are treated with INF β . The increase in NAA could also be associated with the reversal of axonal metabolic dysfunction that is associated with in apparent myelin pathology in the NAWM.

In this study, one of the principal effects, which seems to be due to INF β -1a, was an increase in the total Cho peak, which in the NAWM became evident during the sixth month of treatment and persisted through the twelfth month, and in the WML became evident during the first month of treatment then persisted throughout the study period. Choline-containing compounds are considered to be turnover products of cell membranes, and an increase in the level of Cho seems to be related primarily to inflammatory and glial cell proliferation rather than to myelin destruction. This observation was confirmed in a histopathological and spectroscopic correlative study in EAE, the results of which showed that a high Cho was associated with inflammation and not with demyelination. Furthermore, glial proliferation in bioptic samples from patients with MS was consistent with an in vivo increase in Cho (Brenner et al., 1993). An increased level of Cho has been described in MS lesions in a variety of studies (Bitsch et al., 1999; Davie et al., 1994; Kapeller et al., 2001; Narayana et al., 1998). Myelin and membrane constituents make a major contribution to the constituent of Cho; therefore, increased lesion cellularity and turn over may account for the observed increase in the level of Cho. However, an increase in Cho has been interpreted as an index of active or recent demyelination by some authors (Confort-Gouny et al., 1993; Davie et al., 1994; Kapeller et al., 2001; Larsson et al., 1991), an association suggested by the finding of an abundance of Cho-containing compounds in myelin and in all cell membranes, including those of inflammatory cells, in patients with MS (Brenner et al., 1993). This increase in the level of Cho may occur without significant clinical deterioration or disease activity. In a recent study, an increase in metabolite concentrations of Cho and Cr was found in CIS NAWM (Fernando et al., 2004). H-MRS-visible Cho containing compounds are derived primarily from cell membranes and may be elevated when there is increased cell turnover. Because the relation between the variations in Cho levels and the pathological changes in underlying lesions is not very well known at the moment, it cannot be excluded that the rise in Cho peak could express an increased turnover of myelin in the plaques and NAWM examined, a turnover that may not be the result of new demyelination, but the consequence of the remodeling of plaques or the effects of a remyelination process.

Although an increase in the Cr level has been found in the NAWM of patients with MS (Brex et al., 1999; Rooney et al., 1997; Suhy et al., 2000; van Walderveen, Barkhof et al., 1999), some experts do not agree on the fluctuations of that metabolite in MS lesions. However, some authors have reported a decrease in total Cr (van Walderveen, Barkhof et al., 1999); others have reported an increase (Kapeller et al., 2001; Suhy et al., 2000). It has been suggested that apart from the axonal damage occurring in the NAWM of patients with MS, there is a proliferation of glial cells that produces an increase in the Cr level (Pan et al., 1996; van Walderveen, Barkhof et al., 1999). When working at 4.1tesla with 0.5 voxels, Pan and colleagues found an isolated increase in the Cr level without concomitant changes in Cho or NAA levels in the WM far from the WM lesions and suggested that in NAWM, there may have been reactive astrogliosis without inflammatory changes. It has been postulated that an increase in the Cr level may reflect an astrocytic (gliotic) or oligodendrocytic remyelinating process. Histological evidence confirms that gliosis is the most common abnormality in macroscopically normal WM of patients with MS. Thus the MRSI abnormalities observed in such patients may be due to the effect of microscopic lesions below the resolution of the images (Rooney et al., 1997; Suhy et al., 2000). However, the increase in Cr along with Cho levels in NAWM and WM may also be accounted for an increase in metabolism, which might be expected to occur with inflammatory or glial reactive features like those in the NAWM of patients with MS.

There are some limitations of our study: The small number of patients, the short duration of study, an open label design, and the patients' being either in relatively early stages of disease or experiencing a relatively benign course of MS. However the numbers of patients in relatively early stages of the disease are more or less similar between the groups, and again the ones with a relatively benign form are again similarly distributed between the groups. Therefore we do not consider that this would have caused a bias in our results. It would have been better if the study were performed with a greater number of patients along with a longer study period. However we could not perform such a more desirable study design because of ethical problems.

5. Conclusions

Our results showed that NAA, Cho and Cr in a VOI that predominantly contains NAWM increased in patients with MS after 1 year of treatment with INFβ-1a. The same effect was also observed in WML after treatment. This evidence supports the theory that although axonal pathology begins early in the course of MS, INFβ-1a therapy may reverse part of that early axonal and metabolic dysfunction, and thus inhibit permanent axonal loss. Follow-up studies could help to define the dynamic changes of metabolites in MS plaques and to monitor the disease progression in MS.

6. References


- Allen, I. V., & McKeown, S. R. (1979). A histological, histochemical and biochemical study of the macroscopically normal white matter in multiple sclerosis. *J Neurol Sci*, 41(1), 81-91.

- Armstrong, J. P., Gounot, D., Rumbach, L., & Chambron, J. (1991). In vivo determination of multiexponential T2 relaxation in the brain of patients with multiple sclerosis. *Magn Reson Imaging*, 9(1), 107-113.
- Arnold, D. L., Matthews, P. M., Francis, G. S., O'Connor, J., & Antel, J. P. (1992). Proton magnetic resonance spectroscopic imaging for metabolic characterization of demyelinating plaques. *Ann Neurol*, 31(3), 235-241.
- Arnold, D. L., Riess, G. T., Matthews, P. M., Francis, G. S., Collins, D. L., Wolfson, C., et al. (1994). Use of proton magnetic resonance spectroscopy for monitoring disease progression in multiple sclerosis. *Ann Neurol*, 36(1), 76-82.
- Bitsch, A., Bruhn, H., Vougioukas, V., Stringaris, A., Lassmann, H., Frahm, J., et al. (1999). Inflammatory CNS demyelination: histopathologic correlation with in vivo quantitative proton MR spectroscopy. *AJNR Am J Neuroradiol*, 20(9), 1619-1627.
- Brenner, R. E., Munro, P. M., Williams, S. C., Bell, J. D., Barker, G. J., Hawkins, C. P., et al. (1993). The proton NMR spectrum in acute EAE: the significance of the change in the Cho:Cr ratio. *Magn Reson Med*, 29(6), 737-745.
- Brex, P. A., Gomez-Anson, B., Parker, G. J., Molyneux, P. D., Mischkiel, K. A., Barker, G. J., et al. (1999). Proton MR spectroscopy in clinically isolated syndromes suggestive of multiple sclerosis. *J Neurol Sci*, 166(1), 16-22.
- Confort-Gouny, S., Vion-Dury, J., Nicoli, F., Dano, P., Donnet, A., Grazziani, N., et al. (1993). A multiparametric data analysis showing the potential of localized proton MR spectroscopy of the brain in the metabolic characterization of neurological diseases. *J Neurol Sci*, 118(2), 123-133.
- Davie, C. A., Barker, G. J., Thompson, A. J., Tofts, P. S., McDonald, W. I., & Miller, D. H. (1997). ¹H magnetic resonance spectroscopy of chronic cerebral white matter lesions and normal appearing white matter in multiple sclerosis. *J Neurol Neurosurg Psychiatry*, 63(6), 736-742.
- Davie, C. A., Hawkins, C. P., Barker, G. J., Brennan, A., Tofts, P. S., Miller, D. H., et al. (1994). Serial proton magnetic resonance spectroscopy in acute multiple sclerosis lesions. *Brain*, 117 (Pt 1), 49-58.
- Davies, S. E., Newcombe, J., Williams, S. R., McDonald, W. I., & Clark, J. B. (1995). High resolution proton NMR spectroscopy of multiple sclerosis lesions. *J Neurochem*, 64(2), 742-748.
- De Stefano, N., Matthews, P. M., Antel, J. P., Preul, M., Francis, G., & Arnold, D. L. (1995). Chemical pathology of acute demyelinating lesions and its correlation with disability. *Ann Neurol*, 38(6), 901-909.
- Ferguson, B., Matyszak, M. K., Esiri, M. M., & Perry, V. H. (1997). Axonal damage in acute multiple sclerosis lesions. *Brain*, 120 (Pt 3), 393-399.
- Fernando, K. T., McLean, M. A., Chard, D. T., MacManus, D. G., Dalton, C. M., Mischkiel, K. A., et al. (2004). Elevated white matter myo-inositol in clinically isolated syndromes suggestive of multiple sclerosis. *Brain*, 127(Pt 6), 1361-1369.
- Filippi, M., Campi, A., Dousset, V., Baratti, C., Martinelli, V., Canal, N., et al. (1995). A magnetization transfer imaging study of normal-appearing white matter in multiple sclerosis. *Neurology*, 45(3 Pt 1), 478-482.
- Fu, L., Matthews, P. M., De Stefano, N., Worsley, K. J., Narayanan, S., Francis, G. S., et al. (1998). Imaging axonal damage of normal-appearing white matter in multiple sclerosis. *Brain*, 121 (Pt 1), 103-113.

- Gasperini, C., Horsfield, M. A., Thorpe, J. W., Kidd, D., Barker, G. J., Tofts, P. S., et al. (1996). Macroscopic and microscopic assessments of disease burden by MRI in multiple sclerosis: relationship to clinical parameters. *J Magn Reson Imaging*, 6(4), 580-584.
- Gonen, O., Catalaa, I., Babb, J. S., Ge, Y., Mannon, L. J., Kolson, D. L., et al. (2000). Total brain N-acetylaspartate: a new measure of disease load in MS. *Neurology*, 54(1), 15-19.
- Husted, C. A., Goodin, D. S., Hugg, J. W., Maudsley, A. A., Tsuruda, J. S., de Bie, S. H., et al. (1994). Biochemical alterations in multiple sclerosis lesions and normal-appearing white matter detected by in vivo ³¹P and ¹H spectroscopic imaging. *Ann Neurol*, 36(2), 157-165.
- Kapeller, P., McLean, M. A., Griffin, C. M., Chard, D., Parker, G. J., Barker, G. J., et al. (2001). Preliminary evidence for neuronal damage in cortical grey matter and normal appearing white matter in short duration relapsing-remitting multiple sclerosis: a quantitative MR spectroscopic imaging study. *J Neurol*, 248(2), 131-138.
- Larsson, H. B., Christiansen, P., Jensen, M., Frederiksen, J., Heltberg, A., Olesen, J., et al. (1991). Localized in vivo proton spectroscopy in the brain of patients with multiple sclerosis. *Magn Reson Med*, 22(1), 23-31.
- Loevner, L. A., Grossman, R. I., Cohen, J. A., Lexa, F. J., Kessler, D., & Kolson, D. L. (1995). Microscopic disease in normal-appearing white matter on conventional MR images in patients with multiple sclerosis: assessment with magnetization-transfer measurements. *Radiology*, 196(2), 511-515.
- Matthews, P. M., Pioro, E., Narayanan, S., De Stefano, N., Fu, L., Francis, G., et al. (1996). Assessment of lesion pathology in multiple sclerosis using quantitative MRI morphometry and magnetic resonance spectroscopy. *Brain*, 119 (Pt 3), 715-722.
- McDonald, W. I., Compston, A., Edan, G., Goodkin, D., Hartung, H. P., Lublin, F. D., et al. (2001). Recommended diagnostic criteria for multiple sclerosis: guidelines from the International Panel on the diagnosis of multiple sclerosis. *Ann Neurol*, 50(1), 121-127.
- Moreau, T., Coles, A., Wing, M., Isaacs, J., Hale, G., Waldmann, H., et al. (1996). Transient increase in symptoms associated with cytokine release in patients with multiple sclerosis. *Brain*, 119 (Pt 1), 225-237.
- Narayana, P. A., Doyle, T. J., Lai, D., & Wolinsky, J. S. (1998). Serial proton magnetic resonance spectroscopic imaging, contrast-enhanced magnetic resonance imaging, and quantitative lesion volumetry in multiple sclerosis. *Ann Neurol*, 43(1), 56-71.
- Pan, J. W., Hetherington, H. P., Vaughan, J. T., Mitchell, G., Pohost, G. M., & Whitaker, J. N. (1996). Evaluation of multiple sclerosis by ¹H spectroscopic imaging at 4.1 T. *Magn Reson Med*, 36(1), 72-77.
- Patel, T. B., & Clark, J. B. (1979). Synthesis of N-acetyl-L-aspartate by rat brain mitochondria and its involvement in mitochondrial/cytosolic carbon transport. *Biochem J*, 184(3), 539-546.
- Rooney, W. D., Goodkin, D. E., Schuff, N., Meyerhoff, D. J., Norman, D., & Weiner, M. W. (1997). ¹H MRSI of normal appearing white matter in multiple sclerosis. *Mult Scler*, 3(4), 231-237.
- Sarchielli, P., Presciutti, O., Pelliccioli, G. P., Tarducci, R., Gobbi, G., Chiarini, P., et al. (1999). Absolute quantification of brain metabolites by proton magnetic resonance spectroscopy in normal-appearing white matter of multiple sclerosis patients. *Brain*, 122 (Pt 3), 513-521.

- Stewart, V. C., Giovannoni, G., Land, J. M., McDonald, W. I., Clark, J. B., & Heales, S. J. (1997). Pretreatment of astrocytes with interferon-alpha/beta impairs interferon-gamma induction of nitric oxide synthase. *J Neurochem*, 68(6), 2547-2551.
- Stewart, V. C., Land, J. M., Clark, J. B., & Heales, S. J. (1998). Pretreatment of astrocytes with interferon-alpha/beta prevents neuronal mitochondrial respiratory chain damage. *J Neurochem*, 70(1), 432-434.
- Suhy, J., Rooney, W. D., Goodkin, D. E., Capizzano, A. A., Soher, B. J., Maudsley, A. A., et al. (2000). ¹H MRSI comparison of white matter and lesions in primary progressive and relapsing-remitting MS. *Mult Scler*, 6(3), 148-155.
- Tourbah, A., Stievenart, J. L., Gout, O., Fontaine, B., Liblau, R., Lubetzki, C., et al. (1999). Localized proton magnetic resonance spectroscopy in relapsing remitting versus secondary progressive multiple sclerosis. *Neurology*, 53(5), 1091-1097.
- van Walderveen, M. A., Barkhof, F., Pouwels, P. J., van Schijndel, R. A., Polman, C. H., & Castelijns, J. A. (1999). Neuronal damage in T1-hypointense multiple sclerosis lesions demonstrated in vivo using proton magnetic resonance spectroscopy. *Ann Neurol*, 46(1), 79-87.
- van Walderveen, M. A., Truyen, L., van Oosten, B. W., Castelijns, J. A., Lycklama a Nijeholt, G. J., van Waesberghe, J. H., et al. (1999). Development of hypointense lesions on T1-weighted spin-echo magnetic resonance images in multiple sclerosis: relation to inflammatory activity. *Arch Neurol*, 56(3), 345-351.

IntechOpen



Magnetic Resonance Spectroscopy

Edited by Prof. Dong-Hyun Kim

ISBN 978-953-51-0065-2

Hard cover, 264 pages

Publisher InTech

Published online 02, March, 2012

Published in print edition March, 2012

Magnetic Resonance Spectroscopy (MRS) is a unique tool to probe the biochemistry in vivo providing metabolic information non-invasively. Applications using MRS has been found over a broad spectrum in investigating the underlying structures of compounds as well as in determining disease states. In this book, topics of MRS both relevant to the clinic and also those that are beyond the clinical arena are covered. The book consists of two sections. The first section is entitled 'MRS inside the clinic' and is focused on clinical applications of MRS while the second section is entitled 'MRS beyond the clinic' and discusses applications of MRS in other academic fields. Our hope is that through this book, readers can understand the broad applications that NMR and MRS can offer and also that there are enough references to guide the readers for further study in this important topic.

How to reference

In order to correctly reference this scholarly work, feel free to copy and paste the following:

Münire Kılınc Toprak, Banu Çakir, E.Meltem Kayahan Ulu and Zübeyde Arat (2012). MRS in MS, With and Without Interferon Beta 1a Treatment, to Define the Dynamic Changes of Metabolites in the Brain, and to Monitor Disease Progression, Magnetic Resonance Spectroscopy, Prof. Dong-Hyun Kim (Ed.), ISBN: 978-953-51-0065-2, InTech, Available from: <http://www.intechopen.com/books/magnetic-resonance-spectroscopy/mrs-in-ms-with-and-without-interferon-beta-1a-treatment-to-define-the-dynamic-changes-of-metabolites>

INTECH
open science | open minds

InTech Europe

University Campus STeP Ri
Slavka Krautzeka 83/A
51000 Rijeka, Croatia
Phone: +385 (51) 770 447
Fax: +385 (51) 686 166
www.intechopen.com

InTech China

Unit 405, Office Block, Hotel Equatorial Shanghai
No.65, Yan An Road (West), Shanghai, 200040, China
中国上海市延安西路65号上海国际贵都大饭店办公楼405单元
Phone: +86-21-62489820
Fax: +86-21-62489821

© 2012 The Author(s). Licensee IntechOpen. This is an open access article distributed under the terms of the [Creative Commons Attribution 3.0 License](https://creativecommons.org/licenses/by/3.0/), which permits unrestricted use, distribution, and reproduction in any medium, provided the original work is properly cited.

IntechOpen

IntechOpen