

# We are IntechOpen, the world's leading publisher of Open Access books Built by scientists, for scientists

6,900

Open access books available

185,000

International authors and editors

200M

Downloads

Our authors are among the

154

Countries delivered to

TOP 1%

most cited scientists

12.2%

Contributors from top 500 universities



WEB OF SCIENCE™

Selection of our books indexed in the Book Citation Index  
in Web of Science™ Core Collection (BKCI)

Interested in publishing with us?  
Contact [book.department@intechopen.com](mailto:book.department@intechopen.com)

Numbers displayed above are based on latest data collected.  
For more information visit [www.intechopen.com](http://www.intechopen.com)



# Chemotherapy for Large Cell Neuroendocrine Carcinoma of the Lung: Should It Be Treated with the Same Strategy as Small Cell Lung Carcinoma?

Katsuhiko Naoki, Kenzo Soejima, Takashi Sato, Shinnosuke Ikemura,  
Hideki Terai, Ryosuke Satomi, Sohei Nakayama,  
Satoshi Yoda and Koichiro Asano  
*Keio Cancer Center / Division of Respiratory Medicine,  
Department of Internal Medicine, School of Medicine,  
Keio University, Tokyo / Yuai Clinic, Yokohama  
Japan*

## 1. Introduction

Lung cancer is leading cause of cancer death in many advanced countries and one of the challenging malignancies because of poor prognosis. Lung cancer is traditionally divided into two major categories, so called small cell lung carcinoma (SCLC) and non-small cell lung carcinoma (NSCLC) because of distinctive prognostic and treatment strategies between them. On the other hand, there is a spectrum of tumors called pulmonary neuroendocrine (NE) tumors that are thought to originate from neuroendocrine cells in the pulmonary and bronchial epithelium. Until recently, pulmonary NE tumors were classified into three categories, i.e., typical carcinoid (TC), atypical carcinoid (AC), and SCLC. Large cell neuroendocrine carcinoma (LCNEC) of the lung was officially identified by Travis et al. in 1991 as a fourth category, a unique higher grade NSCLC existing between TC and SCLC (Travis et al., 1991). It is often difficult to diagnose LCNEC with small biopsy specimens because accurate diagnosis needs morphological and immunohistochemical information. Although earlier reports mainly focused on prognosis after surgical procedures, several recent studies reported on the efficacy of chemotherapy for advanced LCNEC. Because of the limited numbers of cases (in surgical series, LCNEC represents ~3% of lung cancers), large scale prospective studies have not been reported. Standard treatment for LCNEC, especially if advanced, is not established although LCNEC is included in NSCLC in the treatment algorithm in many guidelines. However, accumulating data including recent retrospective studies have suggested that there is similarity in the prognosis and treatment response between LCNEC and SCLC.

In this review, we will focus on the treatment of advanced LCNEC for the better selection of chemotherapeutic regimens for the patients with this relatively rare lung cancer.

2. Large cell neuroendocrine carcinoma of the lung

LCNEC is classified as a variant of large cell carcinoma in NSCLC whilst LCNEC has neuroendocrine characteristics similar to SCLC such as morphology and the immunohistochemical staining pattern. This discrepancy raises the question as to what the best therapeutic modality is, that is, should we treat LCNEC as NSCLC or SCLC?

	Typical Carcinoid	Atypical Carcinoid	LCNEC	Small cell carcinoma
Morphology	carcinoid	carcinoid	neuroendocrine	neuroendocrine
Mitosis	<2 / 2mm <sup>2</sup> (10HPF)	<2–10 / 2mm <sup>2</sup> (10HPF)	high: >11 / 2mm <sup>2</sup> (10HPF)	high: >11 / 2mm <sup>2</sup> (10HPF)
Necrosis	absent	present (focal punctate)	present (extensive)	present (extensive)
Cytologic features			NSCLC (large cell, low N/C)	small cell, scant cytoplasm
Immunohistochemistry			positive for NE markers	positive for NE markers

Abbreviations: LCNEC, large cell neuroendocrine carcinoma;  
HPF, high power field;  
NSCLC, non-small cell lung carcinoma;  
N/C, nuclear-cytoplasmic ratio;  
NE, neuroendocrine

Table 1. Tumors with neuroendocrine morphology (Travis 2010, Gollard et al., 2010)

Recently, Varlotto et al. reported survival analysis of resected cases with LCNEC and SCLC (Varlotto et al., 2011). They compared overall survival (OS) and lung cancer-specific survival (LCSS) of patients with LCNEC and SCLC or other large cell lung carcinomas (OLCs) using the US National Cancer Institute database (SEER program). Although, the survival rates tended to be better in LCNEC and OLCs compared to SCLC, multivariate analysis showed no statistical differences (4-year OS rates are 41 % in LCNEC, 42% in OLC, and 32% in SCLC; 4-year LCSS rates are 57 % in LCNEC, 54% in OLC, and 42% in SCLC). The SEER database does not include chemotherapy information, so that we do not know the impact of chemotherapy on survival. Other reports also noted that survival in the early stage LCNEC is similar to SCLC (Asamura et al., 2006, Sun et al., 2009) and not better than NSCLC (Iyoda et al., 2007).

3. Chemotherapy for advanced LCNEC

LCNEC is classified in the category of NSCLC pathologically (Brambilla et al., 2001), so that the guideline recommended treatment of advanced LCNEC as NSCLC (NCCN guideline™ 2011), and many trials have included this disease as a NSCLC. However, recent accumulating data have brought new insights regarding possibly better results with SCLC regimens.

From the published literature, we found four major studies showing the treatment results with chemotherapy for advanced LCNEC (Igawa et al., 2010, Fujiwara et al., 2007, Yamazaki et al., 2005, Rossi et al., 2005) (Table 2). All studies were retrospective and a total of 83 patients were treated with first line systemic chemotherapy. Chemotherapy regimens can be classified into two groups: SCLC-based regimens (total n=44; platinum and etoposide n=27, platinum and irinotecan (CPT-11) n=16, CPT-11 only n=1) and NSCLC-based regimens (total n=39; platinum and paclitaxel (PTX) n=11, platinum and gemcitabine n=10, cisplatin with vindesine and mitomycin n=6, cisplatin and vindesine n=4, other platinum doublet n=2, other single agent n=6).

Report				OS	1yr survival	Chemotherapy	Pt	RR
Igawa	2010	Lung Cancer	n=14	10M	34%	total	n=14	50%
						CDDP+CPT11	n=7	57%
						CBDCA+VP16	n=2	50%
						CPT11	n=1	0%
						CBDCA+PTX	n=1	100%
						CDDP+PTX	n=1	100%
						VNR	n=1	0%
						DTX	n=1	0%
Fujiwara	2007	Jpn J Clin Oncol	n=22	10.3M	43.3%	total	n=22	59%
						Platinum+CPT11	n=9	56%
						Platinum+VP16	n=4	25%
						Platinum+PTX	n=6	67%
						PTX	n=1	100%
						CDDP+VNR	n=1	100%
						CDDP+DTX	n=1	100%
Yamazaki	2005	Lung Cancer	n=20	7.9M	35%	total	n=20	50%
						CDDP+VP16	n=9	56%
						MVP	n=6	33%
						CDDP+VDS	n=4	75%
						CDDP	n=1	0%
Rossi	2005	Lung Cancer	n=27	no data	no data	total	n=27	29%
						Platinum+VP16	n=12	50%
						CDDP+GEM	n=10	0%
						CBDCA+PTX	n=3	0%
						GEM	n=2	0%

Abbreviations: OS, overall survival;  
Pt, patient number;  
RR response rate;  
PTX, paclitaxel;  
VNR, vinorelbine;  
DTX, docetaxel;  
MVP, mitomycin + vindesine + cisplatin;  
VDS, vindesine;  
GEM, gemcitabine.

Table 2. Previous report regarding 1<sup>st</sup> line chemotherapy for advanced large cell neuroendocrine cell carcinoma (LCNEC)

The response rate (RR) was 47.7% (21/44) for SCLC-based regimens and 35.9% (14/39) for NSCLC-based regimens (Table 3). In particular, a platinum doublet yielded a RR of 56.3% (9/16) with platinum and CPT-11, 44.4% (12/27) with platinum and etoposide, 54.5% (6/11) with platinum and PTX, 16.7% (2/12) with platinum and other third generation agents.

Rossi et al. (2005) showed a significant survival benefit with a SCLC-based regimen compared with a NSCLC regimen (OS of 51 months (M) vs 21M). This result is far better than other reports (OS 7.9M-10.3M, 1-year survival rate 35-47.6%), suggesting that the result was from combined effects of surgery and chemotherapy.

	Chemotherapy	Pt	RR
SCLC based	total	n=44	48%
	Platinum+VP16	n=27	44%
	Platinum+CPT11	n=16	56%
	CPT11	n=1	0%
NSCLC based	total	n=39	36%
	Platinum+PTX	n=11	55%
	PTX	n=1	100%
	CDDP+VNR	n=1	100%
	VNR	n=1	0%
	CDDP+DTX	n=1	100%
	DTX	n=1	0%
	CDDP+GEM	n=10	0%
	GEM	n=2	0%
	MVP	n=6	33%
	CDDP+VDS	n=4	75%
	CDDP	n=1	0%

(Abbreviations are the same as in Table 1)

Table 3. Summary of previous reports regarding 1<sup>st</sup> line chemotherapy for advanced large cell neuroendocrine cell carcinoma (LCNEC)

As for second line treatment, there is no report other than a recent publication with amrubicin treatment (Yoshida et al., 2011). Amrubicin has efficacy for both SCLC and NSCLC, and has been used commonly in Japan in a second line setting with SCLC. Promising results for SCLC have also been recently reported from the USA (Ettinger et al., 2010, Jotte et al., 2011).

Currently there are a few prospective clinical trials for LCNEC in the 1st line settings (ClinicalTrials.gov and UMIN-CTR Clinical Trial, accessed 2<sup>nd</sup> Aug, 2011). One is not yet open but is an interesting phase II study with RAD001 + carboplatin/paclitaxel for advanced LCNEC. The other is an ongoing phase II study with cisplatin + irinotecan for advanced LCNEC.

The former study with RAD001 is an interesting study utilizing an mTOR inhibitor which inhibits one of the signaling pathways, i.e. the PI3K-mTOR pathway, that lies downstream of receptor tyrosine kinases (RTKs) such as EGFR and c-MET. EGFR is one of the most

Disease	Report	Study	Pt	RR	PFS	OS
LCNEC	Yoshida, 2011	retrospective	n=18	27.7%	3.1M	5.1M
SCLC (sensitive)	Jotte, 2011	prospective	n=50	44%	4.5M	9.2M
SCLC (refractory)	Ettinger, 2010	prospective	n=75	21.3%	3.2M	6.0M
SCLC (sensitive)	Inoue, 2008	prospective	n=9	53%	3.9M	9.9M
SCLC (refractory)			n=2	17%	2.6M	5.3M
SCLC (sensitive)	Onoda, 2006	prospective	n=44	52%	10.3M	11.6M
SCLC (refractory)			n=16	50%	2.6M	4.4M

Table 4. Efficacy of Amrubicin in the 2nd line treatment for LCNEC and SCLC

important RTKs in NSCLC (Paez et al., 2004), and moreover c-MET is reported to be an important RTK in SCLC as well as NSCLC (Nakachi et al., 2010, Rossi et al., 2005, Schmid et al., 2010). RAD001 has limited but apparent antitumor activity against pretreated SCLC as a single agent (Tarhini et al., 2010). According to these results, targeting signaling pathways with cytotoxic agent might be the next challenge for SCLC and LCNEC. Because many of the current effort in NSCLC is searching for driver mutations (Paez et al., 2004, Naoki et al., 2002), such an effort is also important in SCLC and LCNEC.

4. Conclusion

Although there is an issue regarding accurate diagnosis with small biopsy specimens, accumulating retrospective data suggest that patients with advanced LCNEC will benefit from systemic chemotherapy.

The current recommendation for the treatment of advanced LCNEC is similar to that of SCLC, i.e. platinum based combination chemotherapy, mainly with etoposide or CPT-11 and possibly with PTX. Further prospective data is needed to elucidate the best combination therapy.

5. References

Asamura H, Kameya T, Matsuno Y, Noguchi M, Tada H, Ishikawa Y, Yokose T, Jiang SX, Inoue T, Nakagawa K, Tajima K, & Nagai K. Neuroendocrine neoplasms of the lung: a prognostic spectrum. *J Clin Oncol* 2006 Jan 1;24(1):70-6, ISSN 0732-183X

Brambilla E, Travis WD, Colby TV, Corrin B, & Shimosato Y. The new World Health Organization classification of lung tumours. *Eur Respir J* 2001 Dec;18(6):1059-68, ISSN:0903-1936



- Clinical Trials.gov, 2011 Aug,  
<http://clinicaltrials.gov/>
- Ettinger DS, Jotte R, Lorigan P, Gupta V, Garbo L, Alemany C, Conkling P, Spigel DR, Dudek AZ, Shah C, Salgia R, McNally R, Renschler MF, & Oliver JW. Phase II study of amrubicin as second-line therapy in patients with platinum-refractory small-cell lung cancer. *J Clin Oncol* 2010 May 20;28(15):2598-603, ISSN 0732-183X
- Fujiwara Y, Sekine I, Tsuta K, Ohe Y, Kunitoh H, Yamamoto N, Nokihara H, Yamada K, & Tamura T. Effect of platinum combined with irinotecan or paclitaxel against large cell neuroendocrine carcinoma of the lung. *Jpn J Clin Oncol* 2007 Jul;37(7):482-6, ISSN 0368-2811
- Gollard R, Jhatakia S, Elliott M, & Kosty M. Large cell/neuroendocrine carcinoma. *Lung Cancer* 2010 Jul;69(1):13-8, ISSN 0169-5002
- Igawa S, Watanabe R, Ito I, Murakami H, Takahashi T, Nakamura Y, Tsuya A, Kaira K, Naito T, Endo M, Yamamoto N, & Kameya T. Comparison of chemotherapy for unresectable pulmonary high-grade non-small cell neuroendocrine carcinoma and small-cell lung cancer. *Lung Cancer* 2010 Jun;68(3):438-45, ISSN 0169-5002
- Inoue A, Sugawara S, Yamazaki K, Maemondo M, Suzuki T, Gomi K, Takanashi S, Inoue C, Inage M, Yokouchi H, Watanabe H, Tsukamoto T, Saijo Y, Ishimoto O, Hommura F, & Nukiwa T. Randomized phase II trial comparing amrubicin with topotecan in patients with previously treated small-cell lung cancer: North Japan Lung Cancer Study Group Trial 0402. *J Clin Oncol* 2008 Nov 20;26(33):5401-6, ISSN 0732-183X
- Iyoda A, Hiroshima K, Nakatani Y, & Fujisawa T. Pulmonary large cell neuroendocrine carcinoma: its place in the spectrum of pulmonary carcinoma. *Ann Thorac Surg* 2007 Aug;84(2):702-7, ISSN 0003-4975
- Jotte R, Conkling P, Reynolds C, Galsky MD, Klein L, Fitzgibbons JF, McNally R, Renschler MF, & Oliver JW. Randomized phase II trial of single-agent amrubicin or topotecan as second-line treatment in patients with small-cell lung cancer sensitive to first-line platinum-based chemotherapy. *J Clin Oncol*. 2011 Jan 20;29(3):287-93, ISSN 0732-183X
- Nakachi I, Naoki K, Soejima K, Kawada I, Watanabe H, Yasuda H, Nakayama S, Yoda S, Satomi R, Ikemura S, Terai H, Sato T, & Ishizaka A. The combination of multiple receptor tyrosine kinase inhibitor and mammalian target of rapamycin inhibitor overcomes erlotinib resistance in lung cancer cell lines through c-Met inhibition. *Mol Cancer Res* 2010 Aug;8(8):1142-51, ISSN:1541-7786
- Naoki K, Chen TH, Richards WG, Sugarbaker DJ, Meyerson M. Missense mutations of the BRAF gene in human lung adenocarcinoma. *Cancer Res* 2002 Dec 1;62(23):7001-3, ISSN:0008-5472
- Non-Small Cell Lung Cancer, *NCCN Guidelines™*, 2011 Aug,  
[http://www.nccn.org/professionals/physician\\_gls/pdf/nscl.pdf](http://www.nccn.org/professionals/physician_gls/pdf/nscl.pdf)
- Onoda S, Masuda N, Seto T, Eguchi K, Takiguchi Y, Isobe H, Okamoto H, Ogura T, Yokoyama A, Seki N, Asaka-Amano Y, Harada M, Tagawa A, Kunikane H, Yokoba M, Uematsu K, Kuriyama T, Kuroiwa Y, & Watanabe K; Thoracic Oncology

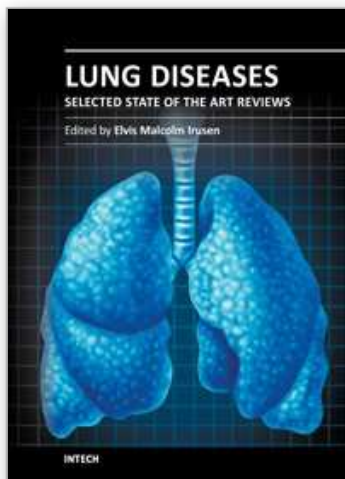
- Research Group Study 0301. Phase II trial of amrubicin for treatment of refractory or relapsed small-cell lung cancer: Thoracic Oncology Research Group Study 0301. *J Clin Oncol* 2006 Dec 1;24(34):5448-53, ISSN 0732-183X
- Paez JG, Jänne PA, Lee JC, Tracy S, Greulich H, Gabriel S, Herman P, Kaye FJ, Lindeman N, Boggon TJ, Naoki K, Sasaki H, Fujii Y, Eck MJ, Sellers WR, Johnson BE, & Meyerson M. EGFR mutations in lung cancer: correlation with clinical response to gefitinib therapy. *Science* 2004 Jun 4;304(5676):1497-500, ISSN:0036-8075
- Rekhtman N. Neuroendocrine tumors of the lung: an update. *Arch Pathol Lab Med* 2010 Nov;134(11):1628-38, ISSN 0003-9985
- Rossi G, Cavazza A, Marchioni A, Longo L, Migaldi M, Sartori G, Bigiani N, Schirosi L, Casali C, Morandi U, Facciolo N, Maiorana A, Bavieri M, Fabbri LM, & Brambilla E. Role of chemotherapy and the receptor tyrosine kinases KIT, PDGFRalpha, PDGFRbeta, and Met in large-cell neuroendocrine carcinoma of the lung. *J Clin Oncol* 2005 Dec 1;23(34):8774-85, ISSN 0732-183X
- Schmid K, Bago-Horvath Z, Berger W, Haitel A, Cejka D, Werzowa J, Filipits M, Herberger B, Hayden H, & Sieghart W. Dual inhibition of EGFR and mTOR pathways in small cell lung cancer. *Br J Cancer* 2010 Aug 24;103(5):622-8, ISSN:0007-0920
- Sun L, Sakurai S, Sano T, Hironaka M, Kawashima O, & Nakajima T. High-grade neuroendocrine carcinoma of the lung: comparative clinicopathological study of large cell neuroendocrine carcinoma and small cell lung carcinoma. *Pathol Int* 2009 Aug; 59(8):522-9, ISSN 1320-5463
- Tarhini A, Kotsakis A, Gooding W, Shuai Y, Petro D, Friedland D, Belani CP, Dacic S, & Argiris A. Phase II study of everolimus (RAD001) in previously treated small cell lung cancer. *Clin Cancer Res* 2010 Dec 1;16(23):5900-7, ISSN:1078-0432
- Travis WD, Linnoila RI, Tsokos MG, Hitchcock CL, Cutler GB Jr, Nieman L, Chrousos G, Pass H, & Doppman J. Neuroendocrine tumors of the lung with proposed criteria for large-cell neuroendocrine carcinoma. An ultrastructural, immunohistochemical, and flow cytometric study of 35 cases. *Am J Surg Pathol* 1991 Jun;15(6):529-53, ISSN 0147-5185
- Travis WD. Advances in neuroendocrine lung tumors. *Ann Oncol* 2010 Oct;21 Suppl 7:vii65-71, ISSN 0923-7534
- UMIN-CTR Clinical Trial, 2011 Aug, <http://www.umin.ac.jp/ctr/>
- Varlotto JM, Medford-Davis LN, Recht A, Flickinger JC, Schaefer E, Zander DS, & DeCamp MM. Should large cell neuroendocrine lung carcinoma be classified and treated as a small cell lung cancer or with other large cell carcinomas? *J Thorac Oncol* 2011 Jun;6(6):1050-8, ISSN 1556-0864
- Yamazaki S, Sekine I, Matsuno Y, Takei H, Yamamoto N, Kunitoh H, Ohe Y, Tamura T, Kodama T, Asamura H, Tsuchiya R, & Saijo N. Clinical responses of large cell neuroendocrine carcinoma of the lung to cisplatin-based chemotherapy. *Lung Cancer* 2005 Aug;49(2):217-23, ISSN 0169-5002



Yoshida H, Sekine I, Tsuta K, Horinouchi H, Nokihara H, Yamamoto N, Kubota K, & Tamura T. Amrubicin Monotherapy for Patients with Previously Treated Advanced Large-cell Neuroendocrine Carcinoma of the Lung. *Jpn J Clin Oncol* 2011 Jul;41(7):897-901, ISSN 0368-2811

IntechOpen

IntechOpen



## **Lung Diseases - Selected State of the Art Reviews**

Edited by Dr. Elvisgran Malcolm Irusen

ISBN 978-953-51-0180-2

Hard cover, 690 pages

**Publisher** InTech

**Published online** 02, March, 2012

**Published in print edition** March, 2012

The developments in molecular medicine are transforming respiratory medicine. Leading clinicians and scientists in the world have brought their knowledge and experience in their contributions to this book. Clinicians and researchers will learn about the most recent advances in a variety of lung diseases that will better enable them to understand respiratory disorders. This treatise presents state of the art essays on airways disease, neoplastic diseases, and pediatric respiratory conditions. Additionally, aspects of immune regulation, respiratory infections, acute lung injury/ARDS, pulmonary edema, functional evaluation in respiratory disorders, and a variety of other conditions are also discussed. The book will be invaluable to clinicians who keep up with the current concepts, improve their diagnostic skills, and understand potential new therapeutic applications in lung diseases, while scientists can contemplate a plethora of new research avenues for exploration.

### **How to reference**

In order to correctly reference this scholarly work, feel free to copy and paste the following:

Katsuhiko Naoki, Kenzo Soejima, Takashi Sato, Shinnosuke Ikemura, Hideki Terai, Ryosuke Satomi, Sohei Nakayama, Satoshi Yoda and Koichiro Asano (2012). Chemotherapy for Large Cell Neuroendocrine Carcinoma of the Lung: Should It Be Treated with the Same Strategy as Small Cell Lung Carcinoma?, Lung Diseases - Selected State of the Art Reviews, Dr. Elvisgran Malcolm Irusen (Ed.), ISBN: 978-953-51-0180-2, InTech, Available from: <http://www.intechopen.com/books/lung-diseases-selected-state-of-the-art-reviews/chemotherapy-for-large-cell-neuroendocrine-carcinoma-of-the-lung-should-it-be-treated-with-the-same->

**INTECH**  
open science | open minds

### **InTech Europe**

University Campus STeP Ri  
Slavka Krautzeka 83/A  
51000 Rijeka, Croatia  
Phone: +385 (51) 770 447  
Fax: +385 (51) 686 166  
[www.intechopen.com](http://www.intechopen.com)

### **InTech China**

Unit 405, Office Block, Hotel Equatorial Shanghai  
No.65, Yan An Road (West), Shanghai, 200040, China  
中国上海市延安西路65号上海国际贵都大饭店办公楼405单元  
Phone: +86-21-62489820  
Fax: +86-21-62489821

© 2012 The Author(s). Licensee IntechOpen. This is an open access article distributed under the terms of the [Creative Commons Attribution 3.0 License](https://creativecommons.org/licenses/by/3.0/), which permits unrestricted use, distribution, and reproduction in any medium, provided the original work is properly cited.

IntechOpen

IntechOpen