

# We are IntechOpen, the world's leading publisher of Open Access books Built by scientists, for scientists

6,900

Open access books available

186,000

International authors and editors

200M

Downloads

Our authors are among the

154

Countries delivered to

TOP 1%

most cited scientists

12.2%

Contributors from top 500 universities



WEB OF SCIENCE™

Selection of our books indexed in the Book Citation Index  
in Web of Science™ Core Collection (BKCI)

Interested in publishing with us?  
Contact [book.department@intechopen.com](mailto:book.department@intechopen.com)

Numbers displayed above are based on latest data collected.  
For more information visit [www.intechopen.com](http://www.intechopen.com)



# Age-Related Changes in Human Skin by Confocal Laser Scanning Microscope

Karine Cucumel, Jean Marie Botto, Nouha Domloge and Claude Dal Farra  
Ashland Specialty Ingredients – Vincience  
France

## 1. Introduction

**Cutaneous aging** is a complex biological phenomenon affecting the different constituents of the skin. Two independent processes, clinical and biological, affect the skin during aging. The first is called “chronological aging” and the second one, “extrinsic aging” or “photoaging”, which is the result of out-door exposure (such as solar irradiation). In this study, we mainly investigated the features of “chronological aging”.

With the advancement of skin research, and the more and more important requests from the cosmetic consumers to have access to technical information on the product efficacy, many non-invasive methods have recently been developed to evaluate and quantify skin-aging parameters. Indeed, numerous available tools allow studying skin-aging as defined by key clinically observed aging parameters such as surface texture, fine lines and wrinkles, skin pigmentation (age spots), firmness, and loss of skin tonicity and elasticity.

In the past decade, laser-scanning confocal microscopy was developed, providing images from *in vivo* human skin without tissue alteration. At the same time, numerous studies comparing and identifying structures imaged by conventional histological sectioning and confocal laser scanning microscope were performed especially by Rajadhyaksha et al., 1995 and Gonzales et al., 2004. Today, the commercially available tool is VivaScope® (Lucid® Inc.), which allows to observe the cellular structure in the whole epidermis, from the *stratum corneum* to the fibrous tissue of superficial dermis, not invasively (without alteration of the tissue), and in real time (without any fixatives). Thanks to the *in vivo* confocal microscopy, a new way to study the signs of age through the epidermis is born. The aim of this chapter was to investigate histometric parameters on several volunteers of different ages in order to better understand the aging process.

## 2. Focus on VivaScope®

### 2.1 Parameters of VivaScope® 1500

Confocal laser scanning microscopy opens a "window into your skin" without damaging the skin. Confocal laser scanning microscopy was performed by using the VivaScope® 1500 (Lucid® Inc.). This method allows the observation of the cutaneous micromorphology *in vivo*; thus, for the first time, a real time optical biopsy is possible.

The principle of *in vivo* confocal laser scanning microscopy consists of a laser that emits, with a wavelength of 830 nm, an illumination power inferior to 35 mW and a water immersion objective. The images obtained using this method have a similar resolution to that of classic microscopy: the lateral resolution is 1.25  $\mu\text{m}$  and the vertical one, about 2  $\mu\text{m}$ . The images are black and white, and parallel to the surface of the skin (Curiel-Lewandrowski et al., 2004; Gerger et al., 2006). In this method, the skin imaging is based on different reflection indices of the micro anatomical structures. Melanin offers the strongest contrast; therefore, the cytoplasm of melanocytes appears very bright. Keratin reflects less intensely, so that the cytoplasm of keratinocytes appears darker. Cell nuclei also appear dark, and collagen very bright (Rajadhyaksha et al., 1995).

This skin imaging technique represents a non-invasive and not painful method, and is not tissue-destructive. All these parameters allow imaging the epidermis up to the papillary dermis at a cellular level without any tissue damage. The skin is unaffected during the preparing procedures, thus minimizing visual artifacts. The data collected in real time are rapidly acquired and processed, and the segment of analyzed skin can be re-examined in order to evaluate the dynamic changes. Image stacks can be obtained by compiling images taken every 2  $\mu\text{m}$ , from the horny layer to the dermis.

Confocal laser scanning microscopy can be used for numerous applications and research areas. The images it produces are especially well suited to assist physicians in performing screening examinations, diagnosing skin cancers, etc. This technology can also be applied in cases of burns, dermatitis, and in the cosmetics research industry (Pierard, 1993; Corcuff et al., 1996; Abramovits et al., 2003; Branzan et al., 2007; Ardigo M. & Gill M., 2008).

## 2.2 VivaScope® 1500 technical performance

Different images, from the *stratum corneum* to the upper part of the dermis, were collected, analyzed, and consecutively transformed into a digital image with different levels of gray. Different measurements can be performed, such as thickness of the *stratum corneum*, of the epidermis, and the number and height of dermal papillae. This paragraph will summarize the methodology to acquire different measurements.

### 2.2.1 Measurement of objective parameters: *Stratum corneum* and epidermis thicknesses

#### 2.2.1.1 *Stratum corneum* thickness

The *stratum corneum* thickness was calculated measuring the intensity variation on vertical reconstruction of the epidermis with the software ImageJ IJ 43 (Abramoff et al., 2004) giving a plot profile. The process is explained in Figure 1. The plot profile gives the intensity of the luminosity at different depths at the place of the yellow line in the vertical reconstruction. (The yellow line is placed by the operating expert). The *stratum corneum* thickness can then be obtained from the graph but can be more precisely obtained by calculating the derivative of the plot profile using finite differences. The depth separation between the maximum and the minimum of the derivative measures the *stratum corneum* thickness. Five measurements were made on one stack per volunteer.

#### 2.2.1.2 Epidermal thickness

The distance between the surface (*stratum corneum*) and the level showing the dermal tissue measures the thickness of the epidermis. In Figure 2, **A** represents the *stratum corneum*

(beginning of the measurement area), **B**, the beginning of the dermal tissue (end of the measurement), and **C**, the measurement done with VivaScope® on H&E. For the epidermis thickness, we performed one measurement per stack, on eight stacks per volunteer. In our experiment, we decided to measure the thickness between interdigitations where the thickness is smaller, i.e. minimal thickness (called Emin).

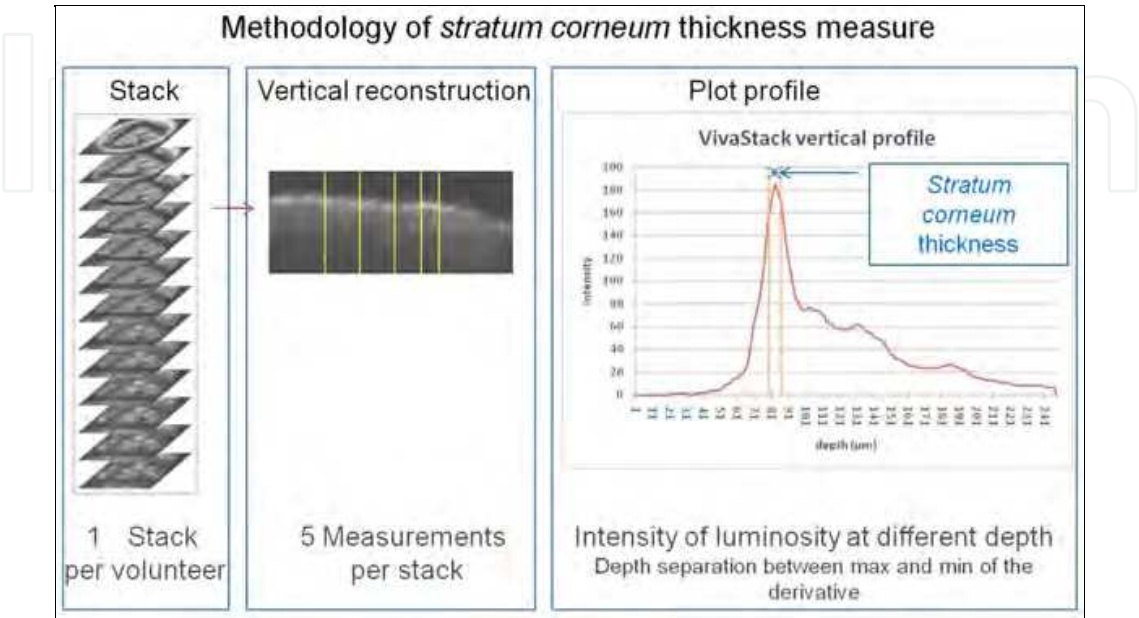


Fig. 1. Methodology of *stratum corneum* thickness measurement: From one volunteer, we collected series of images (stack), then the software provided from the stack a vertical section of the skin, the yellow line was placed by the expert to obtain the measure. The plot profile that gives the intensity at different depth is finally performed with ImageJ software and the calculation of the derivative measurement gave the precise thickness of the *stratum corneum*. Five measurements were made on one stack per volunteer.

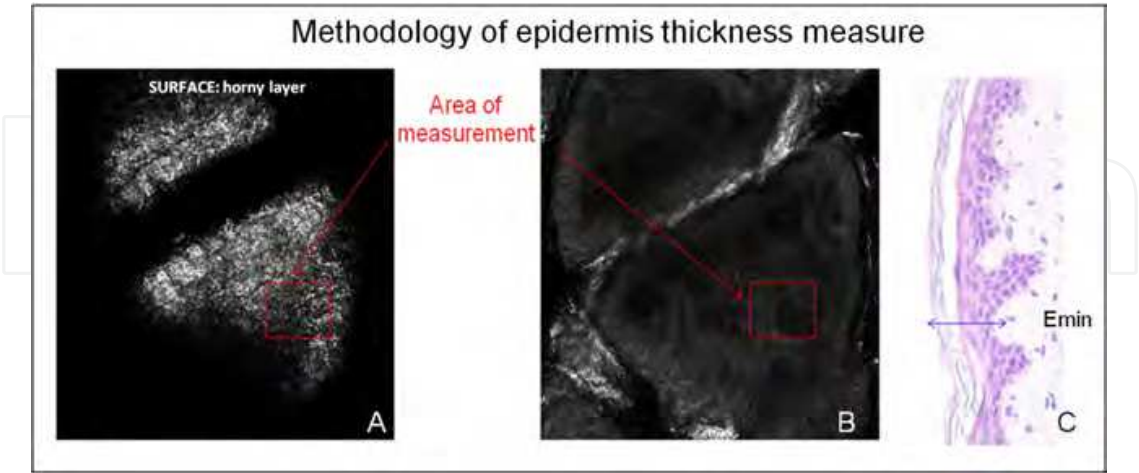


Fig. 2. Methodology of epidermis thickness measurement: The distance between the surface (*stratum corneum*) **A** and the level showing the first dermal tissue **B** measures the thickness of the epidermis. **C** represents the measurement done with the VivaScope® on a H&E biopsy section. For epidermis thickness, we made one measurement per stack, on eight stacks per volunteer.

2.2.2 Measurement of objective parameters: Dermal papillae

2.2.2.1 Measurement of the number of dermal papillae

The number of dermal papillae was evaluated by counting each active/functional papillae showing a lumen. Figure 3 explains how to recognize active/functional papillae from non-active dermal papillae. We made one measurement per stack, on eight stacks per volunteer.

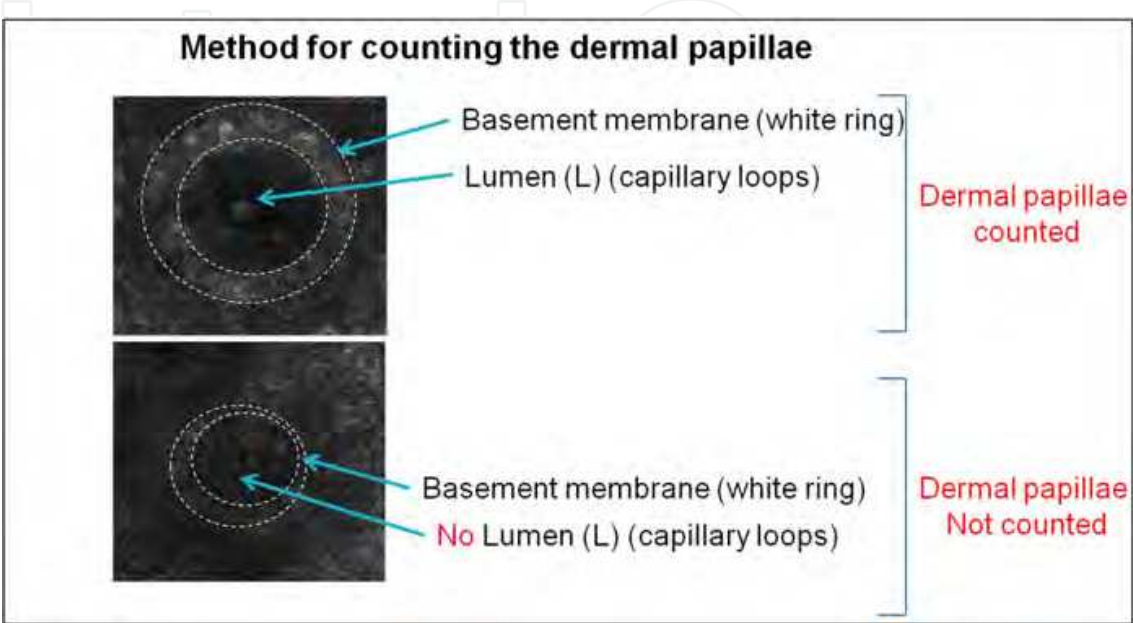


Fig. 3. The number of dermal papillae was evaluated by counting each active/functional papilla showing a lumen. The measurements were performed on eight stacks per volunteer and one measurement per stack.

To determine the height of dermal papillae, we measured the distance between the top of dermal papillae and the level showing no dermal papillae structure at all (Figure 4). We made the measurement on eight stacks per volunteer, and realized one measurement on two dermal papillae per stack. In total, we measured the height of 16 dermal papillae per volunteer.

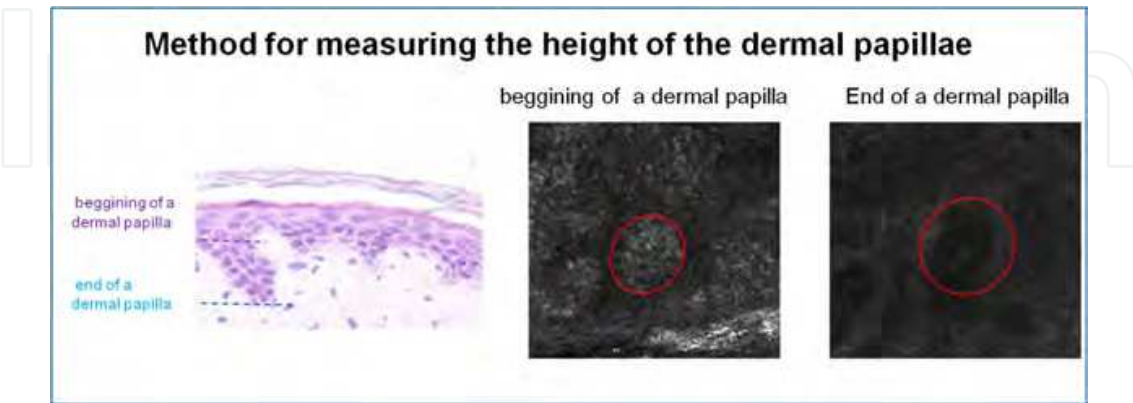

Fig. 4. The height of dermal papillae was measured as the distance between the top of dermal papillae and the level showing no dermal papillae structure at all. The measurements were performed on eight stacks per volunteer, and performed one measurement on two dermal papillae per stack. In total, we measured the height of 16 dermal papillae per volunteer.



### 2.2.2.2 Observations of reticular collagen

In some cases, we could also observe the reticular dermis, but we must note that we reached the detection limit at this point.

The clinical observations and measurements obtained by VivaScope® microscopy offer the cosmetic industry a great opportunity to trace the changes at different age-stages of the skin; and that will be presented in the second part of this chapter.

## 3. Skin changes at different age stages by *in vivo* confocal microscopy

### 3.1 Methodology of the clinical study

To investigate age-related changes, we studied five groups of five healthy volunteers each with Caucasian type of skin:

- The 20-30 group was composed of volunteers aged between 24 and 27 years (mean age: 25.2, 4 females, 1 male)
- The 30-40 group was composed of volunteers aged between 29 and 37 years (mean age: 33.8, 5 females),
- The 40-50 group was composed of volunteers aged between 41 and 46 years (mean age: 44.4, 5 females),
- The 50-60 group was composed of volunteers aged between 51 and 57 (mean age: 54.5, 3 females, 3 males),
- The 60-70 group, the older group, was composed of volunteers aged between 60 and 68 years (mean age: 63.6, 5 females).

Measurements were performed on their volar forearm, over two weeks in May.

For each group, we measured the epidermis and the horny layer thicknesses, the number and height of dermal papillae, and also carefully observed the granular cells, the morphology of dermal papillae, and when possible, the collagen fibers structure.

We compared these results with Hematoxylin-Eosin (H&E) stains on skin biopsies obtained from abdomen plastic surgery of females aged 20 to 79 years. In this part of the study, skin biopsies were fixed in successive baths of formol, alcohol, and xylene, then embedded in paraffin (Excelsior ES, Shandon, UK), and sectioned into 4  $\mu\text{m}$  sections to be used for routine hematoxylin-eosin staining.

In this study, we observed very carefully the morphological features of the skin in the different volunteer groups; for each group, several biopsies were obtained, and for each of them, several skin cross-sections were studied and compared.

### 3.2 H&E staining observations

The following results are illustrated in Figure 5. In the different age groups, we observed:

- **Group 20-30:** The H&E skin coloration showed lots of dermal papillae as well as numerous invaginations, commonly called "rete pegs". The dermoepidermal junction was highly convoluted, and the basal cells appeared well organized without any damage. The papillary dermis appeared very dense.

- **Group 30-40:** At these ages, the structure of the epidermis was similar to that observed for 20-30 year-old donors. The interface between the epidermis and the dermis appeared highly convoluted due to the presence of rete pegs.
- **Group 40-50:** In this group, we observed a retraction of the rete pegs resulting in a flattened interface between epidermis and dermis. The dermal papillae were less apparent. The basal cells became less organized and the papillary dermis was less dense. It was in this group that we noticed the first morphological signs of age in the skin biopsies.
- **Group 50-60:** Here, the dermoepidermal junction was completely flat with a total absence of dermal papillae and so of rete pegs. The basal cells presented several damage and were disorganized. The papillary dermis decreased in density compared to the group 20-30.
- **Group 60-70:** The skin structure was similar to the one observed in the group 50-60. We found the same flattening of the dermoepidermal junction and the same damage of basal cells and papillary dermis.






observations	Comments
	<b>Group 20-30:</b> The H&E skin staining showed lots of dermal papillae as well as numerous invaginations, commonly called "rete pegs". The dermoepidermal junction was highly convoluted, and the basal cells appeared well organized without any damage. The papillary dermis appeared very dense
	<b>Group 30-40</b> At these ages, the structure of the epidermis was similar to that observed for 20 years old donors. The interface between the epidermis and the dermis appeared highly convoluted due to the presence of rete pegs.
	<b>Group 40-50:</b> In this group, we observed a retraction of the rete pegs resulting in a flattened interface between epidermis and dermis. The dermal papillae were less apparent. The basal cells became less organized and the papillary dermis was less dense. It was in this group that we noticed the first morphological signs of age in the skin biopsies.
	<b>Group 50-60:</b> Here, the dermoepidermal junction was completely flat with a total absence of dermal papillae and so of rete pegs. The basal cells presented several damage and were disorganized. The papillary dermis decreased in density compared to the group 20-30.
	<b>Group 60-70:</b> the skin structure was similar to the one observed for the group 50-60. We found the same flattening of the dermoepidermal junction and the same damage of basal cells and papillary dermis.

Fig. 5. H&E staining biopsy observations and comments.

3.2.1 Results of H&E staining

In our light microscopy study, as largely described in the literature, we showed that aged skin revealed a thinner epidermis than young skin. This was primarily due to the retraction of rete pegs resulting in a flattened interface between epidermis and dermis and consequently to a flattened dermoepidermal junction. One of the consequences of this flattening is that aged epidermis becomes less resistant to shearing force, and less vascularized, leading to a bad nutrition of the basal cells. The observation of the *stratum corneum* in light microscopy study, as in other studies, showed that the number of horny cells did not seem to diminish with age, and thus the *stratum corneum* retained its normal thickness (Hull & Warfel, 1983).

In light microscopy, all the studies of the literature are in accordance regarding the evolution of skin thickness with age. However, conflicting results were found in the VivaScope® study and were challenging to interpret, as mentioned and discussed later on.

3.3 Confocal laser scanning microscope (VivaScope® 1500)

3.3.1 Horny layer and epidermis thicknesses

We measured and plotted the mean of horny layer and epidermal thicknesses as a function of age (Figure 6). The mean of horny layer and the epidermal thicknesses became thicker with age. The correlation between the thickening and age was statistically very significant for the *stratum corneum* and highly significant for the epidermal thickness. Table 1 gives the calculated correlation coefficient (r), which measures the correlation between the two variables: X for age and Y for the thickness.

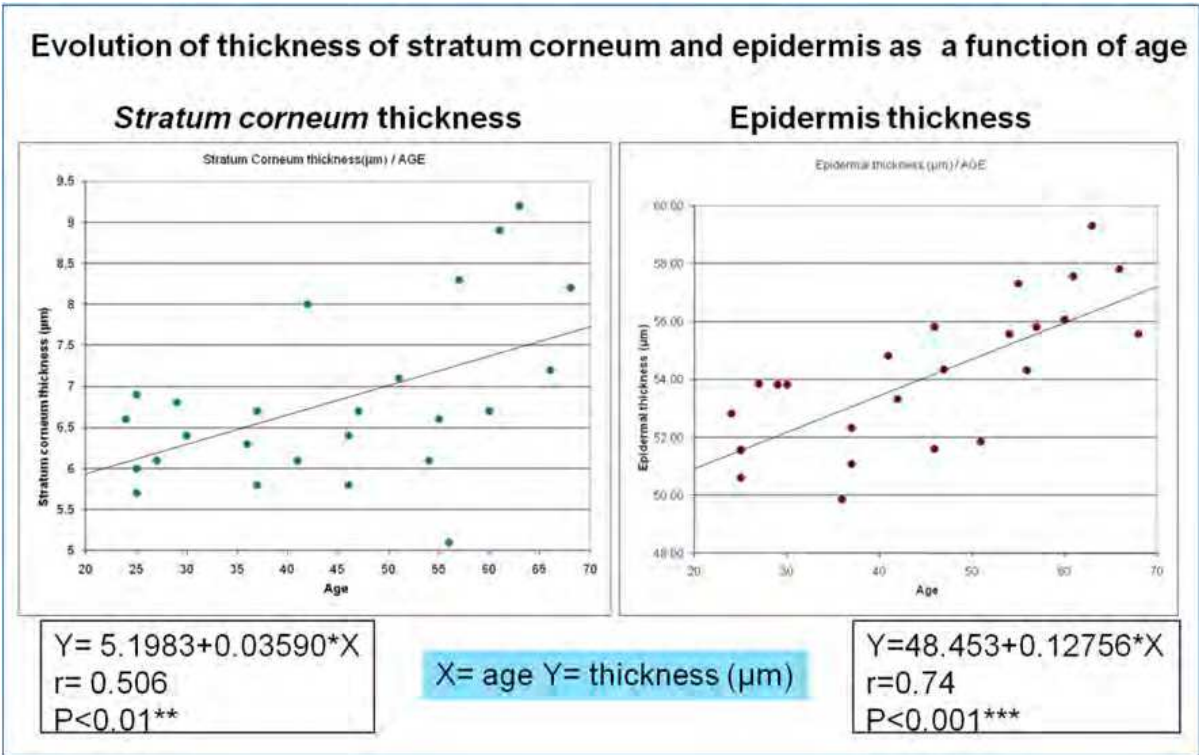


Fig. 6. Measurement and plot of horny layer and epidermis thicknesses as a function of age.



This correlation coefficient was positive, which implied that when age (X) increases, thickness (Y) also increases. The regression line can be used to predict the *stratum corneum* or epidermis thickness by entering the age of an individual.

Correlation test	p<	r=	Regression line	Mean		SD	
				X (age)	Y (thickness)	X	Y
Stratum corneum thickness / age	0.01**	0.506	Y= 5.1983+0.03590*X	44.28	6.788	14.38	1.0199
Epidermal thickness / age	0.001***	0.74	Y=48.453+0.12756*X	44.28	54.102	14.38	2.479

\*\*: very significant \*\*\*: highly significant

Table 1. Parameters of the graph representing the thicknesses of both horny layer and epidermis.

Furthermore, the correlation coefficient of the number and height of dermal papillae being close to 1 suggests that the number and the shape of dermal papillae could be considered as a very good aging indicator. According to the literature, we observed similar results with this technique to the ones that others obtained (Fenske and Lober, 1986; Zaghi et al., 2009).

3.4 Granular cell observation

For each group, we compared the organization and size of the granular cells. For each parameter observed, we assigned a category to each volunteer. Thus, for the granular cell morphology we used four categories: excellent, good, moderate and poor (the data are summarized in Table 2).

Age	excellent	good	moderate	poor
20-30	1	4		
30-40		3	2	
40-50			5	
50-60			2	3
60-70			1	4

Table 2. Granular cell observations: Excellent: very good organization, small and polygonal cells; Good: good organization, small and polygonal cells; Moderate: small cell disorganization and cell spreading, presence of no polygonal cells, vacuoles and dyskeratotic cells; Poor: cell disorganization and cell spreading, lots of cells with irregular shape, vacuoles, and condensed DNA.

- **Group 20-30 and group 30-40:** In these two groups, the granular layer displayed very well organized granular cells. The cells were regular in shape and size and had a good cohesion. We did not notice any cell damage (vacuole, dyskeratotic cells...). The granular layer had a honeycomb pattern as expected in young skin (discussed later in the next paragraph).

- **Group 40-50:** At this age, we observed the beginning of a disorganization of granular cells. The cells lost their polygonal shape and became bigger compared to young granular cells. Dyskeratotic cells appeared in this layer whereas the honeycomb pattern was less apparent.
- **Group 50-60 and group 60-70:** With age, the granular cell organization was completely lost. The cells had no longer a polygonal shape and their size was smaller. Numerous dyskeratotic cells appeared and the granular layer displayed cell spreading with a loss of cohesion.

### 3.5 Epidermal thickness assessment with VivaScope®

The effect of age on the thickness of the skin is one of the most controversial topics among dermatological researches. Indeed, in our study we observed a statistical correlation between thickening and age in both the horny layer and the epidermis. Focusing on the results of Table 1, we were able to observe a better correlation between epidermal thickness and age than horny layer thickness and age. Actually, this correlation difference pointed out that the *stratum corneum* is more influenced by the environment stress and volunteer's lifetime. Moreover, in the *stratum corneum* we observed that the correlation was not really linear but could look like a curve. This last finding suggested that the horny layer thickness could be constant during the first 50 years of life followed by a thickening in older individuals. More investigations have to be made to confirm these findings.

Controversially with others, we observed with the VivaScope® 1500 that the younger the skin is (and presumably healthier), the thinner the epidermis and the horny layer are. To our opinion, the relative thinness in younger skin (observed by this technique) correlated with what was seen in the granular cells in younger groups; the granular cells were more cohesive, often smaller than in the older groups, and better stacked, thus better organized. Hence, this relative thinness of the epidermis is not correlated with what was seen with light microscopy (i.e. the flattening of dermal junction) but correlated to a better internal organization of the granular cells. Besides, concerning the *stratum corneum*, with age, the cohesion between the corneocytes is lost (Fenske et al., 1986); therefore, they are not well organized and there is more space between each of them, which can explain the relative increase of the thickness.

### 3.6 Controversial results

Comparing measurements of the skin layer thickness between studies (and also from one individual to another, as well as between assessments) is especially challenging, due to the significant variations in measurements between individuals, between sites within each individual, between seasons, and hormonal differences between individuals.

Indeed, a study using confocal microscopy found that the thickness of living epidermis on the back of the arm decreased with age (Zaghi et al., 1986; Sandly-Møller et al., 2003). Another study using ultrasounds (Gniadecka et al., 1994) found an increase of facial skin thickness between 25 and 90 year-old people. In another study with 61 women with ages ranging from 18 to 94, authors found that the skin thickness increased on the forehead and buttock with age (Pellacani & Seidenari, 1999). In accordance with our results, in another study, Sauermann et al. (2002) considered a relatively old group with a mean age

of 72.5 years and reported a significantly larger epidermal thickness in elderly volunteers. In the controversial study of Neerken et al. (2004), the thickness of the *stratum corneum* was found not to change with age, but in the older volunteer group, the minimum thickness of viable epidermis was somewhat larger (but no statistical difference between the investigated groups) and that the maximum thickness of the epidermis statistically significantly decreased with age. In our study, we chose to measure the minimum thickness of epidermis (see Figure 2 for reminder), and this can explain certain discrepancy compared with others.

When we focused on the methodology, we observed that Sauermann et al. measured the epidermal thickness on volar forearm with VivaScope® using the same method as we do, and found an increase in epidermal thickness with age.

Authors (Leveque et al., 1984) measured the total skin thickness on the dorsal and ventral forearm (epidermis + dermis) with Holtain Skinfold Caliper and found that the skin thickness decreased with age.

Takema et al. (1994) measured the skin thickness on the face and the ventral forearm by Dermascan A. They found that, with age, the skin thickness decreased in the area slightly sun-exposed (ventral forearm) whereas it increased in the area markedly sun-exposed.

Gambichler et al. (2006) measured the thickness of the epidermis on the forehead, pectoral area, forearm, buttock, upper back, and calf. They observed no inter-regional variation and a thinner epidermis in their older group.

Finally, Rigal & Leveque (1989) measured the skin thickness with ultrasound images for each decade of life (until 80-90 years) on the volar and dorsal forearms and observed an inter-regional difference. On the volar forearm, skin thickness did not vary significantly between the first and the seventh decade of life, but skin atrophy appeared after the eighth decade. On the dorsal forearm, they observed a phase of maturation (thickness increase) up to 15 years of age, and that atrophy signs began after the seventh decade.

Despite all these disagreements observed in bibliographic data, we can affirm that the keratinocyte turnover slows-down with age, leading to the accumulation and the increase in size of corneocytes in the *stratum corneum* (Leveque et al., 1984; Grove & Kligman; Marks, 1981). In our study, we observed that, with age, the granular cells increased in size, the shape changed, and the honeycomb pattern disappeared (correlating with an observed disorganization). According to Sauermann et al., the correlation between size of cells in the granular layer and age is consistent with a documented increase in corneocytes with age. Moreover, others (Fenske & Lober, 1986), who observed that in supra-basal cell layers the keratinocytes tend to display a decreased vertical height and an increased overall surface area, also reported this effect. Other authors suggested that this decrease in height and increase in irregularity could reflect the decrease in proliferation of the basal cell in aged skin (Sauermann et al., 2002). These changes, coupled with poor corneocytes adhesion, could lead to the increase of the thickness observed in our study.

### 3.7 Number and height of dermal papillae

Throughout different decades, we observed a statistically highly significant decrease in the number of dermal papillae ( $p < 0.001$ ). Therefore, mathematically, we could determine a

negative correlation with  $r = -0.699$  between the number of dermal papillae and age. The measured height of the dermal papillae also statistically highly significantly decreased ( $p < 0.001$ ), with a negative correlation of  $r = -0.854$  (Figure 7).

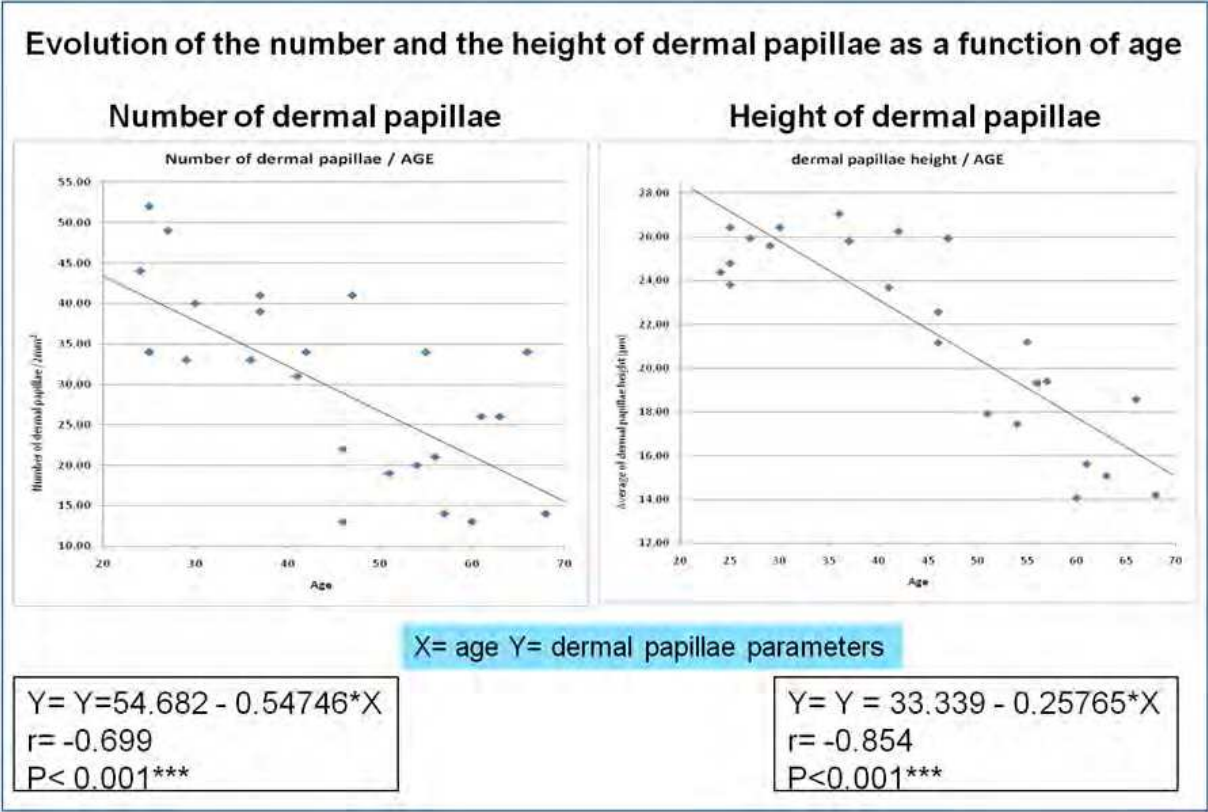


Fig. 7. Measurement and plot of the dermal papilla parameters (Number and height) as a function of age.

Furthermore, the correlation coefficient of the number and height of dermal papillae is close to 1, indicating that the number and shape of dermal papillae could be considered as very good aging indicators. According to the literature, we observed similar results with this technique as the ones that others obtained (Fenske and Lober, 1986; Zaghi et al., 2009).

3.8 Dermal papillae observations

The results of the observations are summarized in Figure 8.

- **Group 20-30:** At these ages, dermal papillae were numerous, round and very well delimited by a “white ring” (intense melanin content), which was constituted by the basal cells. Inside some papillae, we could observe capillary loops. All these observations demonstrated a good vascularization of the epidermis.
- **Group 30-40:** Dermal papillae were still round and pretty well defined although in that case we observed less melanin that interfered in the observation of dermal papillae. Nonetheless, the lumen of capillary loops is still observed, sign of a healthy skin.
- **Group 40-50:** The observed number of dermal papillae decreased in size. The shape was irregular and the dermal papillae were less defined. In this group of age, the capillary loops were hardly observable.



- **Group 50-60 and group 60-70:** The VivaScope® pictures did not display any dermal papillae. In the same manner, cells were disorganized, and the dermoepidermal junction was not observable. Moreover, vascularization was absent suggesting a poor epidermal nutritional status.

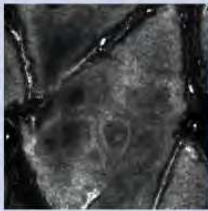

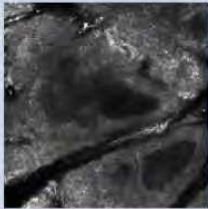


Dermal papillae	Comments
	<b>Group 20-30:</b> At these ages, dermal papillae were numerous, round, and very well delimited by a “white ring”, which was constituted by the basal cells. Inside some papillae, we could observe capillary loops. All these observations demonstrated a good vascularization of the epidermis.
	<b>Group 30-40:</b> Dermal papillae were still round and pretty well defined although, in that case, we only observed a few. Nonetheless, we could still see the lumen of capillary loops, a sign of healthy skin.
	<b>Group 40-50:</b> The dermal papillae were less defined, and their shape irregular. In this group of age, capillary loops were hardly observable.
	<b>Group 50-60:</b> The VivaScope® pictures did not display any dermal papillae. In the same manner, cells were disorganized and the dermoepidermal junction was not observable. Moreover, vascularization was absent, suggesting a poor epidermal nutritional status.
	<b>group 60-70 (same as group 50-60)</b>

Fig. 8. Dermal papillae observations and comments.

3.9 Results on dermal papillae

Today, it is well accepted that the number of dermal papillae decreases with age, according to several studies (Fenske and Lober, 1986; Sauermann et al., 2002; Neerken et al., 2004) and we observed the same downward trend. The decrease in the number of dermal papillae with age reflects the flattening of the epidermal-dermal junction (Sauermann et al., 2002). In particular, this flattening demonstrates that not only the height of the dermal papillae decreases with age, but the number of interdigitations also drops with aging. The dermal

papillae in the oldest groups were found irregular in shape; this feature could be explained by the reduction of the number of basal cells participating in the cellular cycle. This finding can be supported by the disappearance with age of the white ring surrounding dermal papillae that corresponded to basal cells.

After conducting this study, we conclude that the change in the number and morphology of dermal papillae are the parameters the most correlated with age. These parameters were closely linked to the dermal papilla function in supplying the epidermis with water and nutrients *via* dermal vasculature, and directly to the health of the epidermis. The morphology, number, and shape of dermal papillae could be great indicators of the epidermis health and age.

3.10 Collagen observations

The images obtained by the VivaScope® and the observations are compiled in Figure 9.






Collagen observations	Comments
	<b>Group 20-30</b> : the younger group presented a very dense pattern and it was difficult to distinguish the fibers from each other. The collagen bundles were organized in tightly packed bundles.
	<b>group 30-40</b> : same as group 20-30
	<b>Group 40-50</b> : at this rate of age we can see two different collagen aspects. We found dense collagen like in the younger groups and we found straight and filiform fibers that we can distinguish from the others material.
	<b>Group 50-60</b> in older groups collagen fibers were judged filiform. We can easily see them as well as spaces between the fibers. The fibers looked like there were unraveling.
	<b>group 60-70</b> : same as group 50-60

Fig. 9. Collagen observations and comments.

- **Group 20-30 and group 30-40:** The younger group presented a very dense pattern of collagen and it was difficult to distinguish the collagen fibers from one another. The collagen bundles appeared organized in tightly packed bundles as discussed in the next paragraph.
- **Group 40-50:** At these ages, we could see two different collagen distribution patterns. We found dense collagen as in the younger groups, and straight and filiform fibers.
- **Group 50-60 and group 60-70:** In this group, collagen fibers were filiform. We could easily observe them, as well as spaces between the fibers, thus the fibers appeared individualized, isolated from one to another; therefore the fibers looked unraveled.

### 3.11 Results on collagen observations

With a confocal laser scanning microscope, also called VivaScope®, the collagen appearance of young skin was characterized by an organization in tightly packed bundles. At this age range, the collagen is the major dermal matrix component; collagen fiber bundles are compact and dense, which explains why we were not able to distinguish any structure in our observation. In contrast, in older groups, we managed to very well discern some collagen fibers from ground substance. This could be due to the decrease in the rate of collagen synthesis and the thickness of collagen fiber bundles (Fenske and Lober, 1986; Koehler et al., 2008). With age, the matrix becomes thinner, with straight collagen bundle fibers, giving an unraveled appearance to the bundles (Lavker et al., 1987; Zaghi et al., 2009).

## 4. Conclusion

To analyze the aging process, we investigated histometric parameters on biopsies from several donors of different ages, and performed a clinical study to observe the cutaneous micromorphology *in vivo*, using a confocal laser scanning microscope -VivaScope®1500- on groups of volunteers from 20 to 70 years of age.

The thickness of the epidermis and the horny layer seemed to be still controversial. However, regarding the effect of cosmetic ingredients contributing to an improvement of the skin's parameters, we observed that the healthier is the skin (a better-hydrated appearance), the thinner is the epidermis. The thinness parameter always correlates with an increase in the skin turnover and a decrease in size of granular cells.

As in the bibliographic data, we found that the number and height of dermal papillae decreased with age, and that these effects correlated with the flattening of epidermal-dermal junction seen in H&E staining biopsies. Therefore, after conducting this study, we came to the conclusion that the changes in the number and morphology of dermal papillae are the parameters the most correlated with age.

Finally, *in vivo* confocal laser scanning microscope can undoubtedly be considered as a sensitive and non-invasive tool allowing an easy study of the changes of different parameters of the whole epidermis, at all ages.

## 5. References

- Abramoff, MD., Magalhaes, PJ., & Ram, SJ. (2004). Image Processing with ImageJ. *Biophotonics International*, Vol.11, No.7, pp.36-42.

- Abramovits, W., & Stevenson, LC. (2003). Changing paradigms in dermatology: New ways to examine the skin using non-invasive imaging methods. *Clinics in Dermatology*, Vol.21, pp. 353-358.
- Ardigo, M., & Gill, M. (2008). Blue nevus. In: *Reflectance confocal microscopy of cutaneous tumors*, Gonzalez S, Gill M, Halpern, AC, (EDs), 146-150, Informa Healthcare, USA.
- Branzan, AL., Landthaler, M., & Szeimies, RM. (2007). *In vivo* confocal scanning laser microscopy in dermatology. *Laser in Medical Science*, Vol.22, pp. 73-82.
- Corcuff, P., Gonnord, G., Pierard, GE., & Leveque, JL. (1996). *In vivo* confocal microscopy of human skin: a new design for cosmetology and dermatology. *Scanning*, vol.18, pp. 351-355.
- Curiel-Lewandrowski, C., Williams, CM., Swindells, KJ., Tahan, SR., Aster, S., Frankenthaler, RA., & González, S. (2004). Use of *In Vivo* Confocal Microscopy in Malignant Melanoma: an Aid in Diagnosis and Assessment of Surgical and Nonsurgical Therapeutic Approaches. *Archives of Dermatology*, vol.140, No.9, pp. 1127-32.
- Fenske, NA., & Lober, CW. (1986). Structural and functional changes of normal aging skin. *Journal of American Academy of Dermatology*, vol.15, pp. 571-585.
- Gambichler, T., Matip, R., Moussa, G., Altmeyer, P., & Hoffmann, K. (2006). *In vivo* data of epidermal thickness evaluated by optical coherence tomography: effects of age, gender, skin type, and anatomic site. *Journal of Dermatological Science*, vol.44, No.3, pp. 145-52.
- Gerger, A., Koller, S., Weger, W., Richtig, E., Kerl, H., Samonigg, H., Krippel, P., & Smolle, J. (2006). Sensitivity and Specificity of Confocal Laser-Scanning Microscopy for *In Vivo* Diagnosis of Malignant Skin Tumors. *Cancer*, vol. 107, No.1, pp. 193-200.
- Gniadecka, M., Gniadecki, R., Serup, J., & Sondergaard, J. (1994). Ultrasound structure and digital image analysis of the subepidermal low echogenic band in aged human skin: diurnal changes and inter individual variability. *Journal of Investigative Dermatology*, vol.102, No.3, pp. 362-365.
- Gonzalez, S., Gilaberte-Calzada, Y., Gonzalez-Rodriguez, A., Torres, A., & Mihm, MC. (2004). *In vivo* reflectance-mode confocal scanning laser microscopy in dermatology. *Advances in Dermatology*, vol.20, pp. 371-387.
- Grove, GL., & Kligman, AM. (1983). Age-associated changes in human epidermal cell renewal. *Journal of Gerontology*, vol.38, pp. 137-142.
- Hull, MT., & Warfel, KA. (1983). Age-related changes in the cutaneous basal lamina: scanning electron microscopic study. *Journal of Investigative Dermatology*, vol.81, pp. 378-380.
- Koehler, MJ., Hahn, S., Preller, A., Elsner, P., Ziemer, M., Bauer, A., König, K., Bückle, R., Fluhr, JW., & Kaatz, M. (2008). Morphological skin aging criteria by multiphoton laser scanning tomography: non-invasive *in vivo* scoring of the dermal fiber network. *Experimental Dermatology*, vol.17, pp. 519-523.
- Lavker, RM., Zheng, PS., & Dong, G. (1987). Aged skin: A study by light, transmission electron, and scanning electron microscopy. *Journal of Investigative Dermatology*, vol.88, pp. 44s-51s.
- Leveque, JL., Corcuff, P., De Rigal, J., & Agache, P. (1984). *In vivo* studies of the evolution of physical properties of human skin with age. *International Journal of Dermatology*, 23: 322-329.



- Marks, R. (1981). Measurement of biological aging in human epidermis. *British Journal of Dermatology*, vol.104, pp. 627-633.
- Neerken, S., Lucassen, GW., Bisschop, MA., Lenderink, E., & Nuijs, TA. (2004). Characterization of age-related effects in human skin: a comparative study that applies confocal laser scanning microscopy and optical coherence tomography. *Journal of Biomedical Optics*, vol.9, pp. 274-281.
- Pellacani, G., & Seidenari, S. (1999). Variation in facial skin thickness and echogenicity with site and age. *Acta Dermato-Venereologica*, vol.79, pp. 366-369
- Pierard, GE. (1993) *In vivo* confocal microscopy: a new paradigm in dermatology. *Dermatology*, vol.186, pp. 4-5
- Rajadhyaksha, M., Grossman, M., Esterowitz, D., Webb, RH., & Anderson, RR. (1995). *In vivo* confocal scanning laser microscopy of human skin: melanin provides strong contrast. *Journal of Investigative Dermatology*, vol.104, pp. 946-52.
- Rigal, J., & L  v  que, JL. (1989). Assessment of aging of the human skin *in vivo* ultrasonic imaging. *Journal of Investigative Dermatology*, Vol.93, pp. 621-625.
- Sandby-M  ller, J., Poulsen, T., & Wulf, HC. (2003). Epidermal thickness at different bodysites: relationship to age, gender, pigmentation, blood content, skin type and smoking habits. *Acta Dermato-Venereologica*, vol.83, No.6, pp. 410-3.
- Sauermann, K., Clemann, S., Jaspers, S., Gambichler, T., Altmeyer, P., Hoffmann, K., & Ennen, J. (2002). Age related changes of human skin investigated with histometric measurements by confocal laser scanning microscopy *in vivo*. *Skin Research and Technology*, vol.8, pp. 52-56.
- Takema, Y., Yorimoto, Y., Kawai, M., & Imokawa, G. (1994). Age-related changes in the elastic properties and thickness of human facial skin. *British Journal of Dermatology*. Vol.131, No.5, pp. 641-8.
- Zaghi, D., Waller, JM., & Maibach, HI. (2009). The effects of aging on skin. *Nutritional Cosmetics*, pp. 63-77.

IntechOpen



## **Senescence**

Edited by Dr. Tetsuji Nagata

ISBN 978-953-51-0144-4

Hard cover, 850 pages

**Publisher** InTech

**Published online** 29, February, 2012

**Published in print edition** February, 2012

The book "Senescence" is aimed to describe all the phenomena related to aging and senescence of all forms of life on Earth, i.e. plants, animals and the human beings. The book contains 36 carefully reviewed chapters written by different authors, aiming to describe the aging and senescent changes of living creatures, i.e. plants and animals.

### **How to reference**

In order to correctly reference this scholarly work, feel free to copy and paste the following:

Karine Cucumel, Jean Marie Botto, Nouha Domloge and Claude Dal Farra (2012). Age-Related Changes in Human Skin by Confocal Laser Scanning Microscope, *Senescence*, Dr. Tetsuji Nagata (Ed.), ISBN: 978-953-51-0144-4, InTech, Available from: <http://www.intechopen.com/books/senescence/age-related-changes-in-human-skin-by-confocal-laser-scanning-microscope>

**INTech**  
open science | open minds

### **InTech Europe**

University Campus STeP Ri  
Slavka Krautzeka 83/A  
51000 Rijeka, Croatia  
Phone: +385 (51) 770 447  
Fax: +385 (51) 686 166  
[www.intechopen.com](http://www.intechopen.com)

### **InTech China**

Unit 405, Office Block, Hotel Equatorial Shanghai  
No.65, Yan An Road (West), Shanghai, 200040, China  
中国上海市延安西路65号上海国际贵都大饭店办公楼405单元  
Phone: +86-21-62489820  
Fax: +86-21-62489821

© 2012 The Author(s). Licensee IntechOpen. This is an open access article distributed under the terms of the [Creative Commons Attribution 3.0 License](https://creativecommons.org/licenses/by/3.0/), which permits unrestricted use, distribution, and reproduction in any medium, provided the original work is properly cited.

IntechOpen

IntechOpen