

We are IntechOpen, the world's leading publisher of Open Access books Built by scientists, for scientists

6,900

Open access books available

186,000

International authors and editors

200M

Downloads

Our authors are among the

154

Countries delivered to

TOP 1%

most cited scientists

12.2%

Contributors from top 500 universities



WEB OF SCIENCE™

Selection of our books indexed in the Book Citation Index
in Web of Science™ Core Collection (BKCI)

Interested in publishing with us?
Contact book.department@intechopen.com

Numbers displayed above are based on latest data collected.
For more information visit www.intechopen.com



Measurement and Topography Guided Treatment of Irregular Astigmatism

Joaquim Murta and Andreia Martins Rosa
*Hospitais da Universidade de Coimbra,
 Portugal*

1. Introduction

Corneal astigmatism occurs when one corneal meridian has a different refractive power from the orthogonal meridian. In regular astigmatism, the two meridians are at 90° from each other, such as a sphere having a cylinder superimposed on its surface. In irregular astigmatism the two meridians are not at 90° from each other or the cornea curvature is not axially symmetric. Irregular astigmatism can be imagined as a sphere, with or without a cylinder on its surface, and several other different shapes superimposed on it. In irregular astigmatism the same meridian has different degrees of curvature, making it impossible for a spherocylindrical lens to correct such irregularity. (1)

The diagnosis of irregular astigmatism can be suspected when there is loss of spectacle corrected visual acuity but preservation of vision through pinhole or while wearing rigid gas-permeable contact lenses. Other clues for the presence of irregular astigmatism are difficulty in determining the axis of astigmatism during manifest refraction, a significant amount of astigmatism at automated refraction not accepted by the patient and achieving the same visual acuity despite correction of the cylinder in different axis. Patients complain of bad quality of vision resulting from glare, halos, distortion of image and monocular diplopia. The diagnosis can be confirmed with a topographic examination.

2. Etiology of irregular astigmatism

Causes of irregular astigmatism include ectatic disorders, nonectatic disorders, refractive surgery and corneal transplantation. (2) (3)

2.1 Ectatic disorders

Noninflammatory ectatic disorders include keratoconus, pellucid marginal degeneration (PMD), keratoglobus and posterior keratoconus. (2) (3)

KERATOCONUS is the most common ectatic disorder and it is an important cause of irregular astigmatism. It is a non-inflammatory, progressive, ectatic and thinning disease of the cornea, usually bilateral, although asymmetric, with onset at puberty. It manifests as a protusion with paracentral inferior thinning, it may be surrounded by an iron line (Fleisher's ring), it can contain scars and fine posterior stress lines (Vogt striae). Later signs of keratoconus include Munson's sign and Rizutti's phenomenon. (2) (4)

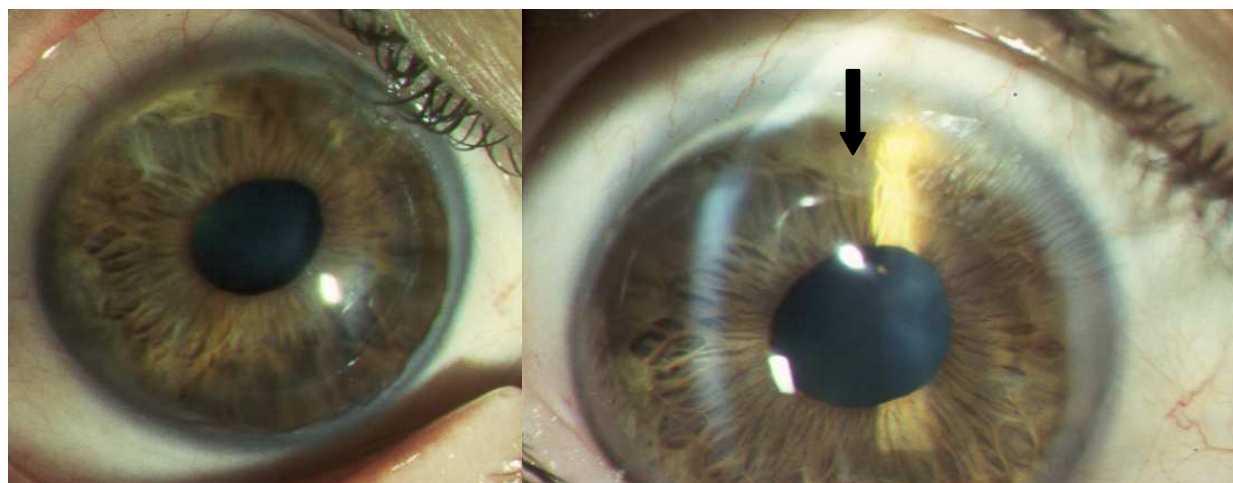


Fig. 1. Keratoglobus. Notice the generalized peripheral thinning.

PELLUCID MARGINAL DEGENERATION is also bilateral, age at onset from 20 to 50 years old, most commonly found in males, with an inferior peripheral band of thinning (usually from 4-8 o'clock with 1 to 2 mm width) and protusion superior to the thinned area. It may have striae, but less frequently than keratoconus. (2) (4)

KERATOGLUBUS is a rare bilateral disorder that presents at birth with a generalized corneal protusion and limbus-to-limbus peripheral thinning, causing the cornea to assume a globular profile. Keratometry measurements can often be as high as 60-70 D. Vogt's striae, sub-epithelial scarring, Fleischer's ring, lipid deposition and corneal vascularisation are rarely found. (2) (4) (Figure 1).

POSTERIOR KERATOCONUS is a very rare corneal disorder, usually unilateral and non-progressive that is present at birth. There is only an excavation in the posterior and paracentral cornea, but scarring is common. (2)

2.2 Nonectatic disorders

CONTACT LENS WARPAGE refers to the modification of corneal topography associated with all types of contact lens wear. It may manifest clinically with decreased best spectacle corrected visual acuity and irregular mires on keratometry or only on topographic examination in patients seeking refractive surgery. It may resemble keratoconus or pellucid marginal degeneration, or it may be an irregularity with no specific pattern. (3) The most important factor indicating the required time for refractive stabilization after contact lens removal is the amount of time the patient has worn contact lenses. (5) A simple way to memorize when to discontinue contact lens wear before refractive surgery is 1 week for each 5 years of use of soft contact lenses and 2 weeks for rigid lenses.

DRY EYE can cause any pattern of irregular astigmatism or it may make impossible to obtain an adequate topography. Dry eye decreases the smoothness of the epithelium, creates focal irregularities on topography and may appear similar to keratoconus and pellucid marginal degeneration. (3) These irregularities improve with artificial tear instillation prior to the examination. Wavefront aberrations are a measure of irregular astigmatism and have been shown to decrease 2 to 3 times with tear instillation. Sequential aberrometry is a useful objective method to evaluate sequential changes of visual performance related to tear-film dynamics. (6)

PTERYGIUM is a commonly occurring ocular surface disease, characterized by epithelial overgrowth of the cornea, usually bilateral. There is also an underlying breakdown of Bowman's layer and its size is significantly correlated with the magnitude of spherical power, asymmetry, regular and irregular astigmatism. (7) (8) (9) Pterygium removal surgery improves these changes, but regular astigmatism and higher order irregularities may remain. (10) Pterygia are usually located in the nasal interpalpebral cornea, where they induce local flattening and with-the-rule astigmatism. However, as the flattening is asymmetric, irregular astigmatism can also be induced (Figure 2). Changes in the tear film, as local pooling at the head of the pterygium, also induce irregular astigmatism. (3) The development of pterygium-like lesions in axes other than the horizontal (pseudo-ptyerygium) are secondary to traumatic, inflammatory or vascular conditions.

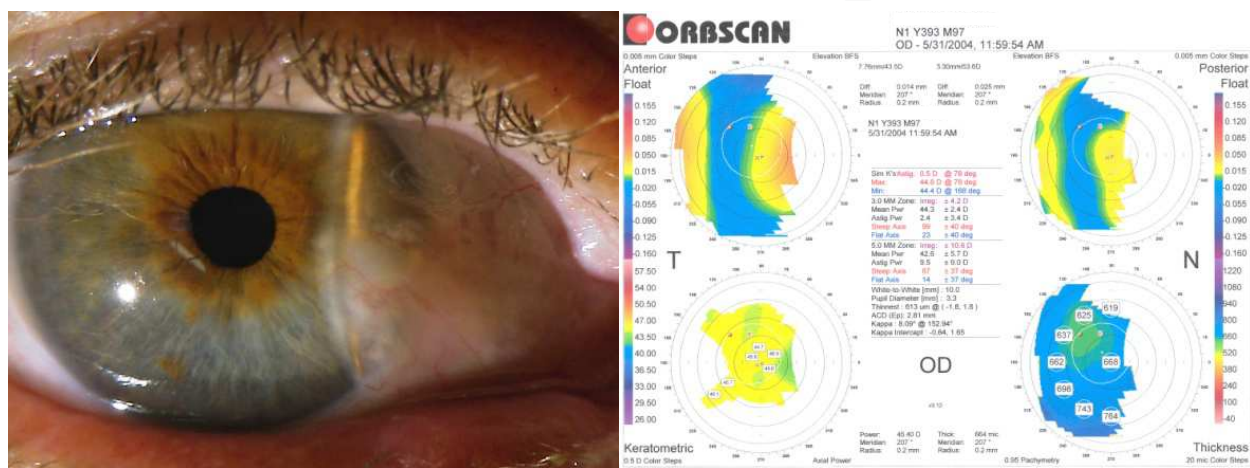


Fig. 2. Pterygium causing nasal flattening of the cornea and significant irregular astigmatism in the 3 and 5 mm zones (4.2D and 10.6D).

INFECTIOUS DISEASES (keratitis) cause corneal scarring and local flattening, resulting in irregular astigmatism. It is important in these cases to differentiate the contribution of the irregular astigmatism from that of opacity in the decrease of visual acuity; a pinhole and a gas permeable contact lens will improve the irregular astigmatism but not the opacity caused by the keratitis.

IMMUNE-MEDIATED DISEASES include Mooren's ulcer, atopic keratoconjunctivitis, peripheral ulcerative keratitis, ocular mucous membrane pemphigoid and Stevens-Johnson syndrome. (2) (4) These diseases can cause severe corneal melting and scarring, with resulting irregular astigmatism.

CORNEAL DYSTROPHIES affecting all corneal levels can cause irregular astigmatism. It is important to differentiate the relative contribution of the irregular astigmatism from that of the opacity itself. Corneal dystrophies can be divided according to the level of the cornea involved into 1) Epithelial and Subepithelial Dystrophies (epithelial basement membrane dystrophy, epithelial recurrent erosion dystrophy, subepithelial mucinous corneal dystrophy, Meesmann corneal dystrophy, Lisch dystrophy and gelatinous drop-like corneal dystrophy); 2) Bowman's layer (Reis-Bucklers, Grayson-Wilbrandt and Thiel-Behnke corneal dystrophies); 3) Stroma (transforming growth factor beta-induced -TGFFBI- corneal dystrophies - granular dystrophy and lattice dystrophy; Macular dystrophy; Schnyder corneal dystrophy; Congenital stromal dystrophy; Fleck dystrophy; Posterior amorphous dystrophy; Central cloudy dystrophy of François and Pre-Descemet corneal dystrophy) and

4) Endothelial (Fuchs endothelial dystrophy, Posterior polymorphous dystrophy, Congenital hereditary endothelial dystrophy 1 and 2 and X-linked endothelial corneal dystrophy). (11)

CORNEAL TRAUMA is an important cause of irregular astigmatism due to scar formation and consequent local variation of the refractive properties of the cornea. Irregular astigmatism occurs relative to the type of trauma as well as with the surgical technique used in the primary repair. (12) It is important, once again, to evaluate the relative contribution of the opacity versus the optical effect of the scar tissue, before attempting laser correction of the irregular astigmatism.

2.3 Following refractive surgery

AFTER RADIAL KERATOTOMY. Healing of the RK incisions is very slow and unpredictable, often incomplete even years after surgery. (13) Healing of these incisions involves irregular fibrous tissue and epithelial plugs, leading to an asymmetric central flattening. Visual distortion and glare are more marked in patients having more than 8 incisions, incisions located inside the 3 mm central zone and hypertrophic scarring. (13) (Figure 3) There is sometimes continuous hyperopic shift that also reduces visual acuity. (13)

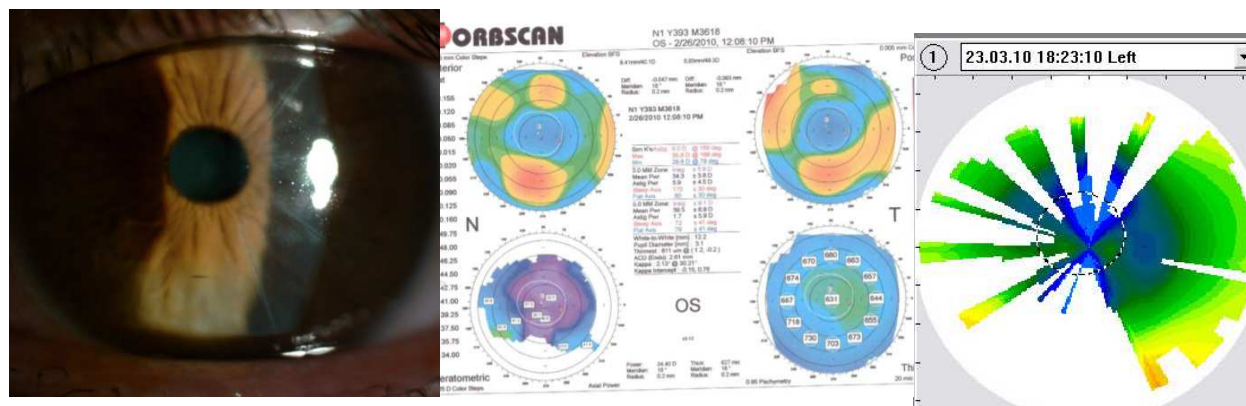

Fig. 3. A-Radial keratotomy incisions inducing 6.0 D of topographic astigmatism and irregularity (5.9 D in the 3 mm zone and 9.1 D in the 5mm zone) at Orbscan (B). C- It is difficult to obtain data over the radial incisions (Topolyzer).

AFTER LASIK. Irregular astigmatism can occur due to problems with the laser ablation pattern, after both myopic and hyperopic treatments, or flap related complications (Figure 4). Laser induced problems include decentered ablations, either from misalignment, involuntary eye movement or eye tracker malfunction and central islands. (14) Central islands are steep areas inside the treatment zone that can result from poor laser calibration, improper laser dynamics, central blockage of the laser treatment by laser plume, central corneal water accumulation and individual healing responses. (14) A small optical zone can also cause symptoms of irregular astigmatism, because when the pupil dilates light rays are focused differentially according to the curvature of the area they go through. Flap related complications inducing irregular astigmatism include partial flaps, buttonhole flaps, flap striae, diffuse lamellar keratitis and epithelial ingrowth. (3) Dry eye is also a cause of irregular astigmatism and it should always be considered in pre and post refractive surgery patients.

AFTER PRK. The causes of irregular astigmatism are the same as the ones mentioned for LASIK. PRK eliminates flap related complications, but stromal incursions during

mechanical epithelial removal, corneal haze and scarring and irregular surface healing can lead to irregular astigmatism. (3)

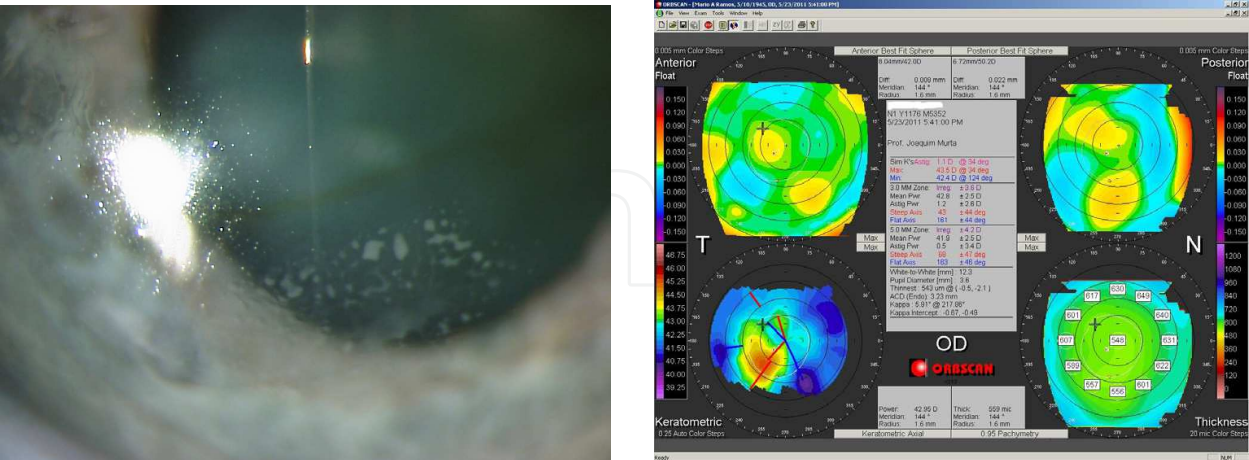


Fig. 4. Epithelial cells in the flap interface causing significant distortion and irregular astigmatism.

POSTOPERATIVE CORNEAL ECTASIA represents the most severe form of irregular astigmatism after corneal refractive surgery. The true incidence remains underdetermined ranging from 0.04% (15) to 0.6% (16) after LASIK. Preoperative weak corneas, thin residual stromal beds (depending on pre-operative refraction, pre-operative corneal thickness, flap thickness and tissue removed by the excimer laser), trauma and forme fruste or latent keratoconus can cause post surgical ectasia. (Figure 5).

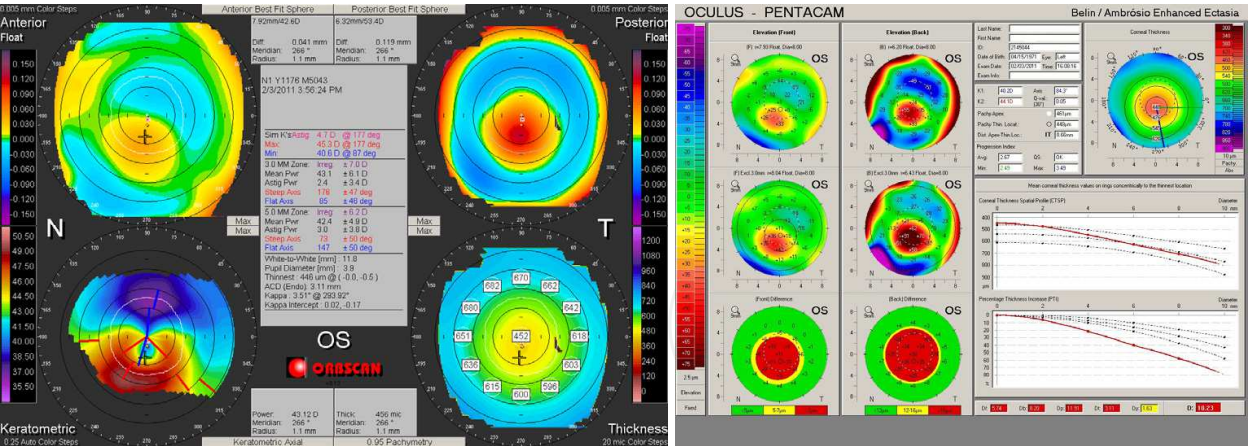


Fig. 5. Keratoectasia after LASIK performed in 1998 to correct -7.0D OS. Notice the high anterior and posterior float values (0.041 and 0.119), inferior steepening with K values of 49D and thinning at the pachymetry map. Pentacam Belin-Ambrosio Display highlights the ectatic zone by showing the difference between this zone and the sphere that most resembles the normal part of the cornea.

2.4 Following penetrating keratoplasty

PRE-EXISTING RECIPIENT DISEASE. Regional thinning, vascularisation, keratoconus and aphakic patients tend to have more irregular astigmatism. (17) (3)

TREPHINATION TECHNIQUE. Tilt, eccentric trephination, poor quality blades, damaged corneal blocks, asymmetric pressure from lid speculums and scleral rings can all cause irregular astigmatism. (17) Although penetrating keratoplasty (PKP) generally results in clear corneal grafts, the procedure is frequently complicated by refractive imperfections and wound-healing problems. (18) Femtosecond laser corneal surgery has been increasing in popularity and has the potential to overcome many of the problems of manual or automated trephines or microkeratomes.

SUTURE PLACEMENT is crucial to obtain a good refractive outcome following corneal transplantation. The second cardinal suture is the most important in keratoplasty. It determines lateral wound apposition, donor/recipient edge alignment and corneal astigmatism. Sutures must purchase the same amount of tissue in donor and recipient beds, which means having the same length and depth. Sutures can be tied with a variety of techniques, but all require meticulous attention to appropriate suture tension with avoidance of loose or tight knots. (12)

SUTURE REMOVAL. Suture manipulation is a very important factor in the astigmatic outcome. Astigmatism is reduced through suture removal at the steep meridian, as indicated by keratometry or topography. Usually, this meridian is at least 3 D steeper for suture removal. Suture removal in the interrupted suture technique can start at the 4th postoperative month, although care must be taken with older patients and if intense steroid regimen is maintained, as healing is delayed in these cases. The effect of removing an individual interrupted suture is unpredictable and the change in astigmatism may last for several months, making it advisable to wait at least 1 month before removing further sutures. (3) The time elapsed between surgery and suture removal plays an important role. As time goes by, the effect of suture removal lessens, although dramatic changes in astigmatism may occur even 2 or more years after surgery. (19) It might be preferable to leave sutures in place indefinitely once a good outcome has been reached.

RECURRENCE OF ECTATIC DISEASE. Keratoconus may recur 7 to 40 years after penetrating keratoplasty, with a mean latency of 17 years. (20) (21) (22) Possible explanations include incomplete removal of the ectatic host cornea when 4-6 mm diameter trephinations are performed, subclinical ectatic disease in the donor cornea, production by host epithelium of degradative enzymes that can weaken the donor cornea and infiltration of the graft by host keratocytes that produce abnormal collagen and lead to recurrence of disease. (22)

3. Evaluation of irregular astigmatism

3.1 Orbscan

Irregular astigmatism may have specific features at topography or have an undefined pattern. Specific features include keratoconus, pellucid marginal degeneration, decentered ablation, decentered steep and central island.

3.1.1 Keratoconus

Suspicious patterns include inferior elevation, inferior thinning in the area of maximal protusion and inferior steepening. (23) Keratoconus may present an asymmetric bow tie pattern, where there is a significant difference in the width of the lobes or a significant difference ($> 1D$) in the dioptric power at 1.5 mm from the centre. (3) It is also suspicious when the two principal meridians are not perpendicular to each other (Figure 6).

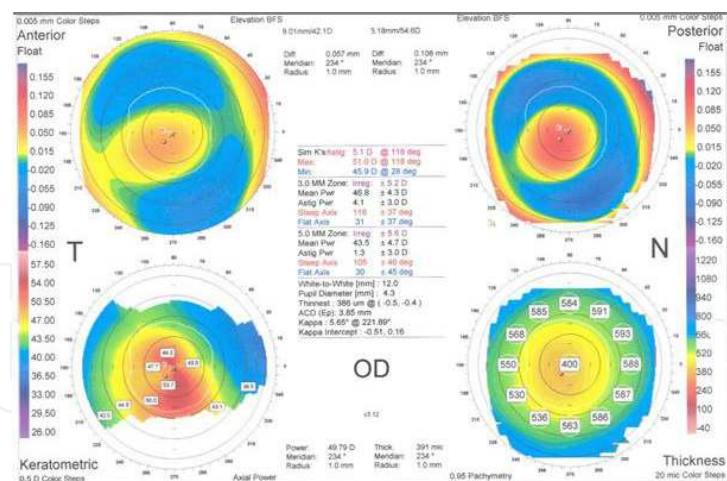


Fig. 6. Keratoconus. The irregularity in the 3 and 5mm zone is 5.2 and 5.6 (higher than 1.5D and 2.0D respectively), anterior float is 0.057 (>0.025) and posterior float is 0.108 (>0.04). Pachymetry is also abnormal with central thickness of 400 μm and thinnest point = 386 μm .

The value for the posterior elevation difference from best fit sphere (posterior float) > 0.04 mm and an anterior float value > 0.025 mm are suspicious of keratoconus. (23) A posterior value > 0.05 mm is usually accompanied by other signs of ectasia. Other clues for the presence of keratoconus are irregularity at the 3 mm zone $> \pm 1.5$ D, irregularity at the 5 mm zone $> \pm 2.0$ D, the thinnest part of the cornea being > 30 μ m thinner than the centre, the thinnest part of the cornea being more than 2.5 mm away from the centre and the peripheral cornea not being at least 20 μ m thicker than the centre. (23)

3.1.2 Pellucid marginal degeneration

There is a band of stromal thinning 1-2 mm wide occurring 1-2 mm central to the inferior limbus. In contrast to keratoconus, protusion occurs superior to the area of thinning. (23) (2) There is central against the rule astigmatism with a classic “kissing doves” or crab claw pattern inferiorly. (2) (Figure 7). However, Lee et al (24) have discussed that a “claw-shaped” pattern is not diagnostic for pellucid marginal degeneration and that such patterns may also be found in keratoconus. Slit-lamp signs and pachymetry maps must be considered in conjunction with corneal topography for a reliable diagnosis.

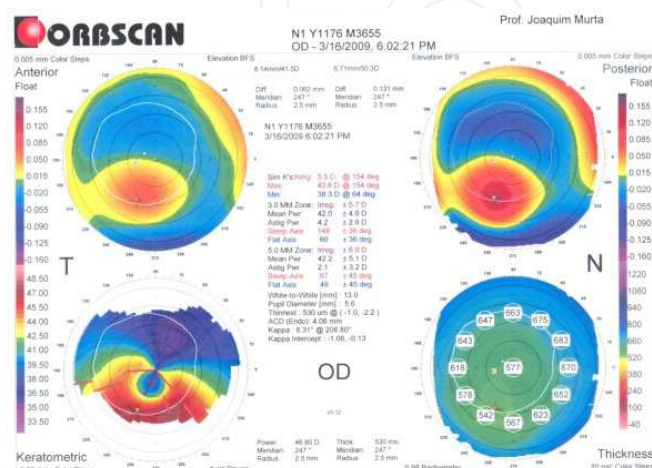

Fig. 7. Pellucid marginal degeneration, with crab claw pattern and inferior thinning.

3.1.3 Decentered ablation and decentered steep

Sagittal or axial curvature maps are poor indicators of the location of previous corneal treatments due to the difference between the curvature map's reference axis, the line of sight and the corneal apex. (25) Elevation maps should be used instead. Elevation maps show the misalignment of the centre of ablation from optical centre.

3.1.4 Central island

A central island is a central area of relatively less flattening that measures >1.0 mm in size and >1.0 diopter (D) in power and does not extend to the periphery.

3.2 Pentacam

The patterns described previously for Orbscan can also be seen with Pentacam. However, there are further criteria that can help recognizing initial ectasia.

Elevation maps are very useful to detect initial ectasia. A central or paracentral islands pattern with positive elevation values $> 10 \mu\text{m}$ for the anterior surface or $> 15 \mu\text{m}$ for the posterior surface are suspicious of keratoconus. There is usually displacement of the thinnest region in the pachymetry map towards the island. (25)

The Belin/ Ambrosio Enhanced Ectasia Display maintains the principle of the best fit sphere but instead of using a "normal" sphere it uses a reference surface that more closely resembles the patient's own normal portion of the cornea. To do this, a 4 mm optical zone centered on the thinnest part of the cornea is excluded from the calculation of the reference shape. The effect is minor in normal eyes but enhances the abnormal portion of the cornea in ectasia patients. The difference maps display the relative change in elevation from the baseline elevation map to the exclusion map. Changes between 6 and $12 \mu\text{m}$ for the front surface and 10 to $20 \mu\text{m}$ for the back surface are suspicious. Values greater than 12 and $20 \mu\text{m}$ for the anterior and posterior surfaces are typically seen in patients with known keratoconus. (25)

3.3 Wavefront aberrometry

Wavefront sensing is a technique of measuring the complete refractive status, including irregular astigmatism, of an optical system. (26) A wavefront aberration is defined as the deviation of the wavefront that originates from the measured optical system from reference wavefront that comes from an ideal optical system. The unit for wavefront aberrations is microns or fractions of wavelengths and it is expressed as the root mean square or RMS. (26) The shape of the wavefront can be described by Zernike polynomials, which are a combination of trigonometric functions. Zernike polynomials can be grouped into lower order or higher order aberrations (HOA). HOA include third order and advancing higher Zernike modes. High levels of HOA have a detrimental effect on retinal image quality that is pupil size dependent. (27) In normal eyes, the predominant ocular aberrations are the second order errors, which include three terms: defocus and regular astigmatism in the two directions. The third order has four terms: coma (horizontal and vertical) and trefoil (horizontal and vertical) and the fourth order has tetrafoil, secondary astigmatism and spherical aberration. Spectacles can correct for only the second order aberrations and not the HOA that represent irregular astigmatism. (26)

In keratoconus there is a prominent increase of vertical coma due to a corneal component. (28) In addition, trefoil, tetrafoil and secondary astigmatism are higher in keratoconic eyes. (26) The direction of the vertical coma (negative sign) is the opposite of normal eyes, that is,

a prominent vertical coma with an inferior slow pattern, attributed to an inferior shift of the cone's apex. (27) However, vertical coma may be higher in the lesser involved eye of patients diagnosed with keratoconus, suggesting that this is the earliest manifestation of keratoconus. (27) Gobbe et al (29) demonstrated that the corneal derived wavefront error of vertical coma is the best detector to differentiate between suspected keratoconus and normal corneas. Trefoil aberration in keratoconus is also the reverse of that of normal eyes. (26)

In pellucid marginal degeneration the mean axes of the coma are the reverse of normal eyes, but the magnitude of the coma is less than in keratoconic eyes. The mean axes of the trefoil and the sign of spherical aberration are opposite to that of keratoconus. (26)

Refractive surgeries tend to increase the total HOA and induce a shift from mainly coma-like aberrations pre op to spherical like aberration post op. (26)

HOA can also have some advantageous effects. For example, coma-like aberrations contribute to an apparent accommodation in pseudophakic eyes. (30) So, although it is important to reduce the HOA for better optical quality of the image, the depth of field might be reduced. (26) Also, the reduction of total spherical aberration after aspheric IOL implantation may degrade distance-corrected near and intermediate visual acuity. (31)

3.4 Allegro topolyzer

The ALLEGRO Topolyzer (WaveLight Laser Technologie AG, Germany) is a combination of placido based topography system and an integrated kerato-meter. The patterns described previously can also be seen with it and there are several useful parameters and indices that can help with the diagnosis of irregular astigmatism.

3.4.1 Fourier analysis

The Topolyzer performs a Fourier analysis on the topographic image, allowing the study of the resulting individual waves:

Decentration

Decentration measures the tilt between the optical axis of the videokeratoscope and the optical vertex of the cornea. In a normal cornea it is < 0.45 mm for sagittal curvature and 1.88 for tangential curvature. Figure 8.

Regular astigmatism

In a normal cornea, regular astigmatism is represented as a cross. Keratoconus is often associated with a rotation of the astigmatic axis from the centre to the periphery, resulting in a spiral pattern. Figure 9.

Irregularities

The Irregularities field only contains wave components that cannot be corrected by means of a sphere, cylinder or prism. In a normal cornea the mean of all irregularities is less than 0.03 mm for sagittal curvature and 0.141 for tangential curvature. Figure 10.

3.4.2 Zernike analysis

The Topolyzer performs a Zernike analysis on measured height data. It calculates for each Zernike polynomial a coefficient which describes the contribution of that polynomial to the height data. The Zernike coefficients can be viewed as "Z separate" or "Z vectors" modes. The relative contribution of each Zernike polynomial (tilt, astigmatism, focus, trefoil, coma,

spherical aberration, etc) is displayed in numerical values. Abnormal values will appear in red. In keratoconus, for example, the coma will often be increased. In addition, the Topolyzer calculates an aberration coefficient from the Zernike coefficients. Values exceeding 1.0 indicate that there are atypical wave components.

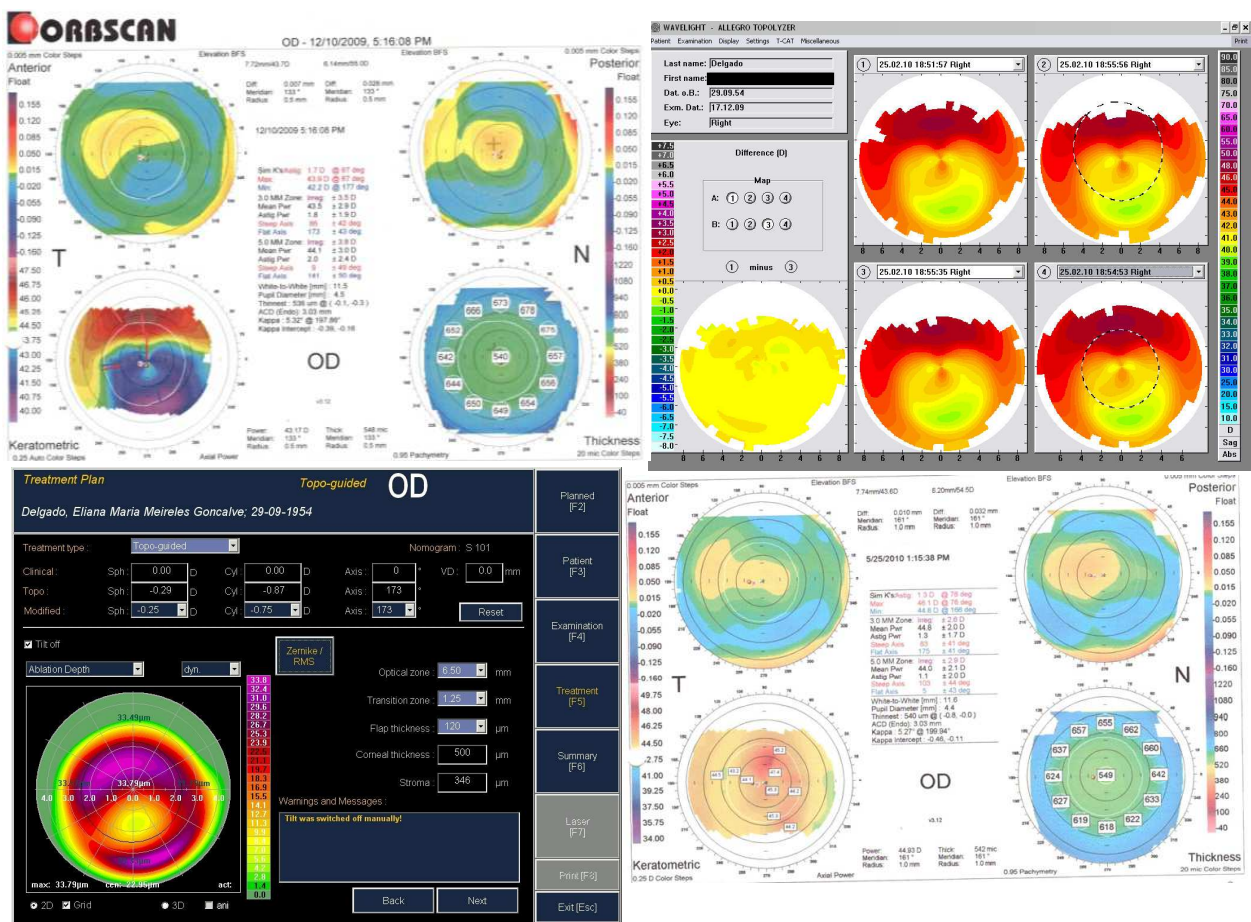


Fig. 8. Decentered PRK myopic ablation Orbscan (top left) and Topolyzer (top right). Decentration value was 0.50 mm. The T-CAT ablation profile (bottom left) and the post op Orbscan (bottom right) showing a more regular cornea.

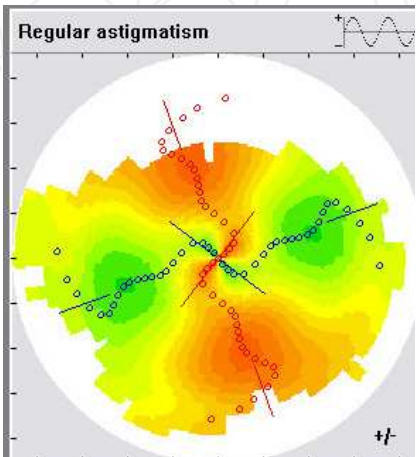


Fig. 9. Fourier analysis of a keratoconus patient, displaying the typical spiral pattern.

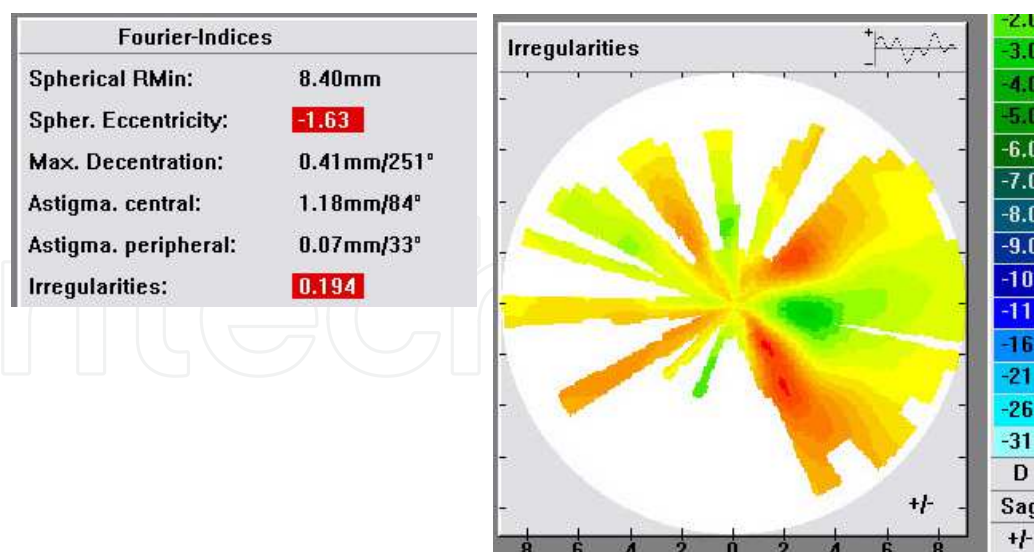


Fig. 10. The mean of all irregularities in this sagittal curvature map of a post radial keratotomy patient is 0.194 (normal value below 0.03 mm).

The Zernike 2D Display Mode represents Zernike polynomials in 2 dimensions and might be a better way to recognize initial keratoconus. It represents more accurately the apex of the cone, which may not be correctly depicted by the sagittal curvature map, as discussed previously. The height of the cone quantifies the degree of keratoconus. The higher the value the more advanced the keratoconus is.

3.4.3 Indices

Indices are calculated from curvature, height, Fourier and Zernike analysis data. Borderline values are displayed in yellow and abnormal values in red.

ISV – the Index of surface variance gives the deviation of individual corneal radii from the mean value. Elevated in all types of irregularities (scars, keratoconus, etc). Abnormal ≥ 37 .

IVA – Index of vertical asymmetry compares the symmetry of corneal radii from the superior to the inferior cornea. Elevated in keratoconus and pellucid marginal degeneration. Abnormal ≥ 0.28 .

KI – Keratoconus index. Elevated especially in keratoconus. Abnormal >1.07

CKI – Center keratoconus index. Elevated especially in central keratoconus. Abnormal ≥ 1.03 .

RMin – The smallest radius of curvature in the field of measurement. Elevated in keratoconus. Abnormal < 6.71 .

IHA – Index of height asymmetry. Gives the degree of symmetry of height data with respect to the horizontal meridian as axis of reflection (superior versus inferior). Sometimes more sensitive than the IVA. Abnormal ≥ 19 .

IHD – Index of height decentration. Gives the degree of decentration in vertical direction. Elevated in keratoconus. Abnormal ≥ 0.014 .

ABR – Aberration coefficient. If there are no abnormal corneal aberrations, aberration coefficient is 0.0, otherwise becomes 1.0 or greater, depending on the degree of aberration. Abnormal ≥ 1 .

KKS – Keratoconus stage. This index follows the Amsler classification.

4. Wavelight allegretto wave topography-guided ablation treatment

4.1 Principle of topography guided treatments

Topography guided treatments can be performed with several acquisition systems linked to an excimer laser. Some examples are the iVIS suite, the VISX system, the CRS-Master software combined with the MEL 80 laser, the CATz algorithm combined with the Nidek CXIII excimer laser and the Schwind system.

We will focus on Allegro T-CAT system, the one we use.

Topography-guided treatments (T-CAT) can be planned from both the ALLEGRO Oculyzer and the ALLEGRO Topolyzer and are indicated for eyes with severe irregularities and corneal disorders. The Allegro Oculyzer is a Scheimpflug imaging system similar to the Pentacam. The Topolyzer is a Placido based system with 11 rings that generate 22,000 measuring points and an integrated keratometer.

T-CAT treatments are based on the principle of reshaping a patient’s irregular cornea to the best fit asphere, thereby removing the excess tissue in order to transform an irregular cornea into a symmetric regular cornea. (3) It also allows the correction of the refractive error, but one has to take into account the change in refraction induced by the correction of the irregularities.

4.2 Indications and decision tree

T-CAT software allows the treatment of corneal scars, small optical zones, decentrations, forme fruste keratoconus and other corneal irregularities. The approved range of treatment for myopia is -14D, for hyperopia +6 and for astigmatism $\pm 6D$.

The correction of irregular astigmatism can be done by either one of 2 customized approaches: wavefront guided or topography guided treatments. The recommended decision tree is displayed in Figure 11.

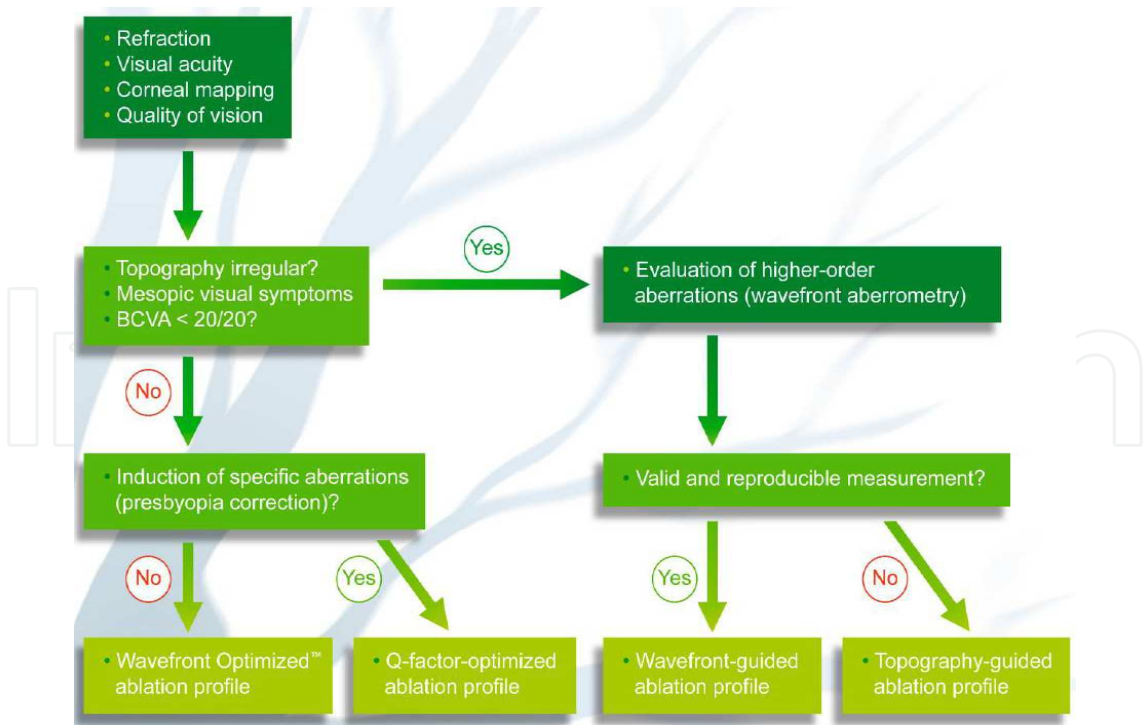


Fig. 11. Recommended decision tree regarding the choice between topography guided, wavefront guided, wavefront optimized (the usual ablation profile) and Q factor optimized treatments.

If BCVA is below 20/20, if there are mesopic symptoms and an irregular topography, a wavefront measurement should be performed. If measurements are reproducible and valid, a wavefront guided treatment can be done. If not, a T-CAT treatment should be preferred. Wavefront measurements are difficult to obtain in irregular corneas, such as in scars, PRK haze, corneal incisions (RK, penetrating keratoplasty) and in the presence of lens opacity. Even if ocular wavefront can be captured several times, the aberration maps often cannot be relied on for treatment planning because they differ markedly from one another and there is no way to know which, if any, is correct. (32) Another problem is that wavefront guided treatments assume that it is possible to correct all the aberrations of the eye on the cornea, so that the postoperative cornea could compensate for all the internal aberrations. In other words, that the location of the aberration does not matter. But the location of the aberration does make a difference. For example, treating non-anterior cylinder (lenticular astigmatism) on cornea gives an unsatisfactory result, with more cylinder left untreated. (3) The resulting cornea can be irregular, since it is compensating for irregularities that are not its own. Vision can decrease over time, because lens irregularities, for example, change over time. The treatment itself creates new aberrations that modify the preoperative aberration map, due to epithelial hyperplasia, stromal remodeling and the LASIK flap. There are also variations in ocular aberrations with age and accommodation. Having said this, when a patient's corneal aberrations correlate with wavefront aberrations, either a wavefront or a topography-guided approach can be used. The major limitation of T-CAT is that it may need a second procedure to address the refractive error.

T-CAT software has been associated with corneal cross linking for the stabilization of progressive ectasia. (33) The Athens protocol (34) (35) involves performing a T-CAT treatment with a reduction in the amount of sphere and cylinder correction (up to 70 percent of the cylinder error and up to 70 percent of the spherical error in order not to remove more than 50 microns of stroma) and corneal cross-linking on the same day. To minimize tissue ablation, the effective optical zone is decreased to 5.5 mm. This approach intends to stop the progression of the disease at the same time it reduces irregular astigmatism by reshaping the cornea. The results are promising and open a new field of applications for topography guided treatments.

4.3 Surgical plan

Before advancing to treatment it is useful to check several issues.

4.3.1 Manifest refraction

A manifest refraction as accurate as possible is very important, because T-CAT can incorporate the refractive error treatment.

4.3.2 Pachymetry

Pachymetry will be needed during the planning of the surgery.

4.3.3 Evaluation of exam quality

Pupil should always be correctly identified by the Topolyzer on the camera image.

Topographic maps should be similar to each other. The best way to check this is in the display "Compare examinations". Maps that are substantially different from others should not be exported to the Wavelight laser. Up to 8 maps will be averaged by the system and the

percentage of the data contained in the chosen optical zone (usually a 6.5mm) is displayed on the last column (Figure 12). Maps with less than 90% of data are excluded automatically. Although the asphericity value can be modified, this adjustment has a poor predictability. (36)

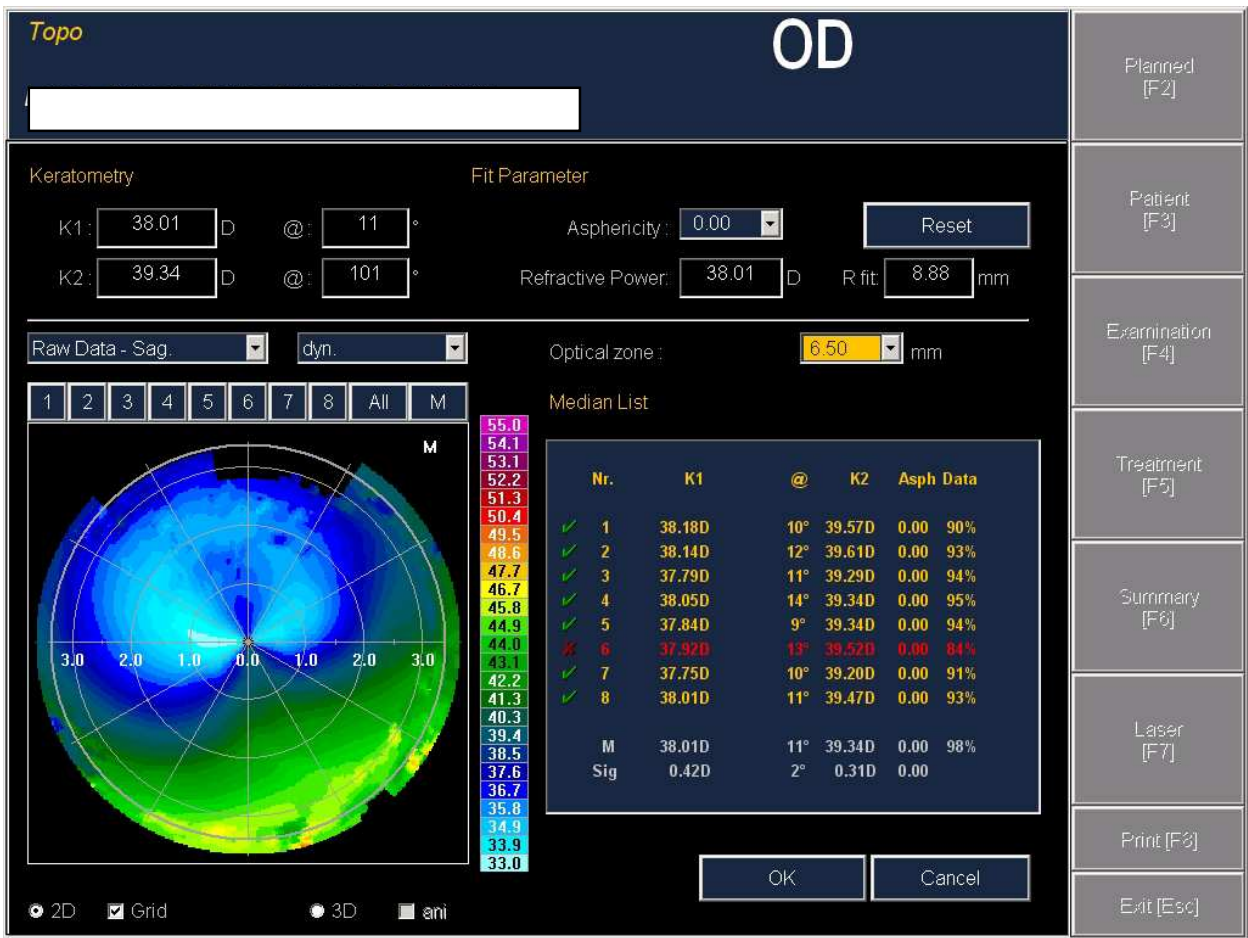


Fig. 12. Left – Mean sagittal topography of the acquisitions displayed on the right. There is decentration of a myopic ablation, performed ten years ago. Right- The software averages up to 8 acquisitions. Examinations containing less than 90% of data in the optical zone are rejected (in this case the examination marked in red was eliminated).

4.3.4 Modification of treatment

The next screen is the actual ablation profile. Despite being possible to turn the tilt on, it is recommended to turn it off because in this mode the software attempts to restore the morphologic axis while sparing the most amount of tissue. This screen displays the clinical refraction, which is better to leave unfilled, the Topolyzer refraction and the modified refraction. As mentioned previously, the correction of the irregularities will induce a shift in refraction, therefore, if the manifest refraction is entered without taking into account the ablation profile a resulting refractive error is obtained. Patients need to understand that a second refractive procedure may be necessary and that the primary goal of this treatment is to improve the corrected visual acuity. Despite this, it is possible to minimize the resulting refractive error. (37)

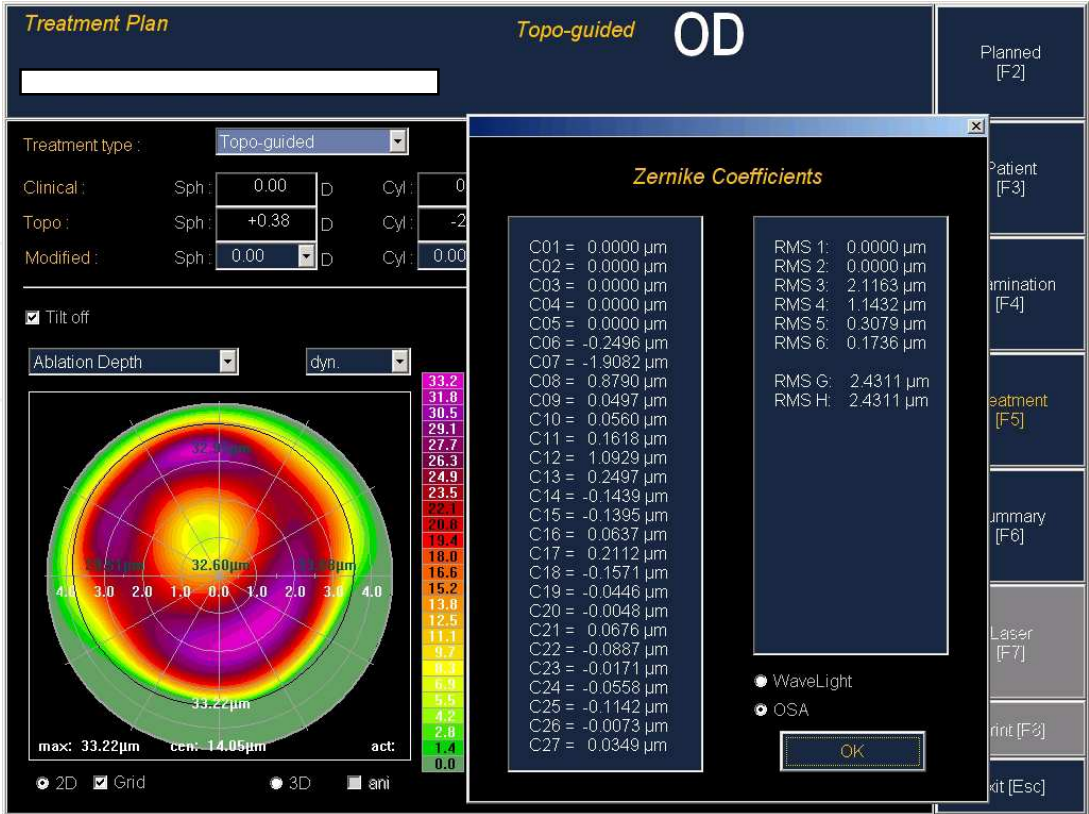


Fig. 13.1

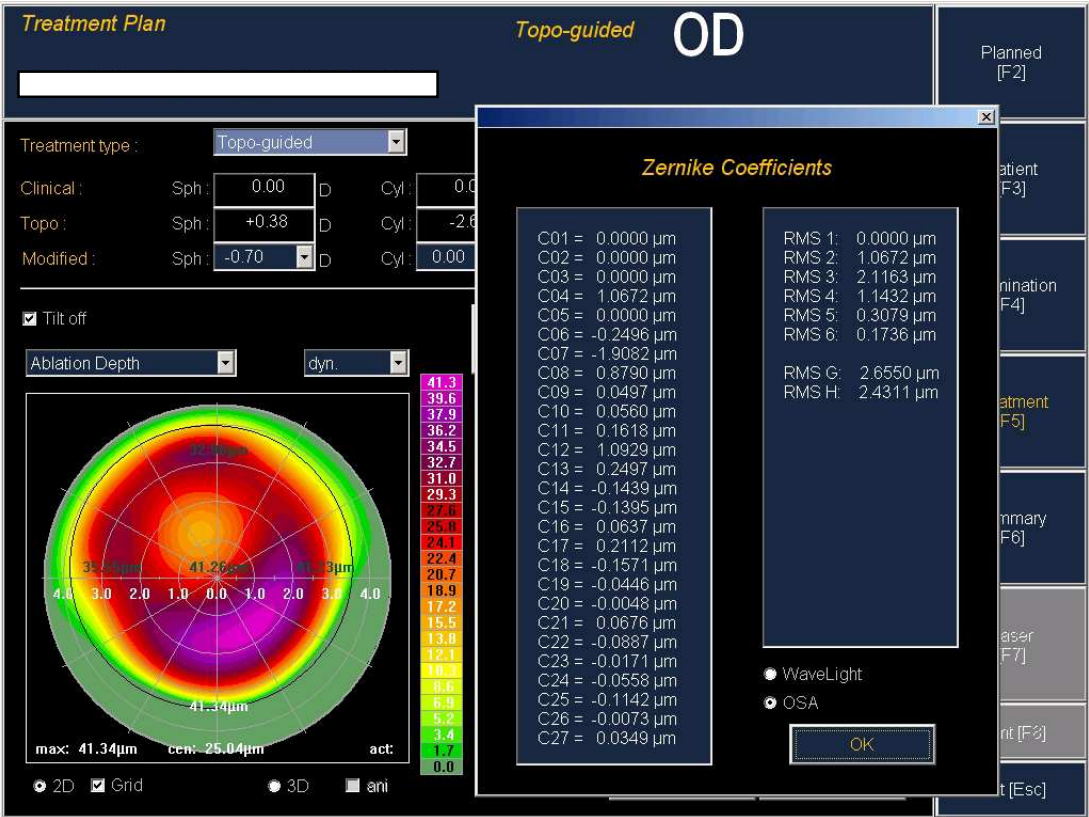


Fig. 13.2

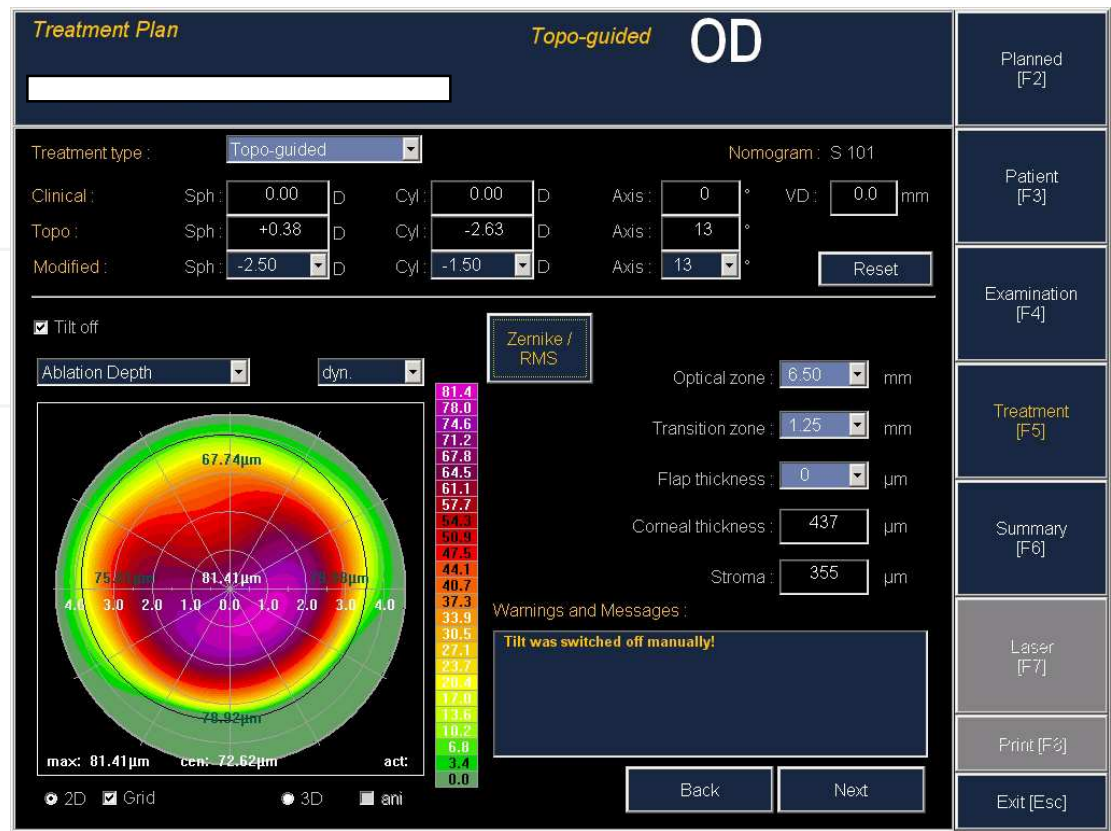


Fig. 13.3

Fig. 13. The first screen shows the ablation profile with no values introduced in the “Clinical” and “Modified” boxes. This shows the necessary ablation to regularize the cornea. The ablation will induce spherical aberration (Zernike coefficient C12 of 1.09) which will have to be compensated by changing the sphere in the “Modified” field. In the second screen the sphere has been modified to -0.7, which makes the C4 component similar to the C12 (C4=1.07 and C12=1.09). The third screen displays the final ablation profile. Because the patient manifest refraction is -2.0D, sphere is modified to -2.5 (-0.7 plus -2.0, but leaving the patient slightly myopic due to age). Cylinder has been reduced because the topographic cylinder is much higher than the refractive.

First, no refraction should be entered in the “modified refraction” field (Figure 13). This shows the ablation profile that regularizes the cornea. The ablation depths can be known by positioning the mouse in the desired area and clicking the left button. Second, identify the induced change in sphere and the amount of treatment needed to compensate for it. Enlargement of an optical zone, for example, will ablate more tissue in the periphery than in the centre, resembling a hyperopic correction. As a general rule, 15 μm of ablation difference are equivalent to 1D. If 45 μm are ablated in the periphery and 15 μm in the centre, this will induce approximately 2D of myopia (30 μm = 2D, tissue was removed in the periphery, making the central cornea more steep). In our later cases we have compensated the spherical aberration (C12) induced by the treatment with an adjustment of the sphere (C4) to equilibrate the C4 and C12 components. The amount of sphere is changed until the C4 and C12 components are similar (Figure 13, first and second screen). It is usually better not to change too much the topographic cylinder value and axis and care must be taken when the patient’s manifest refraction is not consistent with the measurement

obtained by the Allegro Topolyzer. (37) Choosing the manifest refraction will probably result in a persistent irregular cornea, whereas choosing the Topolyzer refraction will probably result in a regular cornea and improvement of corrected visual acuity, but at the expense of reduced uncorrected visual acuity, which might be perceived by the patient as a bad result. The topographic cylinder should be selected in most cases, even if different from the manifest refraction, because there are irregularities (such as coma) that can be perceived by the patient as cylinder on manifest refraction.

Finally, integrate the manifest refraction (sphere) to calculate the final treatment.

4.4 Surgery

Either a PRK or LASIK can be done. We prefer PRK with MMC 0.02% 15 seconds because it spares tissue and retreatments are easier. It avoids performing a deeper flap in post LASIK complications patients and flap related complications in post RK patients (namely flap fragmentation). The ablation depth is usually $< 80 \mu\text{m}$ and haze is very rare with this approach.

In post penetrating keratoplasty patients it is important to wait for refractive stabilization. We usually wait for 6 months after removal of all stitches and perform PRK with MMC 0.02% 15 seconds. PRK avoids the burden of the pressure on the transplant with LASIK and possible flap related complications due to scar tissue. The post operative medication is the same used in routine PRK, although a close follow up is needed with these patients.

5. Clinical pearls and conclusions

Topography guided treatments are indicated in irregular corneas with poor visual acuity and mesopic symptoms, as in corneal scars, decentrations, small optical zones and post penetrating keratoplasty.

The main objective of the procedure is to improve the corrected visual acuity and the mesopic symptoms. The correction of the refractive error may have to be done in a second procedure.

Verify correct pupil identification by the software, choose good quality maps and check the ablation profile with no refraction. Analyze the change in refraction induced by this profile and neutralize it. Add the manifest refraction to the treatment plan.

In the presence of scars, RK or previous flap related complications prefer PRK. In other cases PRK and LASIK present good results.

6. References

- [1] Basic and Clinical Science Course. *Clinical Optics*. s.l.: American academy of Ophthalmology, 2005-2006. ISBN 1-56055-501-7.
- [2] —. *External Diseases and Cornea*. s.l.: American Academy of Ophthalmology, 2006-2007. ISBN 1-56055-612-9.
- [3] Wang, Ming, [ed.]. *Irregular Astigmatism: diagnosis and treatment*. s.l.: SLACK Incorporated, 2008. ISBN 978-1-55642-839-5.
- [4] Krachmer J, Mannis M, Holland E. *Cornea: Fundamentals, Diagnosis and Management*. s.l.: Mosby Elsevier, 2011. ISBN 978-0-323-06387-6.


- [5] *Predicting time to refractive stability after discontinuation of rigid contact lens wear before refractive surgery.* Tsai PS, Dowidar A, Naseri A, McLeod SD. s.l.: Journal of Cataract and Refractive Surgery, 2004, Vol. 30, pp. 2290-2294.
- [6] *Changes in ocular aberrations after instillation of artificial tears in dry-eye patients.* Montes-Mico R, Araceli Caliz A, Alio JL. 2004, Journal of Cataract and Refractive Surgery, Vol. 30, pp. 1649-1652.
- [7] *Quantitative analysis of regular and irregular astigmatism induced by pterygium.* Tomidokoro A, Oshika T, Amano S, Eguchi K, Eguchi S. 4, Jul 1999, Cornea, Vol. 18, pp. 412-415.
- [8] *Effects of pterygium on corneal spherical power and astigmatism.* Tomidokoro A, Miyata K, Sakaguchi Y, Samejima T, Tokunaga T, Oshika T. 8, Aug 2000, Ophthalmology, Vol. 107, pp. 1568-71.
- [9] *Effect of pterygium surgery on corneal topography: a prospective study.* Bahar I, Loya N, Weinberger D, Avisar R. 2, Mar 2004 Mar, Cornea, Vol. 23, pp. 113-7.
- [10] *Effect of pterygium excision on induced corneal topographic abnormalities.* Stern GA, Lin A. 1, Jan 1998, Cornea, Vol. 17, pp. 23-27.
- [11] *ICD3D Classification of the Corneal Dystrophies.* The Cornea Society. 10, Dec 2008, Cornea, Vols. 27, Suppl. 2.
- [12] Macsai, Marian S, [ed.]. *Ophthalmic Microsurgical Suturing Techniques.* s.l.: Springer, 2007. ISBN 978-3-540-28069-9.
- [13] Basic and Clinical Science Course. *Refractive Surgery.* s.l.: American academy of Ophthalmology, 2007-2008. ISBN 978-1-56055-801-9.
- [14] Dimitri Azar, Brian Boxer Wachler, Eric D. Donnenfeld, William J. Dupps JR, Jerome C. Ramos-Esteban, Parag A. Majmudar, Sonia H. Yoo., *LASIK and PRK: Managing Complications.* American Academy of Ophthalmology Web site. [Online] 2009 2009. [Cited: Mar 13, 2011.]
- [15] http://one.aao.org/lms/courses/managing_lasik_complications/index.htm.
- [16] *Risk factors and prognosis for corneal ectasia after LASIK.* Randleman JB, Russell B, Ward MA, Thompson KP, Stulting RD. 2, Feb 2003, Ophthalmology, Vol. 110, pp. 267-75.
- [17] *Progressive keratectasia after laser in situ keratomileusis.* Rad AS, Jabbarvand M, Saifi N. 5, Suppl, Sp-Oct 2004, J Refract Surg, Vol. 20, pp. S718-22.
- [18] *An analysis and interpretation of refractive errors after penetrating keratoplasty.* EM, Perlman. 1, Jan 1988, Ophthalmology, Vol. 88, pp. 39-45.
- [19] *Femtosecond-laser-assisted Descemet's stripping endothelial keratoplasty.* Cheng YY, Pels E, Nuijts RM. 1, Jan 2007, J Cataract Refract Surg, Vol. 33, pp. 152-5.
- [20] *Changes in keratometric astigmatism after suture removal more than one year after penetrating keratoplasty.* Mader TH, Yuan R, Lynn MJ, Stulting RD, Wilson LA, Waring GO 3rd. 1, Jan 1993, Ophthalmology, Vol. 100, pp. 119-126.
- [21] *Histologic evidence of recurrent keratoconus seven years after keratoplasty.* Kremer I, Eagle RC, Rapuano CJ, Laibson PR. 4, Apr 1995, Am J Ophthalmol, Vol. 119, pp. 511-2.

- [22] *Long-term progression of astigmatism after penetrating keratoplasty for keratoconus: evidence of late recurrence.* de Toledo JA, de la Paz MF, Barraquer RI, Barraquer J. 4, May 2003, Cornea, Vol. 22, pp. 317-23.
- [23] *Extended long-term outcomes of penetrating keratoplasty for keratoconus.* Pramanik S, Musch DC, Sutphin JE, Farjo AA. 9, Sep 2006, Ophthalmology, Vol. 113, pp. 1633-8.
- [24] Robert S Feder, Cristopher J Rapuano. *The LASIK Handbook; a case based approach.* s.l. : Lippincott Williams Wilkins, 2007. ISBN 978-0-7817-6208-3.
- [25] *Ectatic disorders associated with a claw-shaped pattern on corneal topography.* Lee BW, Jurkunas UV, Harissi-Dagher M, Poothullil AM, Tobaigy FM, Azar DT. 1, Jul 2007, Am J Ophthalmol, Vol. 144, pp. 154-156.
- [26] Michael Belin, Stephen S. Khachikian. *Elevation Based Topography.* s.l. : Highlights of Ophthalmology, 2008. ISBN 978-9962-613-51-0.
- [27] *Clinical applications of wavefront aberrometry - a review.* N, Maeda. 1, Jan 2009, Clin Experiment Ophthalmol, Vol. 37, pp. 118-29.
- [28] Dingle T, Pepose J, Qazi M, Yoon G. Studies of wavefront aberrometry in corneal ectasia. [book auth.] Wang M. *Keratoconus and keratoectasia, Prevention, Diagnosis and Treatment.* s.l. : Slack, 2010, pp. 89-94.
- [29] *Wavefront aberrations measured with Hartmann-Shack sensor in patients with keratoconus.* Maeda N, Fujikado T, Kuroda T, Mihashi T, Hirohara Y, Nishida K, Watanabe H, Tano Y. 11, Nov 2001, Ophthalmology, Vol. 109, pp. 1996-2003.
- [30] *Corneal wavefront aberration measurements to detect keratoconus patients.* Gobbe M, Guillon M. 2, Jun 2005, Cont Lens Anterior Eye, Vol. 28, pp. 57-66.
- [31] *Apparent accommodation and corneal wavefront aberration in pseudophakic eyes.* Oshika T, Mimura T, Tanaka S, Amano S, Fukuyama M, Yoshitomi F, Maeda N, Fujikado T, Hirohara Y, Mihashi T. 9, Sep 2002, Invest Ophthalmol Vis Sci, Vol. 43, pp. 2882-6.
- [32] *Spherical aberration and depth of focus in eyes implanted with aspheric and spherical intraocular lenses: a prospective randomized study.* Rocha KM, Soriano ES, Chamon W, Chalita MR, Nosé W. 11, Nov 2007, Ophthalmology, Vol. 114, pp. 2050-4.
- [33] *Topography-guided custom ablationss.* D, Lin. Mar 2007, Refractive Eyecare, pp. 1-2.
- [34] *Collagen cross-linking (CCL) with sequential topography-guided PRK: a temporizing alternative for keratoconus to penetrating keratoplasty.* Kanellopoulos AJ, Binder PS. 7, Aug 2007, Cornea, Vol. 26, pp. 891-5.
- [35] *Management of Corneal Ectasia After LASIK with Combined, Same-Day, Topography-Guided Partial Transepithelial PRK and Collagen Cross-Linking: The Athens Protocol.* Kanellopoulos AJ, Binder PS. 5, May 2011, J Refract Surg, Vol. 27, pp. 323-31.
- [36] *Comparison of sequential vs same-day simultaneous collagen cross-linking and topography-guided PRK for treatment of keratoconus.* AJ, Kanellopoulos. 9, Sep 2009, J Refract Surg, Vol. 25, pp. S812-8.
- [37] *Managing Highly Distorted Corneas.* J, Kanellopoulos. s.l. : AAO, 2007. Subspecialty Day, Refractive Surgery.

- [38] *Topography-guided photorefractive keratectomy with Wavelight Allegretto Wave Eye-Q excimer laser system.* Quadrado M., Rosa A., Vasconcelos H., Tavares C., Murta J. s.l. : XXVIII Congress of the ESCRS, 2010.

IntechOpen

IntechOpen



Astigmatism - Optics, Physiology and Management

Edited by Dr. Michael Goggin

ISBN 978-953-51-0230-4

Hard cover, 308 pages

Publisher InTech

Published online 29, February, 2012

Published in print edition February, 2012

This book explores the development, optics and physiology of astigmatism and places this knowledge in the context of modern management of this aspect of refractive error. It is written by, and aimed at, the astigmatism practitioner to assist in understanding astigmatism and its amelioration by optical and surgical techniques. It also addresses the integration of astigmatism management into the surgical approach to cataract and corneal disease including corneal transplantation.

How to reference

In order to correctly reference this scholarly work, feel free to copy and paste the following:

Joaquim Murta and Andreia Martins Rosa (2012). Measurement and Topography Guided Treatment of Irregular Astigmatism, *Astigmatism - Optics, Physiology and Management*, Dr. Michael Goggin (Ed.), ISBN: 978-953-51-0230-4, InTech, Available from: <http://www.intechopen.com/books/astigmatism-optics-physiology-and-management/topography-guided-treatment-of-irregular-astigmatism->

INTECH
open science | open minds

InTech Europe

University Campus STeP Ri
Slavka Krautzeka 83/A
51000 Rijeka, Croatia
Phone: +385 (51) 770 447
Fax: +385 (51) 686 166
www.intechopen.com

InTech China

Unit 405, Office Block, Hotel Equatorial Shanghai
No.65, Yan An Road (West), Shanghai, 200040, China
中国上海市延安西路65号上海国际贵都大饭店办公楼405单元
Phone: +86-21-62489820
Fax: +86-21-62489821

© 2012 The Author(s). Licensee IntechOpen. This is an open access article distributed under the terms of the [Creative Commons Attribution 3.0 License](https://creativecommons.org/licenses/by/3.0/), which permits unrestricted use, distribution, and reproduction in any medium, provided the original work is properly cited.

IntechOpen

IntechOpen