

We are IntechOpen, the world's leading publisher of Open Access books Built by scientists, for scientists

6,900

Open access books available

186,000

International authors and editors

200M

Downloads

Our authors are among the

154

Countries delivered to

TOP 1%

most cited scientists

12.2%

Contributors from top 500 universities



WEB OF SCIENCE™

Selection of our books indexed in the Book Citation Index
in Web of Science™ Core Collection (BKCI)

Interested in publishing with us?
Contact book.department@intechopen.com

Numbers displayed above are based on latest data collected.
For more information visit www.intechopen.com



Controlling Astigmatism in Corneal Marginal Grafts

Lingyi Liang¹ and Zuguo Liu²

¹Zhongshan Ophthalmic Center, Sun Yat-sen University,

²Xiamen Eye Institute, Xia-men University,
China

1. Introduction

Postoperative astigmatism is inevitable after corneal marginal grafts. Visual rehabilitation following corneal transplantation remains a formidable challenge. High degrees of irregular astigmatism can lead to poor functional vision despite a clear corneal graft. The average postoperative astigmatism of penetrating keratoplasty (PK) is approximately 4 to 5 diopters despite all the improved suturing techniques, and is more obvious in eyes with marginal grafts. (Jonas et al., 2001; Riedel et al., 2001; Varley et al., 1990; Chern et al., 1997; Riedel et al., 2002; Kerényi & Süveges, 2003). The common causes of refractive error after anatomically successful marginal KP include preoperative corneal irregularity of the host and the donor, intraoperative surgical tissue alignment, uneven suture tension, and postoperative wound healing variability. Therefore, astigmatism after marginal corneal transplant is mostly irregular and unstable.

2. Detection of postoperative astigmatism

The measurement of astigmatism following marginal corneal grafting is usually quite difficult. Maloney (Maloney et al., 1993) described a method that uses mathematical algorithms to fit the measured corneal surface on the videokeratograph with the closest spherocylinder and then subtracts the curvature of the spherocylinder from that of the actual corneal surface, the difference being the amount of irregular astigmatism. This helps the quantification of the irregular astigmatism. With development in Orbscan topography technology, we can obtain information on anterior and posterior corneal curvature as well as detailed sectorial pachymetry, which may help in the detection of corneal irregularities. (Kang et al., 2000; Seitz et al., 2002) Liang (Liang et al., 2008) and Kerényi (Kerényi et al., 2003) have reported the postoperative astigmatism changes after marginal corneal grafting using Orbscan topography. The reading of Orbscan topography are consistent with the refractive cylinder. Recently, Pentacam Anterior Segment Topography has been employed in the diagnosis and monitoring of postoperative astigmatism, giving more structural and refractive information of the cornea. (Ho et al., 2009) The Pentacam is a recently introduced rotating Scheimpflug system. The Scheimpflug principle has already been established in the assessment of lens thickness and densitometry, corneal transparency, thickness, and curvature, anterior chamber depth, and in the detection of intraocular lens (IOL) tilting.

However, Pentacam is the first Scheimpflug camera-based instrument that can capture images in multiple meridians in a single automated scan. Pentacam has been more commonly used in the evaluation of postoperative astigmatism after keratoplasty and further guiding the keratotomy procedure. (Buzzonetti, et al., 2009) Further evaluation of using Pentacam specifically in marginal corneal grafting is warranted.

3. Control of postoperative astigmatism

3.1 Intraoperative control of astigmatism

As previously mentioned, the postoperative astigmatism arises partly from intraoperative surgical tissue alignment and uneven suture tension; therefore, improvement in surgical skill is essential in minimizing postoperative astigmatism. Good matching of the graft and the corneal button is required. The thickness and size of the graft should fit the recipient site to restore the contour and curvature of the cornea. As illustrated in Table 1 and Figure 1, the shape and position of the graft and the placement of sutures should be designed to avoid involving the optical zone. (Table 1).(Liang et al., 2008; Huang et al., 2008)

For marginal corneal diseases without perforation, semilunar, crescentic, and annular lamellar keratoplasties are commonly performed. The type of lamellar keratoplasty is determined by the size, depth, and location of the corneal lesion and its relationship with pupil (Table 1)

Involved area (clock hours)	Straight line between two ends of involved limbus	Pupillary area involved	Types of PK
<6	Adjucent to the interior side of the involved cornea	No	Semilunar (D shape, Fig 1A)
<6	Incorporate involved area and normal cornea	No	Crescentic (Fig 1B)
>6	Incorporate involved area and normal cornea	No	Annular (Ring shape, Fig 1C)
>6	Within the involved area	Yes	Total

Table 1. Design of different types of lamellar keratoplasty.

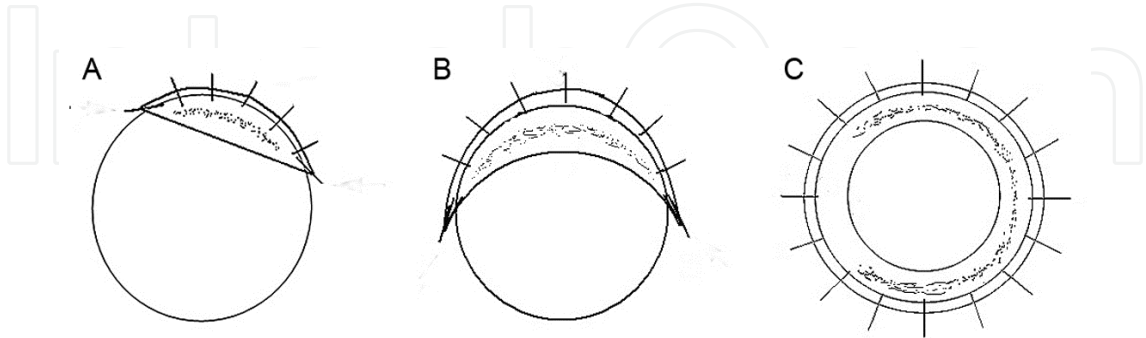


Fig. 1. Schematic Illustration of Marginal Corneal Grafts with Different Shapes According to Different Location of the Corneal Disease. Semiluna (A), Crescentic (B), and Annular (C).

The surgical pearls for different types of marginal corneal grafts are listed as following:
Semilunar (Fig 1A)/crescentic (Fig 1B) lamellar keratoplasty: the corneal epithelial side was dried, and the semilunar/crescentic shape to be excised was marked on the epithelium with

a marker pen. A diamond knife was used to cut the cornea along the epithelial marker line, reaching three-quarters of normal corneal depth. A razor blade was used for dissection parallel to the bed of stromal lamella. The thinnest area was the last to be dissected. Precise dissection of the lamellar recipient bed to form vertical margins and an even stromal bed depth is very important. Then the recipient bed was covered by the wholly dissected lamellar graft, with both limbi being precisely overlapped. The lamellar graft was secured with 10-0 nylon interrupted sutures at the limbus. The shape and border of the recipient bed could be viewed through the translucent lamellar graft. The diamond knife was used to incise the donor graft along the recipient bed border, and the remaining graft was cut off by corneal scissors. The 10-0 nylon suture was used to secure the graft with interrupted or continuous sutures at the interior side (pupil side) and interrupted sutures at the limbus.

Annular lamellar keratoplasty (Fig 1C): a 7 to 7.25 mm trephine was used to cut to a depth of three-quarters thickness of the normal cornea. A razor blade was used to dissect annular-shaped entire corneal circumference. The thinnest area was the last to dissect. The button was prepared in an annular shape leaving the central normal cornea. A trephine with same size or 0.25mm smaller was used to cut the annular donor. The annular graft was inserted into the recipient button and secured with 16 10-0 nylon sutures at the outer border. Since the inner border of the annular graft perfectly fits the inner edge of the recipient bed, the inner border can be left unsutured in most cases. When there is suspected space between graft and the bed, then eight 10-0 nylon sutures should be applied at the inner border.

If the thickness of the peripheral foci is remarkably reduced and results in evident ectasia, the donor graft should be undersized by 0.25 to 0.5 mm as compared with the recipient bed. When this narrower donor is sutured onto the wider recipient bed, tightening of non-absorbable polypropylene sutures results in a 'belt-tightening' effect with exertion of a compressive force on the recipient bed, resulting in flattening and reduction of ectasia of the cornea, and more importantly, in significant reduction in astigmatism.

In advanced cases, corneal perforation may occur before or during surgery. If the perforation is small with iris prolapsed, the anterior chamber is deep without aqueous leaking, lamellar keratoplasty mentioned above is still effective. If the perforation is small but the anterior chamber is shallow with aqueous leakage, a double lamellar keratoplasty is advocated (Fig 2). In double lamellar keratoplasty, beneath the anterior graft, a posterior endothelium graft with a same size as the perforation is sutured by interrupted 10-0 nylon. If the perforation is larger than 3 mm, penetrating keratoplasty should be considered.

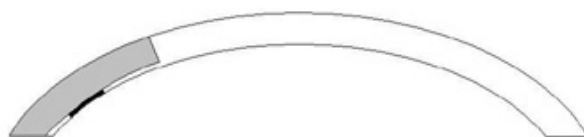

Fig. 2. Schematic Illustration of double lamellar keratoplasty. A graft with endothelium and deep lamellar is underneath the anterior lamellar graft.

When compared penetrating keratoplasty with lamellar keratoplasty, it is believed that lamellar keratoplasty has less postoperative astigmatism. The lower astigmatism in lamellar keratoplasty is ascribed to the fact that the residual corneal lamellar bed provides support to maintain the normal corneal curvature during and after surgery, which

guarantees that the above corneal graft can be placed and heal in an ideal position without corneal torsion.

Additionally, to create a smoother graft-host interface and more accurate incision depth in marginal lamellar keratoplasty, recently-developed techniques (such as excimer laser and femtosecond laser) can be applied to prepare the donor graft and recipient bed. These methods can extensively prevent high astigmatism as well as interlamellar opacification, and provide excellent refractive results (Yilmaz et al., 2007; Mian & Shtein, 2007; Sarayba et al., 2007; Schmitz et al., 2003; Soong et al., 2005).

Intraoperative keratometry is a simple device but very useful to guide adjusting sutures to create an even suture tension (Gross et al., 1997). Therefore the amount of postoperative stigmatism can be further reduced.

3.2 Postoperative control of astigmatism

Several surgical and nonsurgical options now exist for the management of postoperative astigmatism after marginal corneal grafts, and a stepwise approach to disease severity and stability would represent a logical approach. The stability of surgical induced astigmatism mainly depends on the duration of postoperative period. Videokeratography such as Orbscan topography or Pentacam helps to detect and to monitor the changes of corneal astigmatism after surgery.

For low and stable corneal irregular astigmatism, patients are visually rehabilitated with glasses or contact lens. In cases of high but stable corneal irregular astigmatism, surgical intervention becomes an option. According to Guell's definition, "low" means 2 or fewer Snellen lines of difference between the best rigid gas permeable contact lens (RGP) visual acuity and best spectacle corrective visual acuity (BSCVA). When this difference is more than two lines we consider the case as high irregular astigmatism. (Guell & Velasco, 2003)

3.2.1 Contact lens

Although spectacles are the simplest method of addressing postoperative refractive error, its corrective effect for irregular astigmatism is limited. Contact lenses often provide superior visual acuity and are frequently required in eyes with evident irregular astigmatism. Designing a contact lens for a patient who has undergone keratoplasty will require the practitioner to carefully assess all the relevant features of the corneal graft. In this regard, there are many factors that need to be considered including the diameter of the graft zone, the topographical relationship between the host cornea and donor cornea, the corneal (graft) toricity and the location of the graft. (Szczotka & Lindsay, 2003)

The various types of contact lens tried in patients with postoperative astigmatism include soft toric lenses, scleral and toric PMMA contact lens, rigid gas permeable (RGP) contact lens, apex and toric RGP lenses, Softperm and scleral lenses. It is generally believed that a spherical rigid lens can correct up to 4D of corneal astigmatism and for higher astigmatism, a back toric or bitoric lens is preferred. Kastl and Kirby reported usefulness of bitoric rigid contact lens for high corneal astigmatism. The lenses can be manufactured in gas-permeable material for corneas with as much as 6D of toricity. (Kastl & Kirby, 1987)

Kompellar et al have reported that large-diameter RGP contact lenses are better tolerated and lead to significant improvement in visual acuity in patients with irregular astigmatism caused by marginal corneal ectasia. (Kompella et al., 2002) In advanced cases, the high asymmetric against-the-rule astigmatism makes soft lens and rigid lens fitting difficult. The

Softperm lens, which has a central RGP portion and a peripheral hydrophilic skirt, has been found useful in correcting irregular astigmatism. (Astin1994) The introduction of gas-permeable scleral contact lenses has generated a renewed interest. (Pullum & Buckley, 1997) These lenses offer advantages over other lens designs, such as easy maintenance and a scleral bearing surface that eliminates the need for close alignment between the cornea and the lens compared with a RGP contact lens (as required in RGP lenses).

3.2.2 Selective removal or augmentation of suture

Selective suture removal should be waited at least 6-8 weeks after surgery if there is no loose suture. The suture removal should be based on central keratometry readings and corneal topography. The curvature, contour of the whole cornea and the amount of astigmatism, as well as the steepest and flattest axis are evaluated before suture removal. The suture in the steep axis is removed then. Vice Versa, the suture in the flat axis can be considered to be augmented for the same reason. The topographic changes induced by suture removal occurred immediately. However, continued shifting in corneal curvature did take place over the subsequent 4 to 6 weeks. Unpredictable shifts were more pronounced in patients whose surgery had been performed more than 20 months prior to suture removal.(Goren et al., 1997)

3.2.3 Surgical intervention

Many patients who have undergone corneal transplantation are unable to achieve satisfactory visual acuity with spectacle and contact lens correction alone. On the other hand, contact lenses are sometimes difficult to fit, and they may induce peripheral corneal neovascularization, increasing the risk of graft rejection and failure. Furthermore, some patients, especially the elderly, those with bilateral poor vision, and those with severe dry eye, are unable to handle or to maintain contact lenses. For these patients, refractive surgery becomes a viable option to reduce the post-keratoplasty astigmatism. With the many recent advances in refractive surgery, new possibilities arise for application to improve the vision rehabilitation in patients after marginal keratoplasty. The indication for surgery in patients with postoperative astigmatism after marginal corneal graft is stable but remarkable astigmatism that cannot be corrected by conventional optical means or contact lens intolerance.

Prior to attempting refractive surgery after keratoplasty, there must be adequate tectonic, refractive, and immunogenic stability. The timing of surgery should generally be at least 12 months after keratoplasty and 3 months after suture removal. Since inflammation induced by surgery is a trigger factor of graft rejection, it is advocated that the patient should be stable on minimal immunosuppressive agents before and after surgery (Preschel et al., 2000). Astigmatism should be evaluated through a combination of refraction, keratometry, keratotomy, corneal videokeratography, and wavefront analysis. Slit-lamp biomicroscopy should be used to evaluate graft location, size, and clarity, with attention to areas of haze or neovascularization. For cases of lamellar keratoplasty, the graft-host interface should be assessed for quality of apposition, override or underide, asymmetry, and edema. Pachymetry measurements should be performed centrally and on either side of the graft-host interface. Specular microscopy is helpful in determining the status of the endothelial cell layer (Preschel et al., 2000).

3.2.3.1 Releasing incision or wedge excision

Topographic guided releasing incision or wedge excision remains a common and simple method of reducing astigmatism after keratoplasty. The biomechanical effects of incisional

keratotomy on post-keratoplasty corneas continue to be studied. The biomechanical response to contraction or relaxation of corneal tissue forms the basis of incisional keratotomy. Using the same principles as selective suture removal, radial and astigmatic keratotomies are rapid and feasible, but their refractive effects are highly variable. Relaxing incision should be designed in the steep axis; while the wedge excision should be designed in the flat axis. Relaxing incisions and compression sutures can correct an average of 4–5 D of astigmatism (Hardten & Lindstrom, 1997). In a recent study evaluating the refractive effect of a standardized incision, the astigmatic effect was found to be proportional to the magnitude of the preoperative cylinder. This suggests that nomograms for congenital astigmatism do not apply to the correction of post-keratoplasty astigmatism (Wilkins et al., 2005). The releasing incision or wedge excision can also be combined with selective adjustment of sutures (Javadi et al., 2009).

As for relaxing incision, two relaxing incisions of 3 clock hours, at 3/4 depth, are used. This procedure may be in combination with two sets of three compression sutures placed 90 degrees from the incisions. Selective removal of the compression sutures allows for a graded reduction in overcorrection. A mean reduction in astigmatism of 6–7 D can be achieved 3 months postoperatively. (Lustbader & Lemp, 1990)

As for wedge excision, a thin sliver of cornea measuring between 0.1 and 0.2 mm in thickness was excised from just inside the graft-recipient interface. The length of the incision centered at the axis of the flatter meridian of the cornea and was extended over a range of 60–90 degrees. The wound was closed with interrupted 10-0 nylon sutures placed every 15 degrees. The mean reduction in astigmatism in this method ranges from 6.3 to 25.4 D. (Ezra et al., 2007)

It should be noted that most of the studies on relaxing incision and wedge excision are carried on routine centric keratoplasty, studies on their potential effect on marginal corneal graft are warranted. According to author's experience, in cases of marginal corneal grafting, it will be better not to involve the graft when designing the incision or excision. Otherwise the wound of corneal graft may take the risk of dehiscence.

3.2.3.2 Laser treatment

Most authors wait at least 1 year after keratoplasty and 3 months after last suture removal or other refractive procedure prior to performing laser refractive surgeries. Good wound apposition with minimal graft override and underide is important. Adequate endothelial cell counts should also be assessed.

Photorefractive keratectomy has been used after keratoplasty since the early 1990s (Campos et al., 1992). Unfortunately, these studies demonstrated substantial regression, haze, and even severe scarring (Bilgihan et al., 2000). The adjunctive use of mitomycin C 0.02% (0.2 mg/ml) is a promising new method of scar prevention in eyes undergoing photorefractive keratectomy. (Gambato et al., 2005). Photorefractive keratectomy with mitomycin C was used to treat post-keratoplasty hyperopic astigmatism. It should be noted that with larger ablation zones and deeper peripheral ablation than myopic treatments, hyperopic treatments may particularly compromise the integrity of the graft-host junction. No complications have been reported with the adjunctive one-time use of mitomycin C at the time of photorefractive keratectomy.

Nowadays, LASIK has become a popular modality for correcting refractive error after corneal transplantation. This can be combined with arcuate keratotomies and wedge resections for optimal astigmatic control (Barraquer & Rodriguez-Barraquer, 2004; Buzard et al., 2004).

Conductive keratoplasty is a radiofrequency-based technique that denatures and shrinks corneal stromal collagen from the heat generated secondary to tissue resistance to current flow. Although conductive keratoplasty is most often used for the reduction of low to moderate levels of hyperopia (McDonald et al., 2002), some have applied this technique to treat post-LASIK hyperopia (Comaish & Lawless, 2003). The potential effect of this modality in treating post-keratoplasty irregular astigmatism remains unknown.

3.2.3.3 Intraocular refractive surgery

As the understanding of post-keratoplasty biomechanics improves, the ability to apply incisional techniques can be refined with more accurate nomograms. More efficient methods of phacoemulsification are less traumatic to the cornea and warrant further study in this setting. New lens implants allow for the correction of high degrees of astigmatism. Modern cataract surgery appears to have lower incidences of graft rejection and failure. Developments in lens implantation technology continue to offer expanding options for intraocular refractive surgery.

A toric Artisan, or Verisyse, iris-fixated intraocular lens (Ophtec BV, Groningen, The Netherlands) has been used to correct spherocylindrical refractive error after penetrating keratoplasty. In Nuijts's study, the mean time from keratoplasty to lens implantation was 48.9 months, with a mean 21.3 months after suture removal. After implantation, mean refractive spherical equivalent decreased from 4.09 D to 0.96 D, and mean cylinder decreased from 6.66 D to 1.42 D. Eight eyes (50%) had a postoperative uncorrected visual acuity of 20/40 or better, and 94% of eyes were 20/80 or better. No eyes lost lines of best-corrected visual acuity, and eight eyes (50%) gained two or more lines. Although the endothelial loss rate was 7.6% at 3 months and 21.7% at 6 months, there were no cases of graft failure during the study period (Nuijts et al., 2004).

3.2.4 Cross-linking

In recent years, a variety of treatment modalities have emerged, and includes methods to increase corneal rigidity, such as a novel UVA/riboflavin collagen cross-linking approach. This treatment, however, requires longer term study, and is currently limited to few centres. This utilizes UVA at 370nm to activate riboflavin, generating reactive oxygen species that induce covalent bonds between collagen fibrils. The procedure involves first removing corneal epithelium within a central 6–7mm diameter zone. Riboflavin 0.1% solution is applied at 5-min intervals starting 5–20 min before UVA irradiation, which is provided by an array of two to seven ultraviolet emitting diodes (Vinciguerra et al., 2006). Irradiance is calibrated for 3mW/cm² at a working distance of 1cm from the cornea. Exceeding this level of irradiance is contraindicated, and patients with corneal thicknesses of under 400mm should also be excluded as the cytotoxic threshold for the endothelium would be breached. In general, the effects of this treatment are limited in the anterior cornea (Spoerl & Seiler, 2004), and Seiler and Hafezi (Seiler & Hafezi, 2006) reported their findings of a demarcation line visible on slit lamp examination at approximately 60% corneal depth.

Clinically, ultraviolet cross-linking treatment appears to be able to slightly flatten of the cornea of up to 2D and increase the corneal symmetry. (Caporossi et al., 2006). Since this treatment alone does not normalize corneal curvature, attempts have been made to combine it with other surgical modalities. While these results appear promising, further studies evaluating safety, stability of effect, and in addition, combination of cross-linking technology with other modalities remain an intriguing possibility in the treatment of postoperative astigmatism after marginal corneal grafts.


Intrastromal ring implants is an alternative option in the treatment of corneal ectasia induced irregular astigmatism. However, it requires a high safe corneal margin which is absent in post marginal corneal grafts. Therefore, intrastromal ring implants is not advocated in these subset of patients.

4. References

- Adzick NS, Lorenz HP. (1994). Cells, matrix, growth factors, and the surgeon. The biology of scarless fetal wound repair. *Ann Surg*, Vol.220, pp.10-18.
- Astin CL.(1994). The long-term use of the SoftPerm lens on pellucid marginal corneal degeneration. *CLAO J*. Vol.20, No.4, pp.258-260.
- Barraquer C C, Rodriguez-Barraquer T.(2004). Five-year results of laser in-situ keratomileusis (LASIK) after penetrating keratoplasty. *Cornea*. Vol.23, No.3, pp.243-248.
- Bilgihan K, Ozdek SC, Akata F, Hasanreisoglu B.(2000). Photorefractive keratectomy for post-penetrating keratoplasty myopia and astigmatism. *J Cataract Refract Surg*. Vol.26, No.11, pp.1590-1595.
- Buzard K, Febbraro JL, Fundingsland BR.(2004). Laser in situ keratomileusis for the correction of residual ametropia after penetrating keratoplasty. *J Cataract Refract Surg*. Vol.30, No.5, pp.1006-1013.
- Buzzonetti L, Petrocelli G, Laborante A, Mazzilli E, Gaspari M, Valente P.(2009) Arcuate keratotomy for high postoperative keratoplasty astigmatism performed with the intralase femtosecond laser. *J Refract Surg*. Vol.25, No.8, pp.709-714.
- Campos M, Hertzog L, Garbus J, Lee M, McDonnell PJ.(1992). Photorefractive keratectomy for severe postkeratoplasty astigmatism. *Am J Ophthalmol*. Vol.114, No.4, pp.429-436.
- Caporossi A, Baiocchi S, Mazzotta C, Traversi C, Caporossi T.(2006). Parasurgical therapy for keratoconus by riboflavin-ultraviolet type A rays induced cross-linking of corneal collagen: preliminary refractive results in an Italian study. *J Cataract Refract Surg*. Vol.32, No.5, pp.837-845.
- Chern KC, Meisler DM, Wilson SE, Macsai MS, Krasney RH.(1997). Small-diameter, round, eccentric penetrating keratoplasties and corneal topographic correlation. *Ophthalmology*. Vol.104, No.4, pp.643-7.
- Comaish IF, Lawless MA.(2003). Conductive keratoplasty to correct residual hyperopia after corneal surgery. *J Cataract Refract Surg*. Vol.29, No.1, pp.202-206.
- Ezra DG, Hay-Smith G, Mearza A, Falcon MG.(2007). Corneal wedge excision in the treatment of high astigmatism after penetrating keratoplasty. *Cornea*. Vol.26, No.7, pp.819-825.
- Gambato C, Ghirlando A, Moretto E, Busato F, Midena E.(2005). Mitomycin C modulation of corneal wound healing after photorefractive keratectomy in highly myopic eyes. *Ophthalmology*. Vol.112, No.2, pp.208-218.
- Goren MB, Dana MR, Rapuano CJ, Gomes JA, Cohen EJ, Laibson PR.(1997). Corneal topography after selective suture removal for astigmatism following keratoplasty. *Ophthalmic Surg Lasers*. Vol.28, No.3, pp.208-214.
- Gross RH, Poulsen EJ, Davitt S, Schwab IR, Mannis MJ.(1997). Comparison of astigmatism after penetrating keratoplasty by experienced cornea surgeons and cornea fellows. *Am J Ophthalmol*. Vol.123, No.5, pp.636-43.

- Guell JL, Velasco F.(2003). Topographically guided ablations for the correction of irregular astigmatism after corneal surgery. *Int Ophthalmol Clin*. Vol.43, No.3, pp.111-28.
- Hardten DR, Lindstrom RL.(1997). Surgical correction of refractive errors after penetrating keratoplasty. *Int Ophthalmol Clin*. Vol.37, No.1, pp.1-35.
- Ho JD, Tsai CY, Liou SW.(2009). Accuracy of corneal astigmatism estimation by neglecting the posterior corneal surface measurement. *Am J Ophthalmol*. Vol.147, No.5, pp.788-95.
- Huang T, Wang Y, Ji J, Gao N, Chen J.(2008). Evaluation of different types of lamellar keratoplasty for treatment of peripheral corneal perforation. *Graefes Arch Clin Exp Ophthalmol*. Vol.246, No.8, pp.1123-31.
- Javadi MA, Feizi S, Mirbabaei F, Rastegarpour A.(2009). Relaxing incisions combined with adjustment sutures for post-deep anterior lamellar keratoplasty astigmatism in keratoconus. *Cornea*. Vol.28, No.10, pp.1130-1134.
- Jonas JB, Rank RM, Budde WM.(2001). Tectonic sclerokeratoplasty and tectonic penetrating keratoplasty as treatment for perforated or predescemetal corneal ulcers. *Am J Ophthalmol*, Vol.132, No.1, pp.14-8.
- Kang SW, Chung ES, Kim WJ.(2000). Clinical analysis of central islands after laser in situ keratomileusis. *J Cataract Refract Surg*. Vol.26, No.4, pp.536-42.
- Kastl PR, Kirby RG.(1987). Bitoric rigid gas permeable lens fitting in highly astigmatic patients. *CLAO J*. Vol.13, No.4, pp.215-216.
- Kerényi A, Süveges I.(2003). Corneal topographic results after eccentric, biconvex penetrating keratoplasty. *J Cataract Refract Surg*. Vol.29, No.4, pp.752-6.
- Kompella VB, Aasuri MK, Rao GN.(2002). Management of pellucid marginal corneal degeneration with rigid gas permeable contact lenses. *CLAO J*. Vol.28, No.3, pp.140-145.
- Liang LY, Liu ZG, Chen JQ, Huang T, Wang ZC, Zou WJ, Chen LS, Zhou SY, Lin AH.(2008). Keratoplasty in the management of Terrien's marginal degeneration. *Zhonghua Yan Ke Za Zhi*. Vol.44, No.2, pp.116-21.
- Lustbader JM, Lemp MA.(1990). The effect of relaxing incisions with multiple compression sutures on post-keratoplasty astigmatism. *Ophthalmic Surg*. Vol.21, No.6, pp.416-419.
- Maloney RK, Bogan SJ, Waring GO 3rd.(1993). Determination of corneal image-forming properties from corneal topography. *Am J Ophthalmol*. Vol.115, No.1, pp.31-41.
- McDonald MB, Hersch PS, Manche EE, Maloney RK, Davidorf J, Sabry M.(2002). Conductive Keratoplasty United States Investigators Group. *Ophthalmology*. Vol.109, No.11, pp.1978-1989.
- Mian SI, Shtein RM.(2007). Femtosecond laser-assisted corneal surgery. *Curr Opin Ophthalmol*. Vol.18, No.4, pp.295-299.
- Nuijts RM, Abhilakh Missier KA, Nabar VA, Japing WJ.(2004). Artisan toric lens implantation for correction of postkeratoplasty astigmatism. *Ophthalmology*. Vol.111, No.6, pp.1086-1094.
- Riedel T, Seitz B, Langenbucher A, Naumann GO.(2001). Morphological results after eccentric perforating keratoplasty. *Ophthalmologe*. Vol.98, No.7, pp.639-46.
- Riedel T, Seitz B, Langenbucher A, Naumann GO.(2002). Visual acuity and astigmatism after eccentric penetrating keratoplasty - a retrospective study on 117 patients. *Klin Monbl Augenheilkd*. Vol.219, No.1-2, pp.40-5.

- Preschel N, Hardten DR, Lindstrom RL.(2000). LASIK after penetrating keratoplasty. *Int Ophthalmol Clin*. Vol.40, No.3, pp.111-123.
- Pullum KW, Buckley RJ.(1997). A study of 530 patients referred for rigid gas permeable scleral contact lens assessment. *Cornea*. Vol.16, No.6, pp.612-622.
- Sarayba MA, Maguen E, Salz J, Rabinowitz Y, Ignacio TS.(2007). Femtosecond laser keratome creation of partial thickness donor corneal buttons for lamellar keratoplasty. *J Refract Surg*. Vol.23, No.1, pp.58-65.
- Schmitz K, Schreiber W, Behrens-Baumann W.(2003). Excimer laser “corneal shaping”: a new technique for customized trephination in penetrating keratoplasty. First experimental results in rabbits. *Graefes Arch Clin Exp Ophthalmol*. Vol.241, No.5, pp.423-431.
- Seiler T, Hafezi F.(2006). Corneal cross-linking-induced stromal demarcation line. *Cornea*. Vol.25, No.9, pp.1057-1059.
- Seitz B, Langenbucher A, Torres F, Behrens A, Suárez E.(2002). Changes of posterior corneal astigmatism and tilt after myopic laser in situ keratomileusis. *Cornea*. Vol. 21, No.5, pp.441-6.
- Soong HK, Mian S, Abbasi O, Juhasz T (2005) Femtosecond laser-assisted posterior lamellar keratoplasty: initial studies of surgical technique in eye bank eyes. *Ophthalmology*. Vol.112, No.1, pp.44-49.
- Spoerl E, Seiler T.(1999). Techniques for stiffening the cornea. *J Refract Surg*. Vol.15, No.6; pp.711-713.
- Szczotka LB, Lindsay RG.(2003). Contact lens fitting following corneal graft surgery. *Clin Exp Optim*. Vol.86, No.4, pp.244-9.
- Varley GA, Macsai MS, Krachmer JH.(1990). The results of penetrating keratoplasty for pellucid marginal corneal degeneration. *Am J Ophthalmol*. Vol.110, No.2, pp.149-52.
- Vinciguerra P, Albè E, Trazza S, Rosetta P, Vinciguerra R, Seiler T, Epstein D.(2009). Refractive, topographic, tomographic, and aberrometric analysis of keratoconic eyes undergoing corneal cross-linking. *Ophthalmology*. Vol.116, No.3, pp.369-378.
- Wilkins MR, Mehta JS, Larkin DF.(2005). Standardized arcuate keratotomy for postkeratoplasty astigmatism. *J Cataract Refract Surg*. Vol.31, No.2, pp.297-301.
- Yilmaz S, Ali Ozdil M, Maden A (2007) Factors affecting changes in astigmatism before and after suture removal following penetrating keratoplasty. *Eur J Ophthalmol*. Vol.17, No.3, pp.301-306.



Astigmatism - Optics, Physiology and Management

Edited by Dr. Michael Goggin

ISBN 978-953-51-0230-4

Hard cover, 308 pages

Publisher InTech

Published online 29, February, 2012

Published in print edition February, 2012

This book explores the development, optics and physiology of astigmatism and places this knowledge in the context of modern management of this aspect of refractive error. It is written by, and aimed at, the astigmatism practitioner to assist in understanding astigmatism and its amelioration by optical and surgical techniques. It also addresses the integration of astigmatism management into the surgical approach to cataract and corneal disease including corneal transplantation.

How to reference

In order to correctly reference this scholarly work, feel free to copy and paste the following:

Lingyi Liang and Zuguo Liu (2012). Controlling Astigmatism in Corneal Marginal Grafts, *Astigmatism - Optics, Physiology and Management*, Dr. Michael Goggin (Ed.), ISBN: 978-953-51-0230-4, InTech, Available from: <http://www.intechopen.com/books/astigmatism-optics-physiology-and-management/controlling-astigmatism-in-marginal-corneal-grafts>



InTech Europe

University Campus STeP Ri
Slavka Krautzeka 83/A
51000 Rijeka, Croatia
Phone: +385 (51) 770 447
Fax: +385 (51) 686 166
www.intechopen.com

InTech China

Unit 405, Office Block, Hotel Equatorial Shanghai
No.65, Yan An Road (West), Shanghai, 200040, China
中国上海市延安西路65号上海国际贵都大饭店办公楼405单元
Phone: +86-21-62489820
Fax: +86-21-62489821

© 2012 The Author(s). Licensee IntechOpen. This is an open access article distributed under the terms of the [Creative Commons Attribution 3.0 License](https://creativecommons.org/licenses/by/3.0/), which permits unrestricted use, distribution, and reproduction in any medium, provided the original work is properly cited.

IntechOpen

IntechOpen