

We are IntechOpen, the world's leading publisher of Open Access books Built by scientists, for scientists

6,900

Open access books available

185,000

International authors and editors

200M

Downloads

Our authors are among the

154

Countries delivered to

TOP 1%

most cited scientists

12.2%

Contributors from top 500 universities



WEB OF SCIENCE™

Selection of our books indexed in the Book Citation Index
in Web of Science™ Core Collection (BKCI)

Interested in publishing with us?
Contact book.department@intechopen.com

Numbers displayed above are based on latest data collected.
For more information visit www.intechopen.com



Pediatric Kidney Transplant in Uropathies

Cristian Sager, Juan Carlos López, Víctor Durán,
Carol Burek, Juan Pablo Corbetta and Santiago Weller
*Hospital Nacional de Pediatría Prof. Dr. J. P. Garrahan
Argentina*

1. Introduction

It has been long reported that for children with end-stage renal disease (ESRD), renal transplant is the treatment of choice (Fine et al., 1978; Gradus & Ettenger, 1982). With this approach the lost renal function is reestablished and the pondo-stature, psycho-intellectual and social development is not affected (Ferraris & Rodriguez, 2008).

Hemodialysis or ambulatory peritoneal dialysis are modalities used in the treatment of children with ESRD when there is no living donor available or when patients are waiting for a cadaver donor (Galvez et al., 2005). However, these patients will eventually present growth and intellectual development alterations.

In 1954 Murray performed the first truly successful pediatric kidney transplant from one homozygous twin to another (Murray et al., 1958). In 1966 Kelly reported a kidney transplantation in a patient with dysfunctional bladder who had undergone ileal segment urinary diversion (Kelly et al., 1966). Until that time, patients with ESRD and untreatable dysfunctional urinary tract were excluded from renal transplant programs. At that time, it was believed that the renal allograft connected to a dysfunctional bladder would run the same risk as the native kidneys, that is, the result would be again renal insufficiency (Sheldon et al., 1994).

As a consequence, the focus began to be placed on the restoration of the dysfunctional lower urinary tract with the aim of creating urinary reservoirs of adequate volume and low pressure that could have complete voiding capacity (Mitchell & Piser, 1987). At present, children with ESRD can benefit from renal transplantation provided the lower urinary tract dysfunctions are corrected or reestablished by means of medical and/or surgical treatment (Broyer et al., 2004). Otherwise, the bladder dysfunction that is not corrected would have a negative effect on the allograft function (Salomon et al., 2000).

Several studies reporting long term encouraging results on patients that have received kidney transplantation with urinary tract reconstructions have been published. However, higher risks and incidence of complications related to the allograft and reconstruction have also been informed (Shekarris et al., 2000). Despite these risks, Luke obtained comparable and acceptable results in children with reconstructed urinary tract, similar to the renal transplanted subjects that had normal lower urinary tract function, following a careful pre-transplant evaluation and an appropriate post-transplant follow-up (Luke et al., 2003)

Nevertheless, there exists considerable controversy around the best approach to handle these types of patients, since there are no guidelines designed with defined reconstructive surgical criteria, optimal surgical procedures or recommendations as to when the best time to perform such interventions (Riley et al., 2010).

2. Etiologies for end stage renal disease – Uropathies

Among the most frequent etiologies for end stage renal disease are renal hypodysplasia (17%), obstructive uropathies (16.9%), focal segmental glomerulosclerosis (9%), vesicoureteral reflux (6.3%), renal polycystosis, uremic hemolytic syndrome, Prune belly, neurogenic bladder due to neural tube defects, among others (North American Pediatric Renal Transplant Cooperative Study (N.A.P.R.T.C.S.), 2007)

The predominance of one or other etiology is conditioned by the different geographical regions. The deterioration of the renal function is not the most common consequence of vesicoureteral reflux (VUR), with an estimated risk lower than 1%. There is a direct relationship between the degree of VUR and the incidence of the nephropathy (Skoog et al, 1987). Up to 35% of renal scarring is congenital, due to dysmorphic renal tissue from the gestational stage, especially in high degree VUR. When there is vesicoureteral reflux the patient is prone to develop pyelonephritis, and if this occurs during the first months of life or in repeated fashion, there are more chances of developing renal scars and aggravating the renal function. The incidence of chronic pyelonephritis is within 15 and 25% of ESRD.

The term 'obstructive uropathies' includes entities such as pyeloureteral stenosis, ureterovesical stenosis, obstructive megaureters and prior surgically corrected obstructive uropathy remnants. All these uropathies manifest as hydronephrosis or ureterohydronephrosis. The obstruction to the urine flow, if not corrected, eventually produces irreversible reduction of the function, depending on whether the obstruction is bilateral, affects only one kidney or an insufficient one (Podestá & Bertolotti, 2008).

Posterior urethral valve (PUV) remains the most frequent organic-anatomical obstruction in males and it is due to a congenital defect in the development of the membranous urethra. This condition can manifest along a spectrum of severity, ranging from disease incompatible with postnatal life to conditions that have minimal impact later in life. Chronic obstruction of the outlet urinary tract during the critical stage of organogenesis of the urinary system exerts a deep impact on the kidneys, ureters and vesical function. Approximately a third of the patients with PUV progress to ESRD (López & Durán, 2008).

In the case of Prune belly syndrome the kidneys may exhibit: ureterohydronephrosis, VUR, renal dysplasia, anatomical infravesical obstruction. This syndrome has a broad spectrum of affected anatomy with different levels of severity, from incompatibility with life to minimally compromised renal function (Woodward & Smith, 1998). Many patients require multiple urological surgeries with some cases of irreversible deterioration in the renal mass.

Patients with a neurogenic bladder caused by spinal dysraphism that do not receive appropriate treatment can progress to ESRD (De Jong et al., 2008). Spinal dysraphism abnormalities mainly include myelomeningocele, lipomeningocele and caudal regression

syndrome. All of them generate different types of behavior of the neurogenic bladder and particularly affect the renal function (Torre et al., 2011).

The urodynamic variables that are more involved as risk factors are: detrusor hyperactivity, reduced compliance, detrusor-sphincter dyssynergia.

Medical therapies implemented during the first months of life and sustained by anticholinergic drugs and clean intermittent catheterization greatly help to avoid compromise or deterioration of the renal function.

3. Evaluation of the urinary tract

There is general consensus among the most prominent health care centers that assessment of the lower urinary tract before performing a renal transplant is of the utmost importance. If alterations are found, they must be corrected before the allograft is implanted. A dysfunctional lower urinary tract that has promoted the deterioration of the native kidneys represents a risk for the allograft.

In the first place, a history of baseline pathologies and a thorough physical examination are fundamental, since they determine which complementary studies will be needed. It is not necessary to have all patients undergo all possible urological studies. For that reason it is useful to define beforehand whether ESRD was caused by a nephropathy or by an uropathy. If the latter applies, it is necessary to classify patients into two groups: those who did not require urinary tract surgery and those who did.

Overall, for the group of patients who required lower urinary tract surgery most of the complementary studies described below will be needed. When the signs and symptoms reported by patients or parents are not clear enough, especially with respect to urinary incontinence or alterations of the voiding frequency, keeping a voiding diary and a record of urinary leakage becomes very useful.

On occasions, when the history or symptoms of urologic pathology are not defined, we must resort to other specialties for further evaluation, such as neurology-neurosurgery, in order to search for the etiological diagnosis of certain urinary dysfunctions.

The physical examination also includes the assessment of the abdominal and pelvic region for position of dialysis catheters, intestinal and urinary stomas, either for possible reconstructions of the urinary tract or to locate a future allograft implantation. In addition, it is necessary to analyze the status and mobility of lower and upper limbs, with the purpose of deciding whether intermittent catheterization could be used for bladder voiding, via the urethra or via continent stoma.

Ultrasound scanning is the initial technique of choice in order to detect morphological abnormalities. Although it is operator/observer-dependent, it does not present any contraindications and it can be repeated as many times as necessary without having damaging effects on the patient (Bibiloni, et al., 2008). In ESRD, ultrasound is used in order to characterize degree of ureterohydronephrosis, double ureter systems and characteristics of the vesical wall. If diuresis exists, ultrasound scanning with full and empty bladder is required in order to evaluate if there is post void residual or ureterohydronephrosis alterations.

Voiding cystourethrogram is mandatory, especially in the case of patients with a history of urinary infections and lower urinary tract surgeries. It is an irreplaceable method to detect vesicoureteral reflux, to show anatomical details of the bladder neck, of the male urethra, and to characterize other findings, such as bladder stones and irregularities of the bladder wall. This methodology also provides information on voiding pathophysiology. As it is an invasive procedure that uses fluoroscopy radiation, it must be carried out by trained professionals, so that the method can be optimized.

Urodynamic studies record the activity of the lower urinary tract in the filling and voiding phases of the bladder. The variables recorded, such as volume, bladder pressure, urinary leakage pressure, bladder compliance, detrusor muscle stability, coordination of the cycle, perineal surface electromyography activity, among others, determine the type of bladder dysfunction and help to indicate the most appropriate treatment and to control the evolution and therapeutic response (Burek & Sager, 2008). Urodynamic studies are required when there is a history of spinal dysraphism and other etiologies of neurogenic bladder, posterior urethra valves, lower urinary tract surgeries, urine incontinence, therapy with anticholinergic drugs, anatomical alterations as shown in the voiding cystourethrogram and high degree of vesicoureteral reflux.

In the latter case, a video urodynamic study is the preferred method, since it combines the benefits of voiding cystourethrography and urodynamic records. This results in a thorough anatomic and functional evaluation of the urinary tract. The video urodynamic study requires a certain degree of technical complexity and it must be performed by very well-trained professionals. In the case of some patients, in order to simplify and reduce manipulation, the following algorithm can be applied: renovesical ultrasound and video urodynamic study (Cerruto & Artibani, 2006).

4. Adequate bladder function

The urinary tract can be described as being “functional” if the storage and voiding phases of the bladder function in a coordinated way. In the first phase, the pelvis and ureters must void an adequate volume of urine into a bladder or neobladder of low pressure without leaks. Competent ureterovesical junctions stop urine from refluxing into the upper urinary tract. During the voiding phase, the bladder muscle (detrusor) contracts at regular intervals and in a sustained fashion, with relaxation of the outlet urinary tract (bladder neck and sphincter) with the purpose of eliminating urine. Many patients cannot achieve normal voiding and require clean intermittent catheterization.

After evaluation is completed we must define whether the lower urinary tract is in good condition to receive an implant. The parameters used to define “adequate bladder function” are:

- Absence of signs and symptoms of low urinary tract dysfunction.
- Absence or scant post void residual urine on renovesical ultrasound.
- Adequate volume capacity and bladder compliance, stability of the detrusor muscle, adequate voiding, no post void residual and no leaks as assessed by urodynamic/video urodynamic studies (Barry, 2004).

If assessment outcome shows that the lower urinary tract is not in adequate condition to receive a new kidney, therapy customized to the particular urologic condition should be

indicated and a new evaluation should be carried out prior to transplantation. If reconstruction of the lower urinary tract is to be performed, the objective is to achieve a functional urinary tract.

5. Treatments for the lower urinary tract

5.1 Medical treatments

The objective of any treatment is to provide a safe mechanism of drainage for those patients who have voiding difficulties, by means of clean intermittent catheterization (CIC) and pharmacological reduction of storage pressure or non-inhibited contractions with the use of anticholinergic drugs.

CIC is the most significant advancement in the urological care of patients with neurogenic dysfunction of the lower urinary tract. This procedure provides adequate voiding and a reduced risk of urinary infections; it helps to avoid bladder overdistension; it facilitates resolution of the vesicoureteral reflux and favors urinary continence. CIC may be performed at any age, on both sexes and at any position and site. It can be indicated in the presence of high intravesical pressure, detrusor-sphincter dyssynergia, sphincter hypertonia, high residual urine volume and absence of spontaneous voiding. It is fundamental that instruction of the procedure be in charge of trained nurses, who will also supervise CIC management periodically.

CIC is a safe, easy and effective way of emptying the bladder with a low rate of complications. Although unusual, the most frequent complications are urethral bleeding and false passages, and epididymitis. Asymptomatic bacteriuria is observed in 70% of patients, but it is not associated to renal scarring; therefore, it is not treated. Antibiotic prophylaxis is indicated only at the beginning of CIC to patients with vesicoureteral reflux and those who have received a renal transplantation.

Anticholinergic drugs, mainly oxybutynin, are used for the treatment of hyperreflexia and bladder hypertonia. They are widely used in pediatric settings; they are of acceptable tolerance and they have proved to provide a beneficial therapeutic effect. For those patients who do not tolerate oxybutynin, tolterodine can be used. It is more selective; it has fewer adverse effects, but does not seem to have more efficacy. Other even more selective drugs, such as darifenacin, are also being used lately in the pediatric population.

The selective alpha-adrenergic blockade is a therapeutic alternative in cases of dysfunctional voiding of different etiologies. It facilitates the release of infravesical outflow obstruction. Doxazosin is one of the most commonly used drugs (Austin et al., 1999) Biofeedback therapy, mainly used with patients with non-neurogenic bladder dysfunction, contributes to educating, relaxing the perineum region and improving the dynamics of the detrusor-neck-sphincter unit.

5.2 Surgical treatment

5.2.1 Reconstruction of the urinary tract in children

The aim of the surgical intervention/s is to reestablish a new system that can protect the renal function and achieve adequate urine volume at low pressure, avoid urinary infections and lead to continence.

At present, most of the reconstructive procedures are performed in order to correct anomalies of the native urinary tract refractory to medical treatment. Children with bladder and sphincter dysfunction represent a big challenge and most patients who require reconstructive procedures have myelodysplasia as etiology for the neurogenic bladder.

The pathophysiological ways that lead to dysfunction of the excretory system are manifold; therefore, the evaluation of reconstruction should be meticulous and individualized. In addition to technical surgical matters, in questions of evolution and outcome it is important to consider the commitment of the patient and the family in the monitoring and post-surgery care. When a reconstruction of the lower urinary tract is considered, the aim is to achieve the characteristics of a functional urinary tract.

In general, vesicoureteral reflux is secondary to bladder dysfunction. In other etiologies, such as Prune belly syndrome and posterior urethra valves, the reflux can be primary and secondary. In the case of secondary reflux of low degree in patients that will undergo bladder augmentation, it is not necessary to correct the reflux, since after the augmentation, this type of reflux may resolve without the need for reimplantation. If the reservoir has adequate low pressure volume, reimplantation is not necessary. However, some surgeons prefer correction of the reflux, since they state that bacteriuria can unfold episodes of pyelonephritis.

Furthermore, when thinking of reimplanting dilated ureters, it should be taken into account that sometimes they have fibrous walls, and tunnelization and aggressive remodeling can lead to ureterovesical obstruction. For patients suffering from ESRD with vesicoureteral reflux and ureterohydronephrosis, pre-transplant nephroureterectomy can be beneficial. If ureteral dilation comes first and the patient requires bladder augmentation, ureteral segments can be used for the reconstruction.

The urothelium is exempt from complications that are inherent to intestinal segments (Nahas et al, 2004, Hitchcock, 1994). In this case, an extraperitoneal approach is taken: lumbotomy incision for the nephrectomy of the dysplastic kidney and mobilization of the dilated ureter and suprapubic incision for bladder augmentation. This approach is beneficial in that it avoids the risks of peritoneal adhesions, and it should be considered in the case of ventriculoperitoneal diversions and of patients who are still under ambulatory peritoneal dialysis (Bellinger, 1993; Dewan et al., 1994; Reinber et al., 1995; Wolf & Turzan, 1993).

Ureterocystoplasty that is laparoscopically assisted has been used since a few years ago. No serious complications have been reported with the use of this procedure, although the need for reaugmentation has been informed to a high degree in the case of native bladders with severely reduced compliance. It is thought that the best candidates to receive ureterocystoplasty have moderately reduced compliance ($> 20 \text{ ml/cmH}_2\text{O}$) and available ureter of a diameter greater than 15 mm to be used in the reconstruction (Husmann et al., 2004)

When it is not possible to obtain urothelial tissue for bladder augmentation, segments from the digestive tube are used: from the stomach, now hardly ever used, to bowel segments. The native bladder is preserved and, for a better anastomosis to the bowel segment, a sagittal incision is performed in order to divide it in two valves. The intestinal segment is open along its antimesenteric border in order to detubularize it and reconfigure it into

spherical shape thus achieving maximum volume per given surface area, blunting of intestinal contraction, and improving overall compliance and distensibility.

In many health care centers, ileal segments are chosen to perform colocolostomy (Nahas et al., 2007), whereas at Hospital de Pediatría Prof. Dr. J. P. Garrahan and since several years ago, sigmoid colon segments without specific bowel preparation have been the segments of choice. No significant infection complications have been observed postoperatively. We have adopted the colon because of its proximity to the native bladder; it has a low rate of metabolic complications and no technical complications.

It is necessary to train the patient and their family in the postoperative care of the colocolostomy. This consists of clean intermittent catheterization, daily vesical washes and periodical visits to the urologist, because there is a certain risk of complications, such as symptomatic urinary infections, lithiasis, perforations and tumoral neoformations.

Once a bladder or reservoir with adequate volume and low pressure is obtained, it is essential to resolve the urinary incontinence. One of the greatest technical challenges that the urologist surgeon faces in the reconstruction of the vesical neck is to be able to provide adequate outlet resistance. Especially in the case of the neurogenic bladder due to spinal dysraphism, bladder outlet is generally incompetent. There are many surgical options that include adjustments of the neck and proximal urethra thanks to the aponeurosis slings, creation of valve mechanisms, endoscopic injection of artificial volume-formation agents and artificial urinary sphincter.

Several techniques that increase outlet resistance may also deteriorate the detrusor status, reducing its compliance or generating instability. These events will occur depending on the baseline pathology. Therefore, previous urodynamic evaluations carried out and a strict follow-up post-reconstruction and post-transplantation are the golden rule. The final option will undoubtedly be customized according to the baseline disease, the goals of the patients and technical limitations of medical nature.

It is reasonable to say that clean intermittent catheterization may have been the most significant contribution in terms of reconstruction of lower urinary tract functions. The potential need or absence of need for CIC in every reconstruction should always be considered, and both patients and family must be updated as to the objectives of reconstruction as well as the importance of adapting themselves to long term CIC regimens in a strict way. In most cases, the CIC procedure will be needed and patients must learn about it and accept CIC before reconstruction.

When the urethra is inaccessible, sensitive or carries irreparable obstructions, a tubular system with continence mechanism is built with the purpose of facilitating the access to the bladder or the reservoir. The Mitrofanoff principle (1980) solved this dilemma, thanks to the creation of a conduit, being the cecal appendix the most commonly used, reimplanted in the submucosal bladder tunnel at one extreme and converted into a catheterizable stoma at the other extreme, in the abdominal wall. When the bladder is full, optimal coaptation is achieved avoiding urine leakage. If it is not possible to use the cecal appendix, other tubular structures can be used, for instance the ureter, the Fallopian tubes or the reconfigured small intestine (Monti). It should be taken into account that complications that are not so infrequent, such as conduit stenosis, mucous prolapse and false passages, may occur.

5.3 Defunctionalized urinary tract: dry bladder

Anuric children who are awaiting for a kidney transplantation deserve special attention. Patients without a relevant history of urologic disorders, in general patients with nephropathies, have a high probability of recovering the normal functional bladder parameters after the renal transplant, since their bladder has simply defunctionalized due to lack of diuresis. Thus, this alteration is reversible.

On the other hand, patients with a history of neurogenic bladder or posterior urethra valves have a few chances of recovering, with the artificial bladder cycling or after the renal transplant, the adequate features of a functional urinary reservoir. In such cases, due to the chronic status of the baseline disease, the bladder walls suffer an important deposit of collagen connective tissue, with the subsequent reduction or lack of bladder compliance to accommodate increasing volumes of urine. Therefore, the urodynamic alterations are irreversible without an appropriate treatment after the renal transplant.

Pre-transplant augmentation cystoplasty in anuric children can represent a problem if it is not appropriately controlled. The cumulus of intestinal mucus is the main enemy to manage. The lack of regular cycles/washes leads to the appearance of urinary infections, mucus plugs, development of lithiasis and risk of intestinal perforations. Three to four daily washouts with distilled water are recommended with the aim of achieving augmentation distension and eliminating the mucus. It is important to emphasize that the washout liquid must not contain mineral salts in order to avoid precipitates with intestinal mucus, which is an important factor involved in the lithogenesis. Finally, the urodynamic evaluation must be repeated prior to renal transplantation.

5.4 Timing of reconstruction of the lower urinary tract

The reconstruction of the lower urinary tract may be performed before, during or after kidney transplantation. Many authors claim that reconstruction must be done before transplantation (Ali-El-Dei et al., 2004; Nahas et al., 2004) on the assumption that the uropathy is directly responsible for ESRD and must be corrected; furthermore, as post-transplant immunosuppression is far away in time from reconstruction, it will not affect the plastic procedures of the surgery (Fontaine et al., 1998).

In general the reconstruction of the lower urinary tract before the renal transplantation is preferred, since in this way the complications related to the reimplanted ureter that could lead to the loss of the graft are reduced (Taghizadeh et al., 2007). It is worth considering that in already augmented bladders the surgery of the renal transplant may become technically more complex because of the special care needed to avoid damaging the vascular pedicle of the cystoplasty during reimplantation, with the consequent risk of cystoplasty necrosis (MacInerny et al., 1995).

The lower urinary tract reconstruction performed simultaneously with renal transplantation has the main disadvantage of interference in the process of tissue remodeling after bladder augmentation, generated by steroid-based immunosuppression, which would increase tissue fragility. This would promote complications, such as perforations and urinary infections. The manipulation of bowel segments a short time prior to kidney implantation would lead to infection complications related to the allograft. Nevertheless, there exist

specific situations in which some patients would benefit from such an approach. That is the case of patients who at the moment of the transplant surgery present important vesicoureteral reflux to the native kidneys and a bladder with low capacity and high pressure. Then it would be advisable to consider nephroureterectomy of the native kidneys and the use of urothelium segments of dilated ureters for ureterocystoplasty immediately before the placement of the graft. In this way, the reconstruction of the lower urinary tract is resolved with adequate tissues, with a low rate of infection complications for the graft.

The reconstruction of the lower urinary tract after the renal transplantation may be performed when the renal function is stable and immunosuppression has been reduced, in order not to interfere with the postoperative remodeling processes. The main advantage of this approach is that the lower urinary tract is reconstructed 'only' when the infection complications appear, which are related to the difficulties in urinary voiding. That is why it has been suggested that continent appendicovesicostomy of the Mitrofanoff type should be performed before renal transplantation, and augmentation cystoplasty, after the renal transplant, if necessary. Several reports describe acceptable outcomes in terms of complications, survival of the graft and the receptor, compared to the patients that have been operated on before renal transplantation (Sheldon et al., 1994; Thomalla, 1990; Nahas et al., 1997).

However, there is evidence that lower urinary tract reconstructions post renal transplant may trigger a high incidence of complications (Barisi et al., 2002), including episodes of pyelonephritis. Another disadvantage of this approach is that the time needed to reduce the immunosuppression doses exposes the graft and urinary tract to risky situations, where the patient requires a quick surgical solution to a transplant that may be deteriorating but it is not possible yet to reduce the immunosuppression drug doses.

Our team adheres to Taghizadeh, who concludes that augmentation cystoplasty 'before' the renal transplant is preferable, because the incidence of complications related to the transplanted ureter and loss of graft is reduced.

6. Renal transplant – Surgical technique – Anesthetic questions

A main part of the preparation of the living donor's kidney is done in situ by the surgical team of the donor. In general, the cadaveric donor's kidney requires major manipulation in order to be able to be implanted, in a procedure called bench surgery, where the dissections of perirenal tissues are performed, technical procedures are applied in order to prepare the blood vessels to be anastomosed and the kidney is irrigated with specific solutions.

By means of Gibson technique or paramedian cut, the incision extends from the costal border to the pubis and into the retroperitoneal space of the iliac fossa. The choice of one side, right or left, over the other is determined by the availability of the left or right kidney, localization of peritoneal dialysis catheter, stomas and available vascular access. Anastomosis between renal artery and vein is performed with primitive ileac artery and vein or hypogastric ones, and sometimes inferior vena cava and aorta, in a terminal-lateral fashion, with continuous polypropylene sutures 7/0. The procedure is performed by a cardiovascular surgeon.

In the case of small patients, weighing less than 15 kilograms, a transperitoneal approach is preferred, using midline incision, from the xyfoid appendix to the pubis, with release and

dissection of aorta and inferior vena cava. Anastomosis is also done in these vessels using continuous polypropylene sutures 7/0 (Madeiros-Domingo et al., 2005).

Prior to declamping of the vessels for blood reperfusion of the graft, it is essential to maintain central venous pressure between 15 to 20 cmh₂o, with the use of hematic, colloidal and crystalloid products. When reperfusion is done, the graft can sequester up to 300 ml of liquid volume; that is why it is important to keep substantial reposition of liquids post-clamping.

If the size of the organ is considerable in relation to the recipient, it may displace the liver and diaphragm upwards, making breathing and venous return difficult due to obstruction of the inferior vena cava (Madeiros-Domingo et al., 2005).

On the contrary, when the kidneys to be transplanted are small or shorter than 6 cm, they can be implanted in unit fashion, with anastomosis of the distal extreme to the aorta and inferior vena cava of the recipient vessels in a terminal-lateral way, as a segment interposed with proximal and distal anastomosis (Madeiros-Domingo et al., 2005).

Uretero-neo-cystostomy (ureterovesical reimplantation) is performed using extravesical Lich-Gregoire antireflux ureteroneocystostomy method (Lich Jr. et al., 1961). Some groups use intravesical reimplants, according to Politano-Leadbetter technique (Politano, 1958), and it is performed by a urologic surgeon. The former is preferred, since it is fast, does not require extra cystostomy or big ureteral length.

In most cases in our series, and when it was possible, the ureter was reimplanted into the native bladder. When the ureteric reimplantation was difficult or the ureter caliber small, a double J (pig tail) catheter was used and it is removed 6 weeks following transplantation. For the rest of the patients, a K33-like catheter was used up to the renal pelvis of the graft, with an exit site other than the incision site and it was removed 5-7 days after the surgical procedure. The systematic use of a ureteral tutor for all recipients has reduced the incidence of ureteral complications (Pleass et al. 1995).

In the case of patients with bladder augmentation, the ureteroneocystostomy technique is the same, although special attention should be taken not to interfere in the continent diversion site (Mitrofanoff) in order to avoid urine leakage.

In all recipients, in order to guarantee a complete drainage of the bladder, vesical drainage through the urethra or by way of continent appendicovesicostomy (Mitrofanoff procedure) was established for 7 days, and drainage of the perirenal space was performed.

7. Modifications of the lower urinary tract after the renal transplantation

After re-evaluation during follow-up, there are cases in which for different reasons, such as course of the baseline pathology, alterations in the bladder behavior due to reconstructive procedures, inadequate management and care after reconstruction, among others, there appears a need for another reconstruction of the urinary tract in order to keep the features of a "functional urinary tract." Thus, on some occasions bladder re-augmentations, continent appendicovesicostomies of the Mitrofanoff type or procedures in the neck and/or proximal urethra must be performed so as to treat urinary incontinence. There is approximately 3% of cases described in the literature that needed procedures in the lower urinary tract after renal transplantation, although they had undergone evaluation and surgeries previously to the

transplantation (Sager et al., 2011). This evidences that although we may think that everything that was done was enough, in surgical terms, the nephro-urologic follow-up show us that evaluation and follow-up are fundamental and many times it is necessary to do adjustments in order to protect the allograft.

8. Graft survival

Extensive bibliography shows that renal transplantation can be indicated safely in the case of patients with lower urinary tract reconstructions, achieving acceptable survival and function of the graft. The results are comparable to the ones obtained for patients with normal urinary tract (Franc-Guimond & Gonzalez, 2004; Capizzi et al., 2004).

At Hospital Nacional de Pediatría Prof. Dr. J. P. Garrahan, 156 renal transplants have been performed up to date on children with uropathies, 38 of which received reconstructions of the dysfunctional urinary tract. No significant differences have been found between the latter and those patients that had no lower urinary tract reconstructions regarding survival of the graft or levels of creatininemia at year 1 and 5 after transplantation (Sager et al., 2011). In general terms, the actuarial global functional survival rate after the first year postoperatively was higher than 93%, and at year 5 it was between 75% and 85% (Figure 1)

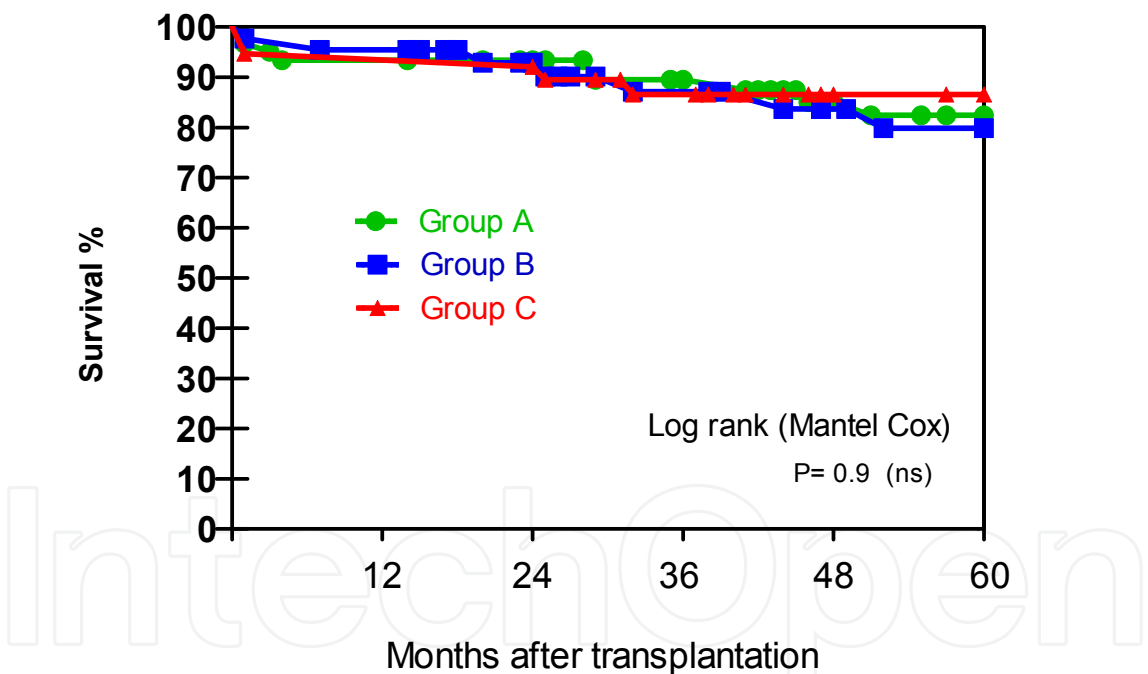


Fig. 1. Actuarial allograft survival in patients with uropathies. Group A: Patients without surgeries in lower urinary tract; Group B: Patients who underwent surgeries in lower urinary tract and preserved adequate bladder function; Group C: Patients who underwent surgeries in lower urinary tract due to inadequate bladder function.

Other authors have shown that patients with dysfunction in the urinary tract that required reconstructions had an increased risk of complications and loss of the graft (Mochon et al., 1992; Salomón et al., 1997). Such discrepancies can be explained because of the heterogeneity of the series published, the wide scope of the disease, the severity of the lower urinary tract and its different treatments (Riley et al., 2010)

9. Complications

9.1 Vascular complications

Vascular thrombosis is the third cause of loss of the graft in children according to the NAPRTCS (North American Pediatric Renal Transplant Cooperative Study), with an incidence of 11.6% (Benfield, 2003). When the receptor is very young and has a low weight, the risk increases because of the reduced diameter in the vascular structures.

Vascular thrombosis, especially venous thrombosis, may occur immediately and up to 90 days post-transplantation. It is a devastating complication, since besides the graft loss, it may unleash rupture of the graft capsule, major hematomas, massive hemorrhage, thromboembolic events and sepsis.

Arterial thrombosis is the most feared, since it invariably conditions the loss of the graft and subsequent nephrectomy. In children its incidence is 6% (Singh et al., 1997).

The causes of vascular thrombosis are intimal dissection, atherosclerosis, immunological factors and hypercoagulable state. Furthermore, high doses of cyclosporine or antilymphocyte globulin, systemic lupus erythematosus, antiphospholipid syndrome, and deficiency of protein C and S are involved.

Arterial stenosis, with an estimated frequency of occurrence between 2% and 10% can appear during the post-transplant period or many years later, and it is localized at the site of anastomosis or distal to it. Immunological and mechanical factors generate a hyperplastic response of the intima. Arterial stenosis manifests as out of control arterial hypertension and deterioration of the function of the graft. This entity forces physicians to perform procedures such as transluminal percutaneous angioplasty with or without endovascular prosthesis or vascular bypass.

Other vascular complications that are less frequent but not less severe are arteriovenous fistulas and perigraft hematomas or ureterovesical joint hematomas on the reimplantation site; the latter are also resolved surgically.

9.2 Urologic complications

Forced immunosuppression and complexity of the reconstructed urinary tract facilitate the appearance of different complications. By far, the most frequent bacteria infection in patients with a renal transplantation is the urinary tract infection (UTI) (Abbott et al., 2001; Karakayali et al., 2001). The incidence of UTI varies significantly across the literature: from 6% to 86% after renal transplantation. This variation responds to the different criteria in defining what UTI involves, the methods of urine collection and type of antibiotic prophylaxis, among others.

The possible impact of UTI increases mortality and morbidity rates due to infection itself, and the potential effects on the processes of acute and chronic rejection. UTI episodes occur especially in the first postoperative stage, when the patient is hospitalized. A great percentage of UTI occurs between 6-12 months after the implant.

Numerous risk factors for UTI are involved in renal transplantation; among the most important are the patients with a reconstructed lower urinary tract. The major causes are: anatomical conditions, characteristics of the intestinal mucus, vesicoureteral reflux and immunosuppression. Most of these patients who are under a clean intermittent

catheterization program present with asymptomatic chronic bacteriuria. Reports have shown that this event has no effect on the survival of the graft (Warhom et al., 1999; Hatch et al., 2001). However, some authors believe that when pyelonephritis and recurrent episodes of asymptomatic UTI appear, the function of the graft is at risk, with the subsequent possibility of extirpation (Mendizabal et al., 2005; Alfrey et al., 1997). Other authors claim that recipients of the renal transplant with repeated UTI episodes show deterioration of the graft function, although its survival does not differ from the survival rate of the general population (Sullivan et al., 2003; Surange et al., 2003).

In some reports, instituting an aggressive treatment for UTI at an early stage post-transplant is recommended, since UTI may trigger acute rejection (Sullivan et al., 2003); other reports, however, suggest that intensive treatment in the case of asymptomatic UTI may favor the development of resistant bacteria strains. In our center, the approach followed consists of using as antibiotic prophylaxis trimetropin/sulfamethoxazol even in the presence of positive urocultures in asymptomatic patients, without alteration of the function of the graft. Intensive antibiotic therapy is reserved for those patients with symptomatic UTI, worsening of the renal function or the presence of aggressive germs such as *pseudomonas aeruginosa* or those related with lithogenesis, like *proteus mirabilis*.

In our case report we showed that 25% of patients with renal transplantation and reconstructed urinary tract presented low UTI; 42.5% presented high UTI, and two patients developed sepsis of urologic cause; one of them with graft loss. Due to the detection of more episodes of UTI in this subgroup, vesicoureteral reflux was more frequently diagnosed (25%) compared to the subgroup of patients with uropathies without reconstructions, where reflux was observed in only 1% of the group (Sager et al., 2011).

Vesicoureteral reflux to the graft, especially of high grade, which is associated to symptomatic UTI, is generally treated first with endoscopic approach. Different materials are used as endoscopic bulking agents in ureterovesical junction: the most common one is dextranomer/hyaluronic acid. Many times the endoscopic technique becomes difficult because the bladder has undergone previous surgery or augmentation, and the opening of the urethral meatus may not always be located. In cases of neurogenic bladders with vesicoureteral reflux to the graft and failure of the bulking agents, as the urinary tract has already been reconstructed, open ureterovesical reimplantation is very frequently done.

If intermediate or low grade vesicoureteral reflux to the graft is detected under ureterohydronephrosis study and there are no UTI leaks nearby and the renal function is preserved, a vigilant attitude under antibiotic prophylaxis is taken before resorting to surgical techniques to resolve the reflux, provided the urodynamic studies do not show significant alterations.

Ureterovesical stenosis may have an incidence between 2% and 4%. Different procedures can be required in order to reestablish the adequate urinary flow, such as pig tail catheters via percutaneous nephrostomy and posterior ureterovesical reimplant. Ureteral fistulas are produced by ischemic necrosis of the distal ureter, as a consequence of vascular lesion during donor nephrectomy. Hematoma of the ureterovesical juncture, urinary fistulas and necrosis of the distal ureter (2 to 4%) are directly associated as causative agents of ureterovesical stenosis and require in all cases open exploration (Sager et al., 2011).

Perirenal collections are another frequent surgical complication with an incidence of approximately 49% (Pollak, et al., 1988). Lymphoceles cause several collections and are

generated by the cumulus of lymphatic liquid in the retroperitoneum, due to the dissection and binding of lymphatic vessels at the moment of forming the vascular pouch. Their occurrence has been associated to the use of Sirolimus (Giessing & Budde, 2003). Some lymphoceles may grow until displacing or comprising the reimplanted ureter, generating ureterohydronephrosis extrinsic to the implant. If the lymphocele grows progressively or is persistent, it may be treated by means of external percutaneous drainage or with laparoscopic exploration and marsupialization.

Transplants <i>n</i>	Group A 68	Group B 48	Group C 40
Complications <i>n</i> (%)			
Vascular:			
Arterial Stenosis	4(6)	2(4.2)	-
Arterial Thrombosis	2(3)	2(4.2)	-
Venous Thrombosis	1(1.5)	2(4.2)	1(2.5)
Arteriovenous Fistula	1(1.5)	-	-
Hematoma	1(1.5)	-	1(2.5)
Urologic:			
Ureterovesical Junction Hematoma	-	1(2)	-
Ureterovesical Stenosis	2(2.9)	2(4.2)	1(2.5)
Vesicoureteral Reflux (>grade II)	1(1.5)	1(2.1)	10(25)
Urinary Fistula - Ureteral Necrosis	2(2,9)	2(4.2)	1(2.5)
Renal Pelvis Necrosis	-	-	1(2.5)
Lymphocele	5(7.5)	2(4.2)	-
Vesical Lithiasis	-	-	2(5)
Retained drainage in surgical site	1(1.5)	-	-
Urinary Infections:			
-Lower:	6(9)	3(6.2)	10(25)
-Upper:	8(12)	11(23.1)	17(42.5)
Sepsis of urologic origin	-	-	2(5)
Urinous Peritonitis	-	-	1(2.5)
Infection of surgical wound	1(1.5)	2(4.2)	6(15)
Abdominal wall abscess	-	-	2(5)
Urine Incontinence	-	-	1(2.5)
Total <i>n</i> (%)	35(51.5)	30(63)	53(132)

References: Group A: Patients without lower urinary tract; Group B: Patients that required surgery in lower urinary tract and preserved adequate bladder function; Group C: Patients that needed surgery in lower urinary tract due to inadequate function.

Table 1. Vascular and Urologic Post Renal Transplant Complications in Patients with Uropathies.

Other causes of perirenal collections include: hematomas, urinomas and sera cumuli, all of which are not resolved unless surgical intervention is performed.

Other urologic complications in decreasing order of presentation are: surgical wound infections, wall abscess, vesical lithiasis and urinous peritonitis due to colocystoplasty perforation.

Recently, colocystoplasty neoformations -infrequent but of poor prognosis- have been reported as appearing several years after bladder reconstruction-augmentation. The exact etiopathogenic mechanism for these neoformations is unknown, but the possible explanations include: increased nitrosamines at the vesicointestinal anastomosis site; influence of disguised and chronic urinary infections, among others. At a histological level, the neoformations may be adenocarcynomas, urothelial tumors located in the native bladder, in the bowel segment or at the vesicointestinal anastomosis site, and in general they exert a very aggressive effect (Bono Ariño, et al., 2001). This poses a serious ethical-medical dilemma, since so far the established modality widely embraced has been the re-functionalization of the lower urinary tract by means of intestinal segments in patients that will surely be put under immunosuppression regimens. Up to date, the only weapon to protect this complex subgroup of patients is a strict clinical, ultrasound and endoscopic follow-up, especially when hematuria is present.

In our case report we describe the following complications and interventions post renal transplant (Tables 1 and 2).

10. Vascular and urologic post renal transplant interventions

Transplants <i>n</i>	Group A 68	Group B 48	Group C 40
<i>Vascular Interventions</i>			
Angioplasty	2	-	-
Bypass	1	2	-
Fistula embolization	1	-	-
<i>Urologic Interventions</i>			
Sigmoid vesical augmentation	1	-	2
Mitrofanoff	1	1	1
Mitrofanoff reoperation	-	1	2
Aponeurotic sling	-	-	1
Closure of bladder neck	-	-	1
<i>Ureterovesical reimplant due to:</i>			
- vesicoureteral reflux	1	-	-
-Stenosis	2	1	1
-Fistula	2	2	1

Transplants <i>n</i>	Group A	Group B	Group C
Nephroureterectomy of native kidney	3	-	2
Drainage-punction of lymphocele	4	1	-
Drainage-punction of abscess-hematoma	2	-	2
Nephrostomy	3	1	3
Cystoscopy	2	-	-
Placement of pig tail catheter	2	1	3
Injection of substances due to vesicoureteral reflux	-	-	1
Injection of substances due to urine incontinence	-	-	1
Nephrectomy of the graft	5	2	4
Partial Ureterectomy	-	2	
Ureterostomy	-	-	2
Endoscopic Cystolitotomy	-	-	1
Open Cystolitotomy	-	-	1

References: Group A: Patients without lower urinary tract; Group B: Patients that required surgery in lower urinary tract and preserved adequate bladder function; Group C: Patients that needed surgery in lower urinary tract due to inadequate function.

Table 2. Vascular and Urologic Post Renal Transplant Interventions.

11. Graft loss

There are different causes of graft dysfunction, such as renal rejection and nephrotoxicity due to cyclosporine, tacrolimus and vascular problems. The vascular thromboses that are more associated to graft loss are venous thromboses. Urologic causes have infrequent relation to the renal graft loss, but recurrent urinary infections, such as pyelonephritis generate lymphocyte and intratubular neutrophilus deposits. As a consequence, but not exclusively due to pyelonephritis, the normal functional renal tissue is replaced by interstitial fibrosis and tubular atrophy (IF/TA).

Even though the patients who have received a kidney transplantation and have corrected or reconstructed urinary tracts are subjected to an important incidence of urologic complications, the main cause for graft loss in our series was the presence of vascular events (Sager, et al., 2011).

12. Survival and quality of life

Survival rates at years 1 and 5 post-transplantation are 98.8% and 94.2%, respectively. In our series, 8 out of 150 patients died due to cardiovascular causes, lymphoproliferative disease and non urologic sepsis (Sager et al., 2011).

In other studies, 100% of transplanted patients with over 10 years of follow-up reported that they feel they have good or excellent health status; 94% stated that their health status does

not interfere with their family and social life; 90% of them study or work; 70% have an active sexual life, and absence from their work or study places was in general minimal (Ferraris & Rodriguez, 2008).

The success of this type of therapy also depends on "the patients's adherence to treatment." Lack of adherence is the most important risk factor for the development of chronic allograft nephropathy (CAN) and sub-clinical rejection. The critical period is when the adolescent goes from dialysis to the post-transplant phase, when the responsibilities as to being alert, managing care and decision-making increase.

13. Follow-up

Strict follow-up is essential in order to carry out a continuous assessment of the following aspects: function of the graft and drainage to the lower tract; function of the lower urinary tract; record of the urinary volume and frequency voided by means of voiding records; need for contrasting studies, such as cystourethrography and urodynamic studies.

It is necessary to monitor compliance with medication therapy, for instance, anticholinergic drugs; compliance with daily bladder washes in the case of those who have undergone bladder augmentation, and the correct use of catheters for those who need catheterization via Mitrofanoff or urethra.

It is likewise important to bear in mind that many patients and parents gradually lose interest in the urologic follow-up after the renal transplant. Thus, physicians should emphasize how essential monitoring is since the first consultation, so that parents, patients and medical caregivers become committed to a thorough and long-term follow-up program.

14. Conclusions

Along the time, it has been demonstrated that the renal transplant is the best option for children with end stage renal disease. At present these children can benefit from this type of therapy provided the functions of the dysfunctional lower urinary tract are corrected, either by means of medical and/or surgical treatment. Otherwise, the bladder dysfunction that is not corrected will negatively affect the function of the graft.

Among the most frequent etiologies for ESRD we can find renal dysplasia, obstructive uropathies, focal and segment glomerulosclerosis, nephropathy due to vesicoureteral reflux, renal polycystosis, hemolytic uremic syndrome, Prune belly, neurogenic bladder due to neural tube defects, and other conditions. All of them must be exhaustively evaluated so that it can be determined whether the lower urinary tract is in optimal condition to receive a renal implant, following the principle of "functional urinary tract." This term refers to the condition that a lower urinary tract should be a reservoir with adequate volume, low intravesical pressure and continence, and correct and complete urine voiding.

For those cases that do not meet these criteria, different treatments are offered in order to provide a safe mechanism of drainage when voiding difficulties are present, via clean intermittent catheterization and pharmacologic reduction of filling pressure or contractions that are not inhibited, with the use of anticholinergic drugs.

When the objectives cannot be reached in spite of applying medical treatments, the option is surgical intervention for reconstruction of the urinary tract. Here the possibility of using urothelial tissues should be considered, since these patients usually have high grades of vesicoureteral reflux or obstructive ureterohydronephrosis. When it is not possible to obtain urothelial tissue to perform bladder augmentation, segments of the digestive tube can be used, either from the small or the large bowel, according to the criterion of each health care center.

Favorable long term outcomes have been reported on patients who underwent renal transplantations with reconstruction of the urinary tract; however, there is considerable controversy around which is the best way to manage these patients, since there are no guidelines with defined criteria for reconstructive surgeries, optimal surgical procedures, or even recommendations as to when is the best time to do them.

Our team adheres to Taghizadeh, whose report claims that augmentation cystoplasty before renal transplant is preferable, as the incidence of complications and graft loss is reduced, especially in relation to lesions of the transplanted ureter.

It has also been agreed that renal transplantation can be indicated in a safe way to patients with lower urinary tract reconstructions, with acceptable survival and function of the graft. Results are comparable to those obtained in the case of patients with normal urinary tract. Nevertheless, it is undeniable that forced immunosuppression and the complexity of the reconstructed urinary tract favor the appearance of complications, especially infections related to the urinary tract. Potentially, this would promote the increase of morbidity and mortality rates and it would attempt against the implant. However, urologic causes have an infrequent relationship with the loss of the renal graft.

In the case of these complex and heterogeneous patients, it is essential to provide a careful and individualized evaluation of the lower urinary tract prior to transplantation and a strict postoperative follow-up in order to diminish and control possible urological complications. Since at present there are no sound guidelines or protocols for the management of pediatric patients with dysfunctional lower urinary tract and end stage renal disease, it is necessary to design randomized multicenter studies in order to achieve better results on morbidity.

15. Acknowledgments

The authors thank all the members of the Nephrology Department at Hospital de Pediatría Dr. Juan P. Garrahan for their collaboration.

16. References

- Abbott KC, Oliver JD III, Hypolite I, et al. (2001). Hospitalization for bacterial sepsis after renal transplantation in the United State. *Am J Nephrol*; 21:120-127.
- Alfrey EJ, Salvatierra O Jr, Tanney DC et al. (1997). Bladder augmentation can be problematic with renal failure and transplantation. *Pediatric Nephrol*; 11:672-5.
- Ali-El-Dei B, Abdol-Eneim H, El-Husseini A, et al. (2004). Renal transplantation in children with abnormal lower urinary tract. *Transplant Proc*; 36:2968.

- Austin PF, Homsy YL, Masel JL, et al. (1999). Alfa-adrenergic blockade in children with neuropathic and nonneuropathic voiding dysfunction. *J Urol*; 162:1064-1067.
- Barisi A, Hosseini Moghaddam S, Khoddam R. (2002). Augmentation cystoplasty before and after renal transplantation: Long-term results. *Transplant Proc*; 34:2106.
- Barry J. (2004). Kidney transplantation into patients with anormal bladders. *Transplantation*; 77:1120-23.
- Bellinger MF. (1993). Ureterocystoplasty: a unique method for vesical augmentation in children. *J Urol*; 149:811-13.
- Benfield MR. (2003). Current status of kidney transplant: update 2003. *Pediatr Clin North Am*; 50: 1301-34.
- Bibiloni N., Bertolotti J., Ferrari C. M. (2008). Diagnóstico por imágenes del riñón y del tracto urinario, In: *Nefrología Pediátrica*, Ferraris JR, Briones LM. 75-89. Fundación Sociedad Argentina de Pediatría-FUNDASAP, ISBN 978-987-1279-16-6, Buenos Aires, Argentina.
- Bono Ariño A, Sanz Vélez JL, Esclarin Duny MA, et al. (2001). Adenocarcinoma de células en anillo de sello en colocistoplastia. *Actas Urol Esp*; 25 (4): 312-314.
- Broyer M, LeBihan C, Charbit M; Guest G, et al. (2004). Long-term social outcome of children after kidney transplantation. *Transplantation*; 77: 1033-1037.
- Burek C & Sager C (2008). Vejiga neurogénica, In: *Nefrología Pediátrica*, Ferraris JR, Briones LM. 480-493. Fundación Sociedad Argentina de Pediatría-FUNDASAP, ISBN 978-987-1279-16-6, Buenos Aires, Argentina.
- Capizzi A. Et al. (2004). Kidney transplantation in children with reconstructed bladder. *Transplantation*; 77:1113-16.
- Cerruto MA & Artibani W (2006). Urodynamics, In: Pediatric neurogenic bladder dysfunction. Diagnosis, treatment, long-Term Follow-up. Esposito C, Guys JM, Gough D, Savanelli A. 133-146, Springer, ISBN-10 3-540-30866-0, Berlin, German.
- De Jong TP, Chrzan R, Klijn AJ, Dik P. (2008). Treatment of the neurogenic bladder in spina bifida. *Pediatr Nephrol*; 23:889-96.
- Dewan PA, Nicholls EA, Goh DW. (1994). Ureterocystoplasty: an extraperitoneal, urothelial bladder augmentation technique. *Eur Urol*; 26:85-89.
- Ferraris JR & Rodriguez L (2008). Transplante renal In: *Nefrología Pediátrica*, Ferraris JR, Briones LM. 682-699. Fundación Sociedad Argentina de Pediatría-FUNDASAP, ISBN 978-987-1279-16-6, Buenos Aires, Argentina.
- Fine RN, Malekkadek MH et al. (1978). Long term results of renal transplantation in children. *Pediatrics*, 61: 641.
- Fontaine E, Gagnadoux MF, Niaudet P, et al. (1998). Renal transplantation in children with augmentation cystoplasty: long-term results. *J Urol*; 159:2110.
- Franc-Guimond J, Gonzalez R. (2004). Renal transplantation in children with reconstructed bladders. *Transplantation*; 77:1116-20.
- Galvez MP, Cusi MP, Corral Molina JM. (2005). Generalidades del trasplante renal pediátrico. *Arch Esp Urol*; 58, 6: 553-562.
- Giessing M, Budde K. (2003). Sirolimus and lymphocele formation after kidney transplantation: an immunosuppressive medication as co-factor for a surgical problem? *Nephrol Dial Transplant*; 18: 448-9.


- Gradus D, Ettenger RB. (1982). Renal Transplantation in children. *Pediatr Clin North Am*, 29: 1013.
- Hatch DA, Koyle MA, Baskin LS et al. (2001). Kidney transplantation in children with urinary diversion or bladder augmentation. *J Urol*; 165:2265-8.
- Hatch DA. (1994). Kidney transplantation in patients with an abnormal lower urinary tract. *Urol clin North Am*; 21:311.
- Hitchcock RJ, Duffy PG and Malone PS. (1994). Ureterocystoplasty: The bladder augmentation of choice. *Br J Urol*; 73:575.
- Husmann DA, Snodgrass WT, Koyle MA et al. (2004). Ureterocystoplasty: indications for a successful augmentation. *J Urol*; 171:376-380.
- Karakayali H, Emiroglu R, Arslan G, et al. (2001). Mayor infectious complications after kidney transplantation. *Transplant Proc*; 33:1816-17.
- Kelly WD, Merkel FK, Markland C. (1966). Ileal urinary diversion in conjunction with renal homotransplantations. *Lancet*; 1:22.
- Lich R Jr., Howerton LW, Davis LA. (1961). Vesicourethrography. *J Urol*; 85: 396-7.
- López JC & Durán V (2008). Obstrucción de la vía urinaria Baja, In: *Nefrología Pediátrica*, Ferraris JR, Briones LM. 432-437. Fundación Sociedad Argentina de Pediatría-FUNDASAP, ISBN 978-987-1279-16-6, Buenos Aires, Argentina.
- Luke P, Herz D, Bellinger M, et al. (2003). Long term results of pediatric renal transplantation into a disfunctional lower urinary tract. *Transplantation*; 76:1578-82.
- Mac Inerny PD, Picramenos D, Koffman CG, et al. (1995). Is cystoplasty a safe alternative to urinary diversion in patients requiring renal transplantation? *Eur Urol*; 27:117.
- Madeiros-Domingo M, Romero-Navarro B, Valverde-Rosas S, et al. (2005). Trasplante renal en pediatria. *Rev Inv Clin*; 57,2:230-36.
- Martz k. (2007). NAPRTCS 2007 Annual Report, In: North American Pediatric Renal Trials and Collaborative Studies, 2007, available from: www.emmes.com/study/ped/annlrept/annlrept2007.pdf
- Mendizabal S, Estornell F, Zamora I, et al. (2005). Renal transplantation in children with severe bladder dysfunction. *J Urol*; 173:226-9.
- Mitchell ME, Piser JA. (1987). Intestinocystoplasty and total bladder replacement in children and young adult: follow up in 129 cases. *J Urol*; 138: 579.
- Mochon M, Kaiser BA, Dunn S, et al. (1992). Urinary tract infections in children with posterior urethral valves after kidney transplantation. *J Urol*; 148:1874.
- Murray JE, Merrill JP, Harrison JH. (1958). Kidney transplantation between seven pairs of identical twins. *Ann Surg*; 48: 343.
- Nahas C. et al. (2007). Comparision of transplantation outcomes in children with and without bladder dysfunction. A customized approach equals the diference. *J Urol*; 179:712.
- Nahas WC, Lucon M, Mazzucchi E, et al. (2004). Clinical and urodynamic evaluation after ureterocystoplasty and kidney transplantation. *J Urol*; 171:1428.
- Nahas WC, Lucon M, Mazzucchi E, et al. (2004). Clinical and urodynamic evaluation after ureterocystoplasty and kidney transplantation. *J urol*; 171:1428.

- Nahas WC, Mazzucchi E, Antonopoulos I, et al. (1997). Kidney transplantation in patients with bladder augmentation: Surgical outcome and urodynamic follow-up. *Transplant proc*; 29:157.
- Podestá M & Bertolotti G (2008). Uropatías obstructivas del tracto urinario superior: diagnóstico y tratamiento, In: *Nefrología Pediátrica*, Ferraris JR, Briones LM. 424-31. Fundación Sociedad Argentina de Pediatría-FUNDASAP, ISBN 978-987-1279-16-6, Buenos Aires, Argentina.
- Politano VA, Leadbetter WF. (1958). An operative technique for the correction of vesicoureteral reflux. *J Urol*; 79: 932-41.
- Pollak R, Veremis SA, Maddux MS, et al. (1988). The natural history of and therapy for perirenal fluid collections following renal transplantation. *J Urol*; 140: 716-20.
- Reinber Y, Allen RC, Vaughn M et al. (1995). Nephrectomy combined with lower abdominal extraperitoneal ureteral bladder augmentation in the treatment of children with vesicoureteral reflux dysplasia syndrome. *J Urol*; 153:777-779.
- Riley P, Marks S, Desai D, et al. (2010). Challenges facing renal transplantation in pediatric patients with lower urinary tract dysfunction. *Transplantation*; 89:1299-1307.
- Sager C, Burek C, Duran V, et al. (2011). Outcome of renal transplant in patients with abnormal urinary tract. *Pediatr Surg Int*; 27:423-430.
- Salomón L, Fontaine E, Gagnadoux MF, et al. (1997). Posterior urethral valves: Long-term renal function consequences after transplantation. *J Urol*; 157:992.
- Salomon L, Fontaine E, Guest G, et al. (2000). Role of the bladder in delayed failure of kidney transplants in boys with posterior urethral valves. *J Urol*; 163: 1282.
- Shekarris B, Upadhyay J, Demirbilek S, et al. (2000). Surgical complications of bladder augmentation: comparison between enterocystoplasties in 133 patients. *Urology*; 55:123.
- Sheldon C A, Gonzalez R, Burn MW, et al. (1994). Renal transplantation into the dysfunctional bladder. The role of adjunctive bladder reconstruction. *J Urol*; 152: 972.
- Singh A, Stablein D, Tejani A. (1997). Risk factors for vascular thrombosis in pediatric renal transplantation: a special report of the North American Pediatric Renal Transplant Cooperative Study. *Transplantation*; 63: 1263-7.
- Sullivan ME, Reynard JM, Cranston DW. (2003). Renal transplantation into the abnormal lower urinary tract. *BJU int*; 92:510-15.
- Surange RS, Johnson RW, Tabakoli A, et al. (2003). Kidney transplantation into an ileal conduit: a single center experience of 59 cases. *J Urol*; 170:1727-30.
- Taghizadeh AK, Desai D, Ledermann SE, et al. (2007). Renal transplantation or bladder augmentation first? A comparison of complications and outcomes in children. *BJU Int*; 100:1365.
- Thomalla JV. (1990). Augmentation of the bladder in preparation for renal transplantation. *Surg Gynecol Obstet*; 170:349.
- Torre M, Guida E, Bisio G, et al. (2011). Risk factors for renal function impairment in a series of 502 patients born with spinal dysraphisms. *J Pediatr Urol*; 7:39-43.
- Warhom C, Berglund J, Andersson J, Tyden G. (1999). Renal transplantation in patients with urinary diversion: a case-control study. *Nephrol Dial transplant*; 14:2937-40.
- Wolf JS, Turzan CW. (1993). Augmentation ureterocystoplasty. *J Urol*; 149:1095-98.

Woodward J.R. & Smith E.A. (1998). Prune-Belly Syndrome, In: *Campbell's Urology*, Walsh PC, Retik AB, Vaughan ED, Jr, Wein AJ. 7 edition, Vol 2: 1917-36, WB Saunders, ISBN 0-7216-44-63-5, United States of America.

IntechOpen

IntechOpen



Renal Transplantation - Updates and Advances

Edited by Dr. Layron Long

ISBN 978-953-51-0173-4

Hard cover, 234 pages

Publisher InTech

Published online 29, February, 2012

Published in print edition February, 2012

This book presents a nice international compilation of scholarly papers and chapters which address the latest advances in renal transplant surgery. These works cover a variety of topics; the last advance and success of renal transplant science: biochemistry, immunology, molecular genetics, pharmacology - pharmacogenetics, pediatric transplant and a few rare uropathies that warrant organ replacement.

How to reference

In order to correctly reference this scholarly work, feel free to copy and paste the following:

Cristian Sager, Juan Carlos López, Víctor Durán, Carol Burek, Juan Pablo Corbetta and Santiago Weller (2012). Pediatric Kidney Transplant in Uropaties, Renal Transplantation - Updates and Advances, Dr. Layron Long (Ed.), ISBN: 978-953-51-0173-4, InTech, Available from: <http://www.intechopen.com/books/renal-transplantation-updates-and-advances/-pediatric-transplant-renal-in-uropaties->

INTECH
open science | open minds

InTech Europe

University Campus STeP Ri
Slavka Krautzeka 83/A
51000 Rijeka, Croatia
Phone: +385 (51) 770 447
Fax: +385 (51) 686 166
www.intechopen.com

InTech China

Unit 405, Office Block, Hotel Equatorial Shanghai
No.65, Yan An Road (West), Shanghai, 200040, China
中国上海市延安西路65号上海国际贵都大饭店办公楼405单元
Phone: +86-21-62489820
Fax: +86-21-62489821

© 2012 The Author(s). Licensee IntechOpen. This is an open access article distributed under the terms of the [Creative Commons Attribution 3.0 License](https://creativecommons.org/licenses/by/3.0/), which permits unrestricted use, distribution, and reproduction in any medium, provided the original work is properly cited.

IntechOpen

IntechOpen