

# We are IntechOpen, the world's leading publisher of Open Access books Built by scientists, for scientists

6,900

Open access books available

186,000

International authors and editors

200M

Downloads

Our authors are among the

154

Countries delivered to

TOP 1%

most cited scientists

12.2%

Contributors from top 500 universities



WEB OF SCIENCE™

Selection of our books indexed in the Book Citation Index  
in Web of Science™ Core Collection (BKCI)

Interested in publishing with us?  
Contact [book.department@intechopen.com](mailto:book.department@intechopen.com)

Numbers displayed above are based on latest data collected.  
For more information visit [www.intechopen.com](http://www.intechopen.com)



# Renal Transplantation in Patient with Fabry's Disease Maintained by Enzyme Replacement Therapy

Taigo Kato

*Department of Urology,  
Osaka University Hospital  
Japan*

## 1. Introduction

Fabry's disease (FD) is a rare inborn error of glycosphingolipid catabolism can lead to renal failure. The life expectancy is reduced for both genders, and the major causes of death include cardiac death, stroke, or the consequences of end stage of renal disease. This article summarizes the current knowledge about FD and the treatment of kidney transplantation and enzyme replacement therapy in FD.

## 2. About Fabry's disease

FD is a rare sphingolipidosis related and X-linked disorder of glycosphingolipid catabolism caused by deficient lysosomal  $\alpha$ -galactosidase A activity(Fig.1). Deficiency of the enzyme leads to progressive accumulation of the glycosphingolipid globotriaosylceramide (Gb3) in vascular endothelia, heart tissue, connective tissue, peripheral nerves, and the kidneys (Table.1, Fig.2). Male patients typically develop painful acroparesthesia followed by proteinuria, renal failure, cardiac hypertrophy and cerebral white matter lesions. Females are carriers and may present a wider range of symptoms(Fig.3,4). The incidence has been estimated to be 1:117,000 live births and 1:50,000 males. Registries of dialysis patients from the United States and Europe indicate that FD is the cause of end-stage renal disease (ESRD) for approximately 0.2% of patients on dialysis(Fig.5). Renal disease of some form occurs in most patients, with ESRD a common manifestation in hemizygous males that may develop by the fourth to fifth decade of life. The clinical course in heterozygous female patients involves a delayed onset of symptoms and milder progression, although some female patients present with symptoms similar to those seen in classically affected male patients. The analysis of 197 kidney transplant recipients with FD indicates that they have superior graft survival and similar patient survival compared with patients with other causes of ESRD. However, Fabry patients had a higher risk of death compared with a matched cohort of patients with other causes of ESRD. The median lifespan is 50 years for affected male patients and 70 years for female patients. Current therapy for ESRD in patients with FD involves renal transplantation and enzyme replacement therapy (ERT).

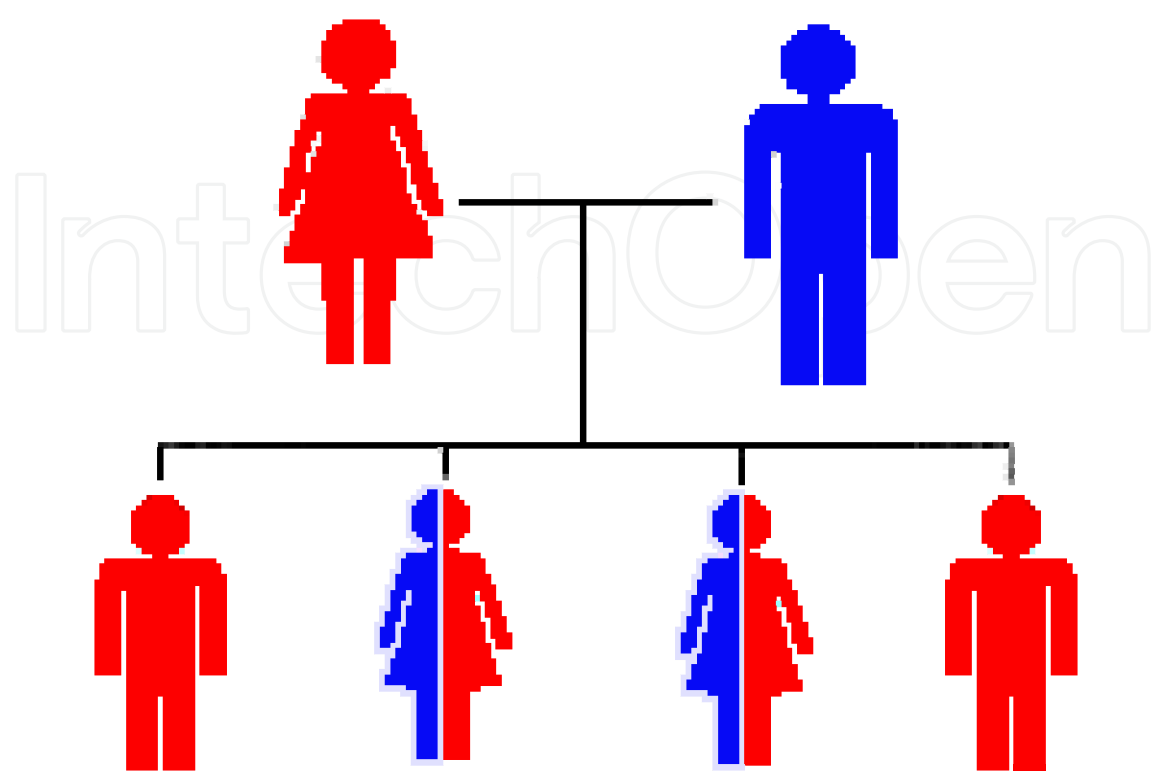


Fig. 1. If a male with Fabry disease and an unaffected (non-carrier) female have children, all of their daughters will be Fabry carriers and none of their sons will be affected with Fabry disease.

Disease		Accumulated material	Deficient enzyme
GM 1 gangliosidosis		GM 1 ganglioside	$\beta$ -galactosidase
GM 2 gangliosidosis	Tay-Sachs Disease	GM 2 ganglioside	$\beta$ -hexosaminidase
	Sandhoff Disease	GM 2 ganglioside	$\beta$ -hexosaminidase
Metachromatic Leukodystrophy		Sulfatide	arylsulfatase A
Ferber Disease		Ceramide	Ceramidase
Gaucher Disease		Glycocerebroside	$\beta$ -glucocerebrosidase
Niemann-Pick Disease		Phosphorylcholine Ceramide	Sphingomyelinase
Krabbe Disease		galactocerebroside	$\beta$ -galactosidase A
Fabry Disease		globotriaosylceramide	$\alpha$ -galactosidase A

Table 1. The classification of sphingolipidosis.

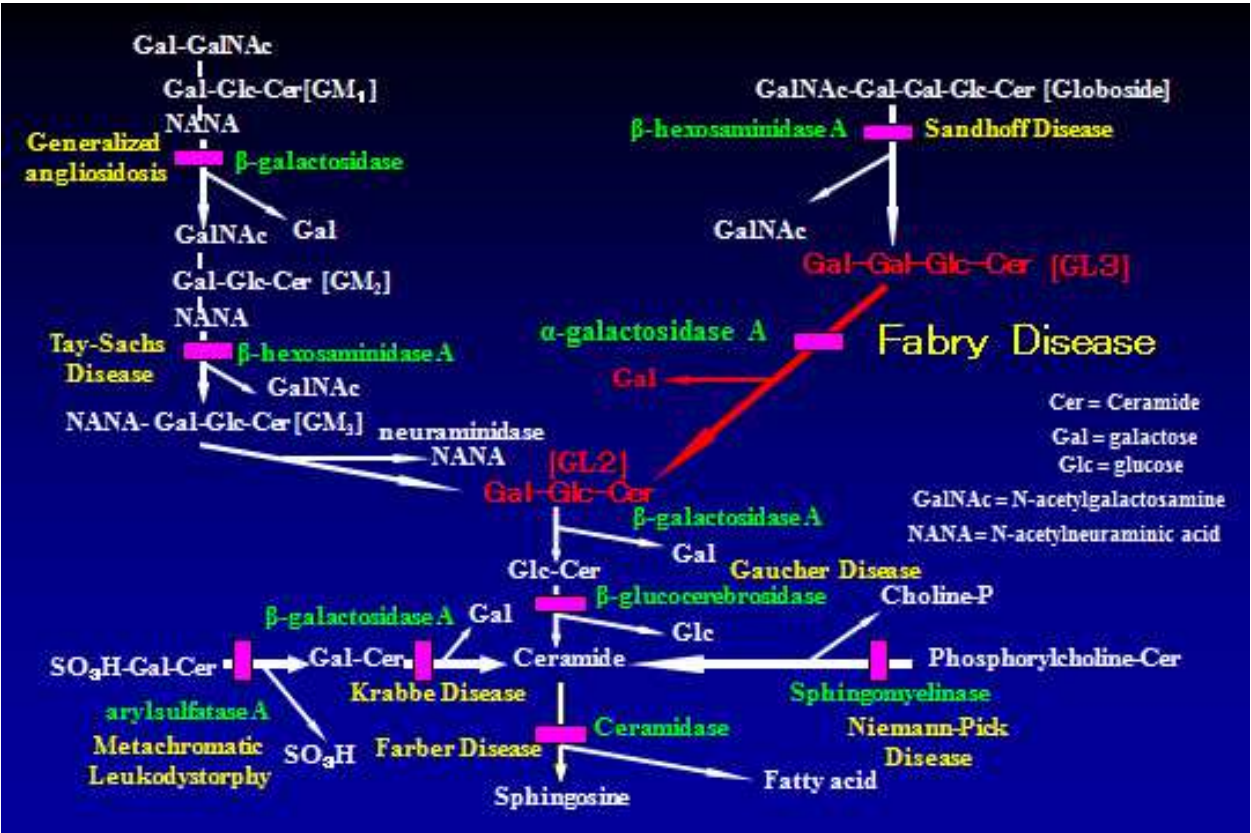


Fig. 2. The classification of sphingolipidosis.

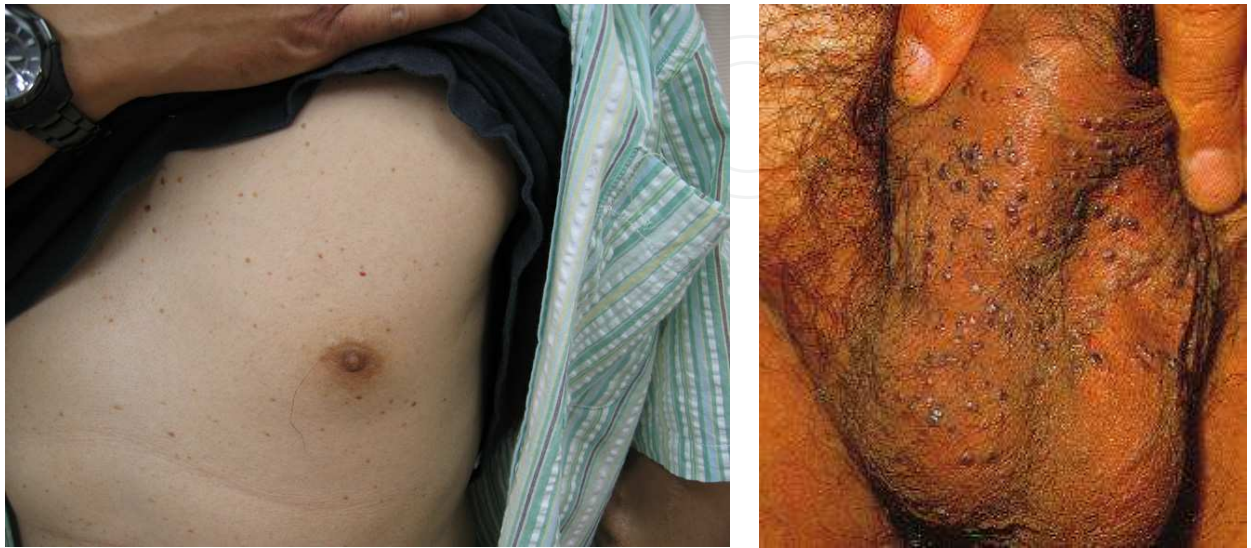

Fig. 3. Clinical features of Fabry's disease; angiokeratomas.



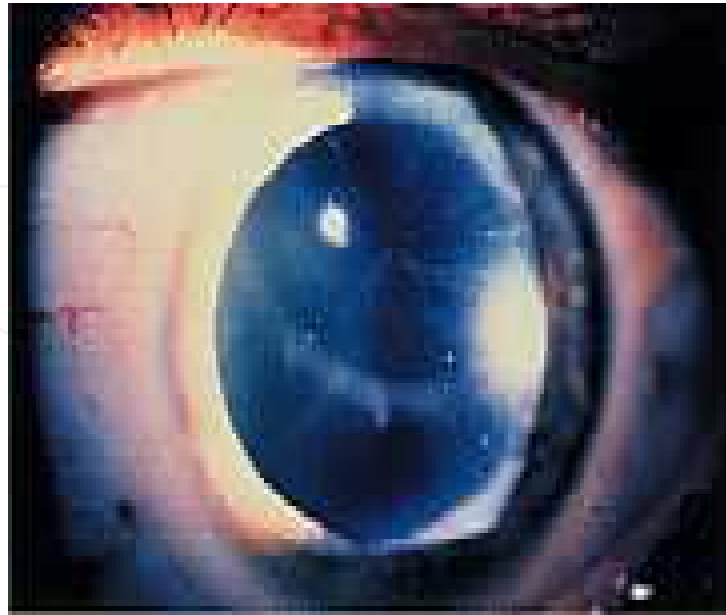

Fig. 4. Clinical features of Fabry's disease; corneal and lenticular opacities.

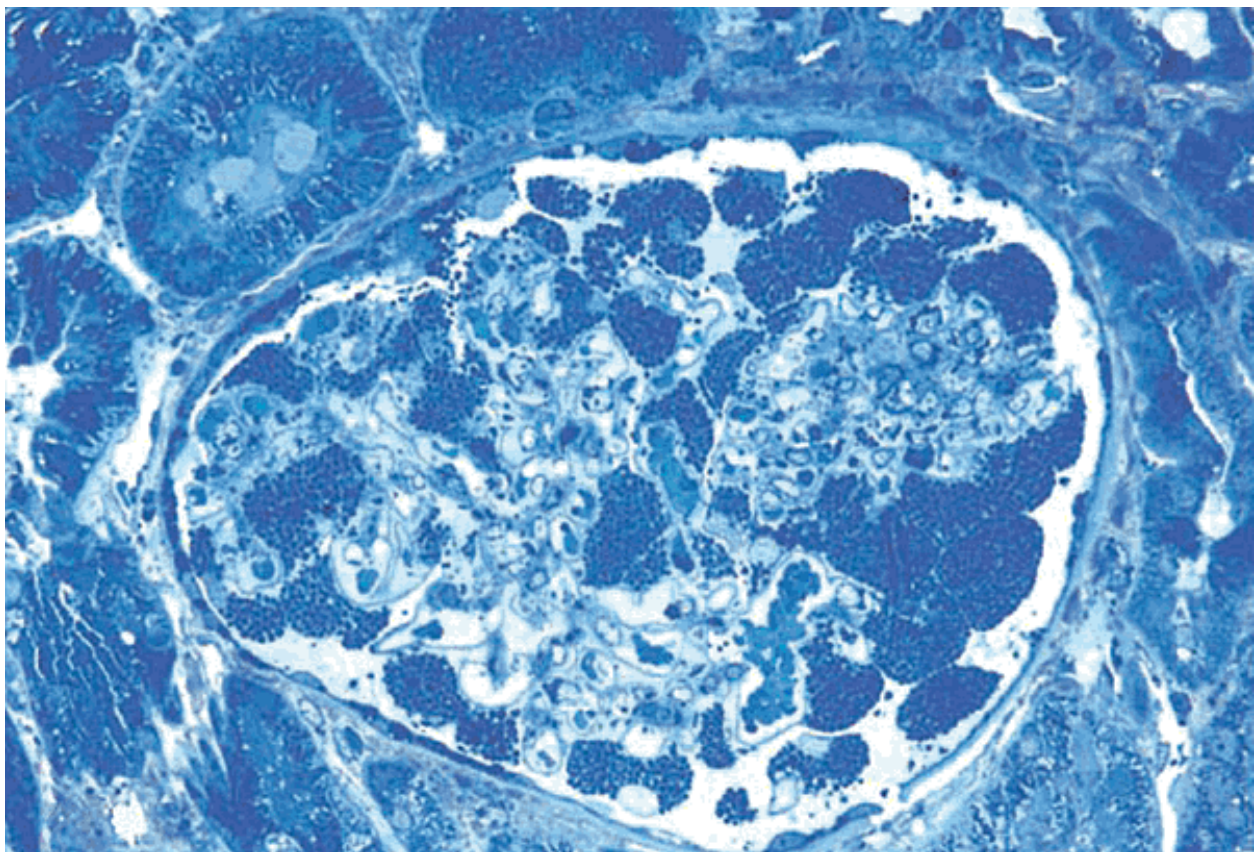


Fig. 5. Ultra structural changes in glomerulus with FD with myelin-like inclusions and subendothelial deposits.

### 3. Renal transplantation in patient with Fabry's disease

Renal transplantation was known to be effective for FD, as previous reports demonstrated that the procedure provided equivalent 5-year patient and graft survivals, as well as improvement of overall prognosis in patients with ESRD due to FD. In contrast, another study found that a renal allograft could not repair the deficient enzyme activity of  $\alpha$ -galactosidase A and noted that the accumulation of Gb3 impaired renal function, which might signify the possibility of recurrence of FD in the renal allograft. According to a previous study from the European Dialysis and Transplant Association/European Renal Association Registry, graft survival at 3 years in 33 patients with FD was not considered as inferior to that of patients with other nephropathies (72% vs. 69%), and patient survival after transplantation was comparable to that of patients aged under 55 years with non-Fabry nephropathies. Excellent graft and patient survival were also reported from the US Renal Data System Registry. FD is therefore not considered a contraindication for renal transplantation. Although a case study has shown that the disease may recur in the transplanted organ, another case study has shown no evidence of disease recurrence in a renal biopsy 8 years after transplantation. A further case study showed extensive Fabry-related renal changes in a renal biopsy from a patient who had received a graft from his sister who was heterozygous for the disease.

### 4. The efficacy of enzyme replacement therapy (ERT)

Enzyme replacement therapy (ERT) for the treatment of Fabry's disease was first performed in the 1970s, however, open-label phase 2 trials were not performed until the 2000s. ERT using recombinant human  $\alpha$ -galactosidase A (generic names agalsidase alpha and agalsidase beta) was approved for use in Europe in 2001 and in the United States in 2003. Initial randomised controlled trials (RCT) showed that 69% of the treatment group was free of renal microvascular endothelial deposits of globotriaosylceramide (primary endpoint) versus no change in the placebo group after 20 weeks ( $p < 0.001$ ). Although there did not appear to be a difference in quality of life as assessed by the SF-36, another RCT showed a statistically significant decrease in pain severity and improvement in quality of life (primary outcome). This study also showed improvement in renal architectural distortion (mesangial diameter) ( $p = 0.01$ ) and increase in creatinine clearance ( $p = 0.02$ ). In a more recent, larger RCT, 42% of placebo patients versus 27% of treated patients had clinical events (defined as renal, cardiac or cerebrovascular event or death); the time to first clinical event adjusted for baseline proteinuria favoured agalsidase beta but included the null (hazard ratio 0.47, CI: 0.21–1.03;  $p < 0.06$ ). Although overall the results were less than overwhelming, treatment effect was greater in patients with preserved renal function. There are no data currently regarding ERT and affect on mortality.

Moreover, a purified recombinant  $\alpha$ -galactosidase A enzyme (Fabrazyme®) was synthesized and administration in non-transplanted FD patients was reported to markedly reduce serum ceramide levels. A detailed report revealed few serious adverse events in a total of 401 patients receiving long-term treatment; as in this study, most adverse events consisted of mild infusion reactions. Patients given recombinant  $\alpha$ -GalA at 1 mg/kg once every two weeks showed decreased microvascular endothelial deposits of Gb3 in skin over a period of 20 weeks and plasma Gb3 also decreased. In addition, in patients who received ERT for 30–36 months, serum creatinine and estimated glomerular filtration rate values remained stable,

while the level of plasma Gb3 remained in a normal range after ERT. More recently, Cybulla et al. explored the effects of agalsidase alfa in transplant patients with FD. Allograft function of 20 patients from the Fabry Outcome Survey registry was analyzed after approximately 3.5 years (median) of agalsidase alfa therapy at the standard dose of 0.2 mg/kg every other week. After 2 years of ERT, there was a slight but nonsignificant increase in serum creatinine (1.4 mg/dl at baseline versus 1.6 mg/dl) and a decrease in eGFR (59.2 ml/min/1.73 m<sup>2</sup> at baseline versus 51.1 ml/min/1.73 m<sup>2</sup> at 2 years). Similar to the previously mentioned study, proteinuria remained stable during this time period. In contrast, ERT may be less effective to improve renal or cardiac function in cases with progressive damage to tissue, as it would likely be difficult to recover the function. Therefore, renal transplantation in conjunction with ERT might achieve better improvement of the graft and overall survival of FD patients.

Mignani et al. reported that plasma Gb3 was decreased by 23-50% after ERT in renal transplant patients with FD. In addition, Inderbitzin et al. treated a patient with persistent FD-related acroparesthesia and found that ERT for 100 months after renal transplantation resulted in an excellent clinical course. In another study, Mignani et al. also reported 3 patients who underwent ERT after renal transplantation, who had maintained renal function and improved cardiac function. In each of those cases, ERT was performed after renal transplantation, whereas we previously reported a rare case of successful cadaveric renal transplantation in patient with FD maintained by ERT with an excellent clinical course. We treated a 48-year-old male patient with a typical clinical history of FD from childhood (intermittent fever, cutaneous angiokeratoma, pain attacks in arms and legs). At the age of 25, renal function disorder with proteinuria was pointed out and hemodialysis started at 26 years old. He was diagnosed with FD based on deficient lysosomal  $\alpha$ -galactosidase A activity at the age of 46 and began ERT by injection of recombinant  $\alpha$ -galactosidase e.g. Agalsidase beta at 1mg per kg bodyweight once every two weeks in August 2004. After the induction of ERT, he still had diffuse angiokeratoma of the body and intermittent abdominal pain. Echocardiographic evaluation suggested hypertrophic obstructive cardiomyopathy with left ventricular hypertrophy.

On December 17, 2005, cadaveric renal transplantation was performed (Fig.6) for the patient. The initial immunosuppressive agents were cyclosporine, mycophenolate mofetil, steroids, and basiliximab, with the cyclosporine trough levels kept at 100-150 ng/ml. No rejection or other complications appeared during the immediate follow-up period, and he withdrew from hemodialysis 23 days after transplantation. At discharge, serum creatinine was reduced to about 1.9 mg/ml and was at a steady-state level. At the same time, the disappearance of the skin lesions and abdominal pain was noticed. At 12 and 24 months after transplantation, graft biopsies were performed, as the serum creatinine level increased to 2.2~2.3 mg/dl. Histological results demonstrated acute cellular rejection, however, there were no abnormal deposits of accumulated glycosphingolipids in the glomerular podocytes or tubular epithelial cells. Electron microscopy revealed normal glomerular cells with a slight increase in the mesangial matrix (Fig.7).

There were no dense deposits. The acute rejection responded to intravenous deoxyspergualin and serum creatinine decreased to 2.0 mg/dl. Since transplantation, ERT has been continued once every two weeks and no complications as a result of that therapy have been recognized.



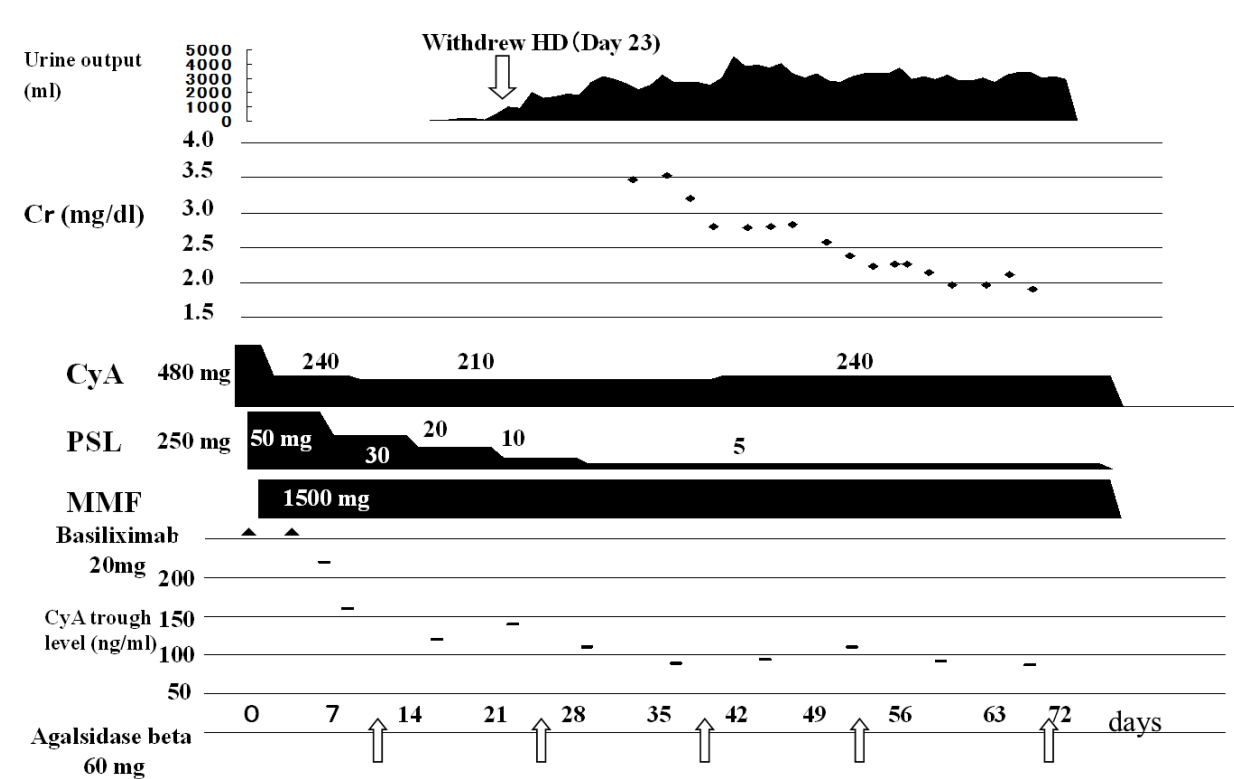


Fig. 6. Clinical course of the patient. Cr creatinine; CsA, cyclosporine; HD, hemodialysis; MMF, mycophenolate mophetil; PSL, prednisolone.

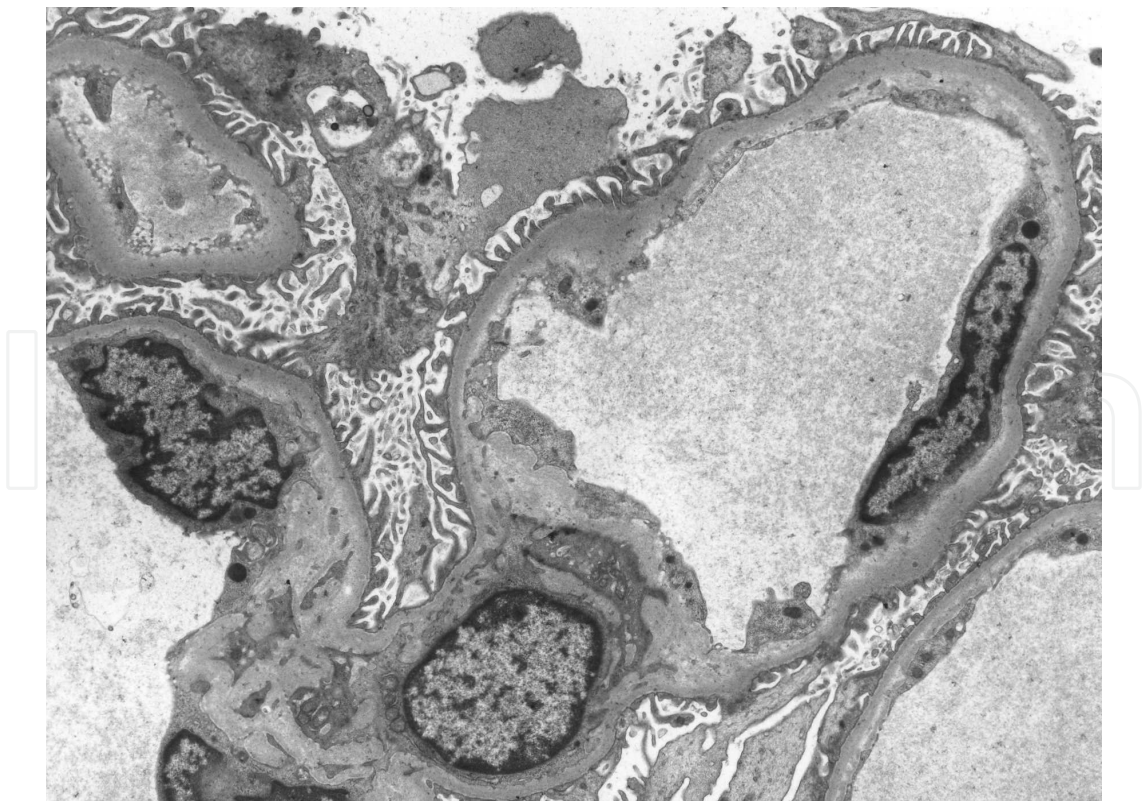

Fig. 7. Electron microscopy of normal glomerulus from kidney graft. Occasional foci of podocyte fusion are present.



The recurrence of FD in patients with a transplanted kidney has rarely been reported. Findings of small amounts of Gb3 deposits in renal grafts have been limited to vascular endothelial cells and tubular epithelial cells. We consider that renal transplantation combined with ERT reduces the risk of recurrence of FD in a transplanted kidney. However, further data are required to confirm whether such treatment will confer long-term renoprotective effects on renal transplantation.

An important problem facing FD patients is that a successful kidney graft survives for 10-15 years, however, cardiovascular complications related to metabolic disease may occur during that time. FD generally progresses systemically after renal transplantation and cardiac ceramide deposition ultimately determines the fate of these patients in the second decade after renal transplantation. Since ERT improves cardiac involvement in FD patients, renal transplantation combined with ERT may be the best therapy for ESRD at the present time. Additional clinical studies are needed to determine the effects of this combination on the overall prognosis of FD.

## 5. Conclusion

Renal transplantation is effective for FD and improves patient and graft survivals as well as overall prognosis in patients with ESRD due to FD. And ERT is well tolerated in patients with FD who have undergone renal transplantation.

In summary, some studies indicate that kidney transplantation and ERT are viable option for patients with ESRD due to FD. Although ERT appears to stabilize renal function, further data are required to confirm whether such treatment will confer long-term renoprotective effects on kidney transplant patients.


## 6. References

- Andrade J, Waters PJ, Singh RS(2008): Screening for Fabry disease in patients with chronic kidney disease: limitations of plasma alpha-galactosidase assay as a screening test. *Clin J Am Soc Nephrol* 3:139-145
- Banikazemi M, Bultas J, Waldek S. (2007) Agalsidase-beta therapy for advanced Fabry disease: a randomized trial. *Ann Intern Med* ; 146:77-86.
- Chimenti C, Morgante E, Tanzilli G.(2008) Angina in Fabry disease reflects coronary small vessel disease. *Circ Heart Fail* ; 1: 161-169.
- Cybulka M, Walter KN, Schwarting A, Divito R, Feriozzi S, Sunder-Plassmann G; European FOS Investigators Group.(2009). Kidney transplantation in patients with Fabry disease. *Transpl Int.* ;22(4):475-81.
- Desnick RJ, Ioannou YA, Eng CM  $\alpha$ -galactosidase A deficiency: Fabry disease. In: Scriver CR, Beaudet AL, Sly WS, Valle D, eds. The metabolic and molecular bases of inherited disease. 8<sup>th</sup> ed. Vol. 3. New York: McGraw-Hill, 2001:3733-74.
- Elliott PM, Kindler H, Shah JS(2006) Coronary microvascular dysfunction in male patients with Anderson-Fabry disease and the effect of treatment with alpha galactosidase A. *Heart* ; 92: 357-360.
- Eng CM, Guffon N, Wilcox WR. (2001) Safety and efficacy of recombinant human  $\alpha$ -galactosidase A replacement therapy in Fabry's disease. *N Engl J Med* 345:9-16

- Inderbitzin D, Avital I. (2005) Kidney transplantation improves survival and is indicated in Fabry's disease. *Transplantation Proceedings* 37;4211-4214
- Karras A, De Lentdecker P, Delahousse M(2008) Combined heart and kidney transplantation in a patient with Fabry disease in the enzyme replacement therapy era. *Am J Transplant*; 8: 1345-1348.
- Kato T, Nishimura K, Ichikawa Y. (2009) Deceased renal transplantation in patient with Fabry's disease maintained by enzyme replacement therapy. *Int J Urol* 16:650
- Kleinert J, Kotanko P, Spada M(2009) Anderson-Fabry disease: a case-finding study among male kidney transplant recipients in Austria. *Transpl Int* 22: 287-292
- Koskenvuo JW, Hartiala JJ, Nuutila P.(2008) Twenty-four-month alphagalactosidase A replacement therapy in Fabry disease has only minimal effects on symptoms and cardiovascular parameters. *J Inherit Metab Dis*; 31: 432-441.
- Kotanko P, Kramar R, Devrnja D(2004) Results of a nationwide screening for Anderson-Fabry disease among dialysis patients. *J Am Soc Nephrol* 15: 1323-1329
- MacDermot KD, Holmes A, Miners AH(2001) Anderson-Fabry disease: Clinical manifestations and impact of disease in a cohort of 98 hemizygous males. *J Med Genet* 38: 750-760
- MacDermot KD, Holmes A, Miners AH(2001) Anderson-Fabry disease: Clinical manifestations and impact of disease in a cohort of 60 obligate carrier females. *J Med Genet* 38: 769-775
- Maslauskienė R, Bumblytė IA, Sileikienė E.(2007) The prevalence of Fabry's disease among male patients on hemodialysis in Lithuania (a screening study). *Medicina (Kaunas)* 43 Suppl 1: 77-80.
- Mehta A, Ricci R, Widmer U.(2004) Fabry disease defined: baseline clinical manifestations of 366 patients in the Fabry Outcome Survey. *Eur J Clin Invest*; 34: 236-242.
- Merta M, Reiterova J, Ledvinova J(2007) A nationwide blood spot screening study for Fabry disease in the Czech Republic haemodialysis patient population. *Nephrol Dial Transplant* 22: 179-186
- Mignani R, Feriozzi S, Pisani A. (2008) Agalsidase therapy in patients with Fabry disease on renal replacement therapy: a nationwide study in Italy. *Nephrol Dial Transplant* May ;23(5):1628-1635
- Mignani R, Gerra D, Maldini. (2001) Long term survival of patients with renal transplantation in Fabry's disease. *Contrib Nephrol*. Vol 136;pp229-233
- Mignani R, Panichi V, Giudicissi A.(2004) Enzyme replacement therapy with agalsidase beta in kidney transplant patients with Fabry disease. *Kidney Int* 66:1279-1282
- Ojo A, Meier-Kriesche HU, Friedman G.(2000) Excellent outcome or renal transplantation in patients with Fabry's disease. *Transplantation* 69;2337
- Porsch DB, Nunes AC, Milani V(2008): Fabry disease in hemodialysis patients in southern Brazil: prevalence study and clinical report. *Ren Fail* 30:825-830
- Rasaiah VI, Underwood JP, Oreopoulos DG(2008) Implementation of high-throughput screening for Fabry disease in Toronto dialysis patients. *Nephrol Dial Transplant Plus* 1: 129-130
- Schiffmann R, Ries M, Timmons M, Flaherty JT, Brady RO.(2006) Long-term therapy with agalsidase alfa for Fabry disease: safety and effects on renal function in a home infusion setting. *Nephrol Dial Transplant*. 21(2):345-54

- Sessa A, Meroni M, Battini G. (2002) Renal transplantation in patients with Fabry disease. *Nephron*;91:348-351
- Shah T, Gill J, Malhotra N, Takemoto SK, Bunnapradist S. (2009) Kidney transplant outcomes in patients with Fabry disease. *Transplantation*. 27;87(2):280-5.
- Spinelli L, Pisani A, Sabbatini M, Petretta M, Andreucci MV, Procaccini D. (2004) Enzyme replacement therapy with agalsidase beta improves cardiac involvement in Fabry's disease. *Clin Genet* 66;158-165.
- Terryn W, Poppe B, Wuyts B (2008): Two-tier approach for the detection of alpha-galactosidase A deficiency in a predominantly female haemodialysis population. *Nephrol Dial Transplant* 23:294–300.
- Tsakiris D, Simpson HK, Jones EH(1996) Report on management of renal failure in Europe, XXVI,: Rare diseases in renal replacement therapy in the ERA-EDTA Registry. *Nephrol Dial Transplant* 11[Suppl 7]: S4–20
- Waldek S. (2003) PR interval and the response to enzyme-replacement therapy for Fabry's disease. *N Engl J Med* ; 348: 1186–1187.
- Weidemann F, Niemann M, Breunig F.(2009) Long-term effects of enzyme replacement therapy on Fabry cardiomyopathy: evidence for a better outcome with early treatment. *Circulation* ; 119: 524–529.
- Whybra C, Kampmann C, Willers I(2001) Anderson-Fabry disease: Clinical manifestations of disease in female heterozygotes. *J Inherit Metab Dis* 24: 715–724
- Wilcox WR, Banikazemi M, Guffon N. (2004) Long-term safety and efficacy of enzyme replacement therapy for Fabry Disease. *Am.J.Hum.Genet.*75;65-74

IntechOpen



## **Renal Transplantation - Updates and Advances**

Edited by Dr. Layron Long

ISBN 978-953-51-0173-4

Hard cover, 234 pages

**Publisher** InTech

**Published online** 29, February, 2012

**Published in print edition** February, 2012

This book presents a nice international compilation of scholarly papers and chapters which address the latest advances in renal transplant surgery. These works cover a variety of topics; the last advance and success of renal transplant science: biochemistry, immunology, molecular genetics, pharmacology - pharmacogenetics, pediatric transplant and a few rare uropathies that warrant organ replacement.

### **How to reference**

In order to correctly reference this scholarly work, feel free to copy and paste the following:

Taigo Kato (2012). Renal Transplantation in Patient with Fabry's Disease Maintained by Enzyme Replacement Therapy, Renal Transplantation - Updates and Advances, Dr. Layron Long (Ed.), ISBN: 978-953-51-0173-4, InTech, Available from: <http://www.intechopen.com/books/renal-transplantation-updates-and-advances/renal-transplantation-in-patient-with-fabry-s-disease-maintained-by-enzyme-replacement-therapy>

**INTECH**  
open science | open minds

### **InTech Europe**

University Campus STeP Ri  
Slavka Krautzeka 83/A  
51000 Rijeka, Croatia  
Phone: +385 (51) 770 447  
Fax: +385 (51) 686 166  
[www.intechopen.com](http://www.intechopen.com)

### **InTech China**

Unit 405, Office Block, Hotel Equatorial Shanghai  
No.65, Yan An Road (West), Shanghai, 200040, China  
中国上海市延安西路65号上海国际贵都大饭店办公楼405单元  
Phone: +86-21-62489820  
Fax: +86-21-62489821



© 2012 The Author(s). Licensee IntechOpen. This is an open access article distributed under the terms of the [Creative Commons Attribution 3.0 License](https://creativecommons.org/licenses/by/3.0/), which permits unrestricted use, distribution, and reproduction in any medium, provided the original work is properly cited.

IntechOpen

IntechOpen