

We are IntechOpen, the world's leading publisher of Open Access books Built by scientists, for scientists

6,900

Open access books available

186,000

International authors and editors

200M

Downloads

Our authors are among the

154

Countries delivered to

TOP 1%

most cited scientists

12.2%

Contributors from top 500 universities



WEB OF SCIENCE™

Selection of our books indexed in the Book Citation Index
in Web of Science™ Core Collection (BKCI)

Interested in publishing with us?
Contact book.department@intechopen.com

Numbers displayed above are based on latest data collected.
For more information visit www.intechopen.com



Renal Explantation Techniques

Marco Antonio Ayala- García^{1,2}, Éctor Jaime Ramírez-Barba^{3,4,5},
Joel Máximo Soel Encalada¹, Beatriz González Yebra^{1,5}

¹Hospital Regional de Alta Especialidad del Bajío

²HGSZ No. 10 del Instituto Mexicano del Seguro Social, Delegación Guanajuato

³Instituto de Salud Pública del Estado de Guanajuato

⁴Secretaría de Salud del Estado de Guanajuato

⁵Universidad de Guanajuato
México

1. Introduction

The demand for kidneys for transplantation has increased significantly in recent years. This increase is, at least in part, due to improvements in therapies that minimize tissue rejection, as well as to more inclusive selection criteria for kidney recipients. The high demand for organs also places challenges on surgeons, requiring them to be familiar with more diverse sources of organ donors. Currently, there are three main sources of kidneys for explantation: cadaveric donors with brain death, non-heart-beating donors, and live donors.

Kidney explantation from a cadaveric donor with brain death can be performed following one of two main approaches: 1) multi-organ explantation using the classic technique or with total abdominal evisceration, or 2) by explanting the kidneys only.

In renal explantation from non-heart-beating donors two techniques can be applied: *in situ* perfusion or cooling of the body with cardiopulmonary bypass.

To obtain a kidney from a live donor, either traditional open surgery or laparoscopy is performed. The latter can be carried out in a transperitoneal or retroperitoneal fashion, with endless variations that take advantage of recent technological improvements.

Surgical transplantation teams within medical institutions should be capable of performing renal explantation from both cadaveric and live donors, and should have in place organizational strategies that are most appropriate for each particular case, complying with the following:

1. Simplicity; the procedures should be easy to perform.
2. Effectiveness; the procedures should best preserve the integrity of the organs.
3. Efficiency; the procedures are carried out using only those resources that are strictly necessary.

This chapter describes each one of the renal explantation techniques, as well as the back-table procedures, i.e. preparation of the renal graft after explantation for further implantation of the organ in the recipient.

2. Renal explantation from cadaveric donor with brain death

Renal explantation from a cadaveric donor with brain death may be performed during multi-organ extraction using the traditional technique or with total abdominal evisceration. Modifications to these techniques, such as quick removal or combined liver-pancreas explantation do exist, but their detailed description is beyond the scope of this chapter.

Exclusive renal explantation from a cadaveric donor with brain death can also be performed, if necessary, when limitations exist due to special circumstances, including:

1. The quality of the facilities available
2. The specific guidelines of different organ transplant programs.
3. The viability of other organs in the cadaveric donor.
4. The need for further approval procedures for the removal of certain organs.

All surgical organ explantation procedures on cadaver must meet the following basic principles:

1. Adequate exploration and dissection to detect anomalies.
2. Cannulation and perfusion with preservation fluids *in situ*.
3. Extraction without damage to organs and with unscathed vascular pedicles.

2.1 Classic multi-organ explantation

This technique was described in 1984 by Starzl, and is based on the dissection of all of the organ vascular pedicles, prior to their perfusion, such that explantation takes place shortly after perfusion. In general, this technique is carried out by independent surgical teams, with one team per organ. It is essential that all surgeons adhere to the pre-approved procedures, with the following order of participation:

Cardiac Surgery Team
Lung Surgery Team
Liver Surgery Team
Pancreatic Surgery Team
Renal Surgery Team
Corneal Team
Musculoskeletal Team

2.1.1 Description of the classical multi-organ extraction technique

The donor is placed in the supine position with arms in forced abduction. A nasogastric tube and a Foley catheter in urethra are placed. Body hair shaving and antisepsis are performed from chin to mid-thigh. Sterile drapes are placed, and two suction devices are installed, one for the thoracic phase and a second one for the abdominal phase. Six thousand (6000) cc of preservation fluid should be available, at a temperature of 0 to 4 ° C, as well as sterile crushed ice. The cardiac or hepatic team starts the surgery by performing a sternotomy and an incision from the xiphoid process to the pubis, with or without bilateral subcostal extension (Fig. 1), allowing access to all thoracic and abdominal organs. After opening the peritoneum, the round ligament is transected and ligated, and the falciform ligament is sectioned with electrocautery until the origin of the right and left triangular ligaments is reached.

In the thoracic phase, a perfect hemostasis of the sternal branches should be accomplished when performing the sternotomy. A Finochietto sternal retractor is put in place before sectioning both pleurae vertically. A short right and left frenectomy improves thoracic and abdominal removal. This is done with electric scalpel, while the lung, pericardium and liver are protected by the hands of the assistant. The opening of the pleura is useful for correction of a possible hypoventilation.

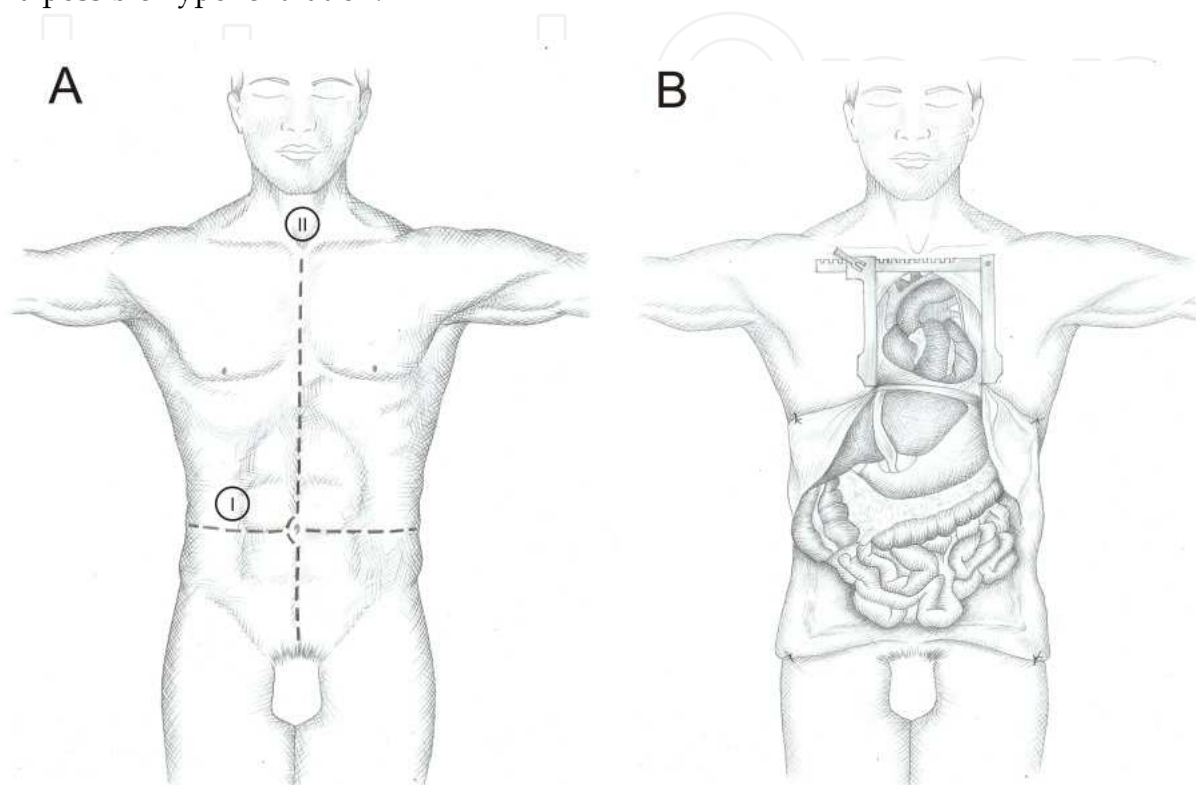


Fig. 1. (A) Sternotomy and midline laparotomy with (I) or without (II) bilateral subcostal extension. (B) Exposure of the thoracoabdominal organs.

The cardiac team opens the pericardium and inspects the heart for vascular or contractility abnormalities. If the organ is deemed adequate for transplantation the team informs the transplant coordinator, such that logistic arrangements related to transplantation procedures can be followed.

The hepatic team inspects the liver, assessing its consistency, color, presence of trauma or other pathology, and the presence of possible vascular abnormalities, especially arterial abnormalities. When applying digital pressure on the parenchyma, a healthy liver rapidly regains its color; when this does not happen, a biopsy will be needed to evaluate steatosis. Injury in more than 60% of the hepatocytes indicates a greatly increased risk of primary dysfunction of the organ, and thus it is rejected for explantation. If after performing this inspection the liver is considered viable for transplantation, the procedure continues and the transplant coordinator is informed. The ascending colon is greatly mobilized by sectioning the right parietocolic and a Kocher maneuver is performed to access the abdominal aorta and inferior vena cava, both of which are dissected and controlled with a thick ligation on their caudal origins (Fig. 2). The inferior mesenteric artery is tied and sectioned.

The pancreatic team sections the gastrocolic ligament and obtains hemostasis by successive ligations, from the right to the left colic flexures, along the greater curvature of the stomach. To the left this maneuver is continued with section of the gastrosplenic ligament and of the short vessels. This allows uncovering of the omentum and exposure of the tail of the pancreas, which can be explored. A normal pancreas has a yellow-orange coloration, is flexible and presents little or no edema. A significant peripancreatic edema that dissects the glandular lobes points to an initial acute pancreatitis, which rules out the explantation of the pancreas. After hanging down the right and left colonic flexures, the vascular pedicles of the mesocolon are dissected and sectioned at their origin, between two ligatures. This maneuver allows the lowering of the colonic frame and exposure of the entire pancreas (Fig. 3).

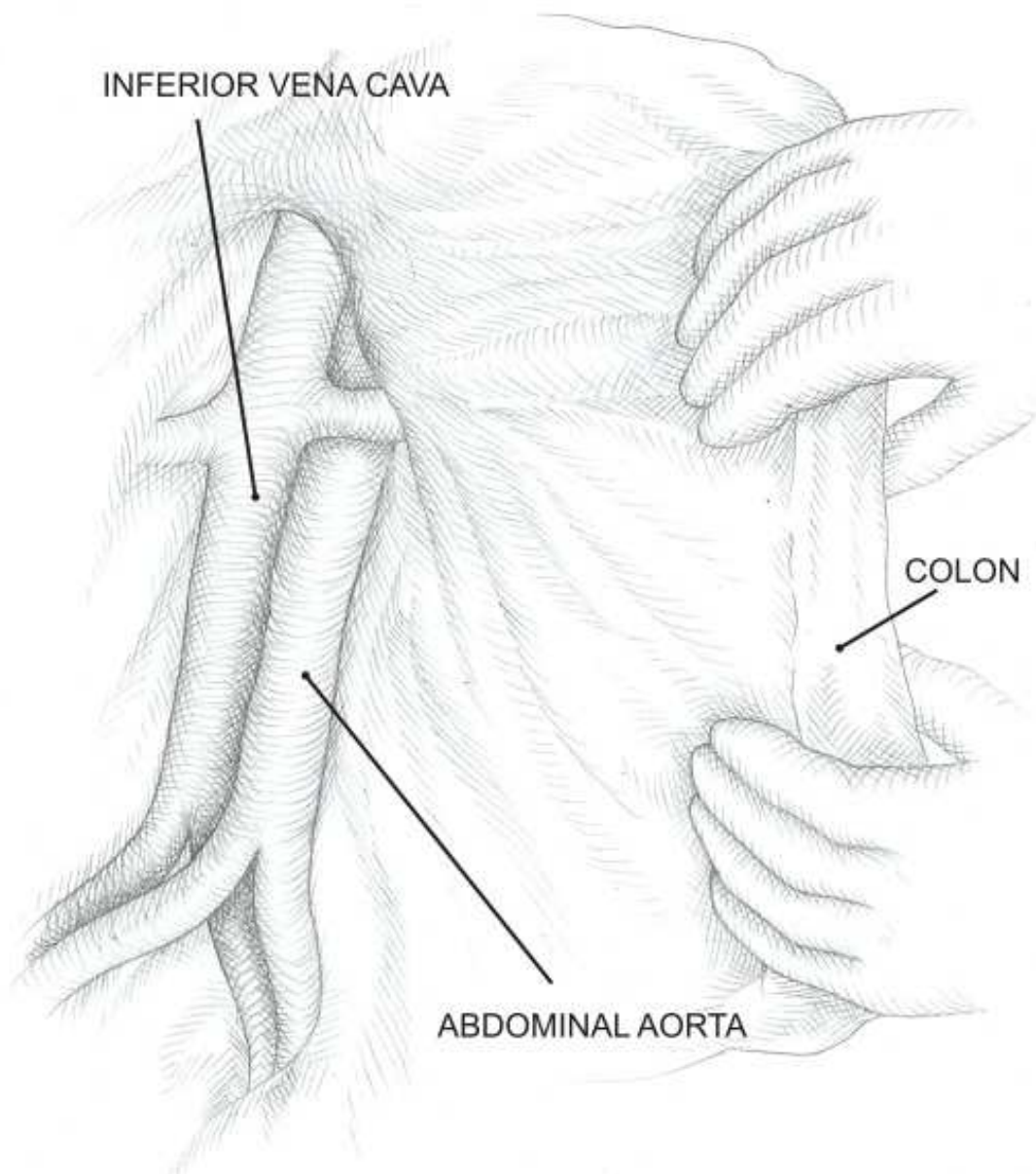


Fig. 2. Kocher maneuver, access to the abdominal aorta and inferior vena cava.

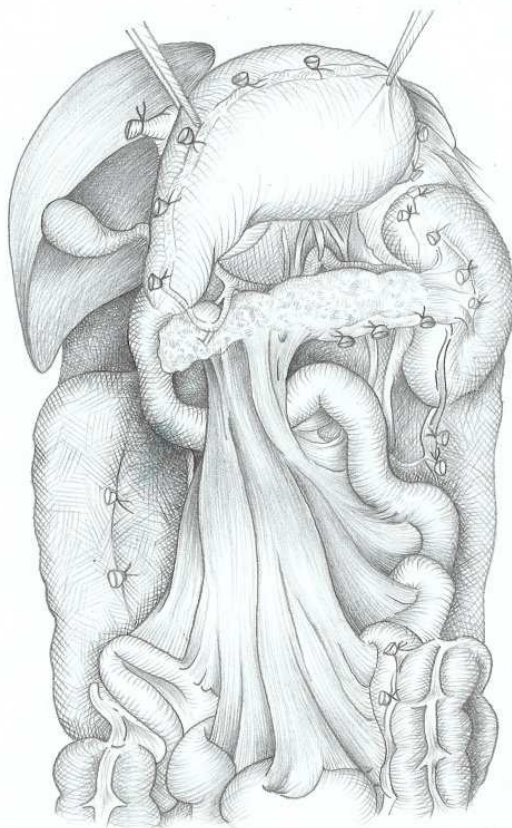

Fig. 3. Downward displacement of the colon, exposing all of the subdiaphragmatic organs.

The hepatic team intervenes further; it identifies and dissects the superior mesenteric artery from its aortic origin to about 3-4 cm distally, to check for the possible presence of an anomalous right hepatic artery. The elements of the hepatic hilum are dissected and the left gastric artery is dissected in search of a left hepatic artery. The left triangular ligament is transected with electrocautery and the left lobe of the liver is moved to the right. A dissection of the supraceliac abdominal aorta is performed, sectioning the right crus of the diaphragm. Once it has been surrounded, the aorta is controlled with a tourniquet, for its subsequent clamping. The gallbladder is opened and rinsed with saline solution.

After the dissection of all of the vascular elements described above, heparinization of the cadaver takes place, by the administration of 300 U/kg of intravenous heparin. Cannulation of the inferior mesenteric vein is performed just below the inferior edge of the pancreas, at about 2 cm, using a probe of 18 to 20 Frens. The end of this probe is placed at the origin of the portal vein, firmly fixing it to the vein above and below its point of entry. Cannulation of the abdominal aorta is performed just above the iliac bifurcation, with a 24 Frens probe in adults and a 16 Frens probe in children. Similarly, cannulation of the vena cava is performed, to allow for venous drainage, thus preventing edema of various organs and facilitating their cooling.

The cardiac team simultaneously cannulates the ascending aorta and the pulmonary artery, through cardioplegia and pulmoplegia needles, respectively. The cardiac team then clamps

the thoracic aorta, while the supraceliac aorta is clamped by the hepatic team. The perfusion of the abdominal organs is initiated by means of the cannulas located in the aorta and inferior mesenteric vein, while the cardioplegic perfusion starts through the ascending aorta, and the pulmoplegic perfusion through the pulmonary artery (Fig. 4). Six thousand (6000) cc of preserving solution is commonly used: 1000 cc in the ascending aorta, 1000 cc in the pulmonary artery, 2000 cc in the abdominal aorta, and 2000 cc in the inferior mesenteric vein.

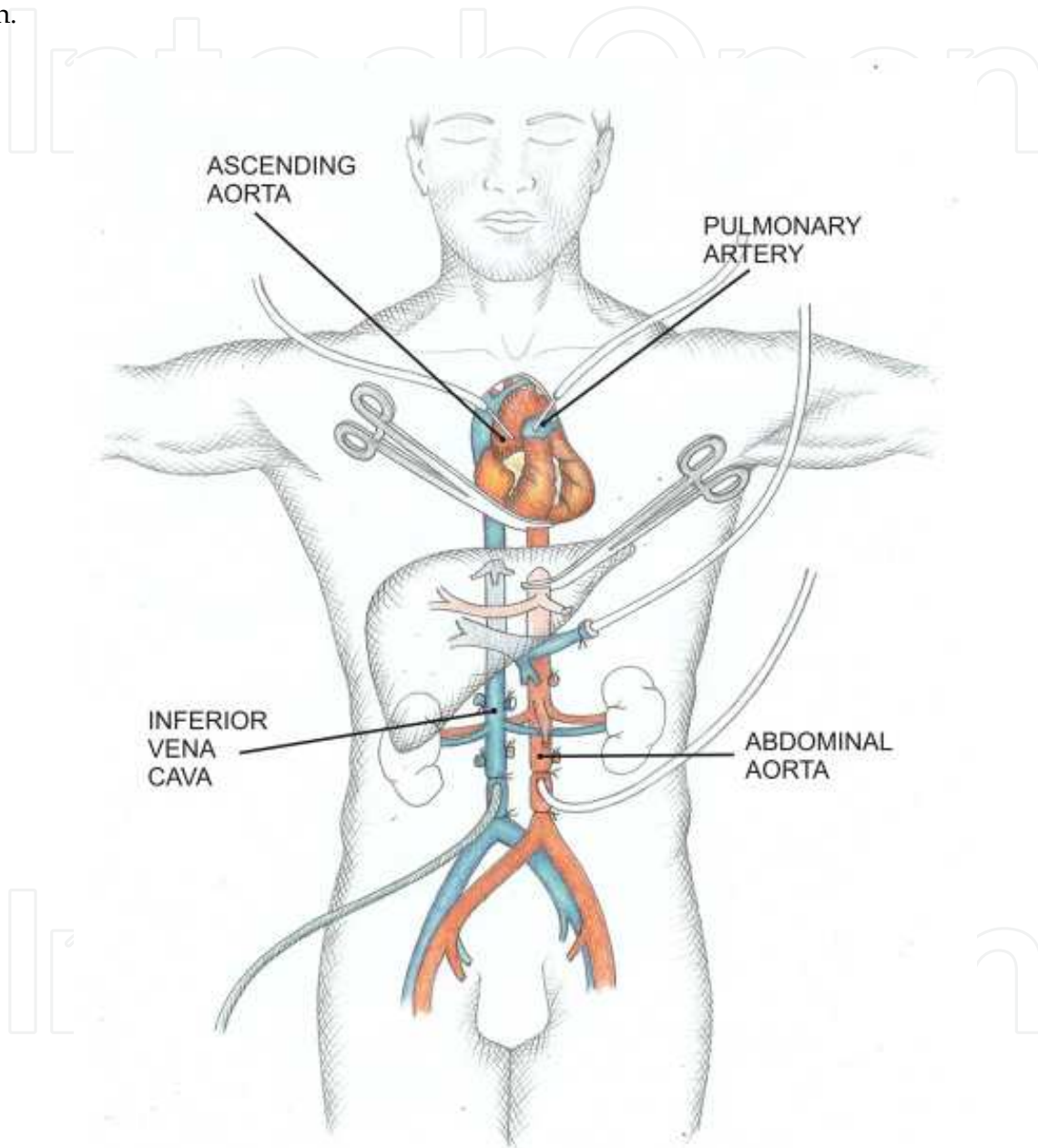


Fig. 4. In situ hypothermic perfusion.

At this point the mechanical ventilator is disconnected from the endotracheal tube. Once the thoracic aorta is occluded, the decompression of the heart chambers is performed via the inferior vena cava, by partially severing the left atrial appendage. The lack of a "universal" preservation solution makes it necessary to separate the cooling territories of heart, lungs

and abdominal organs. The thoracic and abdominal cavities are simultaneously irrigated with crushed ice to further accelerate the cooling.

The cardiac team removes the heart, severing the pulmonary veins, the superior and inferior vena cava, the aorta, and the pulmonary arteries. Special care should be taken with the section of the pulmonary artery, as there should be enough tissue left in both the lung and heart grafts.

The pulmonary team sections the pericardium up to the pulmonary hilum, leaving wide margins. The trachea is clamped as proximally as possible, and a staple line is placed above the 5th tracheal ring (6-8 cm). The trachea is then sectioned between the clamp and the staple line. The triangular ligaments are severed on both hemithorax, as well as the posterior mediastinal soft tissue, allowing the explantation of the lungs as a block.

After removing the heart and lungs, the hepatic team waits until the liver is adequately perfused. This is apparent by the discoloration of the organ, and should take approximately 10 to 15 minutes. The removal of the liver depends intimately on that of the pancreas, because the arteries of these organs originate from a common celiac trunk. Additionally, when a right hepatic artery originates from the superior mesenteric artery, the latter is also a common origin for both hepatic and pancreatic vessels. The issue that arises is whether the celiac trunk should accompany the liver or the pancreas. It all depends on the distribution of the arteries of the liver. If one right and one left hepatic arteries do exist, taking the celiac trunk with the liver may allow taking of the gastrohepatic trunk to the potential implantation site for the right hepatic artery (gastroduodenal stump or splenic ostium).

The gastroduodenal artery and the common bile duct are transected at the level of the duodenum, so that the portal vein is exposed. The perfusion of the inferior mesenteric vein is stopped, the cannula is withdrawn and the vein is tied along the bottom edge of the pancreas. The portal vein is transected. If the celiac trunk accompanies the liver, the aorta is transected between the origin of the celiac trunk and the superior mesenteric artery; the axis of the section should be very oblique, upwards and backwards, to avoid the risk of injury to a renal artery. The infrahepatic vena cava is transected just above the confluency of the renal veins. The right diaphragm and retrocaval tissue are sectioned, which exposes the whole liver and allows its extraction.

The pancreatic team rejoins the surgical field and transects the duodenum between two rows of surgical staples (TA55) immediately below the pylorus and then at the angle of Treitz. The superior mesenteric pedicle is tied and severed at the bottom edge of the third duodenal portion. The origin of the superior mesenteric artery is freed from its lymphatic surroundings and is meticulously tied because it can be the source of considerable lymphatic leakage on the revascularized graft. The superior mesenteric artery is sectioned at the level of the aorta, becoming free of the pancreas.

Once the heart, lungs, liver and pancreas are explanted from the cadaver, the renal team gets involved. The perfusion of preservation solution to the kidneys can be maintained throughout the previous phase, to avoid heating and thereby injury. Both ureters are dissected and sectioned at their distal end, close to the bladder. The aorta and inferior vena cava are sectioned distally to the insertion of the perfusion cannulas. All lumbar vessels and retroaortic tissue are sectioned in a cranial direction. Finally, the adhesions of the kidneys to

the retroperitoneum are sectioned. This fully releases the kidneys, which can then be extracted for subsequent packaging in preservation solution and back-table preparation.

After all useful organs have been explanted, the following tissues are also recovered: iliac vessels that may be needed for vascular reconstruction of both the liver and kidneys, and spleen material for Human Leukocyte Antigen (HLA) system studies. At this time the corneal team intervenes, and finally the musculoskeletal team. At some facilities skin is also removed, and this is the last explantation procedure to be performed.

The reconstruction of the cadaver must be very careful. This step is as important as any of the above, as it is essential to preserve the dignity and integrity of the cadaver (Fig. 5). This procedure should allow delivering of the body of the donor in the following fashion: 1) all incisions performed for the removal of organs and tissues should be sutured, 2) no tubes or catheters should remain, 3) the body should be clean, with particular care in removing all blood stains, 4) the eyes should be closed, 5) limbs from where skeletal or muscle tissue was explanted should be properly covered, 6) a sign should be placed indicating whether skeletal or muscle tissue was obtained, and that prostheses were placed accordingly, 7) the body should be covered with a sheet or placed inside a bag.

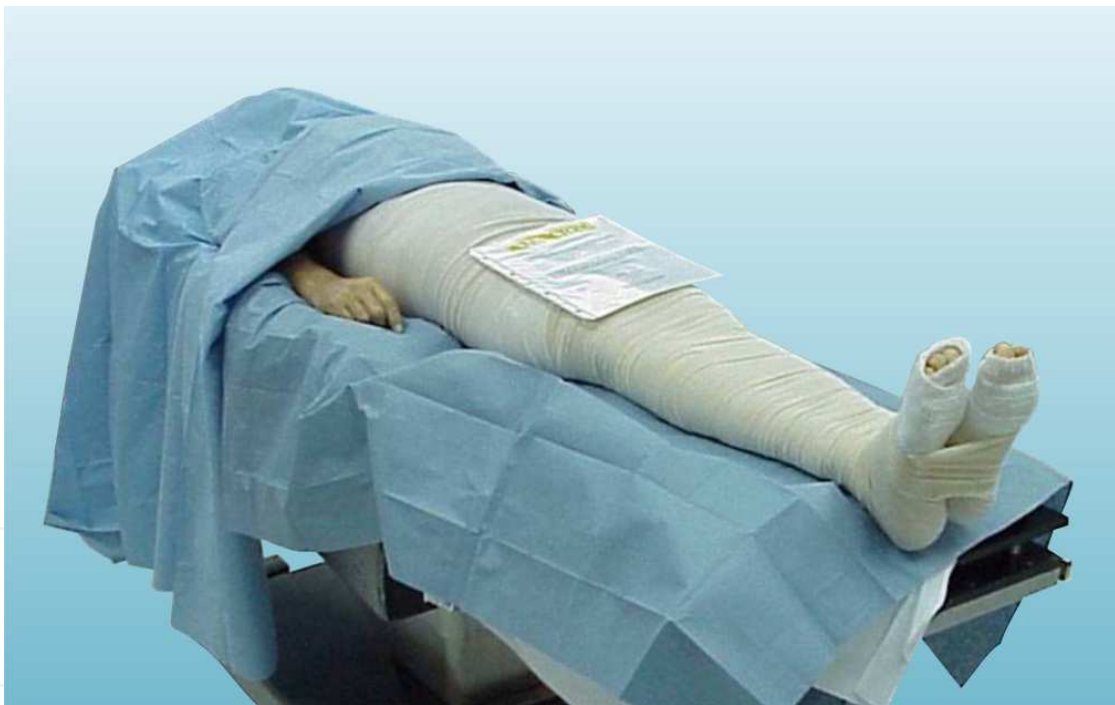

Fig. 5. Dignity of the cadaver.

2.2 Total abdominal evisceration

Developed by Nakazato in 1992, this technique is based on the minimal possible manipulation of the donor body, which is limited to the insertion of cannulas for infusion of preservation fluids. The organs are then dissected out and most of the surgical procedures on the organs are performed at the bench "*ex vivo*". Two surgical teams are involved in this method, a thoracic team and an abdominal team, and they each operate in two distinct phases: the dissection of the corpse and the dissection of organs *ex vivo*.

2.2.1 Dissection on the cadaver

The donor is placed in the supine position as in the classical technique, catheters are placed and antisepsis and shaving are performed. With preservation fluid and sterile crushed ice available, a sternotomy and midline laparotomy are performed with bilateral subcostal extension (Fig. 1). Both the thoracic and abdominal organs are approached and inspected, and their potential viability or any contraindications are communicated.

Once the decision to proceed has been made both the thoracic and abdominal teams work simultaneously. The thoracic team performs the opening of the pericardium, dissection of large vessels, and identification of ascending aorta and pulmonary artery, if lung explantation is going to be performed. The abdominal team identifies the superior mesenteric vein at the root of the mesocolon, identifies the infrarenal aorta just above the origin of the iliac arteries and dissects the descending thoracic aorta before widely opening the left diaphragm. At this level the aorta is covered by only the pleura and has no branches. Once these maneuvers have been performed, which should take approximately 15 to 30 minutes, heparin is administered intravenously at a dose of 300 U/kg. The perfusion cannulas are then put in place.

In the thorax, the cardioplegic cannula is inserted into the aortic root. When the lungs are to be removed, the insertion of the cannula is performed at the level of the pulmonary artery. In the abdomen, the insertion of the cannula (18 to 20 Frens in adults, 14 to 16 Frens in children) is performed at the level of the inferior mesenteric vein. There is also insertion of a cannula into the distal aorta (20 to 24 Frens for adults and 14 to 16 Frens for children). Also, the inferior vena cava is cannulated for venous drainage.

After performing the maneuvers described above both teams are ready to start the infusion and coordinated extraction of the respective organs, in the following order: First, simultaneous clamping of thoracic and abdominal aorta, and establishment of large venous drainage through the cannula placed in the vena cava, with sectioning of the infracardiac vena cava. Perfusion of the preservation fluids is started, at the following ratios: 1000 cc for the heart, 1000 cc for the lung, and 4000 cc for the abdomen. After the organs have been perfused, the removal of the heart and lungs is performed, just as in the classical technique. In the abdomen all of the mesocolon is sectioned, and the colon is mobilized. The jejunum is transected at the level of the ligament of Treitz with a stapling device (GIA™ or PLC™) and the small intestine mesentery is sectioned, after which the small bowel and colon are externalized from the abdomen. Both ureters are identified and distally sectioned. The left diaphragm insertion and left parietocolic are transected. The stomach, spleen, pancreas and left kidney are moved toward the midline. The right diaphragm insertion and right parietocolic are then transected, following mobilization toward the midline of the liver, pancreas and right kidney. The distal thoracic esophagus is identified and sectioned with a stapling device and the thoracic aorta is transected just above the clamp placed at that level, which remains in the closed position to allow the continuous perfusion of the abdominal organs. The posterior diaphragm and all retroperitoneal tissue posterior to the aorta are then sectioned. The infrarenal aorta and vena cava are sectioned distally to the insertion site of the perfusion cannula.

The organ complex consisting of the liver, stomach, duodenum-pancreas-spleen, and kidneys is introduced into a pan with saline solution and crushed ice. The explantation is

now completed, and as in the classical technique, additional tissues are recovered and the final preparation of the corpse is secured. This explantation technique takes about 15 to 30 minutes, such that the overall duration of surgical procedures in the donor will be no longer than 45 to 60 minutes. This relatively short time significantly simplifies logistics and makes total abdominal evisceration particularly advisable in cases where the maintenance of the donor body is complicated.

2.2.2 Dissection *ex vivo*

2.2.2.1 Separation of renal block

The abdominal specimen is dissected from its posterior face. The aorta is sectioned throughout its entire length, thereby identifying the origins of all visceral arteries and their possible anomalies. The anterior side of the aorta is sectioned between the orifices of the renal arteries and superior mesenteric artery. The hepatorenal ligament is sectioned, followed by identification of the infrahepatic vena cava, which is sectioned just above the outlet of the renal vessels. The pancreatorenal ligament is transected. The kidneys are then ready for back-table surgery.

2.2.2.2 Separation of the liver from the pancreas-duodenum-spleen complex

The superior mesenteric artery is identified and dissected to check for the presence of a right hepatic artery which, if present, is preserved as part of the hepatic specimen. The celiac trunk is identified and dissected, after which the splenic and left gastric arteries are identified and sectioned, provided that there are no anomalies in the left hepatic artery. The specimen is turned over, in order to dissect it by its anterior or ventral face. When the pancreas is to be explanted, the common bile duct, gastroduodenal artery and portal vein are distally sectioned from right to left, just above the outlet of the coronary vein. Otherwise, the sectioning is performed at the junction with the superior mesenteric vein. The stomach is separated by cutting the gastrohepatic ligament, and the duodenum is sectioned with a stapling device when the pancreas is to be explanted. Otherwise, the liver can be separated from the rest of the specimen at this point.

2.3 Exclusive renal explantation from cadaveric donor

This technique follows the principles of the classical multi-organ explantation described by Starzl, and kidney transplant surgeons are invariably well versed in this approach. It is used when limitations are imposed on the surgical team by outside factors, such as the hospital, the specific organ transplantation programs that may be active in the facility, the quality of the other organs in the donor, or the unavailability of the authorizations necessary to explant organs other than the kidneys.

2.3.1 Description of the exclusively renal explantation technique

The cadaveric donor is placed on the operating table in the supine position, with the arms in forced abduction, and a Foley catheter is placed in the urethra. Shaving and antisepsis of the abdominal wall is performed, sterile fields are placed and the abdominal cavity is accessed by means of a medial xifopubic laparotomy with bilateral subcostal extension. The right colon is greatly mobilized by cutting the right parietocolic, and a Kocher maneuver is

performed, the small bowel is mobilized superiorly until it is only held together by the mesenteric vessels. Following these maneuvers the abdominal aorta and inferior vena cava can be accessed, dissected, and controlled with a thick ligature in its caudal origins (Fig. 2). The inferior mesenteric artery is ligated and sectioned. The right kidney is identified and is freed from the fascia of Gerota. The same dissection is done with the left kidney, ending with the creation of a window on the left sided colonic mesentery. At this point there is no attempt to identify and dissect the renal arteries or veins. The hilum is left untouched.

During this dissection, the surgeons look for several anomalies that might be present, such as:

1. Congenital malformations and anatomical variations of the kidneys, such as horseshoe kidney.
2. Iliac arterial branches to the lower kidney poles.
3. Precava branches of the lower pole of right kidney.
4. Postaortic left renal vein.

The superior mesenteric artery is sectioned. The lymph nodes near the stump of the superior mesenteric artery are sectioned in order to place the vascular clamp 1 cm above the origin of said artery. The hepatic hilum is dissected and the portal vein is ligated. The donor is heparinized intravenously at a dose of 300 U/kg. The aorta and the cava are ligated distally and are proximally cannulated, and the perfusion of preservation fluids through the aorta is started. The aorta is clamped above the superior mesenteric artery, while the drainage of blood is allowed from the cannula in the abdominal vena cava. It is often necessary to open the diaphragm and cut the infracardiac vena cava, allowing abundant venous drainage. As a consequence of this maneuver blood contaminates the abdominal cavity, and thus constant suction will be required within the cavity. Should it be desirable to keep blood away from the abdominal cavity, a sternotomy could be performed as part of the initial approach (Fig. 1), thus preserving the integrity of the diaphragm and restricting blood to the thoracic cavity, where constant suction with two sets of aspiration equipment should be ensured. The abdominal cavity is irrigated with crushed ice prepared with normal saline to further accelerate cooling, while 4 liters of preservation solution is infused through the aorta (Fig. 6). Subsequently the ureters are clipped in their more distal portion using Kelly forceps, near the bladder, are cut at this level, and dissected in the distal to proximal direction. The abdominal aorta and inferior vena cava are sectioned, above the site of their initial ligation, and are sectioned below the diaphragm. The complete specimen including aorta and vena cava is extracted, together with the kidneys and ureters. The iliac vessels are removed, as they may be required for vascular reconstructions, and splenic tissue is obtained for studies of the HLA system. Everything is placed in cold solution with crushed ice. The specimen consisting of both kidneys will subsequently be subjected to back-table surgery. The abdominal cavity is then sutured, and the cadaver is left clean, removing any catheters and tubes. The corpse is treated as described previously.

3. Renal explantation from non-heart-beating donor

In recent years, the possibility of obtaining organs for transplantation from donors in asystole has been reconsidered. Following the work of García-Rinaldi in 1975, *in situ* perfusion of cadaveric kidneys by cold infusion made directly through a catheter via the

femoral artery into the aorta has successfully been applied. This approach has allowed a significant reduction in the time of warm ischemia, thus overcoming the main limitation of non-heart-beating donors, i.e. the poor preservation of the organs, which are often subjected to long periods of warm ischemia. "Warm ischemic time" is defined as the time elapsed from the moment of circulatory arrest until the cooling of the organ, and includes the time elapsed both with and without effective cardiopulmonary resuscitation maneuvers. In contrast, "cold ischemic time" involves the time elapsed from the moment of cold perfusion until revascularization is achieved, once the organ is implanted in the recipient.

Following García-Rinaldi, many authors have implemented these methods with good results, and the inclusion of this group of donors in organ procurement programs is increasingly being recommended. Other variations to this protocol have also emerged, such as that of Koyama, who has used body hypothermia by cardiopulmonary bypass with good results in non-heart-beating donors.

The sources of non-heart-beating donors are diverse, and after the Maastricht workshop in 1995 four categories have been defined:

Category 1: Donors that reach the hospital as cadavers (after traffic accidents or other causes, patients have cardiac arrest during transport to the hospital, without application of cardiopulmonary resuscitation maneuvers. These donors are considered cadavers upon arrival to the hospital).

Category 2: Recipients of ineffective cardiopulmonary resuscitation (CPR, includes most non-heart-beating donors, and can originate from within the hospital or from outside sources).

Category 3: Donors where cardiac arrest is expected (patients with irreversible brain damage, but that do not meet the criteria for brain death donors. The donors are taken to the operating room, where the life support measures are interrupted, and cardiac arrest is expected). This group raises many ethical considerations and is not accepted in many countries.

Category 4: Donors with brain death that are part of organ donation programs, and who suffer cardiac arrest in the course of the diagnostic procedures or while awaiting for explantation equipment to become available.

3.1 Selection criteria for donors

Selection criteria for potential non-heart-beating organ donors include:

1. Age between 7 and 55.
2. Cause of death should be known or suspected, ruling out those donors who have died as a consequence of personal violent acts (due to potential interference with judicial investigations)
3. Thoracic or abdominal injuries with massive bleeding should be absent
4. Ischemic time without effective CPR of less than 30 minutes.
5. Ischemic time with effective CPR of up to 2 hours.
6. A total warm ischemic time, including the time with and without cardiopulmonary resuscitation maneuvers, of up to 2 and a half hours.
7. The criteria applicable to donors with brain death

3.2 Initial procedures

The procedure for removal of organs from non-heart-beating donors begins after the diagnosis of death by the medical team that has treated the patient, at which point the cadaver is considered as a potential donor. At this point it is necessary to accurately assess the length of warm ischemia suffered by the organs, from the time of cardiac arrest until the beginning of cardiopulmonary resuscitation, and from the beginning of these maneuvers until the onset of cold recirculation. Initially, mechanical ventilation and cardiac massage on the body is continued, in order to maintain the best possible perfusion of the organs, and the heparinization of the donor begins (300 U/kg body weight). Simultaneously, blood samples are obtained to perform laboratory measurements, with emphasis on the plasma serology information that will be necessary for the selection of the recipient. Some authors (Booster MH et al, 1993) recommend the use of phentolamine (0.125 mg/kg) to induce vasodilatation of the renal vessels prior to the infusion, and thus facilitate the rapid decrease in temperature. The femoral artery and vein are catheterized by surgical dissection and cold perfusion of organs is started. Some groups (González MM et al, 1994; Szostek M et al, 1995) have reported good results using mechanical ventilation and cardiac massage for the maintenance of the donor until the moment of explantation.

3.3 Techniques for perfusion *in situ*

Renal perfusion was traditionally achieved by gravity, with perfusion of cold preservation solution through the femoral artery (*in situ* perfusion), and exsanguination via the femoral vein. García Rinaldi et al. used a catheter with a double balloon and triple lumen, placed in the aorta via the femoral artery, thus achieving isolation of renal circulation. Surface cooling of the kidneys has been added to this methodology, by continuous hypothermic peritoneal infusion, which reduces the temperature in the kidney and protects renal microvasculature in case of ineffective cold perfusion. This is especially important in cases when perfusion lasts a relatively long time. Improvements have also been made by adding pressure to the preservation fluid. Anaise has shown that when 70 mmHg of pressure is used, the drop in temperature is faster and more effective (up to 15 degrees Celsius in 5 minutes). Lower pressure would increase the release of renin-angiotensin, which could cause an increase in renal vascular resistance, thus promoting a decrease in renal blood flow and poor hypothermia.

3.4 Body cooling with cardiopulmonary bypass

In this procedure, cannulation of the femoral artery and vein is performed, allowing connection to an extracorporeal circulation system with a membrane oxygenator and heat exchanger (Fig. 6). A Fogarty balloon is placed through the contralateral femoral artery to interrupt blood flow above the level of the superior mesenteric artery. This prevents the flow of blood from the donor and of preservation solution above this level, ensuring a temperature differential between both chambers. Priming and premedication of the extracorporeal circulation system is achieved with 2 g fosfomicin, 8 mg pancuronium, 300 mg hydrocortisone, 2000 cc of Ringer-Lactate, 500 cc hydroxyethyl starch, 200 cc of molar bicarbonate serum, and 30,000 U of heparin.

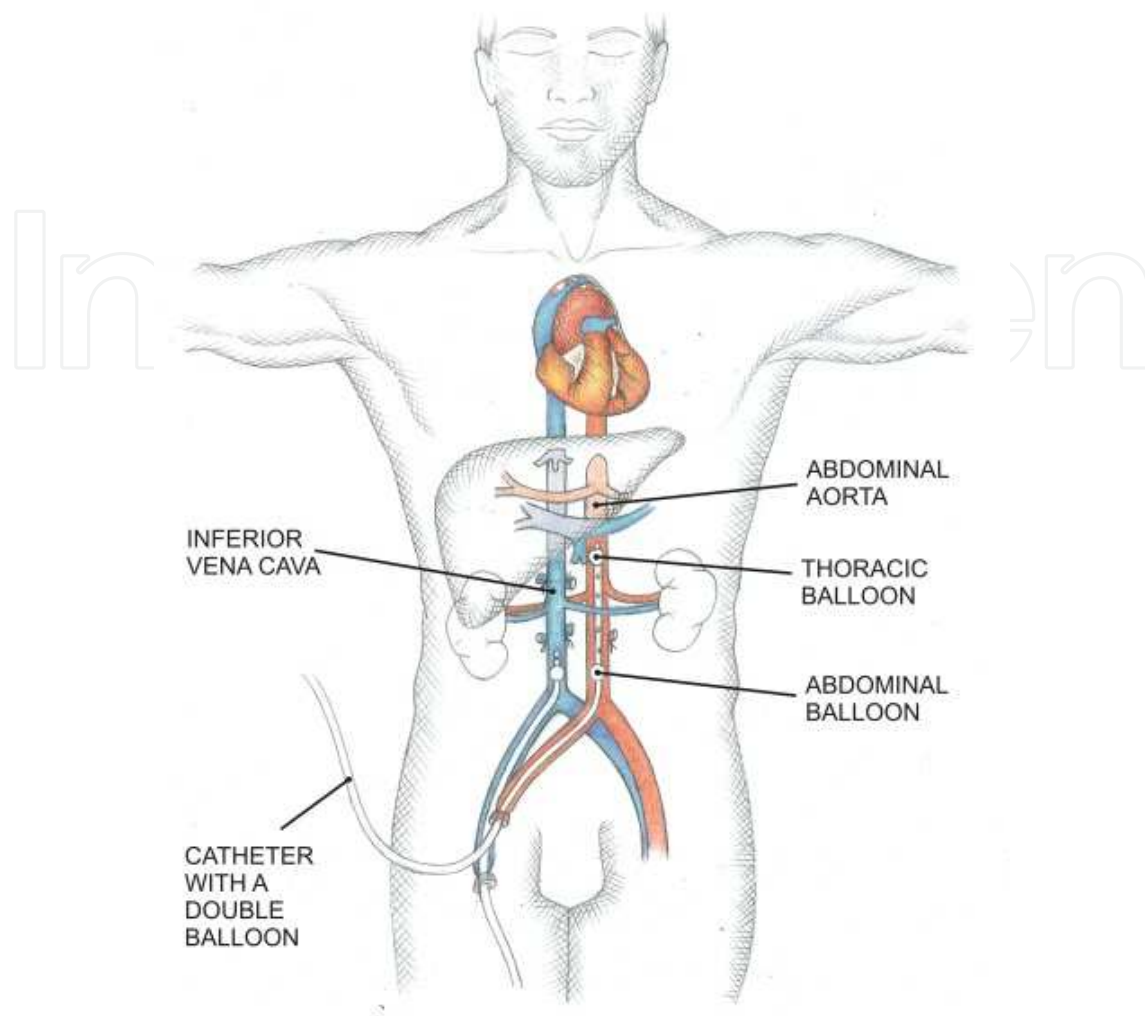


Fig. 6. Cannulation of the femoral artery and vein in the non-heart-beating donor.

The main difference between the *in situ* perfusion technique and body cooling with cardiopulmonary bypass is that in the latter the blood volume of the donor is maintained, without exsanguination. This ensures the reversibility of the process, and therefore its universal applicability, including in cases where it is necessary to wait for further authorization before confirming the deceased as an organ donor. In the two techniques used (*in situ* perfusion and body cooling with cardiopulmonary bypass), the donor is transferred to the operating room after obtaining court approval, and the kidney explantation is performed and, where appropriate, that of the liver and other tissues. The techniques used are the same previously described in this chapter for brain-dead cadaver donors.

3.5 Final procedures

More so than for other types of donor, in the non-heart-beating donor, the assessment of organ viability is crucial. This is achieved through macroscopic examination, and through biopsies. Biochemical determinations after death will provide very little guidance regarding kidney function, due to post-mortem cytolysis. Research in this area is currently focused on

the metabolism of adenine nucleotides. Through these studies, the correlation between cellular energy status (adenine nucleotides) and post-transplant functionality has been established, both in renal and hepatic transplants obtained from non-heart-beating donors.

4. Explantation of kidneys from living donors

Because of the large numbers of patients awaiting kidneys worldwide, public health systems have invested more effort in promoting donation from living individuals. One of the factors that traditionally have discouraged potential living donors is the need to undergo an open nephrectomy, which can cause significant pain and scarring. Open nephrectomy was the first to be applied to living donors, starting in the mid twentieth century.

The advent of laparoscopic procedures in almost all branches of surgery, including urology, opened new possibilities for increasing the number of living kidney donors. Patients are able to return to work sooner, suffer less pain, and find the minimal scarring more aesthetically acceptable. In 1991 Clayman et al. introduced the use of laparoscopic urological procedures for curative nephrectomy. Later, in 1995, Ratner et al. described laparoscopic nephrectomy, initially transperitoneal, for the purposes of transplantation. Also in 1995 Yang et al. published the retroperitoneal procedure, and thereafter a host of variations to these techniques have emerged, increasingly taking advantage of the significant technological advances in surgery. The currently used surgical techniques for kidney explantation from living donors are described below.

4.1 Open nephrectomy with classic lumbar sectioning

This technique is safe for the donor and for the kidney graft; and is used as the “gold standard” for the evaluation of new techniques. The live donor is placed in the lateral position, and the operating table is flexed at the level of the umbilicus to achieve complete flank exposure (Fig. 7). A 15 to 20 cm incision is made on the flank below the 12th rib, and a retroperitoneal dissection is performed. After ligation of the renal vessels the kidney can be removed and placed in cold preservation solution, so that back-table surgery can be performed. This procedure allows for a very short time of warm ischemia. The main disadvantages of this approach are related to the significant surgical wounding of the abdominal wall, which causes pain, prolonged hospital stays, poor aesthetics of the wound, and a slow convalescence.

4.2 Minimally invasive open donor nephrectomy

After the introduction of the laparoscopic donor nephrectomy, there was increasing interest in developing a minimally invasive modification of the classical open donor nephrectomy, and subsequently the muscle-sparing mini-incision donor nephrectomy was developed. This operation can be performed via an anterior, flank or posterior approach with an incision of approximately 7 cm. With the donor placed in a lateral decubitus position and the operation table maximally flexed, a horizontal skin incision is made anterior to the 11th rib toward the umbilicus. The fascia and muscles of the abdominal wall are carefully split between the muscle fibres avoiding harm to the intercostal nerves between the internal oblique and transverse abdominal muscles. The peritoneum is displaced medially and Gerota's fascia is opened on the lateral side of the kidney. The working space is limited,

therefore long instruments are used. The kidney is meticulously dissected and arterial and venous structures are identified. After dissection, the ureter is divided and sutured distally. The renal artery and vein are clamped and ligated. This approach provides the safety of the conventional open technique. This minimally invasive open donor nephrectomy results in reduced blood loss, hospital stay and incision-related complications compared with the classical open donor nephrectomy. There is only a marginal increase in operation time without compromising graft and recipient survival.

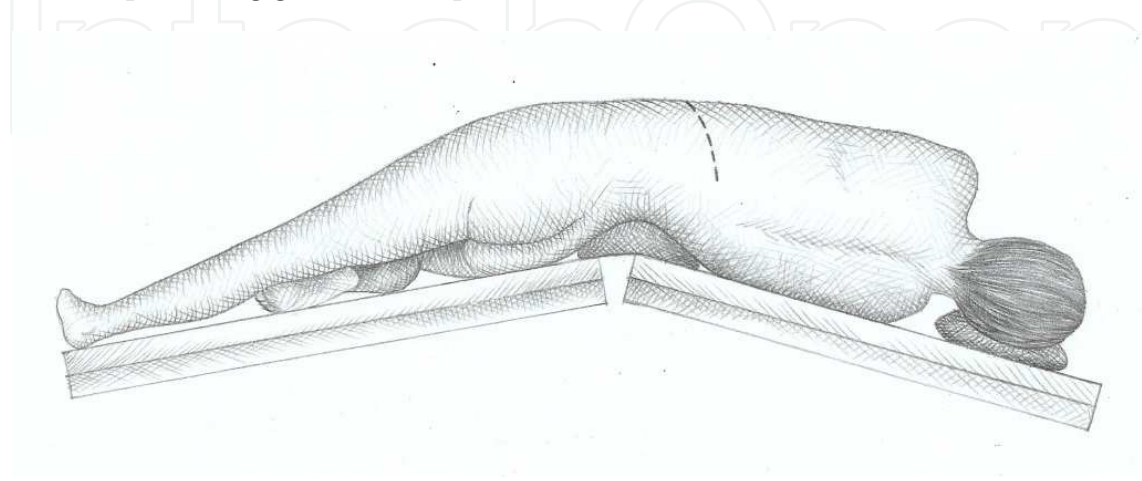


Fig. 7. Living donor position in the open nephrectomy.

4.3 Laparoscopic nephrectomy

With the donor in the lateral position and the operating table maximally flexed, 4 trocars are inserted in the following fashion (Fig. 8): 1) a 12 mm port at the umbilical level in the midclavicular line, 2) a 10 or 12 mm port at the umbilical level, 3) a 5 mm port between the umbilicus and the xiphoid process, and 4) a 12 mm port, 2 cm away from the symphysis pubis (the wound for this port will be incorporated into the Pfannenstiel incision, through which the kidney will be removed from the abdominal cavity). The abdomen is insufflated to 12 mmHg. The colon is mobilised and displaced medially. Gerota's fascia is opened and the renal vein and ureter, with sufficient periureteral tissue, are identified and dissected. The renal artery is identified. Branches of the adrenal, gonadal and lumbar veins are clipped and divided. The ureter is clipped distally and divided. Then, a low transverse suprapubic (Pfannenstiel) incision or midline incision is made creating a gate for extraction of the kidney. The renal artery and vein are divided using an endoscopic stapler or clips. The kidney is extracted through the extraction incision, and flushed with preservation fluid and stored on ice. Extraction of the kidney can be performed directly through the incision or by using a special endoscopic specimen retrieval bag.

Disadvantages of this technique include the steep and long learning curve, the risk of bowel injury from trocar insertion or during instrumentation, internal hernias or hernia through trocar sites and intestinal adhesions. Injuries to the lumbar vein, renal artery and aorta, pneumomediastinum, splenic injury, and adrenal/retroperitoneal haematomas have been reported.

Conversion rate from laparoscopic to open surgery is 1.8% (range 0 to 13.3%). Approximately half of the conversions to open surgery are due to bleeding or vascular

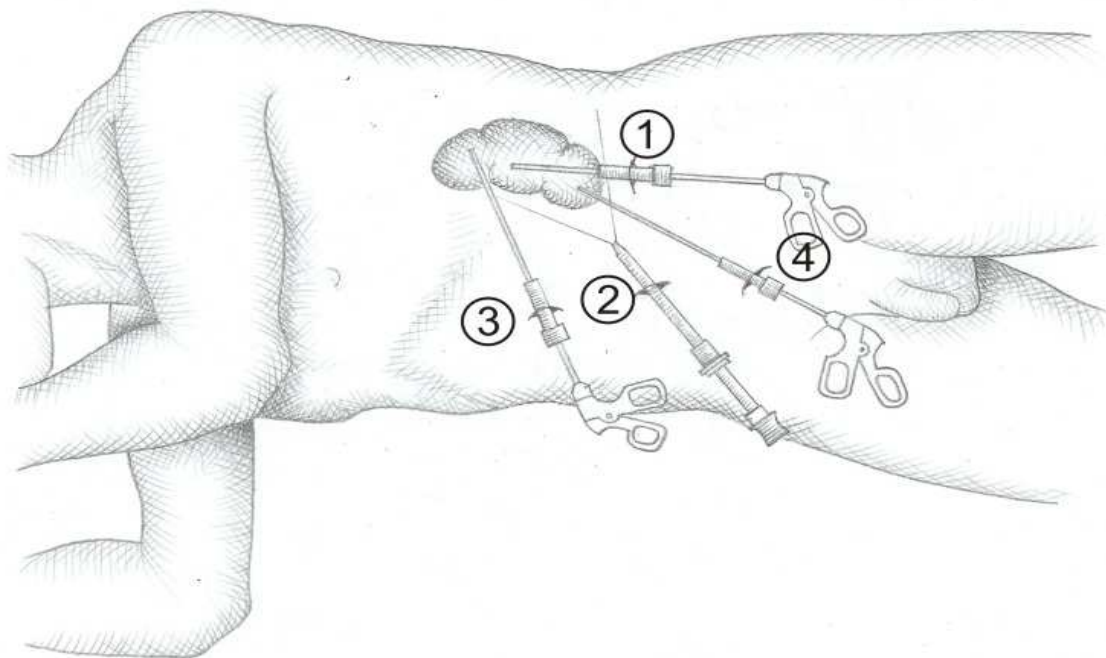


Fig. 8. Living donor position and placement of trocars for laparoscopic nephrectomy.

injury. The laparoscopic technique results in a shorter vascular pedicle when compared with the open donor nephrectomy. The warm ischaemia time and operating time for laparoscopic donor nephrectomy are substantially longer than those achieved in open donor nephrectomy.

4.4 Hand-assisted laparoscopic nephrectomy

This technique incorporates one port for the hand. Hand-assisted laparoscopic donor nephrectomy was first utilized in order to minimize the learning curve of the total laparoscopic donor nephrectomy (Fig. 9). In addition, the hand port provides increased safety to laparoscopic donor nephrectomy, because rapid control of eventual massive blood loss from major blood vessels is possible.

Different incisions for hand introduction have been described, such as a Pfannenstiel incision, a midline supraumbilical, periumbilical, or infraumbilical incision. The hand port can be used partly or totally during the operation.

The hand-assisted laparoscopic donor nephrectomy is done transperitoneally. After open dissection of the distal ureter and gonadal vein through a 7 to 8 cm Pfannenstiel incision the nondominant operator's hand is introduced through a hand port and two trocars are placed. The insufflation pressure is maximally 12 mmHg. The right or left colon is then mobilized. The renal vein and artery are identified and the kidney is mobilized from the surrounding tissue. After transecting the ureter distally, the renal artery is transected with metal clips or an endoscopic stapler which is used to transect the renal vein. The kidney is extracted through the Pfannenstiel incision and flushed and preserved with cold preservation fluid. Potential disadvantages are higher costs because of the hand port, a worse ergonomic

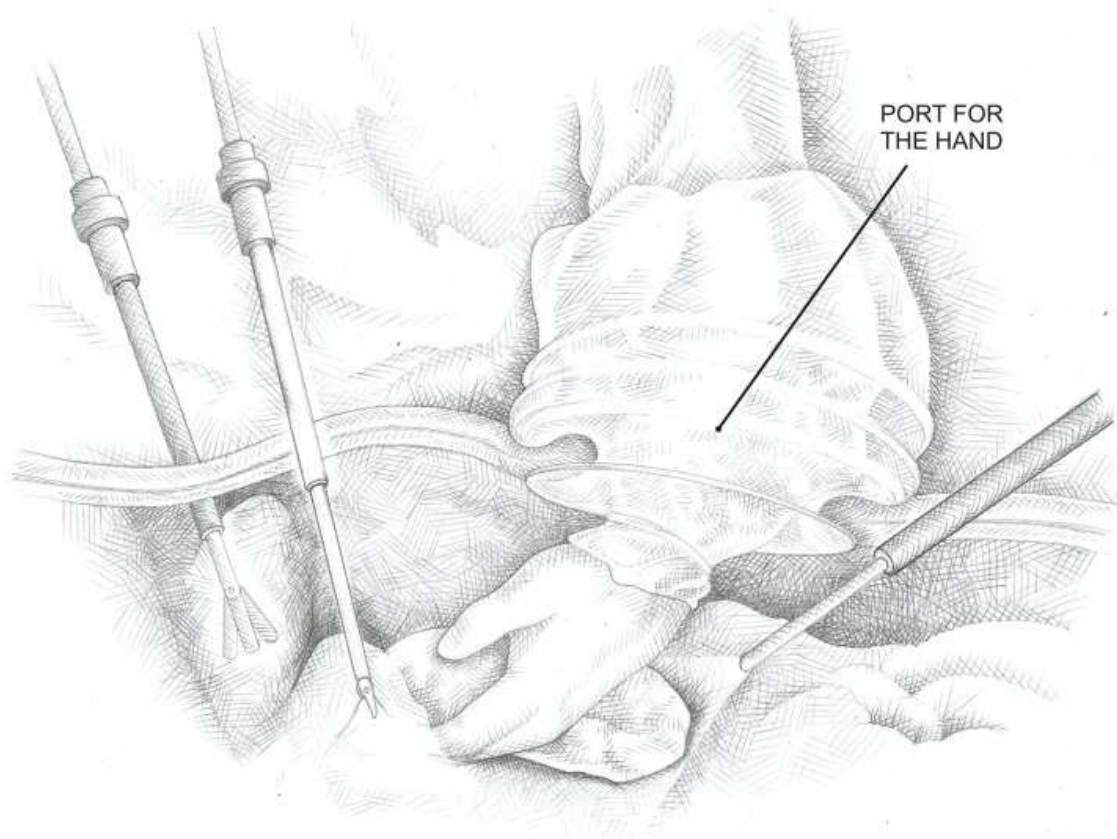


Fig. 9. Hand-assisted laparoscopic donor nephrectomy.

position for the surgeon during operation, a higher rate of wound infections and increased traumatic injury to the transplant as a consequence of manipulation. Conversion to open surgery is 2.97% in the hand-assisted group. The most common causes for conversion to open surgery include intraoperative haemorrhage or vascular injury, difficult kidney exposure or an obese donor, vascular staple malfunction, adhesions and loss of pneumoperitoneum. Potential advantages of hand-assisted laparoscopic donor nephrectomy over conventional laparoscopy include the ability to use tactile feedback, less kidney traction, rapid control of bleeding, fast kidney removal and shorter warm ischaemic periods.

4.5 Laparo-endoscopic single-site (LESS) donor nephrectomy

In this technique a single port is used (Fig. 10). There are two variants, the transperitoneal, which involves a 7 cm periumbilical incision, and the retroperitoneal, which utilizes a 6 cm incision in the groin, below the "bikini line". The instruments and lens for dissection and sectioning of renal hilar vessels and the ureter are introduced through the single port. The same port is later used to remove the kidney.

4.6 Robotic-assisted donor nephrectomy

Robotic-assisted donor nephrectomy can be performed with or without hand assistance. The Da Vinci robotic system has three components: a console, a control tower and the surgical

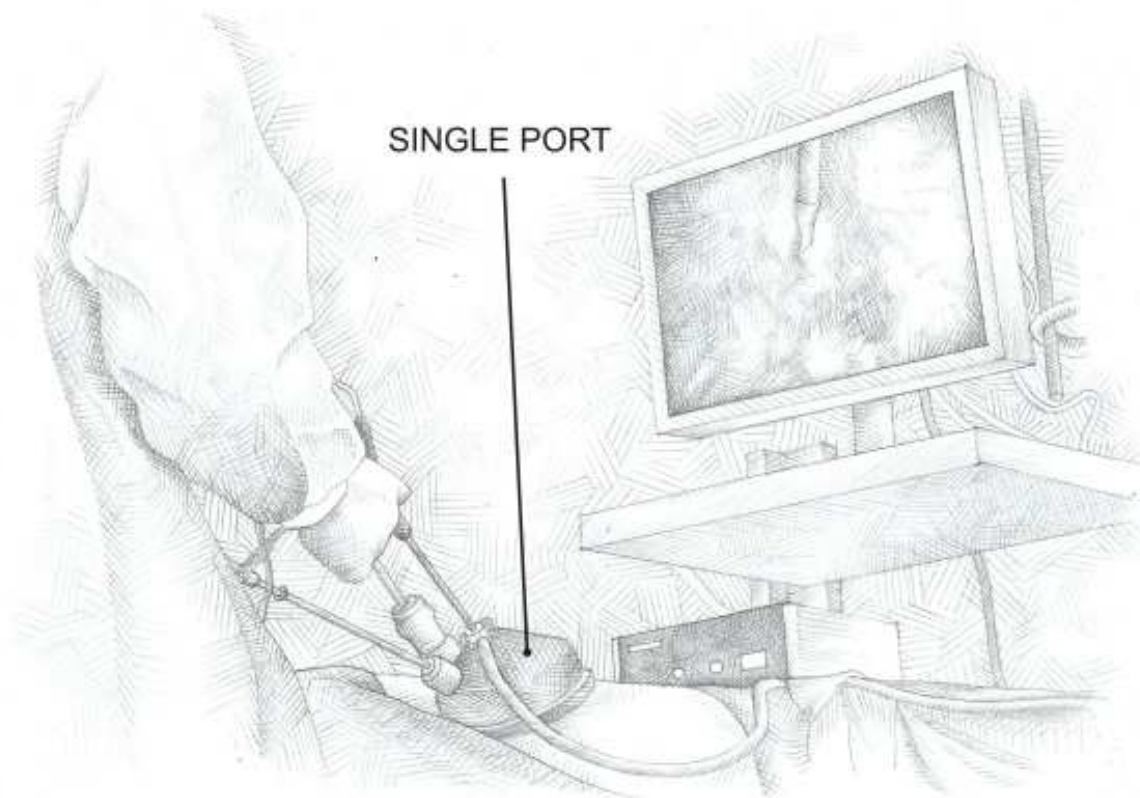


Fig. 10. Laparoendoscopic single-site (LESS) donor nephrectomy.

arm cart (Fig. 11). The donor nephrectomy is performed with the patient placed in a decubitus position. The operating table is flexed to maximize the exposure of the kidney during the procedure. Four trocars are placed in the left or right side of the abdomen to allow placement of three articulated robotic arms, the robotic camera, and the standard laparoscopic instrument used for retraction and dissection during the procedure. The left or right colon is mobilized medially to expose the kidney. Dissection of Gerota's fascia, perirenal tissue and vascular structures are performed as described above.

The advantage of this technique is that the movement of the articulated arm of the robot reproduces the action of the human wrist, which provides more mobility. A potential disadvantage is the costs.

4.7 Use of natural orifices

An innovative approach to spare the donors of some of the surgical consequences of the donation, and thus increase the pool of living donors, relies on avoiding sectioning of the abdominal wall altogether, by removing the kidney through the vagina. This technique has been used before for the purpose of treating a diseased kidney, and has subsequently been proposed as an option for explantation from living donors. This method represents, at this point, just a preliminary proposal, and several objections have been raised, but it is worth mentioning it as one more possible alternative.

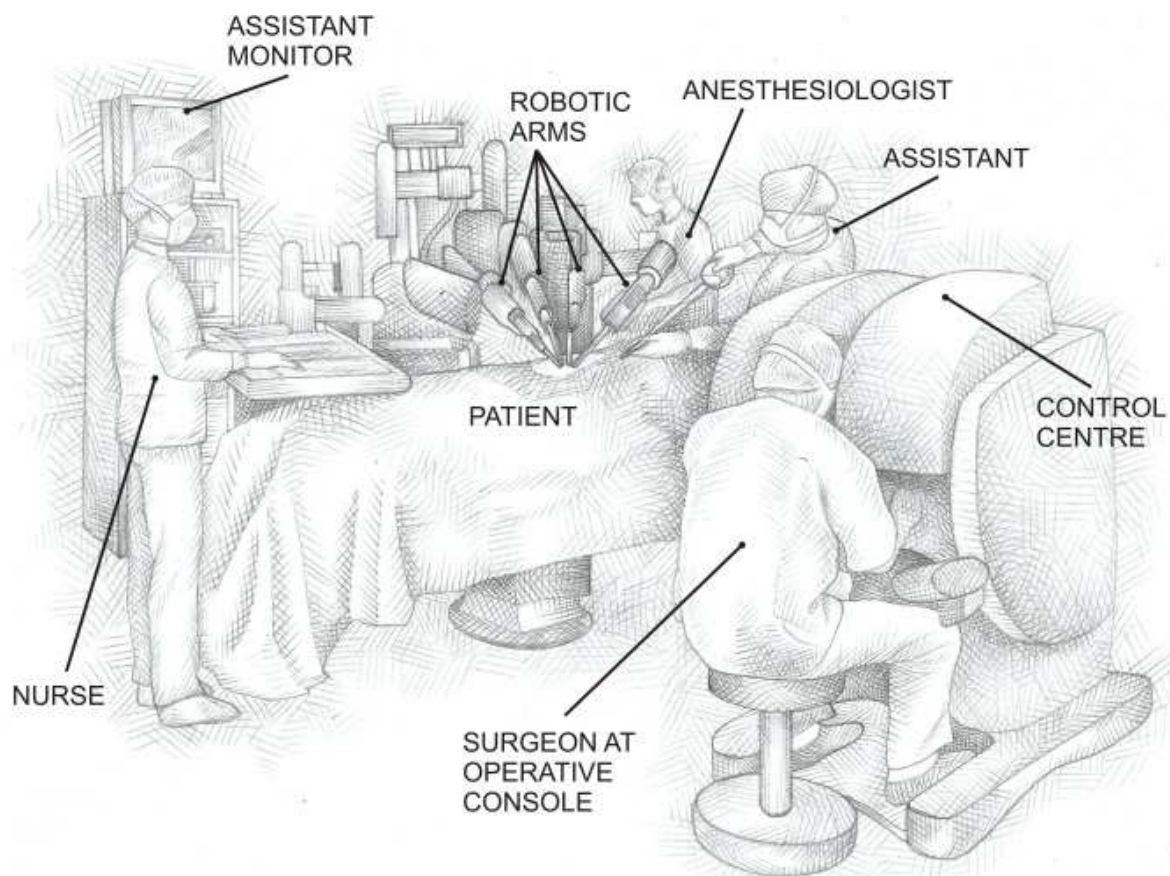


Fig. 11. Da Vinci robotic system.

5. Back-table preparation

The purpose of back-table on the explanted kidney is to examine the organ and prepare, under hypothermic conditions (4°C), the vascular ends for the subsequent vascular anastomosis. Perinephric fat is removed, without damaging the renal vessels or ureter. It is best not to dissect close to the hilum. The vessels that do not lead to or from the kidney are ligated. Arterial branches are completely dissected and, before being ligated, lack of flow to the kidney and ureter must be ensured. If the specimen was obtained from a cadaveric donor, it is placed such that its posterior face is visible. The aorta and the vena cava are opened (Fig. 12), the emergence of both renal vessels is identified, and through them, proper perfusion of the kidney with preservation solution is ensured. The emergence of both renal vessels is dissected and separated from the aorta, leaving behind an ample Carrel patch. There is a difference in the length of the vein and the artery in the right kidney (the vein being shorter). Many surgeons use the vena cava to extend the right renal vein, thus compensating for this difference in length, in order to prevent bending of the renal artery after transplantation. An alternative approach used by some surgeons is to cut the artery and perform an end-to-side anastomosis in the transplant, without a Carrel patch. The kidneys are subsequently packaged in sterile plastic bags (doubly bagged), with preservation solution, and then placed on ice for transport or preservation until the time of transplantation.

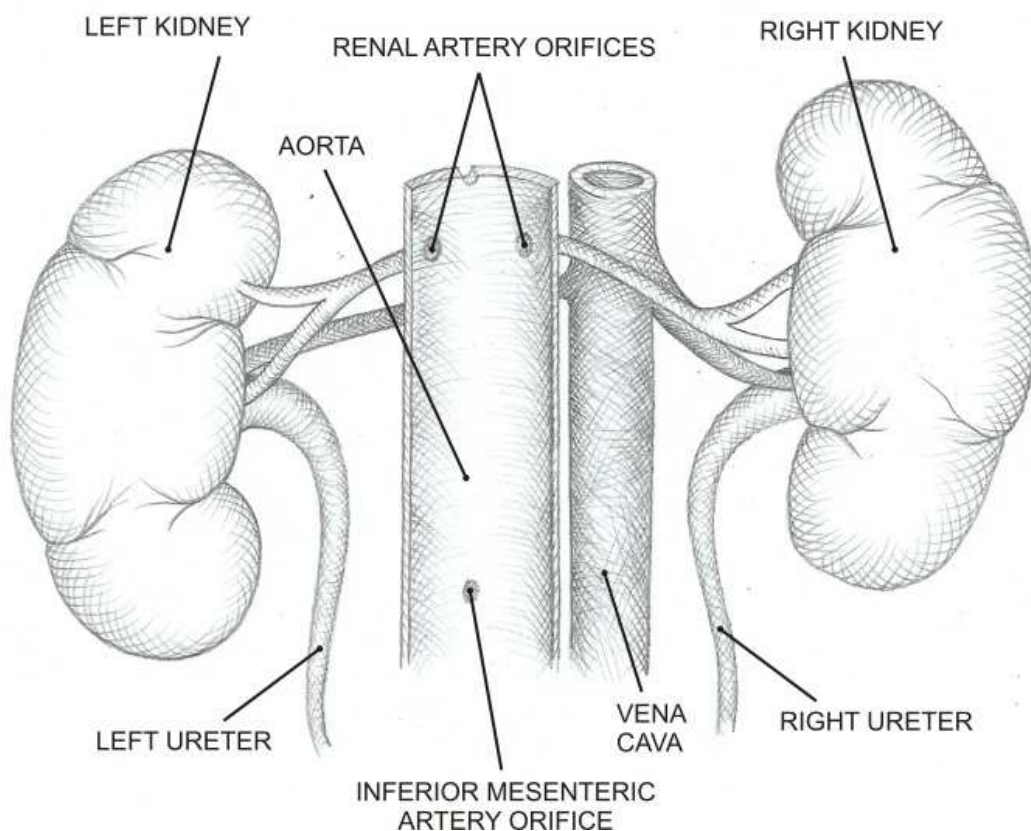


Fig. 12. Posterior view of the kidneys. The aorta is divided in the posterior midline.

6. Conclusions

There are multiple techniques and approaches to renal explantation, whose application will depend on, among other factors:

1. Type of donor.
2. Preferences and experience of the surgical team that will perform the explantation.

Some general guidelines to be considered in choosing the most appropriate renal explantation procedure are shown in Table 2.

Studies that have compared the evolution of transplanted organs and documented the outcomes of both the classical explantation approach and the total abdominal evisceration have found no differences between these two methods.

The kidney-only explantation procedure from cadaveric donor, and the back-table preparation are the two basic techniques that must be mastered by all renal transplant surgeons, because they are the basis on which all other renal explantation techniques for cadaveric donors are based.

Successful kidney explantation from non-heart-beating donors requires perfect organization and coordination between different disciplines, both within and outside the hospital unit, to ensure the quality of the process and therefore the usefulness of the organs procured for transplantation.

TYPE OF DONOR	EXPLANTATION TECHNIQUE	VARIANTS	COMMENTS
Cadaver with brain-death	Classic multi-organ extraction		Requires coordination with different surgical teams.
	Total abdominal evisceration		Indicated when time for extraction is limited (unstable donor)
	Kidney-only extraction		Used when explantation of other organs is not granted
Non-heart-beating donor	Perfusion <i>in situ</i>	With or without continuous hypothermic peritoneal perfusion	Requires a perfect organization and coordination between different disciplines inside and outside the hospital
	Body cooling with cardiopulmonary bypass		
Live donor	Open nephrectomy	Classic lumbar opening	The gold standard for evaluation of other kidney explantation techniques from live donors
		Muscle-sparing mini-incision donor nephrectomy	Reduced blood loss, hospital stay and incision-related complications
	Laparoscopy	Laparoscopic nephrectomy	Shortens hospitalization time, requires less analgesia, improves the aesthetics of the wound and ensures quick return to normal activities
		Hand-assisted laparoscopic nephrectomy	There is less kidney traction, better bleeding control, the kidney is removed faster, reduces the warm ischemia and surgical time
		Transperitoneal or retroperitoneal laparo-endoscopic single-site (LESS) donor nephrectomy	Technically complex procedures
		Robotic-assisted donor nephrectomy	High costs
		Use of natural orifices	It would only be applicable to female patients (vaginal route). Risk of infections

Table 2. Techniques for explantation of kidneys for transplantation.

In selecting techniques for kidney explantation from living donors, the following factors are to be considered: operating time, postoperative complications, postoperative pain, warm ischemic time, surgical aesthetics and prognosis of renal function in the recipient.

Any newly proposed approach or technique for renal explantation must:

1. Be technically feasible.
2. Prove to be as safe as the technique that it seeks to replace.
3. Be demonstrably innocuous to the graft and to the recipient.

7. Acknowledgment

We would like to thank Luis Felipe Alemón Soto and Juan José Lozano García for their help in the preparation of this chapter.

8. References

- Anaise, D.; Yland, MJ.; Waltzer, WC.; Frischer, Z.; Hurley, S.; Eychmuller, S. & Rapaport, FT. (1969). Flush Pressure requirements for optimal cadaveric donor Kidney preservation. *Transplantation Proceedings*, Vol.20, No.5, (October 1988), pp.891-894, ISSN 0041-1337.
- Anaya, R.; Rodríguez, F. & Toledo, L. (1999). Preservación de órganos, In : Introducción al trasplante de órganos y tejidos, Cuervas-Mons V & del Castillo-Olivares JL (Ed.), pp. 107-134, Arán Ediciones S.A., ISBN 84-86725-49-6, Madrid, España
- Anaya, F. (1980). Innovaciones tecnológicas en la donación en asistolia. *Nefrología*, Vol.16, No.2, (February 1996), pp. 96-106, ISSN 0211-6995
- Abecassis, M. & Corry, R. (1965). An update on pancreas transplantation. *Advances in surgery*, Vol. 26, No. 1 (September 1993), pp. 163-188, ISSN 0065-3411
- Allaf, M.; Singer, A.; Shen, W.; Green, I.; Womer, K.; Segev, D. & Montgomery, R. (2000). Laparoscopic live donor nephrectomy with vaginal extraction. *American Journal of Transplantation*, Vol.10, No.6, (June 2010), pp. 1473-1477, ISSN 1600-6143
- Booster, M.; Wijnen, R.; Ming, Y.; Vroemen, J. & Kootstra, G. (1969). In situ perfusion of kidneys from non-heart beating donors: The Maastricht protocol. *Transplantation Proceedings*, Vol.25, (February 1993) pp.1503-1504, ISSN 0041-1337
- Clayman, R.; Kavoussi, L.; Soper, N.; Dierks, S.; Merety, K.; Darcy, M.; Long, S.; Roemer, F.; Pingleton E. & Thomson, P. (1985). Laparoscopic nephrectomy. *New English Journal of Medicine*, Vol.324, No.19, (May 1991), pp. 1370-1371, ISSN 0022-5347
- Chin, E.; Hazzan, D.; Edye, M.; Wisnivesky, J.; Herron, D.; Ames, S.; Palese, M.; Pomp, A.; Gagner, M. & Bromberg, J. (1991). The first decade of a laparoscopic donor nephrectomy program: Effect of surgeon and institution experience with 512 cases from 1996 to 2006. *Journal of American College of Surgeons*, Vol.209, No.1, (July 2009), pp. 106-113, ISSN 1072-7515
- Dols, L.; Kok, N.; Terkivatan, T.; Tran, T.; d'Ancona, F.; Langenhuijsen, J.; Zur, I.; Alwayn, I.; Hendriks, M.; Dooper, I.; Weimar, W. & Ijzermans, J. (2000). Hand-assisted retroperitoneoscopic versus standar laparoscopic donor nephrectomy: Harp-trial. *BMC Surgery*, Vol.10, No. 1, (March 2010), pp. 11, ISSN 1471-2482
- Dols, L.; Ijzermans, J.; Wentink, N.; Tran, T.; Zuidema, W.; Dooper, I.; Weimar, W. & Kok, N. (2000). Long-Term Follow-up of a Randomized Trial Comparing Laparoscopic and Mini-Incision Open Live Donor Nephrectomy. *American Journal of Transplantation*, Vol.10, No.11, (November 2010), pp. 2481-2487, ISSN 1600-6143
- Garcia-Rinaldi, R.; Lefrak, E.; Defore, W.; Feldman, L.; Noon G.; Jachimczyk, J. & DeBakey, M. (1985) In situ preservation of cadaver Kidneys for transplantation: Laboratory observations and clinical application. *Annals of Surgery*, Vol.182, No.5, (November 1975), pp.576-584, ISSN 1528-1140
- Gjertsen, H.; Sandberg, A.; Wadstrom, J.; Tyden, G. & Ericzon, B. (1969). Introduction of hand assisted retroperitoneoscopic living donor nephrectomy at Karolinska


- University Hospital Huddinge. *Transplantation Proceedings*, Vol.38, No.8, (October 2006), pp. 2644-2645, ISSN 0041-1345
- González, M.; García, J.; García C. et al. Trasplante de riñón procedente de donantes en asistolia. *Actas Urológicas Espanolas*, Vol.18, (1994), pp. 433-436, ISSN 1699-7980
- Halgrimson, W.; Campsen, J.; Mandell, M.; Kelly, M.; Kam, I. & Zimmerman, M. (1995). Donor complications following laparoscopic compared to hand-assisted living donor nephrectomy: An analysis of the literature. *Urology*, Vol.70, No.6, (January 2007), pp. 1060-1063, ISSN 0090-4295
- Horgan, S.; Vanuno, D.; Sileri, P.; Cicalese, L. & Benedetti, E. (1969). Robotic-assisted laparoscopic donor nephrectomy for kidney transplantation. *Transplantation*, Vol.73, No.9, (May 2002), pp. 1474-1479, ISSN 0041-1337
- Ho, Y.; Won, H.; Koon, R.; Sang, H.; Young, Ch.; Woong, Han. & Won, Chang. (1960). Laparoendoscopic Single-Site Nephrectomy Using a Modified Umbilical Incision and a Home-Made Transumbilical Port. *Yonsei Medicine Journal*, Vol.52, No.2, (March 2011), pp.307-313, ISSN 0513-5796
- Koyama, I.; Hoshino, T.; Nagashima, N.; Adachi, H.; Ueda, K. & Omoto, R. (1969). A new approach to kidney procurement from non heart beating donors: core cooling on cardiopulmonary bypass. *Transplantation Proceedings*, Vol.21, No.1, (February 1989), pp.1203-1205, ISSN 0041-1337
- Leventhal, J.; Kocak, B.; Slavalaggio, P.; Koffron, A.; Baker, T.; Kaufman, D.; Fryer, J.; Abecassis, M. & Stuart, F. (1945). Laparoscopic donor nephrectomy 1997 to 2003: lessons learned with 500 cases at a single institution. *Surgery*, Vol. 136, No. 4, (October 2004), pp. 881-890, ISSN 0039-6060
- Matas, A.; Bartlett, S.; Leichtman, A. & Delmonico, F. (2000). Morbidity and mortality after living kidney donation, 1999-2001: Survey of United States transplant centers. *American Journal of Transplantation*, Vol.3, No.7, (July 2003), pp. 830-834, ISSN 1600-6143
- Mahdavi, P.; Bowman, R.; Tenggardjaja, C.; Jellison, F.; Ebrahimi, K. & Baldwin, D. (1969). A Novel Bridging Hand-Assisted LESS Donor Nephrectomy Technique. *Transplantation*, Vol.90, No.7, (October 2010), pp. 802-804, ISSN 0041-1337
- Minnee, R.; Bemelman, W.; Donselaar, K.; Booij, J.; ter Meulen, S.; ten Berge, I.; Legemate, D.; Bemelman, F. & Idu, M. (1969). Risk Factors for Delayed Graft Function After Hand-Assisted Laparoscopic Donor Nephrectomy. *Transplantation Proceedings*, Vol.42, No.7, (July 2010), pp. 2422-2426, ISSN 0041-1345.
- Nicholson, M.; Kaushik, M.; Lewis, G.; Brook, N.; Bagul, A.; Kay, M.; Harper, S.; Elwell, R. ; Veitch, P. & Hosgood, SA. (1969). Health-Related Quality of Life After Living Donor Nephrectomy: A Randomized Controlled Trial of Laparoscopic Versus Open Nephrectomy. *Transplantation*, Vol.91, No.4, (February 2011) pp. 457-461, ISSN 0041-1337
- Nanidis, T.; Antcliffe, D.; Kokkinos, C.; Borysiewicz, C.; Darzi, A.; Tekkis, P. & Papalois, V. (1985). Laparoscopic versus open live donor nephrectomy in renal transplantation: a meta-analysis. *Annals of Surgery*, Vol.247, No.1, (January 2008), pp. 58-70, ISSN 1528-1140
- Nakazato, P.; Concepcion, W.; Bry, Limm, W.; Tokunaga, Y.; Itasaka, H.; Feduska, N.; Esquivel, C. & Collins, G. (1945). Total abdominal evisceration: An en bloc

- technique for abdominal organ harvesting. *Surgery*, Vol.111, No.1, (January 1992), pp. 37-47, ISSN 0039-6060
- Nicholson, M.; Elwell, R.; Kaushik, M.; Bagul, A. & Hosgood, S. (1969). Health-related quality of life after living donor nephrectomy: a randomized controlled trial of laparoscopic versus open nephrectomy. *Transplantation*, Vol.91, No.4, (February 2011) pp. 457-461, ISSN 0041-1337
- Rane, A.; Ahmed, S.; Kommu, S.; Anderson, C. & Rimington, P. (1945). Singleport "scarless" laparoscopic nephrectomies: The United Kingdom experience. *British Association of Urological Surgeons*, Vol.104, No.2, (July 2009), pp. 230, ISSN 1464-410X
- Ratner, L.; Ciseck, L.; Moore, R.; Cigarroa, F.; Kaufman, H. & Kavoussi, L. (1969). Laparoscopic live donor nephrectomy. *Transplantation*, Vol.60, No.9, (November 1995), pp. 1047-1049, ISSN 0041-1337
- Ratner, L. & Pescovitz, M. (2000). Giving birth to an operation: laparoscopic live donor nephrectomy with vaginal extraction. Is this misconceived?. *American Journal of Transplantation*, Vol.10, No.6, (June 2010), pp. 1347-1348, ISSN 1600-6143
- Renoult, E.; Hubert, J.; Ladrière, M.; Billaut, N.; Mourey, E.; Feuillu, B. & Kessler, M. (1909). Robot-assisted laparoscopic and open live-donor nephrectomy: a comparison of donor morbidity and early renal allograft outcomes. *Nephrol Dial Transplant*, Vol.21, No.2, (February 2006), pp. 472-477, ISSN 1460-2385
- Starzl, T.; Hakala, T.; Shaw, B.; Hardesty, R.; Roshental, T.; Griffith, B.; Iwatsuki, S. & Bahnson, H. (1909). A flexible procedure for multiple cadaveric organ procurement. *Surgery, Gynecology & Obstetrics*, Vol.158, No.3, (March 1984), pp. 223-230, ISSN 0039-6087
- Starzl, T.; Miller, C.; Broznick, B. & Makowka, L. (1909). An improved technique for multiple organ harvesting. *Surgery, Gynecology & Obstetrics*, Vol.165, No.4, (October 1987), pp. 343-348, ISSN 0039-6087
- Starzl, T.; Todo, S.; Tzakis, A.; Alessiani, M.; Casavilla, A.; Abu, K. & Fung, J. (1909). The many faces of multivisceral transplantation. *Surgery, Gynecology & Obstetrics*, Vol.172, No.5, (May 1991), pp. 335-344, ISSN 0039-6087
- Szostek, M.; Danielewicz, R.; Lagiewska, B. Pacholczyk, M.; Rybicki, Z.; Michalak, G.; Adadynski, L.; Walaszewski, J. & Rowinski, W. (1969). Successful transplantation of kidneys harvested from cadaver donors at 71 to 259 minutes following cardiac arrest. *Transplantation Proceedings*, Vol.27, No.5, (October 1995), pp.2901-2902, ISSN 0041-1345
- Sundqvist, P.; Feuk, U.; Haggman, M.; Persson, A.; Stridsberg, M. & Wadstrom, J. (1969). Hand-assisted retroperitoneoscopic live donor nephrectomy in comparison to open and laparoscopic procedures: a prospective study on donor morbidity and kidney function. *Transplantation*, Vol.78, No.1, (July 2004), pp. 147-153, ISSN 0041-1337
- Troppmann, C.; Daily, M.; McVicar, J.; Troppmann, K. & Perez, R. (1969). The transition from laparoscopic to retroperitoneoscopic live donor nephrectomy: A matched pair pilot study. *Transplantation*, Vol.89, No.7, (April 2010), pp. 858-863, ISSN 0041-1337
- Van der Merwe, A.; Bachmann, A. & Heyn, C. (2005). Retroperitoneal LESS Donor Nephrectomy. *International Brazilian Journal of Urology*, Vol.36, No.5, (October 2010), pp. 602-606, ISSN 1677-6119

- Yang, S.; Park, D.; Lee, D.; Lee, J. & Park, K. (1917) Retroperitoneal endoscopic live donor nephrectomy: report of 3 cases. *Journal of Urology*, Vol.153, No.6, (June 1995) pp.1884-1886, ISSN 0022-5347
- Wadstrom, J.; Lindstrom, P. & Engstrom, B.(1969). Hand-assisted retroperitoneoscopic living donor nephrectomy superior to laparoscopic nephrectomy. *Transplant Proceedings*, Vol.35, No.2, (March 2003), pp. 782-783, ISSN 0041-1345

IntechOpen

IntechOpen



Renal Transplantation - Updates and Advances

Edited by Dr. Layron Long

ISBN 978-953-51-0173-4

Hard cover, 234 pages

Publisher InTech

Published online 29, February, 2012

Published in print edition February, 2012

This book presents a nice international compilation of scholarly papers and chapters which address the latest advances in renal transplant surgery. These works cover a variety of topics; the last advance and success of renal transplant science: biochemistry, immunology, molecular genetics, pharmacology - pharmacogenetics, pediatric transplant and a few rare uropathies that warrant organ replacement.

How to reference

In order to correctly reference this scholarly work, feel free to copy and paste the following:

Marco Antonio Ayala- García, Éctor Jaime Ramírez-Barba, Joel Máximo Soel Encalada, Beatriz González Yebra (2012). Renal Explantation Techniques, Renal Transplantation - Updates and Advances, Dr. Layron Long (Ed.), ISBN: 978-953-51-0173-4, InTech, Available from: <http://www.intechopen.com/books/renal-transplantation-updates-and-advances/renal-explantation-techniques>

INTECH
open science | open minds

InTech Europe

University Campus STeP Ri
Slavka Krautzeka 83/A
51000 Rijeka, Croatia
Phone: +385 (51) 770 447
Fax: +385 (51) 686 166
www.intechopen.com

InTech China

Unit 405, Office Block, Hotel Equatorial Shanghai
No.65, Yan An Road (West), Shanghai, 200040, China
中国上海市延安西路65号上海国际贵都大饭店办公楼405单元
Phone: +86-21-62489820
Fax: +86-21-62489821

© 2012 The Author(s). Licensee IntechOpen. This is an open access article distributed under the terms of the [Creative Commons Attribution 3.0 License](https://creativecommons.org/licenses/by/3.0/), which permits unrestricted use, distribution, and reproduction in any medium, provided the original work is properly cited.

IntechOpen

IntechOpen