

# We are IntechOpen, the world's leading publisher of Open Access books Built by scientists, for scientists

6,900

Open access books available

186,000

International authors and editors

200M

Downloads

Our authors are among the

154

Countries delivered to

TOP 1%

most cited scientists

12.2%

Contributors from top 500 universities



WEB OF SCIENCE™

Selection of our books indexed in the Book Citation Index  
in Web of Science™ Core Collection (BKCI)

Interested in publishing with us?  
Contact [book.department@intechopen.com](mailto:book.department@intechopen.com)

Numbers displayed above are based on latest data collected.  
For more information visit [www.intechopen.com](http://www.intechopen.com)



# Role of Endoscopy in Management of Hydrocephalus

Nasser M. F. El-Ghandour

*Department of Neurosurgery, Faculty of Medicine,  
Cairo University  
Egypt*

## 1. Introduction

Management of hydrocephalus is the most beneficial indication for endoscopy. To cure hydrocephalus and thereby render an individual shunt independent is a great achievement. The standard and the most commonly performed endoscopic procedure is endoscopic third ventriculostomy. However, the field of neuroendoscopy is prepared to extend itself beyond just the ventriculostomy procedure. The neuroendoscope plays other important roles in the management of hydrocephalus.

Although the literature is focusing mainly on the role of endoscopic third ventriculostomy in the treatment of aqueduct stenosis, the indications for endocopy continues to increase rapidly. With increasing experience, and improved endoscopic instruments, another important role of endoscopy has been emerged in approaching intraventricular tumors which may be completely removed without microsurgical brain dissection (Gaab & Schroeder, 1998). In addition to tumor removal it is usually possible to restore obstructed cerebrospinal fluid pathways using the same approach by performing ventriculostomies, septostomies or stent implantation (Oka et al., 1994).

The goal of this chapter is to present the role of endoscopy in the management of hydrocephalus. The following chapter gives a comprehensive review about the indications, outcome, complications, and advantages of endoscopy. Various procedures which can be performed endoscopically for the management of hydrocephalus will be discussed.

## 2. Historical perspectives

Endoscopy was introduced in the neurosurgical speciality at the beginning of this century. In 1910, L'Espinasse used the cystoscope to perform the first registered endoscopic procedure. He explored the lateral ventricle and coagulated the choroid plexus in 2 infants with hydrocephalus (Walker, 2001). In 1918, Walter Dandy started his work on endoscopy using a nasal speculum to inspect the ventricles. He performed choroid plexectomy under direct visualization for the treatment of hydrocephalus. The light source was a head mirror and transillumination was used through the thin cortical mantle of hydrocephalic patient. Four of his five patients did not survive this operation probably due to massive intraventricular bleeding (Dandy 1918).

In 1923, Jason Mixter reported the first endoscopic third ventriculostomy procedure (Mixter 1923). Although it appeared to be a successful procedure and communication was documented by dye studies, there was no available long-term follow-up. The procedure of endoscopic third ventriculostomy did not become widely popular, as surgeons chose instead to perform open procedures via subfrontal or subtemporal craniotomies. In 1935, Scarff described his initial results after using a novel endoscope equipped with a mobile cauterizing electrode, an irrigation system that prevented collapse of the ventricle, and a movable operating tip which was used to perforate the floor of the third ventricle (Scarff 1935). In 1947, McNickle described a percutaneous method of performing third ventriculostomy in patients of both obstructive and communicating hydrocephalus, he reported a success rate that was superior to Dandy's open approach (McNickle 1947).

In 1952, Nulsen and Spitz reported the first treatment of hydrocephalus by using ventricular shunt placement, beginning the era of ventricular cerebrospinal fluid shunting and the end of initial era of neuroendoscopy (Nulsen & Spitz 1952). The birth of ventricular shunting in 1952 pushed endoscopy further into the backward. Despite the numerous reports that demonstrated the potential utility of neuroendoscopy, the field never gained popularity in general neurosurgical practice. This was attributed to the poor magnification and illumination at that time which made neuroendoscopy difficult and unreliable. Although the development of ventricular shunting was considered to be a landmark in the treatment of hydrocephalus, it brought with it a high incidence of complications such as shunt malfunction, infection, migration, and overdrainage. Recognition of the complications associated with ventriculoperitoneal and ventriculoatrial shunting stimulated neurosurgeons to investigate new treatment options and to reuse old ones that existed before ventricular shunts began to be used.

Technical advances in the development of endoscopic lenses and instruments such as bipolar diathermy, irrigation and laser, have led neurosurgeons to begin again to consider the field of neuroendoscopy. With the improved imaging capability of the endoscope, the interest of endoscopic third ventriculostomy for treatment of obstructive hydrocephalus was renewed. Currently endoscopic third ventriculostomy is the primary procedure used to treat obstructive hydrocephalus caused by benign aqueductal stenosis or compressive periaqueductal mass lesions. The endoscopic third ventriculostomy procedure has recently been reported to be superior to ventricular shunt placement for hydrocephalus caused by pineal region tumors (Yamini et al., 2004), tectal gliomas (Li et al., 2005), and posterior fossa tumors (El-Ghandour, 2011). This procedure was subsequently proposed as the primary surgical approach for the treatment of hydrocephalus in these cases.

### **3. Indications of endoscopy**

#### **3.1 Aqueductal stenosis**

In noncommunicating hydrocephalus, there is an obstruction to the passage of cerebrospinal fluid from the ventricular system into the subarachnoid space. The classic example is aqueductal stenosis, in which there is enlargement of the lateral and third ventricles without enlargement of the fourth ventricle. If an opening is created in the third ventricle proximal to the site of obstruction (endoscopic third ventriculostomy), then the cerebrospinal fluid can escape into the subarachnoid space and bypass the obstruction. If there is no co-existing

blockage in the subarachnoid space, cerebrospinal fluid can be absorbed into the venous system and the hydrocephalus can be treated without using a ventriculoperitoneal shunt.

The ideal candidates for endoscopic third ventriculostomy are those patients who have developed aqueductal stenosis or occlusion and became symptomatic later on in life. These patients are more likely to have a functional communication between the subarachnoid space and venous system, as they were presumably able to absorb their cerebrospinal fluid before the aqueduct became obstructed. There is no simple noninvasive study to predict which patients can benefit from endoscopic third ventriculostomy. We need a study which can demonstrate both the stenosis or obstruction of aqueduct as well as efficient passage of cerebrospinal fluid from the subarachnoid space into the venous system.

Currently, the best available imaging modality is the MR imaging, which delineates the anatomy of the aqueduct of Sylvius, the size of the third ventricle, and location of the basilar artery. Moreover, MR imaging can be used to obtain a noninvasive cerebrospinal fluid flow study, using a two-dimensional phase contrast technique which is gated to the cardiac cycle. Such a study (flow gated MR imaging) can be used preoperatively to confirm the diagnosis of aqueductal stenosis, and postoperatively to confirm patency of the third ventriculostomy without the need for intraventricular injection of a contrast agent.

### **3.2 Fourth ventricular outlet obstruction**

Hydrocephalus resulting from fourth ventricular outlet obstruction is commonly observed in infants and young children, due to either infection or intraventricular hemorrhage. Both conditions cause an inflammatory response with arachnoiditis and scar tissue formation, leading to secondary obstruction of the foramina of Magendie and Luschka. Because the associated hydrocephalus is obstructive in nature due to obstruction occurring at the level of the foramen magnum, it is amenable to cerebrospinal fluid diversion by endoscopic third ventriculostomy. However, the underlying pathological process that results in scarring of the subarachnoid space plays a considerable role in determining the overall outcome of the procedure. The extent of adhesions in the basal cisterns is directly correlated with failure of endoscopic third ventriculostomy.

For this reason, some authors advocate endoscopic transaqueductal exploration of the fourth ventricular outlet foramina (Longatti et al., 2006; Mohanty et al., 2008). A thin transparent membrane is sometimes found stretched across the foramen of Magendie and obstructing the flow of cerebrospinal fluid, and membrane fenestration is performed. Nevertheless, diagnostic accuracy is of paramount importance, particularly in differentiating this condition from the noninflammatory obstruction of the outlet of the fourth ventricle which is often seen with other neurological conditions, such as Chiari malformation, basilar invagination, and other craniocervical junction anomalies. In these cases, the obstruction of fourth ventricular outlet is due to crowding in the region of the foramen magnum, and no membranous obstruction has been encountered in direct exploration.

### **3.3 Complex hydrocephalus**

#### **3.3.1 Uniloculated hydrocephalus**

Hydrocephalus may occur in association with loculated collection of cerebrospinal fluid. The lateral ventricle may become trapped by obstruction at the foramina of Monro which

results in an isolated lateral ventricle. Arachnoid and ependymal cysts as well as congenital malformations may contribute to ventricular isolation. When the lateral ventricle is trapped by scar at the foramen of Monro, the endoscope can be used to unblock the ventricle by fenestrating the septum pellucidum (septum pellucidotomy). The septum contains relatively avascular tissue, and a generous septostomy can be performed using a fiberoptic laser, taking care to avoid injury of the fornices or the corpus callosum (Cohen, 1996).

Isolated fourth ventricle is a rare complication observed in patients with ventricular shunts placed to treat hydrocephalus that developed after inflammatory disease such as infection or hemorrhage. This unusual condition arises when two events occur at the same time: collapse of the aqueduct following reduction of transtentorial pressure gradient, and blockage of cerebrospinal fluid at the outlet of the fourth ventricle or at the basal cisterns (Oi & Matsumoto, 1986). In such cases, shunt placement in the lateral ventricle decreases supratentorial pressure and also reduces the pressure keeping the aqueduct open, which occasionally leads to collapse of the aqueduct of Sylvius. Meanwhile, cerebrospinal fluid continues to be produced in the fourth ventricle and make its marked enlargement. Surgical management of isolated fourth ventricle is problematic, and sometimes results in patients undergoing multiple surgeries until the situation is well controlled (Shin et al., 2000).

### 3.3.2 Multiloculated hydrocephalus

The ventricular system may become trabeculated and encysted following germinal matrix hemorrhage or infection. The ventricular system is converted into multiple cavities or loculations which are isolated from each other by multiple membranes. When a loculated collection of cerebrospinal fluid occurs in association with hydrocephalus, conventional treatment often entails inserting shunt catheters into more than one compartment. Endoscopic fenestration techniques can be used to simplify the treatment of loculated hydrocephalus, permitting the use of a single shunt to drain multiple compartments and sometimes avoiding or eliminating the need for shunt (El-Ghandour, 2006, 2008). Contrast CT ventriculography is useful to confirm noncommunication of the compartments preoperatively, and the study can be repeated postoperatively to confirm patency of the fenestrations.

### 3.4 Normal pressure hydrocephalus

The use of endoscopic third ventriculostomy for treating normal pressure hydrocephalus was first suggested in 1999 by Mitchel and Mathew in a series of four patients (Mitchel & Mathew, 1999). One year later, Meier et al reported a series of 48 patients with idiopathic normal pressure hydrocephalus (Meire et al., 2000) treated by insertion of a ventriculoperitoneal shunt (37 cases) or endoscopic third ventriculostomy (11 cases). It has been reported, that patients with a pathologically increased resistance to cerebrospinal fluid outflow in the lumbar infusion test should be treated by endoscopic third ventriculostomy. Nevertheless, Fiorindi et al 2004, reported a low success rate (21%) of endoscopic third ventriculostomy in a series of 14 patients (Fiorindi et al., 2004).

In 2008, Gangemi et al reported the largest group of patients with idiopathic normal pressure hydrocephalus (110 patients), treated in four Italian neurosurgical centers which routinely use endoscopic third ventriculostomy for treating this form of hydrocephalus.



Postoperative clinical improvement was encountered in 76 patients (69.1%) among the median follow-up duration of 6.5 years (Gangemi et al., 2008). It is not exactly well known why endoscopic third ventriculostomy results in clinical improvement in patients with idiopathic normal pressure hydrocephalus who do not have obstruction of the cerebrospinal fluid pathways and show normal or slightly increased cerebrospinal fluid pressure.

It was always believed that chronic hydrocephalus results from cerebrospinal fluid malabsorption owing to hindrance of cerebrospinal fluid circulation. Nevertheless, the modern theory considers hydrocephalus as ventricular enlargement caused by increased regional force directed from the ventricle toward the subarachnoid space, defined as transmantle pulsatile stress, which results in decreased compliance of the brain tissue and ventricular enlargement. Weakening and enlargement of the ventricles may also result from loss of elasticity of the ventricular walls owing to periventricular ischemic lesions (Bradley et al., 1991). According to this theory, chronic hydrocephalus is not caused by decreased cerebrospinal fluid absorption, but rather by decreased intracranial compliance.

Endoscopic third ventriculostomy increases the systolic outflow from the ventricles and decreases the intraventricular pulse pressure, thus decreasing the width of the ventricles. This would dilate the compressed vessels and increase intracranial compliance. The dilated capillaries will facilitate increased blood flow and cerebrospinal fluid absorption (Greitz, 2004). An irreversible loss of brain compliance may explain the failure of endoscopic third ventriculostomy in patients where clinical history is too long and who experienced clinical onset of dementia. In these cases, the preoperative brain involvement is likely more important (Gangemi et al., 2008).

### **3.5 Intraventricular tumors**

#### **3.5.1 Lateral ventricular tumors**

The majority of lateral ventricular tumors are benign or low grade lesions (e.g. gliomas). Tumors of the frontal horn may cause blockage of the foramen of Monro, which results in unilateral hydrocephalus. The endoscope can be used to take biopsy or remove the lesion and restore obstructed cerebrospinal fluid pathways. If restoration of the foramen of Monro is not achieved after tumor removal, the ventricle can be unblocked by fenestration of the septum pellucidum (septum pellucidotomy). In case of very small ventricle, the endoscopic method might not be possible, since there is inadequately working space for manipulation of the instruments. The tumor must be removed microsurgically via transcortical or transcallosal approach.

#### **3.5.2 Third ventricular tumors**

Many tumors may occur within the third ventricle such as colloid cysts, astrocytomas, and ependymomas, and in the pineal region, such as germinomas, pineocytomas, pineoblastomas. Tumors located in the third ventricle are the most difficult to expose and remove. Such tumors usually obstruct one or both foramina of Monro and result in obstructive hydrocephalus. Accordingly, the aim of endoscopic surgery is reconstitution of cerebrospinal fluid pathways with prevention of recurrent obstruction, and establishment of a histological diagnosis. Neuronavigation is especially helpful for patients without ventriculomegaly and for tumors located in the posterior part of the third ventricle.

The most common third ventricular tumor operated by endoscopy is colloid cyst. Approaching a third ventricular colloid cyst is an excellent application of endoscopic technology to surgery within the ventricular system. The endoscope is an ideal instrument for exploration of fluid-filled cavities, and the intraventricular location of colloid cysts make them accessible for the endoscopic approach. The surgical removal of colloid cysts has traditionally been difficult, with a high percentage of postoperative complications.

Ventriculoperitoneal shunting should not be considered a treatment option because it does not provide a cure, frequently requires bilateral ventricular catheters, and is susceptible to malfunction and infection (Lewis & Crone, 1998). Microsurgery permits radical removal of the cyst wall and minimizes the likelihood of recurrence. However, even in very experienced hands, microsurgery implies up to 27% postoperative morbidity. The microsurgical transcortical approach is associated with a higher rate of postoperative seizures than transcortical introduction of the endoscope into the lateral ventricle. Among 190 patients operated by the endoscopic procedure through a transcortical burr hole, no postoperative seizures have occurred. The transcortical burr hole approach is fast, easy, and safe due to well-known landmarks (Gaab & Schroeder, 1998).

The more direct microsurgical transcalloal approach to the third ventricle, avoids cortical disruption. However, it carries many risks such as sagittal sinus thrombosis, venous infarction from dissection of bridging veins, damage to the pericallosal arteries, and injury to the fornix with permanent memory loss (Jeeves et al., 1979). Many reports stress the operative simplicity and low complication rate of the stereotactic approach to colloid cysts. However the initial enthusiasm for stereotactic aspiration has been tempered by its lack of success in treating some patients, lack of intraoperative visual control (i.e. blind procedure) and the high recurrence rate (up to 80%) because the cyst wall could not be resected or even widely fenestrated (Mathiesen et al., 1993). Endoscopic surgery provides a balanced middle ground between microsurgery and stereotactic aspiration. It permits wide fenestration of the capsule and aspiration of the cyst contents under direct vision, with minimal disruption of the cortex and other normal brain structures. Resection of the cyst wall can also be performed using the endoscopic procedure (Abdou & Cohen, 1998).

Colloid cysts located in the anterior third ventricle with a large lateral ventricle are the easiest to remove endoscopically. A large ventricular system allows for more maneuverability, facilitates the endoscopic procedure markedly, and obviates the need for any guidance procedures such as stereotaxy or neuronavigation which makes the procedure more lengthy and sophisticated (El-Ghandour, 2009).

If the ventricles are small, then intraoperative ultrasound or stereotactic guidance may be required to cannulate the lateral ventricle. If there is asymmetry in the lateral ventricular system, then the approach is done through the largest frontal horn. If the patient has undergone previous shunting and has small ventricular system, the patient is admitted to the hospital, the shunt is externalized, and the drain is clamped in order to dilate the ventricular system (Lewis & Crone, 1998).

### 3.5.3 Fourth ventricular tumors

The posterior fossa is a common site for various tumors to occur during childhood. It was estimated that they comprise 54-60% of childhood brain tumors. Medulloblastoma

represents approximately 20% of all childhood central nervous system tumors (Polednak & Flannery, 1995). Ependymoma represents approximately 10% of all reported primary intracranial tumors in children (Farwell et al., 1977). Medulloblastomas and ependymomas are often complicated by the development of hydrocephalus due to obstruction of the fourth ventricle. Children are very sensitive to intracranial pressure elevation and thus management of hydrocephalus has the highest priority and should be performed prior to any surgical treatment of the posterior fossa tumor itself. It is claimed that precraniotomy shunt provides improvement in the patient's physiological condition, a "slack posterior fossa" and a smooth postoperative course (Albright & Reigel, 1977; Raimondi & Tomita, 1981). The development of hydrocephalus in children with posterior fossa tumors is one of the main factors influencing the outcome. In one series, the operative mortality was decreased with preoperative shunting (Albright & Reigel, 1977).

Placement of permanent shunt was the "golden" standard treatment over years. However, the technological advances and changes in the availability of neuroimaging systems have resulted in establishing an earlier diagnosis. This, coupled with the extensive list of potential complications associated with ventricular shunting in this patient population, resulted in another strategy of treatment recommending the use of corticosteroid therapy, early surgery and external ventricular drainage (Papo et al., 1982). Nevertheless, external ventricular drainage is associated with a significant risk of infection and hemorrhage. Moreover, such treatment might not be appropriate for young children with advanced hydrocephalus because these patients usually need a permanent diversion procedure.

It was estimated that children who have advanced hydrocephalus and children who are younger than 3 years of age had persistent hydrocephalus which required a postoperative shunt in about 80% of cases (Epstein, 1993). Approximately, one third of patients overall, will eventually require placement of a shunt (Lee et al., 1994). Many factors have been reported to be associated with required shunt placement including a young age (< 10 years), midline tumors, more severe ventricular enlargement at diagnosis, incomplete tumor resection, cerebrospinal fluid-related infection, prolonged use of external ventricular drainage, cadaveric dural grafts, and persistent pseudomeningocele (Culley et al., 1994).

As long-term survival becomes more frequent in children with posterior fossa tumors, issues pertaining to the quality of life, such as postoperative shunt dependency becomes increasingly important and must be taken into consideration. It has been mentioned that following tumor excision, the obstructive component of the hydrocephalus is relieved in most of the patients, and the flow of cerebrospinal fluid will be restored, thus the shunt will be no more necessary, but the patient now becomes shunt dependent (El-Ghandour, 2011).

Taking all these factors into consideration, a search for a better treatment option should be expected. The obstructive nature of the hydrocephalus associated with posterior location of the tumor, makes internal cerebrospinal fluid diversion to be a promising alternative. The rational basis of endoscopic third ventriculostomy is provided by the obstructive nature of hydrocephalus due to presence of blockage of cerebrospinal fluid pathways at the level of fourth ventricle outlets or at the aqueduct of Sylvius. It has been mentioned that obstructive hydrocephalus secondary to posterior fossa tumors in children with good absorption of cerebrospinal fluid from the subarachnoid space is a good selection for endoscopic third ventriculostomy (El-Ghandour, 2011).



Endoscopic third ventriculostomy creates a communication between the ventricular system and the subarachnoid space at the level of the third ventricle. There is only one comparative study in the literature which compares both procedures; endoscopic third ventriculostomy and ventriculoperitoneal shunt in the treatment of obstructive hydrocephalus due to midline posterior fossa tumors in children. The author reported superiority of the endoscopic third ventriculostomy over shunting because of the shorter duration of surgery, the lower incidence of morbidity, the absence of mortality, the lower incidence of procedure failure, and the significant advantage of not becoming shunt dependant (El-Ghandour, 2011).

It is worthy to mention, that in selected cases of fourth ventricular tumors, biopsy can be also taken endoscopically through the enlarged aqueduct of Sylvius. However, these tumors are rarely amenable to endoscopic resection because of the limited space within the ventricle (Gaab & Schroeder, 1998).

## **4. Endoscopic procedures**

### **4.1 Endoscopic third ventriculostomy**

Endoscopic third ventriculostomy is the standard and the most commonly performed endoscopic procedure. As with any other surgical procedure, appropriate patient selection is essential for successful outcome. Patients who present with classical signs of noncommunicating hydrocephalus are ideal candidates. Unquestionably, patients with aqueduct stenosis (congenital or acquired) are the best candidates. Although initially the role of endoscopy has been limited to performing endoscopic third ventriculostomy in patients with congenital aqueductal stenosis, the indications for this procedure are increasing rapidly. Any patient presenting with a lesion causing obstruction of cerebrospinal fluid outflow at the aqueduct of Sylvius is a candidate for this procedure (Jimenez 1998). Such lesions include primary or secondary (metastatic) neoplasms of the midbrain, pons, medulla, posterior fossa tumors or cysts, pineal region tumors, posterior third ventricular lesions, or ventricular exophytic thalamic gliomas (Ray et al., 2005; El-Ghandour, 2011).

Another group of patients who can benefit from this procedure are those who present with obstructive hydrocephalus secondary to arachnoid cysts of the deep cisternal system (quadrigeminal plate or ambient system). Many published studies have included patients with variety of symptoms, including those with communicating hydrocephalus (Jones et al., 1990), and idiopathic normal pressure hydrocephalus (Gangemi et al., 2008). There is much argument about spina bifida patients, whether considered to be candidates for such procedure or not. These patients have significantly abnormal ventricular anatomy and commonly present with a thick third ventricular floor, a small narrow foramen of Monro, and a large massa intermedia (Jimenez, 1998).

Selection criteria remain the most controversial aspect of this procedure. The reason for this is that there is no single or combined examination which can relatively predict who will benefit from this operation. Cerebrospinal fluid infusion studies may help to select more suitable patients, but false negative results can occur because the absorptive mechanisms may take several hours or even days to accommodate for increased load of cerebrospinal fluid, whereas the study itself extends over a significantly shorter time (Pudenz 1981).

Similarly, cerebrospinal fluid isotope clearance studies should theoretically accurately predict the ability of the arachnoid villi to absorb cerebrospinal fluid. However, it also

suffers from high false negative results, thereby denying some potentially suitable candidates the opportunity to remain shunt independent. To support this contention, clinically, some patients require several weeks before their symptoms resolve and their imaging improves. This implication is that the subarachnoid space needs time to accommodate for the increased cerebrospinal fluid load (Teo, 1998).

### **Surgical Technique**

Following induction of general anesthesia, the patient is placed supine with the head slightly flexed. A standard midpupillary coronal burr hole is used, but optimum localization can be achieved by projecting the best angle to the floor of the third ventricle using preoperative coronal and sagittal T1-weighted MR imaging. The frontal horn is cannulated with a # 14-french peel-away sheath and stylet. After withdrawal of the stylet, a 2 mm-diameter rigid lens (wide-angle, straight-forward, 0 degree) with angled eye piece and working channel diameter of 3 mm, is inserted. The choroid plexus is identified and followed anteriorly to the foramen of Monro. The endoscope is advanced into the third ventricle through the foramen of Monro. Once the third ventricle is entered, the mammillary bodies are usually visualized as well as the tuber cinereum and the infundibular recess. Sometimes, the tuber cinereum has become thin and semitransparent, allowing identification of the basilar artery.

Several methods are used to create the fenestration on the floor of the third ventricle such as using the tip of rigid endoscope, small blunt probes, tip of a transluminal angioplasty balloon catheter, tip of a contact laser fiber or bipolar electrode. An avascular area in the floor of the third ventricle anterior to the mammillary bodies is chosen for fenestration, with care taken to avoid injury of the basilar artery or any of its branches. The opening is then enlarged gently by inflating the balloon of a # 3 french angioplasty balloon catheter in a relatively atraumatic fashion. It is generally agreed that the opening should be 5-6 mm in diameter in order to prevent its reclosure. However, it is also well known that it is the constant flow of cerebrospinal fluid through the fenestration that keeps it open and working. In other words, it is the pressure gradient between the third ventricle and the interpeduncular cistern, which exists in case of noncommunicating hydrocephalus, that prevents the ventriculostomy from reclosure.

If extensive trabeculations are encountered, the fenestration has to be extended to include all these trabeculae. Not uncommonly, a small amount of venous bleeding may be observed from the edges of the ventriculostomy. This type of bleeding usually stops with gentle irrigation or with reinflation of the balloon for 1-2 minutes. Navigation inside the interpeduncular cistern is done to confirm successful creation of the ventriculostomy. The endoscope and peel-away sheath are then removed. Unless there has been significant bleeding, an external ventricular drain is not necessary, although some surgeons leave it in place for 24-48 hours. This is done to monitor the intracranial pressure; the drain is removed once the intracranial pressure has normalized. The wound is closed in a standard fashion. If there are no complications, the patient can be discharged within 24-48 hours.

### **4.2 Choroid plexectomy**

This treatment option is controversial and is not used nowadays by most neurosurgeons. Those patients who have a choroid plexus papilloma or who produce an abnormally high

amount of cerebrospinal fluid, may benefit from this procedure. Choroid plexectomy appears to be indicated in a small group of patients who have normal communications and intact absorptive mechanisms, but do not have the capacity to cope with an overwhelming load of cerebrospinal fluid (Teo,1998).

### **Surgical Technique**

The patient is placed in the prone position and bilateral occipital burr holes are placed 3 cm from the midline at the level of the lambdoid sutures. The rigid endoscope is introduced into the lateral ventricle and the choroid plexus is coagulated using monopolar, bipolar, or Nd:YAG (neodymium-yttrium-aluminum-garnet) laser coagulation. Access to all three horns of the lateral ventricle is possible through this approach. Care should be taken not to coagulate the choroidal arteries, as this may result in retrograde occlusion of the proximal perforating vessels.

### **4.3 Endoscopic opening of foramen of Magendie**

This procedure is used in the treatment of patients with obstructive hydrocephalus due to fourth ventricular outlet obstruction caused by idiopathic stenosis or membranous occlusion of the foramina of Magendie and Luschka (Longatti et al., 2006; Mohanty et al., 2008).

### **Surgical Technique**

The patient is placed supine and general anesthesia is induced. The frontal horn of the lateral ventricle is cannulated through a precoronal burr hole (2 cm anterior to the coronal suture and 2 cm from the midline). The flexible endoscope, with a diameter of 3.9 mm is introduced and manipulated throughout the procedure using a free hand technique. At the third ventricle, the scope is guided backward toward the opening of the aqueduct to the midbrain. In case of tetraventricular hydrocephalus, the aqueduct is dilated and the scope passes quite easily into the fourth ventricle. At this phase, free irrigation is stopped, because the fourth ventricle is now completely trapped and additional liquid volumes can lead to life-threatening episodes of bradycardia.

The scope is positioned posteriorly, the median sulcus of the fourth ventricle is seen, it leads to the posterior triangle of the rhomboid fossa. The lateral recesses appear enlarged and both Luschka foramina are obstructed by thick membranes. A thick membrane is stretched from the borders of the calamus scriptorius to the pyramid of the vermis, occluding the foramen of Magendie. The membrane is perforated using monopolar coagulation or a "saline torch", and the opening is enlarged with the inflation of a Fogarty balloon. The endoscope is advanced to the cisterna magna in order to assess its extent and confirm absence of adhesions. The endoscope is then carefully withdrawn with meticulous attention in order not to injure the aqueductal tip or columns of the fornix.

### **4.4 Septum pellucidotomy**

The endoscopic procedure for treatment of isolated lateral ventricle is fenestration of the septum pellucidum. The degree of difficulty of this procedure is grossly underestimated. This is because most patients requiring this procedure have one collapsed ventricle and one grossly dilated ventricle. It is so difficult to identify the septum in these patients that stereotactic assistance is recommended. In uncomplicated cases, the results of septum

pellucidotomy are excellent, obviating the need for two shunts, and in some cases, the need for any shunting (Teo, 1998).

### **Surgical Technique**

The patient is placed in the supine position with the head slightly flexed. The burr hole site is placed more laterally than the standard coronal burr hole used for shunt placement (5-6 cm from the midline), so that the endoscope approaches the target at an angle more perpendicular to the septum pellucidum. The surgeon is often faced with the dilemma of which ventricle to enter when performing a septostomy. Some authors (Teo, 1998) recommend working in the nondilated ventricle toward the dilated ventricle. Others (Abtin & Walker, 1998) recommend working in the larger ventricle toward the smaller one, where the surgeon can more easily maneuver the endoscope and instruments. The second procedure is more risky, because the opposite ventricle is small and caution is necessary in order to avoid any direct or thermal injury to structures on the lateral wall of the contralateral ventricle.

The rigid endoscope is then introduced into the lateral ventricle, and the septum pellucidum is visualized. A safe target should be 1 cm above and 2 cm anterior to the foramen of Monro. An area of about 1.5 to 2 cm is then fenestrated with laser or other instrumentation. The site of fenestration is critical, if placed too high on the septum, the fenestration may open into the interhemispheric fissure, with potential injury of the anterior cerebral arteries. If the fenestration is made above the foramen of Monro, there is risk of injury to the fornix. If placed posterior to the foramen, there is risk of injury to the genu of the contralateral internal capsule, if the instrument used for fenestration penetrates too deeply. One should also pay attention to variants such as cavum septum pellucidum in order to achieve a satisfactory septostomy (Abtin & Walker, 1998).

### **4.5 Endoscopic cyst fenestration**

Multiloculated hydrocephalus is not uncommon in the hydrocephalic community, especially in those infants whose shunts have been complicated by infection or whose primary pathology was intraventricular hemorrhage. Both conditions cause fibrous septations as a result of chemical or bacterial ventriculitis. Infants with this condition usually require multiple shunts and therefore are subjected to the additive risk of complex shunts mainly malfunctioning (Teo, 1998). These patients are excellent candidates for the endoscopic procedure. The endoscope is used to communicate all the cysts and a shunt is then left in the largest ventricle, using the same burr hole through which the procedure was performed. Endoscopy offers a simple means of communicating isolated cerebrospinal fluid spaces and ventricles by membrane fenestration. In a recent report, endoscopy has led to avoiding, eliminating or simplifying the use of shunts, with a significant decrease in postoperative shunt revision rate (El-Ghandour, 2008).

### **Surgical Technique**

The approach is individually designed in each case separately depending on location of the cysts, entry site of pre-existing ventricular catheter and the need for placement of a new shunt. Cysts located anteriorly are approached through a standard midpupillary coronal burr hole, whereas an occipital or posterior parietal route is used for posterior or temporal

loculations. The burr holes are bevelled laterally to allow the endoscope to reach the contralateral ventricle and the trajectory is planned to fenestrate the maximum number of cysts. The ventricular system or cyst is cannulated with a # 14 french peel-away sheath and stylet. Care is taken to prevent the release of cerebrospinal fluid before the endoscope is introduced. After withdrawal of the stylet, a 2 mm diameter rigid lens (wide-angle, straight-forward, 0 degree) with angled eye piece and working channel diameter 3 mm is inserted.

Cyst fenestration is performed in a relatively avascular segment of the cyst wall sharply with bipolar electrocautery. The fenestration is widened to at least 1 cm in diameter to prevent early reclosure. This is achieved sharply by widening the initial hole or connecting multiple holes using the bipolar electrode. Devascularization of the cyst wall is done by coagulating its vascular supply to prevent or retard its regrowth. Pulsed irrigation with lactated Ringer's solution is used to prevent thermal injury and collapse of the ventricles. Any bleeding from the cyst wall usually stops with irrigation or coagulation. If there is significant intraventricular bleeding, it is better to put an external ventricular drain and postpone shunting procedure to a later date (El-Ghandour, 2008).

#### **4.6 Aqueductoplasty**

There are few indications for this high risk procedure. Most cases of noncommunicating hydrocephalus respond more favourably to third ventriculostomy. Some authors believe that it can be used as an adjunct to third ventriculostomy in patients with adult onset aqueductal stenosis (Oka et al., 1993). Patients who have an isolated fourth ventricle are also excellent candidates for this procedure. Endoscopic reopening of the aqueduct of Sylvius (aqueductoplasty) is considered to be the ideal treatment of isolated fourth ventricle, because it re-establishes communication between the fourth ventricle and the supratentorial ventricular system, equilibrating the transtentorial pressure and allowing a single supratentorial shunt to control the patient's hydrocephalus. However, endoscopic aqueductoplasty cannot be performed in all cases, it can be only performed if a membranous occlusion of the aqueduct is present in preoperative MR images. The standard precoronal approach can be used only in cases in which the supratentorial ventricular system is also dilated; in other cases a suboccipital approach should be used (Cinalli et al., 2006).

##### **4.6.1 Precoronal approach**

The patient is positioned supine with the head lying in a horseshoe-shaped head rest. The burr hole site is placed more anteriorly than the standard coronal burr hole used for shunt placement (just behind the hair line, 4-5 cm anterior to the coronal suture). The right lateral ventricle is cannulated with a peel-away sheath. A flexible endoscope is then inserted and careful inspection of the frontal horn usually allows easy identification of the foramen of Monro. The endoscope is then advanced through the foramen of Monro into the third ventricle, where the obstructed aqueduct inlet is identified.

The aqueduct should not be confused with suprapineal recess, which is located above the aqueduct and behind the posterior commissure. The membrane occluding the inlet of aqueduct is perforated simply by probing the aqueduct with the aid of the smooth tip of a Fogarty balloon catheter; this allows inspection of the cavity of the fourth ventricle. In short



stenosis, the aqueduct is restored by gently inflating the balloon to a diameter of 3 mm. In long stenosis, a stent may be inserted into the aqueduct to prevent later occlusion by scarring (Schroeder & Gaab, 1999). However, implanting stents carries the risk of stent dislodgement and migration (Mohanty, 2005).

#### **4.6.2 Suboccipital approach**

The patient is placed prone with the head lying in a horseshoe-shaped head rest. The head is flexed as much as possible to create the best trajectory to the aqueduct. An infratentorial burr hole is drilled 2-3 cm from the midline over the right cerebellar hemisphere. The dilated fourth ventricle is cannulated with the aid of a peel-away sheath and then the endoscope is inserted. After the aqueduct has been identified, the obstructing membrane is perforated using a Fogarty balloon catheter while carefully avoiding any damage to the periaqueductal gray matter. Inspection of the aqueduct permits the operator to visualize the third ventricle. The limit of this approach is the lack of landmarks available for orientation in the unusual and distorted anatomy of a trapped fourth ventricle, where recognition of the inlet of aqueduct can be very difficult (Cinalli et al., 2006).

#### **4.7 Endoscope-guided shunt placement**

Although placement of a ventricular catheter using endoscopy has yet to be proven superior to other methods, the tip of the ventricular catheter can be properly placed in the desired position under direct visualization using small endoscope that passes through the shunt catheter. Endoscope-guided shunt placement can be done either using free hand method or by stereotactic assistance.

##### **4.7.1 Free hand endoscopic shunt placement**

###### **Direct Placement**

The ventricular catheter is “loaded” on an endoscope with the tip of the endoscope exposed for visualization. The shunt may then be placed directly into the ventricle via the appropriate trajectory. After placing the ventricular catheter into the ventricle, the operator can look through the endoscope to confirm the shunt catheter’s position. If the ventricular catheter is not in a proper position, the shunt is withdrawn and modification of the trajectory can be done. The surgeon determines the preferred position of the shunt catheter, but the general consensus is that it should be as far as possible from the choroid plexus, a natural source of scar formation. Consequently, the frontal horn of the lateral ventricle has become a favored position for catheter placement by most of the neurosurgeons (Brockmeyer, 1998).

###### **Peel-away Catheter**

Another technique for endoscopic shunt placement, which applies to those neurosurgeons using a rod lens endoscope system, involves placing an appropriate-sized peel-away catheter into the ventricle, then inserting the endoscope through the peel-away catheter. In this way, the potential shunt position is confirmed and the length of the ventricular catheter can be estimated. Once the peel-away catheter is in an appropriate position, the endoscope is withdrawn and the ventricular catheter is passed through the peel-away sheath to the

predetermined location. The sheath is then peeled away while the ventricular catheter is held gently with smooth forceps, leaving the ventricular catheter in place (Brockmeyer, 1998).

#### 4.7.2 Stereotactic shunt placement

Applying stereotactic technology to endoscopic techniques has increased the safety and accuracy of such procedures. The available frameless stereotactic systems may be coupled to endoscopes and can be used to pass stereotactic probe to the target ventricle and then withdrawn. A fiberoptic endoscope already loaded with a shunt catheter is then passed down the probe tract under direct vision into the ventricle (Brockmeyer, 1998).

Endoscopic-assisted placement of a multiperforated shunt catheter into the fourth ventricle guided by frameless stereotaxy, has been recently advocated by some authors for the treatment of isolated fourth ventricle and multicompartmentalized hydrocephalus. The procedure is performed via a frontal transventricular approach using the flexible endoscope with dual-port intraventricular access for direct visualization and for mechanical manipulation of the catheter (Upchurch et al., 2007).

#### 4.8 Ventricular catheter retrieval

Endoscopic retrieval of a retained intraventricular catheter is an excellent application of endoscopy in the management of hydrocephalus. The endoscope can be used to extract catheters from inside the ventricle either they are “free” or “adherent” in scar tissue. Adherent ventricular catheters are usually found in cases of multiloculated hydrocephalus. It has been reported that retained pre-existing malfunctioning ventricular catheters in multiloculated hydrocephalus could not be withdrawn safely without endoscopic assistance. Such catheters have to be dissected gently and dislodged under direct endoscopic visualization in order to avoid the risk of hemorrhage and damage which can be induced if the catheter is pulled without being dissected (El-Ghandour, 2008).

##### Surgical Technique

Any endoscope with a working channel can be used for such technique. If the ventricular catheter is “free” within the ventricle, a long grasping forceps is passed through the working channel and the endoscope is navigated into an appropriate position. Obviously, knowledge of the intraventricular anatomy is essential for navigating into correct position for catheter retrieval. The retained catheter is then grasped with the endoscopic forceps and withdrawn outside the ventricular system (Brockmeyer, 1998).

Endoscopy can be also used to remove adherent scarred-in ventricular catheters, and consequently it plays an important role in simplification of complex shunts in multiloculated hydrocephalus. One possible technique described by El-Ghandour, for shunts initially placed via occipital burr hole, involves placing a separate burr hole 2-3 cm above the old one, through which the endoscope is introduced parallel to the ventricular catheter with slight inclination toward its tip. Bipolar electrode is then used to coagulate the scarred-in choroid plexus and dislodge the shunt catheter, which can then be withdrawn gently and safely without risking intraventricular hemorrhage (El-Ghandour, 2008).

Alternatively, the Nd:YAG laser can be used to coagulate the choroid plexus and cut along the interface of the scar and silicone tubing in order to dislodge the catheter. The adherent ventricular catheter is then removed under endoscopic visualization and a new ventricular catheter is placed in an appropriate position (Lewis et al., 1995).

#### **4.9 Shunt revision**

Intracranial neuroendoscopy can be very useful during routine shunt revision. It increases the surgeon's confidence that a ventricular catheter is placed in the appropriate position, and it is useful in repositioning previously inserted malfunctioning shunts under direct visualization.

#### **Surgical Technique**

After dislodging and removing the old ventricular catheter, a new ventricular catheter is loaded on a fiberoptic endoscope and passed down the same tract. The tract may be inspected for nests of scar tissue, membranes or webs. When the endoscope reaches an area in the ventricle free of scar, choroid plexus or membrane, it is withdrawn back through the ventricular catheter and cerebrospinal fluid flow is observed. The need for a longer or shorter ventricular catheter is easily confirmed by the endoscope and demonstrated by the presence or absence of cerebrospinal fluid flow. The flow of cerebrospinal fluid confirms the intraventricular position of a shunt catheter. This technique allows the operator to avoid the nest of scar tissue by direct visual confirmation in order to place the new catheter in a more appropriate position (Brockmeyer, 1998).

#### **4.10 Resection of intraventricular tumors**

With increasing experience and improved endoscopic instruments (such as bipolar diathermy, laser instruments), an increasing number of tumors may be completely removed without microsurgical brain dissection. In certain cases, a neuroendoscopic approach to intraventricular tumors via a simple burr hole is as effective as microsurgery but less invasive. During endoscopic procedures, brain retraction can be completely avoided, and the tumor can be well visualized with the aid of endoscopy. The origin of the tumor and the amount of blood supply can be recognized prior to tumor biopsy or resection. Only a few publications in the neurosurgical literature address the endoscopic treatment of intraventricular tumors. Most authors have not reported details regarding endoscopic technique, complications or outcome (Gaab & Schroeder, 1998).

The ventricular enlargement provides sufficient space for manipulation with the endoscope and instruments. However, if the ventricles are small or the tumor is located in the posterior part of the third ventricle, it is advisable to use a guiding device to follow the ideal access route to the target, thus avoiding unnecessary brain traumatization. Frameless stereotaxy or neuronavigation has been used in conjunction with neuroendoscopy to increase the accuracy in determining the approach. For treatment of intraventricular tumors, rigid endoscopes are preferred because of the superior optical quality which maintains good vision even when small hemorrhages occur. The operating endoscope (wide-angle, straight-forward, 0 degree) with angled eye piece allows accurate guidance of the instruments in a straight line.

Using large operating sheath (approximately 6 mm in diameter) without separate working channels, makes effective piecemeal resection of the tumor possible. However, in most neuroendoscopes currently available, the working channel is no larger than 2.4 mm. It is obvious that removal of intraventricular tumors, even if small in size, is a tedious, time-consuming procedure with these scopes (Gaab & Schroeder, 1998). Some neurosurgeons recommend the insertion of a second working portal, enabling the use of larger instruments and thus accelerating tumor resection (Cohen, 1993; Jallo et al., 1996). Flexible endoscopes can be applied for final inspection. Various endoscopic instruments should be available in order to make the procedure successful such as scissors, puncture needles, biopsy and grasping forceps, balloon catheters, laser fibers and monopolar electrodes.

### **Surgical Technique**

#### **Lateral Ventricular Tumors**

Tumors of the frontal horn and ventricular body are approached via a standard midpupillary precoronal burr hole (3 cm paramedian and 2 cm precoronal). The tumor can be biopsied or resected, and septostomy can be performed if there is unilateral hydrocephalus. For tumors of the trigone, the burr hole is placed more anteriorly (4-6 cm precoronal) in order to reach the tumor in a straight line through the ventricular body. A posterior approach can also be performed, it has the advantage that there is a shorter distance from the cortical surface to the tumor when entering the ventricle posteriorly than when entering it anteriorly. However, there is usually a very limited amount or almost no cerebrospinal fluid-filled working space in front of the tumor, which makes inspection of the lesion, orientation, and dissection extremely difficult or even impossible (Gaab & Schroeder, 1998).

Once the dura is opened, the operating sheath with trocar is inserted free hand or under navigational guidance into the lateral ventricle and fixed with two retractor arms. The trocar is then withdrawn and the rigid endoscope is introduced. The tumor is inspected and its relationship to the choroid plexus and the feeding arteries is visualized. After exploration of the tumor, the diagnostic scope is replaced by the operating scope. Before tumor dissection, capsule vessels are coagulated by bipolar diathermy or Nd:YAG laser. Depending on the tumor size, removal usually begins with intracapsular debulking or dissection in the plane between the tumor and the normal brain tissue. During this dissection, feeding arteries must be identified early and cauterized before bleeding obscures clear vision. If laser is used during resection, it requires vigorous irrigation to avoid thermal damage to adjacent brain tissue.

Hemostasis of small hemorrhages represents no problem as these usually stop spontaneously after a few minutes of irrigation. Larger vessels which are at risk of being torn during tumor resection, should be cauterized by the bipolar diathermy. After isolation of the lesion from the surrounding brain tissue, the tumor is resected in a piecemeal fashion with the aid of grasping and biopsy forceps. In general, the foramen of Monro is usually patent after tumor resection. If the foramen is obstructed, a septostomy through the septum pellucidum may be performed to release cerebrospinal fluid circulation. After successful tumor removal, the region of resection is inspected again with the diagnostic scope to ensure good hemostasis. The ventricles are vigorously rinsed to remove any clots and the operating sheath is then withdrawn and the wound is closed.

### Third Ventricular Tumors

For tumors located in the anterior part of the third ventricle such as colloid cysts, the lesion can be approached via a transcoronal burr hole. The burr hole should be placed (about 1 cm) in front of the coronal suture and far laterally (5-7cm from the midline) in order to directly visualize the cyst wall. Placing the burr hole too close to the midline will decrease visualization of the cyst significantly. Also widening of the outer edges of the burr hole provides a more conical opening which allows greater freedom in maneuvering the endoscope with enough angulation to reach the contralateral ventricle. Laser is usually essential to open the cyst wall and bipolar cautery is usually unsuccessful in opening the tough cyst wall. Monopolar electrode was found to be equally effective like laser and it is less cumbersome (El-Ghandour, 2009).

Devascularizing the outer layer of the colloid cyst is a crucial step that should be done in all the cases. It shrinks the capsule to open the foramen of Monro, cuts off the nutrients to the inner layer that secretes the colloid and prevents regrowth (Fig 1). Residual parts of the capsule firmly attached to the roof of the ventricle should be coagulated rather than vigorously removed, because pulling may cause severe venous bleeding. Re-establishing cerebrospinal fluid pathways is an important step that should be performed in all the cases. The aqueduct of Sylvius is visualized to ensure a clear pathway between the lateral, third and fourth ventricles. The septum pellucidum is often fenestrated to ensure a balanced flow of cerebrospinal fluid between the lateral ventricles. An external ventricular drain is not required, unless uncontrolled bleeding has occurred. Most bleeding will stop with direct irrigation at the bleeding site. Some neurosurgeons prefer inserting an external ventricular catheter routinely to prevent aseptic ventriculitis that may be caused by free-floating colloid material within the ventricular system (Hellwig et al., 2008).

For tumors located in the posterior third ventricle, such as pineal body tumors, an endoscopic supracerebellar infratentorial approach has been used by some authors (Gore et al., 2008). Nevertheless, this approach has considerable risks for many reasons; 1) A simple burr hole is not sufficient to identify the transverse sinus and therefore a small craniotomy has to be performed. 2) Thick arachnoid membranes often cover the pineal region, hindering accurate orientation. 3) The superior cerebellar bridging veins and deep incisural veins are at risk when inserting the endoscope (Gaab & Schroeder, 1998). Other neurosurgeons recommend performing endoscopic third ventriculostomy for the management of the associated obstructive hydrocephalus and obtaining tissue samples sufficient for pathological diagnosis which can be taken endoscopically through the same transcoronal burr hole (Chernov et al., 2006; Al-Tamimi et al., 2008).

## 5. Complications

The complications of endoscopic procedures can be grouped into three groups: general, neurological, and vascular

### 5.1 General complications

This group includes wound infection, ventriculitis, cerebrospinal fluid leaks, and subgaleal fluid collections. It is worth noting that the use of normal saline for irrigation is contraindicated due to the fact that it is strongly acidic and it can lead to chemical



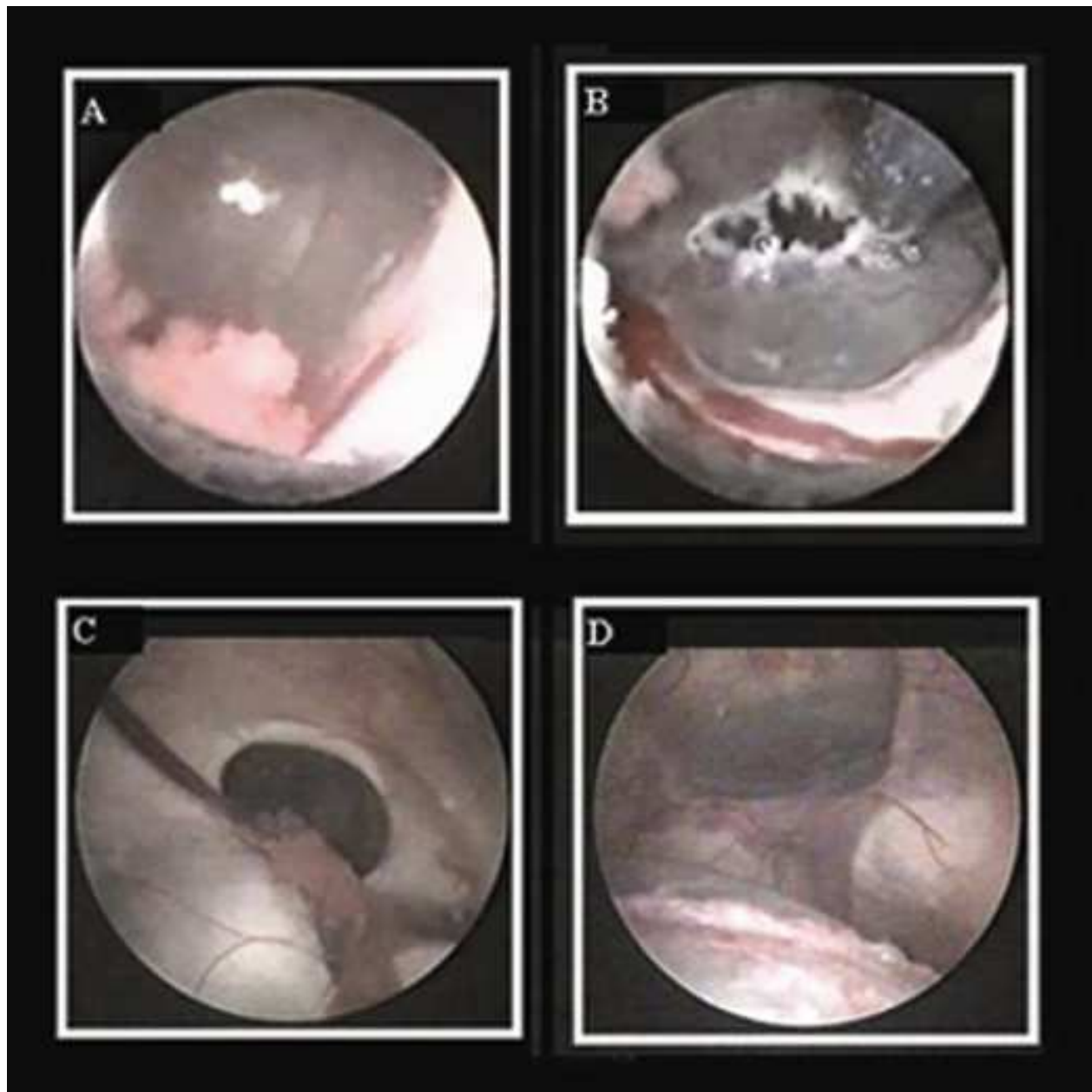


Fig. 1. Intraoperative neuroendoscopic views. A, Photograph showing anterior colloid cyst bulging through and obstructing the foramen of Monro. B, Photograph of the same case where monopolar electrode is used to open the cyst wall and shrink it to a tiny nonvascular remnant. C, Photograph showing posterior colloid cyst causing a bulge in the floor of the lateral ventricle. Note the foramen of Monro is open in this case. D, Photograph of the same case where the endoscope is introduced inside the third ventricle through the foramen of Monro. Note both mammillary bodies. The colloid cyst is seen at 7 o'clock. Endoscopic third ventriculostomy was done in this case. [Reprinted with permission from El-Ghandour NM (2009). Endoscopic treatment of third ventricular colloid cysts: a review including ten personal cases. *Neurosurg Rev*, Vol. 32, No. 4, (October 2009), pp. 395-402, ISSN 0344-5607].

ventriculitis. Lactated Ringer's solution is considered to be the perfusate of choice because its chemical composition is closest to cerebrospinal fluid. The irrigation rate should be controlled in order to prevent dangerous acute intracranial hypertension which may result in significant postoperative neurological sequelae. In order to avoid such complication, care is taken to maintain sufficient outflow of irrigating fluid (Jimenez, 1998).

## 5.2 Neurological complications

During the procedure of endoscopic third ventriculostomy or any other intraventricular endoscopic surgery, injury to the fornix can occur, and it leads to transient deficit in short-term memory. Oculomotor and other cranial nerve palsies can also occur due to incorrect placement of the fenestration off the midline, in a lateral position. The oculomotor nerve can be injured by laterally directing the endoscope while perforating the tuber cinereum. Oculomotor palsy may be transient or permanent depending on the degree of damage that occurs during the endoscopic procedure.

Damage to the hypothalamus can occur due to traction injury associated with the use of the tip of a large endoscope to create the fenestration on the floor of the third ventricle. This can lead to hyponatremia, lethargy, diabetes insipidus, transient syndrome of inappropriate antidiuretic hormone secretion and permanent or temporary weight gain. Midbrain injury and hemiparesis have also been reported. Although seizures can occur following insertion of a large peel-away or rigid introducers through the cortical mantle, this complication has not been found to occur clinically after endoscopic procedures (Jimenez, 1998).

## 5.3 Vascular complications

The most dangerous complication during endoscopic surgery is injury to the superior basilar artery complex, which is manifested intraoperatively by massive intraventricular hemorrhage with complete obscuration of the endoscopic field. Although reported previously (Schroeder et al., 2002), it is considered to be a rare complication. The bleeding is usually profuse, however, it usually stops following persistent and vigorous irrigation. In order to avoid this vascular injury, perforation of the floor of the third ventricle should be performed in the midline, halfway between the infundibular recess and the mammillary bodies, just behind the dorsum sellae.

Less serious although equally bothersome is damage to the ventricular veins, such as thalamostriate, caudate, septal or internal cerebral veins. Bleeding associated with these low pressure venous systems usually stops after few minutes of continuous irrigation. Intraventricular clots can be easily removed with the use of grasping forceps and suction (Jimenez, 1998).

## 6. Outcome and prognosis

A successful outcome following endoscopic third ventriculostomy is defined as resolution of symptoms associated with increased intracranial pressure secondary to cerebrospinal fluid flow obstruction. It should be highlighted that if there is no decrease in ventricular size in postoperative imaging, it should not be taken as a nonsuccessful outcome, because a large number of patients continue to demonstrate ventriculomegaly following successful

endoscopic third ventriculostomy. This is particularly true in patients with long standing hydrocephalus (Jimenez, 1998).

Postoperative MR imaging may show a decrease in ventricular size and/or improvement of transependymal edema especially in acutely or subacutely developing hydrocephalus. It should also demonstrate a flow void in the floor of the third ventricle, otherwise a cine MR imaging is obtained for a better demonstration of systolic/diastolic cerebrospinal fluid flow through the created fenestration (Jallo et al., 2005).

Reported success rates for endoscopic third ventriculostomy vary between 15% and 80%. Several factors appear to be related to poor results and those include younger patients (< 2 years), a history of meningitis, intraventricular or subarachnoid hemorrhage, infants with myelodysplasia, and a history of previous radiation therapy (Jimenez, 1998).

Endoscopic third ventriculostomy plays a crucial role in the treatment of obstructive hydrocephalus secondary to tumors obstructing cerebrospinal fluid pathways. Excellent results were obtained in a series of 32 pediatric patients with obstructive hydrocephalus secondary to midline posterior fossa tumors (20 medulloblastomas, 12 ependymomas). Intracranial hypertension symptoms improved postoperatively in 31 out of 32 cases (96.9%). Ataxia improved in 4 out of 10 cases (40%), sixth nerve palsy improved in 6 out of 9 cases (66.7%). All the 4 cases presented with deteriorated conscious level became fully conscious (100%), immediately postoperatively. Improvement of hydrocephalus in postoperative imaging occurred in 28 out of 32 cases (87.5%) (Fig 2) (El-Ghandour, 2011)

Endoscopy plays an important role in the treatment of complex hydrocephalus. Among 24 pediatric patients with multiloculated hydrocephalus operated by endoscopic cyst fenestration, improvement of hydrocephalus occurred in 18 cases (75%), the need for shunt insertion was avoided in 3 cases (12.5%), shunt revision rate was reduced from 2.9 per year before fenestration to 0.2 per year after fenestration. During the overall mean follow-up period (30 months), repeated endoscopic procedure was necessary in 8 cases (33%). Six out of these 8 patients (75%) had already undergone shunt placement before endoscopy (El-Ghandour, 2008).

Suprasellar arachnoid cysts, which cause hydrocephalus by obstructing the foramen of Monro, can be marsupialized to the ventricular system endoscopically (Fig 3). Excellent results have been obtained in a recent study including 25 pediatric patients operated by endoscopy. In this study, patients were divided into 2 groups. Patients in group A (11 patients) underwent ventriculocystostomy with a mean follow-up 55 months, and those in group B (14 patients) underwent ventriculocystocisternostomy with a mean follow-up of 64.7 months. Both procedures proved to be almost equally effective clinically and radiologically.

The incidence of improvement of hydrocephalus-related symptoms was 63.6% in group A, compared with 85.7% in group B. Improvement in cyst size and hydrocephalus after ventriculocystostomy was 81.8% and 63.6% respectively, compared with 100% and 85.7% respectively after ventriculocystocisternostomy (Fig 4). However because of the statistically significant difference between the incidence of recurrence after ventriculocystostomy and ventriculocystocisternostomy during the long-term follow-up (27.3% versus 0%,  $p < 0.05$ ), the author concluded that ventriculocystocisternostomy should be considered as the procedure of choice in the treatment of these cases (El-Ghandour, 2011).

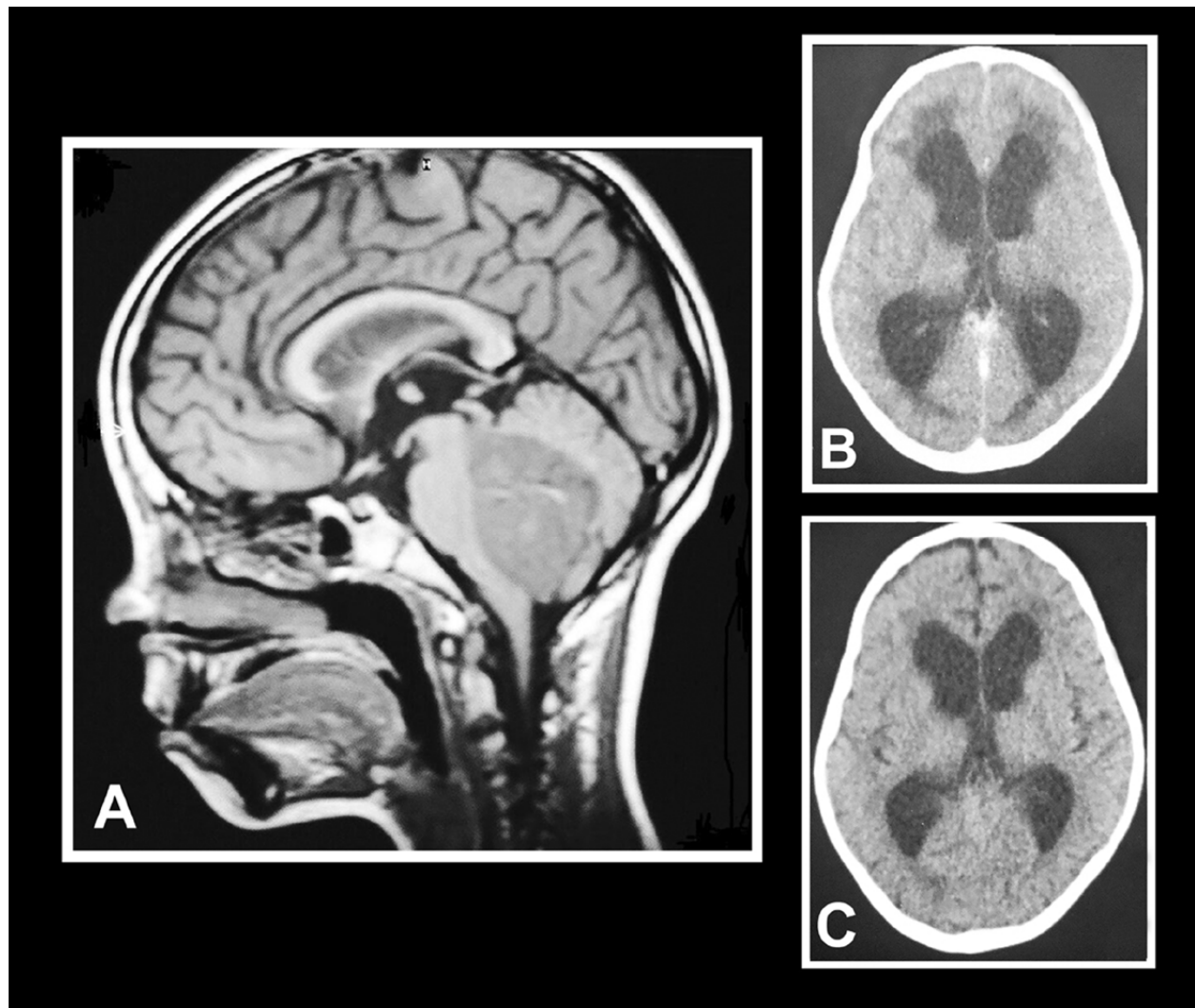


Fig. 2. A: Magnetic resonance imaging T1 weighted sagittal view of a case of posterior fossa tumor (medulloblastoma), demonstrating communication between third ventricle and prepontine cistern after endoscopic third ventriculostomy . B: Preoperative axial CT scan image showing severe obstructive hydrocephalus due to posterior fossa tumor. The presence of massive periventricular edema signifies acutely occurring hydrocephalus. C: Postoperative axial CT scan image obtained 3 days after endoscopic third ventriculostomy showing mild reduction in ventricular size, resolution of periventricular edema, and opening of subarachnoid space. [Reprinted with permission from El-Ghandour NM (2011). Endoscopic third ventriculostomy versus ventriculoperitoneal shunt in the treatment of obstructive hydrocephalus due to posterior fossa tumors in children. *Childs Nerv Syst*, Vol. 27, No. 1, (January 2011), pp. 117-126, ISSN 0256-7040].



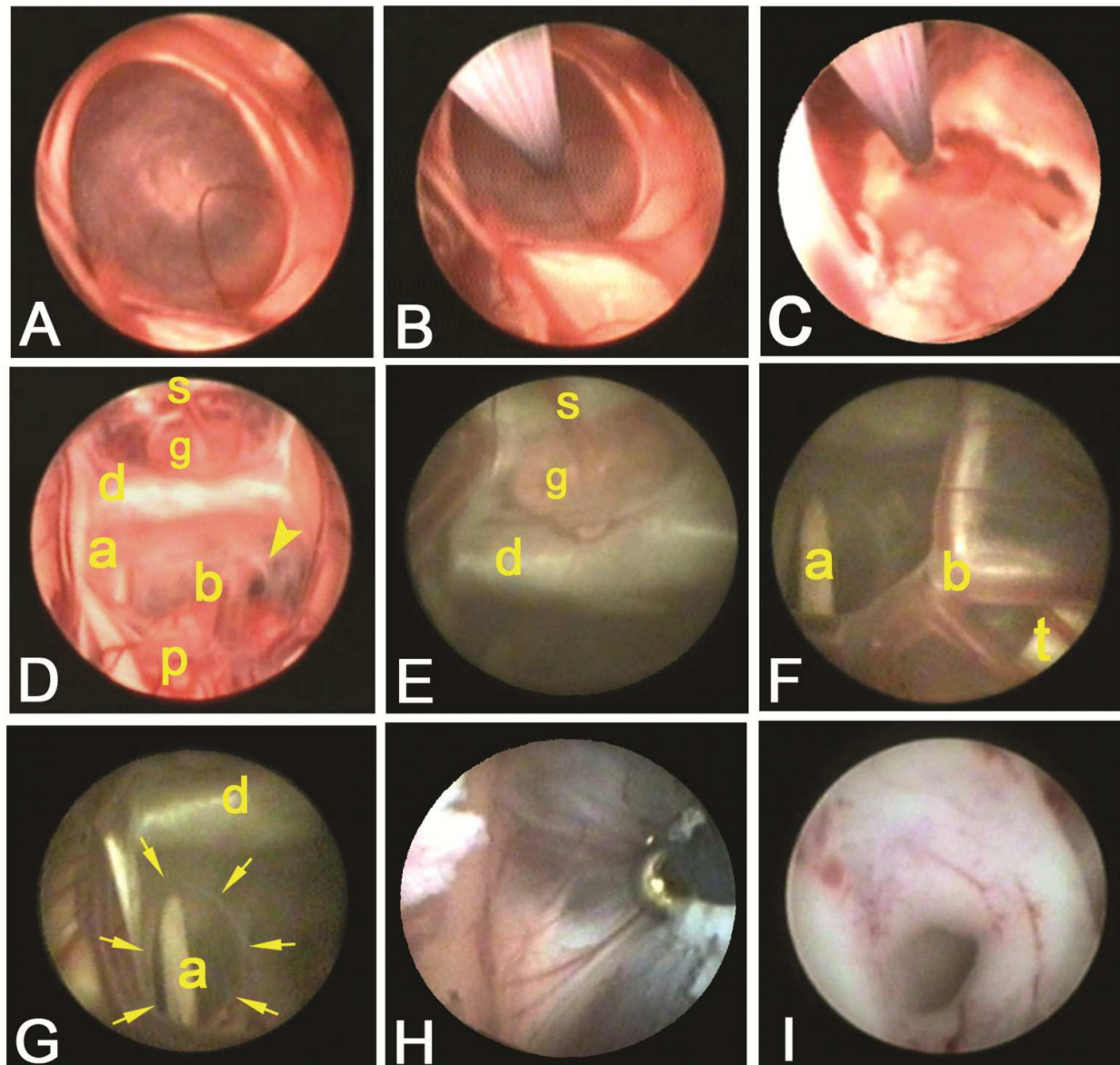


Fig. 3. Intraoperative neuroendoscopic views. A: Bluish-colored apical dome of suprasellar arachnoid cyst bulging through and obstructing the foramen of Monro. B: Opening of upper cyst wall using bipolar electrode. C: Ventriculocystostomy, widening of the fenestration is done by bipolar diathermy. D: Anatomical landmarks as seen through the cyst membrane; a = abducent nerve; b = basilar artery; d = dorsum sellae; g = pituitary gland; p = pons; s = pituitary stalk; arrow head = valve like structure. E: Suprasellar compartment showing pituitary gland (g), pituitary stalk (s), dorsum sellae (d). F: Prepontine compartment as seen through the cyst membrane, a = abducent nerve; b = basilar artery apex; t = trigeminal nerve. G: Cystocisternostomy, a = abducent nerve; d = dorsum sellae; arrows = fenestration. H: Shrinking of the cyst membrane by bipolar diathermy. I: At end of the procedure, the aqueduct of Sylvius is patent [Reprinted with permission from El-Ghandour NM (2011). Endoscopic treatment of suprasellar arachnoid cysts in children. *J Neurosurg Pediat* Vol. 8, No. 1, (July 2011), pp. 6-14, ISSN 1933-0707].



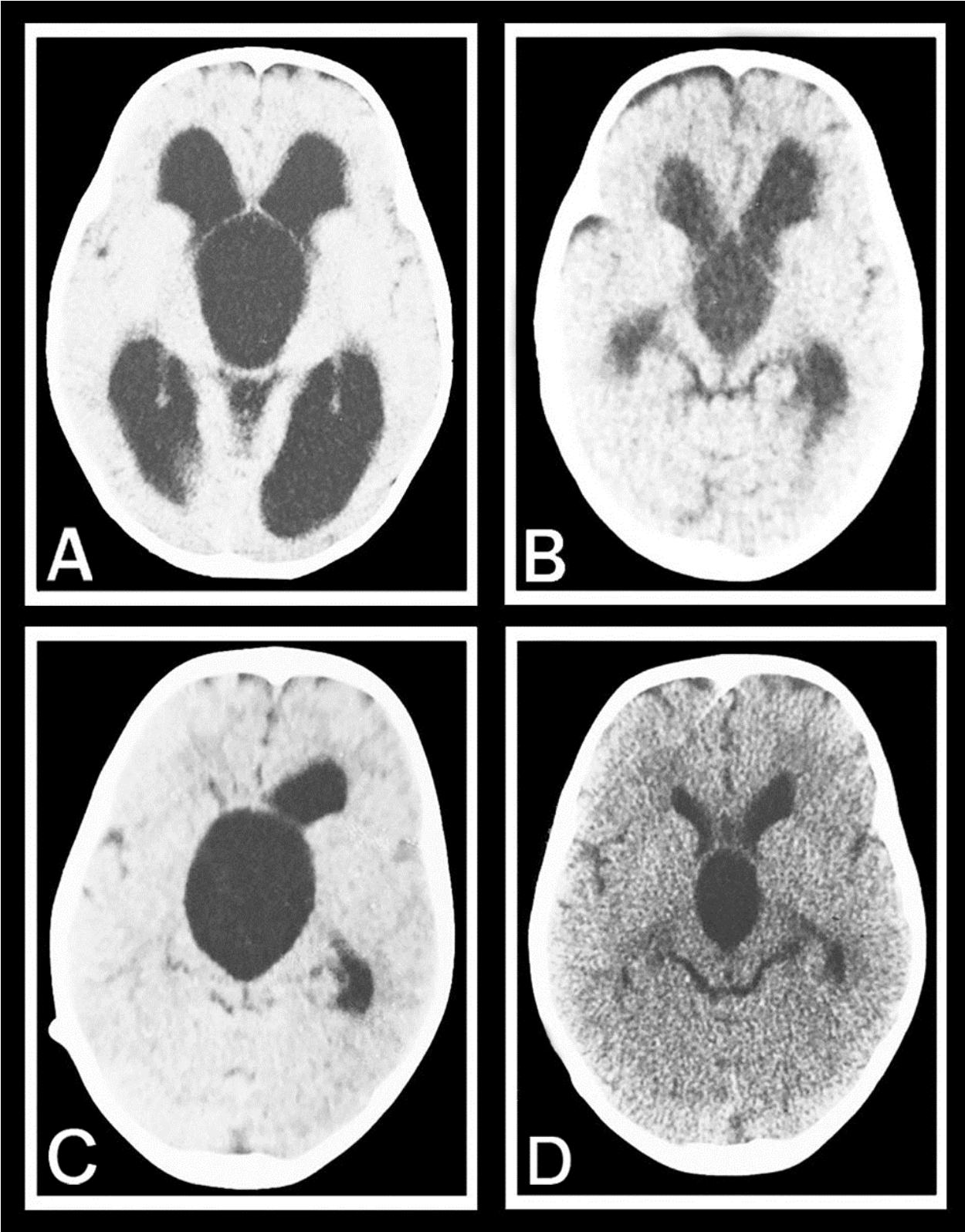


Fig. 4. A: Axial T1 weighted MR imaging showing a huge suprasellar arachnoid cyst with marked obstructive hydrocephalic changes. B: Axial CT scan performed 3 months after endoscopic ventriculocystocisternostomy showing apparent decrease in size of both the cyst and hydrocephalus with opening of the subarachnoid space. C: Axial CT scan showing

a huge suprasellar arachnoid cyst. A right sided ventriculoperitoneal shunt is seen, which was inserted in an outside institution due to a misdiagnosis of aqueduct stenosis. D: Axial CT scan performed 6 months after endoscopic ventriculocystocisternostomy and shunt removal showing apparent decrease in size of both the cyst and hydrocephalus with opening of the subarachnoid space [Reprinted with permission from El-Ghandour NM (2011). Endoscopic treatment of suprasellar arachnoid cysts in children. *J Neurosurg Pediat* Vol. 8, No. 1, (July 2011), pp. 6-14, ISSN 1933-0707].

Although there is an argument about the role of endoscopy in the management of normal pressure hydrocephalus, some studies have reported good outcome. In a series including 110 patients with idiopathic normal pressure hydrocephalus operated by endoscopic third ventriculostomy, postoperative clinical improvement occurred in 76 cases (69.1%). Among the 34 patients who did not improve, 24 (21.8%) were unchanged and stable on the postoperative follow-up examination, whereas 10 (9%) showed clinical progression despite the endoscopic treatment (Gangemi et al., 2008).

Neuroendoscopic management of third ventricular colloid cysts is emerging as a safe, effective alternative to microsurgery. Among 10 cases operated endoscopically in a recent study, near-total excision of the cyst was achieved in 8 cases (80%), all of them were anteriorly located within the third ventricle. In the remaining 2 cases (20%), excision was subtotal, and remnants of the cyst wall were left obstructing the aqueduct of Sylvius. These 2 cases were located in the posterior part of the third ventricle, endoscopic third ventriculostomy and septum pellucidotomy were performed in both of them (Fig 5). Restoration of the foramina of Monro was achieved in all the patients (100%) (El-Ghandour, 2009).

Endoscopic third ventriculostomy and concomitant endoscopic biopsy has been reported by many authors as the procedure of choice in the treatment of pineal region tumors. In cases such as germinomas, establishing pathological diagnosis is quite sufficient, and it obviates the need for open surgery, since these tumors are radiosensitive. In a series of 23 patients with pineal tumors operated by such strategy, the obtained tissue sample was sufficient for pathological diagnosis in all the cases (100%) (Chernov et al., 2006). Endoscopic biopsy has the advantage of being combined with endoscopic third ventriculostomy to treat hydrocephalus and obtain cerebrospinal fluid for tumor markers and cytology, and allows tissue bites to be taken under direct vision (Al-Tamimi et al., 2008).

## 7. Ventriculostomy versus shunting

There are many studies which discuss the role of endoscopic third ventriculostomy in the management of noncommunicating hydrocephalus, but the comparison between endoscopic third ventriculostomy and ventriculoperitoneal shunting has rarely been addressed in the literature. A recent study compares both procedures in the management of obstructive hydrocephalus due to posterior fossa tumors. It included 53 pediatric patients which were divided into 2 groups: group A (32 cases) operated by endoscopic third ventriculostomy and group B (21 cases) operated by ventriculoperitoneal shunting. Both procedures proved to be almost equally effective clinically and radiologically.

Intracranial hypertension symptoms improved in 31 out of 32 patients (96.9%) included in group A, and in all the patients (100%) included in group B. Improvement of hydrocephalus

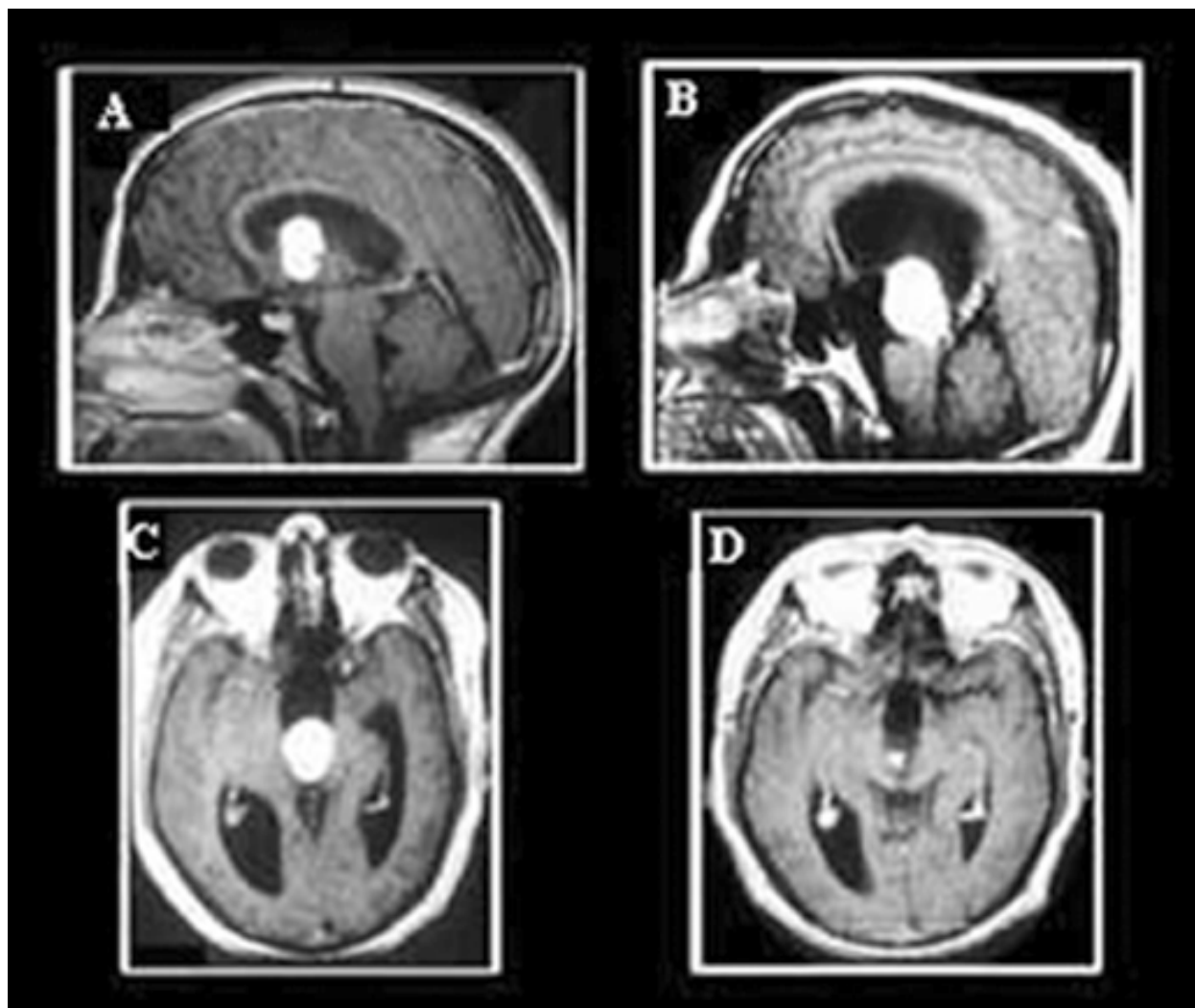


Fig. 5. A, Preoperative midsagittal MR imaging brain showing colloid cyst within the anterior aspect of the third ventricle. B, Preoperative midsagittal MR imaging brain showing colloid cyst within the posterior aspect of the third ventricle. C, Preoperative axial MR imaging brain of the same patient with posteriorly located colloid cyst. D, Postoperative axial MR imaging brain with gadolinium performed 1 year after endoscopic removal of the colloid cyst. Improvement of hydrocephalus and remnant of the cyst wall are noted. [Reprinted with permission from El-Ghandour NM (2009). Endoscopic treatment of third ventricular colloid cysts: a review including ten personal cases. *Neurosurg Rev*, Vol. 32, No. 4, (October 2009), pp. 395-402, ISSN 0344-5607].

in postoperative CT scan occurred in 28 out of 32 patients (81.3%) included in group A (Fig 2) and in all the 21 patients (100%) included in group B. The mean duration of surgery in group A was 15 minutes compared to 35 minutes in group B ( $p < 0.01$ , highly significant).

The incidence of complications after ventriculostomy was 9.3% (3 out of 32 cases) and after ventriculoperitoneal shunting was 38% (8 out of 21 cases). The difference in the incidence of complications between both groups is statistically significant ( $p < 0.05$ ). In group A, intraoperative bleeding occurred in 2 patients (it was minor and stopped spontaneously within few minutes with irrigation), and cerebrospinal fluid leakage occurred in 1 patient. In

group B, shunt infection occurred in 2 patients, one of these 2 patients died 4.5 months postoperatively from ventriculitis. Subdural collection occurred in 2 patients, and upward brain herniation in 1 patient (Table 1).

Morbidity and mortality	ETV group (32 cases)	VPS group (21 cases)	P value
Morbidity (Total)	3 (9.3%)	8 (38%)	0.03
Bleeding	2 (6.2%)	0	--
CSF leak	1 (3.1%)	0	--
Infection	0	2 (9.4%)	--
Subdural collection	0	2 (9.4%)	--
Epidural hematoma	0	1 (4.7%)	--
Upward herniation	0	1 (4.7%)	--
Pseudomeningocele	0	2 (9.4%)	--
Mortality (Total)	0	1 (4.7%)	0.8
Hydrocephalus-related	0	1 (4.7%)	0.8
Nonhydrocephalus-related	0	0	--

Table 1. Morbidity and mortality in 53 pediatric patients with obstructive hydrocephalus due to posterior fossa tumors  
ETV = endoscopic third ventriculostomy; VPS = ventriculoperitoneal shunt. [Reprinted with permission from El-Ghandour NM (2011). Endoscopic third ventriculostomy versus ventriculoperitoneal shunt in the treatment of obstructive hydrocephalus due to posterior fossa tumors in children. *Childs Nerv Syst*, Vol. 27, No. 1, (January 2011), pp. 117-126, ISSN 0256-7040].

Recurrence of hydrocephalus occurred in 2 out of 32 patients (6.2%) operated by endoscopic third ventriculostomy, at 6.5 and 14 months postoperatively respectively (both patients had intraoperative bleeding at initial surgery). Among 21 patients operated by ventriculoperitoneal shunting, shunt revision was performed 15 times in 8 patients. The incidence of recurrence of hydrocephalus was 6.2% among ventriculostomy patients, compared to 38% among shunt patients ( $p < 0.01$ , highly significant) (Table 2). All the 32 patients included in group A were shunt free among the mean follow-up duration of 27.4 months, whereas all the 21 patients included in group B were shunt dependent among the mean follow-up duration of 25 months.

The number of revisions per patient (among the 8 patients with postoperative failure included in group B) was 1.8, and the mean duration which lapsed between the shunting procedure and the first revision procedure was 5.6 months. Kaplan-Meier survival curve for both groups shows a more progressive decrease of the cumulative survival in the ventriculoperitoneal shunt group. The mean survival time in group A is higher than in group B (logrank test is highly significant,  $p < 0.01$ ) (Fig 6).

The author concluded that endoscopic third ventriculostomy is superior than ventriculoperitoneal shunting because of the shorter duration of surgery, the lower

incidence of morbidity, absence of mortality and the lower incidence of procedure failure. It renders the patient independent from a failure-prone shunt system, and offers a good opportunity to become shunt free. It is a preliminary, simple, safe, effective, minimally invasive and physiological method of bypassing obstruction in cerebrospinal fluid circulation in cases of obstructive hydrocephalus (El-Ghandour, 2011).

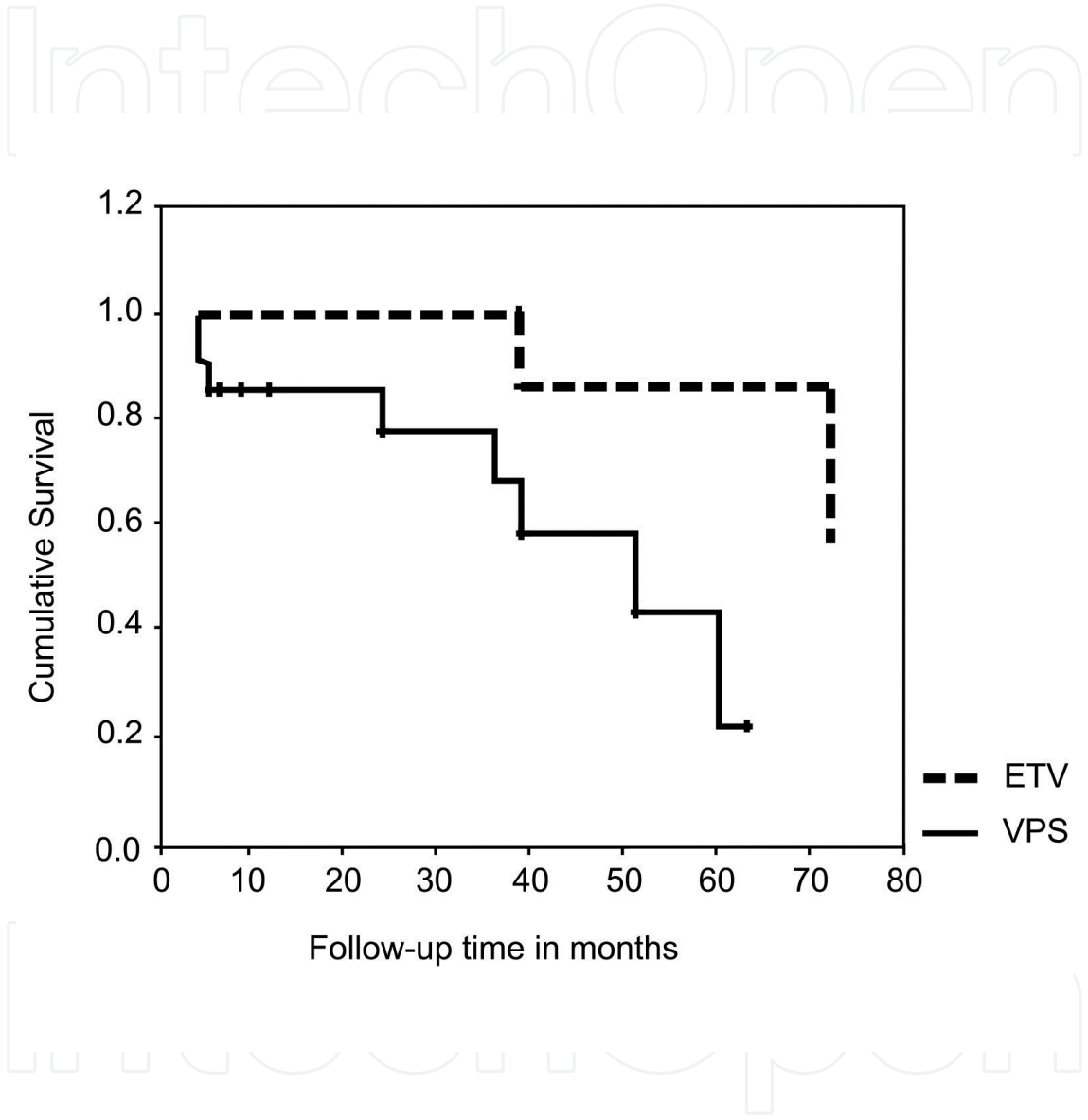


Fig. 6. Kaplan-Meier survival curve plotted for endoscopic third ventriculostomy (group A) and ventriculoperitoneal shunt (group B) showing a more progressive decrease of the cumulative survival in the ventriculoperitoneal shunt group. There is a higher mean survival time for endoscopic third ventriculostomy as compared to ventriculoperitoneal shunt (the logrank test is highly significant,  $p < 0.01$ ) [Reprinted with permission from El-Ghandour NM (2011). Endoscopic third ventriculostomy versus ventriculoperitoneal shunt in the treatment of obstructive hydrocephalus due to posterior fossa tumors in children. *Childs Nerv Syst*, Vol. 27, No. 1, (January 2011), pp. 117-126, ISSN 0256-7040].



Results of outcome	ETV group (32 cases)	VPS group (21 cases)	P value
Improvement of symptoms			
Intracranial hypertension	31/32(96.9%)	21/21(100%)	0.2
Gait ataxia	4/10(40%)	2/8(25%)	0.8
Sixth nerve palsy	6/9(66.7%)	3/6(50%)	0.9
Conscious level	4/4(100%)	2/2(100%)	--
Bulbar symptoms	0/2(0%)	0/3(0%)	--
Improvement of hydrocephalus (in postoperative C.T. scan)	28/32 (87.5%)	21/21(100%)	0.2
Duration of follow-up in months (mean $\pm$ SD)	27.4 ( $\pm$ 20.5)	25 ( $\pm$ 19.7)	0.6
Postoperative failure	2 (6.2%)	8 (38%)	0.003
Time to first failure in months (mean $\pm$ SD)	10.3( $\pm$ 5.3)	5.6( $\pm$ 4.6)	0.2
Shunt free patients	32 (100%)	0	--
Shunt dependent patients	0	21 (100%)	--
Number of revisions in postoperative failure patients (mean $\pm$ SD)	1	1.8( $\pm$ 0.8)	0.2

Table 2. Results of outcome in 53 pediatric patients with obstructive hydrocephalus due to posterior fossa tumors.  
ETV = endoscopic third ventriculostomy; VPS = ventriculoperitoneal shunt.; SD = standard deviation [Reprinted with permission from El-Ghandour NM (2011). Endoscopic third ventriculostomy versus ventriculoperitoneal shunt in the treatment of obstructive hydrocephalus due to posterior fossa tumors in children. *Childs Nerv Syst*, Vol. 27, No. 1, (January 2011), pp. 117-126, ISSN 0256-7040].

8. Conclusions

A significant advance in the treatment of hydrocephalus has been the evolution of endoscopy. Hydrocephalus represents the classic indication for a neuroendoscopic approach. Currently, hydrocephalus remains the most frequent intracranial disease treated endoscopically. The success of neuroendoscopy in recent years has relied heavily on the success of endoscopic third ventriculosromy in the treatment of obstructive hydrocephalus.

Endoscopic third ventriculostomy has become a well established procedure for the treatment of noncommunicating hydrocephalus. In our experience, third ventriculostomy has been successful in controlling obstructive hydrocephalus caused by posterior fossa tumors, and it was much more superior than shunting in terms of morbidity and incidence of procedure failure.

The role of endoscopy in the treatment of complex hydrocephalus is indispensable. Our results of using endoscopy in the treatment of these cases are encouraging. Endoscopic cyst fenestration has led to avoiding or eliminating the need for shunts in some cases, simplification of complex shunts and reduction of shunt revision rate. It can be also used as an adjunct to shunting. It improves the results of shunting, and it plays a crucial role in shunt revision and retrieval of malfunctioning ventricular catheters.

In addition to tumor biopsy sampling, the endoscope has been used for the resection of colloid cysts and other intraventricular lesions. Our results of using endoscopy in the treatment of these cases are excellent. The use of the neuroendoscope provides the unique ability to perform tumor resection, tumor biopsy sampling, restoration of obstructed cerebrospinal fluid pathways (e.g. foramen of Monro and aqueduct of Sylvius), performing endoscopic third ventriculostomy, and cerebrospinal fluid sampling, all can be done in a single procedure.

Over the last few years, the field of neuroendoscopy has been expanded to treat a wide array of neurosurgically managed conditions. A seemingly limitless number of neurosurgical applications await the endoscope. In the future, one can expect routine use of the endoscope in the management of hydrocephalus, either as the primary surgery or as an adjunct. The continued evolution of this modality will rely on new technological advances, improved understanding of endoscopically demonstrated neurosurgical anatomy, discovery of new applications, and the training of neurosurgeons. Endoscopy is expected to become a routine procedure in modern neurosurgical practice and training. Pediatric neurosurgeons should acquire the needed skill in using endoscopy in order to manage one of the most common neurosurgical problems in children, which is hydrocephalus.

## 9. References

- Abdou MS, Cohen AR (1998). Endoscopic treatment of colloid cysts of the third ventricle. Technical note and review of the literature. *J Neurosurg*, Vol. 89, No. 6, pp. 1062-1068, (December 1998), ISSN 0022- 3085
- Abtin K, Walker ML (1998): Endoscopic management of complex hydrocephalus. In: *Intracranial Endoscopic Neurosurgery*, Jimenez DF, pp. 135-145, AANS publication committee, ISBN 0-9624246-6-8, Illinois.
- Albright AL, Reigel DH (1977). Management of hydrocephalus secondary to posterior fossa tumors. *J Neurosurg*, Vol. 46, No. 1, (January 1977), pp. 52-55, ISSN 0022-3085
- Al-Tamimi YZ, Bhargava D, Surash S, Ramirez RE, Novegno F, Crimmins DW, Tyagi AK, Chumas PD (2008). Endoscopic biopsy during third ventriculostomy in pediatric pineal region tumors. *Childs Nerv Syst*, Vol. 24, No.11, (November 2008), pp. 1323-1326, ISSN 0256-7040
- Bradley WG Jr, Whittemore AR, Watanabe AS, Davis SJ, Teresi LM, Homyak M (1991). Association of deep white matter infarction with chronic communicating hydrocephalus: implications regarding the possible origin of normal-pressure


- hydrocephalus. *AJNR Am J Neuroradiol*, Vol.12, No. 1 (January- February 1991), pp. 31-39, ISSN 0195-6108
- Brockmeyer DL (1998). The use of endoscopes for shunt placement. In *Endoscopy of the central and peripheral nervous system*, King W, Frazee J & De Salles A, pp. 91-99, Thieme, ISBN 0- 86577-690-3, New York
- Chernov MF, Kamikawa S, Yamane F, Ishihara S, Kubo O, Hori T (2006). Neuroendoscopic biopsy of tumors of the pineal region and posterior third ventricle: indications, technique, complications and results. *Neurosurgery*, Vol. 59, No. 2, (August 2006), pp. 267-277, ISSN 0148-396x
- Cinalli G, Spennato P, Savarese L, Ruggiero C, Aliberti F, Cuomo L, Cianciulli E, Maggi G (2006). Endoscopic aqueductoplasty and placement of a stent in the cerebral aqueduct in the management of isolated fourth ventricle in children. *J Neurosurg* Vol. 104, No. 1 (Suppl Pediatrics), (January 2006), pp. 21-27, ISSN 0022-3085
- Cohen AR (1993). Endoscopic ventricular surgery. *Pediatr Neurosurg*, Vol. 19, No. 3, (May-June 1993), pp. 127-134, ISSN 1016-2291
- Culley DJ, Berger MS, Shaw D, Geyer R (1994). An analysis of factors determining the need for ventriculoperitoneal shunts after posterior fossa tumor surgery in children. *Neurosurgery*, Vol. 34, No. 3, (March 1994), pp. 402-408, ISSN 0148-396x
- Dandy WE (1918). Extirpation of the choroid plexus of the lateral ventricle in communicating hydrocephalus. *Ann Surg*, Vol. 70, No. 6, (December 1918), pp. 569-579, ISSN 0003-4932
- El-Ghandour NM (2006). Multiloculated hydrocephalus: A study of 24 patients operated by endoscopic cyst fenestration. *Neurosurgery*, Vol. 59, No. 2, (August 2006), p 477, ISSN 0148-396x (Abstr).
- El-Ghandour NM (2008). Endoscopic cyst fenestration in the treatment of multiloculated hydrocephalus in children. *J Neurosurg Pediatr*, Vol.1, No. 3, (March 2008), pp. 217-222, ISSN 1933-0707
- El-Ghandour NM (2009). Endoscopic treatment of third ventricular colloid cysts: a review including ten personal cases. *Neurosurg Rev*, Vol. 32, No. 4, (October 2009), pp. 395-402, ISSN 0344-5607
- El-Ghandour NM (2011). Endoscopic third ventriculostomy versus ventriculoperitoneal shunt in the treatment of obstructive hydrocephalus due to posterior fossa tumors in children. *Childs Nerv Syst*, Vol. 27, No. 1, (January 2011), pp. 117-126, ISSN 0256-7040
- El-Ghandour NM (2011). Endoscopic treatment of suprasellar arachnoid cysts in children. *J Neurosurg Pediatr*, Vol. 8, No. 1, (July 2011), pp. 6-14, ISSN 1933-0707
- Epstein FJ (1993). Medulloblastoma: indications for shunt placement. *Pediatr Neurosurg*, Vol.19, No. 6, (June 1993), pp. 300-302, ISSN 1016-2291
- Farwell JR, Dohrmann GJ, Flannery JT (1977). Central nervous system tumors in children. *Cancer*, Vol. 40, No. 6, (December 1977), pp 3123-3132, ISSN 1097-0142
- Fiorindi A, Longatti PL, Martinuzzi A (2004). Failure of endoscopic third ventriculostomy in treatment of idiopathic normal pressure hydrocephalus. *Minim Invasive Neurosurg*, Vol. 47, No. 6, (December 2004), pp. 342-345, ISSN 0946-7211
- Gaab MR, Schroeder HW (1998). Neuroendoscopic treatment of intraventricular tumors. In: *Intracranial Endoscopic Neurosurgery*, Jimenez DF, pp. 171-183, AANS publication committee, ISBN 0-9624246-6-8, Illinois.
- Gangemi M, Maiuri F, Naddeo M, Godano U, Mascari C, Broggi G, Ferroli P (2008). Endoscopic third ventriculostomy in idiopathic normal pressure hydrocephalus: an Italian multicenter study. *Neurosurgery*, Vol. 63, No. 1, (July 2008), pp. 62-69. ISSN 0148-396x

- Gore PA, Gonzalez LF, Rekate HL, Nakaji P (2008). Endoscopic supracerebellar infratentorial approach for pineal cyst resection : technical case report. *Neurosurgery*, Vol. 62, No. 3 (Suppl 1) (March 2008), pp. 108-109, ISSN 0148-396x
- Greitz D (2004). Radiological assessment of hydrocephalus : new theories and implications for therapy. *Neurosurg Rev*, Vol. 27, No. 3, (July 2004), pp. 145-167, ISSN 0344-5607
- Hellwig D, Bauer BL, Schulte M, Gatscher S, Riegel T, Bertalanffy H (2008). Neuroendoscopic treatment for colloid cysts of the third ventricle : the experience of a decade. *Neurosurgery* Vol. 62, No. 6, (Suppl 3) (June 2008), pp. 1101-1109, ISSN 0148-396x
- Jallo GI, Abbott R (1996). Introduction of a second working portal for neuroendoscopy. A technical note. *Pediatr Neurosurg*, Vol. 24, No.2, (February 1996), pp. 56-60, ISSN 1016-2291
- Jallo GI, Kothbauer KF, Abbott IR (2005). Endoscopic third ventriculostomy. *Neurosurg Focus*, Vol. 19, No. 6, (December 2005), E11, ISSN 1092- 0684
- Jeeves MA, Simpson DA, Geffen G (1979). Functional consequences of the transcallosal removal of intraventricular tumors. *J Neurol Neurosurg Psychiatry*, Vol. 42, No. 2, (February 1979), pp. 134- 142, ISSN 0022-3050
- Jimenez DF (1998). Third ventriculostomy. In: *Intracranial Endoscopic Neurosurgery*, Jimenez DF, pp. 101-110, AANS publication committee, ISBN 0-9624246-6-8, Illinois.
- Jones RFC, Stening WA, Brydon M (1990). Endoscopic third ventriculostomy. *Neurosurgery*, Vol. 26, No. 1, (January 1990), pp. 86-92, ISSN 0148-396x
- Lee M, Wisoff JH, Abbott R (1994). Management of hydrocephalus in children with medulloblastoma: prognostic factors for shunting. *Pediatric Neurosurg*, Vol.20, No. 4 (April 1994), pp. 240 -247, ISSN 1016-2291
- Lewis AI, Keiper GL, Crone KR (1995). Endoscopic treatment of loculated hydrocephalus. *J Neurosurg*, Vol.82, No.5, (May 1995), pp. 780-785, ISSN 0022- 3085
- Lewis AI, Crone KR (1998). Endoscopic removal of colloid cysts. In: *Intracranial Endoscopic Neurosurgery*, Jimenez DF, pp. 125-133, AANS publication committee, ISBN 0-9624246-6-8, Illinois.
- Li KW, Nelson C, Suk I, Jallo GI (2005). Neuroendoscopy : past, present, and future. *Neurosurg Focus*, Vol.19, No.6, (December 2005), E1, ISSN 1092- 0684
- Longatti P, Fiorindi A, Feletti A, Baratto V (2006). Endoscopic opening of the foramen of Magendie using transaqueductal navigation for membrane obstruction of the fourth ventricle outlets. Technical note. *J Neurosurg*, Vol. 105, No. 6, (December 2006), pp. 924-927, ISSN 0022-3085
- Mathiesen T, Grane P, Lindquist C, von Holst H (1993). High recurrence rate following aspiration of colloid cysts in the third ventricle. *J Neurosurg*, Vol. 78, No. 5, (May 1993), pp. 748-752,. ISSN 0022- 3085
- McNickle HF (1947). The surgical treatment of hydrocephalus. A simple method of performing third ventriculostomy. *Br J Neurosurg*, Vol. 34, No. 135, ( January 1947), pp. 302-307, ISSN 0268-8697
- Meier U, Zeilinger FS, Schonherr B (2000). Endoscopic third ventriculostomy versus shunt operation in normal pressure hydrocephalus: diagnostics and indication. *Minim Invasive Neurosurg*, Vol. 42, No. 2, (June 2000), pp. 87-90, ISSN 0946-7211
- Mitchell P, Mathew B (1999). Third ventriculostomy in normal pressure hydrocephalus. *Br J Neurosurg*, Vol. 13, No. 4 (August 1999), pp. 382-385, ISSN 0268-8697
- Mixter WJ (1923). Ventriculostomy and puncture of the floor of the third ventricle. *Boston Med Surg*. Vol. 188, (1923), pp. 277-278, ISSN 0003-4819
- Mohanty A (2005). Endoscopic options in the management of isolated fourth ventricles. Case report. *J Neurosurg: Pediatrics*, Vol. 103, No. 1, (July 2005), pp. 73-78, ISSN 0022-3085



- Mohanty A, Biswas A, Satish S, Vollmer DG (2008). Efficacy of endoscopic third ventriculostomy in fourth ventricular outlet obstruction. *Neurosurgery*, Vol. 63, No. 5 (November 2008), pp. 905-914, ISSN 0148-396x
- Nulsen FE, Spitz EB (1951). Treatment of hydrocephalus by direct shunt from ventricle to jugular vein. *Surgical Forum*, Vol. 2, (1951), pp. 399-403, ISSN 00718041
- Oi S, Matsumoto S (1986). Pathophysiology of aqueductal obstruction in isolated IV ventricle after shunting. *Childs Nerv Syst*, Vol. 2, No. 6, (June 1986), pp. 282-286, ISSN 0256-7040
- Oka K, Yamamoto M, Ikeda K (1993). Flexible endoneurosurgical therapy for aqueductal stenosis. *Neurosurgery*, Vol. 33, No. 2, (August 1993), pp. 236-243, ISSN 0148-396x
- Papo I, Caruselli G, Luongo A (1982). External ventricular drainage in the management of posterior fossa tumors in children and adolescents. *Neurosurgery*, Vol. 10, No. 1, (January 1982), pp. 13-15, ISSN 0148-396x
- Polednak AP, Flannery JT (1995). Brain, other central nervous system, and eye cancer. *Cancer*, Vol. 75, No.1 (Suppl 1) (January 1995), pp. 330-337, ISSN 1097-0142
- Pudenz RH (1981). The surgical treatment of hydrocephalus: a historical review. *Surg Neurol*, Vol. 15, No. 1, (January 1981), pp. 15-26, ISSN 0090-3019
- Raimondi AJ, Tomita T (1981). Hydrocephalus and infratentorial tumors. Incidence, clinical picture, and treatment. *J Neurosurg*, Vol. 55, No. 2, (August 1981), pp. 174-182, ISSN 0022-3085
- Ray P, Jallo GI, Kim RY, Kim BS, Wilson S, Kothbauer K, Abbott R (2005). Endoscopic third ventriculostomy for tumor-related hydrocephalus in a pediatric population. *Neurosurg Focus*, Vol. 19, No. 6, (December 2005), E8, ISSN 1092-0684
- Scarff JE (1935) Third ventriculostomy as the rational treatment of obstructive hydrocephalus. *J Pediatr*, Vol. 6, (1935), pp. 870-871, ISSN 0022-3476
- Shin M, Morita A, Asano S, Ueki K, Kirino T (2000). Neuroendoscopic aqueductal stent placement procedure for isolated fourth ventricle after ventricular shunt placement. *J Neurosurg*, Vol. 92, No. 6, (June 2000), pp. 1036-1039, ISSN 0022-3085
- Schroeder HW, Gaab MR (1999). Endoscopic aqueductoplasty: technique and results. *Neurosurgery*, Vol. 45, No. 3, (September 1999), pp. 508-518, ISSN 0148-396x
- Schroeder HW, Gaab MR (1999). Intracranial endoscopy. *Neurosurg Focus*, Vol. 6, No. 4 (April 1999), E1, ISSN 1092-0684
- Schroeder HW, Niendorf WR, Gaab MR (2002). Complications of endoscopic third ventriculostomy. *J Neurosurg*, Vol. 69, No. 6, (June 2002), pp. 1032-1040, ISSN 0022-3085
- Teo C (1998). Endoscopy for the treatment of hydrocephalus. In *Endoscopy of the central and peripheral nervous system*, King W, Frazee J & De Salles A, pp. 59-67, Thieme, ISBN 0-86577-690-3, New York
- Upchurch K, Raifu M, Bergsneider M (2007). Endoscope-assisted placement of a multiperforated shunt catheter into the fourth ventricle via a frontal transventricular approach. *Neurosurg. Focus*, Vol. 22, No. 4 (April 2007), E8, ISSN 1092-0684
- Walker ML (2001). History of ventriculostomy. *Neurosurg Clin N Am*, Vol. 12, No.1 (January 2001), pp. 101-110, ISSN 1042-3680
- Yamini B, Refai B, Rubin CM, Frim DM (2004). Initial endoscopic management of pineal region tumors and associated hydrocephalus: clinical series and literature review. *J Neurosurg*, Vol. 100, No. 5 (Suppl Pediatrics), (May 2004), pp. 437-441, ISSN 0022-3085





## **Hydrocephalus**

Edited by Dr Sadip Pant

ISBN 978-953-51-0162-8

Hard cover, 214 pages

**Publisher** InTech

**Published online** 24, February, 2012

**Published in print edition** February, 2012

Description of hydrocephalus can be found in ancient medical literature from Egypt as old as 500 AD. Hydrocephalus is characterized by abnormal accumulation of cerebrospinal fluid (CSF) in the ventricles of the brain. This results in the rise of intracranial pressure inside the skull causing progressive increase in the size of the head, seizure, tunneling of vision, and mental disability. The clinical presentation of hydrocephalus varies with age of onset and chronicity of the underlying disease process. Acute dilatation of the ventricular system manifests with features of raised intracranial pressure while chronic dilatation has a more insidious onset presenting as Adams triad. Treatment is generally surgical by creating various types of cerebral shunts. Role of endoscopic has emerged lately in the management of hydrocephalus.

### **How to reference**

In order to correctly reference this scholarly work, feel free to copy and paste the following:

Nasser M. F. El-Ghandour (2012). Role of Endoscopy in Management of Hydrocephalus, Hydrocephalus, Dr Sadip Pant (Ed.), ISBN: 978-953-51-0162-8, InTech, Available from:  
<http://www.intechopen.com/books/hydrocephalus/role-of-endoscopy-in-management-of-hydrocephalus>

**INTECH**  
open science | open minds

### **InTech Europe**

University Campus STeP Ri  
Slavka Krautzeka 83/A  
51000 Rijeka, Croatia  
Phone: +385 (51) 770 447  
Fax: +385 (51) 686 166  
[www.intechopen.com](http://www.intechopen.com)

### **InTech China**

Unit 405, Office Block, Hotel Equatorial Shanghai  
No.65, Yan An Road (West), Shanghai, 200040, China  
中国上海市延安西路65号上海国际贵都大饭店办公楼405单元  
Phone: +86-21-62489820  
Fax: +86-21-62489821

© 2012 The Author(s). Licensee IntechOpen. This is an open access article distributed under the terms of the [Creative Commons Attribution 3.0 License](https://creativecommons.org/licenses/by/3.0/), which permits unrestricted use, distribution, and reproduction in any medium, provided the original work is properly cited.

IntechOpen

IntechOpen