

# We are IntechOpen, the world's leading publisher of Open Access books Built by scientists, for scientists

6,900

Open access books available

185,000

International authors and editors

200M

Downloads

Our authors are among the

154

Countries delivered to

TOP 1%

most cited scientists

12.2%

Contributors from top 500 universities



WEB OF SCIENCE™

Selection of our books indexed in the Book Citation Index  
in Web of Science™ Core Collection (BKCI)

Interested in publishing with us?  
Contact [book.department@intechopen.com](mailto:book.department@intechopen.com)

Numbers displayed above are based on latest data collected.  
For more information visit [www.intechopen.com](http://www.intechopen.com)



## Diabetic Macular Edema

Christina Antonopoulos and Manju Subramanian  
*Boston University School of Medicine*  
 USA

### 1. Introduction

Diabetic macular edema represents one of the most important causes of visual morbidity in diabetes mellitus. The National Diabetes Information Clearinghouse estimates the prevalence of diabetes mellitus types 1 and 2 at 11.3% of the population above the age of 20, with an annual incidence of 1.9 million cases in the United States alone. In this population, the prevalence of diabetic macular edema is estimated at 30% of patients inflicted by the disease for 20 years or more. Diabetes mellitus is the leading cause of preventable blindness owing to both diabetic macular edema and complications of proliferative diabetic retinopathy (NDIC 2011). Thus one can expect that diabetic macular edema is a common entity in any Retina specialty practice with serious implications for vision loss if not treated in a timely and appropriate manner. Based on the critical findings of the Early Treatment in Diabetic Retinopathy Study, the standard of care has been focal laser photocoagulation therapy along with strong recommendations for strict blood glucose and blood pressure control. However since then, the spectrum of therapies for diabetic macular edema has expanded and continues to evolve. The use of steroid therapy and anti-vascular endothelial growth factor biologics have been compared to focal laser photocoagulation in order to establish more treatment options with equivalent efficacy and safety.

The following chapter is a comprehensive review of the basic pathophysiology, symptomatology, clinical findings, diagnostic methods, indications for intervention, and treatment modalities of diabetic macular edema. Careful attention is given to the review of treatment modalities, including steroid therapy, Anti-VEGF pharmacotherapy (sister drugs Lucentis (ranibizumab) and Avastin (bevacizumab)) and surgical techniques. A literature review is also summarized comparing these methods to focal laser photocoagulation therapy. Thus this chapter is designed to give the reader a fuller understanding of the diabetic macular edema as a clinical entity and how it can be addressed so as to preserve vision.

### 2. Pathophysiology

Diabetic macular edema is a microvascular complication of diabetes mellitus with serious implications for vision loss. The central pathophysiologic event is retinal capillary incompetence and leakage. Several biochemical hypotheses exist to explain the damage to retinal capillary constituents in diabetes mellitus. Prolonged hyperglycemia has been

implicated in direct injury to retinal capillary endothelial cell and pericytes and to a decline in cell division (Engerman 1987). Cells in the body produce energy from the metabolism of glucose. The sorbitol (or polyol) pathway concurrently employs aldose reductase to reduce unused glucose to sorbitol (Brownlee 2001). Under normal circumstances cells metabolize glucose primarily via glycolysis, particularly because at a physiologic serum concentration, aldose reductase has a low affinity for glucose. However, high serum glucose concentrations can saturate the glycolysis pathway, making excess glucose molecules available for reduction to sorbitol by the avidly-binding aldose reductase. Excessive activation of the sorbitol pathway in hyperglycemia results in an accumulation of sorbitol in the intracellular space which has been considered toxic to cells, in particular to retinal capillary endothelial cells and pericytes (Brownlee 2001).

Retinal capillary walls normally consist of a succinct network of endothelial cells and mural pericytes, which exist in a deliberate one-to-one ratio. In the 1950s, Kuwabara and Cogan developed Trypsin digest studies in retinal tissue of diabetic human subjects, which made possible the close examination of the retinal vasculature by light microscopy (Kuwabara 1960). These retinal digest studies were the first of their kind to demonstrate the key pathologic events of diabetic retinopathy. The biochemical derangements of diabetes mellitus cause a preferential loss of pericytes, identified histologically as empty “balloon-like spaces” or “ghost cells” along retinal capillary walls (Kuwabara 1960). Immunologic studies have demonstrated that mural pericytes contain properties that make them structurally analogous to the smooth muscle layer of larger scale blood vessels. The contractile nature and tonus of pericytes contribute to the structural integrity of the retinal capillary wall (Herman 1985). Therefore, a loss of mural pericytes may cause focal weakening and saccular dilatation of retinal capillaries, identified biomicroscopically as microaneurysms. Microaneurysms are readily detected on close fundoscopic examination and by fluorescein angiography and are one of the earliest signs of nonproliferative diabetic retinopathy (Freidenwald 1950). They are visually indistinguishable from dot intraretinal hemorrhages and thus represent areas of focal retinal vasculature incompetence.

The breakdown of the inner blood retinal barrier at the level of the retinal capillary endothelial cells likewise contributes to capillary incompetence. This breakdown largely occurs with an opening of tight junctions, or *zonulae occludentes*, between adjacent endothelial cells (Green 1985). The pathophysiologic outcome of inner blood retinal barrier compromise and abnormally permeable microaneurysms is an unchecked leakage of erythrocytes, plasma, and lipoproteins into the retinal interstitium. Retinal edema results once this fluid leakage overwhelms the capacity of the retinal pigment epithelial pump to remove it. The sequelae of vascular incompetence and retinal edema include (1) precipitation of serum lipoproteins in the retinal interstitium, causing a disruption of the delicate retinal architecture and (2) retinal arteriolar closure, resulting in focal retinal ischemia (Ryan 1989).

Retinal arteriolar closure characterizes a more advanced stage of nonproliferative retinopathy and carries more serious implications for widespread retinal ischemia and progression to proliferative disease (Ryan 1989). Several mechanisms of arteriolar occlusion have been hypothesized, implicating both intraluminal and extraluminal forces. Firstly, erythrocyte and platelet agglutination and defective fibrinolysis may cause intraluminal occlusion of arterioles (Little 1981). Endothelial cell basement membrane thickening, a

general histologic characteristic of diabetes mellitus, potentially causes luminal narrowing and occlusion. The accumulation of interstitial fluid and protein leads to increased tissue oncotic pressure and tissue turgor which may cause vascular closure by means of direct compression (Ryan 1989). Macular ischemia resulting from closure of retinal capillaries and arterioles may exacerbate concurrent macular edema.

Deformational macular edema caused by tractional membranes on the retinal surface is often observed in diabetic retinopathy either alone or in the presence of underlying diabetic macular edema (Clarkson 1977). Epiretinal membranes and a taut posterior hyaloid are the most common examples of tractional membranes. Epiretinal membranes are fibrocellular membranes caused by the migration and proliferation of retinal glial cells along the retinal surface. Their origin can be idiopathic or as a consequence of diabetic retinopathy or retinal vascular disorders. Depending on their severity, epiretinal membranes can cause retinal distortion and tractional retinal edema that is evident on both fundoscopy and fluorescein angiography (as cystoid macular edema). Epiretinal membranes can thus exacerbate underlying DME. The posterior hyaloid face of the vitreous can likewise cause deformational macular edema by exerting antero-posterior forces on the macula, as observed in the vitreomacular traction (VMT) syndrome. This is an idiopathic condition characterized by abnormal adhesion of the posterior hyaloid to the macula. As seen with epiretinal membranes, there may be tractional edema causing leakage in the macula and from the optic nerve head on fluorescein angiography (Hikichi 1995). Several hypotheses have attempted to explain the VMT syndrome: (1) Glycation of the vitreous: abnormal crosslinking of cortical vitreous in systemic hyperglycemic with tractional adherence to the macula causing a secondary deformation of retinal architecture (Dillinger 2004); (2) sequestration of pro-inflammatory factors or compounds in the pre-macular area by the posterior hyaloid that increase vascular permeability (Dillinger 2004); (3) frank, idiopathic contraction of the posterior hyaloid face with resultant deformational edema (Figueroa 2008).

The metabolic derangements of diabetes mellitus take a serious toll on the smallest constituents of the retinal vasculature. These early changes eventually manifest themselves on a macroscopic level, causing a generalized dysfunction of the blood retinal barrier, pathologic retinal edema, retinal vascular compromise and closure, tissue ischemia, and the potential for serious loss of visual acuity.

### 3. Clinical considerations

Macular edema is the terminology applied when careful fundoscopic examination reveals retinal thickening (with or without retinal exudates) within two disc diameters of the central macula. It may be observed at any stage of diabetic retinopathy, from minimal background diabetic retinopathy to active proliferative disease. The classic signs of background (nonproliferative) diabetic retinopathy are dot-blot hemorrhages, microaneurysms, hard exudates, and cotton wool spots. Dot-blot hemorrhages are intraretinal hemorrhages located in the outer retinal layers that directly result from incompetent retinal capillaries. Small, dot hemorrhages may be clinically indistinguishable from microaneurysms; whereas “blot” hemorrhages tend to be larger with indistinct borders located in the outer plexiform layer. Hard exudates are discrete, often confluent, yellow-white intraretinal accumulations of

precipitated serum lipid. Their presence is likewise strong evidence of retinal capillary leakage. Cotton wool spots are thusly named due to their fluffy, white appearance in the retina. They represent foci of ischemic retinal whitening in areas of retinal capillary closure. Cotton wool spots may resolve over time without necessarily promoting retinal neovascularization. However, a high density of cotton wool spots in any single area may suggest more severe underlying ischemia and a greater risk of progression to proliferative disease.

Macular edema may exist in several forms, each of which require specific treatment strategies and may vary greatly in terms of visual prognosis. Macular edema is primarily characterized as focal or diffuse. Focal macular edema represents retinal thickening involving localized areas of the macula, usually from a single microaneurysm or of clusters of them. Focal edema is often in the form of a microaneurysm with a surrounding circinate ring of precipitated hard exudates (or plasma lipoproteins), which delineates edematous from non-edematous retina (Gass 1987). Plasma lipoproteins most commonly accumulate in the outer plexiform layer but may be deposited in the subretinal space causing an independent decline in vision if the fovea is involved. Diffuse macular edema corresponds to a more generalized retinal capillary incompetence with extensive fluid leakage in the macula. Additionally, although not generally considered an element of diabetic macular edema (DME), incompetence in the outer blood-retinal barrier has been implicated in diffuse edema (Bresnick 1986). Experimental animal models have suggested that loss of retinal pigment epithelial cell tight junctions and RPE necrosis in diabetes mellitus possibly lead to abnormal permeability from the choroid (Kirber 1980). This often leads to cystoid macular edema and is not necessarily associated with exudates. Both eyes are usually symmetrically affected, demonstrating the same severity of edema and visual acuity. Systemic factors such as glycemic control, blood pressure, and fluid retention status may alter the clinical appearance of diffuse macular edema, with periodic resolution and exacerbation even without therapeutic intervention (Ryan 1989).

Recently, the use of the terminology “focal” versus “diffuse” diabetic macular edema has come under scrutiny. Some critics of this terminology have argued that it is not precise as there may be great overlap between these two entities in terms of visual morbidity, management options, and prognosis. More accurate descriptors should ideally include information regarding the following characteristics: location and extent of edema, central foveal involvement or sparing, and the extent and location of associated exudation (Browning 2008).

Macular edema is a common cause of visual acuity loss, particularly in the context of poorly controlled blood glucose levels. However, vision can be preserved for months to years even with clinically significant diabetic macular edema. Thus the presence of excellent visual acuity does not contraindicate treatment of diabetic macular edema. In the majority of cases, macular edema does eventually lead to a decline in visual acuity, which is potentially reversible if the edema is successfully treated once the diagnosis is made. Chronic DME can cause a profound disruption of the retinal architecture. Cystoid maculopathy, characterized by retinal degeneration and atrophy in the macula, is typically resistant to even aggressive therapy and holds a poor visual prognosis.



A consequence of retinal capillary and arteriolar closure in diabetic retinopathy is the disruption of the fine capillary network surrounding the fovea (Hayreh 2008). The end stage of retinal vascular incompetence, capillary and arteriolar closure is macular ischemia, which results from compromised oxygen delivery in the macula (Hayreh 2008). Retinal edema and exudation in DME will increase the length of the pathway for diffusion of oxygen in to the vessel-devoid foveal avascular zone (Hayreh 2008). The inability to sustain the oxygen demands of this tissue will invariably have visual consequences, particularly once breakdown of the perifoveal capillary network is documented angiographically. Visual acuity is generally not affected until the diameter of the foveal avascular zone (usually 500 microns) exceeds 1000 microns (Ryan 1989). However, once this occurs, irreversible loss of visual acuity can be expected. Macular ischemia will compound diabetic macular edema; thus, when coexistent, it is often difficult to determine which has a greater effect on visual acuity. Such eyes tend to have poorer general prognosis, with a blunted response to focal laser therapy.

#### 4. Clinical assessment

The characteristics of diabetic macular edema are best assessed by a combination of slit lamp biomicroscopy, fundus photography, fluorescein angiography, and more recently optical coherence tomography (OCT). The basic pathophysiologic lesions discussed above may be readily apparent in the posterior pole on fundoscopic examination with contact or noncontact lenses. Macular edema is detected as a thickening in the retinal layers with stereoscopic, binocular viewing. Mild retinal edema may escape detection whereas frank macular edema is typically quite apparent, particularly with coexisting intraretinal hemorrhage and hard exudate. Stereoscopic fundus photographs have been the standard method of quantifying diabetic macular edema in clinical trials (Davis 2008).

In ophthalmoscopically normal eyes, early changes in diabetic retinopathy may be detected by fluorescein angiography. A fluorescein angiogram is obtained when information about the structure and integrity of the retinal circulation is needed. However, it should not be used specifically to evaluate for the presence of DME. Fluorescein dye (a green vegetable-based dye) is injected into a vein in the antecubital fossa and a series of timed photographs are taken of the fundi. As previously stated, diabetic macular edema is a disease of retinal capillary incompetence with leakage of serum and blood products into the retinal interstitium. While fluorescein is largely bound to protein and the surface of erythrocytes in the blood column, approximately 20% of molecules are unbound (Richard 2008). Therefore, in the setting of inner blood retinal barrier compromise, there will be an egress of fluorescein into the retinal interstitium. The earliest evidence of this in background diabetic retinopathy is leakage from retinal microaneurysms, detectable as early punctate hyperfluorescence in the posterior pole. Macular edema is demonstrated as expanding hyperfluorescence from punctate foci in mid and late phases of the study. When cystoid macular edema is present, the leakage may be in a petaloid pattern.

Time domain and spectral domain optical coherence tomography (OCT) are newer imaging modalities commonly employed in the evaluation of diabetic macular edema. OCT provides qualitative cross-sectional images and retinal thickness maps as well as quantitative

thickness estimates of the central macular subfield. The use of OCT as a diagnostic tool in diabetic macular edema has been investigated. Officially, the diagnosis of diabetic macular edema is made by specific fundoscopic criteria established by the ETDRS. Recent studies have compared OCT to fundus photography in order to validate the role of the former in diagnosing DME. For example, a 2008 study by the Diabetic Retinopathy Clinical Research Network demonstrated a moderate correlation between retinal thickness measurements rendered by time domain OCT (Zeiss Stratus OCT3) and area of retinal thickening determined by stereoscopic fundus photographs (Davis 2008). Furthermore, the authors report that OCT may be more sensitive than fundus photographs in measuring the change in retinal thickness over time and, in particular, after treatment of DME. While visual acuity itself remains the most important correlate of the severity of diabetic macular edema, this study demonstrated only a weak correlation between OCT retinal thickness estimates and visual acuity. Nevertheless, the group concluded that OCT is an acceptable method of quantifying diabetic macular edema and suggested the possibility of its use in future clinical trials evaluating the efficacy of treatment modalities. Furthermore, the use of OCT to guide focal laser photocoagulation therapy was suggested in a prospective interventional comparative study comparing it with fluorescein angiogram-guided treatment (Gallego-Pinazo 2011).

OCT has become an indispensable imaging study in the early detection of diabetic macular edema and in the assessment of treatment response. OCT is likewise helpful in the diagnosis of tractional forces impacting macula edema such as epiretinal membranes and vitreomacular abnormalities, which are not as easily assessed by fundoscopy. Prior to such imaging techniques assessment of vitreomacular traction was certainly less accurate.

## 5. Management

The Early Treatment in Diabetic Retinopathy Study (ETDRS), sponsored by the National Eye Institute in 1979, was a benchmark in the management of diabetic macular edema (ETDRS 1985). The ETDRS was a large-scale, multicenter, randomized clinical trial designed to investigate whether early treatment of macular edema by focal argon laser photocoagulation could prevent moderate visual loss, defined as a loss of three lines of vision or a doubling of the visual angle. Eyes with macular edema in the setting of mild to moderate nonproliferative diabetic retinopathy with a visual acuity of 20/40 or worse were recruited and divided into two treatment groups: immediate versus delayed focal laser photocoagulation. The standard technique and parameters of focal laser therapy were detailed by the ETDRS as follows: a laser spot size of 50-100 microns and duration of 0.10 seconds to focal microaneurysms observed with contact lens fundoscopy. When the macular edema is more diffuse, a grid pattern of similar parameters may be applied. Laser burns are titrated to a slight graying of the treated retina (ETDRS 1985; ETDRS 1987). Based on three years of follow-up data, the ETDRS concluded that immediate focal photocoagulation halved the rate of moderate visual loss. When patients were stratified in terms of severity of initial macular edema, the benefit of immediate focal laser therapy was maximized in patients with “clinically significant macular edema” (CSME). As such, the ETDRS defined CSME, which is characterized as follows:

- retinal edema located at or within 500 microns of the foveal center
- hard exudates at or within 500 microns of the foveal center if associated with thickening of adjacent retina
- a zone of retinal thickening larger than 1 disc area within 1 disc diameter of the foveal center (ETDRS 1985)

This treatment strategy implies that is that macular edema which does not satisfy the above characteristics may be closely observed clinically until the criteria are satisfied (ETDRS 1987).

Subclinical macular edema (SCME) is a term used to describe macular edema in which fluid or leakage is detected on optical coherence tomography or fluorescein angiography, but not detected clinically on examination, or if detected on examination, did not meet the definition of CSME as defined by the ETDRS. This has been quantified as a central retinal subfield thickness ranging from 200 to 300 microns (by third generation Zeiss Stratus OCT). A recent retrospective case-controlled study compared type II diabetics with SCME to age, sex, and disease duration-matched controls without macular edema (defined as central subfield thickness <200 microns). This study aimed to identify the risk factors and relative risk for progression to CSME from SCME. It found that a prior history of CSME, advancing age and graded increases in central retinal thickness over time increased the likelihood of progression to CSME in patients with subclinical edema (Bhavsar 2011).

Further analysis of ETDRS data revealed that eyes with center-involving CSME (i.e. intraretinal fluid involving the fovea) versus eyes with CSME without central involvement (i.e. encroaching upon but sparing fixation) demonstrated a differential response to focal laser therapy (ETDRS 1985). The ETDRS presented data indicating that treatment of center-involving CSME resulted in a 67% decrease in the rate of visual loss (defined as 15 or more letter at three years). However, the treatment of center-sparing CSME resulted in only an approximate 45% decrease in the rate of visual loss. The ETDRS was not designed to determine the most appropriate timing for focal laser therapy. However, based on its conclusions, immediate focal laser photocoagulation is recommended in both morphologies of CSME.

The management of diabetic macular edema has expanded since publication of the ETDRS findings. At present, treatment options are quite broad, incorporating proven and new therapies (or combinations of them), each designed to target a central pathophysiologic mechanism of the disease. Three proven methods exist to decrease the long-term risk of vision loss from DME, namely (1) tight blood sugar control (proven in Diabetes Control and Complications Trial (DCCT) and United Kingdom Prospective Diabetes Study (UKPDS)); (2) blood pressure control (UKPDS); and (3) focal laser photocoagulation therapy (ETDRS) (ETDRS 1985; DCCT 1983; UKPDS 1998).

Observation with encouragement of tight glycemic and blood pressure control is an option, particularly in subclinical macular edema (SCME). While spontaneous resolution of macular edema with excellent control of systemic risk factors is entirely possible, observation of patients deemed at high risk for clinical worsening is not advisable. In fact, the ETDRS did recommend focal laser therapy for macular edema outside 500 microns of fixation in the context of poor glycemic control (ETDRS 1985).



### 5.1 Focal laser photocoagulation therapy

Since the findings of ETDRS, focal laser photocoagulation remains the standard of care for the treatment of diabetic macular edema. The effects of focal laser in controlling macular edema are relatively long-lasting, demonstrated at up to three years. However, as was reported by the ETDRS, only 17% of eyes with baseline vision of worse than 20/40 experienced modest visual improvement, and a certain proportion of patients did not respond to focal laser therapy at all (ETDRS 1985). It is generally accepted that diffuse DME or cystoid macular edema in fixation precludes treatment by focal laser by virtue of its location. The more severe entities of DME have served as an impetus in the search for adjunctive or stand-alone pharmacotherapy in the treatment of diabetic macular edema.

### 5.2 Steroid agents

Steroid agents were an earlier first-line pharmacotherapy for diabetic macular edema. Triamcinolone acetonide and its newer, unpreserved formulation (for intravitreal injection) have been used as adjuncts of focal laser or stand-alone alternatives. The utility of peribulbar and intravitreal steroid injections has been established in the management of intraocular inflammation and cystoid macular edema secondary to non-infectious uveitis. (Kok, 2005); (Tanner, 1995). As such, attention was turned to employ this method as a possible treatment for DME. Initial efficacy studies conducted between 2001 and 2002 demonstrated a short-term therapeutic effect of a randomly selected 4 mg dose of intravitreal triamcinolone injection in DME, and its use became widespread despite a lack of data from randomized, prospective clinical trials assessing efficacy or possible adverse effects (Jonas 2001; Martidis 2002).

Peribulbar triamcinolone has likewise been employed as a treatment modality for diabetic macular edema. Peribulbar injection is commonly delivered at a dosage of 20 - 40 mg of triamcinolone acetonide (40mg/1ml ) solution to one of three potential peribulbar locations: (1) anterior subconjunctival or subtenons; (2) posterior subtenons; (3) retrobulbar. Its hypothesized mechanism of action in treating diabetic macular edema involves a combination of decreasing retinal vascular permeability by downregulation of VEGF expression and decreasing leukostasis in retinal capillaries (Kern 2007).

A review of the literature reveals inconsistent reports of the efficacy of peribulbar steroid injection in treating DME. One retrospective study reported the efficacy of 40mg/1 ml posterior subtenons triamcinolone injection in eyes with DME and moderate vision loss (defined as a mean visual acuity of 20/80). Twenty-two percent of enrolled patients maintained a three or more line improvement in vision at 12 months (Bakri 2005). One study that compared posterior subtenons triamcinolone to placebo/sham injection in eyes with a mean visual acuity of 20/160 and fairly recalcitrant macular edema found no statistically significant improvement in visual acuity or decline in central retinal thickness (Entezari 2005). Another study enrolled patients with only mild diabetic macular edema and a mean visual acuity of 20/25. This study employed three arms to compare stand-alone peribulbar (anterior and posterior subtenons) therapy with focal laser photocoagulation therapy and a combination injection-laser therapy. After 34 weeks of follow-up, there was no conclusive improvement in visual acuity or decrement in central macular thickness in any of the

treatment arms. However, a statistical trend indicated a decrease in the likelihood of re-injection if the injection was followed in the short term by focal laser (Chew 2007). A retrospective uncontrolled study reported that intravitreal triamcinolone was superior to a posterior subtenons delivery of the drug (Ozdek 2006).

In September 2008, the Diabetic Retinopathy Clinical Research Network published the two-year results of a multi-center, large scale, randomized clinical trial directly comparing the efficacy of focal laser therapy and intravitreal triamcinolone injections (1mg and 4 mg dosages) with visual acuity and central retinal thickness as primary outcome variables (Figueroa 2008). The original study population met strict inclusion and exclusion criteria and had a wide range of visual acuity and DME severity. The findings of this study declared a short-term benefit of 4 mg triamcinolone over the other groups at four months, no clear benefit of any modality at 12 months, and a clear benefit of focal laser over either steroid dosage at two years in terms of improvement in mean visual acuity. Retinal thickness parameters generally paralleled the trends in visual acuity in this study. Adverse effects, including cataract formation and intraocular pressure increase, were monitored during this study. Intravitreal steroids demonstrated higher rates of cataract formation. Importantly, the reversal of efficacy of focal laser over intravitreal steroid over two years was not confounded by cataract formation (Figueroa 2008). The identical three-year follow-up data were reported by this group in 2009 (Beck RW 2009). Thus focal laser therapy was proven to have a lasting effect on vision with a much safer side effect profile when compared to varying dosages of intravitreal triamcinolone acetate.

### 5.3 Anti-Vascular Endothelial Growth Factor (VEGF) agents

The newest therapy in diabetic macular edema comprises biologic agents engineered to target the root cause of retinal vascular permeability, namely VEGF expression. VEGF-A is a known regulator protein of angiogenesis, vascular permeability, and pro-inflammatory activity (Murugeswari 2008; Roberts 1995). It binds VEGFR1 and VEGFR2 receptors and is upregulated primarily in response to tissue ischemia, inflammation, pH changes, and hormone growth factors (Penn 2008). Ranibizumab and bevacizumab are sister molecules of humanized murine monoclonal antibodies with affinity for binding VEGF isoforms. Ranibizumab (or Lucentis) is a humanized anti-VEGF-A recombinant Fab fragment (molecular weight 48 kDa), which binds all isoforms of VEGF A. Bevacizumab (or Avastin) is a full-length humanized antibody to VEGF-A (molecular weight 149 kDa) that binds all VEGF isoforms. Similar to triamcinolone acetate, the delivery of both drugs is by intravitreal injection. Ranibizumab (or Lucentis) gained attention after approval by the United States Food and Drug administration in the management of exudative age-related macular edema (ARMD) in 2006. Bevacizumab (or Avastin) was initially approved as adjunctive chemotherapy of metastatic colon cancer and has been widely used in an off-label fashion in the treatment of exudative ARMD. These drugs have likewise been applied to treat macular edema secondary to diabetic retinopathy and retinal vein occlusions.

The efficacy of the anti-VEGF agents in diabetic macular edema has been the subject of several recent investigations. Arevalo and colleagues report efficacy data from the Pan-

American Collaborative Retina study group (Arevalo 2007). This retrospective interventional multicenter study evaluated the retinal thickness and ETDRS acuity data of 80 consecutive patients receiving intravitreal Avastin injections for center-involving diabetic macular edema in eyes not previously treated with focal laser. Eyes received at least one Avastin injection (either 1.25mg or 2.50mg) with smaller percentages of patients requiring a second or third injection over a six-month period (on average every 11 to 13 weeks). The group reported a favorable decline in OCT retinal thickness and visual acuities that were stable if not improved from baseline (Arevalo 2007). The 24-month extension of this study supported the six-month findings. Patients who received on average 5.8 injections of single or double dose Avastin demonstrated a partial resolution of macular edema and maintained, if not improved, upon baseline visual acuity (Arevalo 2009). To date, there has been no formal large-scale phase III randomized control trial for the efficacy of anti-VEGF agents in diabetic macular edema.

Additional studies have emerged to compare the efficacy of anti-VEGF therapy to focal laser photocoagulation in DME. The Bevacizumab or Laser Therapy (or BOLT) study was a prospective, randomized phase II clinical trial and a first of its kind to compare anti-VEGF therapy to focal laser therapy (Michaelidis 2010). The study randomized 80 eyes to receive either intravitreal bevacizumab injections (1.25mg/0.50ml) or macula laser therapy (MLT) group. Bevacizumab injections were given every six weeks for the first three months followed by as needed thereafter. Focal laser was offered initially and every four months as needed. Injected eyes received a minimum of three and maximum of nine injections, whereas the focal laser eyes received a minimum of one and maximum of four treatments in the 12-month study period. The primary outcome measure was ETDRS visual acuity. The study reported a statistically significant difference in mean ETDRS visual acuity in the bevacizumab group ( $61.3 \pm 10.4$ ) as compared to the MLT group ( $50.0 \pm 16.6$ ,  $P = 0.0006$ ). Patients in the bevacizumab group were 5.1 times as likely to gain at least 10 ETDRS letters. Analogously, data on central retinal thickness showed a larger decrease from baseline in the bevacizumab group than the focal laser group. The BOLT study suggested that intravitreal bevacizumab therapy should be considered as a first choice in the management of center-involving DME. However, its use must be undertaken prudently in the setting of excellent visual acuity, as intravitreal injection is not without risk of complications.

#### 5.4 Surgical management

Identification of vitreomacular traction (as in VMT syndrome) highlights the possible utility of pars plana vitrectomy in eliminating at least one factor that exacerbates diabetic macular edema. This was formally evaluated by the Diabetic Retinopathy Clinical Research network in a prospective cohort study (Haller 2010). This study was the first of its kind to systematically evaluate the effect of pars plana vitrectomy on visual acuity and retinal thickness outcomes in patients with diabetic macular edema who demonstrated vitreomacular traction on time-domain (Stratus) OCT. The study evaluated one eye from 87 diabetic patients with moderate visual loss (defined in the study as VA ranging from 20/63 – 20/400), a central retinal subfield thickness of  $>300$  microns (by Stratus OCT), and evidence by OCT of vitreomacular traction (as assessed by the clinician). These eyes

underwent standard pars plana vitrectomy and were followed at 3, 6, and 12 months. Six-month data from the study has been published. Care was taken to eliminate confounding factors with strict exclusion criteria. This study revealed that pars plana vitrectomy for eyes with DME and VMT quantitatively decreased the degree of macular edema. However, the visual acuity outcomes were less predictable in that study patients exhibited both an improvement (38%, 10 letters or more) or a decrement (22%, 10 letters or more). A major weakness of this study was the lack of a control group to demonstrate the natural course of eyes with vitreomacular traction (which the authors deemed unethical). Given the variability in operative outcomes of vitrectomy for vitreomacular traction in diabetic macular edema, this treatment modality requires further investigation.

## 6. Conclusion

With the increasing incidence of all types of diabetes mellitus in the United States and worldwide, diabetic macular edema will continue to represent a widespread cause of visual morbidity. A solid understanding of the basic pathophysiologic mechanisms of this disease is critical in the clinical evaluation, severity assessment, appropriate treatment selection, and effective patient counseling. Strict glycemic and blood pressure control are the most effective methods of treating DME, as they directly target the root cause of the problem: hyperglycemia, hypertension, microvascular damage and retinal vessel incompetence. Focal laser photocoagulation therapy is an advantageous, though time-limited, treatment that remains the standard of care for DME. More recent therapies have targeted the inflammatory pathways of this disease on a molecular level and have shown promising results. There is a role of surgical intervention when tractional membranes are believed to exacerbate macular edema. Further study is required to establish which of the available treatment modalities are superior. At present, successful treatment of diabetic macular edema requires thorough patient education, counseling, and compliance such that a mutually acceptable treatment protocol can be established and pursued.

## 7. References

- Arevalo JF, *et al.* Primary intravitreal bevacizumab (Avastin) for diabetic macular edema: results from the Pan-American Collaborative Retina Study Group at 6-month follow-up. *Ophthalmology* 2007;114(4):743-750.
- Arevalo JF, *et al.* Primary intravitreal bevacizumab (Avastin) for diabetic macular edema: results from the Pan-American Collaborative Retina Study Group at 24 months. *Ophthalmology* 2009; 116(8):1488-1497.
- Bakri SJ, Kaiser P. Posterior subtenon triamcinolone acetate for refractory diabetic macular edema: a randomized clinical trial. *Eur J Ophthalmol* 2005;139:290-4.
- Beck RW, Edwards AR, Aiello LP, *et al.* Three-year follow up of a randomized trial comparing focal/grid photocoagulation and intravitreal triamcinolone of diabetic macular edema. *Ophthalmol* 2009; 127(3):245-251.
- Bhavsar KV, Subramanian ML. Risk factors for progression of subclinical diabetic macular edema. *Br J Ophthalmol* . 2011;95(5):671-4.
- Bresnick GH. Diabetic macular edema: a review. *Ophthalmology* 1986;93:989-997.



- Browning J, *et al.* Diabetic Macular Edema: What is Focal and What is Diffuse?. *Am J Ophthalmol* 2008; 146(5): 649 – 655.
- Brownlee M. Biochemistry and molecular cell biology of diabetic complications. *Nature* 414 (6865): 813–820.
- Chew E, Strauber S, Beck R, *et al.* A randomized trial of peribulbar triamcinolone acetate with and without focal photocoagulation for mild diabetic macular edema: a pilot study. *Ophthalmol* 2007;114(6):1190-1196.
- Clarkson JG, Green WR, Massof D. A histologic review of 168 cases of preretinal membrane. *Am J Ophthalmol*.84:1,1977.
- Davis M, Bressler S, Aiello L, *et al.* Comparison of time-domain OCT and fundus photographic assessments of retinal thickening in eyes with diabetic macular edema. *Invest Ophthalmol Vis Sci*. 2008;49(5):1745-1752.
- Diabetes Control and Complications Trial Research Group. The effect of intensive treatment of diabetes on the development and progression of long-term complications in insulin-dependent diabetes mellitus. *N Engl J Med* 1993;329:977-86.
- Dillingner P, Mester U. Vitrectomy with removal of the internal limiting membrane in chronic diabetic macular oedema. *Graefes Arch Clin Exp Ophthalmol* 2004;242:630-7.
- Engerman RL, Pfaffenbach D, Davis MD. Cell turnover of capillaries. *Lab Invest* 1967 17:738-743.
- Entezari M, Ahmadi H, Dehghan MH, *et al.* Posterior sub-tenon triamcinolone for refractory diabetic macular edema: a randomized clinical trial. *Am J Ophthalmol* 2005;139:240-9.
- Early treatment Diabetic Retinopathy Study research group. Photocoagulation for diabetic macular edema. Early Treatment Diabetic retinopathy Study Report Number 1. *Arch Ophthalmol* 1985;103:1796-1806.
- Early Treatment Diabetic Retinopathy Study Research Group: Treatment techniques and clinical guidelines for photocoagulation of diabetic macular edema. Early Treatment Diabetic Retinopathy study report number 2. *Ophthalmology* 1987;103:1796-806.
- Figueroa MS, Contreras I, Noval S. Surgical and anatomical outcomes of pars plana vitrectomy of diffuse nontractional diabetic macular edema. *Retina* 2008;242:630-7.
- Figueroa MS, Regueras A, Bertrand J, *et al.* A randomized trial comparing intravitreal triamcinolone acetate and focal/grid photocoagulation for diabetic macular edema. *Ophthalmol* 2008;115(9):1447-1450.
- Friedenwald JS. Diabetic retinopathy. *Am J Ophthalmol* 1950; 3:1187-1199.
- Gallego-Pinazo R, *et al.* Macular laser photocoagulation guided by spectral-domain optical coherence tomography versus fluorescein angiography for diabetic macular edema. *Clin Ophthalmol* 2011;5 613-617.
- Gass DM. Stereoscopic atlas of macular diseases diagnosis and treatment, Vol 2. C.V. Mosby Company, Washington, DC. 1987.
- Green, WR. Retina. In Spencer, WH, ed: Ophthalmic pathology: an atlas and textbook, vol 2. WB Saunders Co, Philadelphia. 1985.

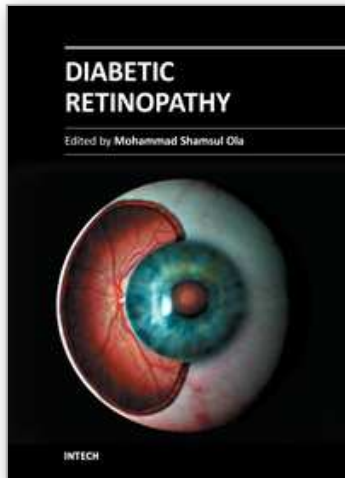


- Haller JA, Qin H, Ante RS, et al. Vitrectomy outcomes in eyes with diabetic macular edema and vitreomacular traction. *Ophthalmology* 2010;117(6):1087-1093.
- Hayreh SS. Role of retinal hypoxia in diabetic macular edema: a new concept. *Graefes Arch Clin Exp Ophthalmol* 2008; 246: 353-361.
- Hikichi T, Yohida A, Trempe CL. Course of vitreomacular traction syndrome. *Am J Ophthalmol*. 1995;119:55-61.
- Herman IM, D'Amore PA. Microvascular pericytes contain muscle and nonmuscle actins. *J Cell Biol* 1985;101:43-52.
- Jonas JB, Sofker A. Intraocular injection of crystalline cortisone as adjunctive treatment of diabetic macular edema. *Am J Ophthalmol* 2001;132:425-7.
- Kern TS. Contributions of inflammatory processes to the development of the early stages of diabetic retinopathy. *Exp Diabetes Res* 2007;2007:95-103.
- Kirber WM, Nchols CW, Grimes PA, et al. A permeability defect of the retinal pigment epithelium occurrence in early streozocin diabetes. *Arch Ophthalmol* 1980;98:725-728.
- Kok H, Lau C, Maycock N, et al. Outcome of intravitreal triamcinolone in uveitis. *Ophthalmology* 2005; 112(11):1916.e1-7.
- Kuwabara T, Cogan DG. Studies of retinal vascular patterns. Part I. Normal architecture, *Arch Ophthalmol* 1960;64:904-911.
- Little HL. Alterations in blood elements in the pathogenesis of diabetic retinopathy. *Ophthalmology* 1981; 88:647-654.
- Martidis A, Duker JS, Greenberg PA, et al. Intravitreal triamcinolone for refractory diabetic macular edema. *Ophthalmology* 2002;109:920-7.
- Michaelidis K, Kaines A, Hamilton RD, et al. A prospective randomized trial of intravitreal bevacizumab or laser therapy in the management of diabetic macular edema (BOLT) study) 12-month data: report 2. *Ophthalmology* 2010;117:1078-1086.
- Murugeswari P, Shukla D, Rajendran A, et al. Proinflammatory cytokines and angiogenic and antiangiogenic factors in vitreous of patients with proliferative diabetic retinopathy and Eales' disease. *Retina* 2008; 28:8170824.
- National Diabetes Information Clearinghouse 2011 (available at <http://diabetes.niddk.nih.gov/dm/pubs/statistics/#fast>)
- Ozdek S, Bahceci UA, Gurelik G, Hasanreisoglu B. Posterior subtenon and intravitreal triamcinolone acetate for diabetic macular edema. *J Diabetes Complications* 2006;20:246-51.
- Penn JS, Madan A, Caldwell RB et al. Vascular endothelial growth factor in eye disease. *Prog Retin Eye Res* 2008; 27:331-371.
- Richard, G. Fluorescein and ICG Angiography Textbook and Atlas. George Thieme Verlag: Stuttgart. 1998. 102-108.
- Roberts WG, Palade GE. Increased microvascular permeability and endothelial fenestration induced by vascular endothelial growth factor. *J Cell Sci* 1995;108:2369-2379.
- Ryan SJ. The Retina, Vol 2. C.V. Mosby Company, Baltimore. 1989.
- Tanner V, Kanski JJ, Frith PA. Posterior Sub-Tenon's triamcinolone injections in the treatment of uveitis. *Eye*. 1998; 12 (Pt 4): 679-85.

UK Prospective Diabetes Study (UKPDS) Group. Intensive blood-glucose control with sulphonylureas or insulin compared with conventional treatment and risk of complications in patients with type 2 diabetes (UKPDS 33). *Lancet* 1998;352:837-53.

IntechOpen

IntechOpen



## **Diabetic Retinopathy**

Edited by Dr. Mohammad Shamsul Ola

ISBN 978-953-51-0044-7

Hard cover, 356 pages

**Publisher** InTech

**Published online** 24, February, 2012

**Published in print edition** February, 2012

The aim of this book is to provide a comprehensive overview of current concepts in pathogenesis, diagnosis and treatments of diabetic retinopathy. It provides a collection of topics written by excellent authors, covering discussions on advances in understanding of pathophysiology, immunological factors and emerging concepts, relating to clinical aspects and treatment strategies. The contents of the book will not only provide a resource for our knowledge but also improve diagnosis and treatment options for those patients who suffer vision loss due to diabetic retinopathy.

### **How to reference**

In order to correctly reference this scholarly work, feel free to copy and paste the following:

Christina Antonopoulos and Manju Subramanian (2012). Diabetic Macular Edema, Diabetic Retinopathy, Dr. Mohammad Shamsul Ola (Ed.), ISBN: 978-953-51-0044-7, InTech, Available from:  
<http://www.intechopen.com/books/diabetic-retinopathy/diabetic-macular-edema>

**INTECH**  
open science | open minds

### **InTech Europe**

University Campus STeP Ri  
Slavka Krautzeka 83/A  
51000 Rijeka, Croatia  
Phone: +385 (51) 770 447  
Fax: +385 (51) 686 166  
[www.intechopen.com](http://www.intechopen.com)

### **InTech China**

Unit 405, Office Block, Hotel Equatorial Shanghai  
No.65, Yan An Road (West), Shanghai, 200040, China  
中国上海市延安西路65号上海国际贵都大饭店办公楼405单元  
Phone: +86-21-62489820  
Fax: +86-21-62489821

© 2012 The Author(s). Licensee IntechOpen. This is an open access article distributed under the terms of the [Creative Commons Attribution 3.0 License](https://creativecommons.org/licenses/by/3.0/), which permits unrestricted use, distribution, and reproduction in any medium, provided the original work is properly cited.

IntechOpen

IntechOpen