

We are IntechOpen, the world's leading publisher of Open Access books Built by scientists, for scientists

6,900

Open access books available

186,000

International authors and editors

200M

Downloads

Our authors are among the

154

Countries delivered to

TOP 1%

most cited scientists

12.2%

Contributors from top 500 universities



WEB OF SCIENCE™

Selection of our books indexed in the Book Citation Index
in Web of Science™ Core Collection (BKCI)

Interested in publishing with us?
Contact book.department@intechopen.com

Numbers displayed above are based on latest data collected.
For more information visit www.intechopen.com



Minimally Invasive Robot – Assisted Colorectal Resections

Annibale D'Annibale, Graziano Pernazza,
Vito Pende and Igor Monsellato
*San Giovanni – Addolorata Hospital, Rome,
Italy*

1. Introduction

Minimally invasive techniques have revolutionized general surgery, especially in the field of gastrointestinal surgery.

Many authors argue that the era of laparoscopic technique had begun in 1987, when Mouret performed the first laparoscopic cholecystectomy (Koopmann et al., 2008; Law et al., 2007). Since that point, laparoscopic technique has become the first choice for a multitude of surgical procedures: cholecystectomy, gastric bypass, fundoplication and its variants are some examples of procedures which are currently performed laparoscopically (Stage et al., 1997; Lacy et al., 2002). This spread has been fostered by the advantages of laparoscopic technique: reduced postoperative pain, decreased hospital stay and faster postoperative recovery, reduced incidence of postoperative complications, improved cosmetic outcome, decreased incidence of incisional hernias (Stage et al., 1997; Lacy et al., 2002; Guillou et al., 2005; Jayne et al., 2007; Fleshman et al., 2007; Nelson et al., 2004; Veldkamp et al., 2005; Ballantyne et al., 2001).

The first hemicolectomy was performed laparoscopically in 1990 (Weber et al., 2002; Delaney et al., 2003). Since then, the introduction of this technique for colorectal disease was gradual, especially in malignancy, because of early skepticism towards this technique. The major questions have arisen about the treatment of malignant disease. The oncological adequacy was analysed in terms of lymph node dissection, resection margins and intraoperative tumor dissemination.

Since 2002 a series of randomized clinical trials compared the laparoscopic and the open technique, the results of which definitely eliminated any doubts concerning the oncological adequacy of laparoscopic technique (Lacy et al., 2002; Jayne et al., 2007; Poulin et al., 1999; Hasegawa et al., 2003; Kaiser et al., 2004; Milsom et al., Tang et al., 2001; Champault et al., 2002). The advantages of minimally invasive approach in colorectal cancer surgery have been demonstrated in both pathophysiological (decreased inflammatory response → decreased immune response → decreased postoperative morbidity / comorbidity) and oncological aspects (similar results in terms of survival and outcome) (Leung et al., 2000; Delgado et al., 2001; Hu et al., 2003; Poulin et al., 1999; Hasegawa et al., 2003; Kaiser et al., 2004; Milsom et al., 1998; Tang et al., 2001; Champault et al., 2002).

The laparoscopic approach for colorectal disease, however, has both technical and "anatomical" disadvantages: the need of a long learning curve, the presence of a large

surgical field that requires a dynamic view and consequently, a skilled camera assistant surgeon, a constant dialogue between the operator and the assistant, the loss of three-dimensional vision, reduced ergonomics during specific phases of the procedure (need to take preternatural positions), poor dexterity of the laparoscopic instruments and decreased range of motion due to the rigidity of the insertion of the trocars site, amplification of physiological tremor and the fulcrum effect. The so-called "surgical robots" or otherwise called "computer-assisted telemanipulators" have been introduced to overcome these "limits" in the practice of surgery (Mirnezami et al., 2009; Weber et al., 2002; Cadiere et al., 2001; Garcia-Ruiz et al., 1998; Lanfranco et al., 2004; Morino et al., 2006; Horgan et al., 2001; Ballantyne et al., 2002; Hanly et al., 2004; Moorthy et al., 2005; Baik et al., 2008; Ballantyne et al., 2001).

2. Criteria in selecting patient for minimally invasive surgery

Patient's selection is based on pathophysiological and pathological conditions. Absolute contraindications in colorectal cancer robotic surgery, reflect those for whole minimally invasive surgery. Nevertheless, indications to minimally invasive approach are expanding rapidly suggesting the establishment of international guidelines in patient's selection.

There are several physiological parameters, which have been analyzed for patient's selection:

- Age. Age does not influence intraoperative or postoperative outcome as shown by several studies in which postoperative morbidity was lower than that in open surgery. Moreover, conversion rates were not statistically significant if different ages were considered (younger, middle-aged, elderly). Age is not a contraindication.
- Cardiopulmonary condition. Generally, altered cardiopulmonary functions are not considered a contraindication to minimally invasive approach. Nevertheless, minimally invasive approach needs continuous monitoring of patient's physiological parameters. The effect of the pneumoperitoneum on hemodynamics in patients ASA (American society of anesthesiologists score) I-II are not clinically relevant, while an invasive monitoring system of the blood pressure or circulating volume is advocated in patient ASA III-IV. In addition, gasless or low-pressure regimen should be maintained during the whole intervention in patients with limited cardiac function. Monitoring of end-tidal carbon-dioxide levels is mandatory, since pneumoperitoneum may causes a CO₂-retention and head position and intrabdominal hypertension lead to ventilation-perfusion mismatch.
- Obesity. Obese patients' ventilation is often problematic because of pulmonary compliance reduced about 30% than in normal-weight patients. Although obesity is not considered an absolute contraindication, complications and conversion rate are higher at BMI (body mass index) greater than 30. Recently, similar postoperative short term outcomes have been demonstrated between obese and non-obese patients (Merkow et al., 2009; Blumberg et al., 2009). Complication rates are comparable with those expected after open surgery.

Pathological criteria:

Characteristics of tumor may influence the surgical approach. A tumor invading adjacent structures (T4) is considered an "absolute" contraindication to minimally invasive approach, as the principles of atraumatic manipulation and wide resection margins could be not

matched. Adhesions, localization and peritoneal carcinomatosis are not considered a contraindication by the majority of experts.

3. Patient preparation

The patient undergoes bowel preparation with Polyethylene glycol one day before the procedure and a slag-free diet three days before the procedure. The banding technique of the inferior arms associated to administration of a low-molecular-weight heparin 12 hours before the procedure is performed for thromboembolism prophylaxis.

3.1 Venous access

Before procedure starts, a venous access is needed to maintain correct blood volume and hydration of the patient and to infuse anesthetic agents during the whole procedure. The preferred choices of venous access are: right superior arm (18G catheter) for right colectomy and left superior arm for left colectomy and rectal resection (16/18 gauge catheter). If peripheral venous access is unavailable, a central catheter should be inserted before the day of the procedure. A heating system for venous access is needed in order to maintain the thermal homeostasis. Keeping patients warm has been associated with a threefold decrease in the rate of wound infection, reduction in operative blood loss, decrease in untoward cardiac events and patient discomfort. Maintenance of a normal temperature during surgery is important to reduce the stress of the surgical procedure and organ dysfunction.

3.2 Types of anesthesia

General anesthesia with orotracheal intubation and mechanical dynamic ventilation is the preferred technique among anesthesiologists. Currently, both intravenous and gas-intravenous (Desforane, Sevorane) techniques are used by anesthesiologists as there is no evidence of better results by the one or the other procedure. The usual scheme provides an association with epidural access in order to better control postoperative pain. N₂O (nitrous oxide) is contraindicated as it may increase the risk of pulmonary embolism. An optimal anesthesia may provide an acceptable muscular relaxation, better ventilation, thus minimizing the risk of pulmonary embolism and hemodynamics alteration, granting a wider operating field thus reducing the operative time.

3.3 Intraoperative monitoring

Intraoperative monitoring differs between ASA I-III or III+ patients:

In ASA I-III:

ECG+HR, O₂ saturation, Airways Pressure (PAW – Pressure plateau), capnography (EtCO₂)

In ASA III+ in addition to previous tests:

Neuromuscular function (TOF), Diuresis monitoring (bladder catheterization), Swan-Ganz catheter, PeakPressure Monitoring, arterial catheterization, haemo-gas analysis.

A peripheral arterial access is mandatory for monitoring blood pressure in high-risk patients.

3.4 Surgical instrumentation

Stereoscopic endoscope (da Vinci Surgical System)

CO₂ insufflator

Irrigation/suction system device

Video processor

1 Hasson-type trocar

1 10/12mm trocar

3 8mm robotic trocar

2 Robotic Cadiere's graspers

2 Robotic needle-holders

1 Laparoscopic needle-holder

1 Laparoscopic dissector

3 Laparoscopic forceps type Johann

1 Laparoscopic clip applier

1 45-mm laparoscopic stapler device with 2-3 cartridges (intestinal and vascular type)

1 Robotic ultrasound device

1 Robotic electrocautery hook

1 Robotic bipolar forceps

1 Wound protector for specimen extraction

4. Robotic right colectomy

4.1 Patient position and operating room setup

Patient is placed in supine reverse Trendelenburg position (15° to 20°), with 10° to 15° left lateral rotation and shoulder supports. The legs are secured at the thigh and calf with straps. The table is tilted to the left to allow the small intestine to fall off from the midline. The assistant surgeon stands on the patient's left side. The robotic cart is approached from the patient's right side. The operating room scheme is shown in fig. 1.

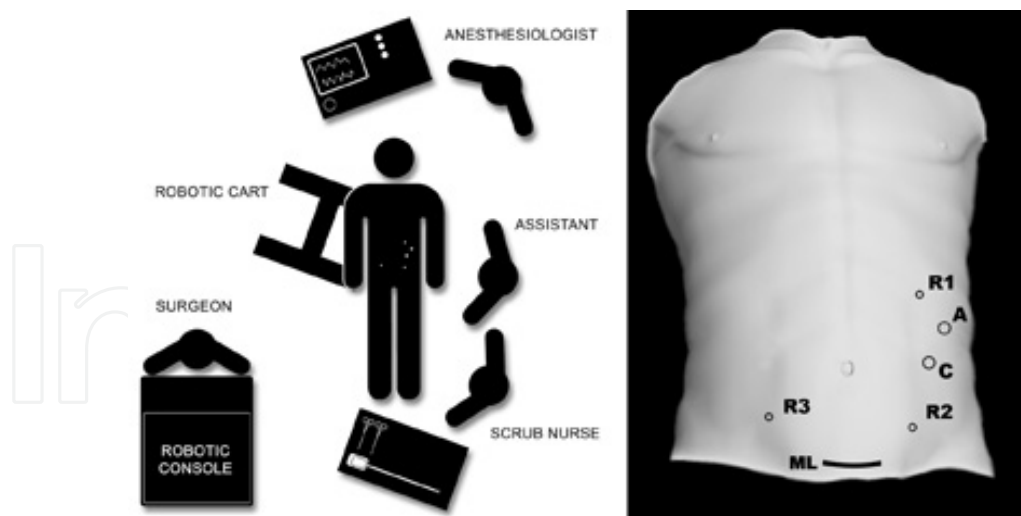


Fig. 1. Operating room setup and trocars position

4.2 Trocars position

A conventional 12mm port is placed by open technique on the lateral margin of the left rectal muscle, 1-2 cm above the transverse umbilical line, and pneumoperitoneum is induced until reaching a 12mmHg endoabdominal pressure. Then the 30° robotic stereo endoscope is inserted. Two daVinci 8-mm ports are inserted respectively in the left

hypochondrium for electrocautery/ultrasonic instruments and in the left iliac fossa for Cadière grasper under direct vision. An additional 12-mm port is inserted in the left flank. This port is used by the assistant to help the surgeon during some steps of the procedure and to introduce the linear stapler for vascular, transverse colon and ileum resection. An additional robotic port is inserted in the right iliac fossa for the fourth robotic arm. It may be useful to provide effective and stable retraction during several steps of the procedure (i.e. to grasp the ileocecal valve and place the ileocolic vascular pedicle under tension, to lift up the hepatic flexure during the dissection of transverse mesocolon, etc.).

4.3 Description of the procedure

The procedure is carried out with a full robotic technique. The robotic cart approaches from the right side of the patient, and the three operative arms are connected to the ports.

The procedure begins by grasping upward and laterally the mesentery of the last ileal loop. This maneuver, performed with the forceps mounted on the fourth arm, enhances the prominence of the ileocolic vessels and provides stable and durable retraction. The peritoneal layer of the mesentery is incised just below this salience, and an accurate lymphadenectomy is performed along the superior mesenteric axis. Then, the ileocolic vessels are isolated and separately ligated and sectioned (fig. 2).

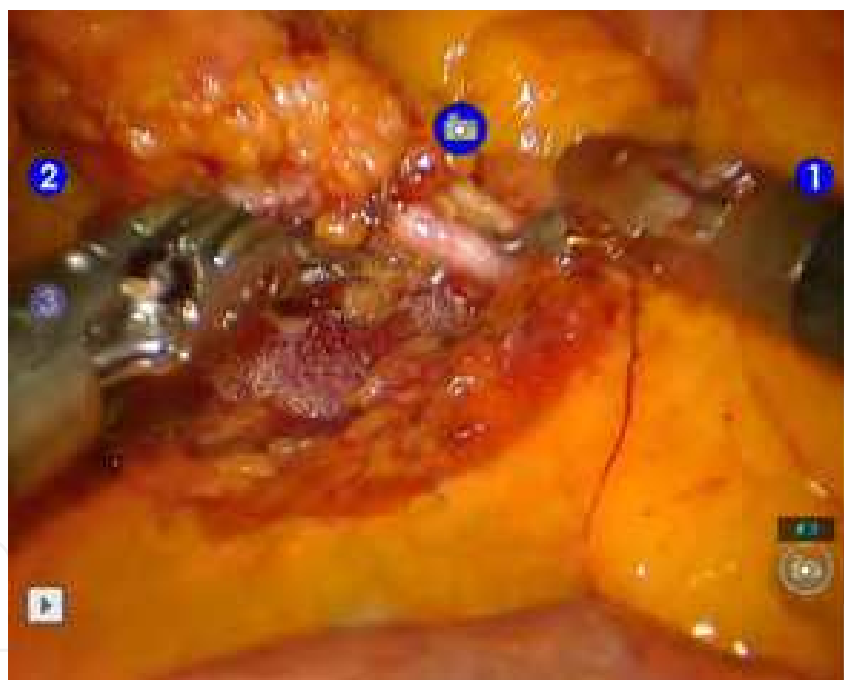

Fig. 2. Intraoperative view: Ileocolic vessels

Dissection of the right mesocolon follows a caudal-cranial pathway, along the right side of the superior mesenteric axis. Following this path, it is possible to remove the lymphatic tissue completely, safely identifying the inconstant right colic vessels, which may be sectioned at their origin, until reaching the root of the transverse mesocolon. Dissection along the lateral margin of the middle colic vessels allows the right branch of the middle colic vessels to be reached more easily, which is then treated as in the standard right colectomy (R1). Resection of the whole pedicle of the middle colic vessels is performed only for localization at the right colic flexure, for which extended right colectomy (R2) is needed.

Mobilization of the colon is performed in a medial-to-lateral direction in the avascular plane between Gerota's and Toldt's fasciae. During this step, the knee of the duodenum constitutes an important landmark to drive the dissection upward, over the duodenal third portion and the pancreatic head, along Fredet's fascia. The right ureter and the gonadic vessels are left below the plane of dissection. The hepatic flexure is then mobilized, sectioning the lateral portion of the gastrocolic and the hepatocolic ligaments. This step enables the resection to join the previously dissected plane and to complete the lymphadenectomy around the gastroepiploic vessels.

The transverse colon and the last ileal loop are finally sectioned by linear stapler. The ileum and the transverse colon are joined with a running suture, and an intracorporeal isoperistaltic double layer side-to-side ileocolic anastomosis is fashioned using a 3-0 absorbable monofilament suture (fig.3).

We performed an extracorporeal anastomosis in the first five cases: the daVinci system is disengaged from the patient, then a median supraumbilical minilaparotomy is performed, through which an isoperistaltic side-to-side ileocolic anastomosis is fashioned.

The specimen is retrieved at the end of the procedure through a small muscle-splitting Pfannenstiel minilaparotomy. This incision is protected from potential contamination by a wound protector.

A 10F Jackson-Pratt drain is placed laterally to the anastomosis through one of the lower trocar access.

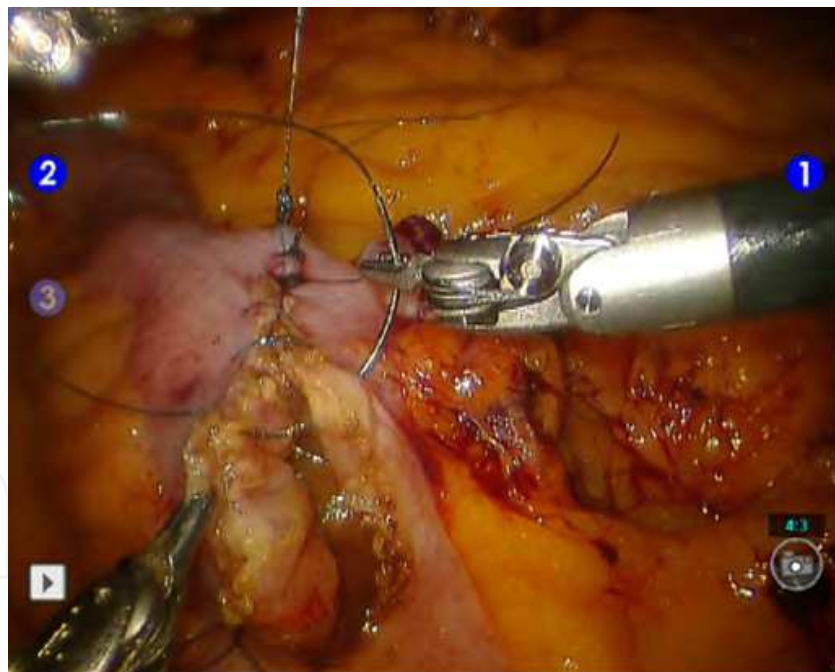


Fig. 3. Intraoperative view: intracorporeal ileocolic robot-assisted anastomosis

5. Left colectomy

5.1 Patient position and operating room setup

Patient is placed in supine Trendelenburg position (15° to 20°), with 10° to 15° right lateral rotation and shoulder supports. The legs are secured at the thigh and calf with straps. The table is tilted to the right to allow the small intestine to fall off from the midline. The

assistant surgeon stands on the patient's right side. The robotic cart is approached from the patient's right side.

5.2 Trocars position

A conventional 12mm port is placed by open technique 2-cm right from the umbilicus along the umbilical transverse line, and pneumoperitoneum is induced until reaching a 12mmHg intrabdominal pressure. Then the 30° robotic stereo endoscope is inserted. Two da Vinci 8-mm ports are inserted under direct vision respectively in the epigastrium just 2 cm right from the midline and in the right flank. An additional 12-mm port is inserted between the two robotic trocars. This port is used by the assistant to help the surgeon during some steps of the procedure and to introduce the linear stapler for vascular and left colon resection.

5.3 Description of the procedure

The procedure is carried out with a full robotic technique. The robotic cart approaches from the left side of the patient, and the two operative arms are connected to the ports.

The dissection begins with the identification of the inferior mesenteric vein at the level of the inferior margin of the pancreas and the incision of the peritoneum at the origin of the mesocolon under the salience of the vein, on the right side. Then, the inferior mesenteric vein is exposed and sectioned by linear stapler or between clips.

A sharp dissection is performed in a cranial-caudal and medial-to-lateral direction between the anterior and the posterior layer of Toldt's fascia. An incision of the peritoneum is performed from the promontory up to the origin of the inferior mesenteric artery, identifying and preserving the preaortic nerves. The dissection is carried out up to join the previous plane of dissection identifying and preserving the left ureter and the gonadal vessels. Then, the inferior mesenteric artery is exposed and sectioned at its origin by linear stapler or between clips.

Afterwards, the colon is freed laterally by the incision along Monk's line, from the sigmoid colon upward: the splenic flexure is taken down if necessary. The colon is divided distally to the tumor at the level of the promontory. Then, the specimen is usually extracted through a mini-Pfannenstiel incision, after the insertion of a wound protector. Before closing the minilaparotomy, the anvil of the circular stapler is inserted at the distal margin of the proximal colon.

Re-induction of the pneumoperitoneum is performed. The proximal colon is joined to the rectum by circular stapler, and a mechanical termino-terminal colorectal anastomosis is fashioned by Knight & Griffen technique.

Two 10F Jackson-Pratt drainages are placed anteriorly and posteriorly to the anastomosis through one of the lower trocar access.

6. Rectal surgery

6.1 Patient position and operating room setup

Patient is placed in a lithotomy position with his legs apart and no modification of position will occur during the whole procedure. The legs are secured at the thigh and calf with straps. The table is tilted to the right (15° – 20°) to allow the small intestine to fall off from the midline. The assistant stands on the patient's right side. The robotic cart then approaches to the operative bed by patient's left side, with a 60 degrees angle, following the imaginary line passing through the umbilicus and the left anterosuperior iliac spine.

6.2 Trocar position

We usually perform a 5-ports technique. The first 12-mm periumbilical port (C) is placed by “open-laparoscopy” technique, for the stereoscopic endoscope. Then a 12-mmHg pneumoperitoneum is gained and other three 8-mm robotic ports are added: the first port (R1) is inserted in the right iliac fossa on an imaginary line between the anterosuperior iliac spine and the umbilicus. The second port (R2) is inserted in the right hypochondrium, and the third port (R3) is placed in patient’s left flank. Last, a second 12-mm port is inserted in patient’s right hip between R1 and R2 for the assistant surgeon (A). Trocar position is performed laparoscopically, and an exploration of the abdominal cavity precedes the robotic technique, with an adhesiolysis in case of visceral adhesions. Hence, the small bowel is displaced right in order to expose the Treitz ligament and the plane of the inferior mesenteric vein (IMV).

6.3 Description of the procedure

The procedure starts with the “vascular phase”: the inferior mesenteric vein is identified at the level of the inferior margin of the pancreas. The peritoneum under the inferior mesenteric vein is then incised, and a smooth dissection is performed in a medial-to-lateral direction along the avascular plane between the Toldt’s, above, and the Gerota’s fascia, below, up to the left abdominal wall. The inferior mesenteric vein is subsequently divided between clips or by linear stapler. The dissection is prolonged up downward. The left ureter and the gonadic vessels are previously identified and preserved. The incision of the peritoneum at the level of the mesosigmoid is performed in order to reach the deeper plane of the inferior mesenteric artery. The iliac vessels and the left ureter are covered by the prerenal fascia. The dissection of the plane covering the inferior mesenteric artery is then performed with an accurate regional lymphadenectomy, preserving the preaortic nerves and the superior hypogastric plexus. The inferior mesenteric artery is then sectioned by stapler or between clips. A complete lateral dissection of the colon is carried out from the sigmoid to the splenic flexure. Flexure takedown is performed if the descending colon is needed to be used for the anastomosis.

Then, arm #2 is switched from R2 to R3. The assistant surgeon could use R2 and A trocars in helping the surgeon during the total mesorectal excision (TME). Dissection starts posteriorly, at the level of the promontory, along the plane between the fascia recti propria, anteriorly, (peritoneum) and the presacral fascia (Waldeyer’s fascia), posteriorly. Rectum is lifted up and laterally by a Cadie on the arm #2 and dissection is carried out by the electrocautery hook or ultrasound device on the arm #1: the retrorectal plane has been opened. Care should be taken to preserve the inferior hypogastric nerves lying laterally along this plane. Pneumoperitoneum also helps the dissection between these two layers. At the level of the fourth sacral vertebra, the rectosacral fascia is incised in order to better mobilize the rectum and to access to the inferior part of the retrorectal space, in case of lower tumor localization. The mesorectal dissection has been completed behind the tip of the coccyx as the pelvic floor curves upward anteriorly toward the anorectal junction. Anteriorly, the rectum is retracted cranially and posteriorly by a Cadie on the arm #2. The anterior peritoneal brim is incised by the electrocautery hook on the arm #1, and the dissection continues along the plane between the Denonvillier’s fascia (or the rectovaginal fascia) and the fascia propria recti. At the level of the base of the prostate, Denonvillier’s fascia is sectioned in order to preserve rectoprostatic (or rectovaginal) blood vessels and branches of the cavernous nerves (fig. 5).

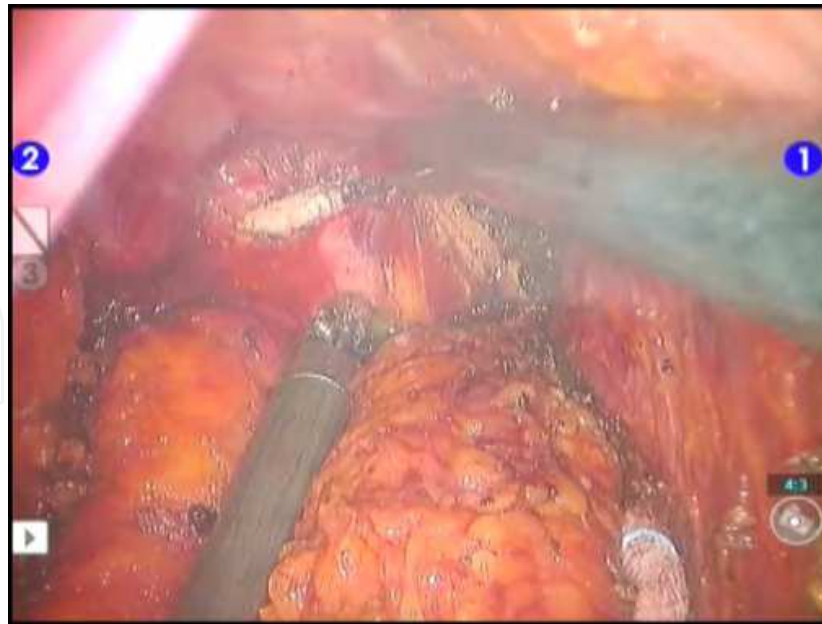


Fig. 5. Intraoperative view: Incision of Denonvillier's Fascia.

The dissection thus continues distal to the rectoprostatic (or rectovaginal) septum: the anterior mesorectal excision is completed, and the rectum is exposed anteriorly to the anorectal junction. A gentle traction of the rectum takes place laterally by a Cadie on the arm #1, on either side, and the dissection is performed by the electrocautery hook until reaching the lateral ligaments of the rectum (LLR). At this level, the dissection is carried out close to the rectum, in order to avoid the injury of the inferior hypogastric plexus (IHP). The dissection must include only the rectal branches from the IHP and the small rectal branches from the middle rectal artery (MRA) (fig. 6).

The total mesorectal excision (TME) is finally completed and the rectum is sectioned at its distal end by linear stapler.

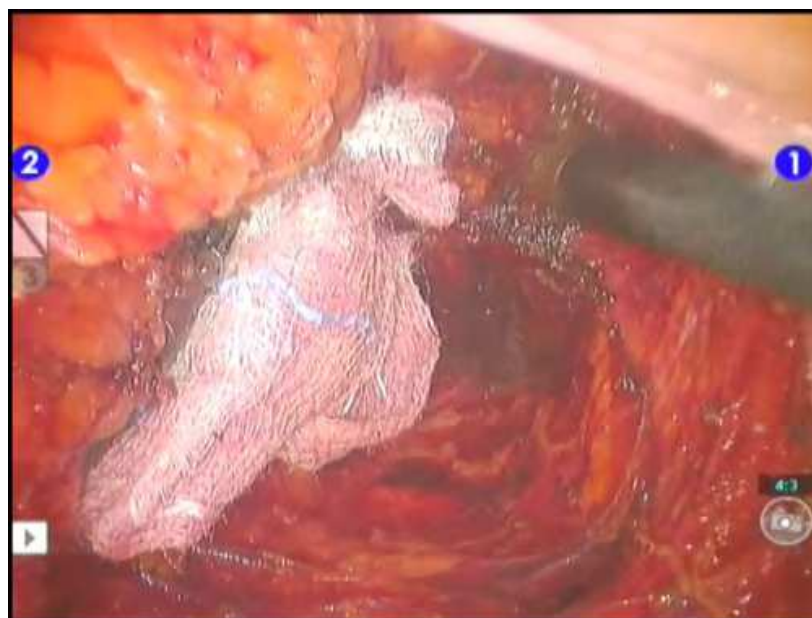

Fig. 6. Intraoperative view: lateral dissection of the rectum

Once the distal rectal transection ended, the robotic cart is disengaged, and a suprapubic minilaparotomy (Pfannenstiel) is performed. The specimen is then extracted, after protecting the minilaparotomy by a wound protector. The descending colon is transected, and the anvil of the stapler is inserted at the end of the colon.

The bowel reconstruction is conducted laparoscopically, and an intracorporeal mechanical colorectal termino-terminal anastomosis is performed by Knight & Griffen technique with a circular stapler. In case of coloanal anastomosis, the specimen is retrieved through the anal canal by a pull-trough technique and a manual colo-anal anastomosis is performed.

In case of ultra-low anterior resections a diverting loop-ileostomy is fashioned enlarging the R3 trocart site.

7. Postoperative patients’ care, outcome and technical results

7.1 Technical results and outcome

Our study is based on about 300 consecutive robotic colorectal procedures structured as follows: 140 colic resections for cancer (84 right colectomies, 43 left colectomies, 13 others), 48 rectal resections and 110 colorectal resections for benign disease.

7.1.1 Right colectomy

Forty-three male and forty-one female patients underwent robotic right colectomy. Mean age was 73.34 ± 11 years. Median operative time was 213.50 (180–250) min. No conversion occurred. Specimen length was 28 ± 5 cm (range 21–50 cm). Number of harvested lymph nodes was 19.70 ± 7.2 (range 12–44), and mean number of positive lymph nodes was 1.65 ± 3 (range 0–17). Surgery-related morbidity was 2/84 (2,3%): one twisting of the mesentery in one of the first cases with extracorporeal anastomosis and a dehiscence of the colic stump in a patient with Crohn disease. All patients were included in a follow-up regimen. Neither conversions nor 30-day mortality occurred. Oral re-intake was on day 3.47 ± 0.6 (range 2–4) and length of stay was 7 ± 1.2 days (range 5–9 days). All patients were treated with curative-intent surgery and adjuvant chemotherapy (CHT) according to current international guidelines for colorectal cancer. At median follow-up of 36 months (range 6–96 months), disease-free survival was 90% (76/84), overall survival was 92% (78/84), and disease-related mortality was 4% (3/84) (Table 1). Stages included in the survival analyses were II, III, and IV. Disease-free survival was 90% (72/80), overall survival was 92% (73/80) and cancer-related mortality was 13% (11/80) at a median 3-year follow-up. Overall survival for stage II, III, and IV was 94.1%, 92.3%, and 66.7%, respectively. Disease-free survival for stage II and III was 100% and 84.6%, respectively (table 1).

Disease free survival	76 (90%)
Alive w/recurrence	5 (6%)
Drop-out	0
Deceased	3 (4% - 3 cancer-related)

Table 1. Robotic right colectomy Follow-up

7.1.2 Left colectomy, hartmann procedure, sigmoidectomy

Twenty-three male and twenty female patients underwent surgery for left-sided colon cancer. Mean age was 60 ± 12 years. Median operative time was 220 (215 – 230) min. One conversion occurred for a splenic injury at the beginning of the experience. Specimen length was 24 ± 7.7 (range 10 – 49) cm. Number of harvested lymph nodes was 12 ± 7 (6 – 24). Surgery-related morbidity was 1/43 (2,3%): an anastomotic dehiscence in one of the first cases. All patients were included in a follow-up regimen. No 30-day mortality occurred. Median hospital stay was 7 d (range, 6 – 11), oral diet resumption was 3 d (range, 2 – 10). All patients were treated with curative-intent surgery and adjuvant chemotherapy (CHT) according to current international guidelines for colorectal cancer. At median follow-up of 36 months, disease-free survival was 88.3% (38/43), overall survival was 90% (38/43), and disease-related mortality was 7% (3/43) (Table 1). One patient was lost during follow-up.

7.1.3 Rectal surgery

Thirty male and eighteen female patients underwent rectal surgery: 45 rectal anterior resections (RAR) with TME and 3 abdominalperineal resections (APA). Mean age was 67 ± 12 years. Median operative time was 270 (240 – 315) min. Specimen length was 23 (19 – 27,5) cm. Number of harvested lymph nodes was 15 (12 – 20). Circumferential margins are shown in table 2.

Cm	Upper rectum	Middle rectum	Lower rectum
< 0.2	0	0	0
0.2 – 0.6	1		7
0.6 – 1.0	0		12
> 1.0	11		17

Table 2. Circumferential margins

Median longitudinal distal margin was 3 (2 – 4) cm. Surgery-related morbidity was 8% (4/48): there were four anastomotic leakages: two were treated laparoscopically only by peritoneal washing and drainage. Two were treated conservatively. No 30-day mortality occurred. Median hospital stay was 8 d (range, 8 – 11), oral diet resumption was 3 d (range, 2 – 13). All patients were treated with curative-intent surgery and neoadjuvant chemoradiotherapy (CHT) according to current international guidelines for colorectal cancer. At median follow-up of 36 months, disease-free survival was 67.8% (38/48), overall survival was 87.5% (42/48), and disease-related mortality was 8.3% (4/48) (Table 3). One patient was lost during follow-up.

Disease free survival	38 (67.8%)
Alive w/ recurrence	3 (13.0%)
Drop-out	1 (4.3%)
Deceased	6 (24.7% - 5 Cancer-related; 1 others)

Table 3. Robotic rectal surgery Follow-up

8. Discussion

Colorectal cancer is still the third leading cause of death in the US, even though death rates have also been declining by 2,2% per year since 1998.

The Medical Research Council Conventional versus Laparoscopic-Assisted Surgery In Colorectal Cancer (MRC CLASICC) trial was set up in 1996 to evaluate the technical and oncological safety and efficacy of laparoscopically assisted surgery in comparison with conventional open surgery for the treatment of colorectal cancer.

The last update of the CLASICC Trial showed the oncological adequacy of the laparoscopic technique compared to the open one. Moreover, minimally invasive surgery has general benefits such as less blood loss, postoperative pain, and use of anesthetics, as well as fewer early and late wound complications, a shorter hospital stay, and better aesthetic outcomes. However, there are some limitations of the laparoscopic surgery: tremor, unstable two-dimensional view, and limited degree of freedom of the instruments.

Robotic surgery is spreading all over the world for many surgical procedures ranging from cardiac to general and urologic surgery thanks to its potential advantages overcoming the negative aspects of laparoscopic approach. It provides the surgeon with a 3-dimension display which enhances depth perception, allows the surgeon to operate in a comfortable, seated position with eyes, hands and operative field in line. Furthermore, the robotic instruments contain articulation which recall human wrist movements with 7 degrees of freedom to improve dexterity.

These characteristics of the robotic system may improve dissection and consequently oncological outcome. It is acquired that presence of nodal metastasis and mainly its distribution are key factors in predicting disease-free and long-term survival and for deciding on postoperative adjuvant therapy. The American Joint Committee on Cancer (AJCC) and College of American Pathologists (CAP) recommend evaluation of a minimum of 12 lymph nodes. In right colon cancer, we were able to perform a correct right colectomy easily identifying the major colic vessels and carrying out accurate lymphadenectomy, taking advantage of the steady, 3-D image view and of the articulation of the robotic instruments, which allowed us to manage organs such as the pancreas or the duodenum gently. The average length of the resected specimen in this series was 28 ± 5 cm, and the mean number of harvested lymph nodes was 19.70 ± 7.2 , above the minimum recommended by the AJCC. To our knowledge our experience on robotic right colon resection is the largest published in the literature. We report a median follow-up of 36 months. Disease-free and overall survival were 90% and 92%, respectively; survival rates for stage II and III was 94.1% and 92.3%, and disease-free survival was 100% and 93%, respectively. Recent studies have shown 3-year overall survival varying from 68% to 100% for stage II and from 68% to 97% for stage III, and 5-year survival rates for stage II and III of about 72–90% and 44–72%, respectively (Gattaj et al., 2003; Roxburgh, 2009; Japan National Cancer Center, 2010). A comparison of our results with the literature shows that robotic right colic resection is able to offer the same short-term outcome as right colic resection performed by conventional laparoscopy or laparotomy. Moreover, we assert that the da Vinci System allows better standardization of the surgical technique of right colectomy, positively increasing the percentage of correct lymphatic resections.

We agree with other authors (deSouza et al., 2010) that among all robotic colorectal resections, right colectomy may be also considered the ideal procedure for the surgeon at the beginning of the learning curve as the robotic left colectomy.

We consider the rectal anterior resection the procedure in which robotic system better expresses its potential advantages.

The current technique of TME was developed to reduce local recurrences and improve overall survival while maintaining an adequate quality of life. The concept of TME is founded on the anatomical dissection along the embryologic avascular areolar plane between the fascia propria recti and the parietal endopelvic fascia. The integrity of the mesorectum as well as clear circumferential and distal margins are important oncological and surgical end-points. Moreover, the complexity of the regional anatomy requires a precise and a sharp dissection under direct vision following anatomical pathways in order to preserve the autonomic innervation. All the advantages may contribute to improve oncological adequacy and nerve preservation during this procedure. The first step of TME starts with the incision of the posterior peritoneum at the level of the promontory on the bifurcation of the aorta into the common iliac arteries. At this level, the 3-D view allows the surgeon to better identify and preserve the preaortic nerves and the superior hypogastric plexus (SHP). The use of the articulated monopolar cautery hook helps to obtain a better energy delivery control, avoiding inopportune cauterization of the nervous bundle. Moreover, the steady image and the view magnification allow a correct identification of both fasciae and a sharp dissection of the “holy plane”. Any dissection strayed to the presacral fascia may lead to injuries to the ureters, autonomic nerves and presacral veins.

The second step of the TME consists in the anterior dissection, following the plane between the Denonvilliers’ fascia above and the fascia recti below. Denonvillier’s fascia can be easily identified by robotic view, helping the surgeon to carry out a precise incision of this fascia at the level of the seminal vesicles, avoiding gross manipulation of the tissue and unintentional injuries to the posterior capsule of the prostate (male) or posterior vaginal wall (female). The third step of TME includes the lateral mobilization of the rectum by incision of the lateral ligaments. A dissection close to the rectal wall avoids injuries to this nervous bundle. Moreover, a gentle counter traction of the rectum may help opening the dissection plane: this maneuver seems to be improved by robotic assistance thanks to the stability and motion scaling of the robotic arms. Excessive traction may lead to risk of injury to the pelvic splanchnic nerve. Robotic stereoscopic view, in addition, makes these structures more clearly visible. Middle rectal artery or its branches may be easily identified and cauterized without any peculiar difficulty. The tip articulation of the instruments facilitates the TME also, allowing a fine and precise dissection even in a narrow space, where dissection may result difficult by conventional laparoscopy or open surgery. This aspect is important as the reduction of the local recurrence rate is directly related to the optimization of the free surgical margins with recognition of the importance of clear radial (CRM) and distal mesorectal margins and of the distance from the tumor rim. The extent of circumferential tumor clearance after rectal cancer excision impacts long-term oncologic outcomes. In our experience, robotic assistance allowed us to achieve a 0% CRM < 2 mm rate and a correct mesorectal excision in all cases. Moreover, median lymph node number was 15.60 (12 – 21) and median specimen length was 23 (19 – 27,50). Length of stay was similar to laparoscopic series and shorter than open experiences. Operative time was 270 (240 – 315) min. A comparison of our results to main robotic experiences in Literature reveals similar trends in terms of length of stay, pathological findings and short-term outcome (table 4).

Author Year	Procedures	Operative Time	LN	Positive RM	Complications	LOS
Ashwin 2011	36	337.9 (81.8)	15 (7.8)	0	11 (30.6)	7.0 (5.8)
Baek 2010	41	296	13.1	1	9	6.5
Bianchi 2010	25	240*	18*	0	4	6.5*
Park 2010	41	231.9 (61.4)	17.3 (7.7)	2	12	9.9 (4.2)
deSouza 2010	44	347*0	14 (5–45)	0	11	5
Koh 2010	21	292.3 ± 32.6	17.8 ± 7.1	1	5	6.4 ± 4.1
Luca 2009	28	290 ± 69	18.5 ± 8.3	0	12	7.5 ± 2.8
D’Annibal e 2011	48	270*	15	0	4	8*

Table 4. Robotic rectal surgery experiences. LN: lymph nodes. LOS: length of stay

9. Conclusions

Laparoscopic colorectal surgery has become a mainstay in the treatment of benign and malignant colorectal diseases. Recently, a new update of the CLASICC trial has confirmed the oncological adequacy and the safety of laparoscopic colorectal surgery (Jayne et al., 2010).

There are some drawbacks, however, of the laparoscopic technique such as unstable video camera platform, limited motion of straight instruments, two-dimensional imaging, and poor ergonomics for the surgeon. Robotic surgery is spreading all over the world for many surgical procedures ranging from cardiac to general and urologic surgery thanks to its potential advantages overcoming the negative aspects of laparoscopic approach (Piazza et al., 1999; Reichenspurner et al., 2000; Kappert et al., 2000; Gill et al., 2000; Chen et al., 2009).

The da Vinci surgical system (Intuitive Surgical Inc., Sunnyvale, CA, USA) was the first telerobotic system approved for intra-abdominal surgery in the USA by the Food and Drug Administration (FDA, 2000). The first robot-assisted colectomy was reported by Ballantyne et al. in 2001 (Ballantyne et al., 2001). Since then, several surgeons have performed robotic colorectal surgery. The advantageous features of the robotic system are the physical separation of the surgeon from the patient, six degrees of freedom plus grasping of the robotic arms, hand-like motions of the instruments offering the surgeon the impression of an open access, elimination of tremor, optional motion downscaling (2:1 to 5:1), and three dimensional stereoscopic image (Ballantyne et al., 2002) The surgeons console and the projected three-dimensional virtual operative field offer an ergonomically comfortable position with minimum fatigue (Braumann et al., 2005).

In right colectomy procedures, we were able to perform correct R1 and R2 right colectomy, easily identifying the major colic vessels and carrying out accurate lymphadenectomy over the plane of the superior mesenteric axis, taking advantage of the steady, 3-D image view and of the articulation (Endowrist) of the robotic instruments, which allowed us to manage organs such as the pancreas or the duodenum gently. Our observation is that robotic technique could allow better standardization, leading to improved performance of minimally invasive right colic resection, especially in terms of achieving correct lymphatic

resection in a high fraction of cases. Moreover, if we compare our oncological results in terms of overall and disease-free survival to those in literature, it is clear how robotic right colic resection is able to offer the same short-term outcome as right colic resection performed by conventional laparoscopy or laparotomy not only by an oncological point of view but also by recovery time duration. In our experience, indeed, hospital stay was shorter than open one and comparable to laparoscopy.

In left colectomy procedures, the sole advantage of the robotic system consists in IMA dissection: the 3-D view and the Endowrist articulation allow the surgeon to better identify the preaortic parasympathetic fibers which may be incorrectly manipulated and injured, increasing the risk of sexual or urinary dysfunctions. Moreover, thanks to a stable and tridimensional view, it is possible to decrease the risk of vascular injuries. Besides this aspect, we believe that robotic left colectomy is to be considered as an initial step in the learning curve of robotic surgery for a surgeon.

In our opinion, the predominant procedure which best enhances the advantages of the robot is TME, and several other authors have reported their experience with the robot in TME. The main concerns about laparoscopic techniques relate to the poor dexterity and the rigidity of the instruments, the 2-dimensional view and the camera stability depending by the assistant skillness. The robot overcomes these limitations and allows for more precise oncologic dissection. In our experience, circumferential margins were acceptable and none of the analyzed specimens presented an infiltrated circumferential margin or less than 2 mm from the tumor bed. Moreover, the magnified, stable, 3-D view and the articulation of the tip of the robotic instruments allowed us to better identify the planes of dissection, so performing a correct nerve sparing resection and a correct TME as showed by the pathological reports. The advantages of the robotic system are emphasized especially in men, in which the narrow structure of the pelvis makes the dissection difficult by laparoscopy approach and “blinded” by open approach. Operative time is longer than the laparoscopic one, but we believe it may be reduced by experience. Moreover, the robot setup we adopted allows to reduce operative time by switching only one robotic arm from one trocar to another one, avoiding disengagement and re-engagement of the robotic system, as described by initial experiences. Recovery time was shorter than in open surgery, and morbidity was acceptable, confirming the safety and feasibility of robotic assistance in TME.

In conclusion, robotic assistance may help the surgeon in performing colorectal procedures and improve the patient outcomes and provides acceptable oncological results.

10. References

- Baik SH. Robotic colorectal surgery. *Yonsei Med J.* 2008 Dec 31;49(6):891-6.
- Ballantyne GH, Merola P, Weber A, Wasielewski A. Robotic solutions to the pitfalls of laparoscopic colectomy. *Osp Ital Chir.* 2001;7:405-12.
- Ballantyne GH. Robotic surgery, telerobotic surgery, telepresence, and telementoring. Review of early clinical results. *Surg Endosc* 2002; 16: 1389-1402.
- Ballantyne GH. The pitfalls of laparoscopic surgery: challenges for robotics and telerobotic surgery. *Surg Laparosc Endosc Percutan Tech* 2002;12:1-5.
- Braumann C, Jacobi CA, Menenakos C, Borchert U, Rueckert JC, Mueller JM. Computer-assisted laparoscopic colon resection with the Da Vinci system: our first experiences. *Dis Colon Rectum.* 2005 Sep;48(9):1820-7.


- Cadiere GB, Himpens J, Gernay O, et al. Feasibility of robotic laparoscopic surgery: 146 cases. *World J Surg* 2001;25:1467-77.
- Champault GG, Barrat C, Raselli R, Elizalde A, Catheline J-M. Laparoscopic versus open surgery for colorectal carcinoma. A prospective clinical trial involving 157 cases with mean follow-up of 5 years. *Surg Laparosc Endosc Percutan Tech* 2002;12:88-95.
- Chen CC, Falcone T. Robotic gynecologic surgery: past, present, and future. *Clin Obstet Gynecol*. 2009;52(3):335-43.
- Delaney CP, Lynch AG, Senagore AJ, Fazio VW. Comparison of robotically performed and traditional laparoscopic colorectal surgery. *Dis Colon Rectum*. 2003;46:1633-9.
- Delgado S, Lacy AM, Filella X, et al. Acute phase response in laparoscopic and open colectomy in colon cancer: randomized study. *Dis Colon Rectum* 2001;44(5):638-46.
- deSouza AL, Prasad LM, Park JJ, Marecik SJ, Blumetti J, Abcarian H. Robotic assistance in right hemicolectomy: Is there a role? *Dis Colon Rectum*. 2010;53(7):1000-6.
- Fleshman J, Sargent DJ, Green E, et al. Laparoscopic colectomy for cancer is not inferior to open surgery based on 5-year data from the COST study group trial. *Ann Surg*. 2007;246(4):655-62.
- Garcia-Ruiz A, Gagner M, Miller J, Steiner C, Hahn JF. Manual vs robotic assisted laparoscopic surgery in the performance of basic manipulation and suturing tasks. *Arch Surg* 1998;133:957- 61.
- Gattaj G, Ciccolallo L. Differences in colorectal cancer survival between European and US populations: the importance of subsite and morphology. *Eur J Cancer*. 2003;39:2214-22.
- Gill IS, Sung GT, Hsu TH, Meraney AM. Robotic remote laparoscopic nephrectomy and adrenalectomy: the initial experience. *J Urol*. 2000;164(6):2082-5.
- Guillou PJ, Quirke P, Thorpe H, et al. Short-term endpoints of conventional versus laparoscopic-assisted surgery in patients with colorectal cancer (MRC CLASICC trial): multicentre, randomized controlled trial. *Lancet*. 2005;365(9472):1718-26.
- Hanly EJ, Talamini MA. Robotic abdominal surgery. *Am J Surg* 2004; 188: 19S-26S.
- Hasegawa H, Kabeshima Y, Watanabe M, et al. Randomized controlled trial of laparoscopic versus open colectomy for advanced colorectal cancer. *Surg Endosc* 2003;17(4):636-40.
- Horgan S, Vanuno D. Robots in laparoscopic surgery. *J Laparoendosc Adv Surg Tech A* 2001; 11: 415-419.
- Hu JK, Zhou ZG, Chen ZX, et al. Comparative evaluation of immune response after laparoscopical and open total mesorectal excisions with anal sphincter preservation in patients with rectal cancer. *World J Gastroenterol* 2003;9(12):2690-4.
- Jayne DG, Gullou PJ, Thorpe H, et al. Randomized trial of laparoscopic-assisted resection of colorectal carcinoma: 3-year results of the UK MRC CLASICC trial group. *J Clin Oncol*. 2007;25(21):3061-8.
- Jayne DG, Thorpe HC, Copeland J, Quirke P, Brown JM, Guillou PJ. Five-year follow-up of the Medical Research Council CLASICC trial of laparoscopically assisted versus open surgery for colorectal cancer. *Br J Surg*. 2010 Nov;97(11):1638-45.
- Kaiser AM, Kang JC, Chan LS, et al. Laparoscopic-assisted vs. open colectomy for colon cancer: a prospective randomized trial. *J Laparoendosc Adv Surg Tech A* 2004;14(6):329-34.

- Kappert U, Cichon R, Schneider J, et al. Closed-chest coronary artery surgery on the beating heart with the use of a robotic system. *J Thorac Cardiovasc Surg.* 2000;120(4):809–11.
- Koopmann MC, Heise CP. Laparoscopic and minimally invasive resection of malignant colorectal disease. *Surg Clin North Am.* 2008;88:1047–72.
- Lacy AM, Garcia-Valdecasas JC, Delgado S, et al. Laparoscopy assisted colectomy versus open colectomy for treatment of non-metastatic colon cancer: a randomised trial. *Lancet.* 2002; 359(9325):2224–9.
- Lanfranco AR, Castellanos AE, Desai JP, Meyers WC. Robotic surgery: a current perspective. *Ann Surg* 2004; 239: 14–21.
- Law WL, Lee YM, Choi HK, et al. Impact of laparoscopic resection for colorectal cancer on operative outcomes and survival. *Ann Surg.* 2007;245(1):1–7.
- Leung KL, Lai PB, Ho RL, et al. Systemic cytokine response after laparoscopic-assisted resection of rectosigmoid carcinoma: a prospective randomized trial. *Ann Surg* 2000; 231(4):506–11.
- Milsom JW, Bohm B, Hammerhofer KA, et al. A prospective, randomized trial comparing laparoscopic versus conventional techniques in colorectal cancer surgery: a preliminary report. *J Am Coll Surg* 1998;187(1):46–54.
- Mirnezami AH, Mirnezami R, Venkatasubramaniam AK, Chandrakumaran K, Cecil TD, Moran BJ. Robotic colorectal surgery: hype or new hope? A systematic review of robotics in colorectal surgery. *Colorectal Dis* 2009 Jul 6 [Epub ahead of print]
- Moorthy K, munz Y, Adams S, Pandey V, Darzi A. A human factors analysis of technical and team skills among surgical trainees during procedural simulations in a simulated operating theatre. *Ann Surg* 2005;242: 631–39.
- Morino M, Pellegrino L, Giaccone C, Garrone C, Rebecchi F. Randomized clinical trial of robot-assisted vs. laparoscopic Nissen fundoplication. *Br J Surg* 2006; 93: 553–558.
- Nelson H, Sargent DJ, Wieand HS, et al. A comparison of laparoscopically assisted and open colectomy for colon cancer. Clinical Outcomes of Surgical Therapy Study Group. *N Engl J Med.* 2004;350(20):2050–9.
- Piazza L, Caragliano P, Scardilli M, Sgroi AV, Marino G, Giannone G. Laparoscopic robot-assisted right adrenalectomy and left ovariectomy (case reports). *Chir Ital.* 1999;51(6):465–6.
- Poulin EC, Mamazza J, Schlachta CM, et al. Laparoscopic resection does not adversely affect early survival curves in patients undergoing surgery for colorectal adenocarcinoma. *Ann Surg* 1999;229(4):487–92.
- Reichenspurner H, Boehm DH, Gulbins H, et al. Three-dimensional video and robot-assisted port-access mitral valve operation. *Ann Thorac Surg.* 2000;69(4):1176–81.
- Roxburgh CS, Salmond JM, Horgan PG, Oien KA, McMillan DC. The relationship between the local and systemic inflammatory responses and survival in patients undergoing curative surgery for colon and rectal cancers. *J Gastrointest Surg.* 2009;13:2011–8.
- Stage JG, Schulze S, Moller P, et al. Prospective randomized study of laparoscopic versus open colonic resection for adenocarcinoma. *Br J Surg.* 1997;84(3):391–6.
- Tang CL, Eu KW, Tai BC, et al. Randomized clinical trial of the effect of open versus laparoscopically assisted colectomy on systemic immunity in patients with colorectal cancer. *Br J Surg* 2001;88(6):801–7.

- Veldkamp R, Kuhry E, Hop WC, et al. Laparoscopic surgery versus open surgery for colon cancer: short-term outcomes of a randomised trial. *Lancet Oncol.* 2005;6(7):477–84.
- Weber PA, Merola S, Wasielewski A, Ballantyne GH. Telerobotic –assisted laparoscopic right and sigmoid colectomies for benign disease. *Dis Colon Rectum.* 2002 Dec;45(12):1689-94; discussion 1695-6.

IntechOpen

IntechOpen



Colorectal Cancer - From Prevention to Patient Care

Edited by Dr. Rajunor Ettarh

ISBN 978-953-51-0028-7

Hard cover, 538 pages

Publisher InTech

Published online 17, February, 2012

Published in print edition February, 2012

The projections for future growth in the number of new patients with colorectal cancer in most parts of the world remain unfavorable. When we consider the substantial morbidity and mortality that accompanies the disease, the acute need for improvements and better solutions in patient care becomes evident. This volume, organized in five sections, represents a synopsis of the significant efforts from scientists, clinicians and investigators towards finding improvements in different patient care aspects including nutrition, diagnostic approaches, treatment strategies with the addition of some novel therapeutic approaches, and prevention. For scientists involved in investigations that explore fundamental cellular events in colorectal cancer, this volume provides a framework for translational integration of cell biological and clinical information. Clinicians as well as other healthcare professionals involved in patient management for colorectal cancer will find this volume useful.

How to reference

In order to correctly reference this scholarly work, feel free to copy and paste the following:

Annibale D'Annibale, Graziano Pernazza, Vito Pende and Igor Monsellato (2012). Minimally Invasive Robot – Assisted Colorectal Resections, Colorectal Cancer - From Prevention to Patient Care, Dr. Rajunor Ettarh (Ed.), ISBN: 978-953-51-0028-7, InTech, Available from: <http://www.intechopen.com/books/colorectal-cancer-from-prevention-to-patient-care/minimally-invasive-robot-assisted-colorectal-resections>

INTECH
open science | open minds

InTech Europe

University Campus STeP Ri
Slavka Krautzeka 83/A
51000 Rijeka, Croatia
Phone: +385 (51) 770 447
Fax: +385 (51) 686 166
www.intechopen.com

InTech China

Unit 405, Office Block, Hotel Equatorial Shanghai
No.65, Yan An Road (West), Shanghai, 200040, China
中国上海市延安西路65号上海国际贵都大饭店办公楼405单元
Phone: +86-21-62489820
Fax: +86-21-62489821

© 2012 The Author(s). Licensee IntechOpen. This is an open access article distributed under the terms of the [Creative Commons Attribution 3.0 License](https://creativecommons.org/licenses/by/3.0/), which permits unrestricted use, distribution, and reproduction in any medium, provided the original work is properly cited.

IntechOpen

IntechOpen