

We are IntechOpen, the world's leading publisher of Open Access books Built by scientists, for scientists

6,900

Open access books available

186,000

International authors and editors

200M

Downloads

Our authors are among the

154

Countries delivered to

TOP 1%

most cited scientists

12.2%

Contributors from top 500 universities



WEB OF SCIENCE™

Selection of our books indexed in the Book Citation Index
in Web of Science™ Core Collection (BKCI)

Interested in publishing with us?
Contact book.department@intechopen.com

Numbers displayed above are based on latest data collected.
For more information visit www.intechopen.com



Superior Vena Cava Syndrome

Francesco Puma and Jacopo Vannucci
*University of Perugia Medical School,
 Thoracic Surgery Unit,
 Italy*

1. Introduction

1.1 Anatomy

The superior vena cava (SVC) originates in the chest, behind the first right sternocostal articulation, from the confluence of two main collector vessels: the right and left brachiocephalic veins which receive the ipsilateral internal jugular and subclavian veins. It is located in the anterior mediastinum, on the right side.

The internal jugular vein collects the blood from head and deep sections of the neck while the subclavian vein, from the superior limbs, superior chest and superficial head and neck.

Several other veins from the cervical region, chest wall and mediastinum are directly received by the brachiocephalic veins.

After the brachiocephalic convergence, the SVC follows the right lateral margin of the sternum in an inferoposterior direction. It displays a mild internal concavity due to the adjacent ascending aorta. Finally, it enters the pericardium superiorly and flows into the right atrium; no valve divides the SVC from right atrium.

The SVC's length ranges from 6 to 8 cm. Its diameter is usually 20-22 mm. The total diameters of both brachiocephalic veins are wider than the SVC's caliber. The blood pressure ranges from -5 to 5 mmHg and the flow is discontinuous depending on the heart pulse cycle.

The SVC can be classified anatomically in two sections: extrapericardial and intrapericardial. The extrapericardial segment is contiguous to the sternum, ribs, right lobe of the thymus, connective tissue, right mediastinal pleura, trachea, right bronchus, lymphnodes and ascending aorta. In the intrapericardial segment, the SVC enters the right atrium on the upper right face of the heart; in front it is close to the right main pulmonary artery. On the right side, the lung is in its proximity, separated only by mediastinal pleura. The right phrenic nerve runs next to the SVC for its entire course [1] (Figure 1).

The SVC receives a single affluent vein: the azygos vein. The azygos vein joins the SVC from the right side, at its mid length, above the right bronchus. The Azygos vein constantly receives the superior intercostal vein, a large vessel which drains blood from the upper two or three right intercostal spaces. In the case of SVC obstruction, the azygos vein is responsible for the most important collateral circulation. According to the expected collateral pathways, the SVC can be divided into two segments: the supra-azygos or

preazygos and the infra-azygos or postazygos SVC. There are four possible collateral systems which were first described in 1949 by McIntire and Sykes. They are represented by the azygos venous system, the internal thoracic venous system, the vertebral venous system and the external thoracic venous system [2]. The azygos venous system is the only direct path into the SVC. The internal thoracic vein is the collector between SVC and inferior vena cava (IVC) via epigastric and iliac veins. The vertebral veins with intercostals, lumbar and sacral veins, represent the posterior network between SVC and IVC. The external thoracic vein system is the most superficial and it is represented by axillary, lateral thoracic and superficial epigastric veins.

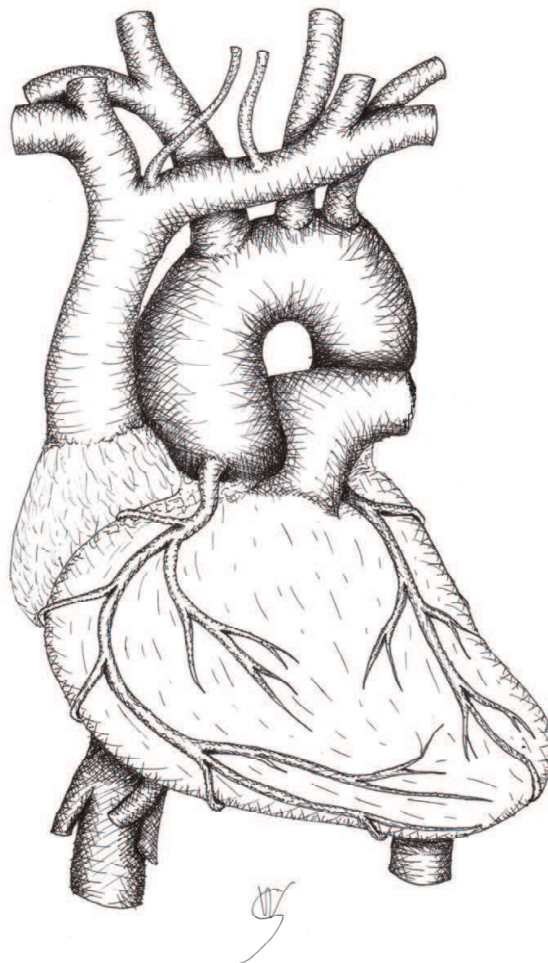


Fig. 1.

The SVC is a constituent part of the right paratracheal space (also called "*Barety's space*"), containing the main lymphatic route of the mediastinum, i.e. the right lateral tracheal chain. *Barety's space* is bounded laterally by the SVC, posteriorly by the tracheal wall, and medially by the ascending aorta. The nodes of the right paratracheal space are frequently involved in malignant growths: the SVC is undoubtedly the anatomical structure of this space which offers less resistance to compression, due to its thin wall and low internal pressure.

Anatomical anomalies are rare. The most frequent is the double SVC which has an embryologic etiology [1].

2. Etiology

SVC syndrome (SVCS) may be related to various etiological factors. Malignancies are predominant (95%) while, in the past, infectious diseases used to be common. During the last century, progression in anti-bacterial therapies and improvement in social conditions have led to a consistent decrease in the benign origin of this condition. The incidence of iatrogenic SVCS is currently increasing [3,4].

SVCS etiology is summarized as follows:

- Malignant
 - Lung cancer
 - Lymphomas
 - Thymoma
 - Mediastinal germ cell tumors
 - Mediastinal metastases
 - Mesothelioma
 - Leiomyosarcoma and angiosarcoma
 - Neoplastic thrombi
 - Anaplastic thyroid cancer
- Benign
 - Fibrosing mediastinitis (idiopathic or radiation-induced)
 - Infectious diseases (tuberculosis, histoplasmosis, echinococcosis, syphilis, aspergillosis, blastomycosis, filariasis, nocardiosis...)
 - Thrombosis (non-neoplastic)
 - Lymphadenopathies (sarcoidosis, Behçet's syndrome, Castelman's disease...)
 - Aortic aneurysm
 - Substernal goiter
 - Pericardial, thymic, bronchogenic cysts
- Iatrogenic
 - Pacemaker and defibrillator placement
 - Central venous catheters

3. Pathophysiology

The pathogenetic basis of SVCS is obstruction to the blood flow. It can result from intrinsic or extrinsic obstacles. The former are uncommon and are represented by thrombosis or invading tissue. Extrinsic factors develop from compression or stricture of the vein.

In physiologic conditions, blood return to the right atrium is facilitated by the pressure gradient between the right atrium and venae cavae. When obstruction of the SVC occurs, the vascular resistances rise and the venous return decreases. SVC pressure may increase consistently [4].

When SVC shows a significant stenosis (3/5 of the lumen or more), blood flow is redirected through the collateral circulation in order to bypass the obstruction and restore the venous

return [5]. The timing of the obstruction development is important for its clinical implications. In acute impairments, the blood flow is not rapidly distributed through the collateral network so symptoms arise markedly. In the case of slow-growing diseases, the collateral venous network has enough time to expand in order to receive the circulating volume. For this reason, long-lasting, severe SVC obstruction can sometimes be found without significant related signs and symptoms [3,6].

4. Clinical presentation

The SVC wall does not offer resistance to compression. When SVC lumen reduction is greater than 60%, hemodynamic changes occur: proximal dilatation, congestion and flow slowdown. The clinical signs of this condition are mainly represented by cyanosis (due to venous stasis with normal arterial oxygenation) and edema of the upper chest, arms, neck and face (periorbital initially). Swelling is usually more important on the right side, because of the better possibility of collateral circulation in the left brachiocephalic vein compared to the contralateral (Figure 2). Vein varicosities of the proximal tongue and dark purple ears are also typical. Other signs or symptoms are: coughing, epistaxis, hemoptysis, dysphagia, dysphonia and hoarseness (caused by vocal cord congestion), esophageal, retinal and conjunctival bleeding. In the case of significant cephalic venous stasis, headache, dizziness, buzzing, drowsiness, stupor, lethargy and even coma may be encountered. Headache is a common symptom and it is usually continuous and pressing, exacerbated by coughing. Epilepsy has been occasionally reported as well as psychosis, probably due to carbon dioxide accumulation [3,4,7-14]. Dyspnea can be directly related to the mediastinal mass or be caused by pleural effusion or cardiocirculatory impairment. Supine position may worsen the clinical scenarios.

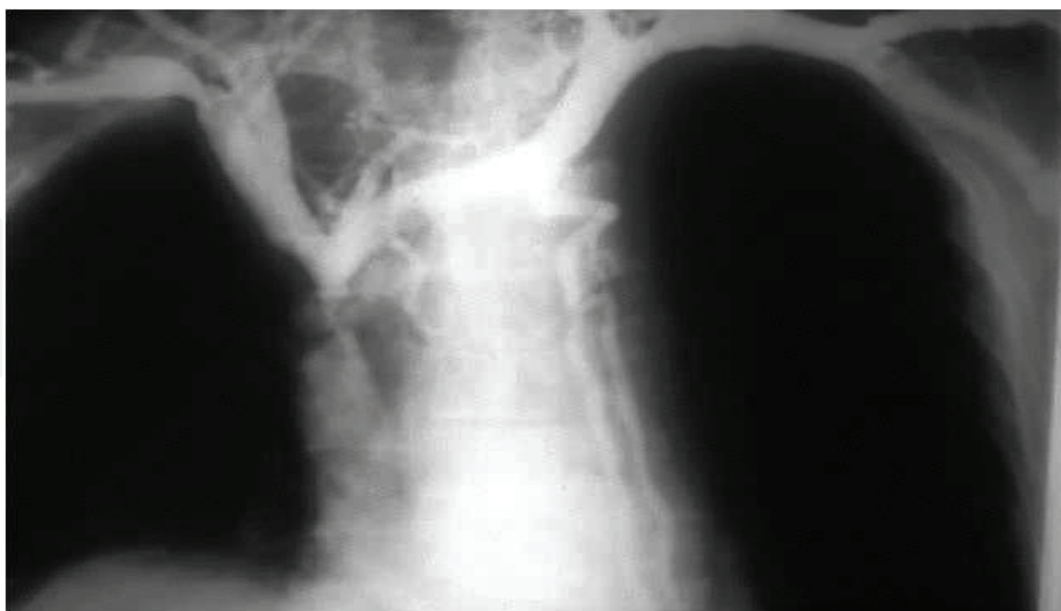


Fig. 2. Phlebogram showing obstruction of the SVC with azygos involvement. Blood return is distributed through a collateral circulation, mainly sustained by branches of the left brachiocephalic vein. Edema in this patient was more severe in the right arm than the left.

The clinical seriousness of the syndrome is related to several factors:

- Level of obstruction and rapidity of development, determining the effectiveness of collateral circulation
- Impairment of lymphatic drainage (pulmonary interstitial edema or pleural effusion)
- Involvement of other mediastinal structures (compression or invasion of heart, pulmonary artery and central airways, phrenic nerve paralysis...)

Intolerance of the supine position is always linked to a severe prognostic significance for patients with mediastinal syndromes [15]. The variation in decubitus may worsen the already existing signs and symptoms: in the supine position, an anterior mediastinal mass may compress the trachea or the heart by means of gravity, with possible cardiorespiratory problems. Direct compression of the common trunk of the pulmonary artery is also possible, although this is not as likely to happen, given that such structure is cranially protected by the aortic arch [16].

The presence of dyspnea at rest, especially in the sitting position, carries a severe prognostic significance in patients with mediastinal syndromes. Dyspnea at rest can be caused by either cardiovascular or respiratory problems:

- pulmonary congestion caused by lymphatic stasis
- combination with pulmonary atelectasis
- pleural effusion
- pericardial effusion
- direct compression of the mass on the airways, on the heart, or on the pulmonary artery
- laryngeal edema

Dyspnea at rest is not uncommon in the natural evolution of SVCS and it should always be considered as a high risk factor for invasive procedures under general anesthesia. If the shortness of breath is related to laryngeal edema, the patient should not be presented for general anesthesia and surgery.

Superficial dilated vascular routes are the main sign of collateral circulation and appear swollen and non-pulsating. In the case of marked obesity, superficial veins can be missing at inspection. The variety of collateral circulation and the differences in the venous re-arrangement are expression of the SVC obstruction site (Figure 3,4,5).

The anatomic classification includes three levels of obstruction:

1. Obstruction of the upper SVC, proximal to the azygos entry point.
 2. Obstruction with azygos involvement.
 3. Obstruction of the lower SVC, distal to the azygos entry point.
1. In this situation, there is no impediment to normal blood flow through the azygos vein which opens into the patent tract of the SVC. Venous drainage coming from the head neck, shoulders and arms cannot directly reach the right atrium. A longer but effective way is provided by several veins, the most important being the right superior intercostal vein. From the superior tract of the SVC, blood flow is reversed and directed to the azygos, mainly through the right superior intercostal vein. The azygos collateral system is eminently deep; therefore the presence of superficial vessels is usually lacking, even if possible in the area of the internal thoracic vein's superficial tributaries. The volumetric increase of the vessels can be consistent and capacity may increase up to eight times. The efficiency of this collateral route is reliable, thus the clinical compensation is unbalanced only in the case of a rapid development of the obstruction or if the stenosis is more than 90% (Figure 3).

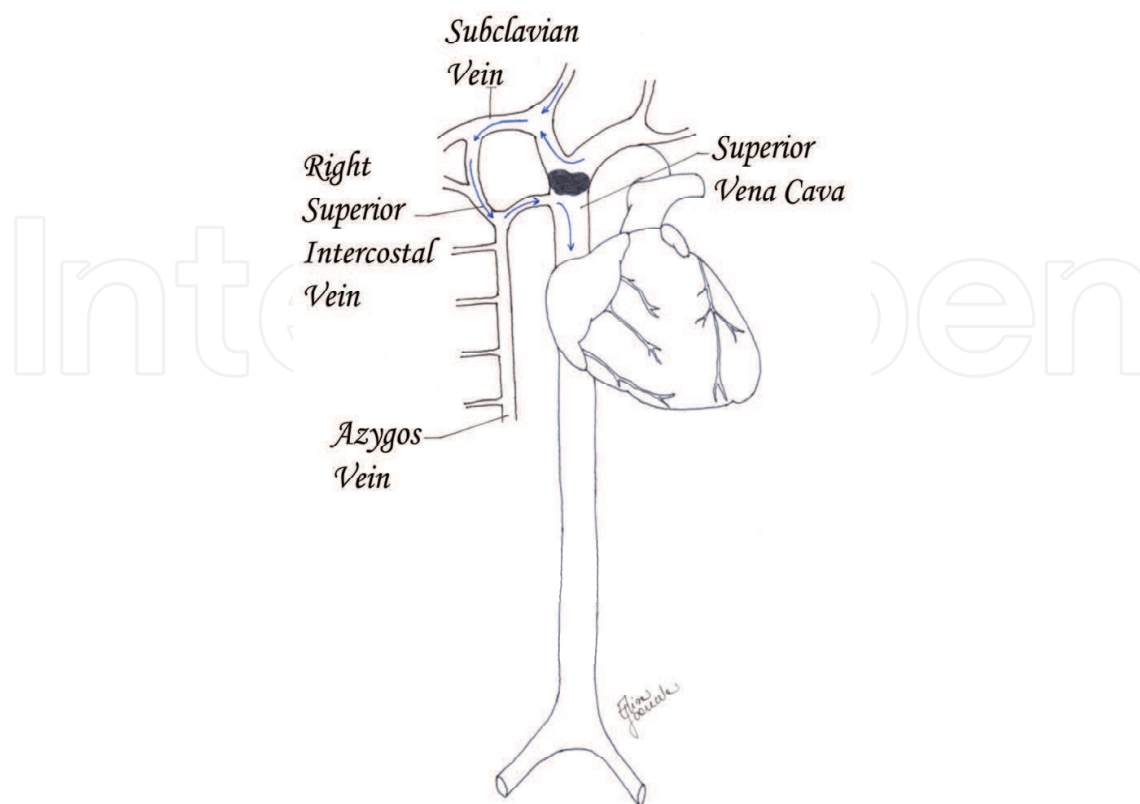


Fig. 3. Obstruction of the upper SVC, proximal to the azygos entry point. Collateral pathways.

2. In this case, the azygos vein cannot be available as collateral pathway and the only viable blood return is carried by minor vessels to IVC (cava-cava or anazygotic circulation). From the internal thoracic veins, blood is forced to the intercostal veins, then to azygos and emiazygos veins. The flow is thus reversed into the ascending lumbar veins to the iliac veins. Direct anastomosis between the azygos' origin and the IVC and between emiazygos and left renal vein are also active. In addition, the internal thoracic veins can flow into the superior epigastric veins. From the superior epigastric veins, blood is carried to the inferior epigastric veins across the superficial system of the cutaneous abdominal veins and finally to the iliac veins. Another course is between the thoraco-epigastric vein (collateral of the axillary vein) and the external iliac vein.

In these conditions, the collateral circulation is partly deep and partly superficial. The physical examination often reveals SVC obstruction. The reversed circulation through the described pathways, remains less efficient than the azygos system and venous hypertension is usually more severe. For this reason, this kind of SVC obstruction is often related to important symptoms, dyspnea and pleural effusion. The ensuing slow blood flow may be responsible for superimposed thrombosis. In the disease progression, renal impairment can evolve as the SVC obstruction affects the lumbar plexus (mostly the ascending lumbar veins, left side) which congests the renal vein (Figure 4).

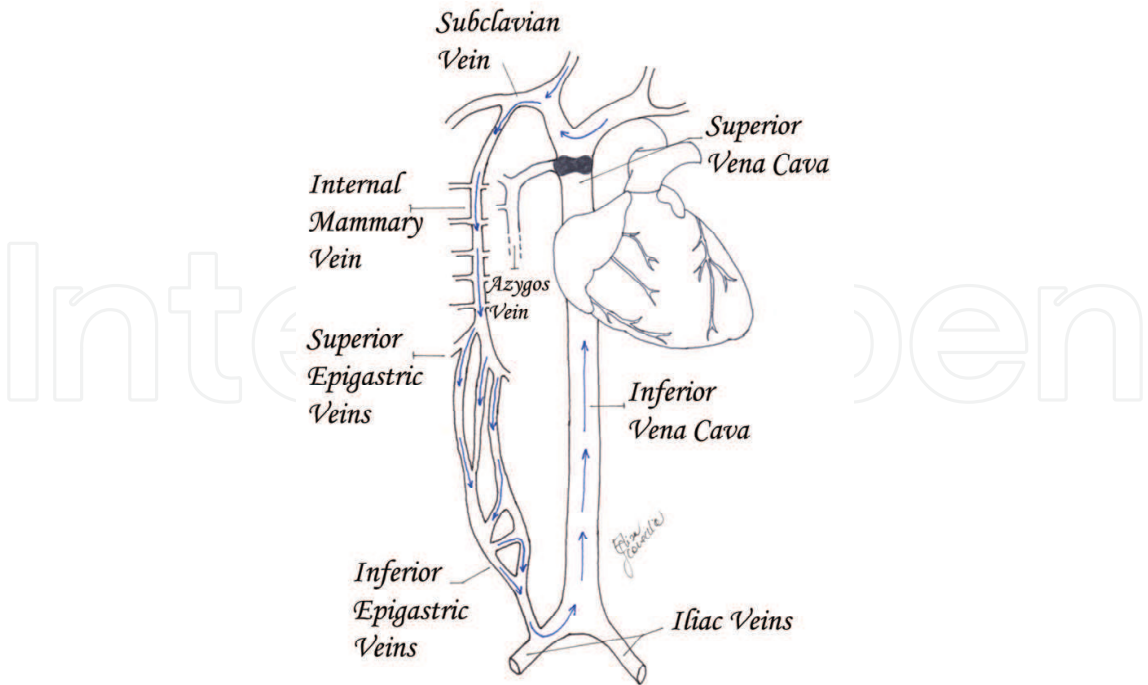


Fig. 4. Obstruction with azygos involvement. Collateral pathways.

3. In this condition, the obstruction is just below the azygos arch. The blood flow is distributed from the superior body into the azygos and emiazygos veins, in which the flow is inverted, to the IVC tributaries. In this type of case, the superficial collateral system is not always evident but the azygos and emiazygos congestion and dilatation are usually important. The hemodynamic changes lead to edema and cyanosis of the upper chest and pleural effusion. Pleural effusion is often slowly-growing and right-sided, probably due to anatomical reasons: there is a wider anastomosis between emiazygos and IVC than between azygos and IVC [17] (Figure 5).

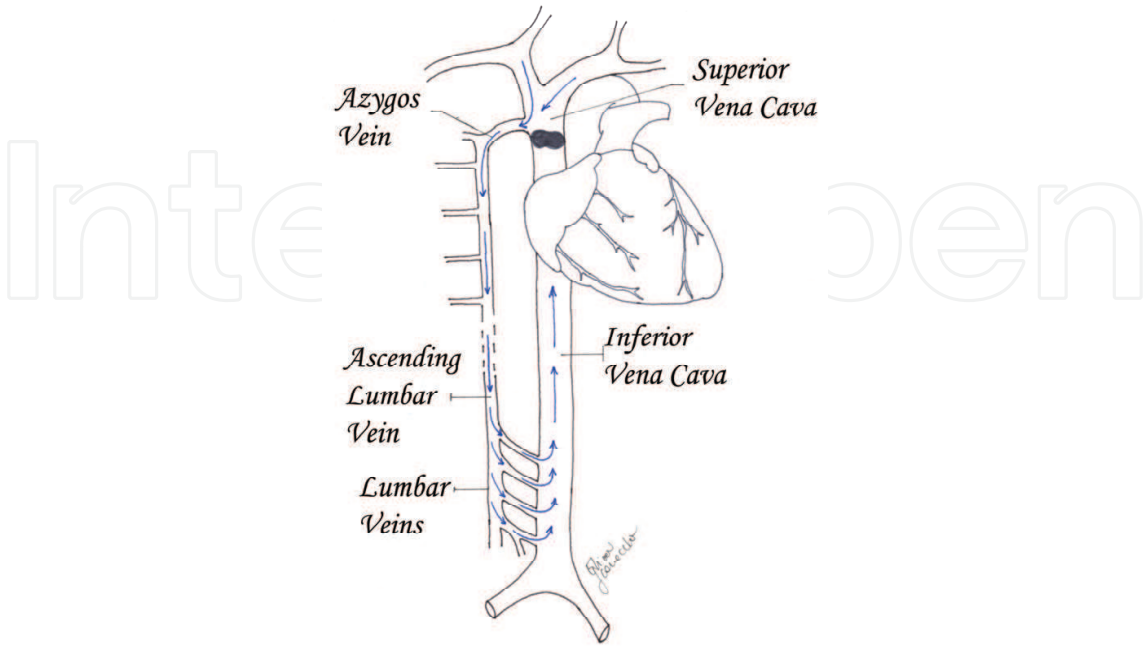


Fig. 5. Obstruction of the lower SVC, distal to the azygos entry point. Collateral pathways.

5. Classification of SVCS

Several classifications of SVCS have been proposed even though further investigations are required to achieve a definitive staging system. There are three main classification proposals which follow different methods of categorization [18-20].

1. Doty and Stanford's classification (anatomical)
 - Type I: stenosis of up to 90% of the supra-azygos SVC
 - Type II: stenosis of more than 90% of the supra-azygos SVC
 - Type III: complete occlusion of SVC with azygos reverse blood flow
 - Type IV: complete occlusion of SVC with the involvement of the major tributaries and azygos vein
2. Yu's classification (clinical)
 - Grade 0: asymptomatic (imaging evidence of SVC obstruction)
 - Grade 1: mild (plethora, cyanosis, head and neck edema)
 - Grade 2: moderate (grade 1 evidence + functional impairment)
 - Grade 3: severe (mild/moderate cerebral or laryngeal edema, limited cardiac reserve)
 - Grade 4: life-threatening (significant cerebral or laryngeal edema, cardiac failure)
 - Grade 5: fatal
3. Bigsby's classification (operative risk)
 - Low risk
 - High risk

The authors proposed an algorithm for SVCS to assess the operative risk in order to submit the patient to invasive diagnostic procedures. The low risk patients present: no dyspnea at rest, no facial cyanosis in the upright position, no change of dyspnea and no worsening of facial edema and cyanosis, during the supine position. The high risk patients present facial cyanosis or dyspnea at rest in the sitting position.

6. Diagnosis

Physical examination is often crucial: the presence of edema and superficial venous network of the upper chest may support the clinical diagnosis. Imaging studies are however required. Most cases are suspected at the standard chest X-ray and the most common radiological findings are right mediastinal widening and pleural effusion [3].

Computed tomography (CT) with multislice detector is the most useful tool in the evaluation of the mediastinal syndromes. CT imaging is widely employed in SVCS assessment because of its large availability and short acquisition time. Intravenous contrast should be administered, in order to provide high-quality vascular imaging. Contrast enhanced multidetector CT may show the site of the obstruction, some aspects of the primary disease and eventual intraluminal thrombi. Multiplanar and 3D reconstructions may provide better image detection and definition. The contrast flow can also help to distinguish the extent of the collateral network (Figure 6) [21].

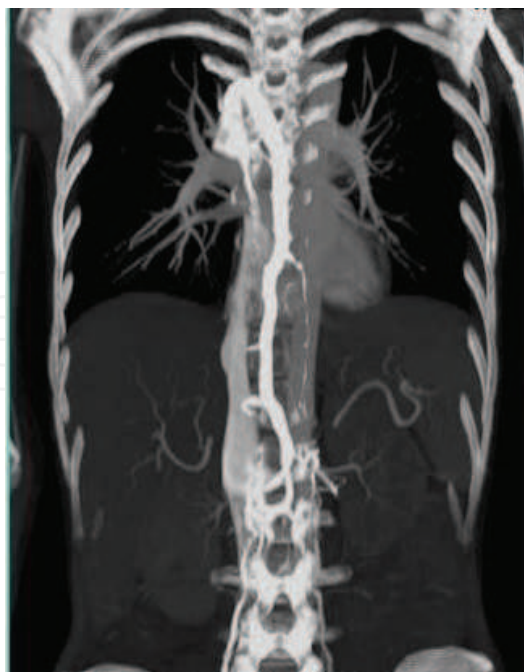

Fig. 6. Angio-CT scan: Obstruction of the lower SVC, distal to the azygos entry point. Collateral pathways: in the azygos vein system the blood flow is inverted and venous return occurs by means of IVC.

Magnetic resonance imaging (MRI) plays a side role; it is indicated when CT cannot be performed (e.g. pregnancy, endovenous contrast intolerance). The long acquisition times of MRI limit its use in critically ill patients.

Invasive venography is now rarely used due to the huge improvement in vascular CT imaging. It is currently performed only as a preliminary to operative procedures such as stent placement.

Once the thoracic imaging is obtained, the work-up should include brain, abdominal and bone studies in view of the probable malignant nature of the primary lesion. Recently Fluorodeoxyglucose-Positron Emission Tomography has gained an important role in oncology [22].

The histological definition remains the key factor for the causative treatment, in the case of neoplastic etiology. Superficial adenopathies have to be carefully investigated in order to find a possible source of tissue and the easiest target for biopsy. The invasive diagnostic procedure varies largely depending on the suspected malignancy and its site. The biopsy can be obtained through traditional bronchoscopy or echo-guided endoscopy, superficial node biopsy, mediastinoscopy, mediastinotomy, transthoracic needle biopsy, thoracoscopy, cervical or supraclavicular biopsies; thoracotomy and sternotomy are rarely indicated. Operative endoscopy has gained a new significance in the evaluation of SVCS since echography has been introduced but the best diagnostic result is still obtained by the mediastinoscopy. Venous hypertension may increase the procedure-related risk [23-27].

7. Treatment

Therapy should be causative. Syndrome management recognizes different levels of priority depending on the severity of symptoms, etiology and prognosis. SVCS needs a multidisciplinary approach and symptoms relief is often the first objective of complex care.

The therapeutic plan is usually targeted to clinical palliation. In fact, most cases are diagnosed as advanced-stage malignancies.

The patient must immediately assume an orthostatic position. Other supportive treatments are usually promptly established; oxygen, diuretics, and steroids are also suggested. The risk of an overlying thrombosis is particularly high and anticoagulant therapy should be introduced.

In case of malignancy, the treatment can have palliative or, rarely, curative intent. Chemotherapy is usually employed in lymphomas, small-cell lung cancer and germ cell tumors. Besides chemotherapy, radiotherapy is widely used in the treatment of non-small cell lung cancer. Radiation therapy can obtain good results but can also produce an initial inflammatory response with a possible temporary worsening [28,29]. Some cases must be approached as an emergency. In this type of situation, the treatment of choice is usually endovascular with the aim of restoring blood flow as soon as possible. The acute life-threatening presentation is the only situation in which radiotherapy before histological diagnosis can be considered. However, this approach should be avoided, whenever possible.

Endovascular stenting provides fast functional relief. It is the best option in an emergency and sometimes the clinical benefit is immediate. It is also advocated in the case of chemo-radiotherapy non-responders [3].

Surgery has a central role in the diagnosis but rarely in the therapy. A SVC resection and reconstruction is not often recommended and is a demanding procedure. The main proposal for SVC resection is direct infiltration in thymomas or in N0-N1 non-small cell lung cancer. In the case of infiltration of less than 30% of the SVC circumference, direct suture is favored (Figure 7). Larger involvements require a prosthetic repair. Different methods of SVC repair have been investigated using different materials (Figures 8, 9, 10a-b). Armoured PTFE grafts and biologic material are the preferred choices. Morbidity after SVC surgical procedures is high and the post-operative care must be intensive [4]. Long-term patency of a SVC by-pass graft is uncertain but, usually, the slow onset of the graft thrombosis favors the development of effective collateral circulation.

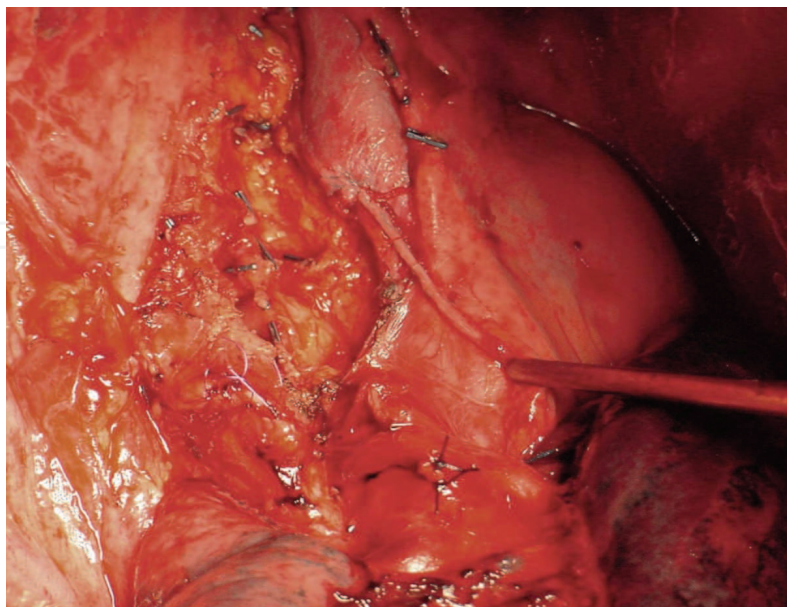


Fig. 7. SVC resection for limited infiltration by a right upper lobe NSCLC. The moderate stenosis following the direct SVC suture did not have hemodynamic consequences, in this patient.

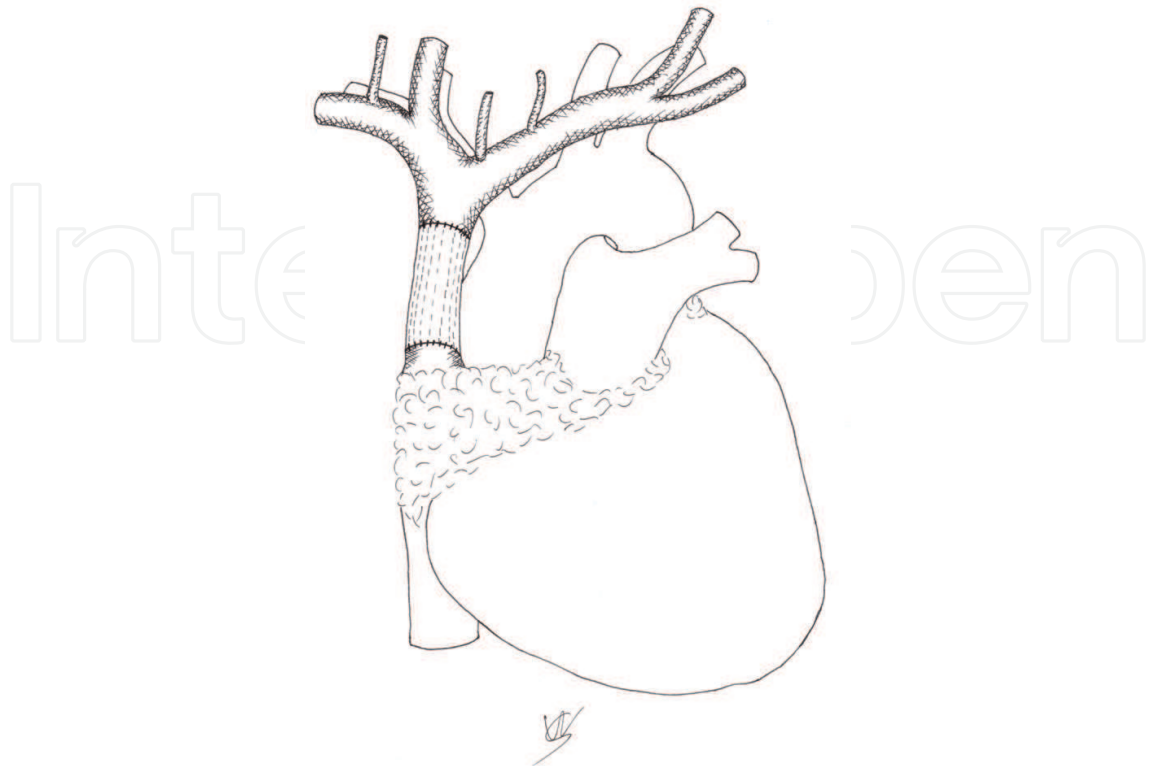


Fig. 8. Graft reconstruction by end-to-end anastomosis between proximal and distal SVC.

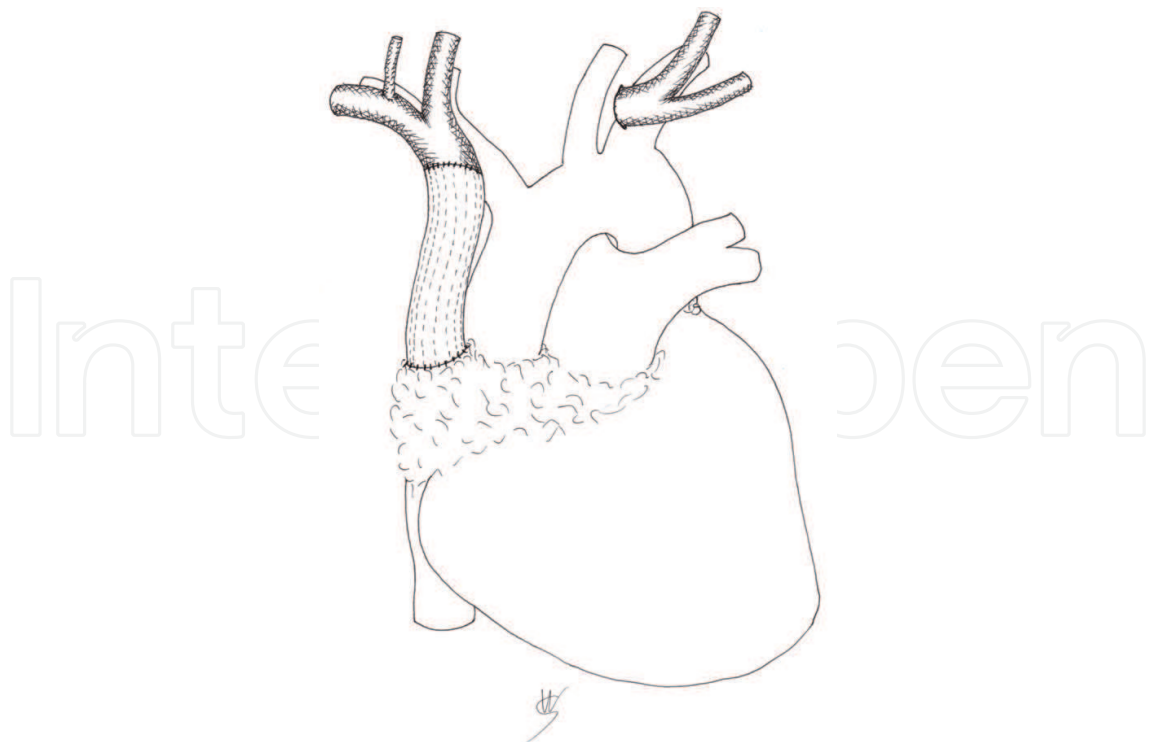


Fig. 9. Graft reconstruction of SVC by end-to-end anastomosis between the right brachiocephalic vein and the SVC.

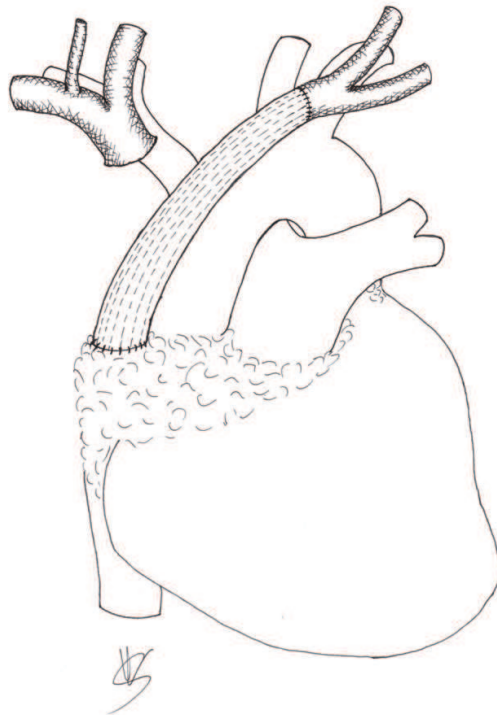


Fig. 10a. Graft reconstruction of SVC by end-to-end anastomosis between the left brachiocephalic vein and the SVC.

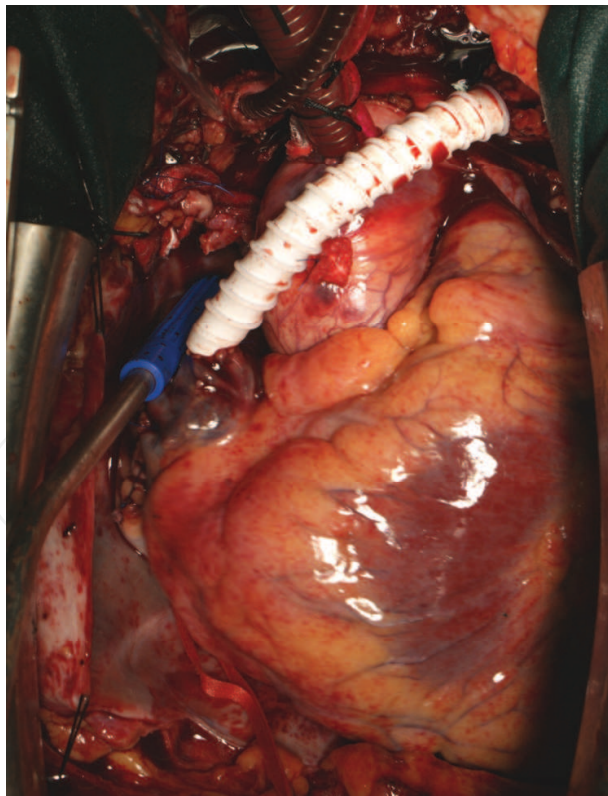


Fig. 10b. Armoured PTFE reconstruction of SVC by end-to-end anastomosis between the left brachiocephalic vein and the SVC.


Artworks by Walter Santilli R.N. and Elisa Scarnecchia M.D.

8. References

- [1] Testut L, Latarjet A. Trattato di Anatomia Umana. 4th edition, Unione tipografica – Editrice Torinese. 1971. pp. 918-921
- [2] McIntire FT, Sykes EM jr. Obstruction of the superior vena cava: A review of the literature and report of two personal cases. *Ann Intern Med* 1949; 30:925.
- [3] Wan JF, Bezjak A. Superior vena cava syndrome. *Hematol Oncol Clin North Am.* 2010; 24:501-13
- [4] Macchiarini P. Superior vena cava obstruction. In: Patterson GA, Cooper JD, Deslauriers J, Lerut AEM, Luketic JD, Rive TW, editors. *Pearson's thoracic & esophageal surgery*. 3rd edition, Philadelphia, PA: Churchill Livingstone, Elsevier; 2008. pp. 1684-96
- [5] Sy WM, Lao RS. Collateral pathways in superior vena cava obstruction as seen on gamma images. *Br J Radiol* 1982; 55:294-300
- [6] Rice TW, Rodriguez RM, Light RW. The superior vena cava syndrome: clinical characteristics and evolving etiology. *Medicine (Baltimore)* 2006; 85:37-42
- [7] Ahmann FR. A reassessment of the clinical implications of the superior vena caval syndrome. *J Clin Oncol* 1984; 2:961-969
- [8] Ganeshan A, Hon LQ, Warakaulle DR, Morgan R, Uberoi R. Superior vena caval stenting for SVC obstruction: current status. *Eur J Radiol.* 2009; 71:343-9
- [9] Armstrong BA, Perez CA, Simpson JR, Hederman MA. Role of irradiation in the management of superior vena cava syndrome. *Int J Radiat Oncol Biol Phys* 1987; 13:531-539
- [10] Yelling A, Rosen A, Reichert N, Lieberman Y. Superior vena cava syndrome: the Myth-the facts. *Am Rev Respir Dis* 1990; 141:1114-18
- [11] Schraufnagel DE, Hill R, Leech JA, Pare JAP. Superior vena caval obstruction: is it a medical emergency? *Am J Med* 1981; 70:1169-74
- [12] Chen JC, Bongard F, Klein SR. A contemporary perspective on superior vena cava syndrome. *Am J Surg* 1990; 160:207-11
- [13] Rice TW, Rodriguez RM, Barnette R, Light RW. Prevalence and characteristics of pleural effusions in superior vena cava syndrome. *Respirology* 2006; 11:299-305
- [14] Urruticoechea A, Mesía R, Domínguez J, Falo C, Escalante E, Montes A, Sancho C, Cardenal F, Majem M, Germà JR. Treatment of malignant superior vena cava syndrome by endovascular stent insertion. Experience on 52 patients with lung cancer. *Lung Cancer* 2004; 43:209-14
- [15] Northrip DR, Bohman BK, Tsueda K. Total airway occlusion and superior vena cava syndrome in a child with an anterior mediastinal tumor. *Anesth Analg* 1986; 65:1079-82
- [16] Levin H, Bursztein S, Haifetz M. Cardiac arrest in a child with an anterior mediastinal mass. *Anesth Analg* 1985; 64:1129-30
- [17] Introzzi P. Trattato Italiano di Medicina Interna, parte quinta. 2nd edition, Industria grafica "l'impronta". 1974. pp.1514-25
- [18] Stanford W, Doty DB. The role of venography and surgery in the management of patients with superior vena cava obstruction. *Ann Thorac Surg* 1986; 41:158

- [19] Yu JB, Wilson LD, Detterbeck FC. Superior vena cava syndrome--a proposed classification system and algorithm for management. *J Thorac Oncol* 2008; 3:811-4
- [20] Bigsby R, Greengrass R, Unruh H. Diagnostic algorithm for acute superior vena caval obstruction (SVCO). *J Cardiovasc Surg* 1993; 34:347-50
- [21] Sheth S, Ebert MD, Fishman EK. Superior vena cava obstruction evaluation with MDCT. *Am J Roentgenol* 2010; 194:336-46
- [22] Abner A: Approach to the patient who presents with superior vena cava obstruction. *Chest* 1993; 103:394-397
- [23] Mineo TC, Ambrogi V, Nofroni I, Pistolese C. Mediastinoscopy in superior vena cava obstruction: analysis of 80 consecutive patients. *Ann Thorac Surg* 1999; 68:223-6
- [24] Porte H, Metois D, Finzi L, Lebuffe G, Guidat A, Conti M, Wurtz A. Superior vena cava syndrome of malignant origin. Which surgical procedure for which diagnosis? *Eur J Cardiothorac Surg* 2000; 17:384-8
- [25] Trinkle JK, Bryant LR, Malette WG, Playforth RH, Wood RC. Mediastinoscopy--diagnostic value compared to bronchoscopy: scalene biopsy and sputum cytology in 155 patients. *Am Surg* 1968; 34:740-3
- [26] Jahangiri M, Taggart DP, Goldstraw P. Role of mediastinoscopy in superior vena cava obstruction. *Cancer* 1993; 71:3006-8
- [27] Callejas MA, Rami R, Catalán M, Mainer A, Sánchez-Lloret J. Mediastinoscopy as an emergency diagnostic procedure in superior vena cava syndrome. *Scand J Thorac Cardiovasc Surg* 1991; 25:137-9
- [28] Sculier JP, Evans WK, Feld R, DeBoer G, Payne DG, Shepherd FA, Pringle JF, Yeoh JL, Quirt IC, Curtis JE, et al. Superior vena caval obstruction syndrome in small cell lung cancer. *Cancer* 1986; 57:847-51
- [29] Lonardi F, Gioga G, Agus G, Coeli M, Campostrini F. Double-flash, large-fraction radiation therapy as palliative treatment of malignant superior vena cava syndrome in the elderly. *Support Care Cancer* 2002; 10:156-60

IntechOpen



Topics in Thoracic Surgery

Edited by Prof. Paulo Cardoso

ISBN 978-953-51-0010-2

Hard cover, 486 pages

Publisher InTech

Published online 15, February, 2012

Published in print edition February, 2012

Thoracic Surgery congregates topics and articles from many renowned authors around the world covering several different topics. Unlike the usual textbooks, Thoracic Surgery is a conglomerate of different topics from Pre-operative Assessment, to Pulmonary Resection for Lung Cancer, chest wall procedures, lung cancer topics featuring aspects of VATS major pulmonary resections along with traditional topics such as Pancoast tumors and recurrence patterns of stage I lung disease, hyperhidrosis, bronchiectasis, lung transplantation and much more. This Open Access format is a novel method of sharing thoracic surgical information provided by authors worldwide and it is made accessible to everyone in an expedite way and with an excellent publishing quality.

How to reference

In order to correctly reference this scholarly work, feel free to copy and paste the following:

Francesco Puma and Jacopo Vannucci (2012). Superior Vena Cava Syndrome, Topics in Thoracic Surgery, Prof. Paulo Cardoso (Ed.), ISBN: 978-953-51-0010-2, InTech, Available from:
<http://www.intechopen.com/books/topics-in-thoracic-surgery/superior-vena-cava-syndrome>

INTECH
open science | open minds

InTech Europe

University Campus STeP Ri
Slavka Krautzeka 83/A
51000 Rijeka, Croatia
Phone: +385 (51) 770 447
Fax: +385 (51) 686 166
www.intechopen.com

InTech China

Unit 405, Office Block, Hotel Equatorial Shanghai
No.65, Yan An Road (West), Shanghai, 200040, China
中国上海市延安西路65号上海国际贵都大饭店办公楼405单元
Phone: +86-21-62489820
Fax: +86-21-62489821

© 2012 The Author(s). Licensee IntechOpen. This is an open access article distributed under the terms of the [Creative Commons Attribution 3.0 License](https://creativecommons.org/licenses/by/3.0/), which permits unrestricted use, distribution, and reproduction in any medium, provided the original work is properly cited.

IntechOpen

IntechOpen