

We are IntechOpen, the world's leading publisher of Open Access books Built by scientists, for scientists

6,900

Open access books available

186,000

International authors and editors

200M

Downloads

Our authors are among the

154

Countries delivered to

TOP 1%

most cited scientists

12.2%

Contributors from top 500 universities



WEB OF SCIENCE™

Selection of our books indexed in the Book Citation Index
in Web of Science™ Core Collection (BKCI)

Interested in publishing with us?
Contact book.department@intechopen.com

Numbers displayed above are based on latest data collected.
For more information visit www.intechopen.com



Video-Assisted Thoracic Surgery (VATS) Systematic Mediastinal Nodal Dissection

Khalid Amer

*The Cardiovascular & Thoracic Unit, Southampton General Hospital, Southampton,
United Kingdom*

1. Introduction

VATS lobectomy and other major pulmonary resections (VMPR) are growing in popularity. One of the main criticisms against minimal access in lung cancer surgery is that mediastinal nodes could be difficult to assess. It was shown by different authorities that VATS complete nodal dissection is feasible and does not differ from that performed by an open thoracotomy [1]. Despite conflicting reports, there is an international agreement that nodal dissection does not influence the disease free or the overall survival in lung cancer. However; proper staging of Non Small Cell Lung Cancer (NSCLC) enables standardization of decision on treatment and evaluation of such treatment comparing it to different centres around the world. Recent publications have shown a significant statistical gain in 5 year survival if stage IIa and higher were treated by adjuvant chemotherapy [2, 3]. It is therefore absolutely mandatory to get the staging right in early lung cancer; otherwise patients would be denied a significant chance of cure. In a pressurised service where commissioning is governed by patients waiting times, targets and cost effectiveness, surgeons might feel reluctant to extend the operating time to perform Systematic Nodal Dissection (SND). The risk of improper mediastinal staging in our view is by far greater than extending the duration of the operation. The long-term results of stage migration lead to faulty comparison, and might dictate the wrong management, ending in completely erroneous survival statistics. Oncological randomised controlled trials rely on final histological staging, and therefore it is mandatory to obtain correct staging to avoid erroneous survival statistics in such trials. In our view the only contraindication to SND would be technical difficulty with dissection in the presence of severe adhesions

The way we stage lung cancer has changed over the years. The TNM6 classification [4] is now superseded by the IASLC new TNM7 classification [5]. Fortunately the naming and significance of nodal stations has not changed substantially. Precarinal nodes #3 for a left sided tumour is now considered an N3 stage. Precarinal nodes for a right sided tumour are designated as #4 (there are no #3R), and these are regarded as N2 disease.

2. Definitions

There are different protocols for staging the mediastinum in search of metastasis in N2 nodes. These include:

- Selective node sampling: the surgeon decides which node looked diseased and randomly removes that node (chance node).
- Sentinel nodal sampling: at operation the primary tumour is injected with ⁹⁹Technitium tracer, and a Geiger counter is used to identify the sentinel hilar nodes which are dissected. If frozen section confirmed absence of metastases, the rest of nodal dissection is omitted (decision node).
- Systematic nodal sampling: one or two nodes sampled from each zonal station (selective).
- Systematic Nodal dissection: at least 2 nodes from each field or station, and at least 3 fields are dissected (total of at least 6 nodes). Must always include subcarinal nodes (universally accepted) [6].
- Lobe-specific nodal sampling: oriented towards the different lymphatic drainage of different lobes e.g. for a right upper lobe tumour, the fields to harvest would be #2-4. Subcarinal lymphadenectomy is not always necessary for tumours of the right upper lobe and left upper trisegmentectomy (selective) [7].
- Extended nodal dissection: by definition means bilateral dissection of nodes (no consensus on extent).

Each of these protocols has points of strengths as well as weaknesses. In general the more the number of harvested nodes, the more likely it is to reveal normal looking nodes with metastatic tumour cells.

- Skip metastases: when stations N2 are involved in the absence of N1 involvement, or N3 involvement in the absence of either N1-N2 nodes. The importance of this phenomenon is not fully understood [8].
- Micrometastases: The prognosis of cancer patients is largely determined by the occurrence of distant metastases. The presence of clinically occult few malignant cells within nodal tissue, bone marrow and pleural fluid, and the clinical relevance of circulating tumour cells are still debatable. The importance of such nodal involvement is not fully understood, as it does not inevitably lead to disease dissemination and disease progression [9, 10].

3. Invasive v non-invasive staging

The tools of staging the mediastinum in NSCLC are either invasive in nature such that histological confirmation of nodal involvement is sought, or non-invasive, whereby an imaging technique is used to infer involvement of nodes by secondary metastasis. Invasive procedures such as mediastinoscopy, mediastinotomy, EBUS-TBNA (Endo Bronchial Ultra Sound - Trans Bronchial Fine Needle Aspirate) and EUS (Endoscopic or trans oesophageal Ultra Sound guided Trucut biopsy or FNA) are still developing. These investigations have limitations in terms of tissue yield, safety profile and cost. At best these are sampling techniques, aimed at sampling specific nodes which have been highlighted by other non-invasive techniques. None of these procedures can claim radical dissection of mediastinal nodes. However, recently VAMLA (Video Assisted Mediastinal Lymph Adenectomy) [11] has claimed bilateral mediastinal clearance of nodes, yet there are still issues with reaching stations #5L & #6L [figure 1] and the distant stations #8 & #9. To enhance the yield of nodes VATS was added to VAMLA to achieve radicality of nodal dissection [12]. On the other

hand TEMPLA (Transcervical Extended Mediastinal Lymph Adenectomy) was introduced in 2004, which involved a collar incision in the neck, elevation of the sternal manubrium with a special retractor, and claims bilateral dissection of all mediastinal nodes apart from #8 & #9 [13]. The choice of using any of the above mentioned techniques depends on the philosophy of nodal sampling versus radical adenectomy.

Non-invasive preoperative techniques have largely concentrated on CT and PET. Whilst Computed Tomography (CT) can give great anatomical details of the mediastinum and other chest anatomy, it cannot differentiate benign from malignant tissue. Positron Emission Tomography (PET) on the other hand was claimed to make that biological distinction.

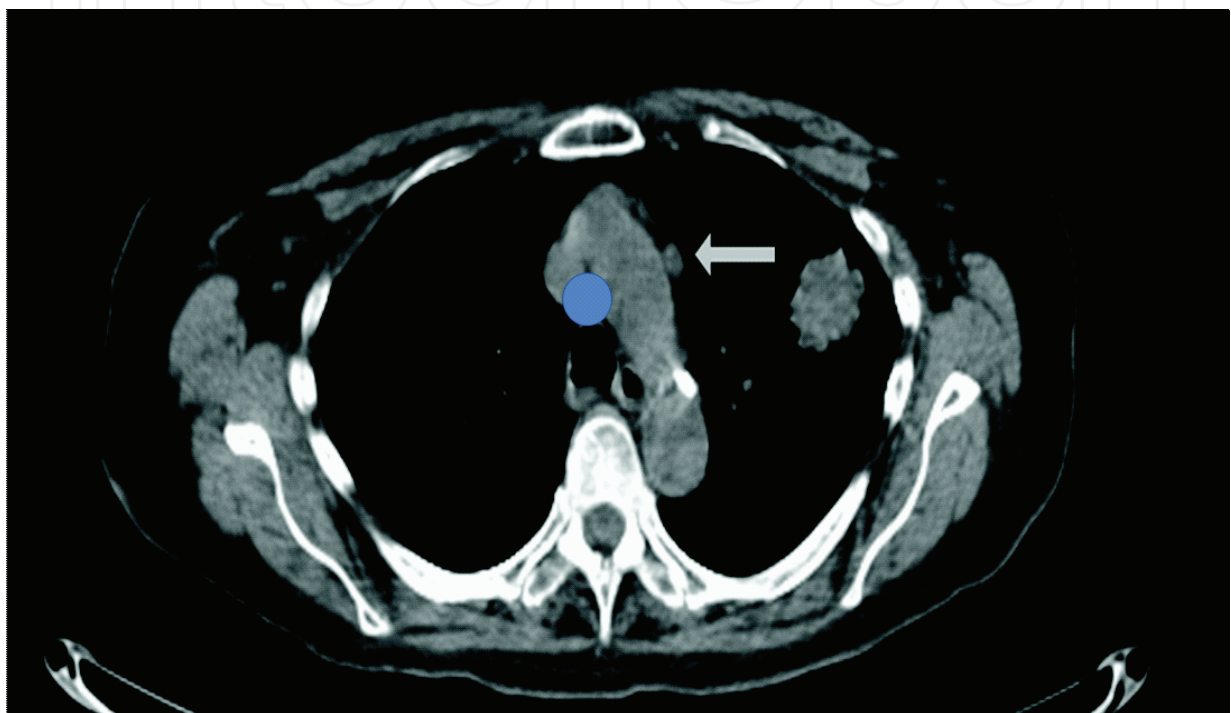


Fig. 1. Station #5L node out of reach of the mediastinoscope (blue circle).

4. The Role of PET

Great hopes were pinned on PET as it seemed to be the most convenient non-invasive staging tool for a fast tract keyhole surgery such as VMPR designed for early lung cancer. PET was expected to identify nodal disease in CT negative and normal looking mediastinum. Recent meta analysis reporting the PET/CT mediastinal staging in patients with NSCLC found the median sensitivity to be 85% (range 67% to 91%) and specificity of 90% (range 82% to 96%) [14]. Gilles et al and Plathow et al summarised the current views about the elevated glucose metabolism in cancers [15,16]. Tumour cells adapt to hypoxia by upregulation of glucose Transporter (GLUTs) and increased activity of Hexokinase. The GLUT is the first energy-independent glucose transporter across the cell membrane down the concentration gradient. Tumours increase their level of energy production by engaging in glycolysis, which is a relatively inefficient way to produce energy compared to aerobic oxidation (2 ATP molecules versus 30 ATPs). The toxic acidic tumour microenvironment results in death of normal tissue while tumour cells evade apoptosis by maintaining normal

intracellular pH. It is thought that this process give the tumour cells a competitive advantage for local growth, ultimately leading to invasion of basement membrane and distant metastases. Primary tumours and their nodal secondaries express high GLUT1 upregulation, which in turn is tied to ^{18}F -FDG accumulation in the tumour cell, and hence directly related to SUV_{max} (Maximum Standard Uptake Value). GLUT expression is tied to tumour cell type and differentiation. Squamous cell carcinoma exhibit over expression of GLUT1 whereas adenocarcinoma does not. One of the serious disappointments of PET scanning in lung cancer is the low uptake of carcinoids, adenocarcinoma and bronchioloalveolar carcinomas, in some series up to 40%. This tumour biological behaviour explains why PET is blinded to adenocarcinoma, Bronchiolo-alveolar carcinoma (BAC) and carcinoids tumours. For the same reason the importance of the SUV_{max} (>3.5) as a surrogate value for malignancy has been played down. Another important snag about the uptake of the FDG metabolite is the mass of active tissue. A node under 1cm in diameter is unlikely to show up as a hot spot on PET even if it was completely replaced by secondary malignant tissue. Al-Sarraf et al found that integrated CT/PET images had reduced sensitivity for non-enlarged $<1\text{cm}$ nodes (40%) [17]. Clinicians should be aware of this fact when interpreting the results, and histological confirmation should be sought on CT positive ($>1.0\text{cm}$ in its shortest diameter) or PET positive nodes. The international literature seems to suggest that the rate of unexpected (occult) N2 disease in c-N0-1 to be 10%. It is likely that the role of PET will continue to evolve with further clinical studies using other new tracers such as the thymidine analogue 3'-deoxy-3'-[^{18}F]fluorothymidine, which more specifically targets proliferative activity of malignant lesions and can differentiate them from the false-positive inflammatory lesions, as seen with FDG [18]. It should not be forgotten that one of the very useful functions of routinely performed PET in early lung cancer is to exclude obvious metastases to liver, adrenal, bone etc that would have otherwise precluded curative resection [figure 2].

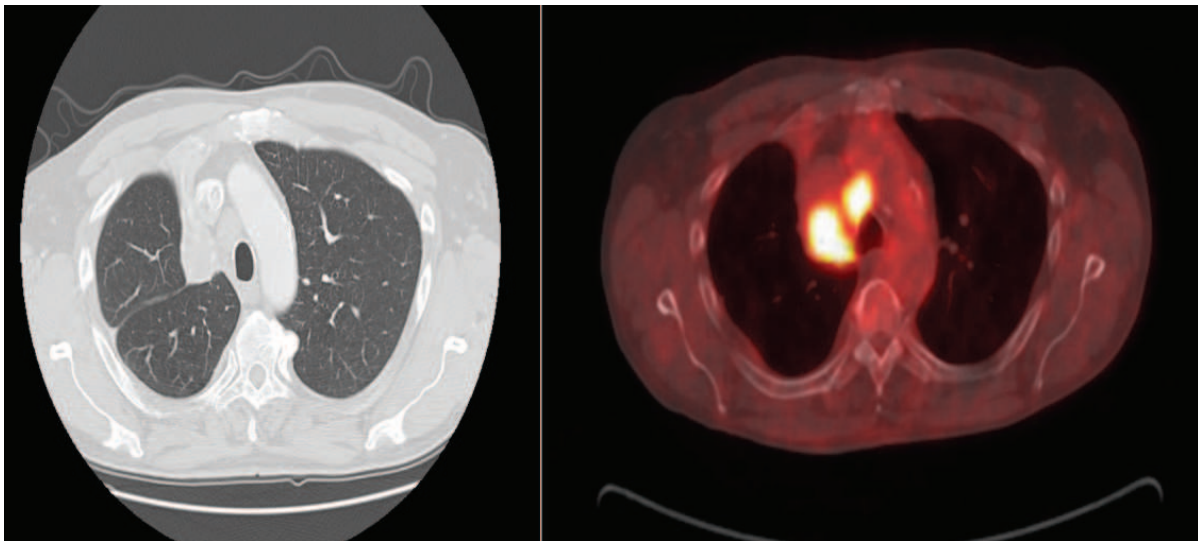


Fig. 2. CT/PET of a patient with right upper lobe lesion. Bronchoscopy obtained squamous cells carcinoma. The high intake of ^{18}F FDG seen in precarinal node #4R was sufficient evidence not to proceed with mediastinoscopy. The patient was treated by chemo-Radiotherapy.

5. Preoperative v postoperative staging

The significance of preoperative as opposed to postoperative staging in resectable early lung cancer is tied to what the clinician wants to do with the information. There might be little disagreement about the N1 disease, but controversy surrounds N2 disease. In our opinion For a CT negative and PET negative mediastinum, no further investigation is needed, and patients should proceed to resectional operation + SND. Further multidisciplinary management should be based on SND staging. This is in line with the latest published British Thoracic Society (BTS) guidelines [19]. The dilemma arises when there is histological evidence of single station N2 disease preoperatively. The choices being (1) avoid surgery all together and opt for chemo-radiotherapy (2) induce chemotherapy before surgery, or (3) make a run for surgery while the tumour is operable and follow that by adjuvant chemotherapy / radiotherapy. The first approach is advocated by Albain et al (2009) who showed that lobectomy will add little to Chemo-radiotherapy for patients with stage IIIa (N2) non-small-cell lung cancer, at the expense of higher mortality (evidence level 1b) [20]. The second approach is supported by the S9900 trial follow up published in 2010 which continues to show that the best treatment for N2 resectable lung cancer would be induction chemotherapy followed by surgery (evidence level 1b) [21]. Rocco et al (2010) is supportive of the third approach, concluding that standard treatment of initially resectable stage IIIa NSCLC remains surgery followed by adjuvant chemotherapy (evidence level 2a) [22]. The subject remains controversial, and patients should be involved in decision taking. Surgery is known to give local control and reduce local recurrence, whereas chemotherapy is a systemic treatment designed to reduce disease progression and distant metastases. Currently we rely on CT/PET, mediastinoscopy or EBUS to direct the patient to one form of treatment or prevent unnecessary operation. However, Lim et al conducted a systematic review of all the published meta-analysis of randomised trials in preoperative versus postoperative chemotherapy in patients with resectable lung cancer (evidence level 1a) [23]. They concluded that in patients with resectable lung cancer, there was no difference in overall and disease-free survival between the timing of administration of chemotherapy (postoperative versus preoperative). Clearly this sends a strong message that earnest preoperative investigation of the mediastinum in PET negative resectable early lung cancer might be unnecessary. Myers et al specifically considered the cost effectiveness of routine mediastinoscopy in CT-negative, PET-negative patients with stage I lung cancer [24]. They concluded that routine mediastinoscopy would add an average 0.01 years (3.65 days) of life at a cost of \$201,918 per life-year gained. Therefore they do not recommend routine mediastinoscopy in PET-negative patients. Our practice advocates neoadjuvant chemotherapy followed by surgical VMPPR-SND followed by adjuvant chemotherapy based on proper SND staging, provided nodal involvement remains single station or single zonal. Multizonal involvement is best served by chemo-radiotherapy, as it is regarded as systemic disease. Surgery alone will not have an impact on the 5 years survival, but might have a palliative effect on local recurrence, and might be considered for instance to control haemoptysis, or continued sepsis precluding the start of other modalities of treatment such as chemotherapy.

6. Where are these mediastinal nodes?

Although nodal mapping has been there for a long time, it seems that there is considerable discordance in nomenclature and designation of nodal stations between Asian and European

thoracic surgeons [25]. Historically the Naruke map was the most popular and most followed worldwide until recently [26]. The American Thoracic Society introduced the Mountain-Dressler ATS map in 2007, and finally Rusch et al from the Memorial Sloan-Kettering Cancer Centre introduced the current IASLC nodal map (International Association for the Study of Lung Cancer 2009) to achieve uniformity and to promote analyses of a planned prospective international database [27]. The IASLC map reconciles differences among other used maps, and provides precise anatomic definitions for all lymph node stations. A method of grouping lymph node stations together into "zones" is also proposed for the purposes of future survival analyses [Figure 3]. It goes without saying that surgeons should familiarise themselves with the details of this map to standardise the staging process in any given centre.

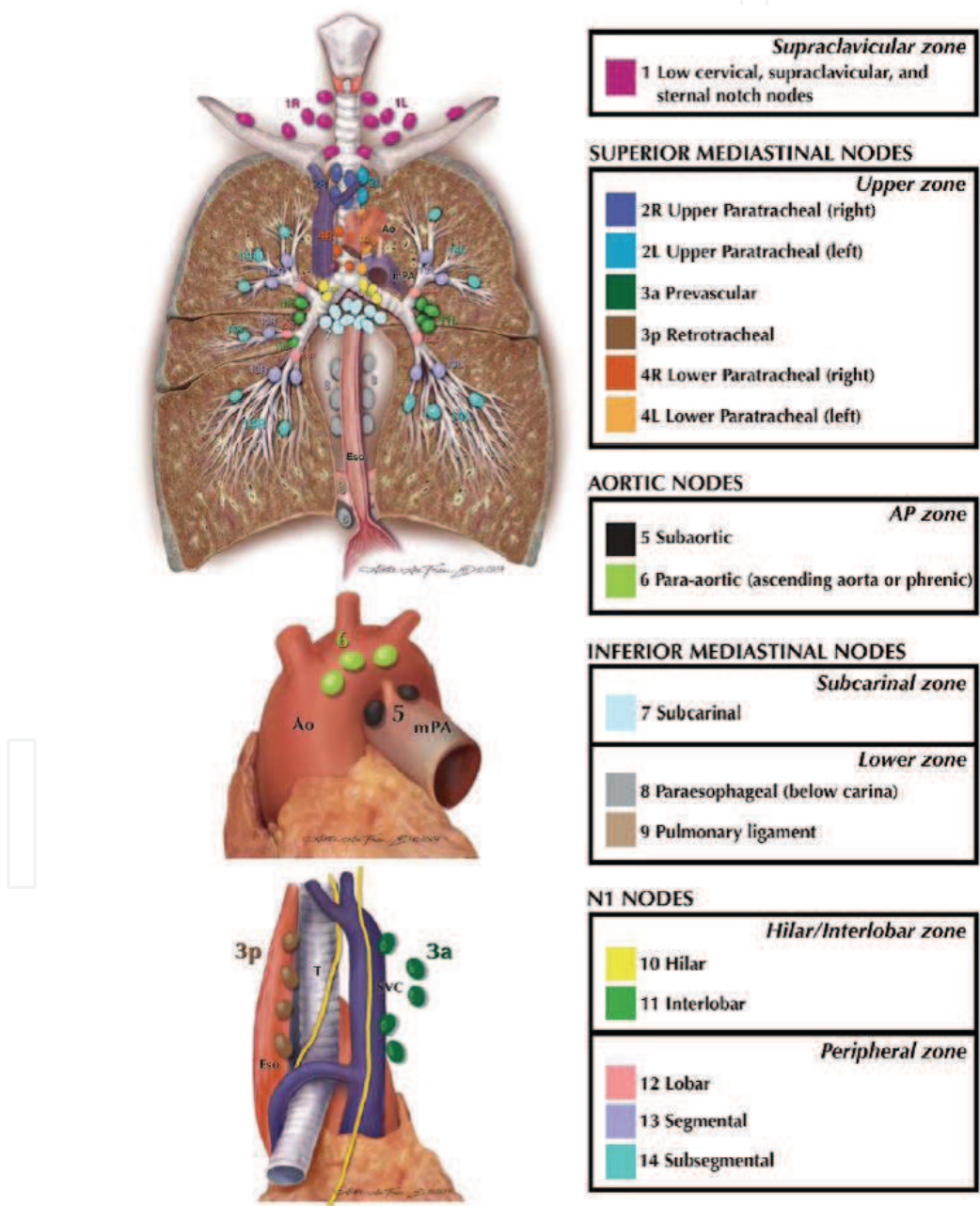


Fig. 3. The IASLC 2009 Nodal map.

7. VATS-SND: Can it be comprehensive?

One of the major criticisms against VATS lung cancer resection is that it is not an oncologically feasible operation, as assessment of the mediastinal nodes is not as complete as open thoracotomy. Comprehensive radical nodal dissection is possible by VATS and should not be different to open thoracotomy, as described by Watanabe et al [1]. The number of harvested nodes is an accepted surrogate to completeness of SND. 99% of patients should have 6 or more nodes harvested from 3 stations as reported in the ACOSOG Z0030 Trial [28]. Racial variations might play a role in the total number of nodes harvested. Video-assisted surgical approach should not adversely affect the yield of lymph node harvest, however; despite extreme care it is sometimes unavoidable to fragment nodes during harvesting [29]. There are few published studies that attest to completeness of VATS-SND, but the most impressive was that of Sagawa et al [30]. After VATS lobectomy-SND, a standard thoracotomy was subsequently opened by a different surgeon to complete systematic nodal dissection and revisit the VATS-SND dissection. The average addition to VATS-SND was 1.2 nodes only. The remnant ("missed" by VATS) lymph nodes and tissues were 2-3%, which seems acceptable for clinical stage I lung cancer. No nodal involvement was observed in the remnant lymph nodes. It would be difficult to obtain clearance for such a study in Europe, but its results are resounding assurance that with practice, VATS SND should be identical to open SND.

8. VATS-SND: How to do it

VMPR is usually considered for early lung cancer T1-2, N0-1 and M0. The decision to include these patients in the VATS series is based on CT/PET studies. The procedure is performed under general anaesthesia, utilising single lung ventilation. 3 ports are fashioned, 2X1cm and a utility port 3-4cm long at the mid-axillary line over the 4th or 5th intercostal space. Nodal harvesting can be performed before, during or after the VATS resection (lobectomy, pneumonectomy, segmentectomy etc) according to published European and international standards [6, 26,28,31].

SND criteria:

- *At least 3 fields nodal dissection*
- *At least 2 nodes from each field*
- *Subcarinal #7 always included*

Southampton "Motto":

- *Every visible node!*
- *"if you see a node, it should be in a pot.."*

We harvest nodes en-block, stations 2-4,7,8,9,10 and 11 on the right, preserving the Azygos vein, and 4,5-6,7,8,9,10, 11 on the left side, preserving the ligamentum arteriosum [32]. We

do not harvest #1 bilaterally, or #2 on the left. However, we harvest #3 (precarinal) when indicated on the left chest without dividing the ligamentum arteriosum by retracting the main pulmonary artery up and pushing the carina down¹. Subcarinal nodes #7 were mandatory for the definition of SND, and if these were not harvested the procedure would have been classified as 'Nodal sampling' and not SND [6]. The procedure extends the operative time by 30 minutes on the right chest and between 45-60 minutes on the left chest. VATS-SND during VMPPR requires patience. Whereas en block dissection on the right is straight forward, that on the left is more taxing. Subcarinal #7 on the left is the most time consuming, as the space has to be clearly displayed. We routinely access it from the back of the hilum, starting with SND before resecting the lung. We found great variation in the number and consistency of nodal groups, especially #8 and #9. Nodes could be completely absent, discrete or lumped in a fibro-fatty tissue amenable to block dissection.

Right side:

Planning the port sites is an important part of nodal dissection, and if the ports are set too low the dissection will be a struggle. The anterior utility port should not be lower than the 5th space, and preferably on the 4th space. The posterior port is fashioned over the auscultatory triangle 1-2 finger breadths from the medial border of the scapula. The inferior port is created opposite the highest point in the dome of the diaphragm, in line with the hilar axis [Fig. 4].

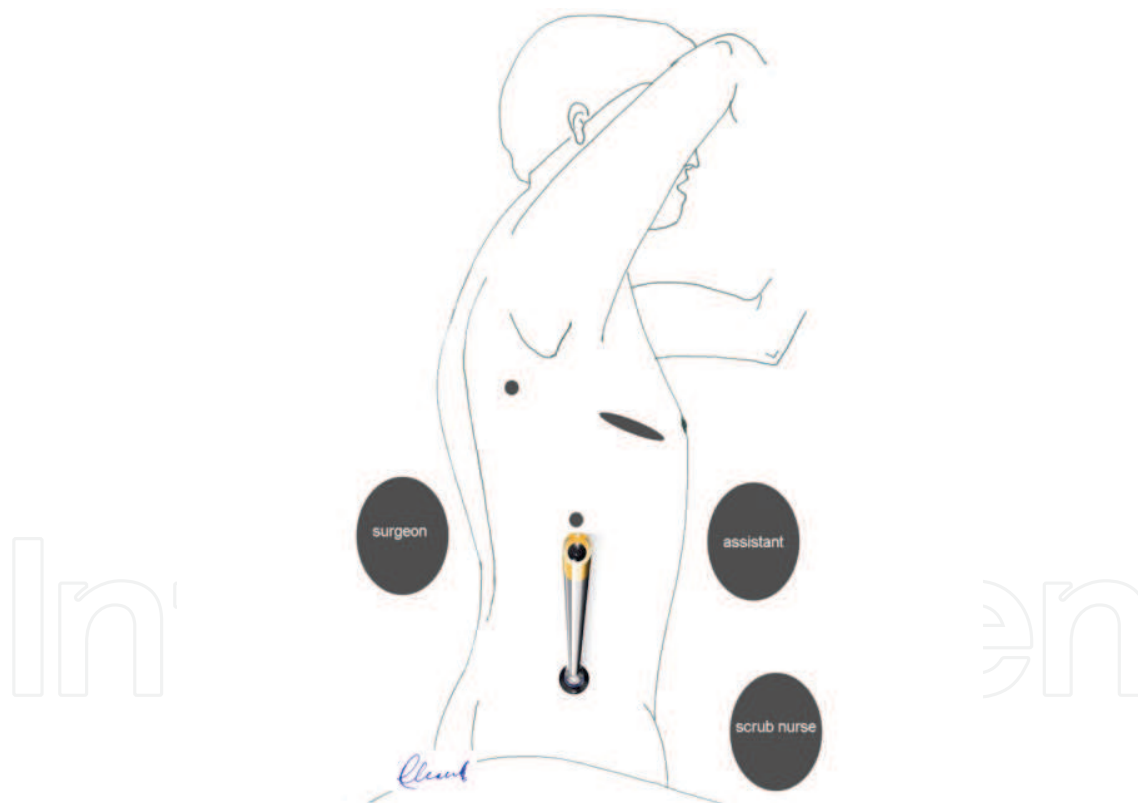


Fig. 4. The camera scope is inserted from the inferior port, and remains there.

¹ Amer K (2011). Routine Systematic Mediastinal Nodal Dissection During VATS Major Pulmonary Resections – The Southampton Technique. Available http://www.ctsnet.org/sections/videosection/videos/vg2011_AmerK_SystematicMediastinal.html. last accessed 01.04.2011

SND is started by releasing the inferior pulmonary ligament, and exposing the inferior pulmonary vein, bringing #9 nodes into light [Fig. 5].

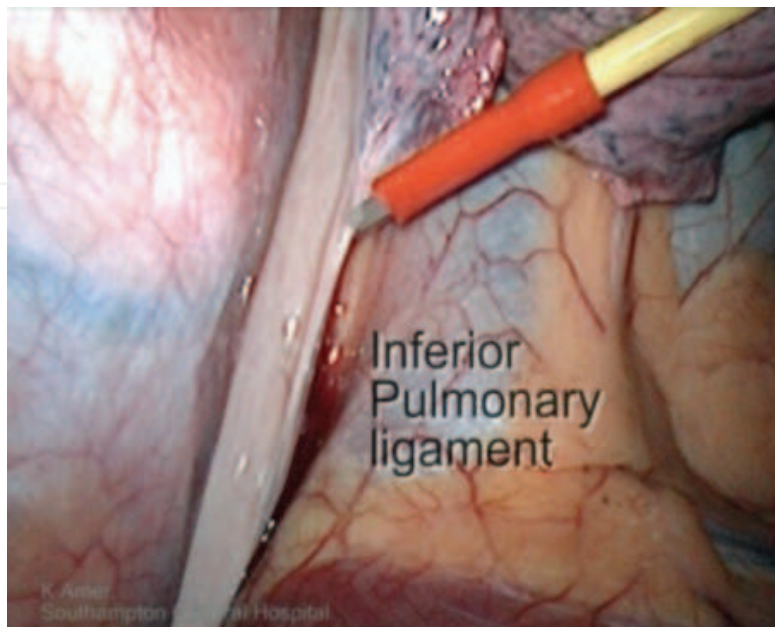


Fig. 5. Releasing the inferior ligament.

The pleural reflection between the SVC and the oesophagus is opened down to the diaphragm, exposing #8 para-oesophageal nodes. The number and consistency of nodes in #8-9 vary greatly. Our method of dissection has evolved into using a malleable diathermy spatula which is insulated albeit for the last 1-2 mm, whilst keeping the energy level at low. Diathermy dissection reduces bleeding and chyle leak, and keeps the operative field neat. Dissection of #8-9 nodes is usually straight forward [Fig. 6-7].

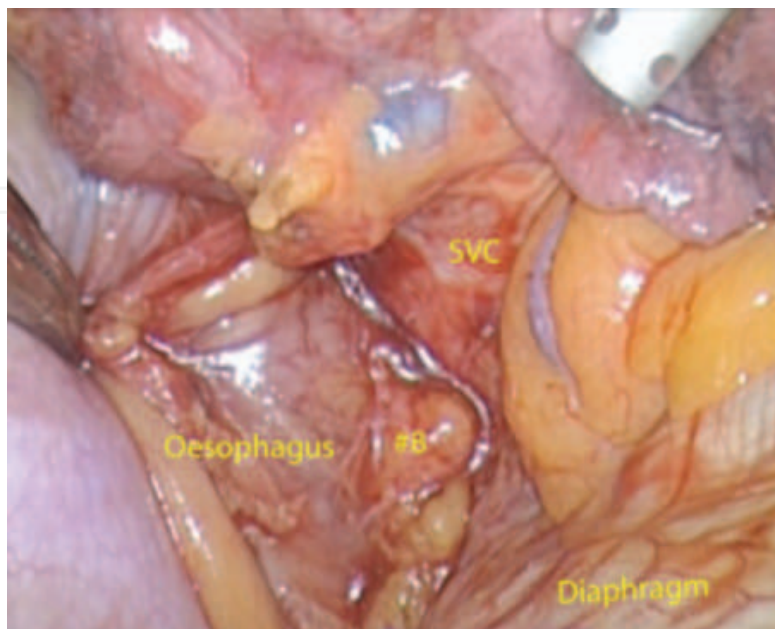


Fig. 6. En-block dissection of #8.

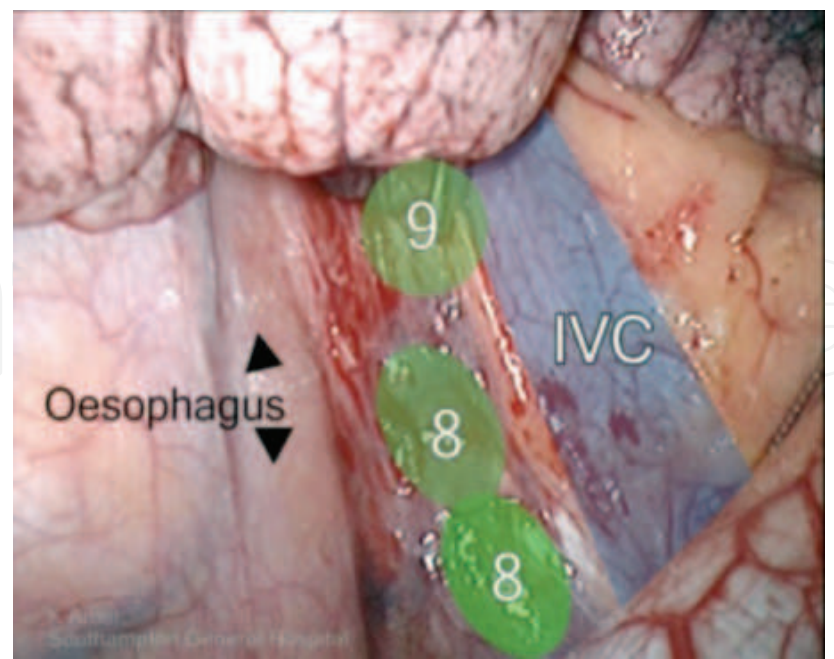


Fig. 7. Schematic location of #8 & #9.

The subcarinal nodes on the right side are found between the right main bronchus and the oesophagus. The lung is retracted anteriorly and the pleural reflection at the back of the hilum is opened from the inferior ligament to the concavity of the Azygos vein, medial to the vagus nerve. All vagal bronchial branches could be cut with impunity [Fig. 8-10].

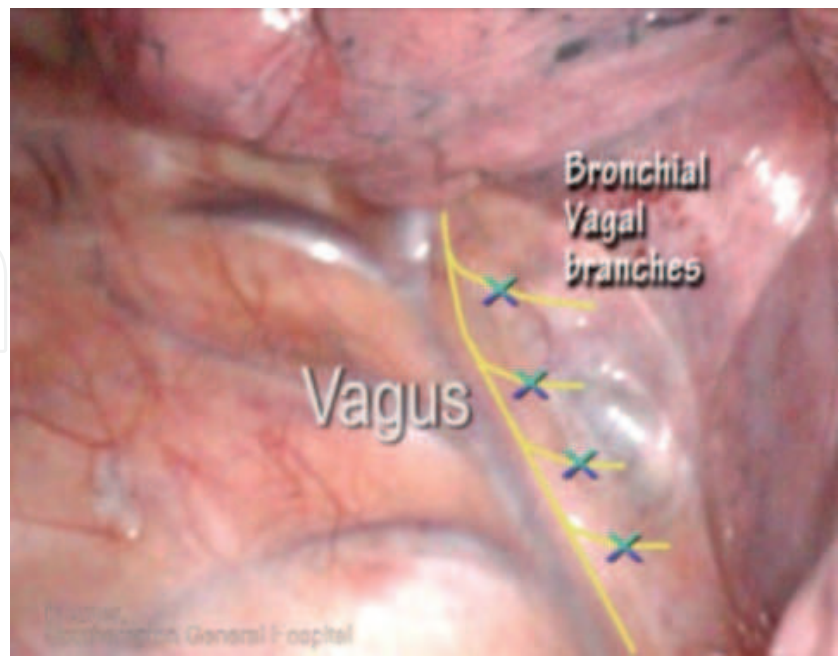


Fig. 8. Vagal bronchial twigs.

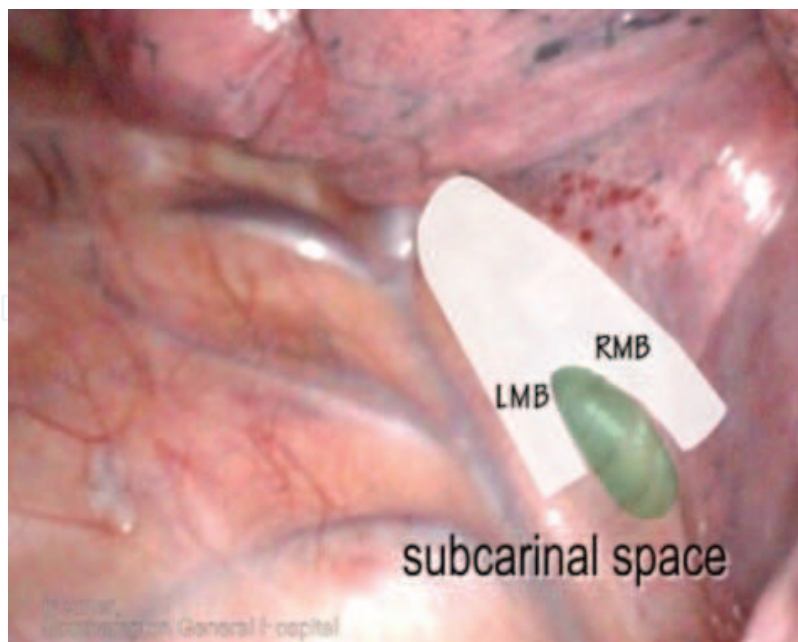


Fig. 9. Schematic location of #7.

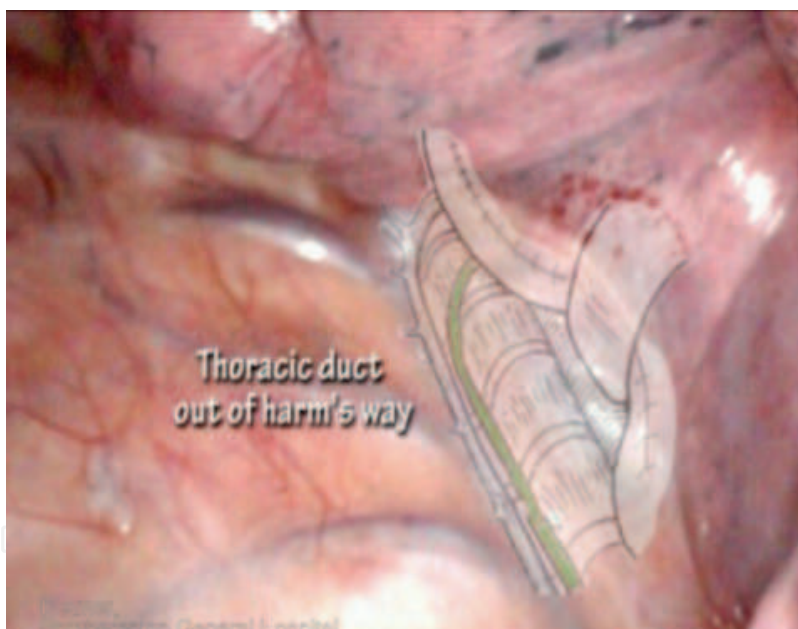

Fig. 10. The thoracic duct surface anatomy.

The right main bronchus is identified and followed proximally until the left main bronchus is seen and identified. The subcarinal nodes are dissected off their blood supply, and for convenience of retrieval a Polythene bag could be used. This is not always necessary. Careful labelling of nodes is to be practiced here as para-oesophageal #8 and para-bronchial #10 nodes could easily be mistaken as #7. Care must be taken not to dig holes in the membranous part of the bronchus or the delicate oesophagus. One should not worry much about thoracic duct injury in this location, as the duct is tucked away from harm's way by the oesophagus [Fig. 10]. At the end of this dissection the right main bronchus, the left main bronchus and the subcarinal space should be well on display [Fig. 11].

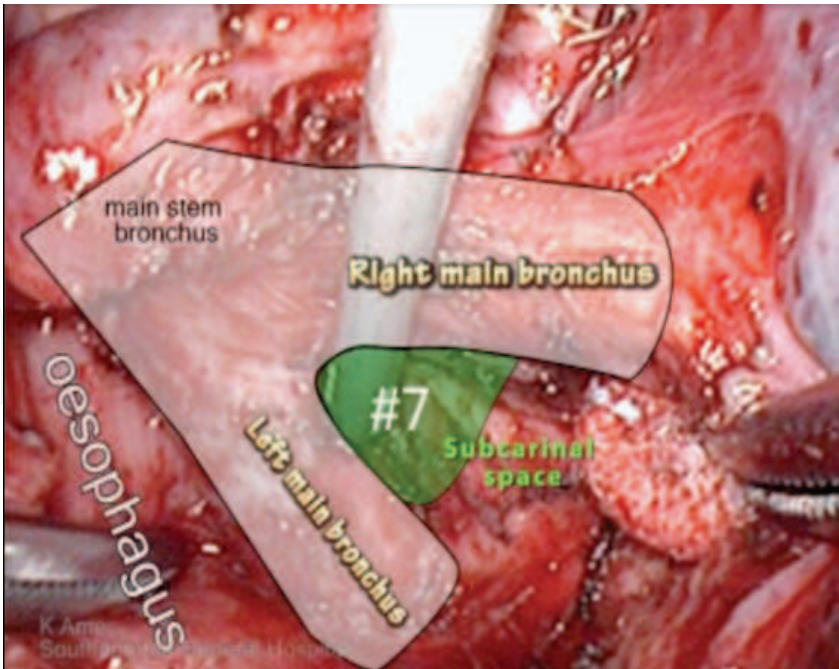


Fig. 11. The right subcarinal space.

Dissection of the parabronchial nodes #2-4 lies within the superior triangle. This triangle is bound by the Vagus and Phrenic nerves, and based on the Azygos vein [Fig. 12].

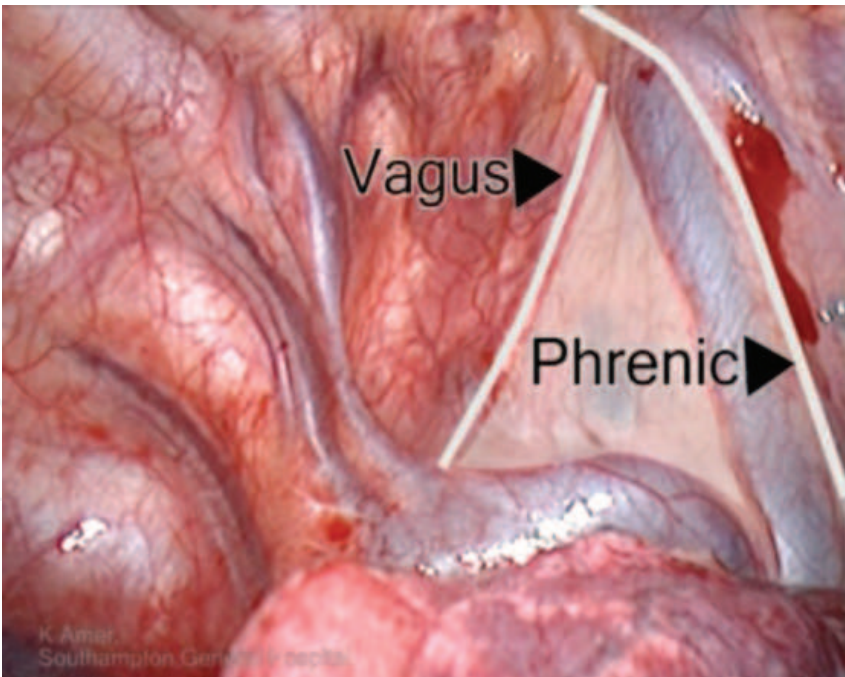


Fig. 12. The right superior triangle.

The pleura is opened like a trap door, just lateral to the SVC and just above the Azygos vein [Fig. 13]. The Vagus nerve could be found plastered to the inside flap of the pleura. Retraction of the pleura using a Prolene stitch opens the triangle and helps in dissection [Fig. 14].

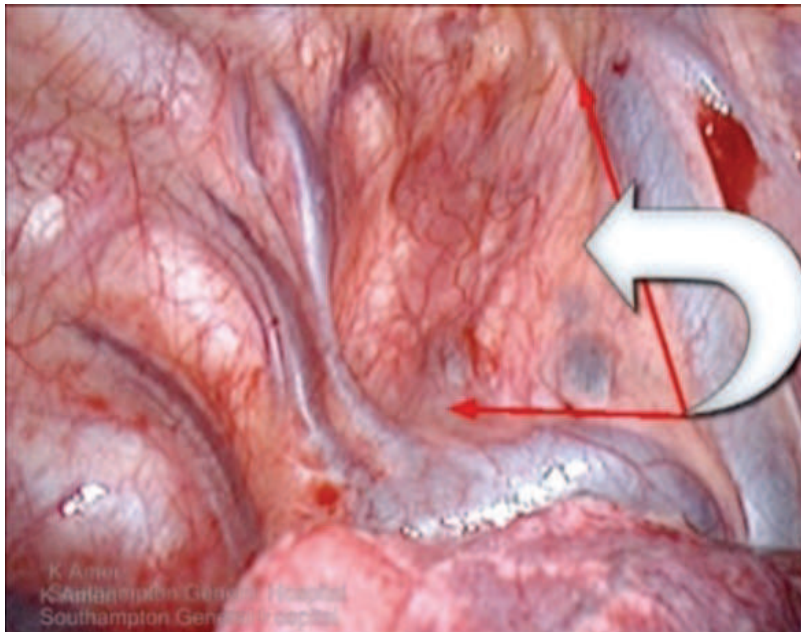


Fig. 13. Trap door to #2-4.

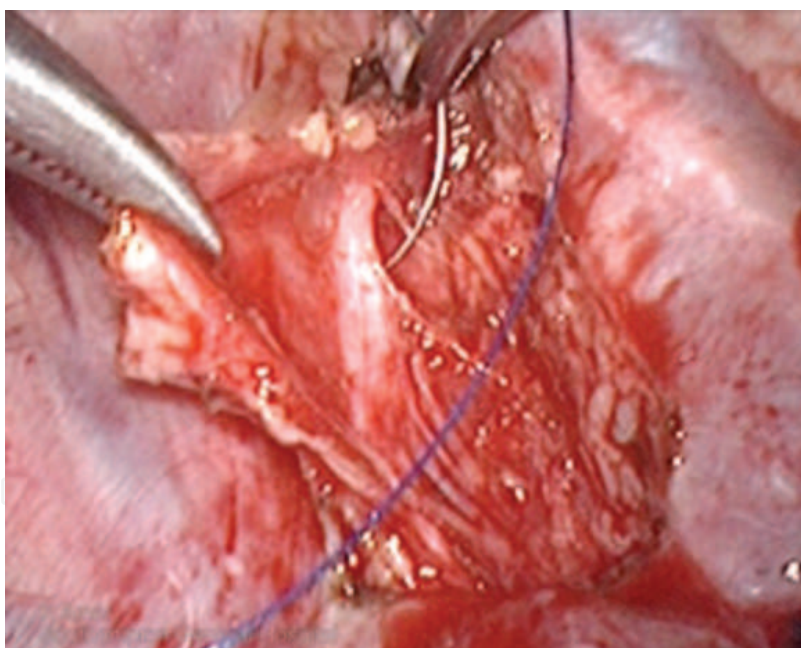


Fig. 14. Retraction of Vagus nerve.

Station #2-4 nodes in the para and pre-tracheal groups exist in a fibro-fatty block that could be dissected en block most of the times. Low energy diathermy is used as before. The dissection is started by pushing the SVC away from the block. One should be aware of the existence of at least one constant vein draining directly from the block to the SVC [Fig. 15]. These veins should be controlled by metal ligaclocks or ultrasonic device before proceeding. If they are accidentally cut they have the propensity to retract and disappear, making control of the bleeding difficult.

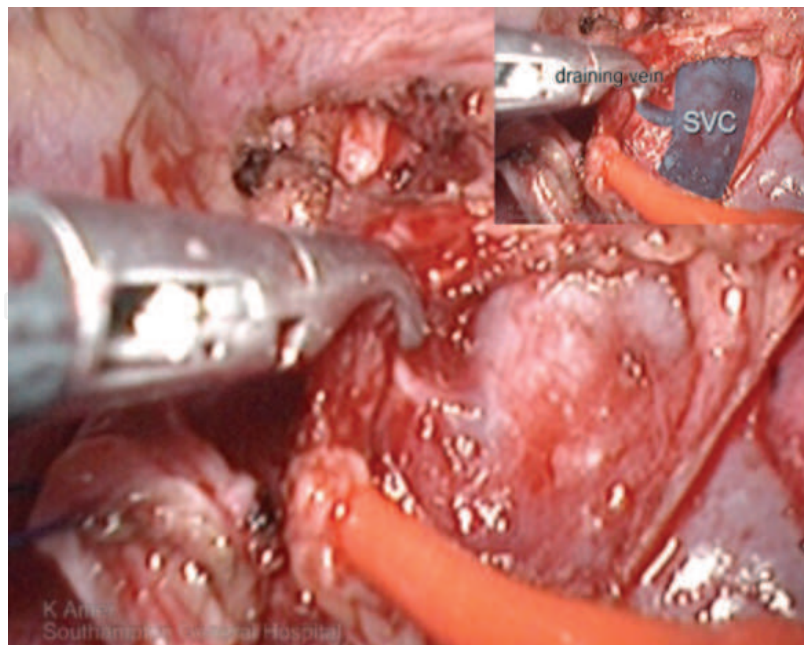


Fig. 15. Direct draining vein from block to SVC.

Further deeper dissection high in the triangle between the SVC and the block identifies the main stem trachea [Fig. 16]. Once the apex of the block is brought down, the dissection becomes easier.

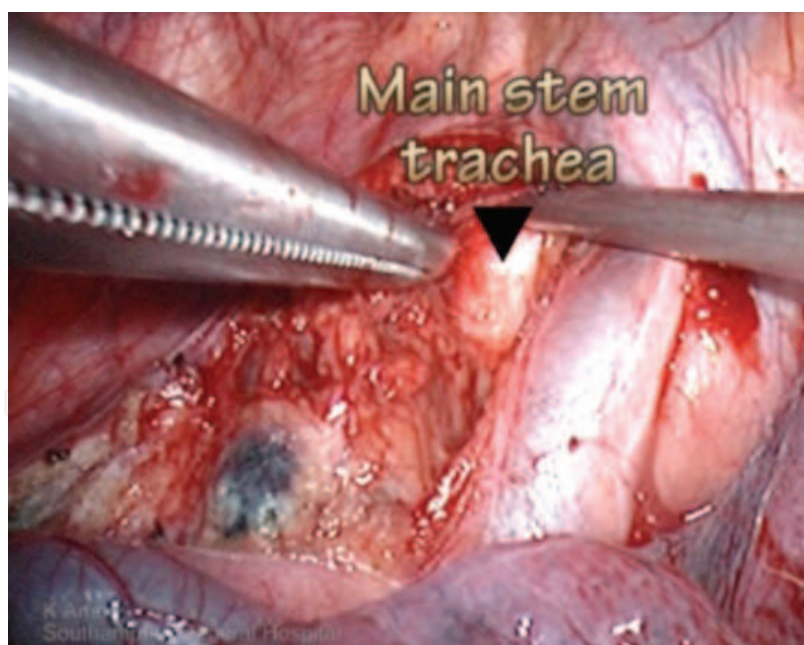


Fig. 16. Identifying the main stem trachea.

Next the lateral part of the block is separated from the vagus nerve. The block is then lifted off the trachea, and the retrocaval part is freed. Large lymphatic channels could be seen here, and differentiated from nerves by their lobular contour and loss of sheen. Again the block is delivered out of the chest in a Polythene bag for convenience of retrieval only [Fig. 17]. Small discrete nodes are retrieved directly on a surgical instrument.

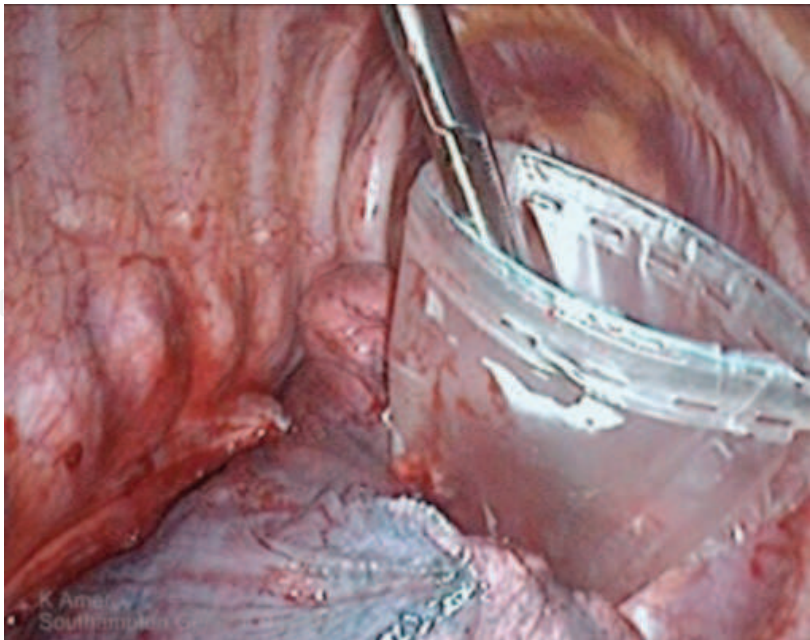


Fig. 17. Retrieval in a Polythene bag of #2-4.

The bed of the superior triangle is made of the arch of the aorta and the right brachiocephalic artery and the main stem trachea [Fig. 18]. The recurrent laryngeal nerve descends into the thoracic inlet parallel to the vagus on the lateral side of the carotid artery. It makes a quick exit out of the chest as it loops around the origin of the right subclavian artery, soon after it enters the thoracic inlet. It continues its course cephalad towards the trachea-oesophageal groove in the neck. This point of looping is approximately 1 cm from the aortic arch, and corresponds to the length of the brachiocephalic trunk [Fig. 18]. It lies at the apex of the superior triangle, and diathermy should be used with extreme caution in this area, especially when the highest #2 nodes are attempted.

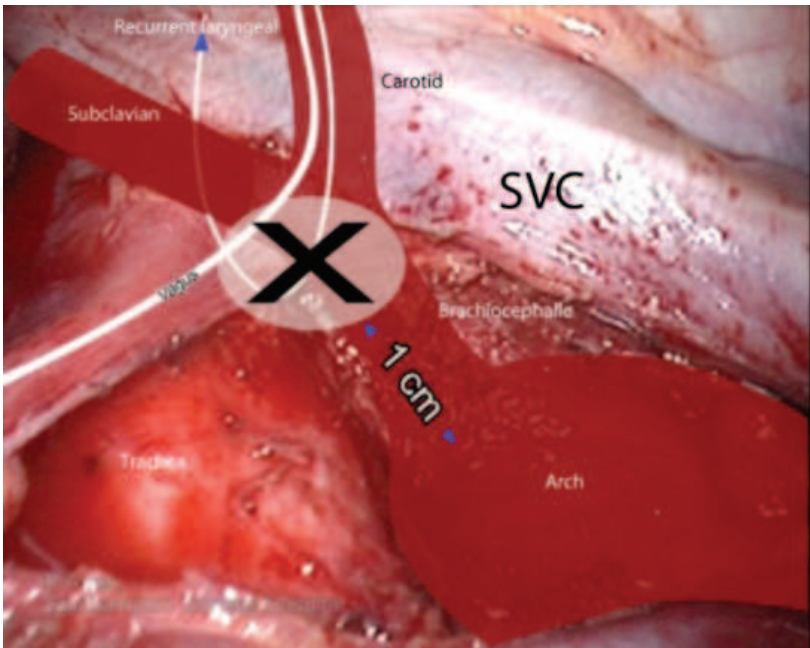


Fig. 18. Location of the right recurrent laryngeal nerve.

Again enthusiasm should be curbed not to cross the median line into the left side, as injury to the thoracic duct could occur. By the end of this dissection the whole length of the trachea should be seen bare of nodes, including a clear retrocaval and retro-azygos spaces [Fig. 19].

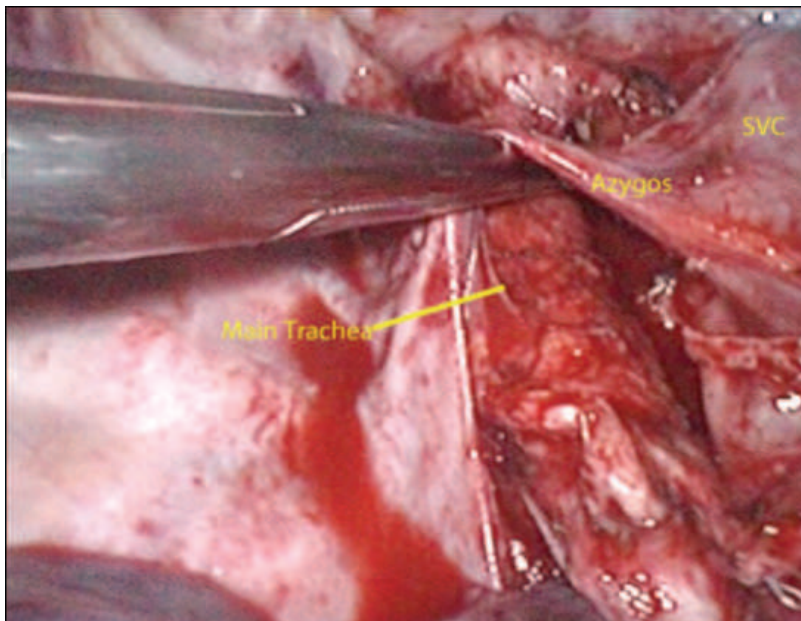


Fig. 19. The view after clearance of #2-4.

Left side:

Dissection is also started here by releasing the inferior pulmonary ligament. This exposes #9 around the inferior vein [Fig. 20]. The pleural reflection between the pericardium and the descending aorta is opened longitudinally from the inferior ligament to the diaphragm. The diaphragm and the pericardium might require retraction using a swab on a stick to expose this area [Fig. 21].

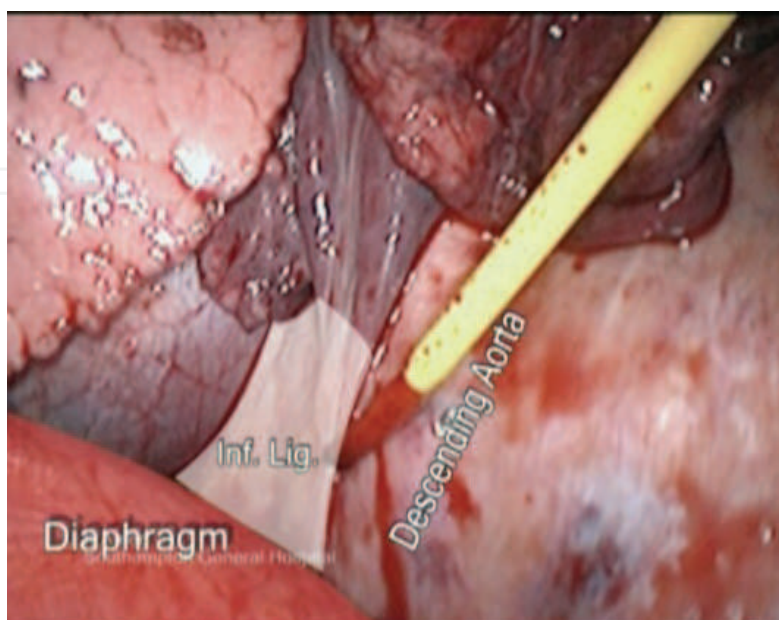


Fig. 20. Exposing left inferior ligament.

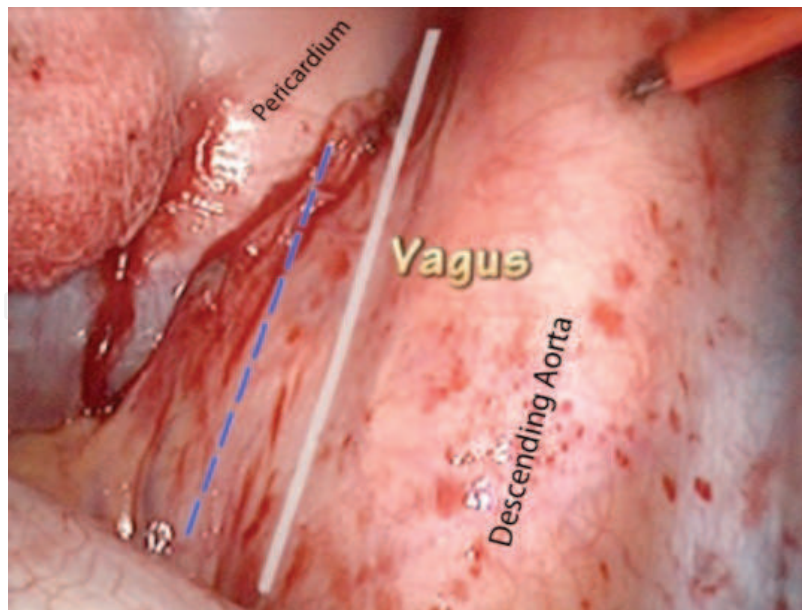


Fig. 21. Pleural landmarks for opening #8 & #9.

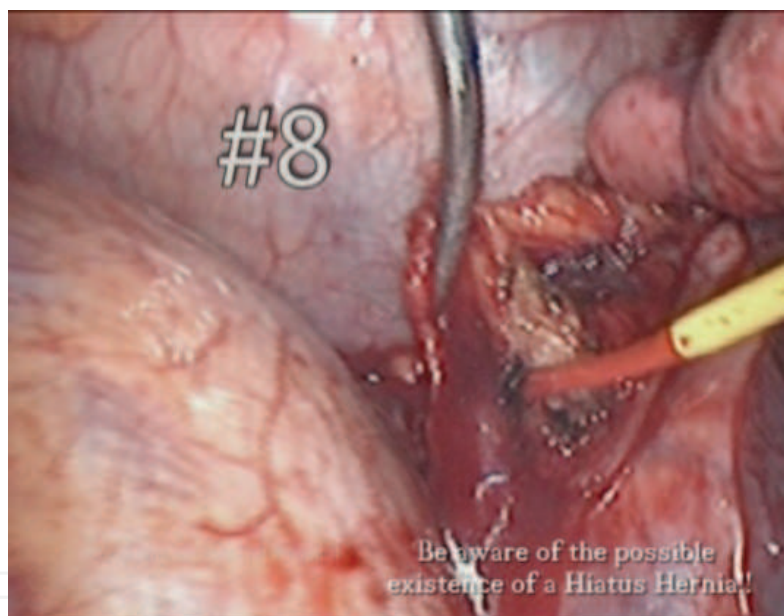


Fig. 22. En-block dissection of left #8.

This exposes #8 nodes which again could be absent, discrete or forming a fibro-fatty block. Care is taken not to injure the vagus, oesophagus, and other organs which are usually not there but could be there, such as a hiatus hernia [Fig. 22].

Dissection of the subcarinal #7 nodes on the left side is time-consuming, and require a prepared plan of action, good suction and detailed mastery of the surrounding anatomy. On retracting the lung anteriorly two nerves and a vein are noted to cross the arch of the aorta. The Phrenic nerve passes anterior to the hilum, whereas the Vagus passes posterior to the hilum. The superior intercostal vein draining the upper 3-4 spaces traverses the upper part of the aorta, crossing the origins of the left subclavian and carotid arteries and drain straight into the innominate vein [Fig. 23].

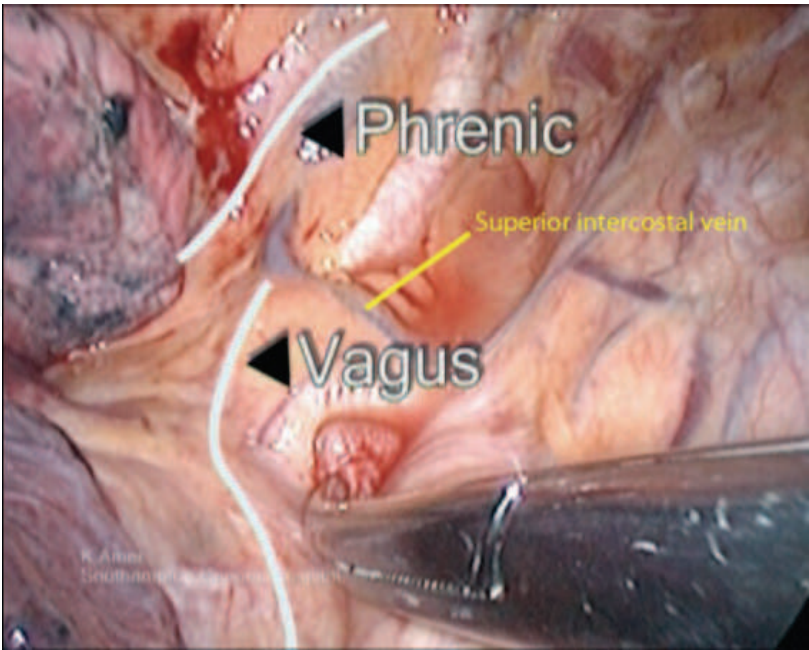


Fig. 23. The hilum watershed between Phrenic and Vagus nerves.

It will be noted that the left recurrent laryngeal nerve descends separate and parallel to the Vagus and hooks around the concavity of the aorta (ligamentum arteriosum) lateral to the vagus. We do not go out of our way to dissect and demonstrate its path, but avoid injury to the recurrent laryngeal by avoiding disturbing the pleura between the arch of aorta and the vagus nerve [Fig. 24]. On the other hand all vagal bronchial branches are cut with impunity [Fig. 25].

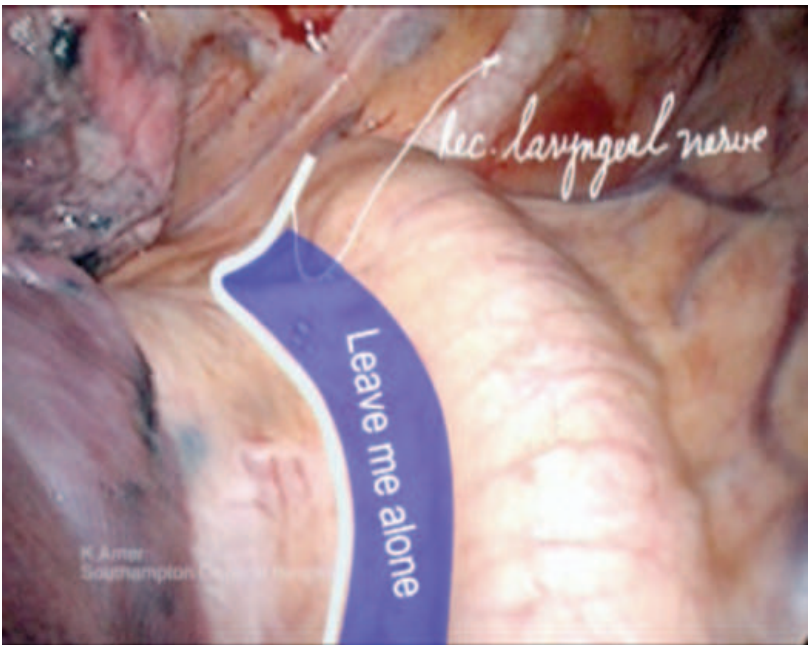


Fig. 24. The no man’s land of the recurrent laryngeal nerve.

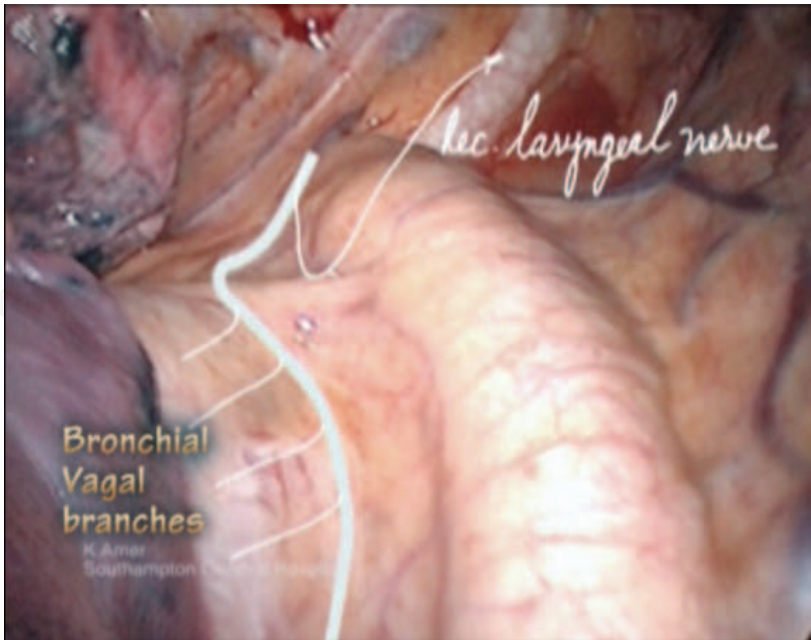


Fig. 25. Left vagal bronchial twigs.

Dissection is started by opening the pleural reflection at the back of the hilum, from the inferior ligament, up to and beyond the aortic arch. Dissection is kept lateral to the vagus, cutting all vagal bronchial branches. One or two bronchial arteries arising directly from the aorta might need to be secured before the space is fully exposed for nodal dissection [Fig. 26].

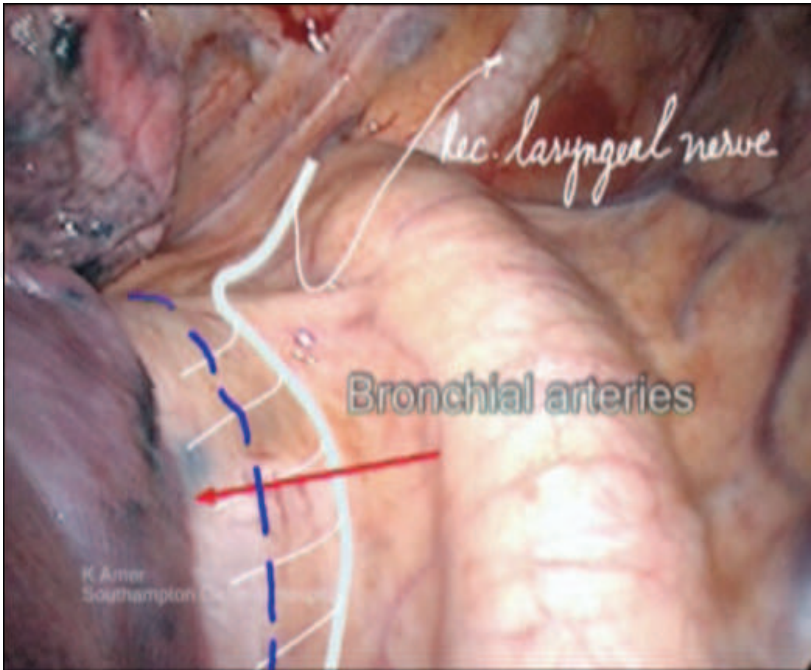


Fig. 26. Vagal bronchial twigs must be cut to access #7.

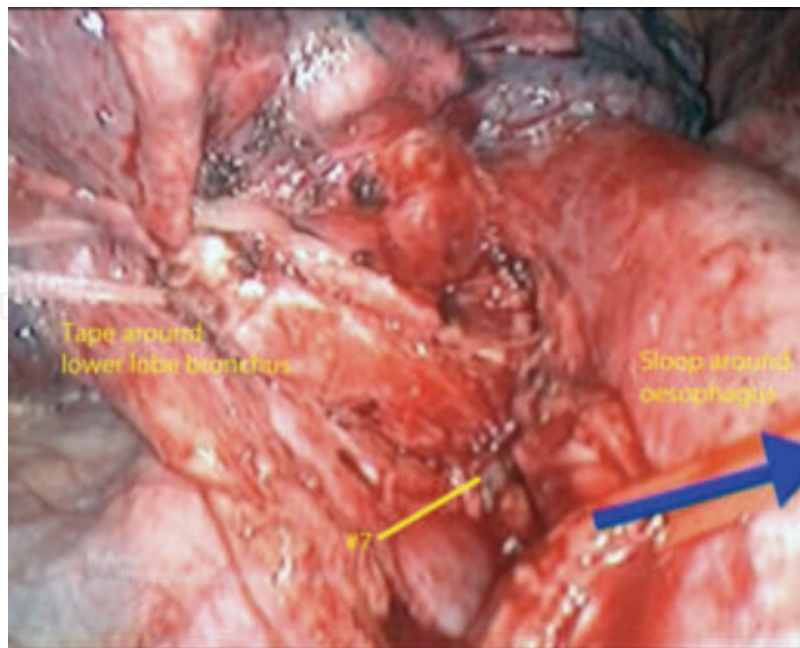


Fig. 27. Exposing the left subcarinal space.

The subcarinal nodes lie in a deep layer, not easily appreciated, deeper than the oesophagus, which is deeper than the aorta. One could make use of strong retraction on the lower lobe bronchus using a tape (has to be sturdy for strong retraction). This will bring the subcarinal space forward into view, and improve vision. A vascular sloop could be used around the oesophagus and *gentle* traction applied to assist in opening the space, but this is not mandatory [Fig. 27].

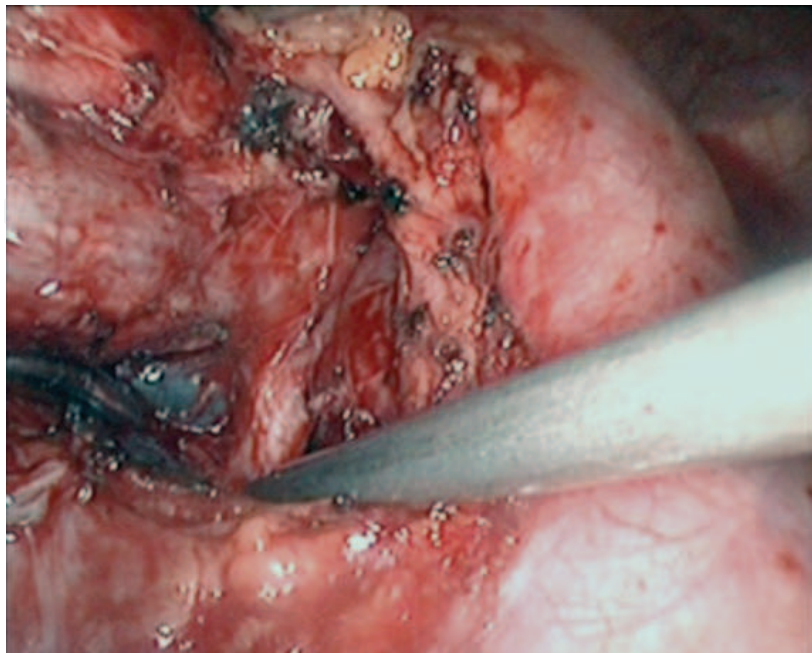


Fig. 28. #7 node.

The principle here is to follow the lower lobe bronchus proximally, as it leads us to the subcarinal space. Pinpoint diathermy dissection of the nodes off their blood supply is performed, taking care not to dig holes in the membranous part of the bronchus. The right main bronchus and the subcarinal space should be well on display by the end of this dissection [Fig. 28-29].

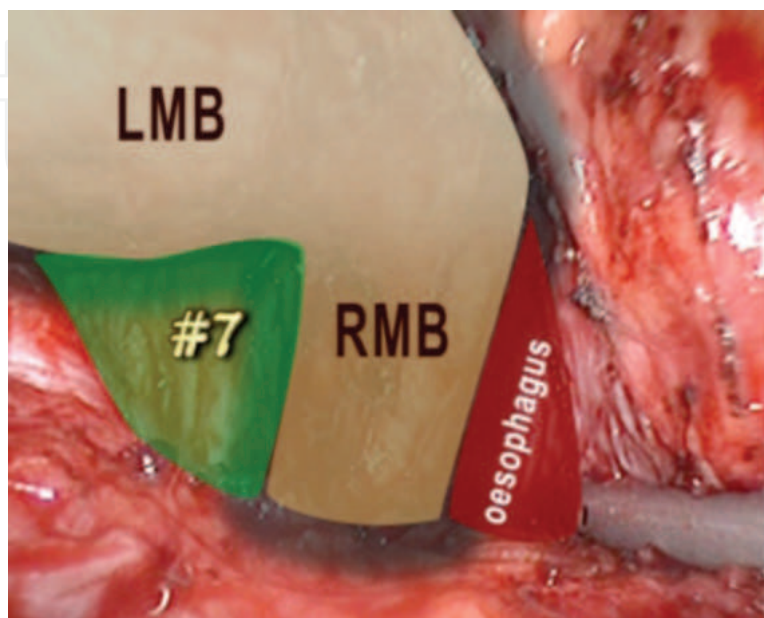


Fig. 29. Anatomy of the subcarinal space.

Nodes that are clearly related to the inferior vein, lower lobe bronchus or the main pulmonary artery are labelled as #10. However; the most lateral of the aorto-pulmonary group are labelled as #4, and these are at a deeper level than #10.

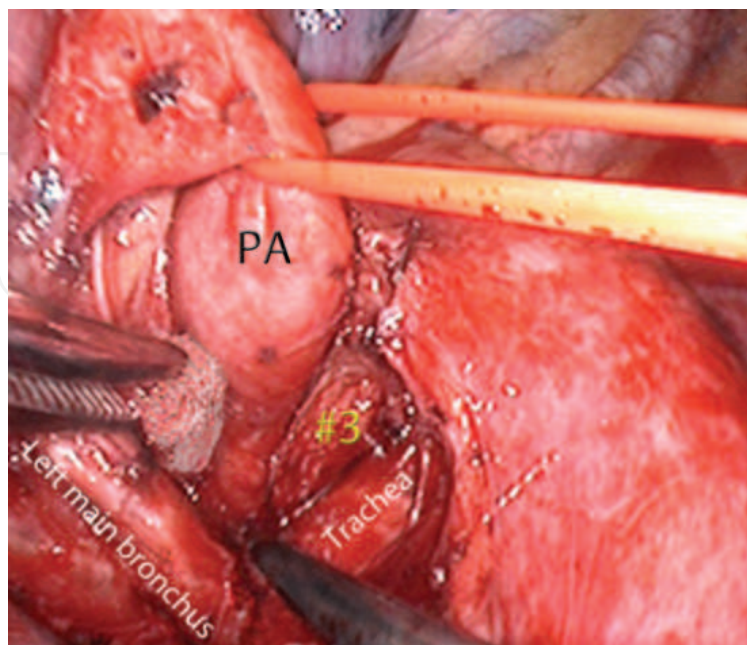


Fig. 30. Exposing pretracheal #3 nodes.

The precarinal #3 nodes could be accessed from the left side if required. The plane of dissection lies below the pulmonary artery, and hence there is no need to dissect and cut the ligamentum arteriosum. The main pulmonary artery is freed from the bronchus and a sloop passed around it. The space under the artery is dissected, and explored by pushing the carina down and the artery up. This manoeuvre exposed the main stem trachea [Fig. 30]. Pretracheal nodes are identified and dissected. Minimal use of diathermy is recommended in this position, as this is the likely position to injure the recurrent laryngeal nerve.

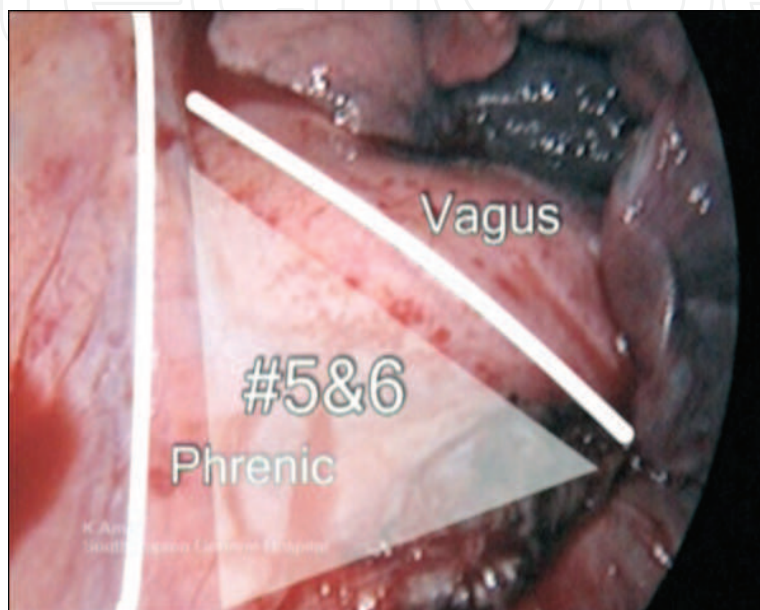


Fig. 31. The left superior triangle.

Dissection of #5 (preaortic) and #6 (sub-aortic and aorto-pulmonary) nodes should be attempted en block. These nodes exist in a triangle similar to the right side, bound by the vagus and Phrenic nerves and the arch of the aorta [Fig. 31]. The fibro-fatty block is lifted off the main pulmonary artery into the aorto-pulmonary space, medial to the vagus nerve. The phrenic nerve is identified and slung using a vascular sloop to avoid harming it. The nodal block is dissected up to the origin of the left subclavian artery, and the block delivered out of the chest.

9. Complications of SND

VATS-SND is safe, and does not add to the morbidity or mortality of the originally planned operation. However there are some complications the surgeon should be aware of:

Major complications:

- Vascular injury; SVC, Aortic arch, Azygos vein etc.
- Bronchial injury; usually the membranous part of major bronchi, especially dissecting around the subcarinal space
- Recurrent laryngeal nerve injury; on the right the danger arises when diathermy is used around the origin of the subclavian artery, and on the left when dissecting #3 (precarinal) at the space between main pulmonary artery and main stem trachea.

- Chyle leak; is rare and usually occurs if dissection involved large lymphatic ducts, mobilisation of oesophagus or in the presence of abnormal anatomical course of the thoracic duct.
- Port-site seedling, which is rare (0.5%) and seems to happen irrespective of whether the nodes were retrieved in a polythene bag or not [32,33].

Minor complications:

- Increased postoperative tube drainage.
- Irritant cough due to diathermy close to the main bronchi.
- Temporary odynophagia (painful swallowing) due to mobilisation of the oesophagus.

10. VATS nodal sampling v dissection

The current evidence suggests that complete mediastinal lymph node dissection is associated with improved survival compared with node sampling in patients with stage I-IIIa NSCLC undergoing resection [34].

11. SND and immune response

It was reported that Systematic lymphadenectomy added to major lung resection performed by open thoracotomy does not increase postoperative humoral immune response in uncomplicated cases [35]. However; there are no studies in the literature that looked into the VMPS-SND and the role of SND in postoperative inflammatory response.

12. Conclusion

VATS Systematic Nodal Dissection during VATS major pulmonary resections is feasible and safe. It should be performed routinely even when nodal involvement is unlikely, as 10% of patients in clinical stage N0-1 will have N2 disease. Multidisciplinary adjuvant treatment of lung cancer should be based on SND staging.

13. References


- [1] Watanabe A, Koyanagi T, Ohsawa H, Mawatari T, Nakashima S, Takahashi N, Sato H, Abe T. Systematic node dissection by VATS is not inferior to that through an open thoracotomy: A comparative clinicopathologic retrospective study. *Surgery* 2005;138:510-517.
- [2] Arriagada R, Bergman B, Dunant A, Le Chevalier T, Pignon JP, Vansteenkiste J; Cisplatin-Based Adjuvant Chemotherapy in Patients with Completely Resected Non-Small-Cell Lung Cancer. *N Engl J Med*. 2004;350:351-60.
- [3] Douillard JY, Rosell R, De Lena M, Carpagnano F, Ramlau R, Gonz  les-Larriba JL, Grodzki T, Pereira JR, Le Groumellec A, Lorusso V, Clary C, Torres AJ, Dahabreh J, Souquet PJ, Astudillo J, Fournel P, Artal-Cortes A, Jassem J, Koubkova L, His P, Riggi M, Hurteloup P. Adjuvant vinorelbine plus cisplatin versus observation in patients with completely resected stage IB-IIIa non-small-cell lung cancer (Adjuvant Navelbine International Trialist Association [ANITA]): a randomised controlled trial. *Lancet Oncol*. 2006;7:719-27.
- [4] Union Internationale Contre le Cancer. TNM classification of malignant tumours, Wiley-Liss, New York (1997) 93-7.

- [5] Goldstraw P, Crowley J, Chansky K, Giroux DJ, Groome PA, Rami-Porta R, Postmus PE, Rusch V, Sobin L. The IASLC Lung Cancer Staging Project: proposals for the revision of the TNM stage groupings in the forthcoming (seventh) edition of the TNM classification of malignant tumours. *J Thorac Oncol* 2007;2:706-714.
- [6] Lardinois D, De Leyn P, Van Schil P, Rami Porta R, Waller D, Passlick B, Zielinski M, Lerut T, Weder W. ESTS guidelines for intraoperative lymph node staging in non-small cell lung cancer. *Eur J Cardiothorac Surg* 2006;30:787-792.
- [7] Asamura H, Nakayama H, Kondo H, Tsuchiya R, Naruke T. Lobe-specific extent of systematic lymph node dissection for non-small cell lung carcinomas according to a retrospective study of metastasis and prognosis. *J Thorac Cardiovasc Surg.* 1999 Jun;117(6):1102-11.
- [8] Misthos P, Sepsas E, Athanassiadi K, Kakaris S, Skottis I. Skip metastases: analysis of their clinical significance and prognosis in the IIIA stage of non-small cell lung cancer *Eur J Cardiothorac Surg* 2004;25:502-508
- [9] Ono T, Minamiya Y, Ito M, Saito H, Motoyama S, Nanjo H, Ogawa J. Sentinel node mapping and micrometastasis in patients with clinical stage IA non-small cell lung cancer. *Interact Cardiovasc Thorac Surg.* 2009 Oct;9(4):659-61.
- [10] Riethdorf S, Wikman H, Pantel K. Review: Biological relevance of disseminated tumor cells in cancer patients. *Int J Cancer.* 2008 Nov 1;123(9):1991-2006
- [11] Witte B, Hürtgen M. Video-assisted mediastinoscopic lymphadenectomy (VAMLA). *J Thorac Oncol.* 2007 Apr;2(4):367-9.
- [12] Witte B, Messerschmidt A, Hillebrand H, Gross S, Wolf M, Kriegel E, Neumeister W, Hürtgen M. Combined videothoracoscopic and videomediastinoscopic approach improves radicality of minimally invasive mediastinal lymphadenectomy for early stage lung carcinoma. *Eur J Cardiothorac Surg.* 2009 Feb;35(2):343-7. Epub 2008 Dec 16.
- [13] Zieliński M. Technical pitfalls of transcervical extended mediastinal lymphadenectomy-how to avoid them and to manage intraoperative complications. *Semin Thorac Cardiovasc Surg.* 2010 Autumn;22(3):236-43.
- [14] Van Tinteren H, Hoekstra OS, Smit EF, van den Bergh JH, Schreurs AJ, Stallaert RA, van Velthoven PC, Comans EF, Diepenhorst FW, Verboom P, van Mourik JC, Postmus PE, Boers M, Teule GJ. Effectiveness of PET in the preoperative assessment of patients with suspected non-small cell lung cancer: The PLUS multicenter randomised trial. *Lancet* 2002;359:1388-92.
- [15] Gillies RJ, Robey I, Gatenby RA. Causes and consequences of increased glucose metabolism of cancers. *J Nucl Med.* 2008;49:24S-42S.
- [16] Plathow C, Weber WA. Tumor cell metabolism imaging. *J Nucl Med.* 2008;49:43S-63S.
- [17] Al-Sarraf N, Gately K, Lucey J, Wilson L, McGovern E, Young V. Lymph node staging by means of positron emission tomography is less accurate in non-small cell lung cancer patients with enlarged lymph nodes: Analysis of 1145 lymph nodes. *Lung Cancer* 2008;60:62-68
- [18] Delphine L. Chen and Farrokh Dehdashti. Advances in Positron Emission Tomographic Imaging of Lung Cancer. *J Thorac Cardiovasc Surg.* 2004;127:1093-9.
- [19] Eric Lim, David Baldwin, Michael Beckles, John Duffy, James Entwisle, Corinne Faivre-Finn, Keith Kerr, Alistair Macfie, Jim McGuigan, Simon Padley, Sanjay Popat, Nicholas Screatton, Michael Snee, David Waller, Chris Warburton, Thida Win.

- Guidelines on the radical management of patients with lung cancer. *Thorax* 2010;65:iii1-iii27
- [20] Albain KS, Swann RS, Rusch VW, Turrisi AT 3rd, Shepherd FA, Smith C, Chen Y, Livingston RB, Feins RH, Gandara DR, Fry WA, Darling G, Johnson DH, Green MR, Miller RC, Ley J, Sause WT, Cox JD. Radiotherapy plus chemotherapy with or without surgical resection for stage III non-small-cell lung cancer: a phase III randomised controlled trial. *Lancet* 2009;374:379-386
- [21] Pisters KM, Vallières E, Crowley JJ, Franklin WA, Bunn PA Jr, Ginsberg RJ, Putnam JB Jr, Chansky K, Gandara D. Surgery with or without preoperative paclitaxel and carboplatin in early-stage non-small-cell lung cancer: Southwest Oncology Group Trial S9900, an intergroup, randomized, phase III trial. *J Clin Oncol.* 2010;28:1843-9.
- [22] Rocco G, Perrone F, Rossi A, Gridelli C. Surgical management of non-small cell lung cancer with mediastinal lymphadenopathy. *Clinical Oncology* 2010;22:325-333
- [23] Lim E, Harris G, Patel A, Adachi I, Edmonds L, Song F. Preoperative versus postoperative chemotherapy in patients with resectable non-small cell lung cancer: systematic review and indirect comparison meta-analysis of randomized trials. *J Thorac Oncol.* 2009;4:1380-8
- [24] Meyers BF, Haddad F, Siegel BA, Zoole JB, Battafarano RJ, Veeramachaneni N, Cooper JD and Patterson GA. Cost effectiveness of routine mediastinoscopy in CT and PET-screened patients with stage I lung cancer. *J Thorac Cardiovasc Surg* 2006;131:822-829.
- [25] Watanabe S, Ladas G, Goldstraw P. Inter-observer variability in systematic nodal dissection: comparison of European and Japanese nodal designation. *Ann Thorac Surg.* 2002 Jan;73(1):245-8
- [26] Naruke T, Tsuchiya R, Kondo H, Nakayama Haruhiko, Asamura H. Lymph node sampling in lung cancer: how should it be done? *Eur J Cardiothorac Surg* 1999;16:17-24.
- [27] Rusch VW, Asamura H, Watanabe H, Giroux DJ, Rami-Porta R, Goldstraw P; Members of IASLC Staging Committee. The IASLC lung cancer staging project: a proposal for a new international lymph node map in the forthcoming seventh edition of the TNM classification for lung cancer. *J Thorac Oncol.* 2009 May;4(5):568-77.
- [28] Darling GE, Allen MS, Decker PA, Ballman K, Malthaner RA, Inculet RI, Jones DR, McKenna RJ, Landreneau RJ, Putnam JB Jr. Number of Lymph Nodes Harvested from a Mediastinal Lymphadenectomy: Results of the Randomized, Prospective ACOSOG Z0030 Trial. *Chest.* 2010 Sep 9. [Epub ahead of print]
- [29] Gossot, D (2010). *Atlas of endoscopic Major Pulmonary Resections*. Paris: Springer-Verlag. 22-32.
- [30] Sagawa M, Sato M, Sakurada A, Matsumura Y, Endo C, Handa M, Kondo T. A prospective trial of systematic nodal dissection for lung cancer by video-assisted thoracic surgery: can it be perfect? *Ann Thorac Surg* 2002;73:900-4.
- [31] Watanabe A, Koyanagi T, Obama T, Ohsawa H, Mawatari T, Takahashi N, Ichimiya Y. Assessment of node dissection for clinical stage I primary lung cancer by VATS. *Eur J Cardiothorac Surg.* 2005;27:745-752.
- [32] Amer K, Khan AZ, Singh N, Addis B, Jogai S, Harden S, Peebles C, Brown I. Video-assisted thoracic surgery systematic mediastinal nodal dissection and stage migration: impact on clinical pathway. *Eur J Cardiothorac Surg.* 2011 Apr 13.

- [33] McKenna RJ, Houck W, Fuller CB. Video-assisted thoracic surgery lobectomy: experience with 1,100 cases. *Ann Thorac Surg.* 2006;81(2):421-5.
- [34] Scott WJ, Allen MS, Darling G, Meyers B, Decker PA, Putnam JB, McKenna RW, Landrenau RJ, Jones DR, Inculet RI, Malthaner RA. Video-assisted thoracic surgery versus open lobectomy for lung cancer: a secondary analysis of data from the American College of Surgeons Oncology Group Z0030 randomized clinical trial. *J Thorac Cardiovasc Surg.* 2010 Apr;139(4):976-81
- [35] Szczesny TJ, Słotwiński R, Szczygiel B, Stankiewicz A, Zaleska M, Kopacz M, Olesińska-Grodź A. Systematic mediastinal lymphadenectomy does not increase postoperative immune response after major lung resections. *Eur J Cardiothorac Surg.* 2007 Dec;32(6):868-72. Epub 2007 Oct 17.

IntechOpen



Topics in Thoracic Surgery

Edited by Prof. Paulo Cardoso

ISBN 978-953-51-0010-2

Hard cover, 486 pages

Publisher InTech

Published online 15, February, 2012

Published in print edition February, 2012

Thoracic Surgery congregates topics and articles from many renowned authors around the world covering several different topics. Unlike the usual textbooks, Thoracic Surgery is a conglomerate of different topics from Pre-operative Assessment, to Pulmonary Resection for Lung Cancer, chest wall procedures, lung cancer topics featuring aspects of VATS major pulmonary resections along with traditional topics such as Pancoast tumors and recurrence patterns of stage I lung disease, hyperhidrosis, bronchiectasis, lung transplantation and much more. This Open Access format is a novel method of sharing thoracic surgical information provided by authors worldwide and it is made accessible to everyone in an expedite way and with an excellent publishing quality.

How to reference

In order to correctly reference this scholarly work, feel free to copy and paste the following:

Khalid Amer (2012). Video-Assisted Thoracic Surgery (VATS) Systematic Mediastinal Nodal Dissection, Topics in Thoracic Surgery, Prof. Paulo Cardoso (Ed.), ISBN: 978-953-51-0010-2, InTech, Available from: <http://www.intechopen.com/books/topics-in-thoracic-surgery/video-assisted-thoracic-surgery-vats-systematic-mediastinal-nodal-dissection>

INTech
open science | open minds

InTech Europe

University Campus STeP Ri
Slavka Krautzeka 83/A
51000 Rijeka, Croatia
Phone: +385 (51) 770 447
Fax: +385 (51) 686 166
www.intechopen.com

InTech China

Unit 405, Office Block, Hotel Equatorial Shanghai
No.65, Yan An Road (West), Shanghai, 200040, China
中国上海市延安西路65号上海国际贵都大饭店办公楼405单元
Phone: +86-21-62489820
Fax: +86-21-62489821

© 2012 The Author(s). Licensee IntechOpen. This is an open access article distributed under the terms of the [Creative Commons Attribution 3.0 License](#), which permits unrestricted use, distribution, and reproduction in any medium, provided the original work is properly cited.

IntechOpen

IntechOpen