

# We are IntechOpen, the world's leading publisher of Open Access books Built by scientists, for scientists

6,900

Open access books available

186,000

International authors and editors

200M

Downloads

Our authors are among the

154

Countries delivered to

TOP 1%

most cited scientists

12.2%

Contributors from top 500 universities



WEB OF SCIENCE™

Selection of our books indexed in the Book Citation Index  
in Web of Science™ Core Collection (BKCI)

Interested in publishing with us?  
Contact [book.department@intechopen.com](mailto:book.department@intechopen.com)

Numbers displayed above are based on latest data collected.  
For more information visit [www.intechopen.com](http://www.intechopen.com)



## Ear-Related Issues in Patients with Nasopharyngeal Carcinoma

Wong-Kein Christopher Low and Mahalakshmi Rangabashyam  
*Department of Otolaryngology, Singapore General Hospital  
 Singapore*

### 1. Introduction

Nasopharyngeal carcinoma (NPC) is the sixth most common cancer in Singapore amongst males. Each year, there are 300-400 new cases diagnosed (Singapore cancer registry 2005-2009). NPC is endemic in Southeast Asia, North Africa, and parts of the Mediterranean basin, with the highest prevalence in Southern China where an average of 80 cases per 100,000 populations is reported each year (Loong et al., 2008).

The nasopharynx is at a point where the ear, nose and upper pharynx converge. NPC is relevant to the Otolologist although the nasopharynx is located outside the precincts of the anatomical confines of the ear, since it frequently manifests itself in the form of ear-related symptoms. The ear deserves special attention not only during diagnosis, but also in treatment and follow-up of patients with NPC. NPC is extremely radiosensitive and potentially curable provided the diagnosis is made early. As ear structures are often included in the radiation fields, ear-related complications of radiotherapy are common as well.

Early diagnosis is important as it has better treatment outcomes. Patients with early stages of the disease may present with ear-related complaints. In advanced disease, adjuvant chemotherapy may become necessary. Chemotherapy usually involves using Cisplatin (CDDP), which is potentially ototoxic. It is of concern that only 10% of patients are diagnosed early at stage I (van Hasselt and Woo, 2008). According to Leong et al.(1999), patient factors identified which contributed to delayed diagnosis included deferment in seeking medical help, defaulting follow up visits and refusing investigations. Other factors contributing to further delay in diagnosis were Clinicians not considering a diagnosis of NPC and Clinicians suspecting NPC but misled by the results of investigations. These factors contributed to nearly a fifth of patients with NPC having delayed diagnosis. Many of the factors responsible for the delays appear to be preventable by better patient education and counseling, doctors having sharper clinical acumen and skills in NPC diagnosis and the hospital administration having a system of tracking down high risk patients who default. Therefore, Clinicians should be familiar with the ear-related manifestations of NPC, which may help in its early diagnosis

This review aims to highlight ear-related issues in NPC patients from 2 perspectives: 1) as a manifestation of the disease itself and 2) ear-related complications arising from treatment of

NPC namely, radiotherapy with and without chemotherapy. There is a relative paucity of world literature focusing on the impact of NPC on the Otologist. A major part of this review is from the principal author's previous work spanning 2 decades and review of other relevant literature.

## 2. Otological manifestations of NPC

Middle ear effusion resulting from NPC is a well-known presenting feature. However, there are other less common otological presentations including otalgia, giddiness, heamotympanum, barotrauma and periauricular mass which one should be mindful of (Low and Goh 1999).

### 2.1 Middle ear involvement

The link between the middle ear and nasopharynx by the Eustachian tube is one of the important reasons why the middle ear is frequently involved in patients with NPC.

A small tumor in the Fossa of Rosenmüller of the nasopharynx does not necessarily impair the Eustachian tubal function, but involvement of the Fossa by NPC seems necessary for Eustachian tube dysfunction to occur (Su et al., 1993). Tumour may spread outward via the mucosa and submucosa, or along the muscle bundles within the fibro-fatty tissue planes that surround the muscles or along the neuro-vascular planes (Miura et al., 1990).

#### 2.1.1 Middle ear effusion

Middle ear effusion (MEE) is a common otological manifestation of NPC and may be the only presenting symptom of the disease. The resulting conductive hearing loss is usually unilateral and is due to the tumour causing Eustachian tube dysfunction.

Sham et al. (1992) evaluated the relationship between the paranasopharyngeal extension of tumor and the presence of MEE using CT scans (1992). The Eustachian tube traverses the paranasopharyngeal space and the presence of tumor in this region was likely to have an impact on tubal function, either mechanical or functional. The degree of paranasopharyngeal extension of tumor, erosion of petrous temporal bone and the obliteration of pharyngeal recess were found to be significantly related to the development of MEE, but not sex and age. Erosion of the petrous temporal bone was not as strong a risk factor for MEE as paranasopharyngeal involvement. The functional derangement of the cartilaginous part of the Eustachian tube was more important than its bony part in the development of MEE.

Despite numerous studies, uncertainty exists with regards to the exact patho-physiological process culminating in MEE. Although Eustachian tube dysfunction can be caused by inflammation within the lumen and invasion of the tubal orifice, there is mounting evidence pointing towards functional pathology rather than true mechanical obstruction of the tubal lumen (Bluestone 1983; Choa, 1981). More recent studies showed that in patients with NPC-associated MEE; the Eustachian tube was actually patent (Young & Hsieh, 1992). This led to the evolution of various theories to explain the observed functional rather than mechanical obstruction.

### 2.1.1.1 Muscle infiltration theory

Sadé (1994) argued that MEE in NPC was usually the consequence of faulty middle ear aeration, due to the inability to introduce air through the Eustachian tube. This was because of its muscles being affected and not because of its opening in the nasopharynx being blocked by a tumor. He observed that in animal studies, MEE could be produced experimentally by damaging the tensor veli palatini muscles in monkeys (Casselbrandt *et al.*, 1988 as cited in Sadé 1994). In post-mortem studies, histological examination of the Eustachian tube in patients with NPC revealed that while sometimes the tumour infiltrated the Eustachian tube submucosa and cause obstruction (Cundy *et al.*, 1973 as cited in Sadé 1994); it usually infiltrated the Eustachian tube muscles and did not involve the Eustachian tube opening or its lumen at all (Cundy *et al.*, 1973; Takahara *et al.*, 1986 as cited in Sadé 1994). In various clinical studies, (Honjo, 1988 as cited in Sadé 1994; Sham *et al.*, 1992) demonstrated a direct relationship between the frequency of MEE in NPC and the extent of its infiltration to the parapharyngeal region where the Eustachian tube muscles were probably infiltrated. Myers *et al.*, (1984) also pointed to the presence of MEE in cases of other head or neck tumours such as maxillary sinus carcinoma and its surgery. They showed that in these cases, damage to the Eustachian tube muscles rather than obstruction of the Eustachian opening or lumen led to the effusion.

### 2.1.1.2 Neurogenic theory

Su *et al.*, (1993) conducted an electromyogenic (EMG) study of the tensor veli palatini (TVP) and levator veli palatini (LVP) muscles in NPC patients. An abnormal TVP wave pattern coincided with a symptomatic ear whereas the non-symptomatic ear had a normal wave pattern. A paralyzed LVP with intact TVP did not result in effusion. NPC invasion generally did not demonstrate a myopathic EMG finding in both muscles. This led to the conclusion that neurogenic paralysis of TVP muscle on the lesion side played an important role in the pathogenesis of functional obstruction of the Eustachian tube leading to MEE. The tough pharyngobasilar fascia not only separated the TVP and LP, but also kept the tensor lateral to it. Anatomically the nerve to TVP was placed in a more vulnerable position and hence, a neurogenic cause of TVP paralysis was more likely (Su *et al.*, 1993; Miura *et al.* 1990).

### 2.1.1.3 Cartilage erosion theory

Low *et al.* (1997) found in a MRI study that NPC patients who had associated MEE had a tendency for the Eustachian tube cartilage to be eroded by tumour. Based on these findings and other observations relating to MEE, the authors postulated that the effect of tumour on Eustachian tube cartilage played an important role in the genesis of MEE in NPC.

The authors argued that MEE could not be explained by simple mechanical obstruction of the Eustachian tube alone. The 'hydrops-ex-vacuo' theory of MEE based on the concept that continuous gaseous absorption occurs in a closed biological air pocket until very high negative pressures capable of inducing MEEs develop, had largely been discredited (Grontved *et al.*, 1990). More recent studies had shown that in an unventilated middle-ear cavity, bidirectional gaseous exchange took place between the middle ear and the circulatory system of the local tissues until an equilibrium was reached, resulting in middle-ear pressures which were only slightly negative or even positive (Hergils and Magnuson, 1990; Sadé and Luntz, 1991). It had been postulated that pressure-regulatory mechanisms in

the middle ear, prevent the formation of excessively high negative middle-ear pressure from gaseous absorption through the middle-ear mucosa (Grontved *et al.*, 1990). This had been supported by animal studies where the prevention of middle ear ventilation by ligating the Eustachian tube led to maximum middle-ear pressures of only 116 mm water (Proud *et al.*, 1971). In humans, it had been observed that inadequate middle ear ventilation from organic obstruction by antro-choanal polyps and some other nasopharyngeal tumors seldom led to MEE formation (Sadé, 1994).

However, for many years, the compliance of the Eustachian tube had been thought to be a factor causing MEE in children (Bluestone, 1985). More recently, the MEE's associated with cleft palate and Down's syndrome was believed to be the result of poorly developed Eustachian cartilages with abnormal compliances (Shibahara and Sando, 1989).

It is therefore reasonable to postulate that abnormal compliance of the Eustachian tube could also result from tumor erosion of the cartilaginous part of the tube and this may also play a role in the pathogenesis of NPC-associated MEE. Low et al. (1997) suggested that when tumour has affected the lamina and the hinge portion of the cartilage, it could lead to a change of tubal compliance, resulting in MEE formation.

### 2.1.2 Ear blockage and negative middle ear pressures

NPC-induced Eustachian tube dysfunction could present as a sensation of ear blockage. Low and Goh (1999) illustrated this with a case study:

A 50-year-old Chinese man presented with the complaint of a sensation of blockage in his left ear lasting for two weeks. He had no preceding upper respiratory tract infection. Examination of the ears was normal. Examination of his nasopharynx with the flexible nasal-endoscope was unremarkable. Epstein-Barr viral serology (as an NPC screen) was positive for both viral capsid and early antigens. Random nasopharyngeal biopsies revealed undifferentiated carcinoma on the left side. Magnetic resonance scan showed a small T 1 submucosal lesion on the left side of the nasopharynx

Ear blockage is the result of negative middle ear pressures (MEPs) without actually developing MEE. Low (1995) carried out a prospective study to investigate MEPs in patients with NPC. Newly diagnosed patients with NPC were studied before and at three to 12 months (mean 7.5 months) after radiotherapy. MEPs were measured by tympanometry. The mean MEP before and after radiotherapy was -55.2 mm water (range -250 to 45 mm water) and -73.1 mm water (range -215 to 35 mm water) respectively. About two-thirds of assessable ears had an increase in negative MEPs after irradiation and the rest had less negative MEPs after irradiation. Those ears that developed post-irradiation middle ear effusions were found to have pre-irradiation negative middle ear pressures of at least -45 mm water. It was concluded that tympanometry before radiotherapy may prove to be useful in identifying ears with a high risk of developing post-irradiation MEE.

### 2.1.3 Barotrauma

Sub-clinical Eustachian tube dysfunction caused by NPC might present clinically as barotrauma. Low & Goh (1999) illustrated this in a case report of a 40-year-old Chinese female complaining of right earache and blockage after descending from an air-flight. She



did not have history of rhinitis prior to nor during the flight. She was diagnosed by her general practitioner to have sustained barotrauma and was treated medically with partial improvement of symptoms. The blockage in her right ear however, deteriorated a month later and was diagnosed by an Otolaryngologist as due to middle-ear effusion. Post-nasal space examination revealed a tumor on the right side, which was histologically proven to be NPC.

#### **2.1.4 Tumor invading the middle ear**

NPC may spread and occupy the middle ear space. It has been proposed that the routes of spread of NPC to the middle ear are via the eustachian tube, direct invasion from the parapharyngeal space and spread from the cavernous sinus through the carotid canal and into the middle ear (Low, 2002).

The incidence of middle ear invasion of NPC is probably higher than what has been reported, considering the anatomic communication and close proximity. Diagnosis may not necessarily be straightforward. Low (2002) reported a case where middle ear invasion by nasopharyngeal carcinoma was misdiagnosed as simple post-radiotherapy middle ear effusion for which myringotomy and ventilation tube insertion were performed. In a patient who had been previously irradiated, a recurrent tumour in the ear can be confused with other related conditions such as osteo-radionecrosis (Figure 1).

#### **2.2 Cerebello-pontine angle involvement**

In the work-up of a space occupying lesion cerebello-pontine angle (CPA), metastatic NPC is normally not considered. Although it is a rare complication, NPC should be kept in mind in a population where NPC is endemic (Yuh et al., 1993). It was observed in a study that when NPC involved the cerebello-pontine, it occurred in patients with advanced or recurrent disease (Low et al., 2000).

Involvement of the CPA can present a varied clinical picture. NPC manifesting as sensorineural hearing loss is rare (Bergstrom et al., 1977). It can be the result of the tumor affecting the cochlear nerve but it seldom affects the cochlea because of the tough otic capsule (Pringle et al., 1993). Although the resulting hearing loss is usually insidious in nature, it may occasionally present as sudden hearing loss (Low and Goh, 1999; Young, 2001). NPC involving the CPA can also affect the vestibular component of the 8<sup>th</sup> cranial nerve causing vestibular symptoms. This usually occurs insidiously and results in imbalance rather than true vertigo (Ramsden, 1987). NPC in the CPA can also affect the facial nerve resulting in facial palsy (Low, 2002).

Clinical diagnosis of NPC involvement at the CPA can be difficult. A patient who has received irradiation for NPC in the past may come to the Otolologist with sensorineural deafness caused by recurrent NPC in the CPA. The attending physician may miss the diagnosis if he/she simply assumes the deafness to be radiation-induced (Low and Fong, 1998). Similarly, dizziness may be assumed to be the result of metabolic abnormalities and other post irradiation effects (Singh and Slevin 1991). Even facial palsy as the presenting symptom of NPC involvement of the CPA can be misleading because doctors are ever eager to attribute it to Bell's palsy, given that facial palsy as a consequence of NPC is rare (Skinner et al., 1991). The maxim, "All that palsies is not Bell's," is particularly relevant with respect to

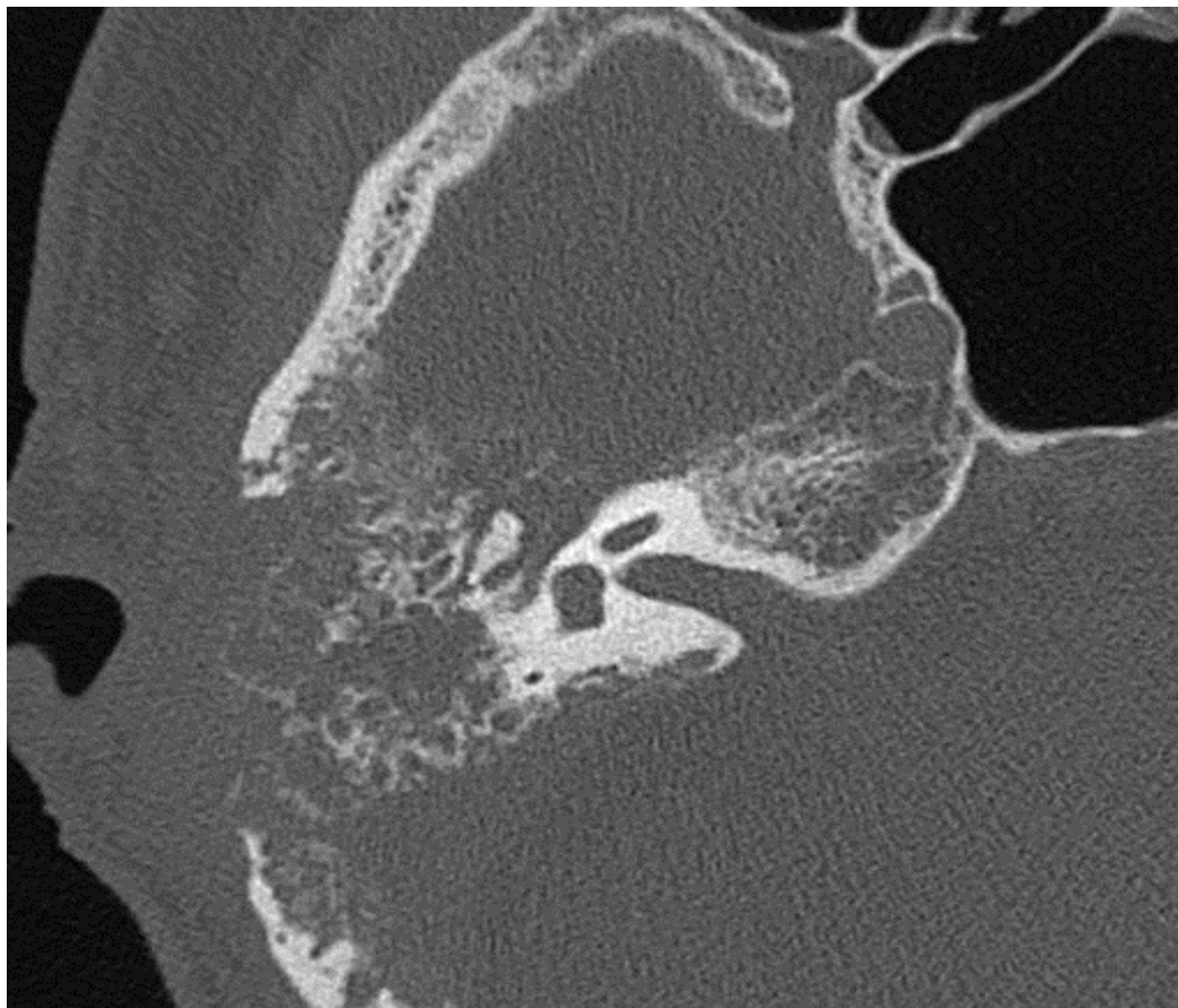


Fig. 1. Axial CT Scan of the right temporal bone ear showing tumor recurrence of the middle ear and mastoid.

This 50 year old Chinese man who had radiotherapy for NPC 2 years ago presented with chronic right ear discharge. Examination of the right ear showed narrowed edematous external ear canal. The eardrum could not be seen from auroscopy. The CT scan showed bony involvement. The list of differential diagnoses included tumour recurrence, osteo-radionecrosis and malignant otitis externa. He underwent surgical exploration and biopsy, which confirmed tumour recurrence. He was treated with palliative chemotherapy.

patients who have previously been treated for advanced NPC. In these patients, recurrent or persistent NPC involving the CPA, temporal bone, or parotid should be excluded (Low 2002). A factor that makes the diagnosis even more elusive is that postnasal space was often free of disease (Gouliamos et al, 1996).

Low et al (2000) reported the following case report, which illustrated the typical features of CPA involvement by NPC. A 53-year-old man was found to have NPC (stage T4N2, UICC 1997) when he experienced left vocal cord palsy (CN 10) and left CN 12 palsy. He was treated with radical radiotherapy. Two years later, he experienced left facial palsy (CN 7), giddiness, and left sensorineural hearing loss (CN 8). The giddiness was described as a

sense of imbalance and light-headedness but not vertigo. The postnasal space was clinically free of tumor, and biopsy did not show malignancy. A CT scan showed a deep submucosal recurrent NPC with bony erosion of the left jugular foramen and extending to the left posterior cranial fossa. He was subsequently treated with gamma knife radio-surgery.

There are a few possible mechanisms by which NPC can involve the CPA. Isolated lesions in the CPA that did not have tumor involvement of the skull base can involve the CPA, suggesting spread from the hematogenous route (Gouliamos et al. 1996). Yuh et al. (1993) suggested that metastatic cancers to the CPA could also arise from direct leptomeningeal spread or from dissemination through cerebrospinal fluid. The jugular foramen also offers a route of communication between the region of the para-nasopharynx and the posterior cranial fossa (Low et al 2000). Goh and Lim et al. (2009) suggested it could be as a result of perineural tumor spread.

According to Low et al. (2000), CPA manifestations of NPC can be as a result of inadequacies of standard radiotherapy techniques in the treatment of advanced NPC. The design of radiotherapy fields is based on the principle of maximal dose delivery to tumor-bearing tissues and maximal sparing of normal structures. A normal tissue or organ is considered to be “dose limiting” if its tolerance to radiation is so poor that it affects the maximum dose deliverable to the adjacent tumor-bearing tissues. Such structures around the postnasal space include the contents of the orbits, the optic nerves and chiasm, the hypothalamic-pituitary axis, the inner ear, the spinal cord, the temporal lobes of the brain, and the brainstem. Encephalomyelopathy is a feared complication in NPC treatment. To minimize the dose to the brainstem, standard radiotherapy techniques to the postnasal space mandate a brainstem shield. Thus, even microscopic disease in this area is under-treated. Geographic under treatment of an initially advanced cancer may result in a patient's returning for treatment at a later stage with clinical manifestations of tumor involving the CPA. Low et al (2000) concluded that this might represent progression of persistent tumor than a true relapse.

Treatment of NPC in the CPA is clinically challenging because when the standard radiotherapy techniques for NPC are applied to this region, the brainstem is at great risk. Gross disease extension into the CPA evident on CT scan is probably not radio-curable for this reason. In our center, such patients would be treated with initial chemotherapy in the hope that the tumor would shrink sufficiently to be encompassed by standard radiotherapy fields. Unfortunately, as illustrated by Low et al. (2000), NPC in the CPA may not respond well to chemotherapy.

Where a tumor is localized in the CPA, focal means of delivering radiotherapy in the form of radiosurgery as delivered by the gamma knife or fractionated stereotactic Linac radiotherapy, may be considered. Such focal means of delivering radiotherapy have the advantage of depositing a high dose to a well-defined volume of tumor-bearing tissues, with rapid dose fall off to the surrounding structures. The disadvantage is that there is a 4-cm upper limit in diameter of tumor size beyond which the dose-sparing feature of this modality is rapidly lost. Where the tumor is larger than is feasible for stereotactic radiotherapy, a standard wedge pair technique may be feasible. The caveat, which cannot be overemphasized, is that the larger the tumor volume, the higher the likelihood of incurring critical damage to surrounding structures (Low et. al., 2000)



### 2.3 Referred otalgia

Referred otalgia is pain felt in the ear but originating from a non-otologic source. Ear pain is a diagnostic dilemma when otoscopy reveals normal external ear and tympanic membrane. As the ear is innervated by sensory contributions of the 5<sup>th</sup>, 7<sup>th</sup>, 9<sup>th</sup> and 10<sup>th</sup> cranial nerves as well as spinal nerves C2 and C3, lesions arising from areas supplied by these nerves may result in pain referred to the ear.

Theoretically, NPC can present as referred otalgia by involving the 9<sup>th</sup> cranial nerve. We concur with the observation by van Hasselt & Gibb (1991) that otalgia is less common than one might expect. We agree with the view that the most common description of pain is not “sharp” but “aching, dull or pressing” (Epstein and Jones, 1993). This is illustrated by a case report by Low & Goh (1999):

A 48 year old man complained of a sensation of fullness in the left peri-auricular region, just antero-inferior to the tragus lasting for a month. Examination by manual palpation failed to reveal any mass in the region. CT scan of the parotid was normal. Nasal-endoscopy however, revealed a discrete mass in the left side of the post-nasal space. Biopsy of this nasopharyngeal mass showed undifferentiated nasopharyngeal carcinoma. His symptom resolved after radiation therapy.

### 2.4 Tinnitus

It is common for patients to consult the Otologist for the complaint of tinnitus in the absence of other ear symptoms or signs. If unilateral, the Otologist often considers the possibility of an early acoustic neuroma and investigates as such. It is however, highly unlikely that NPC presents as tinnitus as an isolated symptom in the absence of other features relating to the ear, a view shared by van Hasselt & Gibb (1991). If present, it is normally a result of Eustachian tube, middle ear or auditory nerve involvement with the resulting associated aural manifestations as well.

### 2.5 Peri-auricular mass

Although NPC metastasizing to the parotid is rare with only 14 cases reported in the literature (Wanamaker et al., 1994), this possibility should be considered in high-risk patients presenting with parotid masses. Batsakis and Bautina (1990) cautioned that some cases of 'primary undifferentiated carcinoma of nasopharyngeal type' in the major salivary glands might in fact be metastatic nasopharyngeal carcinoma. Low (2002) reported a case of metastatic NPC to the parotid and presenting with facial palsy as follows.

A 50-year-old man was treated for nasopharyngeal carcinoma overseas. Two years later, he exhibited complete left lower motor neuron facial nerve palsy. Examination revealed a hard mass in the left parotid over the region of the facial trunk in addition to multiple swollen cervical nodes (figure 3). The postnasal space was clinically free of tumor, and the appearance of the ears was unremarkable. Chest x-ray showed multiple metastases. Analysis of a fine-needle aspiration sample of the parotid mass identified an undifferentiated carcinoma consistent with metastatic nasopharyngeal carcinoma. The patient refused further treatment and died 3 months later.

Parotid metastasis is most commonly due to lymphatic spread (Wanamaker et al., 1994). The parotid is made up of a rich network of lymphatic vessels and interconnecting intra-glandular and peri-glandular lymph nodes. NPC can affect the retropharyngeal lymph nodes, which can drain into the parotid nodes. From the parotid nodes, the tumor has access to the lymphatic plexus, parotid parenchyma, facial nerve, and even the parapharyngeal space (Batsakis & Bautina 1990).

### **3. Otologic complications arising from treatment of NPC**

As NPC is highly radiosensitive, radiation treatment stands as the primary modality of management. The aim of treatment is eradication of tumor through targeted delivery of radiation to the tumor bed, at tolerable doses to minimize acute and late complications. It is a challenge to balance cure on one hand, and prevention of complications from treatment on the other. The focus in this section is to highlight the impact of treatment of NPC on ear structures.

#### **3.1 Radiation therapy**

Megavoltage external beam radiotherapy is the primary treatment of choice. There are two lateral opposing and one anterior field beams. This is meant to cover the sides of the neck and entire nasopharynx. Radiotherapy is given prophylactically to the neck assuming there is occult disease.

A typical convention technique used by us involves patients treated with six megavolt (6MV) X-rays from linear accelerators. Chemotherapy was not part of the protocol for any patient. The primary volume covered the nasopharynx including the Eustachian tube, adjacent parapharynx to the level of the inferior border of C2, and posterior third to half of the nasal cavity and maxillary antra (Figures 2 and 3). As shown, the brainstem was shielded throughout on the lateral fields and the inner ear would be at the edge of this shield. A total dose of 66 – 70 Gys in 2 Gy daily increments was prescribed. The neck received 60 Gy electively, with palpable nodes boosted to 70 Gy.

#### **3.1.1 Post-irradiation otitis media**

##### **3.1.1.1 Middle ear effusion**

MEE is a common finding among patients who have been irradiated for NPC patients and is generally attributed to Eustachian tube dysfunction. Post-irradiated ultra-structural findings of the Eustachian tubal mucosa showed ciliary loss, intercellular and intracellular vacuolation and ciliary dysmorphism (Lou et al., 1999). Most of these pathologic findings were observed to be persistent and did not resolve with time suggesting that radiation had caused long-term damage to the Eustachian tube epithelium. The Eustachian tube could grossly manifest in differing ways ranging from patulous Eustachian tube, adhesion, incomplete and complete obstruction (Zhou et al., 2003).

MEE could be present in the early post-radiotherapy period and some persist in the long-term. Low & Fong (1998) studied the factors, which could possibly influence the development of long-term middle ear effusion in patients irradiated for NPC. Thirty-five patients (70 ears) were studied for 2-8 years (mean 5.5 years) post-radiotherapy. The factors studied were (a) sex (b) age (c) tumour size and (d) presence of pre-radiotherapy MEE. Only

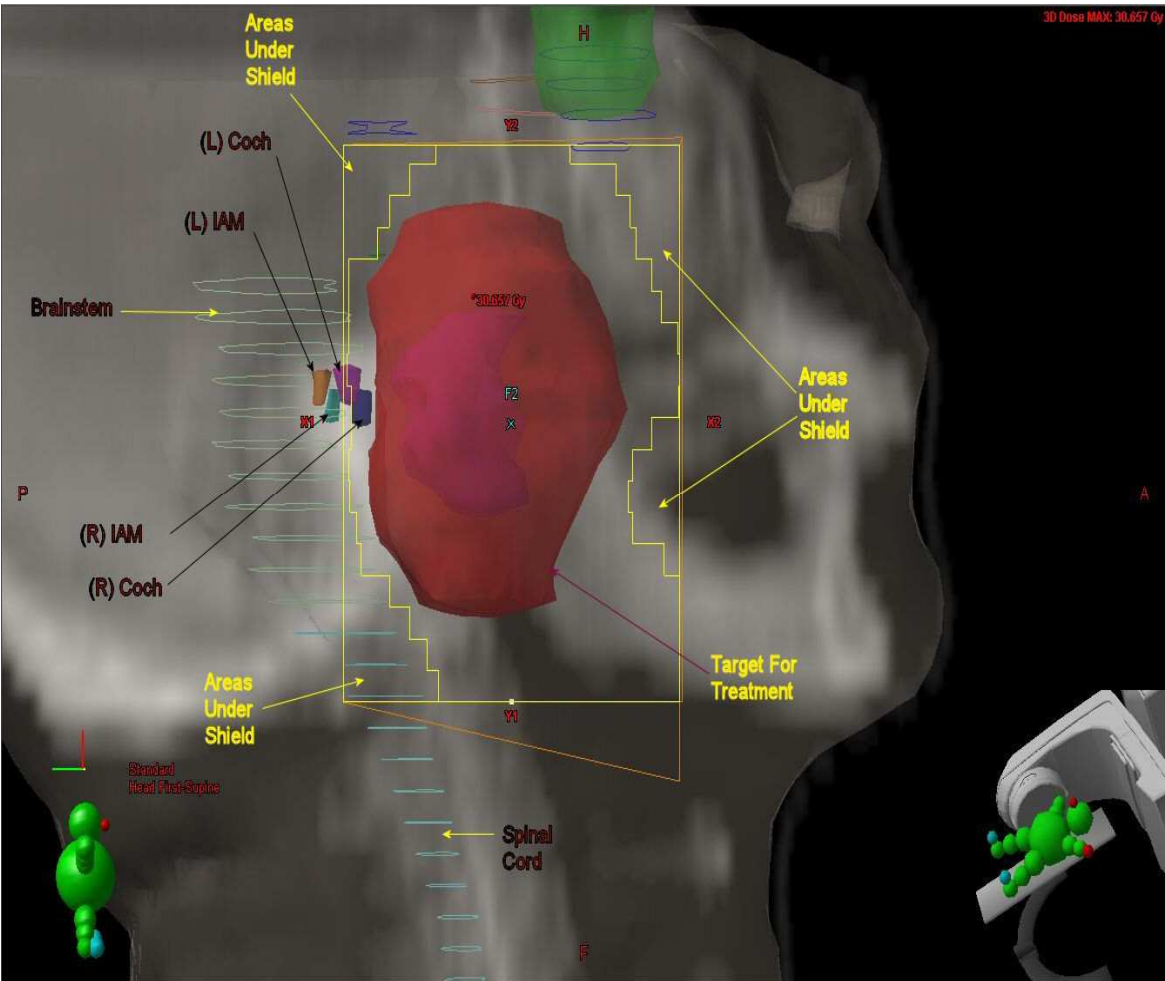


Fig. 2. Beam's Eye View (BEV) of lateral post-nasal space field. The field (yellow box) is superimposed on a digitally reconstructed radiograph (DRR) by the planning computer. The solid red area represents the target volume where a uniform high dose is deposited. Critical structures are shielded to reduce exposure. These structures include the brain stem and spinal cord, optic chiasma (blue), and the inner ear as much as is feasible.

the presence of pre-radiotherapy MEE was found to be statistically significant ( $P = 0.004$ , Fisher's exact test). Stepwise multiple regression analysis showed the presence of pre-radiotherapy MEE was a predictor of post-radiotherapy MEE with an odds ratio of 0.67. Hence, an ear with pre-irradiation MEE was almost seven times more likely to have long-term post-irradiation MEE than an ear without pre-irradiation MEE. It was postulated that irreversible Eustachian tube dysfunction occurred only when the tube that had been damaged by tumour was further damaged by irradiation. It may well be that tumour and irradiation had induced change in the compliance of the Eustachian tube resulting in the development of long-term post-radiotherapy MEE.

As the mechanism of post-radiotherapy MEE is likely to be different from MEE commonly found in children, its principles of management are also different. Unlike in children, the use of ventilation tubes has the tendency to result in chronic infection, which was are often persistent and troublesome. They also tend to be associated with persistent perforations.





reported post-radiation therapy hearing loss rates based on audiometric evaluation varied between 0% and 54% (Ho et al., 1999; Kwong et al., 1996; Raajmakers et al., 2002). This is attributed to radiation-induced damage to the sensorineural auditory pathways.

It is important to know whether the auditory nerve, the central nervous pathways or both, are damaged by radiotherapy. This is important in the context of treating profound hearing loss in post-irradiated ears using the cochlear implant. The cochlear implant works by stimulating the auditory nerve fibres directly, without the need for functioning cochlear hair cells. Its success therefore, depends largely on a functional auditory nerve and its central nervous pathways.

If the auditory nerve and central nervous structures are indeed spared and that damage occurs primarily in the cochlea, it will then be useful to understand the cellular and molecular processes involved in radiation-induced cochlear hair-cell damage. This is because it has relevance in preventive measures where medications are used to target the cellular and molecular pathways involved.

### 3.1.2.1 Pathogenesis

It was demonstrated in chinchillas that cochlear nerve fiber degeneration occurred after exposure to high radiation doses. In ears exposed to 40 to 50Gy and 60 to 90Gy of radiation, the incidence rates were 31% and 62% respectively, (Bohne et al., 1985) confirming that radiation induced damage is dose dependent.

To find out if radiation damages retro-cochlear auditory pathways, we prospectively studied newly diagnosed NPC patients treated by radiotherapy alone (Low et al., 2005). Audiograms including evoked response audiometry which could assess the integrity of retro-cochlear auditory pathways, were carried out prior to and after radiotherapy (at 3, 18 and 48 months). There was no statistically significant difference in inter-waves latencies recorded before and after RT ( $p > 0.05$ , Wilcoxon Signed Ranks Test), suggesting that the retro-cochlear auditory pathways were functionally intact. Analysis of dose-volume histograms confirmed that the cochlea and internal auditory meatus received significant doses of radiation, ranging from 24.1-62.2 and 14.4 – 43.4 Gy respectively.

It is believed that etiologies of SNHL such as ageing and drug toxicity, share similar cell death mechanisms leading to a final common apoptotic pathway (Atar et al., 2005). Radiation-induced apoptosis has been well demonstrated in non-cochlear cell systems and is generally accepted as an important mechanism of radiation-induced cell death in vivo (Shinomiya 2001; Verheij & Bartelink 2000) Therefore, by relating our findings to what is already known, it is not unreasonable to expect radiation-induced apoptosis occurring in cochlear hair-cells in vivo.

It is well accepted that radiation-induced SNHL is progressive in nature. The integrity of normal tissues or organs depends on the maintenance of a certain number of normally functioning mature cells. When the depletion of functioning cells reaches a critical level, a clinically detectable effect becomes apparent (Awwad 1990). In the case of radiation-induced SNHL the cochlea consists of a finite number of post-mitotic non-regenerating hair cells. A patient may experience hearing loss when a critical mass of hair cells is lost and it may take several months or years after radiation exposure before this stage is reached. Radiation-induced SNHL has been described to have either early or late-onset. Early-onset



SNHL occur within hours or days after completion of RT, whereas late-onset radiation-induced SNHL may manifest months or years after exposure. Hence, “late”-onset radiation-induced SNHL may possibly represent the later stages of the progression in hair cell degeneration initiated by direct cellular injury during irradiation. Alternatively, the initial radiation-induced injury could have rendered the cells more susceptible to apoptosis following subsequent exposure to insults such as noise and ototoxic medications (Low et al., 2009).

There has been compelling evidence in animal models, implicating reactive oxygen species (ROS) in the damage associated with non-radiation causes such as cochlear ischemia, noise trauma, presbycusis, meningitis-associated hearing loss and aminoglycoside and cisplatin ototoxicity (Seidman and Vivek, 2004).

In radiation-induced apoptosis in the OC-k3 inner ear cell line, Low et al., (2006a), demonstrated dose-dependant intracellular generation of ROS at 1 hour post-irradiation and was believed to be an important triggering factor in the apoptotic process. ROS could explain the observation that high frequency hearing is preferentially damaged by radiation (Rybak & Whitworth 2005). In an animal study on aminoglycoside ototoxicity, outer hair-cell death in the Organ of Corti was observed to follow a base-to-apex gradient, which was eliminated by the addition of antioxidants (Sha et al., 2001). This was attributed to the outer hair cells in the basal coil (respond to higher frequency sounds) having much lower levels of glutathione than those in the apical region (respond to lower frequency sounds) and therefore, a lower antioxidant capacity (Rybak & Whitworth 2005).

In the OC-k3 inner ear cell line, Low et al., (2006a) found up-regulation of p53 related genes from micro-array studies. Western blotting confirmed up-regulation of p53 at 72 hours and phosphorylation at 3, 24, 48 and 72 hours after irradiation. It is well known that p53 can induce apoptosis.

Nevertheless, a number of different mechanisms leading to cell deaths may also be involved in radiation-induced ototoxicity. These include necrotic cell death, p53-independent mechanisms and caspase-independent programmed cell death. Multiple cellular organelles may trigger several pathways that may act independently or in concert (Leist & Jaattela 2003).

### 3.2 Prevention

For NPC and other tumours that are treated mainly by radiation, improved radiotherapy techniques such as intensity modulated RT help to reduce unnecessary radiation exposure to the ear. This may be facilitated by early detection when the tumours are still small and situated away from ear structures.

Accurate delineation of the middle and inner ear is a prerequisite to achieve dose constraint to those structures. The size and proximity of the middle and inner ear to the tumor, renders it susceptible to damage. As deviation during contouring can have a profound impact on post treatment sequelae (Wang et al., 2011), Pacholke et al. (2005) established guidelines for contouring the middle ear and the two major components of the inner ear. These guidelines have been of practical help to radiation oncologists.

Improving tumor control rate is the aim, but another important goal is to reduce radiation-induced complications and to improve the quality of life of survivors. The application of 3D conformal radiation therapy (3D-CRT) and intensity-modulated radiation therapy (IMRT) signified a major improvement over conventional 2D radiation therapy. A randomized controlled clinical study showed that at 12 months post-radiation therapy, quality of life scores were significantly higher in the IMRT group than the conventional radiation therapy group for patients with NPC (86.5 versus 58.3;  $P < 0.001$ ) (Pow et al., 2006). The incidence of chronic otitis media and abnormal vestibular evoked myogenic potentials in NPC patients treated by IMRT were significantly lower when compared with those treated by 2DRT, demonstrating the superiority of IMRT in decreasing unwanted otologic complications. However, occurrence of MEE, which was related with advanced T stage, cannot be reduced by IMRT (Hsin et al., 2010).

Clinically effective preventive measures can potentially be applied based on the above proposed ROS-linked p-53 dependent apoptotic model of radiation-induced ototoxicity. It also provides a basis for the use of anti-oxidants and anti-apoptotic factors in its prevention. Antioxidants look promising as effective agents to prevent radiation-induced ototoxicity; they target upstream processes leading to different cell death mechanisms that may co-exist in the population of damaged cells (Low et al., 2009). An anti-oxidant, L-N-Acetylcysteine (L-NAC), was demonstrated in the same cell line to have a protective effect (Low et al., 2008). With its track record of safety in humans and efficacy as an anti-oxidant, L-NAC appears promising as an agent to prevent radiation-induced SNHL in the near future. High doses can potentially be delivered trans-tympanically into the middle ear with minimal systematic side effects, and entry to the inner ear is facilitated by its low molecular weight.

### 3.3 Treatment

Efforts to regenerate hair cells represent a large and important field of research and appear promising in animal studies. However, integrating transplanted stem cells into damaged epithelium and generating the correct number of cells in the correct parts of the Organ of Corti will be a challenge. Given that much of cochlear function depends on the precise mechanical properties of the Organ of Corti, excess or inappropriately placed cells are likely to cause problems. Moreover, the possible effects of radiation on the supporting and vascular structures of the Organ of Corti, may also complicate regenerative efforts.

For now, the best therapeutic strategy would be effective rehabilitation of SNHL after RT.

#### 3.3.1 Cochlear implantation

In patients with profound SNHL, cochlear implants may be effective if the retro-cochlear auditory pathways remained intact. To substantiate that the retro-cochlear auditory pathways remained intact after RT (Low et al., 2005), a case-control study of cochlear implant recipients who had prior irradiation for NPC was conducted in our clinic (Low et al 2006b). They received their RT 11-28 years prior to cochlear implantation and the post-implant follow-up period ranged from 9 to 46 months. The implanted ear of each patient had favourable pre-operative promontory stimulation results. Post-implant, all patients were satisfied with their hearing outcomes and the improvement in speech discrimination scores was comparable to the controls.

There are specific issues related to cochlear implantation in post-irradiated ears that one should consider:

#### **3.3.1.1 Surgery**

Adhesions in middle ear could complicate surgery, including posing difficulties during identification of the round window niche. Post radiation obliteration of the cochlea lumen is possible, which could compromise smooth insertion of electrode array during implantation (Formanek et al., 1998).

In cochlear implantation of patients who had been irradiated for NPC, two aspects ought to be highlighted. Firstly, these patients not infrequently have perforated eardrums and middle ear infections, with the Eustachian tube openings in the nasopharynx completely obliterated. For these patients, conventional techniques of cochlear implantation do not apply and modified techniques such as subtotal petrosectomy, fat obliteration and blind sac closure become necessary. Secondly, NPC has a racial predilection and is common in the Chinese. Racial differences in mastoid morphology exist and such differences had even been used in race identification during forensic and anthropology investigations. Indeed, a study of Chinese temporal bones had revealed differences in the course of the facial nerve in the mastoid and in the origin of the chorda tympani, as compared to those described in Western textbooks (Low, 1999). Knowledge of such racial anatomical variations may reduce the risk of facial nerve injury during mastoid surgery, especially in irradiated ears where the bone is usually more friable than normal.

#### **3.3.1.2 Surveillance imaging**

A part of the internal component of the cochlear implant is a small magnet, which is required to secure the external component to the skin of the patient. In an NPC patient who had been treated previously, magnetic resonance imaging is sometimes required to exclude the possibility of tumor recurrence. Should magnetic resonance imaging be indicated in a patient who is already a cochlear implant recipient, there may be a need to remove the magnet from the internal device before the scan.

#### **3.3.1.3 Re-irradiation**

In recurrent tumors, further radiotherapy may be indicated. Fortunately, the internal device had been shown to be resistant to damage by radiation (Ralston et al., 1999). However, cumulative radiation doses from further radiotherapy could inflict severe damage to the auditory nerve, which could compromise the post-implant hearing outcome.

### **3.3.2 Bone-anchored hearing aids**

Conventional hearing aids may effectively address conductive hearing loss resulting from MEE. However, they may aggravate otorrhea, and ear moulds traumatize osteoradionecrosis ulcers in the ear canal. An alternative for patients is the bone-anchored hearing aids (BAHA). BAHA has been shown to have successful osseointegration in post-irradiated NPC patients (Soo et al., 2009). Improved subjective hearing clarity, reduced ear discharge rates, and extended BAHA usage times accounted for high patient satisfaction with the BAHA hearing system. Soo et al (2009) therefore, recommended the BAHA hearing

system for the treatment of chronic suppurative otitis media-related hearing problems in NPC patients.

### 3.3.3 Active middle ear implants

Compared to conventional hearing aids, active middle ear implants such as the Vibrant Soundbridge provide more mechanical energy into the inner ear. However, they still rely on viable cochlear hair cells in order to convert mechanical energy into electrical energy for onward transmission through the auditory nerve to the brain. In radiation-induced SNHL, there may be progressive cochlear hair cell loss. Patients with post-radiotherapy SNHL affecting only the higher frequencies may initially be suitable for middle ear implants. However, its use should be cautioned as the natural progressive nature of radiation-induced SNHL might affect the effectiveness of these devices in the longer term.

### 3.3.4 Chemo-radiation and their combined ototoxic effects

Combined chemo-radiotherapy is increasingly being used clinically to treat advanced head and neck cancers. In radiotherapy of tumours in the head and neck region, the auditory pathways are often included in the radiation fields and radiation-induced SNHL may result. Cisplatin (CDDP), widely used as an effective anti-neoplastic drug for these cancers, is also well known to cause ototoxicity. Therefore, in combined therapy, the synergistic ototoxic effects of CDDP and radiation could theoretically be catastrophic for the patient and is a clinical issue that deserves more attention.

Skinner et al. (1990) remarked that previous or concurrent use of other ototoxic agents with CDDP, may increase toxicity by more than simple algebraic summation. Indeed, there have been a number of reports that described enhanced radiation-induced ototoxicity when used with CDDP. In a study by Schnell et al (1989) it was found that children and young adults treated with CDDP suffered an additional 20-30dB SNHL if they had received prior cranial RT. In a study on children and adolescents who had received CDDP for the treatment of solid tumours, Skinner et al. (1990) reported more severe CDDP ototoxicity in patients who had previously received RT encompassing the ear. Similarly, Merchant et al (2004) observed enhanced ototoxicity in a study on children with brain tumours who were treated by pre-RT ototoxic chemotherapy. Miettinen et al (1997) also found that radiotherapy enhanced the ototoxicity of CDDP in the higher speech frequencies. The results of these studies were consistent with those from case reports, which supported the idea that RT should be considered cautiously in children treated with CDDP for intracranial malignancies (Sweetow & Will, 1993; Walker et al, 1989)

We conducted a single blinded randomized trial to investigate the true differences in extent, onset and clinical course of SNHL between newly diagnosed nasopharyngeal carcinoma (NPC) patients treated by RT alone and by combined chemo-RT (Low et al 2006c). Bone conduction thresholds were performed before treatment and at 1 week, 6 months, 1 year and 2 years after completion of RT. Statistical analysis was performed using the Mann-Whitney test. Hearing thresholds averaged over 0.5, 1 and 2kHz were found to be poorer in the chemo-RT group (116 ears) compared to the radiotherapy group (114 ears), at 1 year ( $p=0.001$ ) and 2 years ( $p=0.03$ ) post-treatment. Hearing thresholds at 4kHz were

significantly worse for patients in the chemo-RT arm at all the post-treatment time points studied and were more severely affected than those at lower frequencies.

### 3.4 Osteo-radionecrosis

Osteo-radionecrosis (ORN) is an uncommon complication of radiation treatment. In post-irradiated NPC patients, it may occur in the temporal bone and presents as chronic or recurrent ear discharge. To the unwary Clinician, this can potentially be misdiagnosed as the symptoms of chronic suppurative otitis media and otitis externa, both of which are common in post-irradiated NPC patients.

Radiation may result in hypoxia, hypovascularity and hypocellularity of canal skin. These impair normal collagen synthesis and cell production and lead to tissue breakdown and eventual ORN (Hao et al., 2007). Obliterative vasculitis also causes a direct radiation-induced avascular necrosis of the bone (Schuknecht & Karmody, 1966). This is more likely to occur in the presence of tumor involvement (Lederman, 1965). There is a positive relationship between the size of the radiation dose and the degree of necrosis (Thornley et al., 1979).

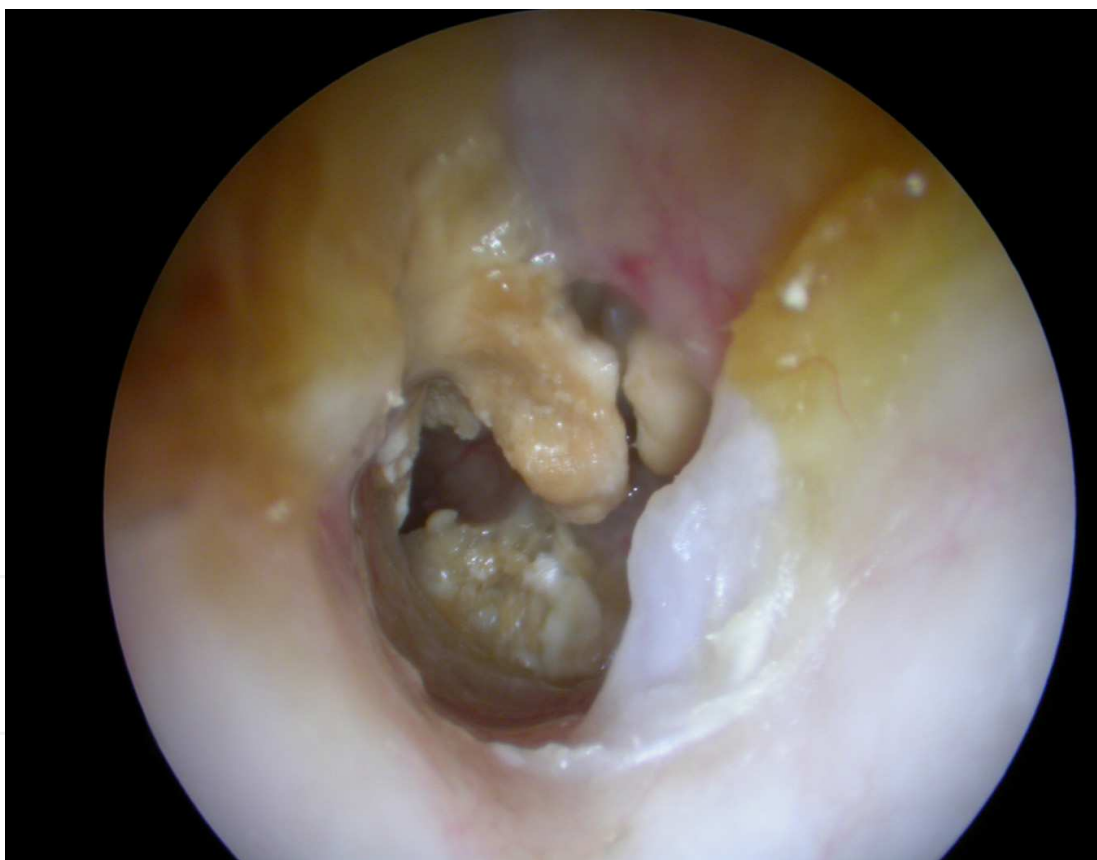


Fig. 4. Endoscopic view of the left external and middle ear showing osteo-radionecrosis. This 60 year old woman had radiotherapy for NPC 15 years ago and had remained disease free since. She presented with chronic left ear discharge 12 years after radiotherapy. Examination showed necrotic in the external ear canal and middle ear. CT scan showed that the bony lesions did not involve the rest of the temporal bone. She was closely followed up with regular aural toilet and topical antibiotics. She was not keen for other treatment options like hyperbaric oxygen and sequestrectomy.



Ramsden et al (1975) classified osteoradionecrosis of the temporal bone as either localized or diffuse. In localized osteoradionecrosis, the disease is generally confined to the external auditory canal, and symptoms manifest according to the site and stage of the disease. In diffuse osteoradionecrosis it extends beyond the temporal bone to the base of the skull and its surrounding structures. The affected patients presented with more severe symptoms of profuse and pulsatile otorrhea and significant pain. The diffuse form is associated with a greater likelihood of complications, including trismus, intracranial infection, facial nerve palsy, labyrinthitis, chronic mastoiditis, CSF leak, and internal carotid artery aneurysm. (John et al., 1993)

The type that is more commonly seen is the localized type where the ORN is heralded by unhealed ulcer, foul discharge, exposed bone and accompanying granuloma. It is typically seen in the lower external canal skin, an area predisposed to downward pressure-induced trauma from wearing hearing aids or iatrogenically traumatized during aural toileting or ear-picking. Sometimes, it involves the middle ear (Figure 4). As suggested by Hao et al, treatment ranges from thorough aural toilet, otic drops, hyperbaric oxygen (Rudge 1993) that reverses the ill effects of radiation induced skin changes, and finally sequestrectomy. Most important though rare, high degree of suspicion and awareness is the key in detection and early management of this condition before serious complication ensues. Lim et al (2005) reported an interesting case of a 44-year-old Chinese man with a history of nasopharyngeal carcinoma that was treated with radiotherapy presented with fluid in the middle ear. A myringotomy was performed and subsequently a diagnosis of cerebrospinal fluid leakage secondary to osteoradionecrosis of the temporal bone was made.

### 3.5 Radiation-associated tumors

Radiation-associated tumours (RATS) are rare complications of radiotherapy. Goh et al (1999) studied RATs in the temporal bones of patients who were previously irradiated for cancers of the nasopharynx. Of the 7 patients studied, 5 had squamous cell carcinomas, 1 osteogenic sarcoma and 1 chondrosarcoma. This distribution of the type of cancer is interesting as radiation-induced cancers are more associated with sarcoma than with squamous cell carcinoma. A possible reason for this observation may be related to the chronic ear infections that are commonly present in post-irradiated ears. The combined long-term effects of radiation and chronic infections may well predispose the ear to squamous cell carcinoma. In another study of patients with malignant tumors of the external auditory canal and temporal bone, the 1-year cumulative recurrence for the RAT group was 100%, but there was no recurrence in the non-RAT group ( $P = 0.001$ ) suggesting a poorer prognosis in RATS patients (Lim et al 2000)

Delayed diagnosis is not uncommon in this condition. Almost two thirds of the patients in the series reported by Lim et al. (2000) had T3 disease at the time of presentation. One reason could be that otorrhea, the most common presentation, was often mistaken to be due to chronic otitis externa.

Another reason for misdiagnosis is difficulty in getting histological confirmation in the Clinic. Lim et al (2000) gave the example of a patient with an initial diagnosis of pseudoepitheliomatous hyperplasia. This was based on superficial small punch biopsy

specimens obtained under local anesthesia. It was only upon larger and deeper specimens obtained under general anesthesia from the mastoid that revealed the true diagnosis.

RATs may be uncommon, but with refinement in radiotherapy techniques and the resultant increase in patient survival, there may be more patients with radiation-associated tumours in the future. It remains imperative for clinicians to be vigilant when patients previously irradiated for NPC present with otological symptoms as the key to the successful management of this condition lies in the early detection and expedient treatment of this difficult disease.

#### 4. Conclusion

Because of the close relation between the nasopharynx and ear structures, NPC frequently has Otological manifestations. Attending Physicians must be mindful of these manifestations as they may aid early diagnosis with consequently better treatment outcomes.

Treatment of NPC with radiotherapy or chemo-radiation also has great impact on the practice of Otolaryngology. Improved RT techniques have reduced unnecessary radiation exposure to ear structures, with lesser chances of developing ear complications. Nevertheless, it is inevitable in many instances. With greater emphasis in the use of chemo-RT in advanced head and neck cancers, chemo-radiation-induced SNHL has also assumed greater significance. Although recent technology such as cochlear implants have been highly successful in rehabilitating profound hearing loss, prevention is still the best practice in the management of radiation-induced SNHL. A proposed ROS-dependent apoptotic model of hair-cell damage offers the prospect of prevention at a molecular level in the near future.

#### 5. Acknowledgement

We thank Dr Fong Kam Weng, Senior Consultant of the Therapeutic Radiology Department, Singapore National Cancer Centre, for the illustrations

#### 6. References

- Atar O, Avraham KB. Therapeutics of hearing loss: expectations vs reality. *Drug Discov Today*; 2005 Oct 1;10 (19):1323-30.
- Awwad HK. Late reacting tissues: radiation damage to central nervous system. *Radiation Oncology: The Netherlands*; 1990 Nov; Kluger Academic Publishers.
- Batsakis JG, Bautina E. Metastases to major salivary glands. *Ann Otol Rhinol Laryngol*. 1990 Jun; 99:501-03.
- Bergstrom L, Baker, BB, Sando I. Sudden deafness and facial palsy from metastatic bronchogenic carcinoma. *J Laryngol Otol*. 1977 Sep; 91: 787-89.
- Bluestone CD. Current concepts in Eustachian tube function as related to otitis media. *Auris-Nasus-Larynx (Tokyo)* 1985; 12 (Suppl 1): 1-4.
- Bluestone CD. Eustachian tube function: physiology, pathophysiology, and role of allergy in pathogenesis of otitis media. *J allergy Clin. Immunol*. 1983 Sep; 72:242-51.
- Bohne BA, Marks JE, Glasgow GP. Delayed effects of ionizing radiation on the ear. *Laryngoscope* 1985 Jul; 95:818-28.

- Casselbrandt ML, Cantekin EI, Dirkmatt DC, Doyle WJ, Bluestone CD. Experimental paralysis of tensor veli palatini muscle, *Acta Otolaryngologica* (Stockholm) 1988 Sep-Oct; 106:178-85
- Choa GB, Nasopharyngeal carcinoma. In: *Otolaryngology*, Vol. 5 ed. G.M. Philadelphia: Harper & Row, 1981; 1-35.
- Cundy LR, Sando I, Hemingway WG. Middle ear extension of nasopharyngeal carcinoma via eustachian tube. *Arch Otolaryngol*. 1973 Aug; 98: 131-33.
- Epstein JB, Jones CK. Presenting signs and symptoms of nasopharyngeal carcinoma. *Oral Surg Oral Med Oral Pathol*. 1993 Jan; 75(1):32-36.
- Formanek M, Czerny C, Gstoettner W, Kornfehl J. Cochlear implantation as a successful rehabilitation for radiation-induced deafness. *Eur Arch Otorhinolaryngol*. 1998; 255:175-78.
- Goh J, Lim K. Imaging of nasopharyngeal carcinoma. *Ann Acad Med Singapore*. 2009 Sep; 38(9):809-16.
- Goh YH, Chong VF, Low WK. Temporal bone tumours in patients irradiated for nasopharyngeal neoplasm. *J Laryngol Otol*. 1999 Mar; 113(3):222-28.
- Gouliamos AD, Athanassopoulou A, Mouloupoulou L, et al. MRI nasopharyngeal carcinoma to the cerebellopontine angle. *Neuroradiol*. 1996 May; 38:375-77.
- Grontved A, Moller A, Jorgenson L. Studies on gas tension in the normal middle ear. *Acta Otolaryngologica* (Stockholm) 1990 Mar; 109:271-77.
- Hao SP, Tsang NM, Chang KP, Chen CK, Chao WC. Osteoradionecrosis of external auditory canal in nasopharyngeal carcinoma. *Chang Gung Med J*. 2007 Mar-Apr; 30(2): 116-21.
- Hao SP, Chen HC, Wei FC, Chen CY, Yeh AR, Su JL. Systematic management of osteoradionecrosis in the head and neck. *Laryngoscope*; 1999 Aug; 109:1324-27.
- Hergils L, Magnuson B. Human ear gas composition studied by mass spectrometry. *Acta Otolaryngologica* (Stockholm) 1990 Jul-Aug; 110:92-99.
- Ho, WK, Wei WI, Kwong DL, Sham JS, Tai PT, Yuen AP, Au DK. Long-term sensorineural hearing deficit following radiotherapy in patients suffering from nasopharyngeal carcinoma: a prospective study. *Head Neck*; 1999 Sep; 21, 547-53.
- Honjo, I. *Nasopharyngeal Carcinoma on Otitis Media with Effusion in Eustachian Tube and Middle Ear Diseases*. Springer-Verlag, Tokyo-Berlin-Heidelberg-New York-London-Paris, 1988; 91-111.
- Hsin CH, Chen TH, Young YH, Liu WS. Comparison of otologic complications between intensity-modulated and two-dimensional radiotherapies in nasopharyngeal carcinoma patients. *Otolaryngol Head Neck Surg*. 2010 Nov; 143(5):662-68.
- John DG, Porter MJ, van Hasselt CA. Beware bleeding from the ear. *J Laryngol Otol* 1993 Feb; 107:137-9.
- Kwong DLW, Wei WI, Sham JST, Ho WK, Yuen PW, Chua DTT, Au DKK, Wu PM, Choy DTK. Sensorineural hearing loss in patients treated for nasopharyngeal carcinoma: A prospective study of the effect of radiation and cisplatin treatment. *Int J Rad Oncol Biol Phys*. 1996 Sep; 36: 281-89.
- Lederman M. Malignant tumours of the ear. *J Laryngol Otol*. 1965 Feb; 79: 85-119.
- Leist M, Jaattela M. Caspase-independent cell death. In: Grimm S, editor. *Genetics of Apoptosis*. UK: BIOS Scientific Publishers Ltd, Trowbridge, 2003.

- Leong JL, Fong KW, Low WK. Factors contributing to delayed diagnosis in nasopharyngeal carcinoma. *J Laryngol Otol*. 1999 Jul; 113(7):633-36.
- Lim BY, Pang KP, Low WK, Tan HM. CSF otorrhea complicating temporal bone osteoradionecrosis in a patient with nasopharyngeal carcinoma. *Ear Nose Throat J*. 2005 Jan; 84(1):39-40.
- Lim LH, Goh YH, Chan YM, Chong VF, Low WK. Malignancy of the temporal bone and external auditory canal. *Otolaryngol and Head Neck Surg*. 2000 Jun;122(6):882-86.
- Loong HH, Ma BB, Chan AT. Update on the management and therapeutic monitoring of advanced nasopharyngeal cancer. *Hematol Oncol Clin North Am*. 2008 Dec; 22(6): 1267-78
- Lou PJ, Chen WP, Tai CC. Delayed irradiation effects on nasal epithelium in patients with nasopharyngeal carcinoma. An ultrastructural study. *Ann Otol Rhinol Laryngol*. 1999 May; 108(5):474-80.
- Low WK. Facial palsy from metastatic nasopharyngeal carcinoma at various sites: Three reports. *Ear, Nose Throat J*. Feb. 2002; 81(2):99-101.
- Low WK. Surgical anatomy of the facial nerve in Chinese mastoids. *ORL J Otorhinolaryngol Relat Spec*. 1999 Nov-Dec; 61(6):341-44.
- Low WK. Middle ear pressures in patients with nasopharyngeal carcinoma and their clinical significance. *Journal of Laryngology and Otology*. 1995 May; 109:390-93.
- Low WK, Burgess R, Fong KW, Wang DY. Effect of radiotherapy on retro-cochlear pathways. *Laryngoscope*; 2005 Oct; 115:1823-26.
- Low WK, Fong KW, Chong VF. Cerebellopontine angle involvement by nasopharyngeal carcinoma. *Am J Otol*. 2000 Nov; 21(6):871-76.
- Low WK, Fong KW. Long-term hearing status after radiotherapy for nasopharyngeal carcinoma. *Auris Nasus Larynx*; 1998 Jan; 25:21-24.
- Low WK, Goh YH. Uncommon otological manifestations of nasopharyngeal carcinoma, *J Laryngol Otol*. 1999 Jun; Vol.113, 558-60.
- Low WK, Gopal K, Goh LK, Fong KW. Cochlear implantation in postirradiated ears: outcomes and challenges. *Laryngoscope*; 2006b Jul; 116(7):1258-62.
- Low Wk, Lim TA, Fan YF, Balakrishnan A. Pathogenesis of middle ear effusion in nasopharyngeal carcinoma: a new perspective. *J Laryngol Otol*. 1997 May; 111(5): 431-34.
- Low WK, Sun L, Tan MG, Chua AW, Wang DY. L-N-Acetylcysteine protects against radiation-induced apoptosis in a cochlear cell line. *Acta Otolaryngol*. 2008 Apr; 128(4):440-45.
- Low WK, Tan MG, Chua AW, Sun L, Wang DY. 12th Yahya Cohen Memorial Lecture: The cellular and molecular basis of radiation-induced sensori-neural hearing loss. *Ann Acad Med Singapore*. 2009 Jan; 38(1):91-94.
- Low WK, Tan MG, Sun L, Chua AW, Goh LK, Wang DY. Dose- dependant radiation-induced apoptosis in a cochlear cell-line. *Apoptosis* 2006a Dec; 11:2127-36.
- Low WK, Toh ST, Wee J, Fook-Chong SM, Wang DY. Sensorineural hearing loss after radiotherapy and chemoradiotherapy: a single, blinded, randomized study. *J Clin Oncol*. 2006c Apr; 20;24(12):1904-09.
- Merchant TE, Gould CJ, Xiong X, Robbins N, Zhu J, Pritchard DL, Khan R, Heideman RL, Krasin MJ, Kun LE. Early neuro-otologic effects of three-dimensional irradiation in




- children with primary brain tumors. *Int J Radiat Oncol Biol Phys*. 2004 Mar 15; 58(4): 1194-207.
- Miettinen S, Laurikainen E, Johansson R, Minn H, Laurell G, Salmi TT. Radiotherapy enhanced ototoxicity of cisplatin in children. *Acta Otolaryngol Suppl*. 1997; 529:90-94.
- Miura T, Hirabuki N, Nishiyama K, Hashimoto T, Kawai R, Yoshida J, Sasaki R, Matsunaga T, Kozuka T. Computed tomographic findings of nasopharyngeal carcinoma with skull base and intracranial involvement. *Cancer*. 1990 Jan; 65(1): 29-37.
- Myers EN, Beery QC, Bluestone CD, Rood SR, Sigler BA. Effect of certain head and neck tumors and their management on the ventilatory function of the eustachian tube. *Ann Otol Rhinol Laryngol Suppl*. 1984 Nov-Dec; 114:3-16.
- Pacholke HD, Amdur RJ, Schmalfuss IM, Louis D, Mendenhall WM. Contouring the middle and inner ear on radiotherapy planning scans. *Am J Clin Oncol*. 2005 Apr; 28(2): 143-47.
- Pow EH, Kwong DL, McMillan AS, Wong MC, Sham JS, Leung LH, Leung WK. Xerostomia and quality of life after intensity-modulated radiotherapy vs. conventional radiotherapy for early-stage nasopharyngeal carcinoma: initial report on a randomized controlled clinical trial. *Int J Radiat Oncol Biol Phys*. 2006 Nov; 66(4): 981-91.
- Pringle MB, Jefferis AF, Barrett GS. Sensorineural hearing loss caused by metastatic prostatic carcinoma: a case report. *J Laryngol Otol*. 1993 Oct; 107(10):933-4.
- Proud GO, Odoi H, Toledo PS. Bullar pressure changes in eustachian tube dysfunction. *Ann Otol Rhinol Laryngol*. 1971 Dec; 80(6):835-7.
- Raaijmakers E, Engelen AM. Is sensorineural hearing loss a possible side effect of nasopharyngeal and parotid irradiation? A systematic review of the literature. *Radiother Oncol*. 2002 Oct; 65(1): 1-7.
- Ralston A, Stevens G, Mahomudally E, Ibrahim I, Leckie E. Cochlear implants: response to therapeutic irradiation. *Int. J Radiat Oncol Biol Phys* 1999 Apr; 44(1):227-31.
- Ramsden RT. Acoustic neuroma. In: Booth JB, Kerr AG. *Scotts-Brown otolaryngology: otology*, 5th ed. London: Butterworth, 1987; 500-33
- Ramsden RT, Bulman CH, Lorigan BP. Osteoradionecrosis of the temporal bone. *J Laryngol Otol*. 1975 Sep; 89:941-55.
- Rudge FW. Osteoradionecrosis of the temporal bone: Treatment with hyperbaric oxygen therapy. *Mil Med*. 1993 Mar; 158(3):196-8.
- Rybak L. P, Whitworth C. A. Ototoxicity:therapeutic opportunities. *Drug Discov Today*; 2005 Oct; 10(9):1313-21.
- Sadé J. The nasopharynx, Eustachian tube and otitis media. *J Laryngol Otol*. 1994 Feb; 108: 95-100.
- Sadé J, Luntz M. Gas diffusions in the middle ear. *Acta Otolaryngologica (Stockholm)*; 1991; 111(2): 354-57.
- Schell M, McHaney VA, Green AA, Kun LE, Hayes FA, Horowitz M, Meyer WH. Hearing loss in children and young adults receiving cisplatin with and without prior cranial irradiation. *J Clin Oncol*. 1989 Jun; 7(6):754-60.
- Schuknecht HF, Karmody CS. Radionecrosis of the temporal bone. *Laryngoscope*; 1966 Aug; 76(8):1416-28.



- Seidman MD, Vivek P. Intratympanic treatment of hearing loss with novel and traditional agents. *Otolaryngol Clin North Am*. 2004 Oct; 37(5): 973-90.
- Sha SH, Taylor R, Forge A, Schacht J. Differential vulnerability of basal and apical hair cell is based on intrinsic susceptibility to free radicals. *Hear Res*. 2001 May; 155(1-2):1-8.
- Sham, JSI, Weis I, Lau SK, Yau CC, Choy D. Serous otitis media and paranasopharyngeal extension of nasopharyngeal carcinoma. *Head and Neck*. 1992 Jan-Feb; 14(1): 19-23.
- Shibahara Y, Sando I. Congenital anomalies of the Eustachian tube in Down Syndrome. Histopathologic case report. *Ann Otol Rhinol Laryngol*. 1989Jul; 98: 543-7.
- Shinomiya N. New concepts in radiation-induced apoptosis: 'premitotic apoptosis' and 'postmitotic apoptosis'. *J Cell Mol Med*. 2001 Jul-Sep; 5(3):240-53.
- Singapore Cancer Registry Interim Report 2001-2005
- Singh IP, Slevin NJ. Late audio-vestibular consequences of radical radiotherapy to the parotid. *Clin Oncol*. 1991 Jul; 3 (4):217-19.
- Skinner DW, van Hasselt CA. A study of the complications of grommet insertion for secretory otitis media in the presence of nasopharyngeal carcinoma. *Clin Otolaryngol Allied Sci*. 1991 Oct; 16(5):480-82
- Skinner DW, van Hasselt CA, Tsao SY. Nasopharyngeal carcinoma: modes of presentation. *Ann Otol Rhinol Laryngol*. 1991 Jul; 100(7): 544-51
- Skinner R, Pearson ADJ, Amineddine HA, Mathias DB, Craft AW. Ototoxicity of cisplatin in children and adolescent. *Br J Cancer*. 1990 Jun; 61(6):927-31.
- Soo G, Tong MC, Tsang WS, Wong TK, To KF, Leung SF, van Hasselt CA. The BAHA hearing system for hearing-impaired post-irradiated nasopharyngeal cancer patients: a new indication. *Otol Neurotol*. 2009 Jun; 30(4):496-501.
- Su CY, Hsu SP, Lui CC. Computed tomography, magnetic resonance imaging and electromyographic studies of tensor veli palatini muscles in patients with nasopharyngeal carcinoma. *Laryngoscope*; 1993 Jun; 103(6): 673-78.
- Sweetow RW, Will TI . Progression of hearing loss following the completion of chemotherapy and radiation therapy: case report. *J Am Acad Audiol*. 1993 Nov; 4:360-63.
- Takahara T, Sando I, Bluestone CD, Myers EM. Lymphoma invading the anterior Eustachian tube. Temporal bone histopathology of functional tubal obstruction. *Ann Otol Rhinol Laryngol*. 1986 Jan-Feb; 95: 101-105.
- Thornley GD, Gullane PJ, Ruby RR, Heeneman H. Osteoradionecrosis of the temporal bone. *J Otolaryngol*. 1979 Oct; 8 (5):396-400.
- van Hasselt AC, Gibb AG. *Nasopharyngeal Carcinoma*, Chinese University Press, Hong Kong, 1991; 105-44.
- van Hasselt, A, Woo JKS. *Nasopharyngeal carcinoma*. Scott Brown's otorhinolaryngology and head and neck surgery, 7<sup>th</sup> ed., 2008; vol-2: ch188: 2445-74..
- Verheij M, Bartelink H. Radiation-induced apoptosis. *Cell Tissue Res* 2000 Jul; 301 (1):133-42.
- Walker DA, Pillow J, Waters KD, et al. Enhanced Cis-platinum ototoxicity in children with brain tumours who have received simultaneous or prior cranial irradiation. *Med Pedia Oncol*. 1989; 17:48-52.
- Wanamaker JR, Kraus DH, Biscotti CV, Eliachar I. Undifferentiated nasopharyngeal carcinoma presenting as a parotid mass. *Head Neck*. 1994 Nov-Dec; 16(6):589-93.
- Wang X, Hu C, Eisbruch A. Organ-sparing radiation therapy for head and neck cancer. *Nat Rev Clin Oncol*. 2011 Jul 26. doi: 10.1038/nrclinonc.2011;106.

- Wei WL., Lund VJ, Howard, DJ. Serious otitis media in malignancies of the nasopharynx and maxilla. *Journal of Laryngol and Otol.* 1988 Feb; 102(2): 129-32.
- Young, YH, Hsieh T. Eustachian tube dysfunction in patients with nasopharyngeal carcinoma, pre- and post- irradiation. *Eur Arch Otorhinolaryngol.* 1992; 249 (4): 206-08.
- Young YH, Lin CY, Lou PJ, Hsu MM. Intracranial relapse of nasopharyngeal carcinoma manifested as sudden deafness. *Otol Neurotol.* 2001;22:392-96.
- Yuen PW, Wei WI. Tympanomastoidectomy for chronic suppurative otitis media of irradiated ears of nasopharyngeal carcinoma patients. *J Otolaryngol.* 1994 Aug; 23(4):302-04.
- Yuh WTC, Mayr-Yuh NA, Koci TM, Simon JH, Nelson KL, Zyroff J, Jinkins JR. Metastatic lesions involving the cerebellopontine angle. *AJNR Am J Neuroradiol.* 1993 Jan-Feb; 14(1):99-106.
- Zhou Y, Tang A, Li J, Chen P, Mao R. The damaged types of eustachian tube function in the patients of nasopharyngeal carcinoma after radiotherapy. *Lin Chuang Er Bi Yan Hou Ke Za Zhi.* 2003 Aug; 17(8):464-65.

IntechOpen



## **Carcinogenesis, Diagnosis, and Molecular Targeted Treatment for Nasopharyngeal Carcinoma**

Edited by Dr. Shih-Shun Chen

ISBN 978-953-307-867-0

Hard cover, 246 pages

**Publisher** InTech

**Published online** 15, February, 2012

**Published in print edition** February, 2012

This book is a comprehensive treatise of the potential risk factors associated with NPC development, the tools employed in the diagnosis and detection of NPC, the concepts behind NPC patients who develop neuro-endocrine abnormalities and ear-related complications after radiotherapy and chemotherapy, the molecular mechanisms leading to NPC carcinogenesis, and the potential therapeutic molecular targets for NPC.

### **How to reference**

In order to correctly reference this scholarly work, feel free to copy and paste the following:

Wong–Kein Christopher Low and Mahalakshmi Rangabashyam (2012). Ear-Related Issues in Patients with Nasopharyngeal Carcinoma, Carcinogenesis, Diagnosis, and Molecular Targeted Treatment for Nasopharyngeal Carcinoma, Dr. Shih-Shun Chen (Ed.), ISBN: 978-953-307-867-0, InTech, Available from: <http://www.intechopen.com/books/carcinogenesis-diagnosis-and-molecular-targeted-treatment-for-nasopharyngeal-carcinoma/ear-related-issues-in-patients-with-nasopharyngeal-carcinoma>

**INTECH**  
open science | open minds

### **InTech Europe**

University Campus STeP Ri  
Slavka Krautzeka 83/A  
51000 Rijeka, Croatia  
Phone: +385 (51) 770 447  
Fax: +385 (51) 686 166  
[www.intechopen.com](http://www.intechopen.com)

### **InTech China**

Unit 405, Office Block, Hotel Equatorial Shanghai  
No.65, Yan An Road (West), Shanghai, 200040, China  
中国上海市延安西路65号上海国际贵都大饭店办公楼405单元  
Phone: +86-21-62489820  
Fax: +86-21-62489821

© 2012 The Author(s). Licensee IntechOpen. This is an open access article distributed under the terms of the [Creative Commons Attribution 3.0 License](https://creativecommons.org/licenses/by/3.0/), which permits unrestricted use, distribution, and reproduction in any medium, provided the original work is properly cited.

IntechOpen

IntechOpen