

We are IntechOpen, the world's leading publisher of Open Access books Built by scientists, for scientists

6,900

Open access books available

186,000

International authors and editors

200M

Downloads

Our authors are among the

154

Countries delivered to

TOP 1%

most cited scientists

12.2%

Contributors from top 500 universities



WEB OF SCIENCE™

Selection of our books indexed in the Book Citation Index
in Web of Science™ Core Collection (BKCI)

Interested in publishing with us?
Contact book.department@intechopen.com

Numbers displayed above are based on latest data collected.
For more information visit www.intechopen.com



Ischemic Type Biliary Lesions

Dennis Eurich, Daniel Seehofer and Peter Neuhaus
*Charité Campus Virchow / General, Visceral and Transplant Surgery / Berlin,
 Germany*

1. Introduction

Liver transplantation (LT) is an established therapy for end-stage liver disease based on a substantial progress in surgical and immunological management of concomitant post-transplant phenomena. Apart from rejection and HCV-recurrence, the development of biliary strictures is one of the most serious complications observed after LT significantly affecting graft and patient survival [1, 2]. Frequently compared to Achilles foot, the dynamics of post-transplant biliary restitution may determine the overall transplant success and play the role of a critical step after LT. Post-transplant complications in the biliary system occur in 10-50% with significant mortality in up to 19% and re-transplantation rates of 6-12.5% [3-6]. Early post-transplant biliary complications are predominantly related to technical aspects of the operation regarding the insufficiency of bile duct anastomosis, biliary leaks or anastomotic stenosis [7]. One third of all biliary complications occur later than first two months after LT affecting intrahepatic integrity on donor side and functionality of distal parts of the biliary tree in the recipient including the bile duct anastomosis and the ampulla of Vater [1, 2, 8]. In contrast to the anastomotic strictures, which can be successfully treated endoscopically or surgically, non-anastomotic strictures represent a significant therapeutic problem [9, 10]. Non-anastomotic strictures of the bile duct may develop in up to 20% of all LTs. Untreated stricture-associated complications may lead to cholestasis, severe graft dysfunction, cholangiosepsis, secondary cirrhosis and even death [6, 8, 11, 12]. Non-anastomotic strictures may be classified according to their etiology into strictures related to PSC-recurrence (primary sclerosing cholangitis), strictures occurring due to vascular complications in case of a manifest hepatic artery thrombosis as ischemic biliary lesions (IBL), strictures occurring after prolonged ischemia (e.g. successfully treated hepatic artery thrombosis) and strictures occurring without an obvious vascular complication. In the presence of a macroscopically obviously undisturbed perfusion they are described as so-called ischemic type biliary lesions (ITBL). The occurrence of biliary lesions after primarily successful LT justifies the necessity to introduce ITBL as an independent pathologic entity. In spite of a certain descriptive inaccuracy, the terms “non-anastomotic strictures”, “intrahepatic biliary strictures” and “ischemic type biliary strictures” are usually used as synonyms for post-transplant strictures, diffuse dilatations and segmental ectasia of the biliary tract as a result of inflammation and fibrotic remodeling (figs. 1 and 2) [13]. Due to terminological diversity, the incidence of ITBL significantly varies among published studies between 1.4 and 26% [1, 5, 14]. The diagnosis “ITBL” may be made only after the exclusion of vascular (IBL) and immunologic pathologies (PSC-recurrence and chronic

ductopenic rejection) [1]. As a diagnosis of exclusion, ITBL is regarded as a serious transplant complication and a notable graft disease, undeniably deserving scientific attention.

1.1 Anatomical aspects of the biliary tract

Biliary tract is a complex network of ductal structures beginning with Hering-canal, merging into major ducts and finally into intestine in a highly coordinated manner [15, 16]. Apart from conductive functions, the biliary epithelium demonstrates morphological heterogeneity, which depends upon functional requirements [17]. The ability to undergo phenotypic changes, to participate in inflammatory processes and even to behave as liver progenitor cells underlines the uniqueness of cholangiocytes under physiological conditions [15, 18]. In contrast to parenchymal blood supply of liver sinusoids via portal vein and hepatic artery, biliary tree predominantly depends on the integrity of the hepatic artery and periductal plexus being more vulnerable to transplant-related disrupted blood supply and immunologic processes justifying the metaphoric comparison to Achilles foot [19, 20].

1.2 Biliary tract reconstruction

One of the most important surgical steps and goals during LT is the reconstruction of the biliary tract and the restitution of its function. The most widely employed reconstructive techniques are choledocho-choledochostomy (with or without T-tube) performed in patients with uncomplicated anatomy and intact distal segment of the biliary tract including functioning sphincter Oddi and Roux-en-Y hepatico-jejunostomy, which is usually reserved for cases with intrinsic damage to the biliary system (e.g. PSC) and technically difficult anastomosis (e.g. re-transplantation, living donor LT) [6, 21, 22]. Underlying liver disease, size of biliary tracts of the donor and the recipient, anatomic aspects, prior surgery on the biliary duct and surgeon preference may influence the choice of the reconstructive technique [23].

2. Non-anastomotic strictures: Morphology

Chronic disturbance of bile flow, accompanied by inflammatory processes, may lead to the development of irregular strictures, dilatations and sequestrations of the biliary tree (figs 1 and 2). Bacterial ascension, causing cholangitis, cholangiohepatitis and cholangiosepsis, may forward the progression of ITBL. Macroscopically, ITBL is classified according to the localization of pathological alterations in three groups (type-I: extrahepatic; type-II: intrahepatic; type-III: intra- and extrahepatic), which may determine the severity of the disease, its course and therapeutic options. Inflammation and remodeling represent the functional backbone of ITBL-development. Presence of intracellular cholestasis, abundance of lymphocytes and granulocytes and proliferation of new bile ducts represent the microscopic picture of ITBL, hardly differing from biliary pathologies with unrelated etiologies [24]. Remodeling processes result in the formation of connective tissue. Degree, localization and duration of inflammation determine the extent of the disease. Resulting in a “scar” and the perpetuation of bile flow obstruction, inflammation and progression of biliary damage may promote secondary alterations and forward extensive fibrogenesis and tissue remodelling of the graft parenchyma [25]. Finally, graft atrophy and the reduction of functional reserve may develop, compromising the result of an initially successful LT.

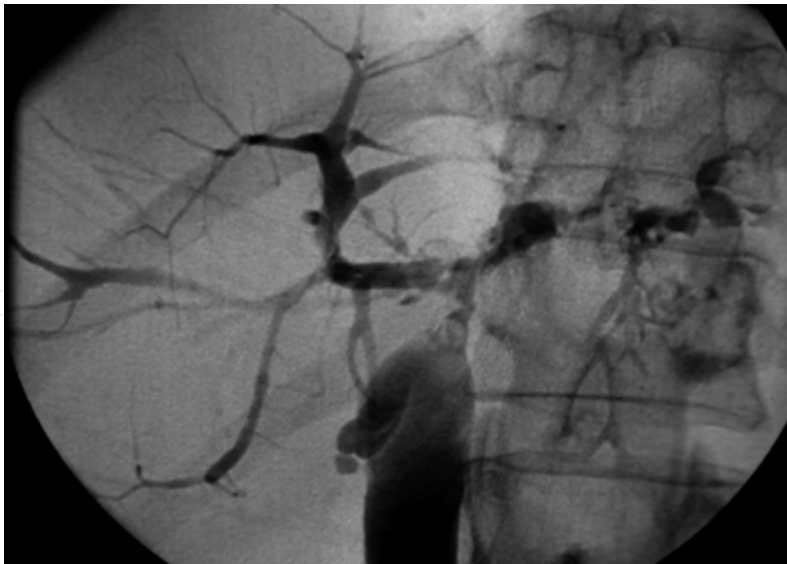


Fig. 1. Cholangiograph. Illustration of central stenosis at the level of distal right and left ductus hepatici, diffuse biliary strictures and dilatations in the left lobe, cholestasis in the right lobe. ITBL developed within the first post-transplant year

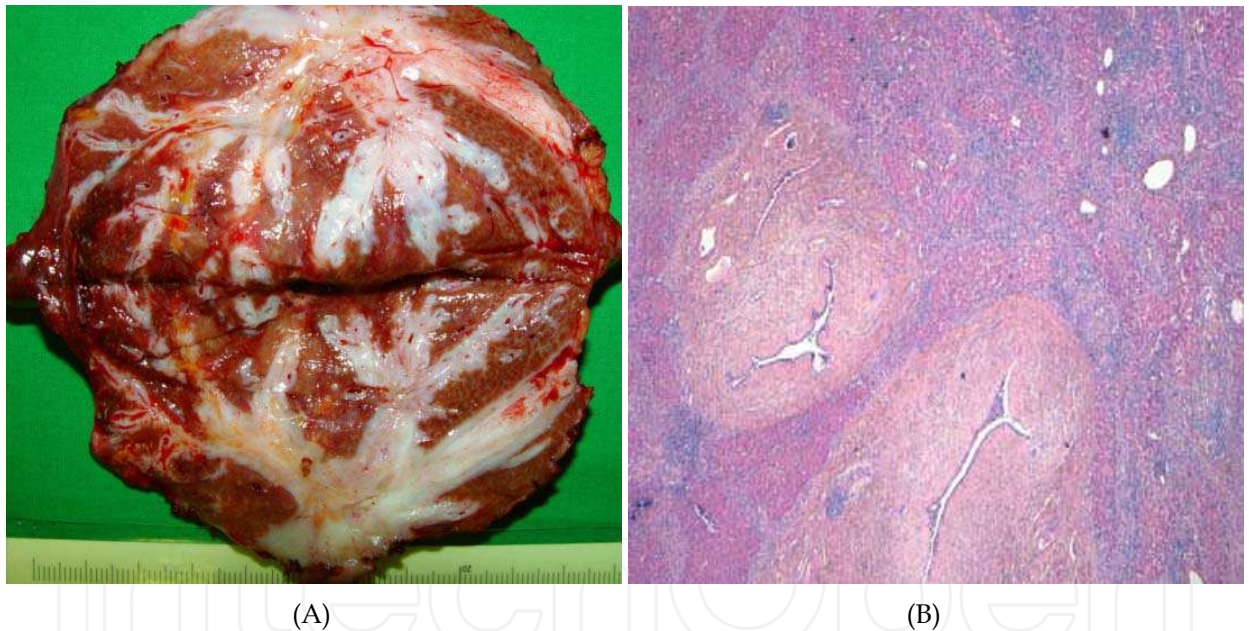


Fig. 2. (A) Resected graft with ITBL (left liver lobe). Macroscopically evident atrophy of liver parenchyma with broad peribiliary shroud of connective tissue (B) Microscopic view of the same graft depicting a profound periductular inflammation (lymphocytes, granulocytes), connective tissue and remaining islets of liver parenchyma

Significant morphological similarities are observed in a non-transplant setting as well: in patients with HIV-associated cholangiopathy as vanishing bile duct-syndrome, sclerosing cholangitis and shock-liver [1, 26]. In summary, chronic inflammation caused by any noxious effectors may lead to the uniform picture described above. Frequently, significant difficulties arise in the attempt of differentiation between recurrent PSC and ITBL in the graft. Morphologically these entities may present identical pictures [1].

Variables		
Donor	Age (years)	older than 60
	Size	small-for-size
	LT-mode	living donor
Stage of liver disease	Child & Pugh	C > A or B
Surgery	Solution	UW > HTK
	Perfusion mode	retrograde caval
		gravity arterial perfusion
	Periductal tissue	little
	Reconstructive technique	hepatico-jejunostomy
Ischemic factors	Cold and warm ischemia	prolonged
	Reperfusion injury	not assessable
	Periductal plexus	altered
	Re-arterialization	present
Cholangial pressure & bile toxicity	External bile drainage	no T-tube
	Bile acids	high bile-to-phospholipid ratio
Immunologic factors	ABO-system	incompatible
	Immunosuppression	Low level
	Rejection	chronic / ductopenic
	Autoimmune disease	PSC, PBC, AIH
	Co-infection	CMV
	Genetic variants	CCRdelta32, Mdr-2

Table 1. Suspected risk factors for the development of ITBL

3. Pathophysiology

The process of ITBL-development is not clearly understood yet. ITBL seems to be a polygenic disease, influenced by a whole variety of confounders. Currently identified risk factors may be divided into four major pathogenetic columns: peri-operative ischemia (including preserving solution), immunologic damage, toxicity of bile salts and

epidemiological confounders [1, 27]. The degree and relation of the functional impact among risk factors are not fully investigated. Hereby, ischemic injury seems to be the most important factor including cold and warm ischemia during transplantation, disturbed blood flow in the peribiliary plexus resulting from an inappropriate procurement of the donor liver with little periductal tissue, and hypoxemia during the postoperative period [12, 27]. Immunological injury including ABO-incompatibility, rejection, pre-existing liver disease with autoimmune component, CMV-Infection, immunosuppressive medication and chronic rejection also seem to play a role in the development of the non-anastomotic strictures [1, 27, 28]. Moreover, bile fluid has been shown to be toxic for the vulnerable biliary epithelium of the graft [29]. Although biliary strictures have been reported to be more frequent in transplant patients with hepatico-jejunostomy, they may occur, disregarding the type of biliary tract reconstruction [6, 30]. Finally, factors related to epidemiology (older donor age, advanced stage of pre-transplant liver disease) and donation (preservation solution, perfusion technique) also seem to be relevant in the pathogenesis of ITBL [1, 27, 31]. Table 1 summarizes currently known risk factors.

4. Diagnostics

The diagnosis of non-anastomotic lesions or ITBL is made by clinical presentation, exclusion of evident vascular complications, histological pattern and cholangiography as gold standard either by ERC (endoscopic retrograde cholangiography) or by PTC (percutaneous transhepatic cholangiography) [1, 2, 32]. Increased expertise in diagnostic and therapeutic ERC in transplant-related liver diseases has been demonstrated to be a safe and effective tool. Therefore ERC has been suggested to be the primary method for diagnosis and treatment of most transplant-related biliary complications except for acute surgical complications (broad insufficiency of biliary duct anastomosis) [33]. The diagnosis "ITBL" is made when typical signs of segmental strictures and dilatations appear on the cholangiography (fig. 1, 3, 4).

4.1 Clinical aspects

Characteristic and disease-specific aspects of clinical presentation do not exist. Symptoms reflect cholestasis and subsequent infective tendency ranging from unspecific discomfort in the right abdomen, elevated temperatures, shivering and jaundice. Clinical presentation of ITBL-patients may cover the whole range of complaints and symptoms originating from the biliary tract. Classical symptoms are pruritus, jaundice and fever. Untreated ITBL may lead to cholangiosepsis, graft insufficiency and patient death [27]. Clinically, ITBL closely resembles liver diseases with chronic inflammation of the biliary tract (PSC, SSC, cholangitis) [1].

4.2 Laboratory

Although laboratory parameters are frequently normal or only slightly elevated, alkaline phosphatase (AP), gamma glutamyltransferase (γ -GT) and bilirubin may indicate pathological processes in the biliary tree. Biochemical results do not reliably reflect early stages of the disease and easily be misinterpreted as normal or acceptable in the post-transplant setting. Highly sensitive but not disease-specific, laboratory parameters are,

nevertheless, helpful as a non-invasive tool and their deviation is frequently the first sign perceived in the outpatient setting of most follow-up programs. Cholestatic profile with leukocytosis usually indicates complicated biliary pathology. Clinical symptoms and pathological laboratory findings may necessitate hospitalization and the initiation of further diagnostic procedures [32].

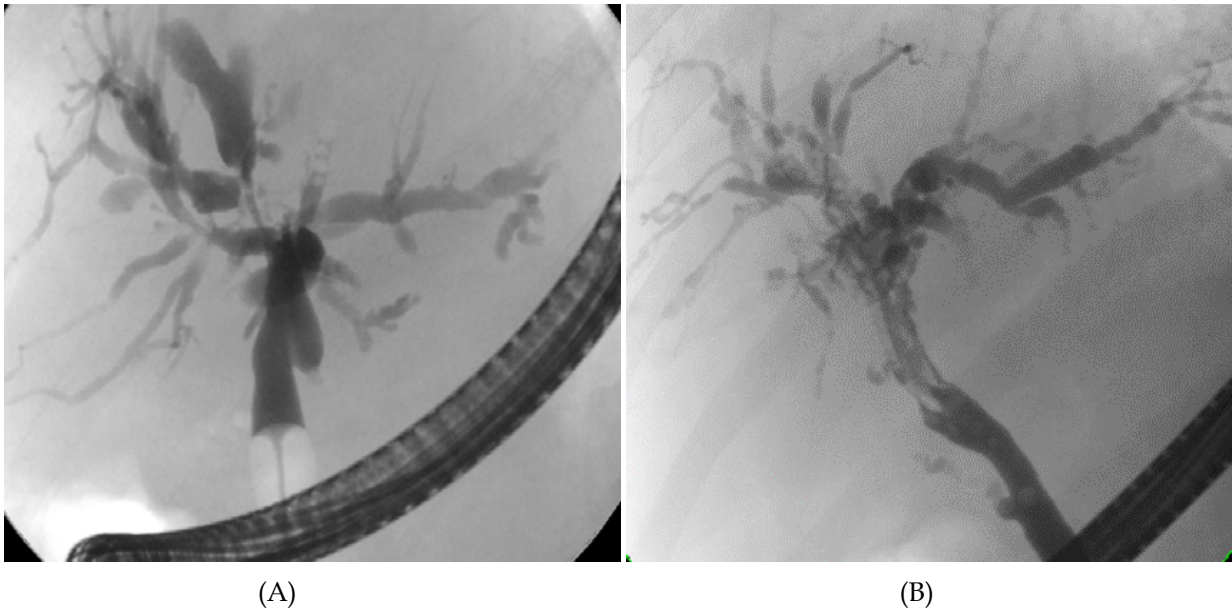


Fig. 3. (A) Cholangiograph (ERC): Illustration of central stenosis at the level of distal right and left ductus hepatici, diffuse biliary strictures and dilatations in the left lobe and cholestasis in the right lobe. (B) Cholangiograph (ERC): Diffuse strictures and dilatations nearly in the entire biliary tree

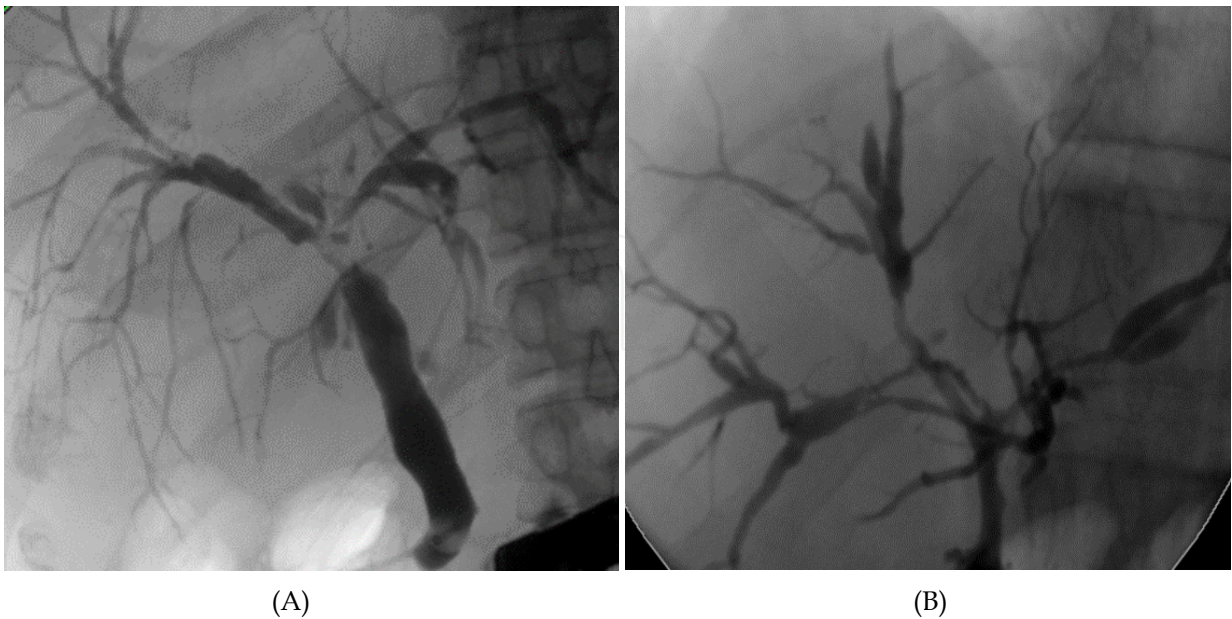


Fig. 4. (A) Cholangiograph (ERC): Central stenosis and proximal cholestasis in both graft lobes (B) Cholangiograph (ERC): Relevant strictures close to the biliary bifurcation with dilatations in both graft lobes

4.3 Radiology

Radiological examination is the most important column in ITBL-diagnostics comprising conventional X-ray performed during ERC or PTC and indirect imaging methods: ultrasound, computer tomography (CT) and magnetic resonance cholangiography (MRC).

4.3.1 Ultrasound

As a safe and easily accessible tool, ultrasound examination including Doppler-mode is definitely helpful and routinely performed to rule out vascular causes for biliary dysfunction. In contrast to early changes, advanced stages of ITBL may well be assessed by ultrasound, revealing dilatations, stenosis and sediment, which predispose to the development of secondary complications regarding infection and disease progression. However, morphologic differences between naive liver and graft must be considered. Due to a higher stiffness of the graft, dilatations caused by strictures tend to appear more slowly and less distinctly in the affected biliary tract and may remain invisible or mistaken for normal conditions on a routine ultrasound examination.

4.3.2 Conventional cholangiography

Cholangiography is usually performed by ERC as the method of choice, if technically possible in the absence of contra-indications [9, 32]. Based on the classical endoscopic examination of the upper digestive tract, the goal of ERC is the visualization of the biliary tract by a selective instillation of contrast agent through the sphincter Oddi (fig. 3, 4). As a rather invasive diagnostic method, ERC should be performed with maximal accuracy, in order to avoid frequently observed pancreatitis, which is a potentially severe iatrogenic complication [34]. In contrast to the usually easily assessable biliary tract, if reconstructed as standard choledochostomy, endoscopic cholangiography is impossible with the majority of patients with hepatico-jejunostomy [32]. Occasionally, ERC may be feasible in patients with short efferent loops of hepatico-jejunal anastomosis if examined by experienced endoscopists. In most cases, cholangiography must be performed percutaneously as transhepatic puncture and instillation of contrast fluid in the biliary system (fig. 6) [2, 35]. Elevated pressure and subsequent dilatation of the biliary tract may facilitate the examination. In spite of high effectiveness, transhepatic puncture may cause graft damage, bleeding and injury of adjacent abdominal organs. Therefore, maximal accuracy and caution are required when applying this method. Simultaneous diagnostic and therapeutic options are the major advantages of conventional cholangiography (ERC or PTC).

4.3.3 Computer tomography (CT)

CT-scan may accurately visualize graft perfusion using contrast agent and biliary pathology regarding the localization, structural changes and secondary complications (abscess, atrophy). In spite of frequent incapability to detect short segment stenosis without pre-stenotic dilatations, full-blown ITBL can easily be diagnosed by this method [32, 36]. In general, CT is considered to be a reliable diagnostic tool.

4.3.4 Magnetic resonance cholangiography (MRC)

MRC is a reliable noninvasive technique to visualize the biliary anastomosis and depict biliary strictures after LT (fig. 5) [37]. MR-cholangiography has been shown to be an accurate imaging technique to non-invasively detect biliary complications in patients especially in patients with bilio-enteric anastomosis with high positive and negative predictive values [32, 38]. However, no direct therapeutical options are available during this procedure. Non-invasiveness and significant risk reduction for side events are major advantages of MRC. Further progress in MRC-processing may increase the potential to complement or even replace conventional cholangiographic methods [32].

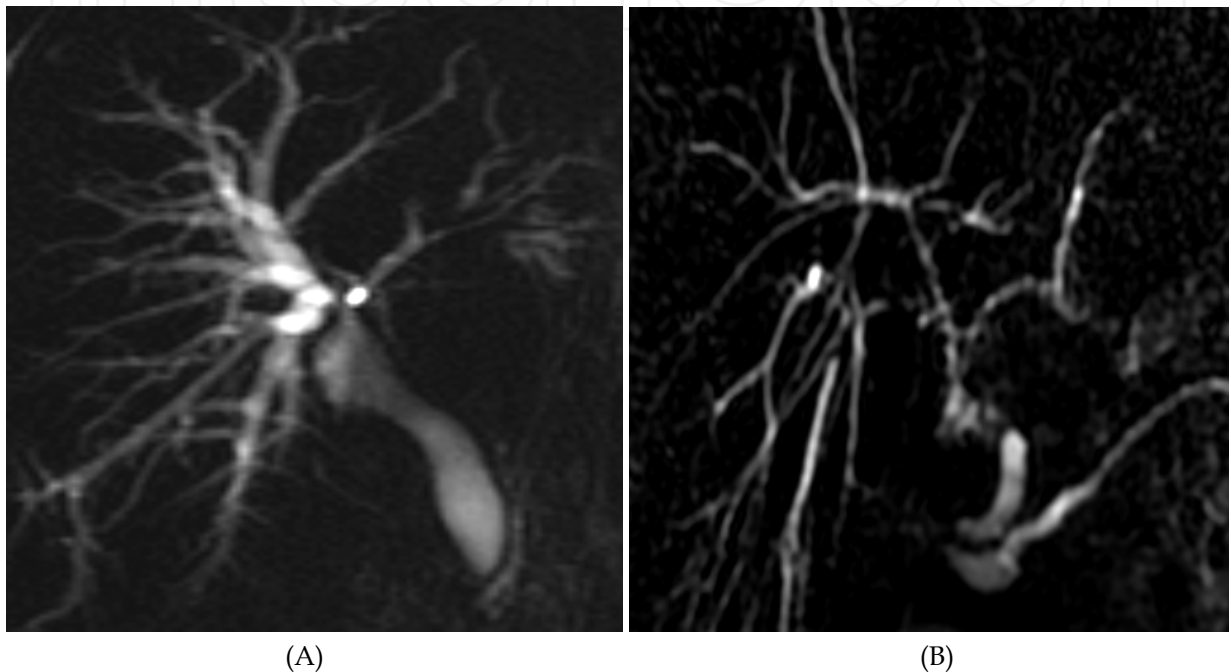


Fig. 5. (A) Cholangiograph (MRC): Central strictures and proximal diffuse dilatation (B) Cholangiograph (MRC): Diffuse strictures and dilatations of the entire biliary tract

5. Therapy

Early identification of high risk patients for ITBL-occurrence may help to initiate necessary therapeutical steps and possibly prevent disease progression. The goal of ITBL-treatment implies the reduction of morbidity and mortality among the diseased transplant population. Previously, surgery including re-transplantation of the diseased liver had been thought to be the leading therapeutical option for ITBL-patients [39]. Modern ITBL-treatment strategy comprises a multimodal approach and an excellent cooperation between departments of radiology, endoscopy and surgery (fig. 6) [2, 10, 25]. In most cases the treatment of strictures is performed conservatively by endoscopic or transhepatic dilatation [24, 33, 40]. Supportive measures should comprise antibiotic prophylaxis and treatment with ursodesoxycholic acid [2].

5.1 Endoscopic and transhepatic treatment

Most of the ITBL-patients are currently treated by the endoscopic or percutaneous placement of stents and balloon dilatation [32, 33, 40]. However, significantly different

success rates are observed depending upon the localization and occurrence of the strictures. Anastomotic strictures are usually easier to treat than intrahepatic lesions. Early non-anastomotic strictures demonstrate higher success rates than strictures appearing later than three months after LT [41-43]. Endoscopic and transhepatic treatment options are limited in patients with impaired liver function similarly to the diagnostic procedure. Complication rates (bleeding, pancreatitis) are reported to be 3.4% for PTC and up to 7% for endoscopic treatment [44].

5.2 Surgery

Surgical intervention may still be required in patients who do not respond to dilatative treatment or in patients with circumscribed localization of the strictures either in the extrahepatic biliary tree or resectable graft lobe [2, 33, 39]. Endoscopic or radiological dilatation of strictures has been shown to be ineffective in some patients, who may profit from surgical treatment [10]. Therefore, reconstructive surgical approach should be reserved to ITBL patients not responsive to endoscopic or trans-hepatic interventions [2].

5.2.1 Resection

Sufficient evidence exists about beneficial effects of partial graft resection, resection of biliary bifurcation and performance of hepatico-jejunostomy in liver transplant recipients with anatomically limited biliary damage, thus avoiding re-transplantation and preserving scarce donor organs [25, 45, 46]. In spite of higher vulnerability of the graft and a certain reluctance, graft resection in ITBL-patients with a sufficient graft function is possible and comparable to common liver surgery.

5.2.2 Re-transplantation

In spite of encouraging progress in interventional non-surgical ITBL-treatment, and achievements in graft resection, up to 50% of patients with non-anastomotic strictures still require re-transplantation of the liver [30, 43, 47, 48]. Re-transplantation of the liver is supposed to be the definitive therapy of graft damage being the last resort of therapeutical options. Unfortunately, survival rates after re-transplantation are significantly lower than after first LT. In technically more complicated re-transplant setting, cold ischemia and MELD-score have been shown to be associated with higher mortality rates [49]. Prevention of re-transplantation should be aspired as the goal of ITBL-treatment, especially in the era of organ shortage.

In summary, ITBL-treatment may require an unpredictable amount of patience regarding the strategy, performance and follow-up. Exemplarily, more than two dozens of dilatative interventions and one graft resection (left hemihepatectomy) have been reported in one case of successful ITBL-treatment, preventing re-transplantation of the liver (fig. 6) [25].

6. Prevention

The principle of ITBL-prevention focuses on the major pathogenic factors mentioned above and should be considered in the peri-operative period as far as possible. Hereby, allocation, preservation, reduction of ischemia, reconstructive techniques and adequate immunosuppression seem to be very important. Once, immunological effects were claimed

to cause spasms in hepatic arteries, resulting in hypoxemia of the bile duct system [50]. Currently, the mechanism of the disease is considered to be multifactorial. Immunological injury including ABO-incompatibility, rejection, pre-existing disease with autoimmune component, CMV-Infection and chronic rejection also seem to play a role in the development of the non-anastomotic strictures [12, 47]. Finally the toxicity of the bile fluid has been shown to be relevant in the pathogenesis of ITBL [51]. In summary, the development of ITBL is influenced by a whole range of donor, recipient, technical and immunological factors.

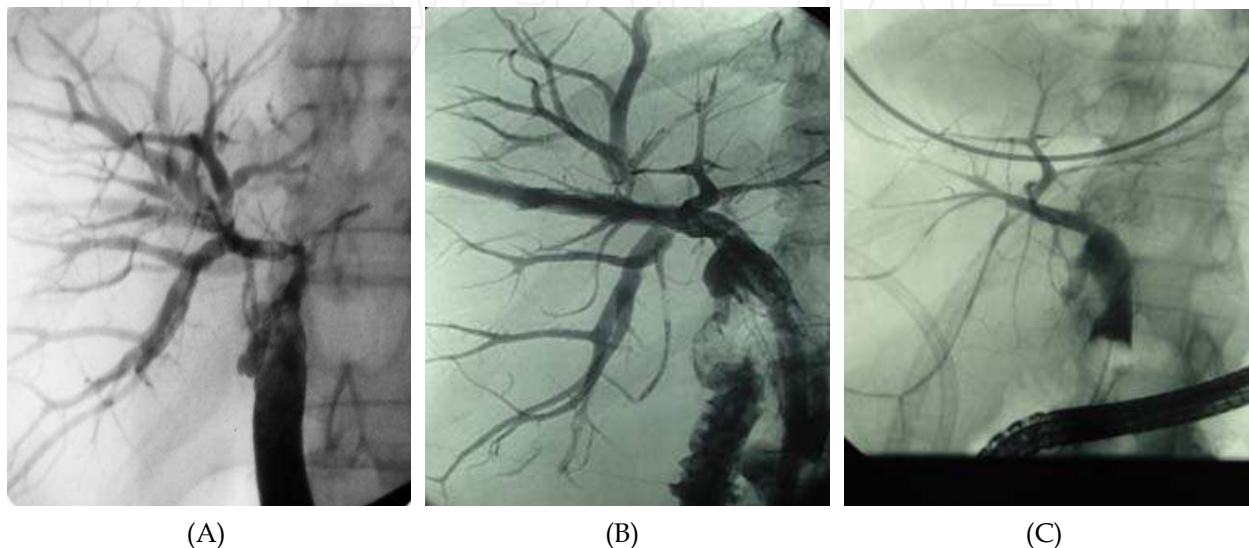


Fig. 6. (A) ERC after left hemihepatectomy in a patient with ITBL after LT for HCV-induced cirrhosis demonstrating a significant stenosis of the right hepatic duct and proximal dilations (B) PTC via Yamakawa-drain of the same patient during the dilatative treatment (C) ERC after the completion of treatment depicting acceptable conditions in the right biliary tree

6.1 Ischemic time

Several studies have demonstrated a significant correlation of ITBL-incidence with ischemic time before reperfusion. In spite of controversial discussion, cold ischemic time especially of more than 10 hours may affect the development of ITBL [1, 12, 52]. Analogously, re oxygenation and warm ischemia time also seem to be involved in the pathogenesis of the disease [27, 53]. Moreover, delayed re-arterialization of the graft may favor the occurrence of ITBL [2, 43, 54]. Therefore, the time period between explantation and reperfusion should be as short as possible under an adequate preserving temperature.

6.2 Epidemiologic aspects

The use of donor organs particularly older than 60 years is associated with ITBL [1, 31]. Furthermore, patients with advanced liver disease before transplantation seem to be more likely to develop ITBL compared to lower Child and Pugh-stages [1]. Deteriorated pre-operative status, early biliary complications and “small-for-size” transplantation are currently suspected to contribute to the occurrence and progression of ITBL [55]. Further potential confounders regarding the recipient (age, gender) do not seem to play a significant role in the pathogenesis of ITBL [1]. Interestingly, the incidence of ITBL seems to be higher

in patients undergoing living-donor-liver-transplantation of the right lobe [14, 56]. A differentiated selection of donor and recipient simply based on epidemiological data might help to avoid the accumulation of predisposing factors.

6.3 Reconstructive technique

In spite of ischemia reduction in LDLT-recipients, the increased susceptibility may be explained by the difference of biliary reconstruction, which is performed as hepatico-jejunostomy compared choledocho-choledochostomy in patients receiving whole organs. Bacterial ascension leading to cholangitis may negate the expected advantage of reduced cold ischemia time [55, 57]. Thus, the main advantages of choledocho-choledochostomy comprise the integrity of anatomic barrier regarding the reflux of intestinal flora to a great extent, better technical feasibility than Roux-en-Y and physiological condition for an endoscopic access [35, 58]. Choledocho-choledochostomy in side-to-side-technique seems to be the most reliable reconstructive method [22, 59]. Particular attention should be paid to periductal tissue. The integrity of the periductal vascular plexus must be guaranteed.

6.4 Preservation and perfusion

Among the two commonly used preservation solutions, the UW-solution (University of Wisconsin) has been shown to increase the risk of ITBL-occurrence compared to the less viscous HTK-solution [1, 60, 61]. Furthermore, retrograde graft perfusion via vena cava seems to exhibit a negative effect on the development of ITBL, whereas, additional back-table arterial graft perfusion lowers the risk of ITBL [1, 62]. Regular gravity arterial perfusion has been suspected to be insufficient to flush the arterial system of the biliary tract completely [1]. All inflammatory active and potential fibrogenic blood compounds should be removed before transplantation. Therefore, additional arterial pressure perfusion preferably with a HTK-solution should be performed [1].

6.5 Toxicity of the bile

Bile acids may exhibit their toxic potential on vulnerable cholangiacellular epithelium and therefore, be relevant in the pathogenesis of ITBL. In contrast to hydrophilic bile salts, hydrophobic compounds are cytotoxic [29, 63]. Prolonged warm ischemia is associated with the formation of an unfavorable bile salt-to-phospholipid ratio subsequently contributing to bile duct injury [51]. The exposure of biliary epithelium to toxic bile compounds can be minimized by the careful retrograde flushing of the bile duct with perfusion solution during liver explantation, strictly avoiding bile duct ligation [27].

6.6 Genetic aspects

Highly variable rates of functional impairment suggest the existence of endogenous risk compounds both in natural and post-transplant settings of the disease. The maximal capacity to produce different levels of cytokines in response to noxious stimulation has been shown to be under genetic control and differs among liver graft recipients. Chemokine receptor 5delta32 polymorphism has been suggested to increase the incidence of ITBL and to reduce patient survival [64]. As demonstrated in a rat model, genetic polymorphisms of the multidrug resistance protein 2 (Mdr-2), which is involved in the regulative processes of bile

fluid composition, may negatively affect bile salt to phospholipid ratio, and contribute to cholangiocellular vulnerability [27]. Although, the exact mechanism is not yet understood in detail, both, donor and recipient genetics may interact. The expression of disease-related effectors may be individual and tissue dependant [65]. In spite of the pathogenetic heterogeneity, the role of genetic variants in the development of ITBL should be investigated in large scale multi-center trials regarding diagnostic, therapeutic and predictive values. Currently, no conclusion can be made considering ITBL-management.

6.7 External bile drainage

Internal or external drainage of the bile in the early postoperative period may have an impact on the development of non-anastomotic strictures [34]. Although the external bile drainage via T-tube is currently a subject of controversy, T-tube insertion has been demonstrated to reduce the risk for ITBL in several randomized studies and recent a meta-analysis [23, 34, 66-69]. T-tube may prevent the occurrence of ITBL and potentially reduces long-term morbidity especially regarding late strictures [34, 67]. The arterial perfusion of the biliary tract, which is at risk in transplant setting, remains one of the most important determinants of ITBL. Manipulations on ligamentum hepatoduodenale may affect the function of sphincter Oddi and result in discoordinated motility of the biliary tract. [6, 33]. Sphincter spasms may contribute to bile flow obstruction as demonstrated by elevated intra-biliary pressure after LT, which has been observed to be twice as high (up to 20mm H₂O) as in livers without dyskinesia of the biliary tract (10mm H₂O) (unpublished data). Elevated intra-biliary pressure may aggravate blood supply, which is predominantly maintained by periductal arterial plexus [20, 70]. Any kind of tools, which are capable of pressure reduction (intra-operative insertion of T-tube, pre-transplant sphincterotomy) should be regarded as helpful methods for ITBL-prevention. Moreover, T-tube has been demonstrated to prevent bile leakage in split-liver transplantation via pressure reduction [71]. Therefore, T-tube should be used in biliary tract reconstruction as side-to-side choledocho-choledochostomy during LT, in order to avoid the negative effect of elevated pressure and theoretically increased toxic impact of bile acids [59, 66].

6.8 Immunological aspects

Although a rejection is likely to induce significant damage in the biliary tree, no clear evidence is currently available about the role in the development of ITBL except for chronic ductopenic rejection [1, 2]. Compared to sinusoidal liver parenchyma, cholangiocytes are more vulnerable and seem to have less potential for regeneration [15]. Triggered by insufficient immunosuppression, immune complexes may induce inflammatory and fibrotic processes in tiny arteries of the biliary tract, thus forwarding ischemic damage [47, 72, 73]. Unfortunately, only inconsistent data are currently present regarding the role of immunosuppression mode and CMV-infection in the development of ITBL [1, 2]. Therefore, these factors should be re-evaluated in larger cohorts based on multi-center concepts. In contrast to patients transplanted due to virally or metabolically induced liver disease, the immunosuppression in patients with autoimmune component should be sufficient and preferably stronger according to current standards, in order to prevent rejection processes. ABO-incompatibility should be completely avoided because the antigens of the blood-type system may also be expressed on biliary epithelium and serve as immunologic target for preformed blood group antibodies.

7. Conclusion and future prospective

The development of non-anastomotic strictures in the biliary tract after LT is a serious post-transplant complication, potentially compromising the initial success of the surgical treatment of patients with advanced liver disease. ITBL represents a post-transplant biliary disease, which cannot be explained by vascular damage or PSC-recurrence. Due to a strong similarity to ischemia-induced biliary injury, and ischemia-reperfusion injury, disrupted or disturbed microcirculation seems to be the main pathogenic column. Most probably, ITBL develops in a highly individual manner from ischemic injury acquired in the peri-operative period predominantly before LT in spite of the restored arterial blood supply. The integrity of arterial perfusion separates ischemia-related strictures from IBL, playing a central role in the definition of the disease. In spite of the significant correlation between ITBL-incidence and pre-transplant ischemia, current definition of ITBL, based on radiological evidence of an undisturbed graft perfusion, does not depict the actual extent of ischemic damage. The assessment of ischemia- and reperfusion-related alterations should be therefore performed at the cellular level. Moreover, additive ischemic damage caused by thrombosis of the hepatic artery, occurring in about 10%, may contribute to the total cellular hypoxigenation. Not assessable pathogenic effect of prolonged ischemia in patients after a successful thrombectomy and restitution of blood supply may increase the risk for the development of ITBL in spite of formally intact vascular status. Unfortunately, current definition of ITBL does not allow a clear categorization of this subpopulation. Remarkable similarities of ITBL and PSC or biliary pathologies in non-transplant setting resulting from chronic inflammation, fibrotic remodeling with a secondary loss of organ function seem to be uniform. Although patients transplanted due to PSC may also develop ITBL, no diagnostic method can definitively guarantee the differentiation between ITBL and PSC-recurrence. Therefore, the relatively high chance of misclassification regarding patient cohorts undergoing statistical analysis of etiologic risk factors including epidemiologic aspects may explain differences in ITBL-incidence reported in the literature [10, 74]. After the exclusion of PSC-patients and managed post-transplant vascular complications the incidence of ITBL is supposed to be much lower than 20% [27, 40, 47, 75]. Recent analysis performed in a homogenous cohort after the exclusion of patients with prolonged re-arterialization and PSC-recurrence, seems to reflect the incidence of ITBL (3.9%) most accurately [1]. Therefore, a precise and uniform definition of the disease, awareness of risk factors and potential confounders may help to understand the mechanism of ITBL-development, prevent its occurrence and progression, select and initiate an adequate treatment. Any progress in the understanding of the development and clinical course of post-transplant biliary strictures should be welcome at a time of donor organ shortage.

8. References

- [1] Heidenhain C, Pratschke J, Puhl G, Neumann U, Pascher A, Veltzke-Schlieker W et al. Incidence of and risk factors for ischemic-type biliary lesions following orthotopic liver transplantation. *Transpl Int*; 23:14- 22.
- [2] Pascher A, Neuhaus P. Bile duct complications after liver transplantation. *Transpl Int* 2005;18:627-642.
- [3] Jeffrey GP, Brind AM, Ormonde DG, Frazer CK, Ferguson J, Bell R et al. Management of biliary tract complications following liver transplantation. *Aust N Z J Surg* 1999;69:717-722.

- [4] Koivusalo A, Isoniemi H, Salmela K, Edgren J, von Numers H, Hockerstedt K. Biliary complications in one hundred adult liver transplantations. *Scand J Gastroenterol* 1996;31:506-511.
- [5] Li S, Stratta RJ, Langnas AN, Wood RP, Marujo W, Shaw BW, Jr. Diffuse biliary tract injury after orthotopic liver transplantation. *Am J Surg* 1992;164:536-540.
- [6] Greif F, Bronsther OL, Van Thiel DH, Casavilla A, Iwatsuki S, Tzakis A et al. The incidence, timing, and management of biliary tract complications after orthotopic liver transplantation. *Ann Surg* 1994;219:40-45.
- [7] Moser MA, Wall WJ. Management of biliary problems after liver transplantation. *Liver Transpl* 2001;7:S46-52.
- [8] Lewis WD, Jenkins RL. Biliary strictures after liver transplantation. *Surg Clin North Am* 1994;74:967-978.
- [9] Hintze RE, Abou-Rebyeh H, Adler A, Veltzke W, Langrehr J, Wiedenmann B et al. [Endoscopic therapy of ischemia-type biliary lesions in patients following orthotopic liver transplantation]. *Z Gastroenterol* 1999;37:13-20.
- [10] Thethy S, Thomson B, Pleass H, Wigmore SJ, Madhavan K, Akyol M et al. Management of biliary tract complications after orthotopic liver transplantation. *Clin Transplant* 2004;18:647-653.
- [11] Porayko MK, Kondo M, Steers JL. Liver transplantation: late complications of the biliary tract and their management. *Semin Liver Dis* 1995;15:139-155.
- [12] Guichelaar MM, Benson JT, Malinchoc M, Krom RA, Wiesner RH, Charlton MR. Risk factors for and clinical course of non-anastomotic biliary strictures after liver transplantation. *Am J Transplant* 2003;3:885-890.
- [13] Ludwig J, Batts KP, MacCarty RL. Ischemic cholangitis in hepatic allografts. *Mayo Clin Proc* 1992;67:519-526.
- [14] Nakamura T, Tanaka K, Kiuchi T, Kasahara M, Oike F, Ueda M et al. Anatomical variations and surgical strategies in right lobe living donor liver transplantation: lessons from 120 cases. *Transplantation* 2002;73:1896-1903.
- [15] Strazzabosco M, Fabris L. Functional anatomy of normal bile ducts. *Anat Rec (Hoboken)* 2008;291:653-660.
- [16] Roskams TA, Theise ND, Balabaud C, Bhagat G, Bhathal PS, Bioulac-Sage P et al. Nomenclature of the finer branches of the biliary tree: canals, ductules, and ductular reactions in human livers. *Hepatology* 2004;39:1739-1745.
- [17] Crawford AR, Lin XZ, Crawford JM. The normal adult human liver biopsy: a quantitative reference standard. *Hepatology* 1998;28:323-331.
- [18] Sell S. Heterogeneity and plasticity of hepatocyte lineage cells. *Hepatology* 2001;33:738-750.
- [19] Abt P, Crawford M, Desai N, Markmann J, Olthoff K, Shaked A. Liver transplantation from controlled non-heart-beating donors: an increased incidence of biliary complications. *Transplantation* 2003;75:1659-1663.
- [20] Kono NN, Nakanuma Y. Ultrastructural and immunohistochemical studies of the intrahepatic peribiliary capillary plexus in normal livers and extrahepatic biliary obstruction in human beings. *Hepatology* 1992;15:411-418.
- [21] Neuhaus P, Platz KP. Liver transplantation: newer surgical approaches. *Baillieres Clin Gastroenterol* 1994;8:481-493.


- [22] Nuno J, Vicente E, Turrion VS, Pereira F, Ardaiz J, Cuervas V et al. Biliary tract reconstruction after liver transplantation: with or without T-tube? *Transplant Proc* 1997;29:564-565.
- [23] Paes-Barbosa FC, Massarollo PC, Bernardo WM, Ferreira FG, Barbosa FK, Raslan M et al. Systematic review and meta-analysis of biliary reconstruction techniques in orthotopic deceased donor liver transplantation. *J Hepatobiliary Pancreat Sci*;18:525-536.
- [24] Abou-Rebyeh H, Veltzke-Schlieker W, Radke C, Steinmuller T, Wiedenmann B, Hintze RE. Complete bile duct sequestration after liver transplantation, caused by ischemic-type biliary lesions. *Endoscopy* 2003;35:616-620.
- [25] Eurich D, Seehofer D, Veltzke-Schlieker W, Neuhaus R, Neumann U, Neuhaus P. Successful endoscopic and surgical management of non-anastomotic biliary strictures after liver transplantation - case report. *Ann Transplant* 2009;14:47-51.
- [26] Hindupur S, Yeung M, Shroff P, Fritz J, Kirmani N. Vanishing bile duct syndrome in a patient with advanced AIDS. *HIV Med* 2007;8:70-72.
- [27] Buis CI, Hoekstra H, Verdonk RC, Porte RJ. Causes and consequences of ischemic-type biliary lesions after liver transplantation. *J Hepatobiliary Pancreat Surg* 2006;13:517-524.
- [28] Urbani L, Mazzoni A, Bianco I, Grazzini T, De Simone P, Catalano G et al. The role of immunomodulation in ABO-incompatible adult liver transplant recipients. *J Clin Apher* 2008;23:55-62.
- [29] Hertl M, Hertl MC, Kluth D, Broelsch CE. Hydrophilic bile salts protect bile duct epithelium during cold preservation: a scanning electron microscopy study. *Liver Transpl* 2000;6:207-212.
- [30] O'Connor TP, Lewis WD, Jenkins RL. Biliary tract complications after liver transplantation. *Arch Surg* 1995;130:312-317.
- [31] Serrano MT, Garcia-Gil A, Arenas J, Ber Y, Cortes L, Valiente C et al. Outcome of liver transplantation using donors older than 60 years of age. *Clin Transplant*;24:543- 549.
- [32] Zoepf T, Maldonado-Lopez EJ, Hilgard P, Dechene A, Malago M, Broelsch CE et al. Diagnosis of biliary strictures after liver transplantation: which is the best tool? *World J Gastroenterol* 2005;11:2945-2948.
- [33] Pfau PR, Kochman ML. Endoscopic management of biliary tract disease. *Curr Opin Gastroenterol* 1999;15:448-453.
- [34] Weiss S, Schmidt SC, Ulrich F, Pascher A, Schumacher G, Stockmann M et al. Biliary reconstruction using a side-to-side choledochocholedochostomy with or without T-tube in deceased donor liver transplantation: a prospective randomized trial. *Ann Surg* 2009;250:766-771.
- [35] Hisatsune H, Yazumi S, Egawa H, Asada M, Hasegawa K, Kodama Y et al. Endoscopic management of biliary strictures after duct-to-duct biliary reconstruction in rightlobe living-donor liver transplantation. *Transplantation* 2003;76:810-815.
- [36] Quiroga S, Sebastia MC, Margarit C, Castells L, Boye R, Alvarez-Castells A. Complications of orthotopic liver transplantation: spectrum of findings with helical CT. *Radiographics* 2001;21:1085-1102.
- [37] Pecchi A, De Santis M, Gibertini MC, Tarantino G, Gerunda GE, Torricelli P et al. Role of magnetic resonance imaging in the detection of anastomotic biliary strictures after liver transplantation. *Transplant Proc*;43:1132-1135.

- [38] Colletini F, Kroencke TJ, Heidenhain C, de Bucourt M, Renz D, Schott E et al. Ischemic type biliary lesions after orthotopic liver transplantation: diagnosis with magnetic resonance cholangiography. *Transplant Proc*;43:2660-2663.
- [39] Schlitt HJ, Meier PN, Nashan B, Oldhafer KJ, Boeker K, Flemming P et al. Reconstructive surgery for ischemic-type lesions at the bile duct bifurcation after liver transplantation. *Ann Surg* 1999;229:137-145.
- [40] Rizk RS, McVicar JP, Emond MJ, Rohrmann CA, Jr., Kowdley KV, Perkins J et al. Endoscopic management of biliary strictures in liver transplant recipients: effect on patient and graft survival. *Gastrointest Endosc* 1998;47:128-135.
- [41] Thuluvath PJ, Atassi T, Lee J. An endoscopic approach to biliary complications following orthotopic liver transplantation. *Liver Int* 2003;23:156-162.
- [42] Jagannath S, Kalloo AN. Biliary Complications After Liver Transplantation. *Curr Treat Options Gastroenterol* 2002;5:101-112.
- [43] Colonna JO, 2nd, Shaked A, Gomes AS, Colquhoun SD, Jurim O, McDiarmid SV et al. Biliary strictures complicating liver transplantation. Incidence, pathogenesis, management, and outcome. *Ann Surg* 1992;216:344-350; discussion 350-342.
- [44] Boraschi P, Braccini G, Gigoni R, Sartoni G, Neri E, Filipponi F et al. Detection of biliary complications after orthotopic liver transplantation with MR cholangiography. *Magn Reson Imaging* 2001;19:1097-1105.
- [45] Guckelberger O, Stange B, Glanemann M, Lopez-Hanninen E, Heidenhain C, Jonas S et al. Hepatic resection in liver transplant recipients: single center experience and review of the literature. *Am J Transplant* 2005;5:2403-2409.
- [46] Filipponi F, Vistoli F, Urbani L, Mosca F. Extended right hepatectomy as graft-saving option in non-anastomotic biliary strictures after liver transplantation. *Hepatogastroenterology* 2002;49:1679-1681.
- [47] Rull R, Garcia Valdecasas JC, Grande L, Fuster J, Lacy AM, Gonzalez FX et al. Intrahepatic biliary lesions after orthotopic liver transplantation. *Transpl Int* 2001;14:129-134.
- [48] Sanchez-Urdazpal L, Gores GJ, Ward EM, Maus TP, Buckel EG, Steers JL et al. Diagnostic features and clinical outcome of ischemic-type biliary complications after liver transplantation. *Hepatology* 1993;17:605-609.
- [49] Zhu ZJ, Rao W, Sun JS, Cai JZ, Deng YL, Zheng H et al. Liver retransplantation for ischemic-type biliary lesions after orthotopic liver transplantation: a clinical report of 66 cases. *Hepatobiliary Pancreat Dis Int* 2008;7:471-475.
- [50] Nakamura K, Murase N, Becich MJ, Furuya T, Todo S, Fung JJ et al. Liver allograft rejection in sensitized recipients. Observations in a clinically relevant small animal model. *Am J Pathol* 1993;142:1383-1391.
- [51] Yska MJ, Buis CI, Monbaliu D, Schuurs TA, Gouw AS, Kahmann ON et al. The role of bile salt toxicity in the pathogenesis of bile duct injury after non-heart-beating porcine liver transplantation. *Transplantation* 2008;85:1625-1631.
- [52] Sanchez-Urdazpal L, Gores GJ, Ward EM, Hay E, Buckel EG, Wiesner RH et al. Clinical outcome of ischemic-type biliary complications after liver transplantation. *Transplant Proc* 1993;25:1107-1109.
- [53] Noack K, Bronk SF, Kato A, Gores GJ. The greater vulnerability of bile duct cells to reoxygenation injury than to anoxia. Implications for the pathogenesis of biliary strictures after liver transplantation. *Transplantation* 1993;56:495-500.

- [54] Sanchez-Urdazpal L, Gores GJ, Ward EM, Maus TP, Wahlstrom HE, Moore SB et al. Ischemic-type biliary complications after orthotopic liver transplantation. *Hepatology* 1992;16:49-53.
- [55] Kasahara M, Egawa H, Takada Y, Oike F, Sakamoto S, Kiuchi T et al. Biliary reconstruction in right lobe living-donor liver transplantation: Comparison of different techniques in 321 recipients. *Ann Surg* 2006;243:559-566.
- [56] Trotter JF, Wachs M, Everson GT, Kam I. Adult-to-adult transplantation of the right hepatic lobe from a living donor. *N Engl J Med* 2002;346:1074-1082.
- [57] Ikegami T, Taketomi A, Soejima Y, Yoshizumi T, Shimada M, Maehara Y. Characteristics of biliary reconstruction using a T-tube as compared with other methods in left-lobe adult living-donor liver transplantation. *J Hepatobiliary Pancreat Surg* 2008;15:346-347.
- [58] Ishiko T, Egawa H, Kasahara M, Nakamura T, Oike F, Kaihara S et al. Duct-to-duct biliary reconstruction in living donor liver transplantation utilizing right lobe graft. *Ann Surg* 2002;236:235-240.
- [59] Neuhaus P, Blumhardt G, Bechstein WO, Steffen R, Platz KP, Keck H. Technique and results of biliary reconstruction using side-to-side choledochocholedochostomy in 300 orthotopic liver transplants. *Ann Surg* 1994;219:426-434.
- [60] Canelo R, Hakim NS, Ringe B. Experience with histidine tryptophan ketoglutarate versus University Wisconsin preservation solutions in transplantation. *Int Surg* 2003;88:145-151.
- [61] Buis CI, Verdonk RC, Van der Jagt EJ, van der Hilst CS, Slooff MJ, Haagsma EB et al. Nonanastomotic biliary strictures after liver transplantation, part 1: Radiological features and risk factors for early vs. late presentation. *Liver Transpl* 2007;13:708-718.
- [62] Heidenhain C, Heise M, Jonas S, Ben-Asseur M, Puhl G, Mittler J et al. Retrograde reperfusion via vena cava lowers the risk of initial nonfunction but increases the risk of ischemic-type biliary lesions in liver transplantation--a randomized clinical trial. *Transpl Int* 2006;19:738-748.
- [63] Geuken E, Visser D, Kuipers F, Blokzijl H, Leuvenink HG, de Jong KP et al. Rapid increase of bile salt secretion is associated with bile duct injury after human liver transplantation. *J Hepatol* 2004;41:1017-1025.
- [64] Moench C, Uhrig A, Lohse AW, Otto G. CC chemokine receptor 5delta32 polymorphism-a risk factor for ischemic-type biliary lesions following orthotopic liver transplantation. *Liver Transpl* 2004;10:434-439.
- [65] Eurich D, Boas-Knoop S, Ruehl M, Schulz M, Carrillo ED, Berg T et al. Relationship between the interleukin-28b gene polymorphism and the histological severity of hepatitis C virus-induced graft inflammation and the response to antiviral therapy after liver transplantation. *Liver Transpl*;17:289-298.
- [66] Riediger C, Muller MW, Michalski CW, Huser N, Schuster T, Kleeff J et al. T-Tube or no T-tube in the reconstruction of the biliary tract during orthotopic liver transplantation: systematic review and meta-analysis. *Liver Transpl*;16:705-717.
- [67] Randall HB, Wachs ME, Somberg KA, Lake JR, Emond JC, Ascher NL et al. The use of the T tube after orthotopic liver transplantation. *Transplantation* 1996;61:258-261.
- [68] Vougas V, Rela M, Gane E, Muiesan P, Melendez HV, Williams R et al. A prospective randomised trial of bile duct reconstruction at liver transplantation: T tube or no T tube? *Transpl Int* 1996;9:392-395.

- [69] Rabkin JM, Orloff SL, Reed MH, Wheeler LJ, Corless CL, Benner KG et al. Biliary tract complications of side-to-side without T tube versus end-to-end with or without T tube choledochocholedochostomy in liver transplant recipients. *Transplantation* 1998;65:193-199.
- [70] Scanga AE, Kowdley KV. Management of biliary complications following orthotopic liver transplantation. *Curr Gastroenterol Rep* 2007;9:31-38.
- [71] Wojcicki M, Silva MA, Jethwa P, Gunson B, Bramhall SR, Mayer D et al. Biliary complications following adult right lobe ex vivo split liver transplantation. *Liver Transpl* 2006;12:839-844.
- [72] Oguma S, Belle S, Starzl TE, Demetris AJ. A histometric analysis of chronically rejected human liver allografts: insights into the mechanisms of bile duct loss: direct immunologic and ischemic factors. *Hepatology* 1989;9:204-209.
- [73] Ludwig J, Wiesner RH, Batts KP, Perkins JD, Krom RA. The acute vanishing bile duct syndrome (acute irreversible rejection) after orthotopic liver transplantation. *Hepatology* 1987;7:476-483.
- [74] Sanchez-Bueno F, Robles R, Ramirez P, Acosta F, Rodriguez JM, Lujan J et al. Hepatic artery complications after liver transplantation. *Clin Transplant* 1994;8:399-404.
- [75] Feller RB, Waugh RC, Selby WS, Dolan PM, Sheil AG, McCaughan GW. Biliary strictures after liver transplantation: clinical picture, correlates and outcomes. *J Gastroenterol Hepatol* 1996;11:21-25.

IntechOpen



Liver Transplantation - Technical Issues and Complications

Edited by Prof. Hesham Abdeldayem

ISBN 978-953-51-0015-7

Hard cover, 454 pages

Publisher InTech

Published online 10, February, 2012

Published in print edition February, 2012

This book covers a wide spectrum of topics including, but not limited to, the technical issues in living and deceased donor liver transplant procedures, cell and experimental liver transplantation, and the complications of liver transplantation. Some of the very important topics, such as the arterial reconstruction in living donor liver transplantation, biliary complications, and the post-transplant-lymphoproliferative disorders (PTLD), have been covered in more than one chapter.

How to reference

In order to correctly reference this scholarly work, feel free to copy and paste the following:

Dennis Eurich, Daniel Seehofer and Peter Neuhaus (2012). Ischemic Type Biliary Lesions, Liver Transplantation - Technical Issues and Complications, Prof. Hesham Abdeldayem (Ed.), ISBN: 978-953-51-0015-7, InTech, Available from: <http://www.intechopen.com/books/liver-transplantation-technical-issues-and-complications/ischemic-type-biliary-lesions>

INTECH
open science | open minds

InTech Europe

University Campus STeP Ri
Slavka Krautzeka 83/A
51000 Rijeka, Croatia
Phone: +385 (51) 770 447
Fax: +385 (51) 686 166
www.intechopen.com

InTech China

Unit 405, Office Block, Hotel Equatorial Shanghai
No.65, Yan An Road (West), Shanghai, 200040, China
中国上海市延安西路65号上海国际贵都大饭店办公楼405单元
Phone: +86-21-62489820
Fax: +86-21-62489821

© 2012 The Author(s). Licensee IntechOpen. This is an open access article distributed under the terms of the [Creative Commons Attribution 3.0 License](https://creativecommons.org/licenses/by/3.0/), which permits unrestricted use, distribution, and reproduction in any medium, provided the original work is properly cited.

IntechOpen

IntechOpen